



Universiteit
Leiden
The Netherlands

Ventriculostomy-associated hemorrhage: a risk assessment by radiographic simulation

Robertson, F.C.; Abd-El-Barr, M.M.; Mukundan, S.; Gormley, W.B.

Citation

Robertson, F. C., Abd-El-Barr, M. M., Mukundan, S., & Gormley, W. B. (2017).
Ventriculostomy-associated hemorrhage: a risk assessment by radiographic simulation.
Journal Of Neurosurgery, 127(3), 532-536. doi:10.3171/2016.8.JNS16538

Version: Publisher's Version

License: [Leiden University Non-exclusive license](#)

Downloaded from: <https://hdl.handle.net/1887/4307874>

Note: To cite this publication please use the final published version (if applicable).

Ventriculostomy-associated hemorrhage: a risk assessment by radiographic simulation

Faith C. Robertson, BS,^{1,2} Muhammad M. Abd-El-Barr, MD, PhD,^{1–3}
Srinivasan Mukundan Jr., MD, PhD,^{1–3} and William B. Gormley, MD, MPH, MBA^{1–3}

¹Harvard Medical School; and ²Cushing Neurosurgical Outcomes Center and ³Department of Neurological Surgery, Brigham and Women's Hospital, Harvard Medical School, Boston, Massachusetts

OBJECTIVE Ventriculostomy entry sites are commonly selected by freehand estimation of Kocher's point or approximations from skull landmarks and a trajectory toward the ipsilateral frontal horn of the lateral ventricles. A recognized ventriculostomy complication is intracranial hemorrhage from cortical vessel damage; reported rates range from 1% to 41%. In this report, the authors assess hemorrhagic risk by simulating traditional ventriculostomy trajectories and using CT angiography (CTA) with venography (CTV) data to identify potential complications, specifically from cortical draining veins.

METHODS Radiographic analysis was completed on 50 consecutive dynamic CTA/CTV studies obtained at a tertiary-care academic neurosurgery department. Image sections were 0.5 mm thick, and analysis was performed on a venous phase that demonstrated high-quality opacification of the cortical veins and sagittal sinus. Virtual ventriculostomy trajectories were determined for right and left sides using medical diagnostic imaging software. Entry points were measured along the skull surface, 10 cm posteriorly from the nasion, and 3 cm laterally for both left and right sides. Cannulation was simulated perpendicular to the skull surface. Distances between the software-traced cortical vessels and the virtual catheter were measured. To approximate vessel injury by twist drill and ventricular catheter placement, veins within a 3-mm radius were considered a hemorrhage risk.

RESULTS In 100 virtual lines through Kocher's point toward the ipsilateral ventricle, 19% were predicted to cause cortical vein injury and suspected hemorrhage (radius \leq 3 mm). Little difference existed between cerebral hemispheres (right 18%, left 20%). The average (\pm SD) distance from the trajectory line and a cortical vein was 7.23 ± 4.52 mm. In all 19 images that predicted vessel injury, a site of entry for an avascular zone near Kocher's point could be achieved by moving the trajectory less than 1.0 cm laterally and less than 1.0 cm along the anterior/posterior axis, suggesting that empirical measures are suboptimal, and that patient-specific coordinates based on preprocedural CTA/CVA imaging may optimize ventriculostomy in the future.

CONCLUSIONS In this institutional radiographic imaging analysis, traditional methods of ventriculostomy site selection predicted significant rates of cortical vein injury, matching described rates in the literature. CTA/CTV imaging potentiates identification of patient-specific cannulation sites and custom trajectories that avoid cortical vessels, which may lessen the risk of intracranial hemorrhage during ventriculostomy placement. Further development of this software is underway to facilitate stereotactic ventriculostomy and improve outcomes.

<https://thejns.org/doi/abs/10.3171/2016.8.JNS16538>

KEY WORDS external ventricular drainage; intracranial hemorrhage; Kocher's point; ventriculostomy; diagnostic technique

VENTRICULOSTOMY is one of the most common neurosurgical procedures, with more than 40,000 performed annually for both diagnostic and therapeutic purposes.¹ Historically, ventriculostomy placement involved freehand catheterization using skull surface anat-

omy to estimate an appropriate entry site, first performed by Keen in 1890.¹² Later, Kocher used a craniometer to estimate ventricle location by anatomical skull landmarks, followed by Dandy cannulating the anterior and occipital ventricular horns in 1918,⁷ to the device-assisted method

ABBREVIATIONS CTA = CT angiography; CTV = CT venography.

SUBMITTED March 9, 2016. **ACCEPTED** August 4, 2016.

INCLUDE WHEN CITING Published online December 2, 2016; DOI: 10.3171/2016.8.JNS16538.

described by Ghajar in 1985. Ghajar's approach involved catheterization perpendicular to the skull surface at Kocher's point, which lies 1 cm anterior to the coronal suture in the midpupillary line, or 10 cm above the nasion and approximately 3 cm lateral to the sagittal suture. Cannulation perpendicular to Kocher's point continues to predominate in clinical practice.^{9–11,13,14,23} However, image guidance and frameless stereotaxy are increasingly being used to improve catheterization of the ipsilateral frontal horn.^{2,4,11,17,21,22} While new image-guided methods prioritize accuracy of ventricle entry, little is known about the damage to cortical vasculature during ventriculostomy and whether iatrogenic hemorrhage can be prevented.

Intracranial hemorrhage from cortical vessel tearing during ventriculostomy is a well-recognized complication; reported rates range from 1% to 41%, although recent meta-analyses provide a more accurate assessment of risks of this procedure.^{3,6} Bauer et al. reported a 7.0% cumulative rate of hemorrhage and 0.8% risk of significant hemorrhage, defined as patient death or neurological deficit requiring surgical intervention. Importantly, some hemorrhages may be missed during clinical assessment, despite their appearance on CT, so the authors conducted a subgroup analysis to evaluate radiographically detected hemorrhage. In this subset, rates of hemorrhage and significant hemorrhage were 20.3% and 3.7%, respectively. These data demonstrate the clinical relevance of iatrogenic hemorrhage during ventriculostomy and underscore a need to optimize ventriculostomy techniques in the future.

Preprocedural CT angiography (CTA) and venography (CTV) and design of patient-specific cannula trajectories may reduce the incidence of hemorrhage from ventriculostomy. In this study, we used radiographic simulation to investigate the risk of cortical vessel injury during a planned ventriculostomy. Additionally, we examined distances between the catheter and vessels to elucidate whether CTA/CTV imaging could identify patient-specific cannulation sites that minimize the risk of intracranial hemorrhage.

Methods

The study was performed under the supervision of the Internal Review Board of Partners Health Care and Brigham and Women's Hospital.

Patient Population

Fifty consecutive dynamic CTA/CTV studies were examined (July 2014 to June 2015). The cohort included the most recent adult patients with normal ventricular anatomy undergoing CTA with contrast within a tertiary-care academic neurosurgery department. Patients with midline brain shift or grossly abnormal frontal lobe anatomy due to a large parenchymal lesion were excluded.

Radiographic Simulation of Ventriculostomy Trajectories

The dynamic CTA image sections were 0.5 mm thick, and analysis was performed on a venous phase that demonstrated high-quality opacification of the cortical veins and sagittal sinus.⁵ The approach for virtual ventriculostomy was modeled after the Ghajar Guide technique described in 1985 to direct a ventricular catheter at a 90°

angle to the skull surface at Kocher's point.⁹ The entry site where the twist drill or bur hole would be placed was determined with medical diagnostic imaging software (VitreaCore; Fig. 1) by measuring along the skull surface, 10 cm posteriorly from the nasion in the sagittal plane, and 3 cm laterally in the coronal plane for both right and left sides. Cannulation was simulated perpendicular to the skull surface in the coronal plane. A virtual line marked the catheter trajectory; the yellow-arrow tool allowed trajectory visualization in all windows.

The 3D reconstruction was used to examine vascular anatomy. Vessels were identified using software tools for CT angiography vessel tracking and segmentation. In cross-sections perpendicular to the virtual cannula, the distance between vessels and the midline of the trajectory was measured. To approximate cortical venous injury by twist drill or cannulation, veins within a 3-mm radius were considered at risk for iatrogenic damage and hemorrhage. This distance was chosen because the thread diameter of subarachnoid screws and twist drills are generally between 5.6 mm and 6 mm (Codman/Johnson & Johnson). Therefore, any major cortical vessels beneath the dura in that 3-mm radius of Kocher's point were estimated to be at risk. For the trajectories that involved vessel injury, the surrounding area was surveyed for the nearest avascular zone in which a cannula could be safely placed.

Results

The patient population ($n = 50$) consisted of 66% women ($n = 33$) with a mean age of 50 years (range 20–76 years). The indication for CTA was tumor related in 79.6% of cases. Other indications included stroke, sinus thrombosis, hemorrhage, and arteriovenous fistula suspicion. Both right and left hemispheres was examined, and of the 100 virtual lines through Kocher's point toward the ipsilateral ventricle, the average distance from the trajectory line to the nearest cortical vein was 7.23 ± 4.52 mm and half of the vessels were more than 5.9 mm (Fig. 2).

Overall, 19% of simulated ventriculostomies were within a 3-mm radius of a major cortical vein and were predicted to cause vessel injury and suspected hemorrhage. There was no significant difference in vessel injury by side (right 18%, left 20%). In all 19 patient studies that predicted vessel injury, avascular zones more than 6.0 mm in diameter were identified near Kocher's point. A site of entry for an avascular zone could be achieved by moving the trajectory less than 1.0 cm laterally and less than 1.0 cm along the anterior/posterior axis (Fig. 3). This finding suggests that each patient has a ventriculostomy site that would allow accurate placement of a cannula without vascular damage; however, the coordinates of the avascular zone differed by patient (Fig. 4).

Discussion

Despite more than a century of technological advances, ventriculostomy, one of the most common neurosurgical procedures, continues to be performed as it was originally described in 1890. Freehand ventricular catheter placement according to anatomical landmarks remains the principally used method, and is currently the standard of

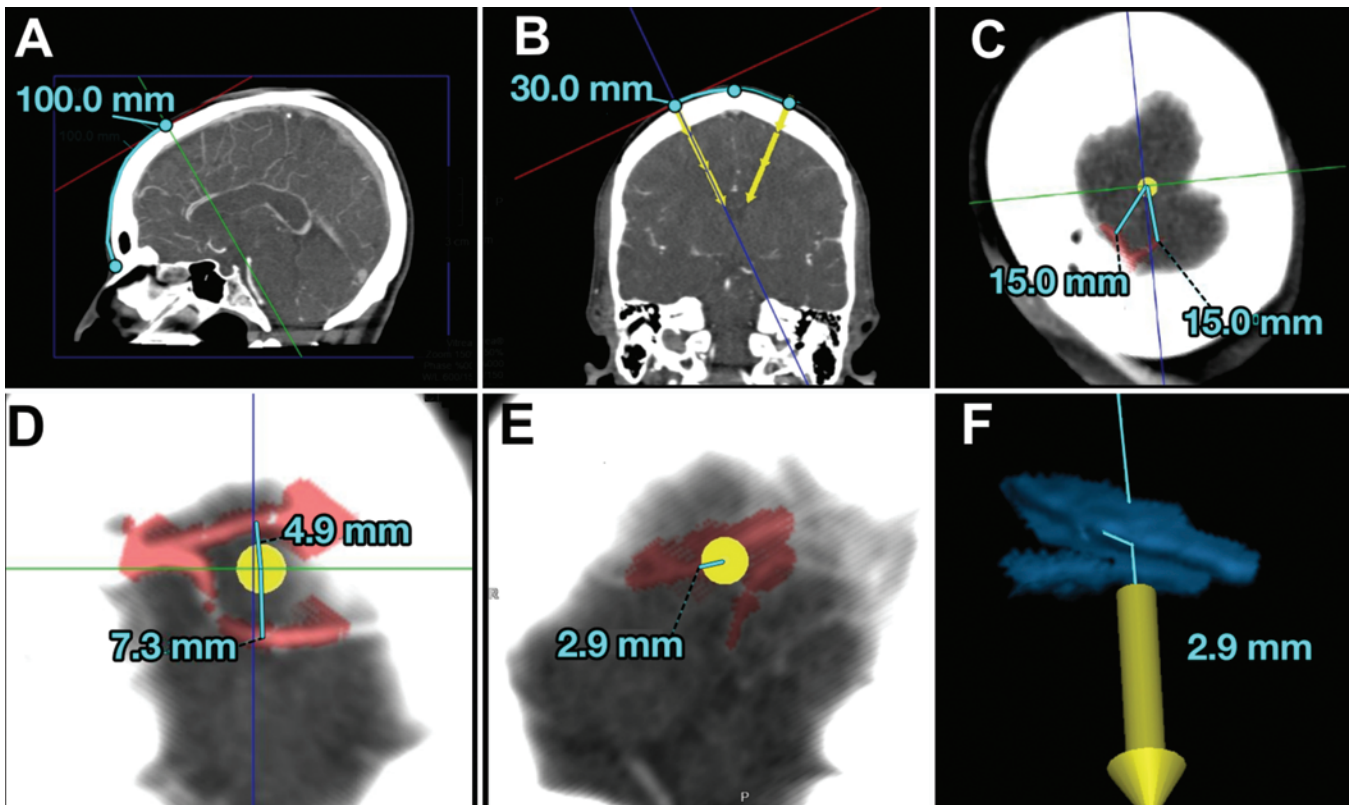


FIG. 1. Three-dimensional reconstructions performed using medical diagnostic imaging software to depict ventriculostomy trajectory (yellow arrow) and risk of cortical vessel injury. The entry site was marked by measuring along the skull surface, 10 cm posteriorly from the nasion in the sagittal plane (A), and 3 cm laterally in the coronal plane for both right and left sides (B), with perpendicular entry. The rest of the images (C–F) demonstrate measurements between a ventricular catheter and the nearest cortical vessel (C–E, red; F, blue). Figure is available in color online only.

care for ventricular cannulation.⁸ While the freehand pass approach allows for simplicity and efficiency at the bedside or in the operating room, 10%–40% of cases require revisions or have associated complications.¹⁰ In particular, there is a considerable rate of iatrogenic damage to the cortical vessels during catheter placement. A recent meta-analysis of ventriculostomy-associated hemorrhage detected on CT suggests that hemorrhagic complications are present in 20.3% of ventriculostomy attempts, and rates of significant hemorrhage are as high as 3.7%.³ These complication rates underscore the need to improve accurate and safe catheter placement.

Introduction of the Ghajar Guide was intended to increase the accuracy of ventricular cannulation by facilitating a truly perpendicular vector of entry at Kocher's point. When the Ghajar Guide was compared with the freehand pass technique, the Ghajar Guide tended to permit accurate ventricle placement in fewer attempts, although there was no statistically significant difference between the two techniques.¹⁵ Since then, endoscopy, ultrasonography, and neuronavigation are being increasingly used in selected cases. A recent nationwide survey revealed that more than half of neurosurgeons and neurosurgical residents in the US prefer to use image-guided techniques,¹⁸ and recent trials are aiming to use smartphone technology in conjunction with MRI and CT images.^{19,20} The development

of an easy-to-use, portable, image-guided system could reduce the need for multiple passes and improve the rate of accurate catheter placement in a more efficient, safe, and cost-effective manner. Nonetheless, most image-guided studies have a primary outcome of ventricular catheter tip location, and while incidental hemorrhage may be considered as a secondary outcome, little attention is dedicated to prevention of cortical vessel damage.

In this study, we aimed to use radiographic analysis of CT angiograms to elucidate the incidence of cortical vessel damage when the theoretical ventriculostomy approach was taken, and to determine if patient vessel anatomy varied in a way that suggested a more appropriate entry location exists. Traditional methods of ventriculostomy site selection using the premise of Ghajar's guided technique with entry perpendicular to the skull surface at Kocher's point predicted significant rates of cortical vein injury, matching described rates in the literature: 19% of attempts intersecting with a cortical vessel, compared with 20.3% noted by Bauer and colleagues.⁴ Additionally, our study suggests that a more appropriate, patient-specific entry site may exist. Vessel tracing revealed an average distance of 7.23 mm between the trajectory line and a cortical vessel, and a site of entry for an avascular zone could be achieved with minor adjustments to the trajectory (< 1.0 cm laterally and < 1.0 cm along the anterior/posterior axis) in all

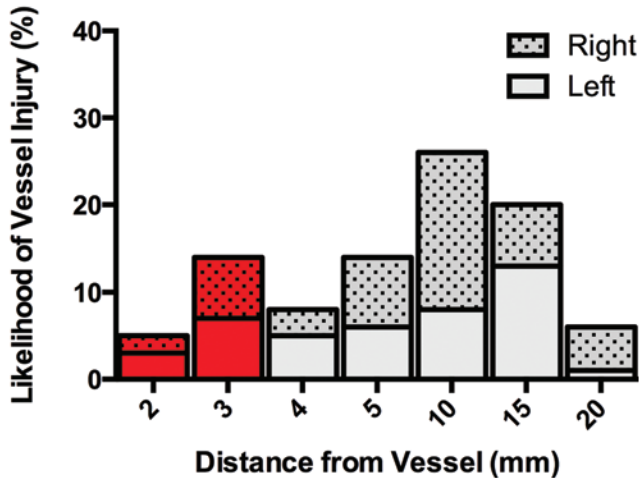


FIG. 2. Bar graph showing the distance between the ventricular catheter and nearest cortical vessel, according to a simulated ventriculostomy trajectory on CTA. Assuming a twist-drill diameter of 6 mm, vessels within a 3-mm radius (red) were considered at risk for iatrogenic damage. Figure is available in color online only.

19 cases of predicted vessel injury. However, it is critical to acknowledge that the coordinates of the avascular zone differed by patient. The anatomical variability suggests that a new empirical entry site is not recommended, but rather a patient-specific coordinate based on preprocedural CTA/CTV.

While stereotactic planning to ensure ventricle catheterization with minimal vessel injury would be ideal for patient safety, there are important obstacles. Equipment availability and the additional preparation time and cost required for CTA scans may hinder its adoption, as a survey study found that 94% of neurosurgeons would not use technology that could improve the accuracy of ventriculostomy if it added more than 10 minutes to the procedure.¹⁶ The concern that image guidance takes longer than the freehand pass technique, and is not accessible outside

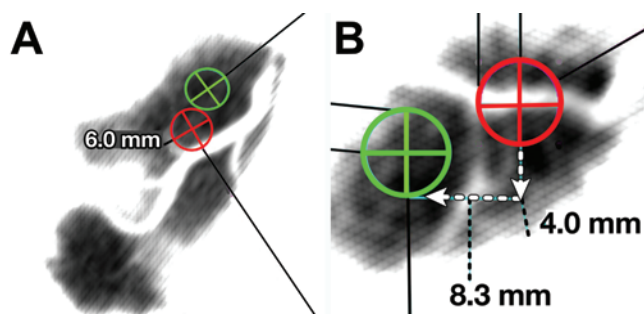


FIG. 3. Measuring avascular zones on CT angiograms. For those trajectories that involved vessel injury, the cortical vessel anatomy was viewed in a plane perpendicular to the trajectory, and the area was surveyed for the nearest avascular zone in which a cannula could be safely placed. The circles are 6 mm in diameter to reflect the area of the twist drill. Red circles represent the empirical entry at Kocher's point for 2 representative images (A and B) where vessel injury was predicted. The distance from the empirical entry site to an avascular zone (green circles) was measured (B). An avascular zone existed in all cases. Figure is available in color online only.

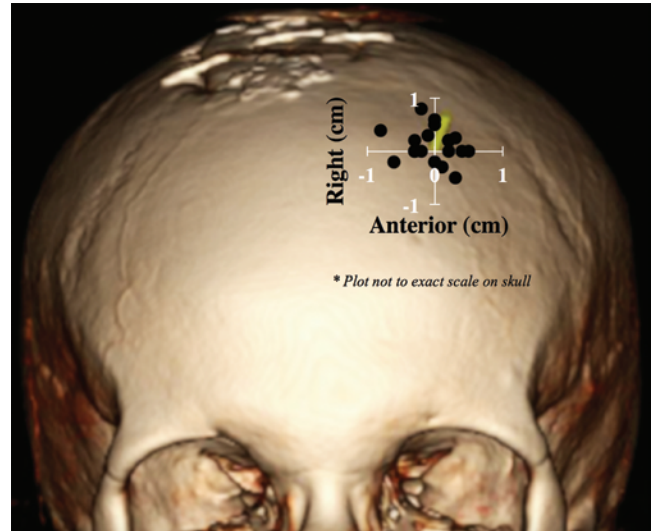


FIG. 4. Calculating an ideal ventriculostomy site. Avascular zones near Kocher's point were attainable with minor adjustments to the trajectory (< 1.0 cm laterally and < 1.0 cm along the anterior/posterior axis) in all 19 cases of predicted vessel injury. The nearest avascular zone is indicated by the black dots on the skull. Notably, the coordinates of the nearest avascular zone differed by patient, underscoring the importance of patient-specific ventriculostomy planning. Figure is available in color online only.

of the operating room, represents a real problem. However, many patients are already undergoing CT angiograms under routine protocol, so the added cost and time could be solely contingent on digital vessel analysis and the method of projecting the trajectory. Furthermore, image-guidance technology is rapidly improving and requiring less equipment and effort by the neurosurgeon. To improve ventricular placement in a more user-friendly fashion, recent trials are aiming to use smartphone technology in conjunction with MR and CT images. In the smartphone VENTRI-GUIDE trial, an entry point is projected onto the skull and a rectangular trajectory orientation for the catheter is displayed as a dotted line; it is simpler than the previous bulky, expensive equipment.^{19,20} If venogram data could be integrated into algorithms for handheld technology, neurosurgeons may be able to perform bedside ventriculostomy procedures that account for both patient-specific ventricular and vascular anatomy.

This study was limited in scope to identify the percentage of times that Kocher's point is associated with potential peril. Because obtaining a venogram on patients who undergo ventriculostomy is not standard practice in our department, we were unable to include patients who underwent CTA/CTV prior to ventriculostomy, and the studies included were part of a separate preoperative assessment by departmental skull-base surgeons, with minimal overlap in these patient populations. Furthermore, this cohort had grossly normal ventricular anatomy; patients with intraventricular hemorrhage may present a greater challenge due to midline shift, but this further emphasizes the importance of image-guided ventriculostomy, as imaging facilitates navigation of aberrant patient anatomy. Given these limitations, the study objectives were met,

and based upon this initial analysis, it may now be possible to implement protocols that include CTA/CTV in the pre-ventriculostomy workup and to translate this work into a prospective study of patients undergoing ventriculostomy. The speed of digital vessel mapping will impact its adoption, and the development of real-time algorithms that identify patient-specific ventriculostomy entry sites are currently underway.

Conclusions

Given the prevalence of ventriculostomy and risk of associated hemorrhage, a significant number of patients may benefit from a more strategic procedural method. In the era of using advanced technology for personalized care, we underscore the importance of exploring patient-specific image-guided ventriculostomy that incorporates cortical vessel anatomy, as opposed to the ventricle anatomy alone. Optimizing image-guided ventriculostomy in this manner can improve accuracy, reduce complications, and improve patient care.

References

1. Abu-Serieh B, Ghassempour K, Duprez T, Raftopoulos C: Stereotactic ventriculoperitoneal shunting for refractory idiopathic intracranial hypertension. **Neurosurgery** **60**:1039–1044, 2007
2. American Association of Neurological Surgeons: **National Neurosurgical Procedural Statistics, 2006 Survey**. Rolling Meadows, IL: AANS, 2008
3. Azeem SS, Origitano TC: Ventricular catheter placement with a frameless neuronavigational system: a 1-year experience. **Neurosurgery** **60** (4 Suppl 2):243–248, 2007
4. Bauer DF, Razdan SN, Bartolucci AA, Markert JM: Meta-analysis of hemorrhagic complications from ventriculostomy placement by neurosurgeons. **Neurosurgery** **69**:255–260, 2011
5. Bi WL, Brown PA, Abolfotoh M, Al-Mefty O, Mukundan S Jr, Dunn IF: Utility of dynamic computed tomography angiography in the preoperative evaluation of skull base tumors. **J Neurosurg** **123**:1–8, 2015
6. Binz DD, Toussaint LG III, Friedman JA: Hemorrhagic complications of ventriculostomy placement: a meta-analysis. **Neurocrit Care** **10**:253–256, 2009
7. Dandy WE: Ventriculography following the injection of air into the cerebral ventricles. **Ann Surg** **68**:5–11, 1918
8. Dunn IF, Fierichs K, Day A, Kim DH: Ventriculostomy, in Schmidek HH, Roberts DW (eds): **Schmidek and Sweet, Operative Neurosurgical Techniques: Indications, Methods, and Results, ed 5**. Philadelphia: Saunders, 2006, pp 35–36
9. Ghajar JB: A guide for ventricular catheter placement. Technical note. **J Neurosurg** **63**:985–986, 1985
10. Huyette DR, Turnbow BJ, Kaufman C, Vaslow DF, Whiting BB, Oh MY: Accuracy of the freehand pass technique for ventriculostomy catheter placement: retrospective assessment using computed tomography scans. **J Neurosurg** **108**:88–91, 2008
11. Kandasamy J, Hayhurst C, Clark S, Jenkinson MD, Byrne P, Karabatsou K, et al: Electromagnetic stereotactic ventriculoperitoneal CSF shunting for idiopathic intracranial hypertension: a successful step forward? **World Neurosurg** **75**:155–160, 32–33, 2011
12. Keen W: Surgery of the lateral ventricles of the brain. **Lancet** **2**:553–555, 1890
13. Lind CR, Correia JA, Law AJ, Kejrival R: A survey of surgical techniques for catheterising the cerebral lateral ventricles. **J Clin Neurosci** **15**:886–890, 2008
14. McWilliam RC, Stephenson JB: Rapid bedside technique for intracranial pressure monitoring. **Lancet** **2**:73–75, 1984
15. O’Leary ST, Kole MK, Hoover DA, Hysell SE, Thomas A, Shaffrey CI: Efficacy of the Ghajar Guide revisited: a prospective study. **J Neurosurg** **92**:801–803, 2000
16. O’Neill BR, Velez DA, Braxton EE, Whiting D, Oh MY: A survey of ventriculostomy and intracranial pressure monitor placement practices. **Surg Neurol** **70**:268–273, 2008
17. Park J, Son W, Park KS, Kim MY, Lee J: Calvarial slope affecting accuracy of Ghajar Guide technique for ventricular catheter placement. **J Neurosurg** **124**:1429–1433, 2016
18. Rehman T, Rehman AU, Rehman A, Bashir HH, Ali R, Bhimani SA, et al: A US-based survey on ventriculostomy practices. **Clin Neurol Neurosurg** **114**:651–654, 2012
19. Sarrafzadeh A, Smoll N, Schaller K: Guided (VENTRI-GUIDE) versus freehand ventriculostomy: study protocol for a randomized controlled trial. **Trials** **15**:478, 2014
20. Thomale UW, Knitter T, Schaumann A, Ahmadi SA, Ziegler P, Schulz M, et al: Smartphone-assisted guide for the placement of ventricular catheters. **Childs Nerv Syst** **29**:131–139, 2013
21. Wilson TJ, Stetler WR Jr, Al-Holou WN, Sullivan SE: Comparison of the accuracy of ventricular catheter placement using freehand placement, ultrasonic guidance, and stereotactic neuronavigation. **J Neurosurg** **119**:66–70, 2013
22. Woerdeman PA, Willems PW, Han KS, Hanlo PW, Berkelbach van der Sprenkel JW: Frameless stereotactic placement of ventriculoperitoneal shunts in undersized ventricles: a simple modification to free-hand procedures. **Br J Neurosurg** **19**:484–487, 2005
23. Woo H, Kang DH, Park J: Preoperative determination of ventriculostomy trajectory in ventriculoperitoneal shunt surgery using a simple modification of the standard coronal MRI. **J Clin Neurosci** **20**:1754–1758, 2013

Disclosures

The authors report no conflict of interest concerning the materials or methods used in this study or the findings specified in this paper.

Author Contributions

Conception and design: all authors. Acquisition of data: Robertson, Mukundan. Analysis and interpretation of data: Robertson, Abd-El-Barr, Mukundan. Drafting the article: Robertson, Abd-El-Barr. Critically revising the article: all authors. Reviewed submitted version of manuscript: all authors. Statistical analysis: Robertson. Administrative/technical/material support: Mukundan. Study supervision: Gormley, Mukundan.

Correspondence

William B. Gormley, Department of Neurosurgery, Brigham and Women’s Hospital and Harvard Medical School, 75 Francis St., Boston, MA 02115. email: wgormley@partners.org.