



Universiteit  
Leiden  
The Netherlands

## Discovering biomarkers and druggable targets in uveal melanoma

Wierenga, A.P.A.

### Citation

Wierenga, A. P. A. (2026, June 24). *Discovering biomarkers and druggable targets in uveal melanoma*. Retrieved from <https://hdl.handle.net/1887/4306948>

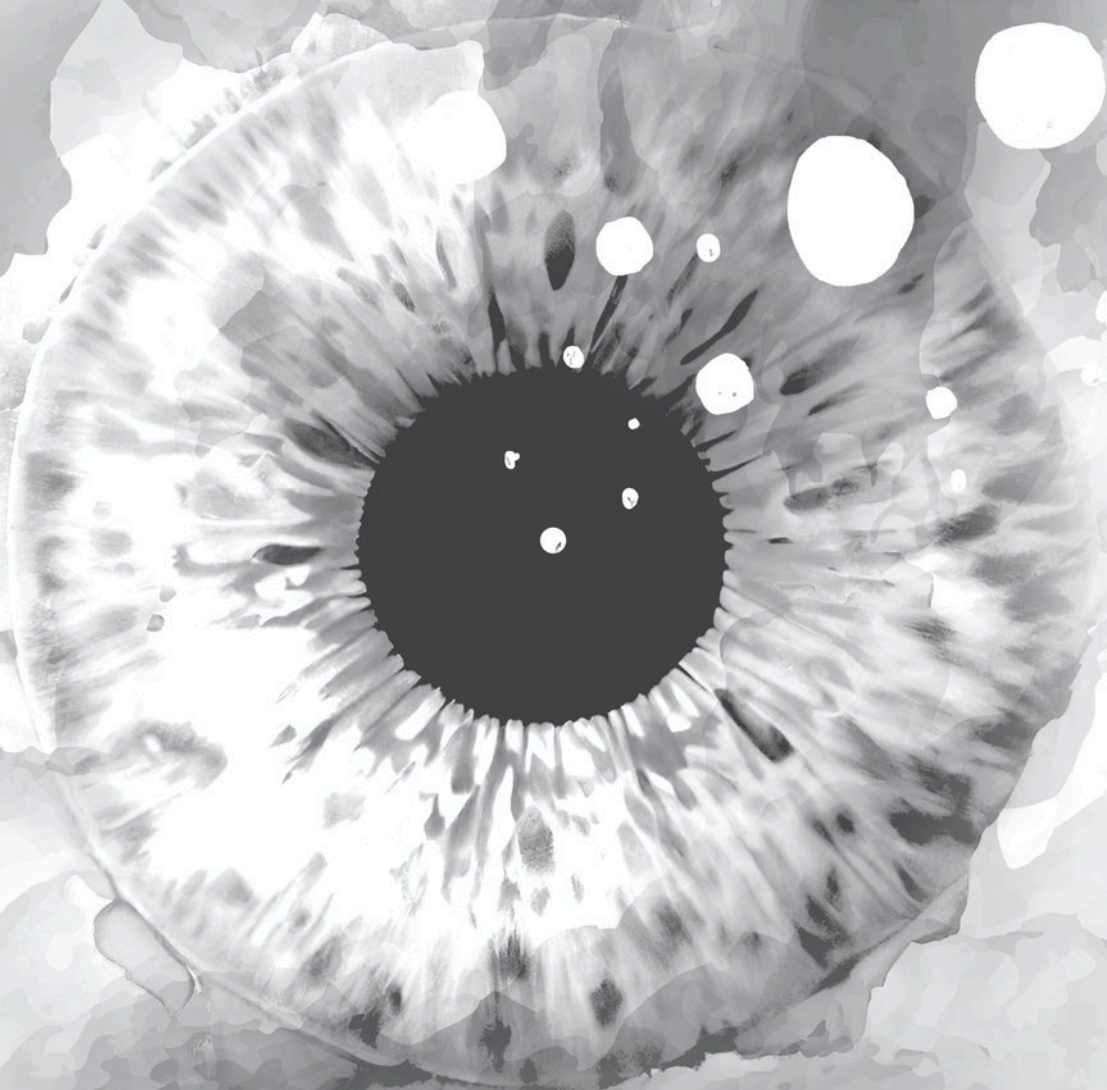
Version: Publisher's Version

License: [Licence agreement concerning inclusion of doctoral thesis in the Institutional Repository of the University of Leiden](#)

Downloaded from: <https://hdl.handle.net/1887/4306948>

**Note:** To cite this publication please use the final published version (if applicable).

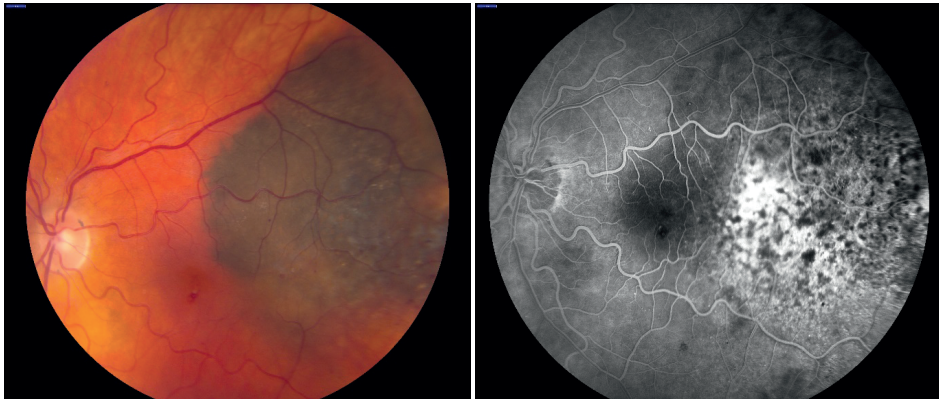
# Chapter 1



## General introduction and thesis outline

## Introduction

Uveal Melanoma (UM) is a melanocytic tumor that originates in the iris, the ciliary body or the choroid; together, these structures are called the *uvea* which is derived from the Latin word *uva*, meaning grape [1]. A UM is a malignant tumor and often starts as a benign nevus. The clinical presentation includes blurred vision, visual field loss, complaints of floaters, photopsia, pain or a visible tumor. However, about a third of UM patients are asymptomatic and only diagnosed by an optician or ophthalmologist when somebody comes for glasses or check-up [2]. Treatment of the primary tumor includes radiotherapy – e.g. brachytherapy with a radioactive plaque, stereotactic radiation or proton beam therapy – or enucleation. In spite of excellent results of local treatment, 50% of the patients may develop metastases; until recently, there were hardly any treatment options for metastatic disease [3]. In 2021, a new type of bi-specific monoclonal antibody, tebentafusp, was shown to prolong life of patients with UM metastases [4]. As the main organ affected by metastases is the liver, liver specific treatments have been developed. Recently, a randomized study (the CHOPIN study) investigated liver perfusion with melphalan with and without the addition of two immune checkpoint inhibitors. The combination of the three treatments led to a better 1-year progression free survival than liver perfusion alone [5]. While it is important to be able to delay progression, no cure has as yet been developed and in order to achieve lasting success in the treatment of these metastases, it is essential to develop a better understanding about the metastatic process and biology of this tumor and its metastases [6-8].



**Figure 1:** Pictures of a Uveal Melanoma as depicted on fluorescein angiography (FAG).

## Epidemiology and Risk factors

UM is a rare disease, with an incidence varying between 5 and 9.5 cases per million [9-13]. UM specifically occurs in people of European ancestry, with a light eye color and a light skin. A low level of cellular melanin in choroidal melanocytes constitutes a risk factor for developing UM [14]. The presence of multiple moles and melanocytosis are associated with an increased risk of developing UM and a choroidal nevus carries a small risk for transformation into a UM [15-17].

Clinical features of UM patients with a high risk of developing metastases include an older age, a large tumor basal diameter and high tumor thickness, involvement of the ciliary body and extraocular tumor extension [9, 18, 19].

During progression from a normal melanocyte to a nevus and then a melanoma, specific genetic changes occur, which differ from those in the much more common cutaneous melanoma (CM). CM is distinctly different in genetic background, pathology as well as clinical disease. As opposed to UM, the lethality of CM is lower because of more success in treatment of metastases with targeted chemotherapy or with checkpoint inhibitors [20, 21]. Important driver mutations in CM include mutations in *v-raf murine sarcoma viral oncogene homolog B1 (BRAF)* or *Neuroblastoma RAS viral oncogene homolog (NRAS)* [22]. Important genes associated with a high risk of developing a cutaneous melanoma, so called high-penetrance melanoma susceptibility genes, include *CDKN2A*, *POT1* and *MC1R* [23, 24]. In UM, susceptibility genes are germline mutations in the *BAP1* gene (Abdel-Rahman, Pilarski et al. 2011, Wiesner, Obenaus et al. 2011).

In UM, mutually-exclusive mutations in *GNAQ* or *GNA11* occur early in a melanocyte. These mutations can be found in around 83% of UM patients [25, 26]. In a collaboration with Dr Madigan in Australia, our lab showed that these mutations already occur in choroidal nevi [27]. Another type of mutation is seen in *CYSLTR2*, which is much rarer and found to occur in nevi as well as in UM [28].

While the mutations in *GNAQ* and *GNA11* are considered driver mutations, several other changes may subsequently occur, leading to malignant progression. These changes include chromosomal rearrangements and other mutations. These additional oncogenic mutations also usually occur in a mutually-exclusive manner, and include mutations in the *BRCA1-associated protein-1 (BAP1)*, *SF3B1* and *EIF1AX* genes, with the latter two mutations leading to a relatively better prognosis than *BAP1* mutated tumors [6, 29, 30].

When looking at chromosomal aberrations, a frequent change is loss of the long arm of chromosome 6 (6q) and gain of the short arm of chromosome 6 (6p) [31]. Important prognostic changes occur with chromosome 8q: gain of 8q may occur early during the pathogenic process and is associated with the development of metastases [32,33].

The most important chromosomal prognostic parameter that determines prognosis is loss of one chromosome 3 (Monosomy 3, M3) [34]. The (BAP1) gene is situated on chromosome 3, in the 3p21 region, and a mutation in this gene together with M3 is associated with a bad outcome. It leads to loss of BAP1 protein and mRNA expression in the tumor [35, 38].

The exact role of the BAP1 protein is unclear, but inactivating mutations in the gene of this deubiquitinating enzyme are seen in multiple malignancies. *BAP1* is a tumor suppressor involved in the epigenetic regulation of gene expression [36, 39]. Loss of one chromosome 3 and loss of BAP1 protein expression in the tumor is associated with an increase in inflammation [40, 41].

## Inflammation

The presence of infiltrating immune cells is a hallmark of cancer. In most tumors, the presence of more inflammatory cells in the tumor might lead to better immune recognition, eliciting a better immune response and thus a better chance of survival. In UM, the presence of tumor-infiltrating leucocytes and macrophages is associated with a worse prognosis [42, 43]. Several studies on the identification of Tumor-Infiltrating Lymphocytes (TILs) in primary UM (PUM) showed that TILs in UM are related with an immunosuppressive tumor microenvironment. CD8+ regulatory T cells, in addition to chemokines, may help to generate a pathway for metastatic development of the tumor [44-46]. Another related cell type is the macrophage: in general, there are two types of Tumor-Associated Macrophages (TAMs), M1 and M2 macrophages; especially the latter is typically associated with UM [47]. A high density of TAMs as well as TILs is associated with a poor prognosis [48]. The presence of TILs and TAMs, coupled with a high HLA expression, constitutes the so-called “inflammatory phenotype” [40, 43], which is related to a bad prognosis.

The presence of an inflammatory phenotype is associated with specific chromosome aberrations in UM: Monosomy of chromosome 3 is related to a highly-inflamed tumor [40, 49]. Specifically, gain of 8q is related to the presence of more TAM in the tumor and loss of BAP1 protein expression is associated with the influx of T cells as well as increased numbers of TAM [41]. The genes encoding *HLA* expression are located on chromosome 6. Gain of the short arm (6p) and loss of the long arm (6q) are chromosomal aberrations found in UM [50]. However, loss of heterozygosity of

chromosome 6p did not affect HLA expression [51]. HLA expression is essential for presenting antigens and eliciting an immune response from the body. Therefore, HLA expression in UM is a well-studied factor with regard to the potential immunogenicity of the tumor in a UM patient [52]. A high HLA Class I and II expression is related to bad survival [53]. The presence of T lymphocytes and/or macrophages may be responsible for an increased HLA Class I and II expression [54].

## Immune privilege

The immune-privileged environment in the eye is unique in the human body and known to be essential in the success of corneal transplantations; the corneal allograft is protected from rejection because of the absent or limited induction of immune responses and lack of immunological recognition [55]. Similarly, experimental mouse models show that the immune privilege of the eye provides a less hostile environment for the tumor to grow. This alleged increased threshold of immune responsiveness is illustrated by the lack of treatment response in UM patients, when treated with immune-checkpoint inhibitors alone (Jager et al. 2020). In addition to the immune privilege, the *BAP1* mutation has been described to be involved in the upregulation of genes that have an immunosuppressive role in the tumor environment. It has been suggested that this negatively impacts the treatment success with immunotherapeutic approaches [56].

## Prognostic indicators

Chromosomal aberrations, *BAP1* mutation status and the mRNA gene expression profile [57-59] all provide good prognostic biomarkers in UM. In order to obtain the chromosome status of a tumor, one needs a tumor sample, either from tumor tissue after enucleation of the eye or from a tumor biopsy, which is challenging and not without risk [60]. Since UM spread via the haematogenous route, different studies have focussed on blood biomarkers to develop a liquid biopsy [61].

Current methods to detect metastatic disease, as part of standard clinical care, include ultrasound of the liver and serum liver function enzyme levels [62]. Metastatic UM often presents as micro metastases. When liver metastases are detected, they often have spread throughout the liver and resection of the metastases is not an option anymore. Liver perfusion may then be an option.

## Angiogenesis

In order for a tumor to grow it needs new blood vessels. The ability to do this depends on the stimulation by pro-angiogenic cytokines. A tumor's angiogenic ability can be measured by studying the microvascular density (MVD), which was previously found to be increased in tumors with monosomy 3 and *BAP1* loss [63, 64]. A high MVD was

found to be associated with an increased expression of angiopoietin 2 (ANGPT2), Von Willebrand Factor (VWF) and increased numbers of tumor-infiltrating macrophages and lymphocytes.

## **Pigmentation in UM and its metastases**

A UM originates from a uveal melanocyte. It is the melanocyte that contains the pigment typical of the uveal tract. Given that having a light eye color and a light skin type are important risk factors for developing a UM, the role of pigmentation as a predisposing factor in tumor development as well as in tumor behavior is well-studied, but the exact pathophysiology remains unclear [65].

## **Treatment of UM metastases**

While there are multiple treatment options for primary UM, there are no standard treatment options for metastatic disease. In cancer treatment, e.g. in cutaneous melanoma, the last decade has seen major improvements in curative and life-extending treatments, especially thanks to the development of immunotherapy. However, in UM, these so-called biological therapies are very rarely effective. Treatment options in case of hepatic metastases include partial hepatectomy in case of solitary metastases and percutaneous hepatic perfusion with melphalan or systemic treatment with tebentafusp [4, 21]. A problem in studying clinical efficacy of new treatments for metastatic disease in a Randomised Controlled Treatment (RCT) trial setting, is the low incidence of UM and thus low number of patients with metastatic disease [6, 66, 67]. As described above, the combination of percutaneous liver perfusion with two immune checkpoint inhibitors led to a longer progression-free survival [5].

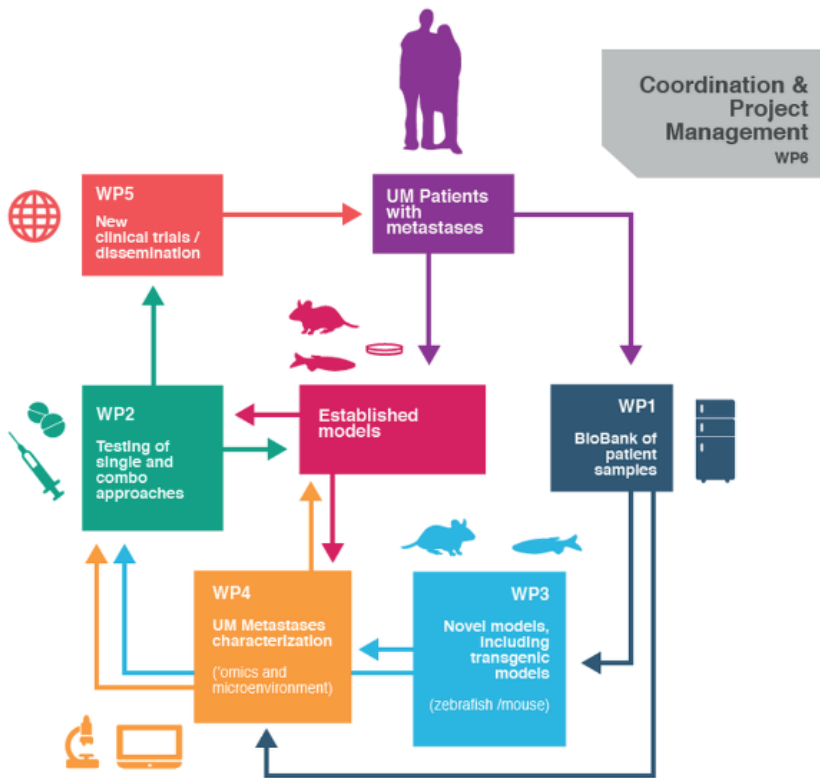
In order to optimize testing of new therapeutic combinations for the treatment of metastatic disease, drugs and combinations of drugs are first tested on UM cell lines and later in preclinical cancer models, for instance in a mouse patient-derived xenograft (PDX) model [68, 69]. These PDX model better mimic the immune environment of a tumor in the body [70].

## **A research consortium**

The research described in this thesis has been part of the UM CURE consortium. This is a Horizon 2020 project funded by The European Union for Research & Innovation program, under grant agreement 667787. UM CURE was comprised of 12 partners who bring their own expertise to the consortium in a symphonic action. The partners came from seven European countries, and include: Institut Curie, Seeding Science and Pep-Therapy, from France, the Cancer Research UK Manchester Institute and the University of Liverpool from the United Kingdom (UK), Leiden University and Leiden University

Medical Centre (LUMC) as well as PamGene, from The Netherlands, the University of Trento from Italy, the Jagiellonian University in Krakow, Poland, the Champalimaud Foundation from Portugal and the Melanoma Patient Network Europe, Sweden.

The goals of UM CURE include the establishment of a European UM virtual Biobank registry, identifying new therapeutic targets, testing new experimental models, both *in vitro* and *in vivo*, to study the genetics, pathophysiology and immune landscape of UM and its metastases and testing drugs. All of these approaches have the purpose of finding a cure for metastatic disease (Figure 2) [7] ([www.umcure2020.org](http://www.umcure2020.org)).



**Figure 2.** The UM CURE 2020 Approach and Methodology

**This thesis**

The studies described in this thesis focus on the current situation in UM and the analysis of potential biomarkers in order to find potential treatment targets for metastatic disease.

In **Chapter 2**, we analyse the developments in UM over time. Due to the presence of a large database containing the clinical and histopathological data of UM that led to enucleation of the eye at the Leiden University Medical Centre, we could evaluate survival over five decades.

Survival in UM depends on the development of metastatic disease. In **Chapter 3**, the current situation on treatment with immune checkpoint inhibitors in both uveal and conjunctival melanoma is described. We further determined the presence of PD-L1, a well-known T-cell inhibitor, in the anterior chamber fluid in UM-containing eyes that had been enucleated at the LUMC.

**Chapter 4** further describes the identification of potential biomarkers in the aqueous humor of enucleated UM eyes, which leads to the identification of three prognostic groups in UM.

Continuing the identification of biomarkers in aqueous humor, **Chapter 5** describes the innovative process of testing soluble HLA (sHLA) in the aqueous humour of UM-containing eyes and the prognostic outcome of sHLA and its association with tumor characteristics.

**Chapter 6** focuses on the important process of angiogenesis in tumor growth and describes that in UM, it is the expression of Angiopoietin-2 but not Angiopoietin-1 in tissue and aqueous humor that correlates with prognosis.

With a light iris color being an important risk factor for developing a UM, **Chapter 7** describes the role of iris pigmentation including a comparison of the distribution of iris colour between Dutch UM patients and healthy Dutch controls.

**Chapter 8** continues the focus on iris pigmentation and demonstrates that genetic aberrations in UM show greater impact on metastasis-free survival in individuals with light iris color versus dark iris color, hypothesizing the importance of pigmentation in the pathophysiological pathway or even as a biomarker.

When studying kinase and phosphatase activity, **Chapter 9** describes the use of functional phosphoproteomic assays in order to find potential pathways and biomarkers. Kinase activity in primary UM is increased through the presence of infiltrating leukocytes, while phosphatase activity is a characteristic of the tumor itself. This may have implications for therapy.

**Chapter 10** includes a summary and discussion of this thesis as well as future perspectives.

## References

1. Krantz BA, Dave N, Komatsubara KM, Marr BP, Carvajal RD. Uveal melanoma: epidemiology, etiology, and treatment of primary disease. *Clinical ophthalmology* (Auckland, NZ). 2017;11:279–89.
2. Damato EM, Damato BE. Detection and time to treatment of uveal melanoma in the United Kingdom: an evaluation of 2,384 patients. *Ophthalmology*. 2012;119(8):1582–9.
3. Dogrusoz M, Jager MJ, Damato B. Uveal Melanoma Treatment and Prognostication. *Asia-Pacific journal of ophthalmology* (Philadelphia, Pa). 2017;6(2):186–96.
4. Nathan P, Hassel JC, Rutkowski P, Baurain JF, Butler MO, Schlaak M, et al. Overall Survival Benefit with Tebentafusp in Metastatic Uveal Melanoma. *N Engl J Med*. 2021;385(13):1196–206.
5. van den Hoek L, Burgmans M, Tong T, Goeman J, Speetjens F, Zunder S, et al. Percutaneous hepatic perfusion combined with ipilimumab and nivolumab for metastatic uveal melanoma (CHOPIN): a single-centre, open-label, randomised, phase 2 trial. *Lancet Oncol*. 2026;27(3):372–82.
6. Jager MJ, Shields CL, Cebulla CM, Abdel-Rahman MH, Grossniklaus HE, Stern MH, et al. Uveal melanoma. *Nat Rev Dis Primers*. 2020;6(1):24.
7. Rodrigues M, Koning L, Coupland SE, Jochemsen AG, Marais R, Stern MH, et al. So Close, yet so Far: Discrepancies between Uveal and Other Melanomas. A Position Paper from UM Cure 2020. *Cancers*. 2019;11(7).
8. Singh AD, Bergman L, Seregard S. Uveal melanoma: epidemiologic aspects. *Ophthalmology clinics of North America*. 2005;18(1):75–viii.
9. Virgili G, Gatta G, Ciccolallo L, Capocaccia R, Biggeri A, Crocetti E, et al. Incidence of uveal melanoma in Europe. *Ophthalmology*. 2007;114(12):2309–15.
10. Singh AD, Turell ME, Topham AK. Uveal melanoma: trends in incidence, treatment, and survival. *Ophthalmology*. 2011;118(9):1881–5.
11. Mahendraraj K, Lau CS, Lee I, Chamberlain RS. Trends in incidence, survival, and management of uveal melanoma: a population-based study of 7,516 patients from the Surveillance, Epidemiology, and End Results database (1973-2012). *Clinical ophthalmology* (Auckland, NZ). 2016;10:2113–9.
12. Baily C, O'Neill V, Dunne M, Cunningham M, Gullo G, Kennedy S, et al. Uveal Melanoma in Ireland. *Ocul Oncol Pathol*. 2019;5(3):195–204.
13. Conte S, Lagacé F, Ghazawi FM, Cattelan L, Nath S, Dhillon J, et al. Uveal melanoma incidence trends in Canada: 1992-2010 vs. 2011-2017. *Front Med (Lausanne)*. 2022;9:1001799.
14. Nayman T, Bostan C, Logan P, Burnier MN, Jr. Uveal Melanoma Risk Factors: A Systematic Review of Meta-Analyses. *Current eye research*. 2017;42(8):1085–93.
15. Seddon JM, Gragoudas ES, Glynn RJ, Egan KM, Albert DM, Blitzer PH. Host factors, UV radiation, and risk of uveal melanoma. A case-control study. *Archives of ophthalmology* (Chicago, Ill : 1960). 1990;108(9):1274–80.
16. Singh AD, De Potter P, Fijal BA, Shields CL, Shields JA, Elston RC. Lifetime prevalence of uveal melanoma in white patients with oculo(dermal) melanocytosis. *Ophthalmology*. 1998;105(1):195–8.
17. Chien JL, Sioufi K, Surakiatchanukul T, Shields JA, Shields CL. Choroidal nevus: a review of prevalence, features, genetics, risks, and outcomes. *Curr Opin Ophthalmol*. 2017;28(3):228–37.
18. Shields CL, Kaliki S, Shah SU, Luo W, Furuta M, Shields JA. Iris melanoma: features and prognosis in 317 children and adults. *J aapos*. 2012;16(1):10–6.
19. Damato B. Progress in the management of patients with uveal melanoma. The 2012 Ashton Lecture. *Eye* (London, England). 2012;26(9):1157–72.
20. Amaro A, Gangemi R, Piaggio F, Angelini G, Barisione G, Ferrini S, et al. The biology of uveal melanoma. *Cancer metastasis reviews*. 2017;36(1):109–40.
21. Carvajal RD, Sacco JJ, Jager MJ, Eschelmann DJ, Olofsson Bagge R, Harbour JW, et al. Advances in the clinical management of uveal melanoma. *Nat Rev Clin Oncol*. 2023;20(2):99–115.
22. Newton-Bishop J, Bishop DT, Harland M. Melanoma Genomics. *Acta Derm Venereol*. 2020.
23. Landi MT, Bishop DT, MacGregor S, Machiela MJ, Stratigos AJ, Ghiorzo P, et al. Genome-wide association meta-analyses combining multiple risk phenotypes provide insights into the genetic architecture of cutaneous melanoma susceptibility. *Nat Genet*. 2020;52(5):494–504.
24. Newton Bishop JA, Gruis NA. Genetics: what advice for patients who present with a family history of melanoma? *Semin Oncol*. 2007;34(6):452–9.

25. Van Raamsdonk CD, Bezrookove V, Green G, Bauer J, Gaugler L, O'Brien JM, et al. Frequent somatic mutations of GNAQ in uveal melanoma and blue naevi. *Nature*. 2009;457(7229):599–602.
26. Van Raamsdonk CD, Griewank KG, Crosby MB, Garrido MC, Vemula S, Wiesner T, et al. Mutations in GNA11 in uveal melanoma. *The New England journal of medicine*. 2010;363(23):2191–9.
27. Vader MJC, Madigan MC, Versluis M, Suleiman HM, Gezgin G, Gruis NA, et al. GNAQ and GNA11 mutations and downstream YAP activation in choroidal nevi. *British journal of cancer*. 2017;117(6):884–7.
28. Nell RJ, Menger NV, Versluis M, Luyten GPM, Verdijk RM, Madigan MC, et al. Involvement of mutant and wild-type CYSLTR2 in the development and progression of uveal nevi and melanoma. *BMC cancer*. 2021;21(1):164.
29. Harbour JW, Onken MD, Roberson ED, Duan S, Cao L, Worley LA, et al. Frequent mutation of BAP1 in metastasizing uveal melanomas. *Science*. 2010;330(6009):1410–3.
30. Smit KN, Jager MJ, de Klein A, Kiliç E. Uveal melanoma: Towards a molecular understanding. *Progress in retinal and eye research*. 2020;75:100800.
31. Kiliç E, van Gils W, Lodder E, Beverloo HB, van Til ME, Mooy CM, et al. Clinical and cytogenetic analyses in uveal melanoma. *Invest Ophthalmol Vis Sci*. 2006;47(9):3703–7.
32. Cassoux N, Rodrigues MJ, Plancher C, Asselain B, Levy-Gabriel C, Lumbroso-Le Rouic L, et al. Genome-wide profiling is a clinically relevant and affordable prognostic test in posterior uveal melanoma. *The British journal of ophthalmology*. 2014;98(6):769–74.
33. Versluis M, de Lange MJ, van Pelt SI, Ruivenkamp CA, Kroes WG, Cao J, et al. Digital PCR validates 8q dosage as prognostic tool in uveal melanoma. *PLoS one*. 2015;10(3):e0116371.
34. Dogrusoz M, Jager MJ. Genetic prognostication in uveal melanoma. *Acta Ophthalmol*. 2018;96(4):331–47.
35. Harbour JW, Onken MD, Roberson EDO, Duan S, Cao L, Worley LA, et al. Frequent mutation of BAP1 in metastasizing uveal melanomas. *Science (New York, NY)*. 2010;330(6009):1410–3.
36. Kuznetsov JN, Aguero TH, Owens DA, Kurtenbach S, Field MG, Durante MA, et al. BAP1 regulates epigenetic switch from pluripotency to differentiation in developmental lineages giving rise to BAP1-mutant cancers. *Sci Adv*. 2019;5(9):eaax1738–eaax.
37. van Essen TH, van Pelt SI, Versluis M, Bronkhorst IH, van Duinen SG, Marinkovic M, et al. Prognostic parameters in uveal melanoma and their association with BAP1 expression. *The British journal of ophthalmology*. 2014;98(12):1738–43.
38. Koopmans AE, Verdijk RM, Brouwer RW, van den Bosch TP, van den Berg MM, Vaarwater J, et al. Clinical significance of immunohistochemistry for detection of BAP1 mutations in uveal melanoma. *Mod Pathol*. 2014;27(10):1321–30.
39. Ventii KH, Devi NS, Friedrich KL, Chernova TA, Tighiouart M, Van Meir EG, et al. BRCA1-associated protein-1 is a tumor suppressor that requires deubiquitinating activity and nuclear localization. *Cancer Res*. 2008;68(17):6953–62.
40. Maat W, Ly LV, Jordanova ES, de Wolff-Rouendaal D, Schalijs-Delfos NE, Jager MJ. Monosomy of chromosome 3 and an inflammatory phenotype occur together in uveal melanoma. *Invest Ophthalmol Vis Sci*. 2008;49(2):505–10.
41. Gezgin G, Dogrusoz M, van Essen TH, Kroes WGM, Luyten GPM, van der Velden PA, et al. Genetic evolution of uveal melanoma guides the development of an inflammatory microenvironment. *Cancer immunology, immunotherapy : CII*. 2017;66(7):903–12.
42. Maat W, Jordanova ES, van Zelderen-Bhola SL, Barthen ER, Wessels HW, Schalijs-Delfos NE, et al. The heterogeneous distribution of monosomy 3 in uveal melanomas: implications for prognostication based on fine-needle aspiration biopsies. *Archives of pathology & laboratory medicine*. 2007;131(1):91–6.
43. Jager MJ, Hurks HM, Levitskaya J, Kiessling R. HLA expression in uveal melanoma: there is no rule without some exception. *Human immunology*. 2002;63(6):444–51.
44. de Waard-Siebinga I, Hilders CG, Hansen BE, van Delft JL, Jager MJ. HLA expression and tumor-infiltrating immune cells in uveal melanoma. *Graefes Arch Clin Exp Ophthalmol*. 1996;234(1):34–42.
45. Ksander BR, Chen PW. Immunotherapy of uveal melanoma. *Dev Ophthalmol*. 1999;30:220–30.
46. Bronkhorst IH, Vu TH, Jordanova ES, Luyten GP, Burg SH, Jager MJ. Different subsets of tumor-infiltrating lymphocytes correlate with macrophage influx and monosomy 3 in uveal melanoma. *Invest Ophthalmol Vis Sci*. 2012;53(9):5370–8.
47. Bronkhorst IH, Jager MJ. Uveal melanoma: the inflammatory microenvironment. *Journal of innate immunity*. 2012;4(5-6):454–62.

48. Krishna Y, McCarthy C, Kalirai H, Coupland SE. Inflammatory cell infiltrates in advanced metastatic uveal melanoma. *Human pathology*. 2017;66:159–66.
49. Bronkhorst IH, Ly LV, Jordanova ES, Vrolijk J, Versluis M, Luyten GP, et al. Detection of M2-macrophages in uveal melanoma and relation with survival. *Invest Ophthalmol Vis Sci*. 2011;52(2):643–50.
50. van Gils W, Kilic E, Bruggenwirth HT, Vaarwater J, Verbiest MM, Beverloo B, et al. Regional deletion and amplification on chromosome 6 in a uveal melanoma case without abnormalities on chromosomes 1p, 3 and 8. *Melanoma research*. 2008;18(1):10–5.
51. Metzelaar-Blok JA, Jager MJ, Moghaddam PH, van der Slik AR, Giphart MJ. Frequent loss of heterozygosity on chromosome 6p in uveal melanoma. *Human immunology*. 1999;60(10):962–9.
52. Jager MJ, Hurks HMH, Levitskaya J, Kiessling R. HLA expression in uveal melanoma: there is no rule without some exception. *Human immunology*. 2002;63(6):444–51.
53. Blom DJ, Luyten GP, Mooy C, Kerkvliet S, Zwiderman AH, Jager MJ. Human leukocyte antigen class I expression. Marker of poor prognosis in uveal melanoma. *Invest Ophthalmol Vis Sci*. 1997;38(9):1865–72.
54. van Essen TH, van Pelt SI, Bronkhorst IH, Versluis M, Nemati F, Laurent C, et al. Upregulation of HLA Expression in Primary Uveal Melanoma by Infiltrating Leukocytes. *PloS one*. 2016;11(10):e0164292.
55. Niederhorn JY. Immune privilege and immune regulation in the eye. *Advances in immunology*. 1990;48:191–226.
56. Figueiredo CR, Kalirai H, Sacco JJ, Azevedo RA, Duckworth A, Slupsky JR, et al. Loss of BAP1 expression is associated with an immunosuppressive microenvironment in uveal melanoma, with implications for immunotherapy development. *J Pathol*. 2020;10.1002/path.5384.
57. Zuidervaart W, van der Velden PA, Hurks MH, van Nieuwpoort FA, Out-Luiting CJ, Singh AD, et al. Gene expression profiling identifies tumour markers potentially playing a role in uveal melanoma development. *Br J Cancer*. 2003;89(10):1914–9.
58. Tschentscher F, Hüsing J, Hölter T, Kruse E, Dresen IG, Jöckel KH, et al. Tumor classification based on gene expression profiling shows that uveal melanomas with and without monosomy 3 represent two distinct entities. *Cancer Res*. 2003;63(10):2578–84.
59. Onken MD, Worley LA, Ehlers JP, Harbour JW. Gene expression profiling in uveal melanoma reveals two molecular classes and predicts metastatic death. *Cancer Res*. 2004;64(20):7205–9.
60. Field MG, Harbour JW. Recent developments in prognostic and predictive testing in uveal melanoma. *Curr Opin Ophthalmol*. 2014;25(3):234–9.
61. Bande Rodríguez MF, Fernandez Marta B, Lago Baameiro N, Santiago-Varela M, Silva-Rodríguez P, Blanco-Teijeiro MJ, et al. Blood Biomarkers of Uveal Melanoma: Current Perspectives. *Clinical ophthalmology (Auckland, NZ)*. 2020;14:157–69.
62. Donoso LA, Berd D, Augsburger JJ, Mastrangelo MJ, Shields JA. Metastatic uveal melanoma. Pretherapy serum liver enzyme and liver scan abnormalities. *Archives of ophthalmology (Chicago, Ill : 1960)*. 1985;103(6):796–8.
63. Mäkitie T, Summanen P, Tarkkanen A, Kivelä T. Microvascular density in predicting survival of patients with choroidal and ciliary body melanoma. *Invest Ophthalmol Vis Sci*. 1999;40(11):2471–80.
64. Brouwer NJ, Gezgin G, Wierenga APA, Bronkhorst IHG, Marinkovic M, Luyten GPM, et al. Tumour Angiogenesis in Uveal Melanoma Is Related to Genetic Evolution. *Cancers*. 2019;11(7).
65. Markiewicz A, Donizy P, Nowak M, Krzyżiński M, Elas M, Płonka PM, et al. Amelanotic Uveal Melanomas Evaluated by Indirect Ophthalmoscopy Reveal Better Long-Term Prognosis Than Pigmented Primary Tumours-A Single Centre Experience. *Cancers*. 2022;14(11).
66. Rantala ES, Hernberg MM, Piperno-Neumann S, Grossniklaus HE, Kivelä TT. Metastatic uveal melanoma: The final frontier. *Prog Retin Eye Res*. 2022;90:101041.
67. Salaün H, de Koning L, Saint-Ghislain M, Servois V, Ramtohl T, Garcia A, et al. Nivolumab plus ipilimumab in metastatic uveal melanoma: a real-life, retrospective cohort of 47 patients. *Oncimmunology*. 2022;11(1):2116845.
68. Kassumeh S, Arrow S, Kafka A, Luft N, Priglinger SG, Wolf A, et al. Pharmacological drug screening to inhibit uveal melanoma metastatic cells either via EGF-R, MAPK, mTOR or PI3K. *Int J Ophthalmol*. 2022;15(10):1569–76.
69. Glinkina K, Nemati F, Teunisse A, Gelmi MC, Etienne V, Kuipers MJ, et al. Preclinical Evaluation of Trabectedin in Combination With Targeted Inhibitors for Treatment of Metastatic Uveal Melanoma. *Invest Ophthalmol Vis Sci*. 2022;63(13):14.
70. Carita G, Némati F, Decaudin D. Uveal Melanoma Patient-Derived Xenografts. *Ocul Oncol Pathol*. 2015;1(3):161–9.