



Universiteit
Leiden
The Netherlands

Timing-specific debridement, antibiotics, and implant retention and 2-stage revision for megaprosthesis-related infection: optimizing the window period for improved outcomes

Sharma, R.K.; Lumban-Gaol, I.; Vinayak, U.; Budhiparama, N.C.

Citation


Sharma, R. K., Lumban-Gaol, I., Vinayak, U., & Budhiparama, N. C. (2025). Timing-specific debridement, antibiotics, and implant retention and 2-stage revision for megaprosthesis-related infection: optimizing the window period for improved outcomes. *Arthroplasty Today*, 33. doi:10.1016/j.artd.2025.101688

Version: Publisher's Version

License: [Creative Commons CC BY-NC-ND 4.0 license](#)

Downloaded from: <https://hdl.handle.net/1887/4289359>

Note: To cite this publication please use the final published version (if applicable).



Original Research

Timing-specific Debridement, Antibiotics, and Implant Retention and 2-Stage Revision for Megaprosthesis-Related Infection: Optimizing the Window Period for Improved Outcomes

Rajeev K. Sharma, MS, DNB, Mch^a, Imelda Lumban-Gaol, MD^b, Udit Vinayak, MS, DNB^a, Nicolaas C. Budhiparama, MD, PhD^{b, c, d, *}

^a Institute of Orthopaedics & Joint Replacement, Moolchand Medcity, New Delhi, India

^b Nicolaas Institute of Constructive Orthopaedic Research & Education Foundation for Arthroplasty & Sports Medicine at Medistra Hospital, Jakarta, Indonesia

^c Department of Orthopaedic and Traumatology, Faculty of Medicine, Universitas Airlangga, Surabaya, Indonesia

^d Department of Orthopaedics, Leiden University Medical Centre, Leiden, The Netherlands

ARTICLE INFO

Article history:

Received 15 November 2024

Received in revised form

14 March 2025

Accepted 18 March 2025

Available online 24 April 2025

Keywords:

Knee arthroplasty

Periprosthetic joint infection

PJI

Revision knee arthroplasty

2-stage exchange

ABSTRACT

Background: This study aimed to evaluate the outcomes of debridement, antibiotics, and implant retention (DAIR) procedures and 2-stage revision surgeries in patients with periprosthetic joint infection following megaprosthesis, including treatment failure; the patient-reported outcomes; and to determine the survival rates of the revised megaprosthesis.

Methods: A retrospective study of 30 patients diagnosed with periprosthetic joint infection following megaprosthesis between 2018 and 2023, with minimum 1-year follow-up. Patients with previous unsuccessful debridement in other institutions were excluded. Patients presenting within 4 weeks of megaprosthesis implantation underwent the DAIR procedure, while those presenting after this window were taken for a 2-stage revision surgery. The primary outcome was treatment failure, defined as persistent wound complication or the need for subsequent surgical intervention. The secondary outcomes included patient-reported outcomes, assessed with the Oxford Hip Score and Oxford Knee Score, and the survival rates of the revised megaprosthesis.

Results: The mean follow-up duration for all patients was 38 ± 12.6 months. Improvement was found for Oxford Hip Score and Oxford Knee Score with mean 34.22 ± 9.2 and 32.40 ± 8.1 , respectively, at the 1-year follow-up. DAIR achieved an 81% success rate (13 out of 16) and 2-stage exchange had a 71.4% success rate (10 out of 14).

Conclusions: Both DAIR and 2-stage exchange procedures yielded favorable functional outcomes with satisfactory 2-year survival function. Careful patient selection and indication management are crucial for optimal results.

Level of evidence: Level IV.

© 2025 The Authors. Published by Elsevier Inc. on behalf of The American Association of Hip and Knee Surgeons. This is an open access article under the CC BY-NC-ND license (<http://creativecommons.org/licenses/by-nc-nd/4.0/>).

Introduction

Revision arthroplasty, in the setting of a megaprosthesis, poses significant challenges for orthopaedic surgeons, with periprosthetic

joint infection (PJI) being the most common and morbid cause for revision. [1,2] Prompt diagnosis and appropriate treatment are essential to achieve a good prognosis. [3] The inherently compromised physiology of patients undergoing megaprosthesis reconstruction frequently results in these cases being secondary to low-virulence organisms. [4] These infections rarely manifest with classical clinical features like discharging sinuses or wound dehiscence. It is essential to maintain a low threshold of suspicion for clinical symptoms and laboratory markers, for early diagnosis. [5]

* Corresponding author. Faculty of Medicine, Department of Orthopaedic and Traumatology, Universitas Airlangga, Jl. Mayjen Prof. Dr. Moestopo 47, Surabaya 60131, Indonesia. Tel.: + 62 852 1070 7070.

E-mail address: n.c.budhiparama@gmail.com

Despite the susceptibility of PJI in patients with megaprosthesis implantation, limited studies have documented the complications and functional outcomes due to the rarity of this surgical procedure. Considering the expected growth in megaprosthesis surgeries, a wider range of literature could help surgeons in advising appropriate treatment options and in being able to adequately manage patient expectations.

This study was designed to evaluate the outcome of debridement, antibiotics, and implant retention (DAIR) procedures and 2-stage revision surgeries in patients with PJI after megaprosthesis, including treatment failure; the patient-reported outcomes; and to determine the survival rates of the revised megaprosthesis.

Material and methods

Study design and population

Following approval from the institutional review board, a retrospective review of medical records was performed between 2018 and 2023. A total of 34 patients diagnosed with PJI following megaprosthesis were identified. All patients with megaprosthesis who subsequently developed PJI and had minimum follow-up of 1-year were included in this study. PJI was diagnosed with the presence of pain, reduced range of motion, along with the latest International Consensus Meeting criteria, or the elevated erythrocyte sedimentation rate (ESR) or C-reactive protein (CRP). [6,7] Patient with previous unsuccessful debridement in other institutions were excluded. One patient passed away due to an accident unrelated to the surgery and 3 patients had to be excluded as they did not meet the criteria of minimum 1-year follow-up. The final analyses were performed on 30 patients with infected megaprosthesis, including 19 proximal femoral replacements (PFRs) and 11 distal femoral replacements. The initial indication for megaprosthesis implantation was previous PJI in 15 patients (50%), aseptic loosening in 9 patients (30%), and post-traumatic bone loss in 6 patients (20%) (Fig. 1, Table 1).

Surgical technique

The surgical approach selected was determined by the onset of presentation. Patients presenting within 4 weeks of megaprosthesis implantation underwent DAIR procedure, while those presenting after this window underwent 2-stage revision surgery. The previous incision was marked with methylene blue and included in the dissection. Radical debridement, including debridement of all devitalized osseous and soft tissue, was performed. A minimum of 6 tissue samples and fluid samples were collected in culture medium bottles for microbiological analysis and separate samples were sent for histological analysis. [8] In addition to these samples,

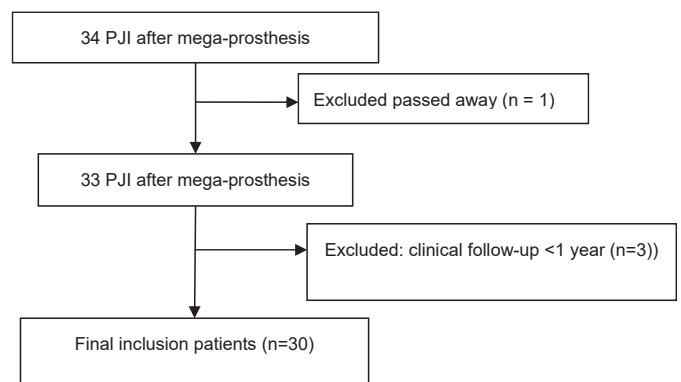


Figure 1. Flowchart of patients.

Table 1
Baseline characteristics of the patients.

Characteristics	DAIR (n = 16)	2-Stage revision (n = 14)	P value
Mean age at time of infection (y)	57.2 ± 10.6	59.6 ± 6.4	.314
Gender (M/F)	(6/10)	(6/8)	.593
Body mass index (kg/m ²)	28.1 ± 2.1	29.1 ± 2.8	.414
Charlson Comorbidity Index	4.05 ± 1.4	3.5 ± 1.1	.052
Interval from symptom onset to surgery (d)	21.5 ± 2.6	94.3 ± 40.2	.070
Type of prosthesis			.510
PFR (18)	11 (68%)	8 (57%)	
DFR (10)	5 (31%)	6 (43%)	
Culture (positive/ negative)	16/0	8/6	.003
Aspirate culture	0/16	7/7	P < .001
Culture of intraoperative sample	16/0	8/6	.003
Histology of intraoperative sample	16/0	8/6	.003
VAS	7.75 ± 0.77	8.36 ± 0.63	.065
Preoperative ESR	101.63 ± 5.6	77.8 ± 5.2	.018
Preoperative CRP	51.2 ± 4.7	41.0 ± 5.5	.056

DAIR, distal femoral replacement; VAS, visual analog scale.

a wash of the implant was also sent in all cases for culture and sensitivity for aerobic and anaerobic cultures. This process involved using 20-mL saline to wash the removed implant under high pressure using a syringe, which was then sent for testing. [9] Fungal and mycobacterial cultures were decided based on analysis of the preoperative synovial fluid. [10]

Once the samples were taken, the debridement was continued. First, a pulse lavage of 3 L 0.9% saline was given. This was followed by a 3-minute soak in 100-mL 3% hydrogen peroxide, which was poured and kept in the wound cavity and subsequently washed away by another liter of saline lavage. Third, a betadine soak using 20-mL 10% povidone iodine diluted with 500-mL 0.9% saline was given to the cavity for another 3 minutes. Next, a chlorhexidine soak using 20-mL Hibiscrub (chlorhexidine gluconate 4%; Moln-lycke) 0.05% (5 mL in 50 mL saline) was given for 1 minute. A final wash with a pulse lavage of 9-L 0.9% saline was given. A single dose of 1 g tobramycin and 1 g cefazolin were given intraoperatively once the appropriate samples had been collected.

Before proceeding with the next step, we replaced all the surgical drapes and instruments. The wound was packed with betadine-soaked gauze and covered with clean gauze, a layer of loban drape, and with new sterile surgical drapes. The surgical team, including the assistants, rescrubbed before moving ahead. The wound was reopened, a repeat saline wash was given, and we proceeded with the next step.

In case of DAIR, the decision to perform the modular exchange was made by the surgeon. Normally the surgeon exchanged the modular except due to customized implant or unavailability during the surgery, which was followed by insertion of a suction drain and a watertight closure. For patients with 2-stage revision, the components were explanted, and the articulating antibiotic spacer was placed after debridement. The spacer included dual antibiotics containing 3 g of vancomycin and 3.6 g of tobramycin per 40 g bone cement. The decision for reimplantation was based on clinical and laboratory evaluations. Similar steps for debridement were followed before the reimplantation. Antibiotic cement, PALACOS (radiopaque bone cement containing gentamycin; Heraeus Medical GmbH, Germany), with 1 g vancomycin per 40 g cement was used in all cases.

The anticoagulation prophylaxis and postoperative rehabilitation protocols were kept similar for all patients. Initial antibiotic therapy was started with intravenous antibiotics comprising a beta-lactam and an aminoglycoside combination. Subsequent

Table 2
Operative treatment and success rate.

Operative treatment	Initial etiology			Success rate
	Previous PJI	Aseptic loosening	Post-traumatic	
DAIR (16)				
With modular component exchange	3	6	-	13 of 16 (81 %)
Without modular exchange	-	-	4	
2-Stage revision (14)	8	1	1	10 of 14 (71.4 %)
Success rate	11 of 15 (73.3%)	7 of 9 (77.8%)	5 of 6 (83.3%)	

modification was done based on consultation with an infection disease specialist, the culture reports, treatment response, clinical picture, and serum markers. To cover coagulase-negative *Staphylococci* (CoNS), second-generation cephalosporins were initiated. In cases of methicillin-resistant *Staphylococcus aureus*, a combination of vancomycin and linezolid was administered; for *Pseudomonas* infections, a fluoroquinolone with a carbapenem was given, and for enterococcal infections, a third-generation cephalosporin was prescribed. In cases with negative cultures, a combination of vancomycin and a third-generation cephalosporin was administered. Polymicrobial infections were treated with medications based on the specific drug sensitivities reported for each individual organism. Injectables were given for 6 weeks, followed by oral antibiotics lasting from 6 to 12 months. In resistant cases with reversing trends of ESR or CRP or recurrence of clinical features, a combination of intravenous meropenem 6 g/day and daptomycin 700 mg/day was started. Regular monitoring of levels of ESR or CRP along with liver and renal function was done.

Outcome variables

The manual review was conducted to collect demographic, clinical, laboratory, and radiological data for all patients (described in Table 1). Demographic data included age, gender, Charlson comorbidity index, and body mass index. Preoperative and postoperative radiographs of the femur, knee, and a lower-limb scanogram for limb alignment were done for all patients. Surgical data recorded operative time, estimated blood loss, and intraoperative events. Follow-up data were collected at 6 weeks, 3 months, 6 months, and 1 year postoperatively. Postoperative wound complications included wound dehiscence, incisional drainage, or redness.

The primary outcome was treatment failure, defined as persistent wound complication or need for subsequent surgical intervention. The secondary outcome encompassed patient-reported outcomes, as

measured by Oxford Hip Score (OHS) and Oxford Knee Score (OKS), as well as the survival rates of the revised megaprosthesis. [11,12]

Data analyses

The data analyses were carried out using SPSS 22.0 software. Student *t* test was used to analyze categorical data and independent *t* test for analyzing continuous variables, with *P* value of .05 to determine significance. Kaplan–Meier survivorship curve was generated using treatment failure as an end point.

Results

The mean follow-up duration for all patients was 35 ± 16.4 months. Of the 30 patients, 8 patients complained solely of pain (26.6%, all were PFRs), 20 patients experienced swelling (66.7%), and 26 patients reported increased temperature (86.6%). Of the 30 patients, DAIR was performed in 16 patients (53%) with 11 undergoing a modular component exchange. Among these 16 patients, 10 (62%) underwent a single DAIR procedure with no resistant cases, while 2 (12.5%) underwent 2 DAIR procedures and 4 patients (25%) required 3 or more DAIR procedures. The mean duration between the first stage and final reimplantation for the 14 patients who underwent 2-stage revision was 9.42 ± 1.5 weeks. These patients received intravenous antibiotics for a mean period of 7.4 ± 1.2 weeks based on clinical signs and serum biomarker levels. This was followed by a 2-week antibiotic-free period before definitive reimplantation. Preoperative OHS mean was 8.72 ± 2.2 , which improved to 34.22 ± 9.2 at 1 year postoperation. Similarly, the mean OKS improved from 8.50 ± 1.9 preoperation to 32.40 ± 8.1 at 1 year postoperation. The success rate based on the indication for megaprosthesis was 73.3% for prior PJI, 77.8% for aseptic loosening, and 83.3% for post-traumatic bone loss patients (Table 2). The reinfection rate based on the initial indication for megaprosthesis was 30.7 % (4 of 13) for

Table 3
Description of patients who had treatment failure.

No.	Region	Initial etiology for megaprosthesis	Previous culture result	Clinical feature	First operation	Intraoperative culture	Second operation	Final status
1	PFR	Post-traumatic	-	Sinus tract	DAIR	Mixed	2-Stage exchange	Antibiotics continue at last follow-up
2	PFR	Aseptic loosening	Negative	Persistent pain	DAIR	CoNS	2-Stage exchange	Antibiotics continue at last follow-up
3	PFR	PJI	MSSA	Sinus tract	DAIR	Group B <i>Streptococcus</i>	2-Stage exchange	Antibiotics continue at last follow-up
4	PFR	PJI	MSSA	-	2-Stage exchange	Culture-negative	Vascular repair and 2-stage exchange revision	Antibiotics continue at last follow-up
5	PFR	Aseptic loosening	Negative	Persistent Pain	2-Stage exchange	<i>P. aeruginosa</i>	DAIR	Antibiotics continue at last follow-up
6.	DFR	PJI	CoNS	-	2-Stage exchange	Mixed	Implant revision	Hyperextension deformity
7	DFR	PJI	Mixed	-	2-Stage exchange	Enterococcus	2-Stage exchange revision	Arthrodesis

DFR, distal femoral replacement; MSSA, Methicillin-Sensitive *Staphylococcus aureus*.

Table 4
Microorganisms isolated in infected megaprosthesis.

Organism	Frequency (%)
Aerobic gram-positive bacteria	
Coagulase-negative <i>Staphylococcus</i> species	12 (40.0%)
<i>S. aureus</i>	2 (6.6%)
<i>Streptococcus</i> species	1 (3.3%)
Aerobic gram-negative bacteria	
<i>Pseudomonas</i> species	2 (6.6%)
Enterobacterales	1 (3.3%)
Polymicrobial growth	6 (20.0%)
Fungal	
<i>Candida</i>	1 (3.3%)
Culture negative	5 (16.6%)

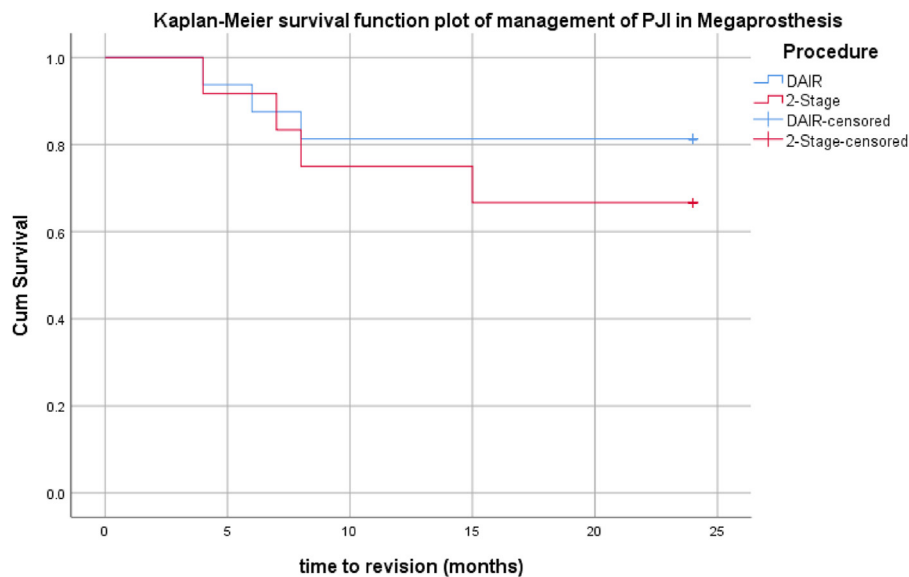


Figure 2. Kaplan–Meier plot comparing survival functions between DAIR and 2-stage exchange procedure. The 2-year survival function was 81% for DAIR and 71.4% for the 2-stage exchange procedure.

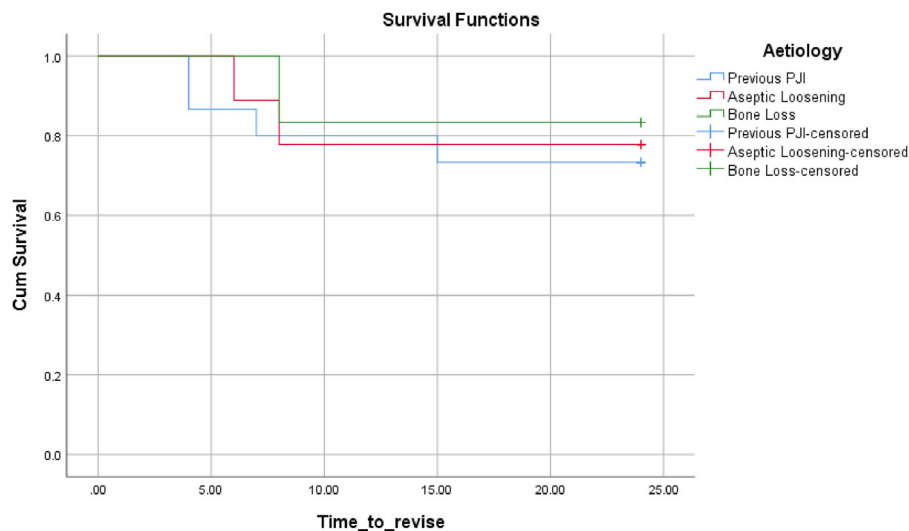


Figure 3. Kaplan–Meier plot comparing survival functions between etiology. This graph showed 77.8% 2-year survival function for aseptic loosening cause, 83.3% for bone loss cause, and 73.3% for previous PJI.

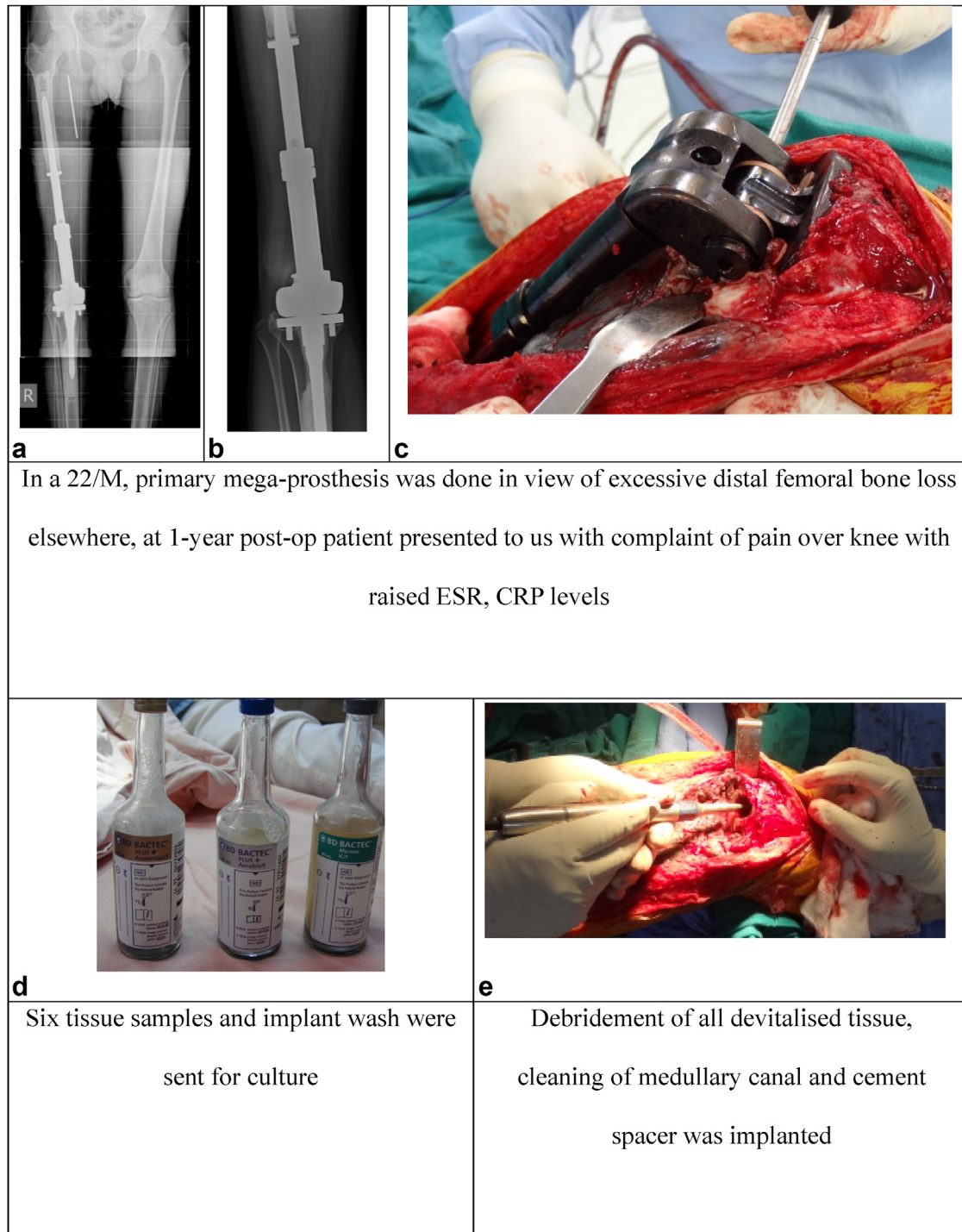


Figure 4. In case I, a 22-year-old male patient, primary megaprosthesis was done in view of excessive distal femoral bone loss elsewhere. At 1 year postoperation, the patient presented to us with complaint of pain over knee with raised ESR and CRP levels, as seen in the radiograph (a and b) and intraoperatively (c). Six tissue samples and implant wash were sent for culture (d). Debridement of all devitalized tissue, cleaning of medullary canal, and implanting of the cement spacer (e). Definitive implantation was done in the second stage, 8 weeks after explantation, as seen intraoperatively (f) and in postoperative radiograph (g). At 1 year postoperation, the patient has returned to daily functional activities without any limitations (h and i). At 5 years postoperation, patient comes with complaint of pain on walking. Radiograph reveals stem breakage but no recurrence of infection (j, k, and l). Implant was revised and patient can do daily activities with postoperative x-ray as seen in the picture (m and n). Four years postoperative patient developed a hyperextension deformity. There is no sign of active infection (o and p).

prior PJI, 18.8 % (2 of 11) for aseptic loosening, and 16.6% (1 of 6) for post-traumatic bone loss patients ($P = .505$). Treatment failure was observed in 7 patients (23.3%) (Table 3). DAIR achieved an 81% success rate (13 out of 16), while 2-stage exchange had a 71.4%

success rate (10 out of 14). The 2-year implant survival rate was 76.6 % (Figs. 2 and 3). CoNS was the most isolated organism in 12 patients (40%), followed by polymicrobial growth in 7 patients (25%). Five patients showed no growth and were defined as culture

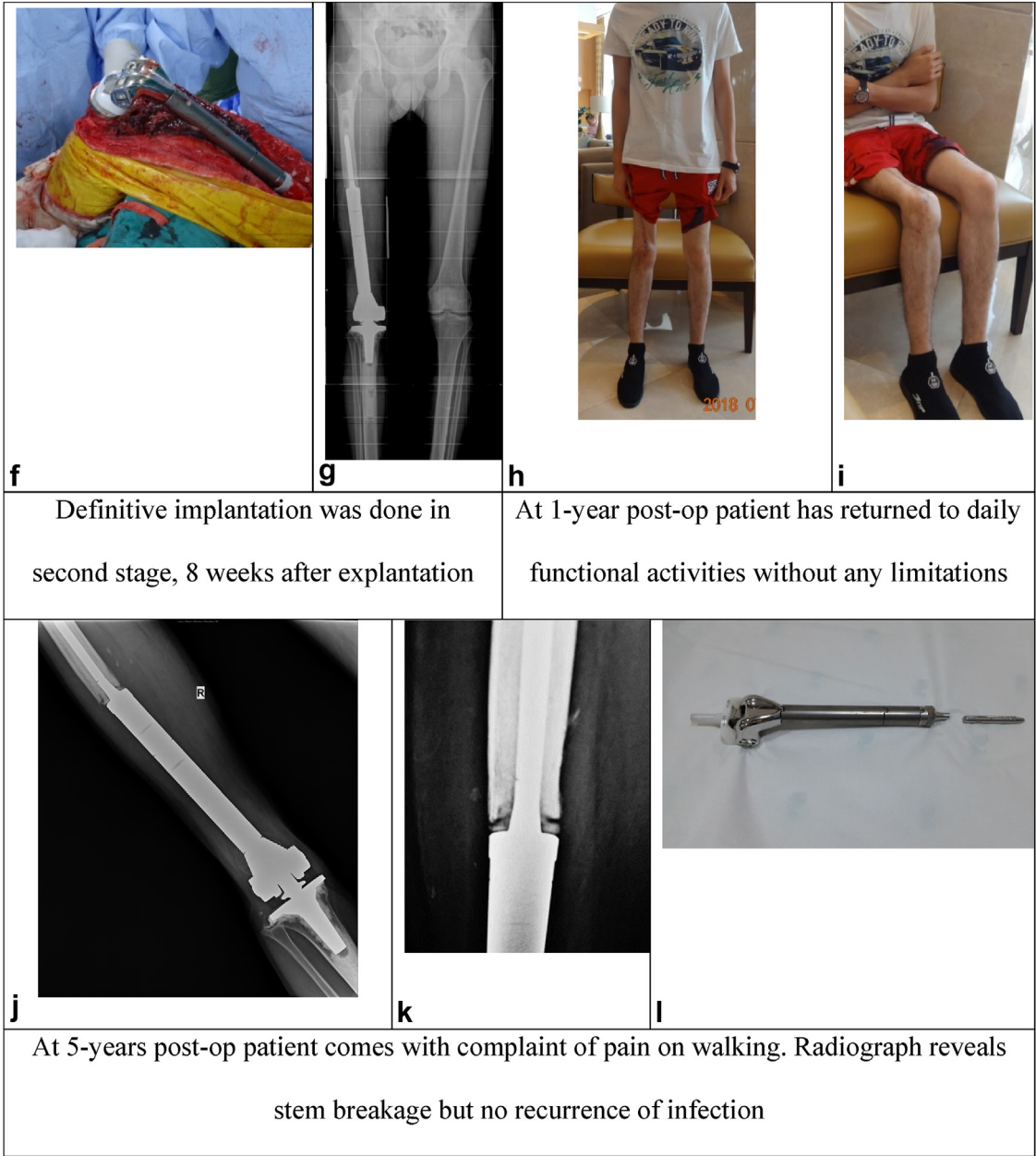


Figure 4. (continued).

negative (16.6%). The isolated microorganisms have been described in Table 4. Figures 4–6 provide detailed accounts of representative cases involving mega-prosthesis implantation.

One patient with a PFR experienced a vascular injury of the iliac artery 4 years after first revision surgery due to migration of the cup cage. The iliac artery was repaired by a vascular surgeon using a graft, which was followed by a 2-stage exchange procedure. Post-operative cultures showed no growth, and the patient was started on vancomycin and cefoperazone-sulbactam. The patient has reported no clinical signs of infection recurrence at latest 2-year follow-up but remains on oral antibiotics.

Persistent infection occurred in 5 patients, necessitating multiple subsequent surgical procedures, and continued antibiotic therapy lasting more than a year. One patient underwent a knee arthrodesis, but no amputations were required. Two patients with a history of previous PJI experienced reinfection after a period of 8 months and 15 months, respectively. A 22-year-old patient who underwent 2-stage revision developed a stem breakage at a follow-up of 5 years. This was revised with a larger stem, and the patient returned to routine activities. At a subsequent 4-year follow-up, the patient developed a hyperextension deformity of the

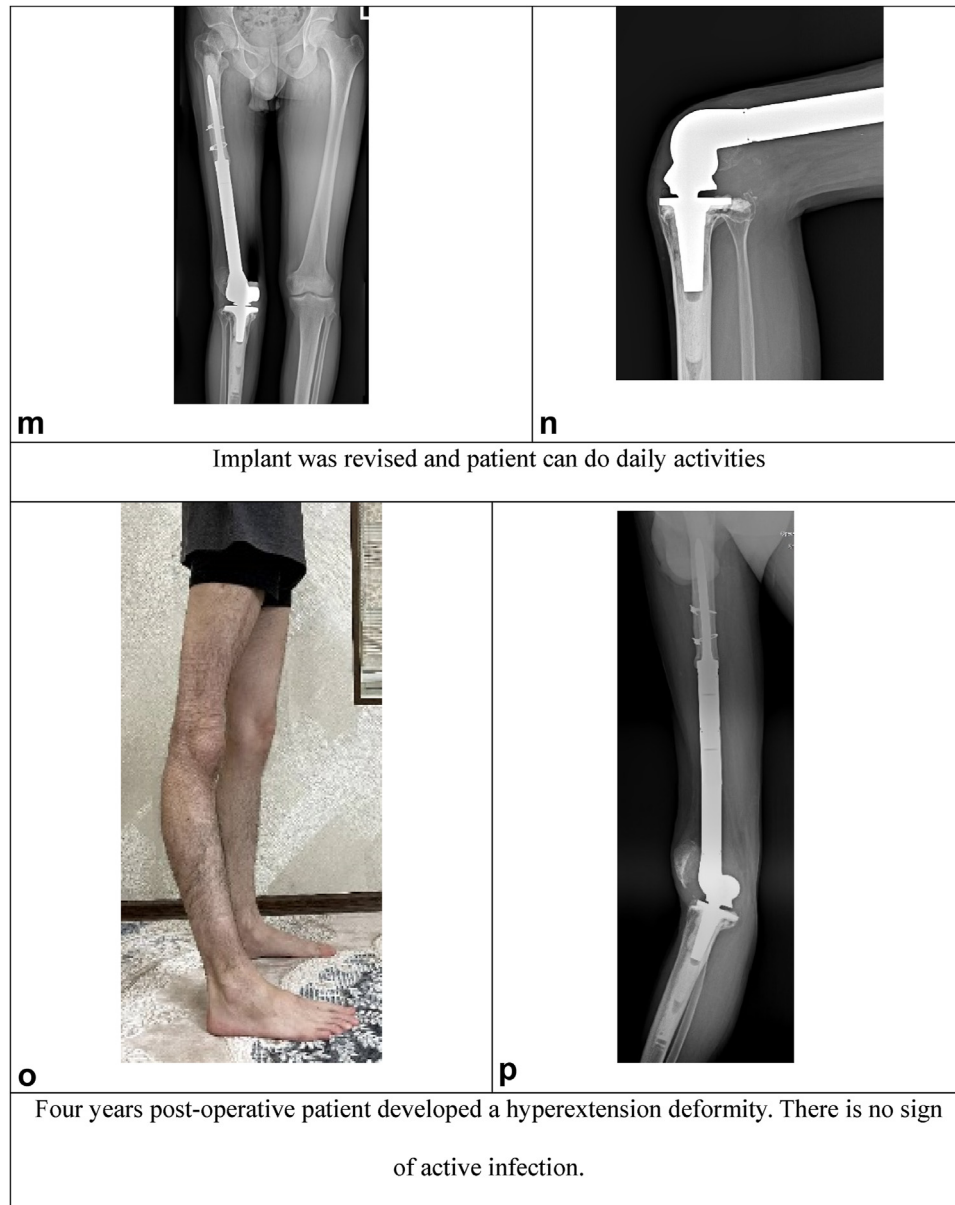


Figure 4. (continued).

knee requiring a change of poly and locking mechanism. No sign of active infection was noted. There were no reported deaths during the follow-up period.

Discussion

The primary finding of this study is the favorable outcome achieved with both DAIR and 2-stage exchange procedures, as evidenced by OHS and OKS improvement at 1-year follow-up with 34.22 ± 9.2 and 32.40 ± 8.1 , respectively. DAIR had an implant retention success rate of 81% (13 out of 16), while 2-stage exchange had a success rate of 71.4% (10 out of 14). Based on etiology, 2-year survival function for aseptic loosening cause was 77.8%, for bone loss cause was 83.3%, and for previous PJI was 73.3%.

Early and accurate diagnosis of PJI is a crucial factor in determining prognosis. However, the absence of distinct clinical signs or symptoms in many cases presents a significant diagnostic

challenge. The presence of a sinus tract was noted in only 4 patients (13.3%). Local symptoms such as erythema were uncommon. Persistent surgical site pain was reported in all cases, serving as the sole symptom in 6 patients. The high incidence of obesity within the study cohort (mean body mass index was $30.2 \pm 5.6 \text{ kg/m}^2$) may account for the lack of local findings, particularly in cases involving PFR. [13] In most cases, diagnoses relied on maintaining a low suspicion threshold and closely monitoring changes in ESR and CRP values.

The interval from symptom onset to surgical intervention was the primary determinant in selecting the appropriate surgical intervention. Literature suggests that implant preservation within 4 weeks of symptom onset is associated with better outcomes; otherwise, implant revision is recommended. [14–16] Adhering to established guidelines, we performed DAIR procedures exclusively for patients presenting within the initial 4 weeks of symptom onset. The management of delayed PJI remains a subject of debate,

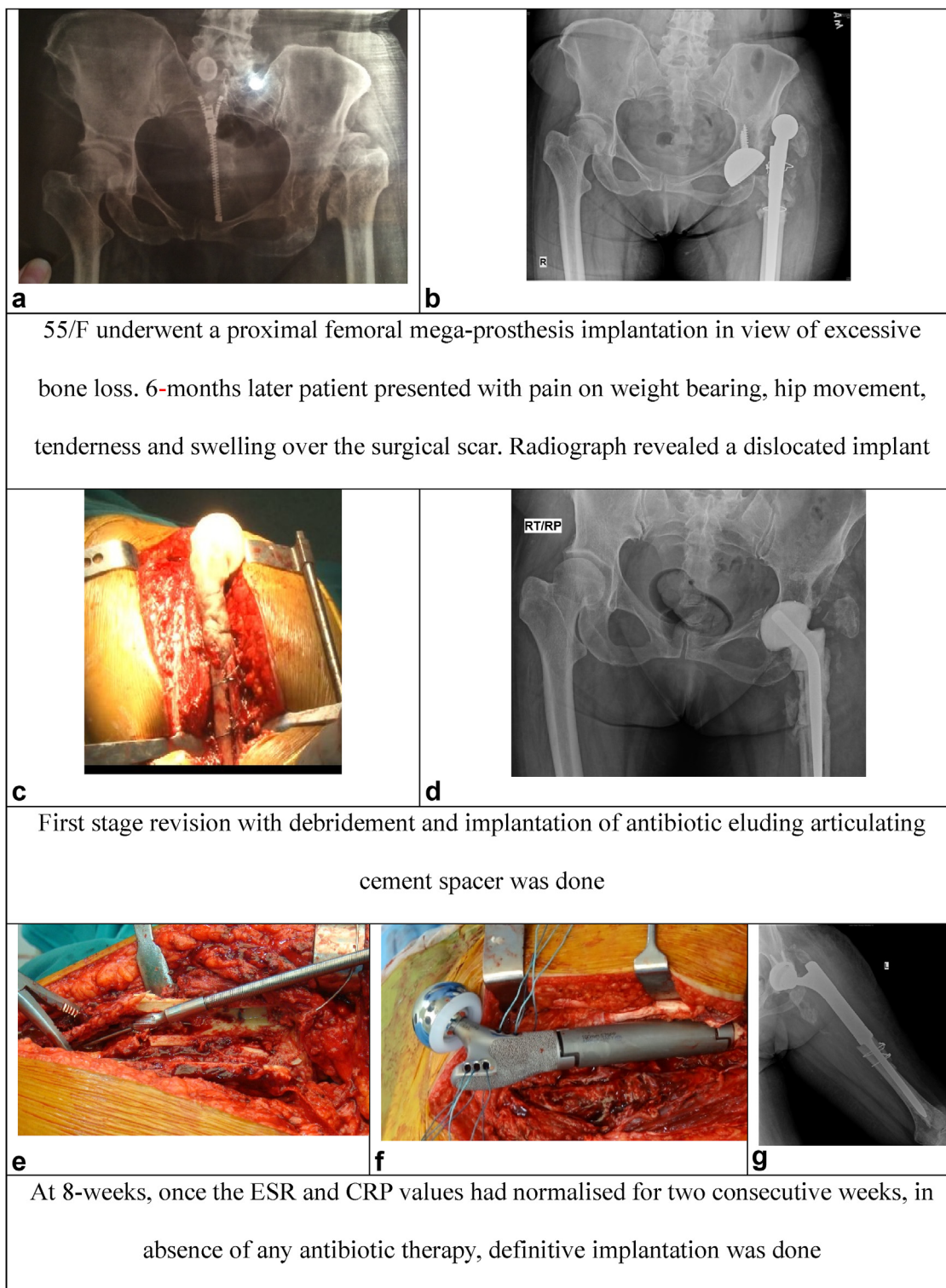


Figure 5. Case II, a 55-year-old female patient, underwent a proximal femoral megaprosthesis implantation in view of excessive bone loss. Six months later, the patient presented with pain on weight bearing, hip movement, tenderness, and swelling over the surgical scar. Radiograph revealed a dislocated implant (a and b). First-stage revision with debridement and implantation of antibiotic eluding articulating cement spacer was done (c and d). At 8 weeks, once the ESR and CRP values had normalized for 2 consecutive weeks, in absence of any antibiotic therapy, definitive implantation was done (e, f, and g). At 4-year follow-up, radiograph shows well-seated implant. Patient is able to carry out all activities of daily living without complaints (h, i, j, and k).

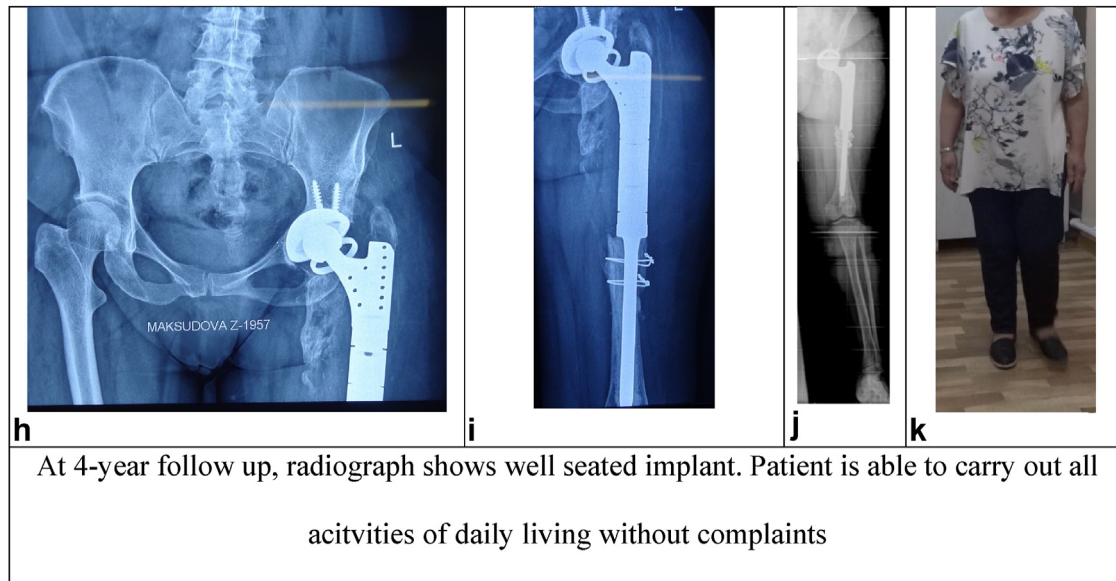


Figure 5. (continued).

with the standard 2-stage procedure being gradually replaced by single-stage revision, offering reduced hospitalization, potential functional benefits, and comparable outcomes. [17] However, considering the vulnerable physiology of typical megaprosthesis patients, we preferred to stage our revision surgery. The preceding etiology for the primary megaprosthesis implantation significantly influences the risk of PJI. [3] Notably, 46.4% patients had a prior history of PJI, underscoring the overall challenge in eradicating bone infection once established.

Despite adequate surgical intervention, the role of antibiotic suppression remains pivotal. The lack of consensus on standardized treatment regimens, the preferred antibiotic, route of administration, and treatment duration, pose a challenge. Adhering to standard antibiotic guidelines, we prioritized intravenous administration to enhance bioavailability while minimizing systemic effects. Bacterial load-independent drugs were used to lower risk of resistance development, with continuous and extended administration optimizing antibiotic efficacy over the pathogen's minimal inhibitory concentration. [18] The duration of the antibiotic therapy varied based on the surgical intervention; a 6-week postoperative period sufficed in cases of 2-stage exchange, while a minimum of 12 weeks was recommended following implant preservation in DAIR procedures, often extending indefinitely. [19,20]

The type of microorganism isolated also played a crucial role in treatment decisions, with CoNS being the most frequently identified, followed by polymicrobial growths. In 16.6% of cases, no growth was observed (culture-negative). In the absence of standardized regimens to tackle culture-negative cases, these patients received broad-spectrum antibiotics effective against both gram-positive and gram-negative pathogens. Despite the lack of specific guidelines, this strategy yielded outcomes comparable to standard regimens for positive cultures. [21]

Monomicrobial diagnoses can be addressed with standardized antibiotic regimens. [19] However, when dealing with

polymicrobial or culture-negative isolates, there is a lack of consensus regarding appropriate drug selection, optimal therapy duration, or the mode of drug delivery. [22] The endpoint of treatment is also ill-defined, given the high risk of recurrence and associated morbidity.

The psychological impact of PJI following major surgery should not be underestimated. Given the nonconfirmatory diagnoses in most cases, it is essential to recognize the challenge faced by the surgeons in persuading patients to undergo prolonged and intensive treatment. The physiological and emotional stress associated with extended therapy, coupled with the frequent adverse effects of antibiotics, poses a persistent challenge to patient compliance. This, in turn, can lead to inadequate treatment, frequent relapses, and the significantly lower patient reported outcome scores compared to other revision procedures.

This study has several limitations. First, the retrospective nature of the study meant the risk of selection bias. Second, the limited sample size can cause type II error. Third, there is an absence of definitive criteria for determining the appropriate treatment regimen, hindering effective comparisons. However, given the rarity of available cases and the heterogeneous nature of infecting organisms, further studies of this nature could contribute valuable insights for surgeons in formulating appropriate surgical plans while also enabling them to counsel patients adequately regarding their expected outcomes. Fourth, while the wash of the implant was used for diagnostic purposes in this study, it is not a standard technique for diagnosing PJI. "Sonication" has been described as a method to achieve a higher concentration of organisms within the sample. Due to the absence of requisite infrastructure, we sent the fluid that was used to wash the implant. Although no previous studies have described this technique, we found positive results in a significant number of PJI cases. However, these implant wash specimens were positive for similar organisms that were present in tissue cultures, therefore there was no change in any treatment

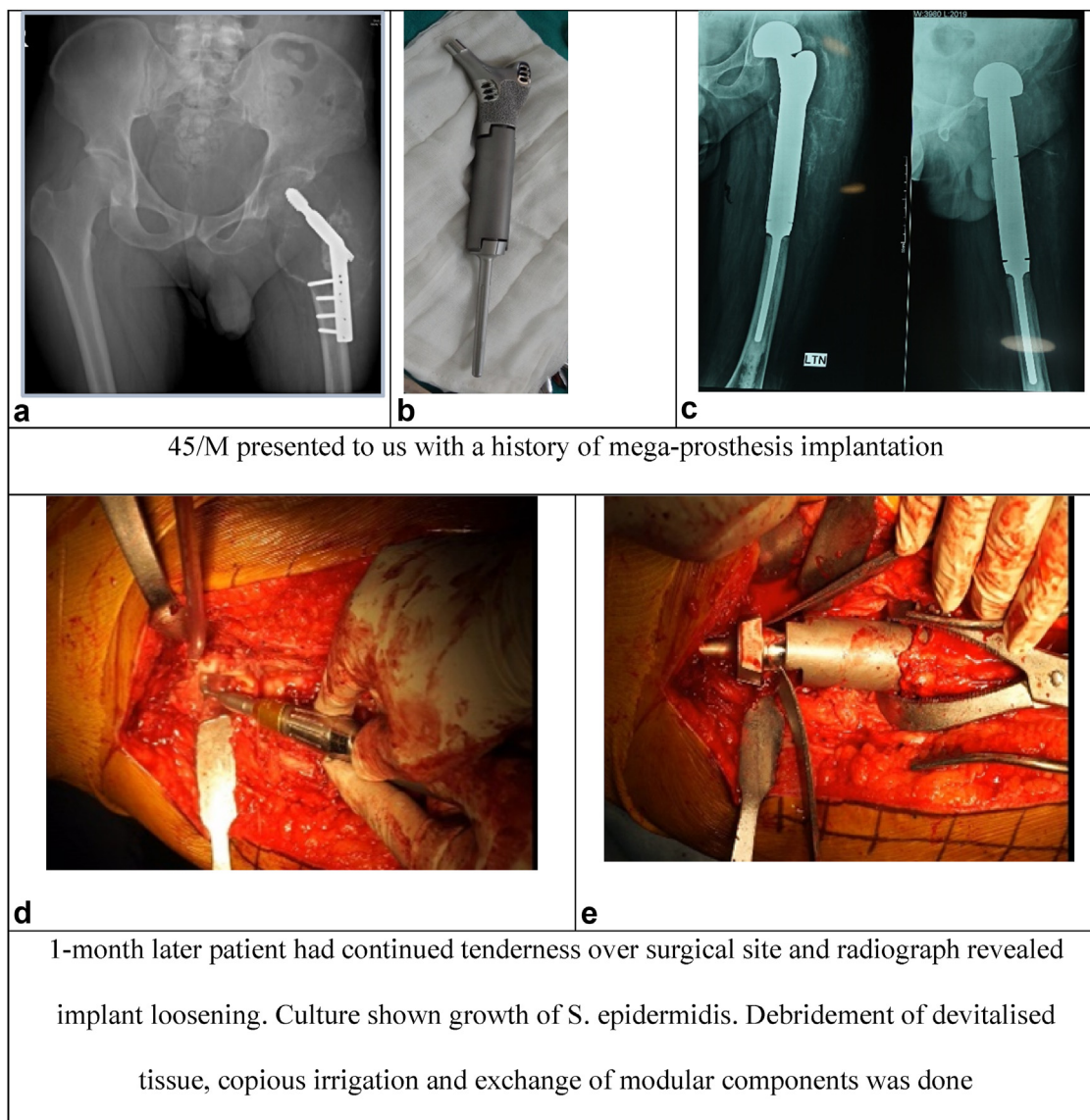


Figure 6. Case III, a 45-year-old male patient, presented to us with a history of megaprosthesis implantation (a, b, and c). One month later, the patient had continued tenderness over surgical site and radiograph revealed implant loosening. Culture showed growth of *S. epidermidis*. Debridement of devitalized tissue, copious irrigation, and exchange of modular components was done (d and e). At 3-year follow-up, figure shows a well-seated implant; patient is carrying out all routine daily activities without any complaints (f, g, and h).

decisions. It is unclear with regards to the specificity or sensitivity of this test, but it may be useful to gain further insight into pathological etiology. Fifth, we did not exchange polyethylene in several cases based on surgeon decisions. We were aware that keeping the polyethylene is one of the risk factors of failure in DAIR. But during our evaluation, it was observed that the number of failures in DAIR was lower and the survival rate was higher in DAIR compared to the 2-stage revision process.

Conclusions

Both DAIR and 2-stage exchange procedures yielded favorable functional outcomes with satisfactory 2-year survival function. Careful patient selection and indication management are crucial for optimal results.

Conflicts of interest

Nicolaas C. Budhiparama receives payment or benefits from DePuy Johnson & Johnson and Zimmer Biomet and sits on the editorial board of BJJ, CORR, OJSM, Journal of Orthopaedic Surgery. All other authors declare no potential conflicts of interest.

For full disclosure statements refer to <https://doi.org/10.1016/j.artd.2025.101688>.

CRediT authorship contribution statement

Rajeev K. Sharma: Writing – original draft, Formal analysis, Conceptualization. **Imelda Lumban-Gaol:** Writing – review & editing, Writing – original draft, Project administration, Formal analysis, Data curation. **Udit Vinayak:** Writing – original draft, Methodology, Formal analysis, Data curation, Conceptualization.

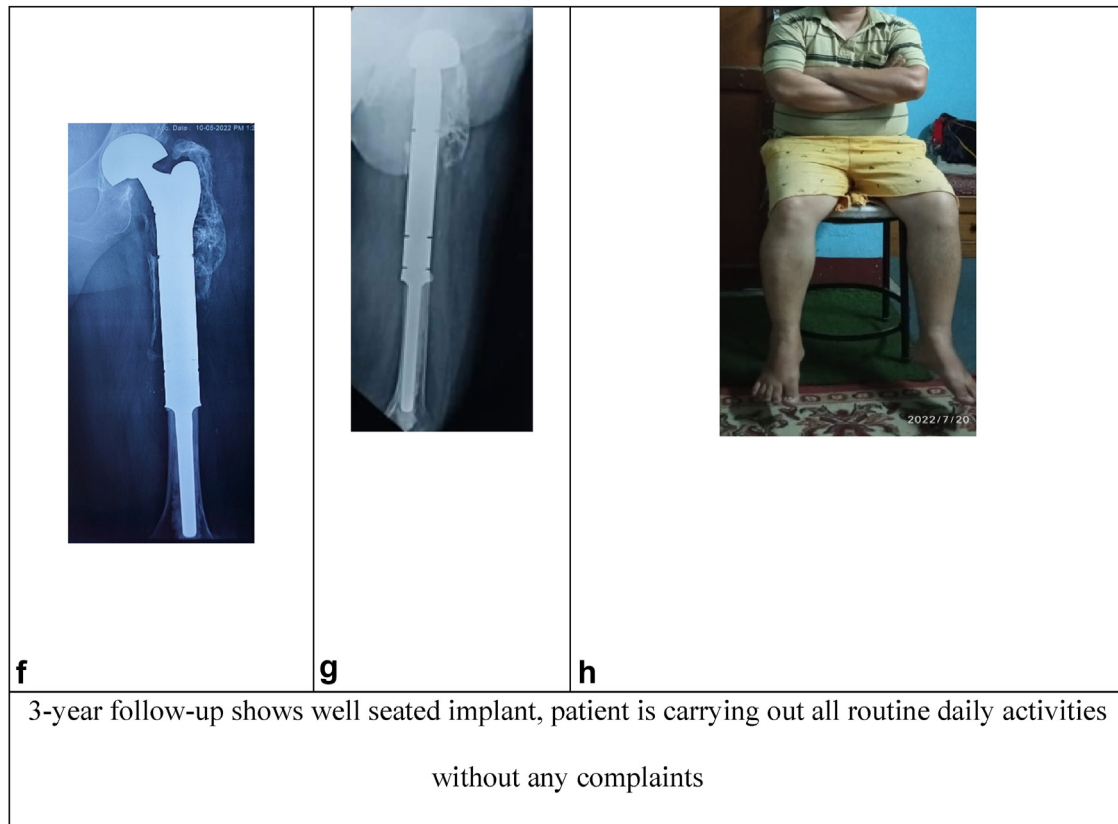


Figure 6. (continued).

Nicolaas C. Budhiparama: Writing – review & editing, Validation, Supervision, Resources, Project administration, Conceptualization.

Acknowledgments

The authors would like to express their sincere gratitude to Andrew Timothy for proofreading this manuscript.

References

- [1] Ercolano LB, Christensen T, McGough R, Weiss K. Treatment solutions are unclear for perimegaprosthetic infections. *Clin Orthop Relat Res* 2013;471:3204–13. <https://doi.org/10.1007/s11999-013-2852-7>.
- [2] Logoluso N, Pedrini FA, Morelli I, De Vecchi E, Romanò CL, Pellegrini AV. Megaprotheses for the revision of infected hip arthroplasties with severe bone loss. *BMC Surg* 2022;22:68. <https://doi.org/10.1186/s12893-022-01517-y>.
- [3] Sukhonthamarn K, Tan TL, Strony J, Brown S, Nazarian D, Parvizi J. The fate of periprosthetic joint infection following megaprosthesis reconstruction. *JB JS Open Access* 2021;6:4. <https://doi.org/10.2106/jbjs.Oa.21.00003>.
- [4] Asokan A, Ibrahim MS, Thompson JW, Haddad FS. Debridement, antibiotics, and implant retention in non-oncological femoral megaprosthesis infections: minimum 5 year follow-up. *J Exp Orthop* 2022;9:32. <https://doi.org/10.1186/s40634-022-00469-9>.
- [5] Tan TL, Kheir MM, Shohat N, Tan DD, Kheir M, Chen C, et al. Culture-negative periprosthetic joint infection: an update on what to expect. *JB JS Open Access* 2018;3:e0060. <https://doi.org/10.2106/jbjs.Oa.17.00060>.
- [6] Parvizi J, Gehrke T. Definition of periprosthetic joint infection. *J Arthroplasty* 2014;29:1331. <https://doi.org/10.1016/j.arth.2014.03.009>.
- [7] Parvizi J, Tan TL, Goswami K, Higuera C, Della Valle C, Chen AF, et al. The 2018 definition of periprosthetic hip and knee infection: an evidence-based and validated criteria. *J Arthroplasty* 2018;33:1309–13014.e2. <https://doi.org/10.1016/j.arth.2018.02.078>.
- [8] Walker LC, Clement ND, Wilson I, Hashmi M, Samuel J, Deehan DJ. The importance of multi-site intra-operative tissue sampling in the diagnosis of hip and knee periprosthetic joint infection - results from a single centre study. *J Bone Jt Infect* 2020;5:151–9. <https://doi.org/10.7150/jbji.39499>.
- [9] Kalbian I, Park JW, Goswami K, Lee YK, Parvizi J, Koo KH. Culture-negative periprosthetic joint infection: prevalence, aetiology, evaluation, recommendations, and treatment. *Int Orthop* 2020;44:1255–61. <https://doi.org/10.1007/s00264-020-04627-5>.
- [10] Tai DBG, Wengenack NL, Patel R, Berbari EF, Abdel MP, Tande AJ. Fungal and mycobacterial cultures should not be routinely obtained for diagnostic work-up of patients with suspected periprosthetic joint infections. *Bone Joint J* 2022;104-b:53–8. <https://doi.org/10.1302/0301-620x.104b1.Bjj-2021-0876.R1>.
- [11] Field RE, Cronin MD, Singh PJ. The oxford hip scores for primary and revision hip replacement. *J Bone Joint Surg Br* 2005;87:618–22. <https://doi.org/10.1302/0301-620x.87b5.15390>.
- [12] Khaw YZ, Liow MHL, Goh GS, Chen JY, Lo NN, Yeo SJ. The oxford knee score minimal clinically important difference for revision total knee arthroplasty. *Knee* 2021;32:211–7. <https://doi.org/10.1016/j.knee.2021.08.020>.
- [13] Imagama T, Seki K, Seki T, Matsuki Y, Yamazaki K, Sakai T. Low frequency of local findings in periprosthetic hip infection caused by low-virulent bacteria compared to periprosthetic knee infection. *Sci Rep* 2021;11:11714. <https://doi.org/10.1038/s41598-021-91139-w>.
- [14] Argenson JN, Arndt M, Babis G, Battenberg A, Budhiparama N, Catani F, et al. Hip and knee section, treatment, debridement and retention of implant: proceedings of international consensus on orthopedic infections. *J Arthroplasty* 2019;34:S399–419. <https://doi.org/10.1016/j.arth.2018.09.025>.
- [15] Bedair HS, Katakam A, Bedeir YH, Yeroushalmi D, Schwarzkopf R. A decision analysis of treatment strategies for acute periprosthetic joint infection: early irrigation and debridement versus delayed treatment based on organism. *J Orthop* 2020;22:246–50. <https://doi.org/10.1016/j.jor.2020.04.003>.
- [16] Longo UG, De Salvatore S, Bandini B, Lalli A, Barilla B, Budhiparama NC, et al. Debridement, antibiotics, and implant retention (dair) for the early prosthetic joint infection of total knee and hip arthroplasties: a systematic review. *J ISAKOS* 2024;9:62–70. <https://doi.org/10.1016/j.jisako.2023.09.003>.
- [17] Kildow BJ, Della-Valle CJ, Springer BD. Single vs 2-stage revision for the treatment of periprosthetic joint infection. *J Arthroplasty* 2020;35:S24–30. <https://doi.org/10.1016/j.arth.2019.10.051>.

- [18] Fischbacher A, Borens O. Prosthetic-joint infections: mortality over the last 10 years. *J Bone Jt Infect* 2019;4:198–202. <https://doi.org/10.7150/jbji.35428>.
- [19] Bernard L, Arvieux C, Brunschweiler B, Touchais S, Ansart S, Bru JP, et al. Antibiotic therapy for 6 or 12 weeks for prosthetic joint infection. *N Engl J Med* 2021;384:1991–2001. <https://doi.org/10.1056/NEJMoa2020198>.
- [20] Le Vasseur B, Zeller V. Antibiotic therapy for prosthetic joint infections: an overview. *Antibiotics (Basel)* 2022;11:4. <https://doi.org/10.3390/antibiotics11040486>.
- [21] Hersh BL, Shah NB, Rothenberger SD, Zlotnicki JP, Klatt BA, Urish KL. Do culture negative periprosthetic joint infections remain culture negative? *J Arthroplasty* 2019;34:2757–62. <https://doi.org/10.1016/j.arth.2019.06.050>.
- [22] Osmon DR, Berbari EF, Berendt AR, Lew D, Zimmerli W, Steckelberg JM, et al. Executive summary: diagnosis and management of prosthetic joint infection: clinical practice guidelines by the infectious diseases society of America. *Clin Infect Dis* 2013;56:1–10. <https://doi.org/10.1093/cid/cis966>.