



Universiteit
Leiden
The Netherlands

ESTRO ACROP guidelines for external beam radiotherapy of patients with complicated bone metastases

Oldenburger, E.; Brown, S.; Willmann, J.; Velden, J.M. van der; Spalek, M.; Linden, Y.M. van der; ... ; Hoskin, P.

Citation


Oldenburger, E., Brown, S., Willmann, J., Velden, J. M. van der, Spalek, M., Linden, Y. M. van der, ... Hoskin, P. (2022). ESTRO ACROP guidelines for external beam radiotherapy of patients with complicated bone metastases. *Radiotherapy & Oncology*, 173, 240-253.
doi:10.1016/j.radonc.2022.06.002

Version: Publisher's Version

License: [Licensed under Article 25fa Copyright Act/Law \(Amendment Taverne\)](#)

Downloaded from: <https://hdl.handle.net/1887/4252106>

Note: To cite this publication please use the final published version (if applicable).



Guidelines

ESTRO ACROP guidelines for external beam radiotherapy of patients with complicated bone metastases



Eva Oldenburger^{a,1}, Stephanie Brown^{b,1}, Jonas Willmann^c, Joanne M. van der Velden^{d,e}, Mateusz Spałek^f, Yvette M. van der Linden^{d,e}, Joanna Kazmierska^{g,h}, Johan Menten^{a,i}, Nicolaus Andratschke^{c,2}, Peter Hoskin^{b,j,*}

^a Department of Radiation Oncology, University Hospital Leuven, Belgium; ^b Mount Vernon Cancer Centre, Northwood, UK; ^c Department of Radiation Oncology, University Hospital Zurich, University of Zurich, Switzerland; ^d Dept of Radiotherapy, Leiden University Medical Centre; ^e Netherlands Comprehensive Cancer Organisation, Utrecht, The Netherlands; ^f Department of Soft Tissue/Bone Sarcoma and Melanoma, Maria Skłodowska-Curie National Research Institute of Oncology, Warsaw; ^g Radiotherapy Department II, Greater Poland Cancer Centre; ^h Electroradiology Department, University of Medical Sciences, Poznan, Poland; ⁱ Catholic University Leuven, Belgium; ^j Division of Cancer Sciences, University of Manchester, UK

ARTICLE INFO

Article history:

Received 4 May 2022

Received in revised form 31 May 2022

Accepted 1 June 2022

Available online 7 June 2022

Keywords:

Bone metastases

Complicated

Cord compression

Neuropathic pain

Fracture

Prophylaxis

Stereotactic

Dose fractionation

ABSTRACT

This is the second part of the guidelines on the management of bone metastases. In the first part, the diagnosis and management of uncomplicated bone metastases have been addressed.

Bone metastases may significantly reduce quality of life due to related symptoms and possible complications. The most common symptoms include pain and neurologic deficits. The most serious complications of bone metastases are skeletal-related events (SRE), defined as pathologic fracture, spinal cord compression, pain, or other symptoms requiring an urgent intervention such as surgery or radiotherapy. Diffuse bone metastases may lead to hypercalcaemia that can be fatal if untreated. The growing access to modern diagnostic tools allows early detection of asymptomatic bone metastases that could be successfully managed with local treatment if oligometastatic or systemic treatment for diffuse bone metastases to try to avoid the development of SRE.

© 2022 Elsevier B.V. All rights reserved. Radiotherapy and Oncology 173 (2022) 240–253

Metastatic spinal cord compression

What are the demographics and pathophysiology of metastatic spinal cord compression?

Any cancer that can metastasise to the spinal column or within the epidural space has the potential to cause cord compression. It is well recognised that prostate, breast and lung cancers often metastasise to the spine and these typically make up 45–60% of metastatic spinal cord compression (MSCC) cases [1]. Other less frequent tumours include renal cell carcinoma, multiple myeloma, sarcoma, colorectal cancers, non-Hodgkin lymphoma, and cancers of unknown primary. Table 1 is a representation of tumours causing MSCC, taken from a large systematic review [2], however this should be viewed with caution as papers included within the systematic review may have excluded certain cancer types.

* Corresponding author at: Mount Vernon Cancer Centre, Rickmansworth Road, Northwood HA6 2RN, UK.

E-mail address: peterhoskin@nhs.net (P. Hoskin).

¹ Joint first authors.

² Joint last authors.

There is no universal definition of the term spinal cord compression. It is acknowledged that there are different degrees of epidural space involvement and spinal cord displacement and this is taken into account when treatment decisions are made. With more precise modern day treatments being developed e.g. stereotactic radiotherapy, there is a need for better grading systems which may help direct treatment decisions. One example is the 6-point, MR-based grading system of epidural spinal cord compression (ESCC) with classifications from bone only disease to spinal cord compression with no visible CSF around the cord (see Fig. 1) [3].

Incidence

The frequency of MSCC in cancer patients was estimated at 5% based on data from post-mortems and studies between 1959 and 1990 [1]. A retrospective study of 121,435 patients who died from cancer in Ontario (Canada) between 1990 and 1995, demonstrated an overall 2.5% cumulative incidence of cancer patients experiencing MSCC in the last 5 years of life [4]. Depending on tumour type this ranged from 7.9% in multiple myeloma patients to 0.2% in pancreatic cancer patients. With improvements in cancer treatment

Table 1
Tumour sites causing metastatic spinal cord compression (MSCC) and their frequency [2].

Tumour Primary Site	Number (%) n = 2656
Breast	605 (22.8)
Lung	416 (15.7)
Prostate	340 (12.8)
Myeloma/Lymphoma	269 (10.1)
Renal/GU	225 (8.5)
GI	110 (4.1)
Melanoma	74 (2.8)
Sarcoma	55 (2)
Unknown	160 (6)
Other	402 (15.1)

and people living to an older age, these figures are now likely out of date.

Anatomical distribution of MSCC

MSCC predominantly affects the thoracic vertebrae (65) followed by the lumbosacral (25) and cervical region (10) [2]. 20–35 of patients have multiple sites of MSCC on imaging [1]

Pathophysiology

If not detected and treated urgently, MSCC may lead to paraplegia, tetraplegia, sensory neuropathies, bladder and bowel dysfunction depending on the level of the spinal cord affected. It is important to note that cauda equina syndrome is also encompassed within the term MSCC.

Compression of the spinal cord is due to haematogenous spread initially to the vertebral body and then to the epidural space in up to 85% of cases [1,5]. Less frequently, compression can occur from invasion of paravertebral malignant tissue or through sudden oncological collapse of a vertebral body causing bone fragments to dislocate into the epidural space [1,6,7]. This can be caused by a metastasis or directly from a primary tumour. Occasionally intramedullary and leptomeningeal metastasis can occur and cause cord compression [8].

The pathophysiology of MSCC is thought to consist of direct mechanical compression of the spinal cord, causing venous hypertension and white matter oedema which reduces the arterial supply resulting in infarction of the cord and cell death [1,7]. The rationale behind giving steroids early is to reduce oedema to protect the spinal cord from infarction and in some tumours steroids will also have a tumouricidal effect (e.g. leukaemias and lymphomas) [1].

What is the best way to diagnose patients with MSCC?

MSCC can be suspected based upon history and clinical examination. Baseline neurological examination including assessment of motor function and sensory level is important to aid diagnosis as well as monitor a patient's progress. The MRC classification can aid motor assessment [9].

Urgent imaging is required when MSCC is suspected. The gold standard investigation for MSCC is MRI of the whole spine [10] to assess the location, grade and extent of tumour involvement [1,11,12]. This is important since 20–35% of cases will have multiple sites of MSCC as mentioned earlier. MRI can also help to differentiate benign from malignant causes of cord compression [7].

Both T1 and T2 weighted MR images, where possible without and with contrast are recommended [13]. Unenhanced T1 weighted images will demonstrate vertebral and epidural masses, contrast enhanced images are best to demonstrate intradural extramedullary disease and T2 weighted imaging is optimal to detect intramedullary disease [14].

In certain instances MRI scans are contraindicated due to patient habitus, the presence of a pacemaker or defibrillator, claustrophobia or in some situations MR may not be accessible. Plain X-ray myelography is rarely used but CT of the spine with IV contrast or CT myelography are alternative forms of imaging [15]. A CT of the whole spine is able to detect vertebral and paravertebral masses but has poor soft tissue resolution compared to MRI. CT can also be used to assess if the spine is stable. A systematic review of diagnosis and management of MSCC identified 4 studies including 456 patients; three that directly compared MRI and myelography [16–18] and one looking at MRI imaging vs plain radiographs when detecting MSCC [19]. MRI was 44–93% sensitive and 90–98% specific, compared to myelography which was 71–95% sensitive and 88–100% specific. Disadvantages of myelography which may explain why it is not used widely include the requirement of experience to inject contrast into the epidural space, it is time-consuming and poses increased risks to patients through contrast reactions, a detriment in neurological function and it is an invasive procedure [18].

Timing of imaging

Two national guidelines have recommendations for the timing of investigations and treatment and are summarised in Table 2 [20,21].

Recommendations:

- MRI-whole spine is the investigation of choice for suspected metastatic spinal cord compression and should be performed urgently within 24 h of presentation. [Grade A, Level 1a]

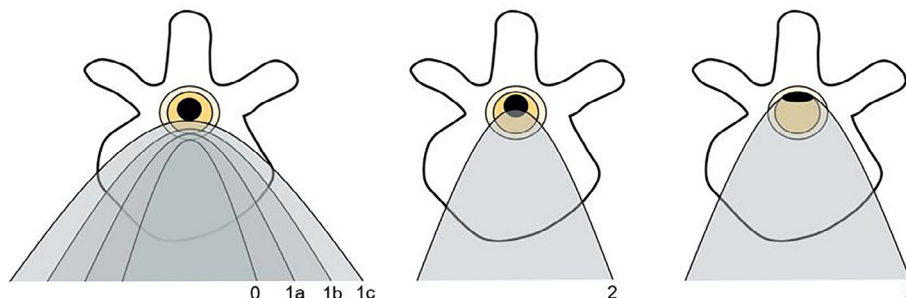


Fig. 1. Classification of epidural spinal cord compression (ESCC) grading scale (based on Bilsky et al. 2010). Classification of epidural spinal cord compression according to Bilsky et al. Schematic representation of a vertebra. Yellow: vertebral canal. Orange: dural sac. Black: spinal cord. Grade 0: tumour confined to the bone. Grade 1a: tumour touches the dural sac without deforming it. 1b: deformation of the dural sac without touching the spinal cord; 1c: deformation of the dural sac, contact with the spinal cord, but without compression. 2: Compression, but with visible CSF. 3: Spinal cord compression, no CSF visible around the spinal cord.

Table 2

Summary of timing of investigations and treatment of metastatic spinal cord compression (MSCC) according to two national guidelines.

NICE 2008 (UK)		Groenen et al. 2018 (Netherlands)	
Clinical Scenario	Timescale for imaging	Clinical Scenario	Timescale for imaging
<i>Suspected bone metastasis</i>	Within 1 week	<i>Suspected bone metastasis (local back pain)</i> <i>Unilateral radicular pain</i> <i>Progressive unilateral radicular deficit developing >7 days</i> <i>Progressive unilateral radicular deficit developing <7 days</i>	Within 2 weeks Within 1 week Within 48 h Within 24 h
<i>Suspected MSCC</i>	Within 24 h Sooner if pressing clinical need for surgery	<i>Suspected MSCC</i>	As soon as possible, within 12 h at least
<i>Confirmed MSCC</i>	Definitive treatment to start within 24 h	<i>Confirmed MSCC</i>	Definitive treatment to start within 24 h

- If MRI is contraindicated or unavailable, CT whole spine without and with IV contrast should be used. [Grade C, Level 3b]

Management of metastatic spinal cord compression

What are the first steps in the management of MSCC?

Clinical MSCC is a medical emergency which needs urgent treatment to reduce the risk of progression of neurological deficits. Ambulatory function after radiotherapy is better in those with a slower presentation of motor deficit (>7 days), but in those with a history of less than 7 days and in particular within 24–48 h there is more urgency to establish a diagnosis and plan treatment to maintain functional integrity of the cord [22].

Most patients will present in the context of a known underlying malignancy, but it may also be the first presentation of malignancy. In these patients it is important to establish a tissue diagnosis to enable optimal management. Rapid assessment should include a thorough history and clinical examination, neurological assessment and performance status, and screening blood tests including a myeloma screen and serum PSA. Other tumour markers may be indicated based on clinical findings. In addition to spinal imaging, a CT chest, abdomen and pelvis with contrast will provide a good screen for likely malignancies and also possible sites for subsequent biopsy confirmation. A tissue sample should then be urgently obtained. This may be at surgical decompression of MSCC or where surgery is not to be undertaken, either a CT guided biopsy of the spinal metastasis or a biopsy of any other location of suspected malignant tissue under image guidance [23]. This should ideally be prior to administering steroids which can distort cellular morphology, particularly in haematological malignancies [24]. Smear cytology can be used to rapidly distinguish a haematological malignancy from an epithelial malignancy which is important for deciding the ongoing treatment of a patient.

One study of 69 patients (aged 50–88), with good performance status, who underwent spinal surgery to manage MSCC with an unknown primary diagnosis found that the most common malignancy to present with MSCC as a first symptom or sign was prostate (35%), followed by multiple myeloma (16%), cancer of unknown primary (14.5%), lung (10%), and lymphoma (9%) [25].

Once diagnostic procedures have been completed, steroids should be started immediately. Only one study has ever compared high dose steroids to no steroids in this setting. 57 patients were randomised to steroids (immediate intravenous bolus of 96 mg dexamethasone, followed by three days of oral 96 mg and then slowly tapered to stop over 10 days) or no steroids. There was a statistically significant difference in continued or regained ambulation in the steroid group versus the non-steroid group at 3 months (81% vs. 63%) and 6 months (59% vs. 33%) after treatment [26]. Further evaluation of such very high initial doses of dexamethasone to a standard dose of 10–16 mg daily have revealed no evidence of a

dose response for neurological function but an increase in gastrointestinal toxicity with higher doses. The standard evidence based recommendation therefore is to start treatment with 16 mg dexamethasone IV, followed by 16 mg orally which is subsequently tapered [26–28]. A proton pump inhibitor for gastric protection should be considered based on the patient's history, but should always be given when corticosteroids are combined with NSAIDs [29]. The evidence around other steroid dosing regimes is lacking and it is acknowledged that different steroid regimes are being used in different centres.

Recommendations:

- Urgently assess suspected MSCC for evidence of a primary tumour clinically. [Grade C, Level 2b]
- If there is no known malignancy, urgent tissue diagnosis should be sought through blood markers e.g. PSA, definitive surgery, CT guided biopsy of the spinal tumour or biopsy of an accessible soft tissue mass under image guidance. [Grade D, Level 5]
- IV dexamethasone 10–16 mg should be started immediately after completion of diagnostic procedures. [Grade C, Level 2b]
- IV dexamethasone should be followed by a tapering course of oral dexamethasone from starting dose over the next 10–14 days. [Grade C, Level 2b]
- Consider use of a proton pump inhibitor for gastric protection with dexamethasone, especially if the patient is already taking a NSAID. [Grade B, Level 2a]

What are the roles of radiotherapy and surgery for MSCC?

Historically, surgical posterior decompressive laminectomy was not shown to be better than radiotherapy alone in terms of pain and ambulation [30–34]. However, modern surgery addresses the fact that the majority of MSCCs occur from posterior invasion of tumour from the vertebral body to affect the anterior cord with circumferential decompressive surgery and spinal stabilisation [35] which results in far better outcomes in terms of ambulation.

Surgery has been compared with radiotherapy in a randomised trial of 101 patients with MSCC where one group received surgery followed by radiotherapy and the other radiotherapy alone delivering 30 Gy in 10 fractions. Very radiosensitive tumours, patients with multiple areas of spinal cord compression, previous MSCC or spinal irradiation, a life expectancy of <3 months and total paraplegia for more than 48 h were excluded from the study. In those who entered the trial ambulatory, 84% (42/50) remained ambulatory in the surgical group compared to 57% (29/51) in the radiotherapy alone group. In those who entered the trial and were not ambulatory, 62% (10/16) became ambulatory in the surgical group and 19% (3/16) in the radiotherapy alone group. Surgery was also superior in maintenance of ambulatory ability when compared to radiotherapy alone (median 122 days in surgical group versus

13 days in radiotherapy group). All results were statistically significant and the superiority of results from the surgical treatment arm led to early termination of the trial [36]. It should be noted however that this was a single centre study with accrual over ten years and surgery by one experienced surgeon; such results may not reflect routine real world practice.

A meta-analysis compared 238 patients undergoing direct decompressive surgical resection with stabilisation and radiotherapy with 1137 patients undergoing radiotherapy alone. The combination of surgery and radiotherapy was superior to radiotherapy alone improving ambulatory status (RR 1.43, 95% CI 1.14–1.78), survival at 6 months (RR 1.21, 95% CI 1.09–1.33) and 12 months (RR 1.32, 95% CI 1.12–1.56) [37] but selection bias in such analyses must be considered.

To help assessment for surgery, radiotherapy or systemic therapy, the “NOMS” framework may be used [38], which considers Neurological (degree of compression on imaging and clinical examination) and Oncological status (expected tumour response to different oncological treatments), Mechanical instability (assessment for vertebral fractures which could be considered a strong indication for surgery) and Systemic disease burden (which takes into account comorbidities, histology, prognosis, performance status, age, etc.) using a 5-point score for each parameter and classifying patients according to their cumulative score. In addition, spinal instability is a clear indication for surgery [39], and its assessment will be discussed later in this guideline.

Spinal instability is often associated with mechanical pain (i.e. pain that is worse on movement and relieved on lying flat). Patients with suspected spinal instability and neurological compromise should be nursed flat with neutral spine alignment until bony and neurological stability are confirmed, only then should remobilisation start [21]. If the patient needs to be moved then aim to keep spinal mobility to a minimum and methods such as log rolling with turning sheets or the use of turning beds can help. Spinal bracing and positional techniques may help relieve instability pain but the evidence to support this is lacking [40]. Most cases of MSCC however occur with compression from posterior invasion through a vertebral body which does not impede the stability of the spine. These patients should begin mobilising as soon as possible to avoid associated complications and to aid mental wellbeing [41,42].

Recommendations:

- Patients with single site MSCC, <48 h paraplegia and life expectancy of ≥ 3 months should be referred for urgent surgical decompression and stabilisation followed by postoperative radiotherapy. [Grade A, Level 1B]
- For patients with suspected spinal instability, consult with a spinal surgeon. [Grade D, Level 5]
- All other patients should be discussed urgently within a multidisciplinary team including a radiation oncologist and a spinal surgeon. [Grade B, Level 2a]

What is the optimal technique and dose fractionation for primary radiotherapy for treatment of MSCC?

Conventional external beam radiotherapy

Various radiotherapy regimes have been used for the treatment of MSCC ranging from conventional 2 Gy per day schedules delivering around 40 Gy to hypofractionated schedules of 30 Gy in 10 fractions and 20 Gy in 5 fractions to single doses of 8–10 Gy. Several case series have been published with conflicting results.

There are now four randomised trials providing high level evidence for the efficacy of single fraction radiotherapy. The first of these randomised 327 patients with a prognosis of less than

6 months; of the 303 assessable patients 150 received 8 Gy in 1 fraction and 153 received 16 Gy in 2 fractions. Following radiological diagnosis, radiotherapy was delivered within 24–48 h. The area treated included a margin of two vertebrae above and below the level of compression and dose was prescribed to the depth of the cord. The median duration of response was 4.5 months in the single fraction group and 5 months in the multiple fraction group. The median overall survival for both groups was 4 months. No regime was more effective than the other in terms of survival or ambulatory rate [43].

The SCORAD III phase 3 trial randomised 686 patients with MSCC and an expected prognosis of greater than 8 weeks into two arms, either a single dose of 8 Gy or 20 Gy in 5 fractions [44]. Treatment was started within 48 h of the decision to treat using conventional megavoltage techniques. The area treated included a margin of one vertebrae above and below the level of compression and the dose was prescribed to the depth of the cord. All time points except at week 8 (which was the primary outcome) met the criteria for non-inferiority in ambulatory status and there was no difference in survival, median 12 weeks and 13 weeks.

The ICORG 05–03 phase 3, randomised, multicentre, non-inferiority study compared a single dose of 10 Gy and 20 Gy in 5 fractions using a volume including a margin of at least one vertebra above and below the level of compression and dose prescribed to the depth of the cord [45]. Only 112 patients were enrolled and 73 were included in the analysis. The study concluded that 10 Gy single dose was non-inferior to 20 Gy in 5 fractions in the treatment of MSCC with less toxicity and no difference in median overall survival rates: 6.6 months and 6 months respectively.

A fourth, phase 3, randomized controlled trial compared three fractionation regimes, a single dose of 8 Gy, 30 Gy in 10 fractions and 40 Gy in 20 fractions, in 285 randomised patients in total. No significant difference was detected in functional outcome or toxicity. At 2 years, 162 patients had in-field recurrence data and single fraction treatment was associated with a higher in-field recurrence rate than the other two multi fractionated regimes (22.2% vs. 16.1% (30 Gy in 10 fractions) vs. 13.5% (40 Gy in 20 fractions)) [46].

A recent systematic review and meta-analysis compared single fraction radiotherapy to short course multiple fraction radiotherapy (defined as multiple fractions given in 1 week or less) in MSCC [47]. The first three RCTs described above were included in their analysis. Overall, they found no evidence of an observed difference in motor response or overall survival between single dose or multi fraction radiotherapy for MSCC.

Recommendation:

- In patients who are not fit or eligible for surgery a single dose of 8–10 Gy should be delivered. [Grade A, Level 1a]

Stereotactic body radiotherapy (SBRT) in the context of MSCC

In the context of MSCC, the role of SBRT remains unclear with little published data to date. The relative complexity also limits its applicability in the emergency situation. One phase 2 study has evaluated ‘precision radiotherapy’ in the context of MSCC patients who were not suitable for decompression surgery and already had motor deficits. A fractionation regime of 25 Gy in 5 fractions over 1 week was used, with volume modulated arc therapy (VMAT) in 38/40 patients and fixed field intensity modulated radiotherapy (IMRT) in the remaining 2/40 patients. The clinical target volume included the affected level and half a vertebral body above and below. Overall 60% (24/40) of patients had an improvement in motor symptoms and 82.5% (33/40) were ambulatory after treatment. There was one case of grade three toxicity and three patients with grade two toxicity. A historical comparison with conventional 20 Gy in 5 fractions showed superior local progression

free survival at 6 months but no difference in motor function outcome [48].

Recommendation:

- SBRT should not be used routinely outside clinical trials for MSCC. [Grade D, Level 5]

Re-irradiation in the context of MSCC

MSCC in a previously irradiated spinal cord is an increasing problem as systemic treatment becomes more effective. A prospective study of 224 patients who had initial benefit or no change from radiotherapy reported that long course fractionation regimes (40 Gy in 20 fractions, 37.5 Gy in 15 fractions or 30 Gy in 10 fractions), had a better 1 year local control than short course (8 Gy in a single fraction or 20 Gy in 5 fractions) (81 vs. 61). Similar functional and survival outcomes were reported between the two groups [49].

There is no evidence to compare salvage surgery or radiotherapy re-irradiation in this context. The concern regarding re-irradiation is that of exceeding spinal cord tolerance and invoking subsequent radiation induced myelopathy. In two prospective randomised trials 24/579 (4%) patients were reported with an in-field recurrence [50]. Around 50% had re-irradiation with maintained ambulation, in the majority dependent upon pre-retreatment ambulatory status. No patients suffered from radiation induced myelopathy. In a retrospective study of 62 patients who received a cumulative BED ≤ 100 Gy₂, no cases of radiation induced myelopathy were reported, and 40% of patients showed an improvement in motor function [51]. Median time to recurrence was between 5–6 months in both papers. Multiple fractionation regimes were used in these studies including 4 Gy, 7 Gy or 8 Gy single fraction, 15 Gy in 5 fractions, 16 Gy in 2 fractions or 20 Gy in 5 fractions. No differences between regimes were reported and

the risk of myelopathy appears small if the cumulative BED is restricted to less than 135 Gy₂.

There is no evidence to guide retreatment within 6 months from initial radiotherapy treatment.

Recommendation:

- Re-irradiation of MSCC is safe after six months providing the cumulative BED is ≤ 100 –135.5 Gy₂. [Grade B, Level 2]

What is the optimal technique and dose fractionation for postoperative radiotherapy?

Evidence for post-operative radiotherapy

Since surgical decompression for MSCC is not a tumour ablative procedure, postoperative radiotherapy is routinely recommended. Various radiotherapy regimens have been used including 30–40 Gy in 15–20 fractions post laminectomy [52] and 30 Gy in 10 fractions post decompressive surgery [36]. The only randomised trial which provides the justification for primary surgery and post-operative radiotherapy used 30 Gy in 10 fractions to a field encompassing the ‘visible lesion’ and one vertebral level above and below [36]. Pre-operative radiotherapy is not recommended due to the higher complication rate in particular wound infection and dehiscence [53].

Recommendation:

- In the absence of high level comparative data a dose of 30 Gy in 10 fractions should be used post-operatively. [Grade B, Level 1]

Can the outcome of MSCC after radiotherapy be predicted?

A number of scoring systems to predict prognosis after treatment for MSCC have been published. The most widely quoted is the Tokuhashi Score which produces a score to aid treatment deci-

Table 3
Summary of scoring systems available to assist in predicting outcome in patients receiving radiotherapy for metastatic spinal cord compression (MSCC).

	Bartels et al. 2007	Rades et al. 2013	Rades et al. 2008
Predicted Outcome	Survival	Survival	Ambulatory function
How the scoring systems are used	The 5 below variables are inputted into a freely available website and survival tables and plots are produced. Based on predicting prognosis of more or less than 3 months which may help guide management	Points based system for each variable below. A total score of ≥ 24 points is highly probable of death within 2 months which may help guide management	Points based system for each variable below. A score of ≤ 28 – poor prognosis, consider short course radiotherapy for pain control or best supportive care, 29–37 – consider surgical management, ≥ 38 – consider RT alone
Number	219	2029	2096
Performance Status	KPS 10–20, 30–40, 50–70, 80+	ECOG 1/2 vs 3/4	
Extraskelatal Metastasis	Curable Y/N	Y/N	Y/N
Vertebral Metastasis	Cervical Y/N	Other bone metastasis Y/N	
Primary Site	Breast and Prostate/Lung/Kidney/Other	Breast/Prostate/Lung/Myeloma/Lymphoma/Other	Breast/Prostate/Myeloma/Lymphoma/Lung/CUP/Renal/Colorectal/Other
Gender	M/F		
Time to developing motor deficits		1–7, >7 days	1–7, 7–14, >14 days
Ambulatory prior to radiotherapy		Y/N	Y/N
Interval from cancer diagnosis to MSCC		\leq or >15 months	\leq or >15 months

sions, and is based on performance status, mobility, primary tumour, presence of extra skeletal metastases, organs involved, and number of vertebral metastases [54]. This was developed and validated in surgical cohorts, as were several of the other scoring systems.

Only four, the Bartels [55], van der Linden [56], Rades [57] and Bollen [58] scores, are based on radiotherapy cohorts. Bartels and Rades scoring systems were based on MSCC cohorts and a summary has been included in Table 3. No single scoring system has been shown to have greater predictive power. There is one scoring system to predict post radiotherapy ambulatory outcomes in patients with MSCC based on a previous retrospective analysis, also shown in Table 3 [59].

Recommendations:

- Survival after radiotherapy for spinal cord compression can be predicted using one of the published scoring systems developed in radiotherapy cohorts. [Grade B, Level 2]
- Recovery of ambulatory function after radiotherapy may be predicted by the Rades prognostic score. [Grade C, Level 2]
- Fig. 2 provides a decision tree of the management MSCC

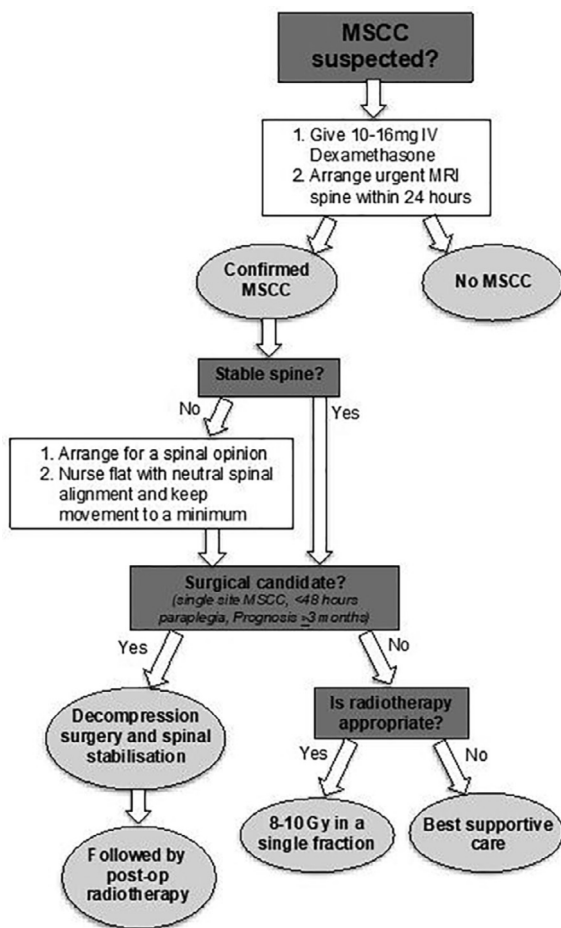


Fig. 2. Decision tree for the management of metastatic spinal cord compression (MSCC).

Box 1 Key recommendations: Metastatic Spinal Cord Compression

Diagnosis:

- MRI-whole spine is the investigation of choice for suspected metastatic spinal cord compression and should be performed urgently within 24 h of presentation
- If MRI is contraindicated or unavailable, CT whole spine without and with IV contrast should be used

MSCC with unknown primary:

- Urgently assess suspected MSCC for evidence of a primary tumour clinically
- If there is no known malignancy, urgent tissue diagnosis should be sought through blood markers e.g. PSA, definitive surgery, CT guided biopsy of the spinal tumour or biopsy of an accessible soft tissue mass under image guidance.

Steroids:

- IV dexamethasone 10-16 mg should be started immediately after completion of diagnostic procedures
- IV dexamethasone should be followed by a tapering course of oral dexamethasone from starting dose over the next 10-14 days
- Consider use of a proton pump inhibitor for gastric protection with dexamethasone, especially if the patient is already taking a NSAID

Spinal instability:

- Patients with single site MSCC, <48 h paraplegia and life expectancy of ≥3 months should be referred for urgent surgical decompression and stabilisation followed by postoperative radiotherapy
- For patients with suspected spinal instability, consult with a spinal surgeon
- All other patients should be discussed urgently within a multidisciplinary team including a radiation-oncologist, medical oncologist and a spinal surgeon

Confirmed single site MSCC, < 48 h paraplegia and life expectancy of >3 months:

- Refer for urgent surgical decompression and stabilisation followed by postoperative radiotherapy
- All other patients should be referred for radiotherapy

Radiotherapy fractionation:

- In patients who are not fit or eligible for surgery a single dose of 8–10 Gy should be delivered
- SBRT should not be used routinely outside clinical trials for MSCC

Re-irradiation for MSCC

- Re-irradiation of MSCC is safe after six months providing the cumulative BED is ≤100–135.5 Gy

Prediction of outcome scoring systems after radiotherapy for MSCC:

- Survival after radiotherapy for spinal cord compression can be predicted using one of the published scoring systems developed in radiotherapy cohorts
- Recovery of ambulatory function after radiotherapy may be predicted by the Rades prognostic score

Neuropathic pain

What is neuropathic pain?

Neuropathic pain is defined by the International Association for the Study of Pain as “pain caused by a lesion or disease of the somatosensory nervous system” [60]. In the context of malignancy, it may arise from damage to neural tissue through infiltrative, compressive or iatrogenic processes such as biopsy or surgical excision and can also arise following chemotherapy or radiotherapy [61]. Pain is typically in the distribution of the peripheral nervous system and is characteristically described as “sharp, stabbing, burning, electric shock like” and often accompanied by sensory, motor or autonomic impairment [62].

In the context of bone metastasis, pain is thought to come from compression of nerves due to tumour itself or from cytokines produced in response to tumour triggering a pain response [63].

A systematic review of patients with cancer related pain analysing 11,063 patients, concluded that between 19% and 39% of patients with cancer related pain are likely to have an element of neuropathic pain [64]. Pain was solely neuropathic in 19% of the cohort, and in an additional 20% showed a mixed pain with a neuropathic element.

What is the role of radiotherapy versus drugs versus physical treatments?

The ESMO Clinical Practice Guideline 2018 [60] for the management of cancer pain, recommends first line treatment for neuropathic pain should be based on medication using one of gabapentin, pregabalin, duloxetine or a tricyclic antidepressant. These can be used in combination with opioids. Other pharmacological approaches include ketamine, an NMDA (N-Methyl-D-aspartic acid) receptor antagonist, and spinal opioids using temporary or permanent catheters. Radiotherapy is also an effective treatment for neuropathic pain from bony metastases. Unfortunately, most studies demonstrating the benefit in reducing pain from bone metastases with radiotherapy fail to differentiate the type of pain experienced by patients.

Neurostimulation therapy using transcutaneous (TENS) or implanted devices works by inhibiting dorsal horn neuronal activity, which is triggered through noxious stimuli, by stimulation of the dorsal columns [65].

There is no comparative evidence to evaluate the relative role of these treatments and no recommendation can be given with regard to the use of radiotherapy. In practice most patients will have a trial of drug therapy whilst awaiting referral for radiotherapy if the pain persists.

What is the optimal technique and dose fractionation in patients with neuropathic pain?

A phase 3 randomised controlled trial [63] compared 8 Gy single dose with 20 Gy in 5 fractions in 272 patients with bony metastasis causing neuropathic pain based on clinical criteria with no

evidence of cord compromise. Photon or electron radiation was used depending on the site to be treated, and typically was a direct field to 5 cm depth for spinal metastases, direct field applied to Dmax for ribs and parallel opposed fields to midplane for any other sites.

The overall response rate in the 8 Gy group was 53% (45–62%) and for 20 Gy was 61% (53–70%) $p = 0.18$ with similar complete responses (26% in 8 Gy group vs. 27% in 20 Gy group, $p = 0.89$). There were no differences between the two groups in need for re-treatment, pathological fracture or spinal cord compression. It was concluded that 8 Gy in 1 fraction was not statistically significantly worse than 20 Gy in 5 fractions.

Recommendation:

- Radiotherapy should be used alongside appropriate drug and neurostimulatory treatments for neuropathic pain from bone metastases.
- A single dose of 8 Gy using conventional techniques should be used for neuropathic pain. [Grade A, Level 1b]

Box 2 Key recommendations: Neuropathic Pain

- Radiotherapy should be used alongside appropriate drug and neurostimulatory treatments for neuropathic pain from bone metastases
- A single dose of 8 Gy using conventional techniques should be used for neuropathic pain

Fracture and threatened fracture

What is the epidemiology of pathologic fracture?

A fracture that develops through a metastasis is considered a ‘pathologic fracture’. In some cases, the extent of bone destruction is such that a fracture is imminent but not complete, a so-called threatened fracture. The goal of treatment of a threatened fracture is to prevent fracture, minimize morbidity and maximize function and skeletal integrity. Although pathological fractures are often seen in patients with known bone metastases, sometimes a pathologic fracture is the presenting sign of malignancy. Pathologic fractures are not infrequent, developing in up to 30% of patients with bone metastases [66–68].

Before fracturing, the lesion at risk can present with pain or discomfort as a sign of a threatened fracture [69]. When a pathological fracture occurs, the patient may experience an increase in pain and deformity of the broken bone including shortening or distortion if the fracture is within the limb or kyphosis of the spine if one or more vertebrae are affected. If in a weight bearing bone, the fracture can render the patient non-ambulatory.

Common sites of long bone pathological fractures include the femur, tibia, and humerus. Within the long bones, the femur is the most commonly affected site, with most cases affecting the proximal femur [69].

On one hand recognition of metastatic lesions at high risk of fracture is essential for timely prophylactic fixation, while on the other hand patients with a low risk of pathologic fractures should be spared from overtreatment. Because of anatomical considerations, the definition of a threatened pathologic fracture differs among three of the most important, major anatomic sites (long bones, acetabulum, and vertebrae).

What investigations are recommended for the diagnosis of a suspected pathologic fracture in different locations?

Besides a focussed history and clinical examination, the diagnosis of a pathologic fracture is usually made through imaging. Most pathologic fractures result in symptoms. The main recommendations for imaging of symptomatic bone metastasis are discussed in the guideline for uncomplicated bone metastases.

On a plain radiograph, a fracture line may be visible and the normal anatomic alignment may be displaced. Compression fractures in vertebral bodies show up as a collapse of the endplates. However, it is estimated that close to 10% of pathologic fractures are not confidently detected by plain radiographs [70].

CT is accurate for the determination of the bone cortex as well as the presence of malignant extra-osseous tissue. The character of underlying bone marrow patterns of destruction can also be reviewed [71]. MRI is even more sensitive than CT for the detection of underlying bone marrow lesions at a fracture site, in order to differentiate between a pathological or an insufficiency fracture [70].

For suspected pathologic fracture in the spine, MRI is the investigation of choice, in order to exclude spinal cord compression. This is discussed in more detail in the guideline for uncomplicated bone metastases.

Recommendations:

- Urgently investigate an increase in bone pain, deformity or loss of height, especially in weight bearing bone, with imaging to identify pathological fracture. [Grade D, Level 4]
- Imaging can be limited to plain X-ray in clear cases, but more detail is obtained with CT or MRI. [Grade D, Level 4]

How can the fracture risk best be assessed?

Long bones

There is one scoring system for defining the risk of fracture in long bones: the Mirels scoring system [72]. This system is based on four criteria (clinical and radiographical), weighted with one to three points. The total score is linked to fracture risk and recommendations for prophylactic surgical treatment. A score of ≥ 9 defines an impending pathologic fracture for which prophylactic stabilization is recommended. It is considered the gold standard for the diagnosis of impending fractures [72]. However, there are several limitations to this scoring system: while it is highly sensitive, specificity for actual fracture prediction is limited. Fracture risk for the defined “impending fracture” risk category (≥ 9) was only 33% [72]. In other words, fracture risk prediction using Mirels’ score, based on pure clinical data, shows a negative predictive value between 86 and 100%, but moderate to poor results in predicting non-impending fractures with a positive predictive value

between 14 and 70% [73,74]. Additionally, there is an issue with interobserver and intraobserver reproducibility and the risk of humeral fracture utilizing Mirels system may require an adjustment of the definition in order to yield comparable fracture risks to those derived from the original population, which was predominantly femoral fractures [75].

A simpler and more clinically useful predictor of fracture is the parameter of 30 mm axial cortical involvement on plain radiography derived from fracture risk in femoral bone metastases, combined with increasing pain [76,77]. A clinical validation study showed that sensitivity, specificity, positive predictive value and negative predictive value of axial cortical involvement for predicting femoral fractures were 86%, 50%, 20% and 96%, respectively.

On CT the risk of fracture can be determined by the structural rigidity analysis (CTRA), using tissue mineral density and cross-sectional geometry to determine changes to structural competency of the bone induced by lytic lesions [73,78,79].

Acetabulum

Classically, the location and extent of cortical destruction in the acetabulum are used to evaluate the biomechanical impact on function [80]. Destruction of the superior and medial walls has been suggested to constitute mechanical compromise [81].

Spine

There has been no widely accepted definition of what constitutes an unstable spine. Older approaches to defining spinal instability relied mainly on clinical features with support from diagnostic imaging. Both clinical signs and symptoms, as well as radiological findings must be considered. A classification system for spinal instability in neoplastic disease was developed by the Spine Oncology Study Group on the basis of a systematic review and modified Delphi criteria evaluating factors crucial for the assessment of spinal stability [82]. Six individual components of spinal instability are scored, with the final Spine Instability Neoplastic Score (SINS) representing a composite score of the individual components (Table 4). The score stratifies patients into three categories: those with a suspected stable spine (score 0 to 6), potentially unstable spine (score 7 to 12), and unstable spine (score 13 to 18). According to this classification, a surgical consultation is recommended for patients with SINS scores greater than 7. The sensitivity and specificity of SINS for potentially stable and unstable lesions is 95.7% and 79.5%, with a high intraobserver reliability [83,84]. Note that the SINS was developed to help identify spinal tumour related instability, to guide referrals and improve communication but not as a prognostic tool for treatment outcome. As the SINS includes components quantifying the current degree of spinal instability (e.g. spinal alignment) as well as components reflecting

Table 4
Summary table of all elements including in the SINS score adapted from Fisher et al 2010.

Score	0	1	2	3	4
Instability Pain	No	Occasional pain but not instability pain	–	Yes	–
Bone lesion	Blastic	Mixed	Lytic	–	–
Location	S2–S5	T3–T10	C3–C6, L2–L4	Occiput–C2, C7–T2, T11–L1, L5–S1	–
Radiological alignment	No change	–	Kyphosis/– scoliosis	–	Subluxation/translation present
Radiological collapse	No	No collapse but >50% vertebral body involved	<50% collapse	>50% collapse	–
Posterior spinal element involvement	No	Unilateral	–	Bilateral	–

Score: 0–6 – stable, 7–12 – potentially unstable, 13–18 – unstable (7–18 warrants surgical review).

the future risk of spinal instability (e.g. lytic aspect of the lesion), the SINS is less applicable as a prediction tool [85,86].

Other

For other anatomic sites, such as ribs, we could not find any data to calculate the risk of a pathologic fracture.

Recommendations:

- The Mirels score is used to predict risk of long bone fracture recognising its low predictive value for fracture and limitations for long bones other than femur. [Grade C, Level 3]
- 30 mm axial cortical involvement should be used for clinical evaluation of fracture risk as an alternative to Mirels.
- Spinal stability may be assessed using the SINS score. [Grade C, Level 3]

Box 3 Key recommendations: Pathological fracture

- An increase in pain, deformity or loss of weight bearing is an indication for urgent imaging to identify pathological fracture
- Imaging includes plain x-ray but more detail is obtained with CT or MRI
- 30 mm axial cortical involvement should be used for clinical evaluation of fracture risk as an alternative to Mirels
- Spinal instability should be assessed using the SINS score

What is the role of local management for impending fracture?

The choice of treatment for a patient with a threatened fracture depends on the site, the tumour histology, the patient's general condition and estimated survival. There are several independent risk factors and scoring systems to determine the risk of fracture and no gold standard has been defined, so risk estimates should be regarded with caution.

In general, multidisciplinary treatment consisting of surgical stabilisation with post-operative radiotherapy should be the primary treatment option, especially for a weight bearing bone [87,88]. The type of surgical fixation should be selected based on the patient's estimated survival: treatment should last patients throughout the rest of their lives. Recovery time after surgery should also be relative to their estimated survival. General consensus is that an estimated survival of 6–12 weeks would be the minimum life expectancy required for relatively simple procedures to stabilise a bone such as intramedullary nailing, and 6 months for complex reconstruction procedures [71,75].

After surgery alone, tumour progression may occur. Postoperative radiotherapy may have a role to eliminate residual tumour and to prevent disease progression and further osteolysis [89–91]. Additionally, postoperative radiotherapy achieves pain relief, reverses inflammation resulting from bone metastasis, and promotes the recalcification of lytic lesions [92]. The role of postoperative radiotherapy in patients with surgically stabilized metastatic bone disease has been shown in a retrospective study in which recovery of normal functional status was significantly better for the group having surgery plus postoperative radiotherapy compared to radiotherapy only [93]. A second retrospective study has confirmed this effect [94]. However, it should be noted that the quality of evidence is low, due to the design of both studies (Willeumier et al. 2016). In patients with a poor performance status and limited life expectancy postoperative radiotherapy may be omitted.

Non-surgical treatment with radiotherapy, chemotherapy or both should be considered for patients with chemosensitive tumours about to undergo chemotherapy, such as myeloma and lymphoma, or those with poor PS and limited prognosis, even for weight bearing bone [95,96]. In other cases with poor performance status and limited life expectancy a non-surgical approach may also be chosen.

Currently, there is no evidence for the use of high dose radiotherapy or SBRT in this setting.

Pelvis

Lesions of the wing of the ilium, the sacroiliac joint or the anterior arch of the pelvis are generally not at risk of mechanical failure. Peri-acetabular lesions are weight bearing and are at risk of mechanical failure [80]. Radiotherapy has a role in helping with pain relief and bone healing [97]. In selected cases surgery can be considered at these sites for solitary and late onset lesions in patients with a favourable prognosis (>6 months) [81,87–89,95,96].

Long bones

In the long bones, highly stressed anatomical sites are at particular risk of pathological fracture [89]. Prophylactic treatment to prevent fracture will help to maintain patient function and mobility and can be technically easier than reactive surgery. It is likely to be associated with less patient morbidity, better recovery, and shorter postoperative care and length of hospital stay [98,99].

Approximately 23–60% of impending pathological fractures occur in the proximal femoral region [100,101]. Surgical stabilisation with intramedullary nailing is generally considered the preferred treatment over plate osteosynthesis in this and most areas of the femur due to load sharing capabilities [102,103].

For lesions in the humerus both intramedullary nailing and plate fixation can be considered, as this is a non-weight bearing structure [104,105]. Because pathological fractures of the humerus severely restrict the use of the involved arm and hand, surgical stabilization of symptomatic impending pathological fractures is frequently recommended [106].

Traditional teaching is to include all surgical hardware within the CTV if there was potential surgical seeding of malignant cells, for example the full extent of the intramedullary nail in the femur. However, there is limited evidence to suggest it is better than a smaller CTV and some suggestions have been made to omit the surgical hardware from the CTV in patients with a poor performance status, in order to limit the risk of any excessive toxicity [107]. As toxicity of radiation is limited in long bones, traditional fields including all surgical hardware are recommended.

Spine

Fractures of the vertebrae that cause dural or spinal cord compression are usually grouped with patients who experience spinal cord compression due to extra-osseous tumour growth. The treatment of patients experiencing spinal cord compression by pressure from bone fragments or tumour extending outside the vertebrae is covered under the section 'spinal cord compression'.

EBRT alone is a commonly used primary treatment option for patients with vertebral metastases resulting in adequate pain relief with acceptable local tumour control [108]. However, it does not always result in the stabilization or healing of vertebral compression fractures [109,110].

Spinal instability as a consequence of metastatic spine disease without fracture may occur [84,111]. Patients in this situation may benefit from surgical intervention in combination with radiotherapy [111–113].

Kyphosis of the spine may compromise the biomechanics of the spine, which in turn predisposes to an increased risk of further

fractures in the adjacent vertebrae [114]. For patients with compression fractures in the vertebrae, with pain and/or instability, but who do not qualify for stabilizing surgery balloon kyphoplasty (BKP) is a treatment option. BKP is a minimally invasive procedure that stabilizes the vertebral fracture and also provides the opportunity to restore vertebral height and reduce spinal kyphosis [115,116]. An alternative procedure for compression fractures of the spine is percutaneous vertebroplasty (PVP) [117–119]. In the absence of direct symptoms of cord compression, destruction of the vertebral dorsal wall and the presence of epidural involvement are considered to be relative contraindications to the procedure. Neurological symptoms due to spinal canal compression is regarded as a strong contraindication to PVP, because the procedure carries a risk of aggravating it, although it has been used in patients with symptoms [120–123].

In the CAFE trial, 134 patients with vertebral compression fractures were enrolled and randomly assigned to kyphoplasty or non-surgical management. The study found that patients treated with BKP had a significantly better reduction in back pain after seven days [124]. BKP has a lower risk of cement leakage to the spinal canal when compared to PVP, and a positive effect on pain relief and improvement of the functional capacity of patients up to 24 months following the intervention [109].

Both BKP and PVP have no documented anti-tumour effect and thus additional postoperative radiotherapy is required to avoid further tumour growth, however no clear fractionated schedule has been established.

Traditionally, radiotherapy is given after surgical stabilisation, within a timeframe of 1–2 weeks to allow for wound healing [125]. However, a single arm phase I trial where patients with unstable spinal metastases were given SBRT followed by surgical stabilization within 24 h showed promising results. In this trial there was a fast improvement of pain and no wound complications [126]. A phase III trial to confirm these findings has not been performed yet.

Other localisations

Some localisations, such as ribs, are difficult to treat with surgery, and can be treated with primary radiotherapy. Regarding pain after primary radiotherapy, little is known about the differences in response rates between patients with complicated and uncomplicated bone metastases. Most RCTs that evaluate radiotherapy for bone metastases exclude patients with features of complicated bone metastases, including threatened or existing pathologic fracture [127].

Recommendations:

- Impending fracture, regardless of the anatomical localisation, requires multidisciplinary discussion, to consider treatment with surgery and radiotherapy. [Grade B, Level 2]
- In case of disease-related poor performance status, myeloma or lymphoma, radiotherapy alone can be considered. [Grade B, Level 2]

What fractionation scheme is most effective for the treatment and remineralisation of threatened fracture?

There is no direct evidence on fractionation for prevention of pathologic fracture, because there are no randomised comparisons of different dose fractionated schedules and other trials have not evaluated the risk of pathologic fracture prior to treatment. Osteolytic bone lesions which have been irradiated may remineralise while sclerotic lesions may demineralise. Some studies show a reduction of bone density just after completion of radiotherapy followed by an increase during follow-up [128,129].

The risk of pathological fracture after radiotherapy for uncomplicated bone metastases has been evaluated in several clinical trials. However, the primary endpoint of all these trials was to evaluate the difference in pain relief, not the pathological fracture incidence. Overall, no difference in fracture rate after a single fraction (8 Gy) or a multi-fraction schedule (20 Gy in 4 fractions, 30 Gy in 10 fractions, 35 Gy in 14 fractions, 40 Gy in 20 fractions) is seen [63,130–134]. One exception is the Dutch bone metastases study, which showed more pathological fractures long term after 8 Gy in a single fraction (4%) compared to 24 Gy in 6 fractions (2%) which although statistically significant may not be considered clinically relevant [135].

Multi-fractionation schedules such as the most commonly used 30 Gy in 10 fractions tend to be prescribed with the aim to maximize recalcification but there is no clear evidence to support this schedule above any other fractionated schedule [136–138]. Recalcification can occur after a single fraction of 8 Gy [130,132] and based on the response rate seen in painful bone metastases and results of re-irradiation in this group, 8 Gy single fraction seems no less effective than fractionated schedules [139]. One retrospective study suggests that there is a preference for a fractionated schedule compared to a single fraction schedule [134] and a prospective trial has suggested that because the biological efficacy is higher, a fractionated schedule for recalcification could lead to better stabilisation. In this trial, there was a slight difference in remineralisation between the fractionated arm (30 Gy in 10 fractions) and the single fraction arm (8 Gy in 1 fraction), but the only primary tumour for which this was significant was breast cancer ($p < 0.0001$) [138]. In pathological fracture or high fracture risk there is no evidence that SBRT is superior to conventional radiotherapy and an increased risk of fracture of unstable vertebrae after SBRT has been reported particularly with doses exceeding 20 Gy per fraction.

Recommendations:

- In the absence of comparative data, a single dose of 8 Gy or fractionated schedule such as 20 Gy in 5 fractions or 30 Gy in 10 fractions may be used to prevent pathological fracture. [Grade C, Level 3]
- Where recalcification is the aim of treatment a single dose of 8 Gy or fractionated schedules such as 20 Gy in 5 fractions or 30 Gy in 10 fractions are recommended as there is no evidence for a clinically significant difference. [Grade C, Level 1]

Re-irradiation of a threatened fracture

Various rates of pathologic fracture have been reported at a site of previous irradiation. Data from the Dutch Bone Metastases Study show a risk of post-irradiation fracture of 12.7%, based on 110 femurs. In a retrospective study with 428 patients with a femoral metastasis, post-irradiation fracture occurred in 7.7% [76]. These fractures occurred a median of 4.4 months after radiotherapy, with 39.4% occurring within 3 months and 63.6% within 6 months. Among femurs with high fracture risk according to Harrington's criteria or Mirels' score, the fracture rate was 13.9% and 11.8%, respectively [140]. Another, smaller, retrospective study on 47 patients (18 lung, 11 breast, 10 prostate and 8 other cancers) reported initial circumferential involvement $\geq 30\%$ to be the only predictive parameter for fracture after multivariate analysis [141]. In this study the risk of fracture was 21%.

The problem with most studies regarding fracture risk after radiation is that they rarely report large numbers of patients and many reports do not describe the histology of the fracture sites.

Additionally, there is no comparative data to define precise treatment regimes for re-irradiation of a threatened fracture or progressive fracture after treatment. Management should be the

same as for a primary pathologic fracture with the same considerations regarding surgery and post-operative radiotherapy or primary re-irradiation. In case of a fracture in an area that was previously treated with higher doses, a recalculation of the given dose should be considered to avoid excessive treatment-related toxicity. There is no indication that re-irradiation of a lesion has a lower success rate than the initial irradiation.

Recommendation:

- Consider surgery and post-operative irradiation or primary re-irradiation for previously irradiated bone with threatened or actual fracture using single dose 8 Gy or fractionated schedules such as 20 Gy in 5 fractions or 30 Gy in 10 fractions. [Grade D, Level 5]

Extra-osseous tumoural extension

What is the preferred treatment for bone metastases with extra-osseous tumoural extension?

In cases where lytic disease is associated with a large soft-tissue mass, the desired palliative endpoint may be tumour shrinkage as well as pain control. Lesions with soft tissue components extending beyond the cortex of the bone can cause specific pain if they push upon or invade the neural foramina, epidural space or spinal cord. The treatment of neuropathic pain has already been described. Soft-tissue extension from a vertebral metastasis may result in neural or spinal cord compression, management of which has already been described.

There is no data to specifically guide management of extra-osseous soft tissue extension of bone metastases.

Recommendations:

- Neuropathic pain or spinal cord compression due to extraosseous extension of bone metastases should be treated according to the specific guidelines for these conditions.
- Bone metastases with extra-osseous extension may be treated with palliative radiotherapy encompassing the entire tumour mass using for example a single dose of 8 Gy, 20 Gy in 5 fractions or 30 Gy in 10 fractions. [Grade D, Level 5]

Box 4 Key recommendations: Threatened fracture and recalcification

- Pathological fracture requires multidisciplinary treatment with surgery followed by radiotherapy
- In case of disease-related poor performance status, myeloma or lymphoma, radiotherapy alone can be considered
- Balloon kyphoplasty or percutaneous vertebroplasty should be considered for compression fractures of the vertebrae
- In the absence of comparative data a single dose of 8 Gy or palliative fractionation schedule such as 20 Gy in 5 fractions or 30 Gy in 10 fractions may be used to prevent pathological fracture
- Where recalcification is the aim of treatment a single dose of 8 Gy, 20 Gy in 5 fractions or 30 Gy in 10 fractions may be given
- Bone metastases with extra-osseous extension may be treated with palliative radiotherapy encompassing the entire tumour mass using for example a single dose of 8 Gy, 20 Gy in 5 fractions or 30 Gy in 10 fractions

Acknowledgements

We are grateful to the following for reviewing these guidelines:
E. Chow, Y. Lievens, S. Lutz, C. Nieder.

Financial support and conflicts of interest

The authors report no conflicts of interest.
Peter Hoskin is supported by NIHR Manchester Biomedical Centre.

Disclaimer

ESTRO cannot endorse all statements or opinions made on the guidelines. Regardless of the vast professional knowledge and scientific expertise in the field of radiation oncology that ESTRO possesses, the Society cannot inspect all information to determine the truthfulness, accuracy, reliability, completeness or relevancy thereof. Under no circumstances will ESTRO be held liable for any decision taken or acted upon as a result of reliance on the content of the guidelines.

The component information of the guidelines is not intended or implied to be a substitute for professional medical advice or medical care. The advice of a medical professional should always be sought prior to commencing any form of medical treatment. To this end, all component information contained within the guidelines is done so for solely educational and scientific purposes. ESTRO and all of its staff, agents and members disclaim any and all warranties and representations with regards to the information contained on the guidelines. This includes any implied warranties and conditions that may be derived from the aforementioned guidelines.

Appendix A. Supplementary data

Supplementary data to this article can be found online at <https://doi.org/10.1016/j.radonc.2022.06.002>.

References

- [1] Cole JS, Patchell RA. Metastatic epidural spinal cord compression. *Lancet Neurol* 2008;7:459–66. [https://doi.org/10.1016/S1474-4422\(08\)70089-9](https://doi.org/10.1016/S1474-4422(08)70089-9).
- [2] Kim JM, Losina E, Bono CM, Schoenfeld AJ, Collins JE, Katz JN, et al. Clinical outcome of metastatic spinal cord compression treated with surgical excision ± radiation versus radiation therapy alone: a systematic review of literature. *Spine (Phila Pa 1976)* 2012;37:78–84.
- [3] Bilsky MH, Laufer I, Fourny DR, Groff M, Schmidt MH, Varga PP, et al. Reliability analysis of the epidural spinal cord compression scale. *J Neurosurg Spine* 2010;13:324–8.
- [4] Loblaw DA, Laperriere NJ, Mackillop WJ. A population-based study of malignant spinal cord compression in Ontario. *Clin Oncol (R Coll Radiol)* 2003;15:211–7. [https://doi.org/10.1016/s0936-6555\(02\)00400-4](https://doi.org/10.1016/s0936-6555(02)00400-4).
- [5] Pigott KH, Baddeley H, Maher EJ. Pattern of disease in spinal cord compression on MRI scan and implications for treatment. *Clin Oncol* 1994;6:7–10. [https://doi.org/10.1016/S0936-6555\(05\)80361-9](https://doi.org/10.1016/S0936-6555(05)80361-9).
- [6] Bach F, Larsen BH, Rohde K, Borgesen SE, Gjerris F, Bøge-Rasmussen T, et al. Metastatic spinal cord compression. Occurrence, symptoms, clinical presentations and prognosis in 398 patients with spinal cord compression. *Acta Neurochir (Wien)* 1990;107:37–43.
- [7] Prasad D, Schiff D. Malignant spinal-cord compression. *Lancet Oncol* 2005;6:15–24. [https://doi.org/10.1016/S1470-2045\(04\)01709-7](https://doi.org/10.1016/S1470-2045(04)01709-7).
- [8] Loblaw DA, Laperriere NJ. Emergency treatment of malignant extradural spinal cord compression: an evidence-based guideline. *J Clin Oncol* 1998;16:1613–24. <https://doi.org/10.1200/JCO.1998.16.4.1613>.
- [9] Medical Research Council (Great Britain). Aids to the examination of the peripheral nervous system. London: H.M.S.O.; 1976.
- [10] Gold M. Magnetic resonance imaging of spinal emergencies. *Top Magn Reson Imaging* 2015;24:325–30. <https://doi.org/10.1097/RMR.000000000000069>.
- [11] Colletti PM, Siegel HJ, Woo MY, Young HY, Terk MR. The impact on treatment planning of MRI of the spine in patients suspected of vertebral metastasis: an efficacy study. *Comput Med Imaging Graph* 1996;20:159–62. [https://doi.org/10.1016/0895-6111\(96\)00009-2](https://doi.org/10.1016/0895-6111(96)00009-2).
- [12] Cook AM, Lau TN, Tomlinson MJ, Vaidya M, Wakeley CJ, Goddard P. Magnetic resonance imaging of the whole spine in suspected malignant spinal cord compression: impact on management. *Clin Oncol (R Coll Radiol)* 1998;10:39–43. [https://doi.org/10.1016/s0936-6555\(98\)80111-8](https://doi.org/10.1016/s0936-6555(98)80111-8).

- [13] Kim JK, Learch TJ, Colletti PM, Lee JW, Tran SD, Terk MR. Diagnosis of vertebral metastasis, epidural metastasis, and malignant spinal cord compression: are T(1)-weighted sagittal images sufficient? *Magn Reson Imaging* 2000;18:819–24. [https://doi.org/10.1016/s0730-725x\(00\)00181-8](https://doi.org/10.1016/s0730-725x(00)00181-8).
- [14] Ratanatharathorn V, Powers WE. Epidural spinal cord compression from metastatic tumor: diagnosis and guidelines for management. *Cancer Treat Rev* 1991;18:55–71. [https://doi.org/10.1016/0305-7372\(91\)90004-j](https://doi.org/10.1016/0305-7372(91)90004-j).
- [15] Patel DM, Weinberg BD, Hoch MJ. CT myelography: clinical indications and imaging findings. *Radiographics* 2020;40:470–84. <https://doi.org/10.1148/rg.2020190135>.
- [16] Carmody RF, Yang PJ, Seeley GW, Seeger JF, Unger EC, Johnson JE. Spinal cord compression due to metastatic disease: diagnosis with MR imaging versus myelography. *Radiology* 1989;173:225–9. <https://doi.org/10.1148/radiology.173.1.2675185>.
- [17] Hagenau C, Grosh W, Currie M, Wiley RG. Comparison of spinal magnetic resonance imaging and myelography in cancer patients. *J Clin Oncol* 1987;5:1663–9. <https://doi.org/10.1200/JCO.1987.5.10.1663>.
- [18] Li KC, Poon PY. Sensitivity and specificity of MRI in detecting malignant spinal cord compression and in distinguishing malignant from benign compression fractures of vertebrae. *Magn Reson Imaging* 1988;6:547–56. [https://doi.org/10.1016/0730-725x\(88\)90129-4](https://doi.org/10.1016/0730-725x(88)90129-4).
- [19] Husband DJ, Grant KA, Romaniuk CS. MRI in the diagnosis and treatment of suspected malignant spinal cord compression. *Br J Radiol* 2001;74:15–23. <https://doi.org/10.1259/bjr.74.877.740015>.
- [20] Groenen KHJ, van der Linden YM, Brouwer T, Dijkstra SPD, de Graeff A, Algra PR, et al. The Dutch national guideline on metastases and hematological malignancies localized within the spine; a multidisciplinary collaboration towards timely and proactive management. *Cancer Treat Rev* 2018;69:29–38.
- [21] National Collaborating Centre for Cancer (UK). Metastatic spinal cord compression: diagnosis and management of patients at risk of or with metastatic spinal cord compression. Cardiff (UK): National Collaborating Centre for Cancer (UK); 2008.
- [22] Rades D, Blach M, Bremer M, Wildfang I, Karstens JH, Heidenreich F. Prognostic significance of the time of developing motor deficits before radiation therapy in metastatic spinal cord compression: one-year results of a prospective trial. *Int J Radiat Oncol Biol Phys* 2000;48:1403–8. [https://doi.org/10.1016/s0360-3016\(00\)01408-5](https://doi.org/10.1016/s0360-3016(00)01408-5).
- [23] Findlay GF, Sandeman DR, Buxton P. The role of needle biopsy in the management of malignant spinal compression. *Br J Neurosurg* 1988;2:479–84. <https://doi.org/10.3109/02688698809029602>.
- [24] Borenstein SH, Gerstle T, Malkin D, Thorner P, Filler RM. The effects of prebiopsy corticosteroid treatment on the diagnosis of mediastinal lymphoma. *J Pediatr Surg* 2000;35:973–6. <https://doi.org/10.1053/jpsu.2000.6945>.
- [25] Wänman J, Grabowski P, Nyström H, Gustafsson P, Bergh A, Widmark A, et al. Metastatic spinal cord compression as the first sign of malignancy. *Acta Orthop* 2017;88:457–62.
- [26] Sørensen S, Helweg-Larsen S, Mouridsen H, Hansen HH. Effect of high-dose dexamethasone in carcinomatous metastatic spinal cord compression treated with radiotherapy: a randomised trial. *Eur J Cancer* 1994;30A:22–7. [https://doi.org/10.1016/s0959-8049\(05\)80011-5](https://doi.org/10.1016/s0959-8049(05)80011-5).
- [27] Heimdal K, Hirschberg H, Slettebø H, Watne K, Nome O. High incidence of serious side effects of high-dose dexamethasone treatment in patients with epidural spinal cord compression. *J Neurooncol* 1992;12:141–4. <https://doi.org/10.1007/BF00172664>.
- [28] Vecht CJ, Haaxma-Reiche H, van Putten WL, de Visser M, Vries EP, Twijnstra A. Initial bolus of conventional versus high-dose dexamethasone in metastatic spinal cord compression. *Neurology* 1989;39:1255–7. <https://doi.org/10.1212/wnl.39.9.1255>.
- [29] Scarpignato C, Gatta L, Zullo A, Blandizzi C. Italian Society of Pharmacology, the Italian Association of Hospital Gastroenterologists, and the Italian Federation of General Practitioners. Effective and safe proton pump inhibitor therapy in acid-related diseases - A position paper addressing benefits and potential harms of acid suppression. *BMC Med* 2016;14. <https://doi.org/10.1186/s12916-016-0718-z>.
- [30] Gilbert RW, Kim JH, Posner JB. Epidural spinal cord compression from metastatic tumor: diagnosis and treatment. *Ann Neurol* 1978;3:40–51. <https://doi.org/10.1002/ana.410030107>.
- [31] Martenson JA, Evans RG, Lie MR, Ilstrup DM, Dinapoli RP, Ebersold MJ, et al. Treatment outcome and complications in patients treated for malignant epidural spinal cord compression (SCC). *J Neurooncol* 1985;3:77–84.
- [32] Sørensen S, Børgesen SE, Rohde K, Rasmussen B, Bach F, Bøge-Rasmussen T, et al. Metastatic epidural spinal cord compression. *Results Treatm Surv Cancer* 1990;65:1502–8. [https://doi.org/10.1002/1097-0142\(19900401\)65:7<1502::aid-cnrc2820650709>3.0.co;2-d](https://doi.org/10.1002/1097-0142(19900401)65:7<1502::aid-cnrc2820650709>3.0.co;2-d).
- [33] Stark RJ, Henson RA, Evans SJ. Spinal metastases. A retrospective survey from a general hospital. *Brain* 1982;105:189–213. <https://doi.org/10.1093/brain/105.1.189>.
- [34] Young RF, Post EM, King GA. Treatment of spinal epidural metastases. Randomized prospective comparison of laminectomy and radiotherapy. *J Neurosurg* 1980;53:741–8. <https://doi.org/10.3171/ins.1980.53.6.0741>.
- [35] Klimo P, Thompson CJ, Kestle JRW, Schmidt MH. A meta-analysis of surgery versus conventional radiotherapy for the treatment of metastatic spinal epidural disease. *Neuro Oncol* 2005;7:64–76. <https://doi.org/10.1215/S1152851704000262>.
- [36] Patchell RA, Tibbs PA, Regine WF, Payne R, Saris S, Kryscio RJ, et al. Direct decompressive surgical resection in the treatment of spinal cord compression caused by metastatic cancer: a randomised trial. *The Lancet* 2005;366:643–8. [https://doi.org/10.1016/S0140-6736\(05\)66954-1](https://doi.org/10.1016/S0140-6736(05)66954-1).
- [37] Lee C-H, Kwon J-W, Lee J, Hyun S-J, Kim K-J, Jahng T-A, et al. Direct decompressive surgery followed by radiotherapy versus radiotherapy alone for metastatic epidural spinal cord compression: a meta-analysis. *Spine (Phila Pa 1976)* 2014;39:E587–592. <https://doi.org/10.1097/BRS.0000000000000258>.
- [38] Laufer I, Rubin DG, Lis E, Cox BW, Stubblefield MD, Yamada Y, et al. The NOMS framework: approach to the treatment of spinal metastatic tumors. *Oncologist* 2013;18:744–51. <https://doi.org/10.1634/theoncologist.2012-0293>.
- [39] Leone A, Cianfoni A, Zecchi V, Cortese MC, Rumi N, Colosimo C. Instability and impending instability in patients with vertebral metastatic disease. *Skeletal Radiol* 2019;48:195–207. <https://doi.org/10.1007/s00256-018-3032-3>.
- [40] Lee SH, Grant R, Kennedy C, Kilbride L. Positioning and spinal bracing for pain relief in metastatic spinal cord compression in adults. *Cochrane Database Syst Rev* 2015:CD007609. <https://doi.org/10.1002/14651858.CD007609.pub3>.
- [41] Lawton AJ, Lee KA, Chevillat AL, Ferrone ML, Rades D, Balboni TA, et al. Assessment and management of patients with metastatic spinal cord compression: a multidisciplinary review. *J Clin Oncol* 2019;37:61–71. <https://doi.org/10.1200/JCO.2018.78.1211>.
- [42] Paniagua-Collado M, Cauli O. Non-pharmacological interventions in patients with spinal cord compression: a systematic review. *J Neurooncol* 2018;136:423–34. <https://doi.org/10.1007/s11060-017-2684-5>.
- [43] Maranzano E, Trippa F, Casale M, Costantini S, Lupattelli M, Bellavita R, et al. 8Gy single-dose radiotherapy is effective in metastatic spinal cord compression: results of a phase III randomized multicentre Italian trial. *Radiother Oncol* 2009;93:174–9.
- [44] Hoskin PJ, Hopkins K, Misra V, Holt T, McMenemin R, Dubois D, et al. Effect of single-fraction vs multifraction radiotherapy on ambulatory status among patients with spinal canal compression from metastatic cancer: The SCORAD randomized clinical trial. *JAMA* 2019;322:2084.
- [45] Lee KA, Dunne M, Small C, Kelly PJ, McArdle O, O'Sullivan J, et al. (ICORG 05-03): prospective randomized non-inferiority phase III trial comparing two radiation schedules in malignant spinal cord compression (not proceeding with surgical decompression); the quality of life analysis. *Acta Oncol* 2018;57:965–72. <https://doi.org/10.1080/0284186X.2018.1433320>.
- [46] Abu-Hegazy M, Wahba HA. Single-versus multi-fraction radiation treatment for metastatic spinal cord compression: functional outcome study. *Chin Ger J Clin Oncol* 2011;10:535–40. <https://doi.org/10.1007/s10330-011-0832-5>.
- [47] Donovan EK, Sienna J, Mitera G, Kumar-Tyagi N, Parpia S, Swaminath A. Single versus multifraction radiotherapy for spinal cord compression: A systematic review and meta-analysis. *Radiother Oncol* 2019;134:55–66. <https://doi.org/10.1016/j.radonc.2019.01.019>.
- [48] Rades D, Cacicedo J, Conde-Moreno AJ, Segedin B, But-Hadzic J, Groselj B, et al. Precision radiation therapy for metastatic spinal cord compression: final results of the PRE-MODE trial. *Int J Radiat Oncol Biol Phys* 2020;106:780–9. <https://doi.org/10.1016/j.ijrobp.2019.11.401>.
- [49] Rades D, Lange M, Veninga T, Stalpers LJA, Bajrovic A, Adamietz IA, et al. Final results of a prospective study comparing the local control of short-course and long-course radiotherapy for metastatic spinal cord compression. *Int J Radiat Oncol Biol Phys* 2011;79:524–30. <https://doi.org/10.1016/j.ijrobp.2009.10.073>.
- [50] Maranzano E, Trippa F, Casale M, Anselmo P, Rossi R. Reirradiation of metastatic spinal cord compression: definitive results of two randomized trials. *Radiother Oncol* 2011;98:234–7. <https://doi.org/10.1016/j.radonc.2010.12.011>.
- [51] Rades D, Stalpers LJA, Veninga T, Hoskin PJ. Spinal reirradiation after short-course RT for metastatic spinal cord compression. *Int J Radiat Oncol Biol Phys* 2005;63:872–5. <https://doi.org/10.1016/j.ijrobp.2005.03.034>.
- [52] Landmann C, Hünig R, Gratzl O. The role of laminectomy in the combined treatment of metastatic spinal cord compression. *Int J Radiat Oncol Biol Phys* 1992;24:627–31. [https://doi.org/10.1016/0360-3016\(92\)90707-0](https://doi.org/10.1016/0360-3016(92)90707-0).
- [53] Loblaw A, George KJ, Misra V. Surgical and Radiotherapeutic Management of Malignant Extradural Spinal Cord Compression. *Clin Oncol (R Coll Radiol)* 2020;32:745–52. <https://doi.org/10.1016/j.clon.2020.07.022>.
- [54] Tokuhashi Y, Uei H, Oshima M, Ajiro Y. Scoring system for prediction of metastatic spine tumor prognosis. *World J Orthop* 2014;5:262–71. <https://doi.org/10.5312/wjvo.v5.i3.262>.
- [55] Bartels RHMA, Feuth T, van der Maazen R, Verbeek ALM, Kappelle AC, André Grotenhuis J, et al. Development of a model with which to predict the life expectancy of patients with spinal epidural metastasis. *Cancer* 2007;110:2042–9. <https://doi.org/10.1002/cncr.23002>.
- [56] van der Linden YM, Dijkstra SPDS, Vonk EJA, Marijnen CAM, Leer JWH. Dutch Bone Metastasis Study Group. Prediction of survival in patients with metastases in the spinal column: results based on a randomized trial of radiotherapy. *Cancer* 2005;103:320–8. <https://doi.org/10.1002/cncr.20756>.
- [57] Rades D, Hueppe M, Schild SE. A score to identify patients with metastatic spinal cord compression who may be candidates for best supportive care. *Cancer* 2013;119:897–903. <https://doi.org/10.1002/cncr.27849>.
- [58] Bollen L, van der Linden YM, Pondaag W, Fiocco M, Pattynama BPM, Marijnen CAM, et al. Prognostic factors associated with survival in patients with symptomatic spinal bone metastases: a retrospective cohort study of 1,043

- patients. *Neuro Oncol* 2014;16:991–8. <https://doi.org/10.1093/neuonc/nof318>.
- [59] Rades D, Rudat V, Veninga T, Stalpers IJA, Basic H, Karstens JH, et al. A score predicting posttreatment ambulatory status in patients irradiated for metastatic spinal cord compression. *Int J Radiat Oncol Biol Phys* 2008;72:905–8. <https://doi.org/10.1016/j.ijrobp.2008.02.018>.
- [60] Fallon M, Giusti R, Aielli F, Hoskin P, Rolke R, Sharma M, et al. Management of cancer pain in adult patients: ESMO Clinical Practice Guidelines. *Ann Oncol* 2018;29:iv166–91. <https://doi.org/10.1093/annonc/ndy152>.
- [61] Martin LA, Hagen NA. Neuropathic pain in cancer patients: mechanisms, syndromes, and clinical controversies. *J Pain Symptom Manage* 1997;14:99–117. [https://doi.org/10.1016/s0885-3924\(97\)00009-2](https://doi.org/10.1016/s0885-3924(97)00009-2).
- [62] Kerba M, Wu JSY, Duan Q, Hagen NA, Bennett MI. Neuropathic pain features in patients with bone metastases referred for palliative radiotherapy. *J Clin Oncol* 2010;28:4892–7. <https://doi.org/10.1200/JCO.2010.28.6559>.
- [63] Roes D, Turner S, Obrien P, Smith J, Spry N, Burmeister B, et al. Randomized trial of 8 Gy in 1 versus 20 Gy in 5 fractions of radiotherapy for neuropathic pain due to bone metastases (Trans-Tasman Radiation Oncology Group, TROG 96.05). *Radiother Oncol* 2005;75:54–63.
- [64] Bennett MI, Rayment C, Hjermstad M, Aass N, Caraceni A, Kaasa S. Prevalence and aetiology of neuropathic pain in cancer patients: a systematic review. *Pain* 2012;153:359–65. <https://doi.org/10.1016/j.pain.2011.10.028>.
- [65] Peng L, Min S, Zejun Z, Wei K, Bennett MI. Spinal cord stimulation for cancer-related pain in adults. *Cochrane Database Syst Rev* 2015:CD009389. <https://doi.org/10.1002/14651858.CD009389.pub3>.
- [66] Hussain A, Yong C, Tkaczuk KHR, Qian Y, Arellano J, Mullins CD, et al. Prevalence and risk of skeletal complications and use of radiation therapy in elderly women diagnosed with metastatic breast cancer. *PLoS One* 2018;13:e0193661. <https://doi.org/10.1371/journal.pone.0193661>.
- [67] Kawai AT, Martinez D, Saltus CW, Vassilev ZP, Soriano-Gabarró M, Kaye JA. Incidence of skeletal-related events in patients with castration-resistant prostate cancer: an observational retrospective cohort study in the US. *Prostate Cancer* 2019;2019:5971615. <https://doi.org/10.1155/2019/5971615>.
- [68] Saad F, Lipton A, Cook R, Chen Y-M, Smith M, Coleman R. Pathologic fractures correlate with reduced survival in patients with malignant bone disease. *Cancer* 2007;110:1860–7. <https://doi.org/10.1002/cncr.22991>.
- [69] Hu Y-C, Lun D-X, Wang H. Clinical features of neoplastic pathological fracture in long bones. *Chin Med J (Engl)* 2012;125:3127–32.
- [70] Fayad LM, Kamel IR, Kawamoto S, Bluemke DA, Frassica FJ, Fishman EK. Distinguishing stress fractures from pathologic fractures: a multimodality approach. *Skeletal Radiol* 2005;34:245–59. <https://doi.org/10.1007/s00256-004-0872-9>.
- [71] Brodowicz T, Hadji P, Niepel D, Diel I. Early identification and intervention matters: A comprehensive review of current evidence and recommendations for the monitoring of bone health in patients with cancer. *Cancer Treat Rev* 2017;61:23–34. <https://doi.org/10.1016/j.ctrv.2017.09.008>.
- [72] Mirels HILTON. Metastatic disease in long bones. A proposed scoring system for diagnosing impending pathologic fractures. *Clin Orthop Relat Res* 1989;249:256–64.
- [73] Benca E, Patsch JM, Mayr W, Pahr DH, Windhager R. The insufficiencies of risk analysis of impending pathological fractures in patients with femoral metastases: A literature review. *Bone Rep* 2016;5:51–6. <https://doi.org/10.1016/j.bonr.2016.02.003>.
- [74] Van der Linden YM, Dijkstra PDS, Kroon HM, Lok JJ, Noordijk EM, Leer JWH, et al. Comparative analysis of risk factors for pathological fracture with femoral metastases. *J Bone Joint Surg Br* 2004;86-B:566–73.
- [75] Evans AR, Bottros J, Grant W, Chen BY, Damron TA. Mirels' rating for humerus lesions is both reproducible and valid. *Clin Orthop Relat Res* 2008;466:1279–84. <https://doi.org/10.1007/s11999-008-0200-0>.
- [76] van der Linden YM, Kroon HM, Dijkstra SPDS, Lok JJ, Noordijk EM, Leer JWH, et al. Simple radiographic parameter predicts fracturing in metastatic femoral bone lesions: results from a randomised trial. *Radiother Oncol* 2003;69:21–31. [https://doi.org/10.1016/s0167-8140\(03\)00232-9](https://doi.org/10.1016/s0167-8140(03)00232-9).
- [77] van der Wal CWPG, Eggermont F, Fiocco M, Kroon HM, Ayu O, Slot A, et al. Axial cortical involvement of metastatic lesions to identify impending femoral fractures: a clinical validation study. *Radiother Oncol* 2020;144:59–64. <https://doi.org/10.1016/j.radonc.2019.10.007>.
- [78] Nazarian A, Entezari V, Villa-Camacho JC, Zurakowski D, Katz JN, Hochman M, et al. Does CT-based rigidity analysis influence clinical decision-making in simulations of metastatic bone disease? *Clin Orthop Relat Res* 2016;474:652–9. <https://doi.org/10.1007/s11999-015-4371-1>.
- [79] Villa-Camacho JC, Iyoha-Bello O, Behrouzi S, Snyder BD, Nazarian A. Computed tomography-based rigidity analysis: a review of the approach in preclinical and clinical studies. *Bonekey Rep* 2014;3:587. <https://doi.org/10.1038/bonekey.2014.82>.
- [80] Harrington KD. The management of acetabular insufficiency secondary to metastatic malignant disease. *J Bone Joint Surg Am* 1981;63:653–64.
- [81] Bickels J, Dadia S, Lidar Z. Surgical management of metastatic bone disease. *J Bone Joint Surg Am* 2009;91:1503–16. <https://doi.org/10.2106/JBJS.H.00175>.
- [82] Dakson A, Leck E, Brandman DM, Christie SD. The clinical utility of the Spinal Instability Neoplastic Score (SINS) system in spinal epidural metastases: a retrospective study. *Spinal Cord* 2020;58:892–9. <https://doi.org/10.1038/s41393-020-0432-8>.
- [83] Campos M, Urrutia J, Zamora T, Román J, Canessa V, Borghero Y, et al. The Spine Instability Neoplastic Score: an independent reliability and reproducibility analysis. *The Spine Journal* 2014;14:1466–9. <https://doi.org/10.1016/j.spinee.2013.08.044>.
- [84] Fournay DR, Frangou EM, Ryken TC, DiPaola CP, Shaffrey CI, Berven SH, et al. Spinal instability neoplastic score: an analysis of reliability and validity from the spine oncology study group. *J Clin Oncol* 2011;29:3072–7. <https://doi.org/10.1200/JCO.2010.34.3897>.
- [85] Bollen L, Groenen K, Pondaag W, van Rijswijk CSP, Fiocco M, Van der Linden YM, et al. Clinical evaluation of the spinal instability neoplastic score in patients treated with radiotherapy for symptomatic spinal bone metastases. *Spine (Phila Pa 1976)* 2017;42:E956–62. <https://doi.org/10.1097/BRS.0000000000002058>.
- [86] van der Velden JM, Versteeg AL, Verkooyen HM, Fisher CG, Chow E, Oner FC, et al. Prospective evaluation of the relationship between mechanical stability and response to palliative radiotherapy for symptomatic spinal metastases. *Oncologist* 2017;22:972–8. <https://doi.org/10.1634/theoncologist.2016-0356>.
- [87] Krishnan CK, Han I, Kim H-S. Outcome after surgery for metastases to the pelvic bone: a single institutional experience. *Clin Orthop Surg* 2017;9:116–25. <https://doi.org/10.4055/cios.2017.9.1.116>.
- [88] Willeumier JJ, van der Linden YM, van de Sande MAJ, Dijkstra PDS. Treatment of pathological fractures of the long bones. *EFORT Open Rev* 2016;1:136–45. <https://doi.org/10.1302/2058-5241.1.000008>.
- [89] Capanna R, Campanacci DA. The treatment of metastases in the appendicular skeleton. *J Bone Joint Surg Br* 2001;83:471–81. <https://doi.org/10.1302/0301-620x.83b4.12202>.
- [90] Gajjar BJ, Buchert P. Fracture healing in metastatic bone disease. *Clin Orthop Relat Res* 1983;178:297–302.
- [91] Riccio AL, Wodajo FM, Malawer M. Metastatic carcinoma of the long bones. *Am Fam Physician* 2007;76:1489–94.
- [92] Nathan SS, Healey JH, Mellano D, Hoang B, Lewis I, Morris CD, et al. Survival in patients operated on for pathologic fracture: implications for end-of-life orthopedic care. *J Clin Oncol* 2005;23:6072–82.
- [93] Townsend PW, Smalley SR, Cozad SC, Rosenthal HG, Hassanein RE. Role of postoperative radiation therapy after stabilization of fractures caused by metastatic disease. *Int J Radiat Oncol Biol Phys* 1995;31:43–9. [https://doi.org/10.1016/0360-3016\(94\)E0310-G](https://doi.org/10.1016/0360-3016(94)E0310-G).
- [94] Kraus RD, Weil CR, Wells S, Tward JD, Groundland JS, Jones KB, et al. Radiotherapy in conjunction with surgical stabilization of impending or pathologic fractures secondary to metastasis: is there a difference between single and multifraction regimens? *Adv Radiat Oncol* 2021;0. <https://doi.org/10.1016/j.adro.2021.100795>.
- [95] Müller DA, Capanna R. The surgical treatment of pelvic bone metastases. *Adv Orthop* 2015;2015:525363. <https://doi.org/10.1155/2015/525363>.
- [96] Saarto T, Janes R, Tenhunen M, Kouri M. Palliative radiotherapy in the treatment of skeletal metastases. *Eur J Pain* 2002;6:323–30. [https://doi.org/10.1016/s1090-3801\(02\)00028-9](https://doi.org/10.1016/s1090-3801(02)00028-9).
- [97] Groenen KHJ, Pouw MH, Hannink G, Hosman AJF, van der Linden YM, Verdonchot N, et al. The effect of radiotherapy, and radiotherapy combined with bisphosphonates or RANK ligand inhibitors on bone quality in bone metastases. A systematic review. *Radiother Oncol* 2016;119:194–201. <https://doi.org/10.1016/j.radonc.2016.03.001>.
- [98] Arvinis C, Parra JLC, Mateo LS, Maroto RG, Borrego AF, Stern L-L-D. Benefits of early intramedullary nailing in femoral metastases. *Int Orthop* 2014;38:129–32. <https://doi.org/10.1007/s00264-013-2108-x>.
- [99] Piccioli A, Rossi B, Scaramuzza L, Spinelli MS, Yang Z, Maccauro G. Intramedullary nailing for treatment of pathologic femoral fractures due to metastases. *Injury* 2014;45:412–7. <https://doi.org/10.1016/j.injury.2013.09.025>.
- [100] Hage WD, Abouafia AJ, Abouafia DM. Incidence, location, and diagnostic evaluation of metastatic bone disease. *Orthop Clin North Am* 2000;31:vii. [https://doi.org/10.1016/s0030-5898\(05\)70171-1](https://doi.org/10.1016/s0030-5898(05)70171-1).
- [101] Weikert DR, Schwartz HS. Intramedullary nailing for impending pathological subtrochanteric fractures. *J Bone Joint Surg Br* 1991;73:668–70. <https://doi.org/10.1302/0301-620X.73B4.2071657>.
- [102] Leddy LR. Rationale for reduced pressure reaming when stabilizing actual or impending pathological femoral fractures: a review of the literature. *Injury* 2010;41:S48–50. [https://doi.org/10.1016/S0020-1383\(10\)70009-7](https://doi.org/10.1016/S0020-1383(10)70009-7).
- [103] Ormsby N, Leong W, Wong W, Hughes H, Swaminathan V. The current status of prophylactic femoral intramedullary nailing for metastatic cancer. *Ecanermedscience* 2016;10:698. <https://doi.org/10.3332/ecancer.2016.698>.
- [104] Dijkstra S, Stapert J, Boxma H, Wiggers T. Treatment of pathological fractures of the humeral shaft due to bone metastases: a comparison of intramedullary locking nail and plate osteosynthesis with adjunctive bone cement. *Eur J Surg Oncol* 1996;22:621–6. [https://doi.org/10.1016/s0748-7983\(96\)92450-6](https://doi.org/10.1016/s0748-7983(96)92450-6).
- [105] Moura DL, Alves F, Fonseca R, Freitas J, Casanova J. Tratamento de fraturas patológicas tumorais diafisárias do úmero com haste intramedular rígida bloqueada estática - Experiência de 22 anos. *Rev bras ortop* 2019;54:149–55. <https://doi.org/10.1016/j.rbo.2017.10.012>.
- [106] Choi E-S, Han I, Cho HS, Park IW, Park JW, Kim H-S. Intramedullary nailing for pathological fractures of the proximal humerus. *Clin Orthop Surg* 2016;8:458–64. <https://doi.org/10.4055/cios.2016.8.4.458>.
- [107] Tsang RW, Campbell BA, Goda JS, Kelsey CR, Kirova YM, Parikh RR, et al. Radiation therapy for solitary plasmacytoma and multiple myeloma: guidelines from the International Lymphoma Radiation Oncology Group. *Int J Radiat Oncol Biol Phys* 2018;101:794–808.

- [108] Gerszten PC, Mendel E, Yamada Y. Radiotherapy and radiosurgery for metastatic spine disease: what are the options, indications, and outcomes? *Spine (Phila Pa)* 2009;34:S78–92. <https://doi.org/10.1097/BRS.0b013e3181b8b6f5>.
- [109] Bates MJ, Mijoya A. A review of patients with advanced cervical cancer presenting to palliative care services at Queen Elizabeth Central Hospital in Blantyre. *Malawi Malawi Med J* 2015;27:93–5. <https://doi.org/10.4314/mmi.v27i3.4>.
- [110] Schachar NS. An update on the nonoperative treatment of patients with metastatic bone disease. *Clin Orthop Relat Res* 2001;75–81. <https://doi.org/10.1097/00003086-200101000-00012>.
- [111] Fisher CG, DiPaola CP, Ryken TC, Bilsky MH, Shaffrey CI, Berven SH, et al. A novel classification system for spinal instability in neoplastic disease: an evidence-based approach and expert consensus from the Spine Oncology Study Group. *Spine (Phila Pa 1976)* 2010;35:E1221–1229. <https://doi.org/10.1097/BRS.0b013e3181e16ae2>.
- [112] Fisher CG, Schouten R, Versteeg AL, Boriani S, Varga PP, Rhines LD, et al. Reliability of the Spinal Instability Neoplastic Score (SINS) among radiation oncologists: an assessment of instability secondary to spinal metastases. *Radiat Oncol* 2014;9. <https://doi.org/10.1186/1748-717X-9-69>.
- [113] Fisher CG, Versteeg AL, Schouten R, Boriani S, Varga PP, Rhines LD, et al. Reliability of the spinal instability neoplastic scale among radiologists: an assessment of instability secondary to spinal metastases. *AJR Am J Roentgenol* 2014;203:869–74.
- [114] Grados F, Depriester C, Cayrolle G, Hardy N, Deramond H, Fardellone P. Long-term observations of vertebral osteoporotic fractures treated by percutaneous vertebroplasty. *Rheumatology (Oxford)* 2000;39:1410–4. <https://doi.org/10.1093/rheumatology/39.12.1410>.
- [115] Lieberman IH, Dudeney S, Reinhardt MK, Bell G. Initial outcome and efficacy of “kyphoplasty” in the treatment of painful osteoporotic vertebral compression fractures. *Spine (Phila Pa 1976)* 2001;26:1631–8. <https://doi.org/10.1097/00007632-200107150-00026>.
- [116] Phillips FM, Ho E, Campbell-Hupp M, McNally T, Todd Wetzel F, Gupta P. Early radiographic and clinical results of balloon kyphoplasty for the treatment of osteoporotic vertebral compression fractures. *Spine (Phila Pa 1976)* 2003;28:2260–5. <https://doi.org/10.1097/01.BRS.0000085092.84097.7B>.
- [117] Gerszten PC, Germanwala A, Burton SA, Welch WC, Ozhasoglu C, Vogel WJ. Combination kyphoplasty and spinal radiosurgery: a new treatment paradigm for pathological fractures. *J Neurosurg: Spine* 2005;3:296–301. <https://doi.org/10.3171/spi.2005.3.4.0296>.
- [118] Gu Y-F, Li Y-D, Wu C-G, Sun Z-K, He C-J. Safety and efficacy of percutaneous vertebroplasty and interventional tumor removal for metastatic spinal tumors and malignant vertebral compression fractures. *AJR Am J Roentgenol* 2014;202:W298–305. <https://doi.org/10.2214/AJR.12.10497>.
- [119] Hulme PA, Krebs J, Ferguson SJ, Berlemann U. Vertebroplasty and kyphoplasty: a systematic review of 69 clinical studies. *Spine (Phila Pa 1976)* 2006;31:1983–2001. <https://doi.org/10.1097/01.brs.0000229254.89952.6b>.
- [120] Amar AP, Larsen DW, Esnaashari N, Albuquerque FC, Lavine SD, Teitelbaum GP. Percutaneous transpedicular polymethylmethacrylate vertebroplasty for the treatment of spinal compression fractures. *Neurosurgery* 2001;49:1105–15.
- [121] Heini PF, Wälchli B, Berlemann U. Percutaneous transpedicular vertebroplasty with PMMA: operative technique and early results. A prospective study for the treatment of osteoporotic compression fractures. *Eur Spine J* 2000;9:445–50. <https://doi.org/10.1007/s005860000182>.
- [122] Murphy KJ, Deramond H. Percutaneous vertebroplasty in benign and malignant disease. *Neuroimag Clin N Am* 2000;10:535–45.
- [123] Saliou G, Kocheida EM, Lehmann P, Depriester C, Paradot G, Le Gars D, et al. Percutaneous vertebroplasty for pain management in malignant fractures of the spine with epidural involvement. *Radiology* 2010;254:882–90.
- [124] Berenson J, Pflugmacher R, Jarzem P, Zonder J, Schechtman K, Tillman JB, et al. Balloon kyphoplasty versus non-surgical fracture management for treatment of painful vertebral body compression fractures in patients with cancer: a multicentre, randomised controlled trial. *Lancet Oncol* 2011;12:225–35.
- [125] Itshayek E, Yamada J, Bilsky M, Schmidt M, Shaffrey C, Gerszten P, et al. Timing of surgery and radiotherapy in the management of metastatic spine disease: A systematic review. *Int J Oncol* 2010;36:533–44. <https://doi.org/10.3892/ijco.00000527>.
- [126] Versteeg AL, van der Velden JM, Hes J, Eppinga W, Kasperts N, Verkooijen HM, et al. Stereotactic radiotherapy followed by surgical stabilization within 24 h for unstable spinal metastases: A stage I/IIa study according to the IDEAL framework. *Front Oncol* 2018;8. <https://doi.org/10.3389/fonc.2018.00626>.
- [127] Saito T, Toya R, Oya N. Pain response rates after conventional radiation therapy for bone metastases in prospective nonrandomized studies: A systematic review. *Pract Radiat Oncol* 2019;9:81–8. <https://doi.org/10.1016/j.prro.2018.11.006>.
- [128] Finkelstein S, Raman S, Van Der Velden J, Zhang L, Tan C, Dhillon A, et al. Changes in volume and density parameters measured on computed tomography images following stereotactic body radiation therapy of nonspine bone metastases. *Technol Cancer Res Treat* 2019;18:1533033819853532. <https://doi.org/10.1177/1533033819853532>.
- [129] Foerster R, Eisele C, Bruckner T, Bostel T, Schlamp I, Wolf R, et al. Bone density as a marker for local response to radiotherapy of spinal bone metastases in women with breast cancer: a retrospective analysis. *Radiat Oncol* 2015;10. <https://doi.org/10.1186/s13014-015-0368-x>.
- [130] Chow E, Harris K, Fan G, Tsao M, Sze WM. Palliative radiotherapy trials for bone metastases: a systematic review. *J Clin Oncol* 2007;25:1423–36. <https://doi.org/10.1200/JCO.2006.09.5281>.
- [131] Chow E, Zeng L, Salvo N, Dennis K, Tsao M, Lutz S. Update on the systematic review of palliative radiotherapy trials for bone metastases. *Clin Oncol (R Coll Radiol)* 2012;24:112–24. <https://doi.org/10.1016/j.clon.2011.11.004>.
- [132] Hartsell WF, Scott CB, Bruner DW, Scarantino CW, Ivker RA, Roach M, et al. Randomized trial of short- versus long-course radiotherapy for palliation of painful bone metastases. *J Natl Cancer Inst* 2005;97:798–804.
- [133] Nielsen OS, Bentzen SM, Sandberg E, Gadeberg CC, Timothy AR. Randomized trial of single dose versus fractionated palliative radiotherapy of bone metastases. *Radiother Oncol* 1998;47:233–40. [https://doi.org/10.1016/s0167-8140\(98\)00011-5](https://doi.org/10.1016/s0167-8140(98)00011-5).
- [134] Sprave T, Hees K, Bruckner T, Foerster R, Bostel T, Schlamp I, et al. The influence of fractionated radiotherapy on the stability of spinal bone metastases: a retrospective analysis from 1047 cases. *Radiat Oncol* 2018;13. <https://doi.org/10.1186/s13014-018-1082-2>.
- [135] Steenland E, Leer J, van Houwelingen H, Post WJ, van den Hout WB, Kievit J, et al. The effect of a single fraction compared to multiple fractions on painful bone metastases: a global analysis of the Dutch Bone Metastasis Study. *Radiother Oncol* 1999;52:101–9.
- [136] Bates T. A review of local radiotherapy in the treatment of bone metastases and cord compression. *Int J Radiat Oncol Biol Phys* 1992;23:217–21. [https://doi.org/10.1016/0360-3016\(92\)90565-y](https://doi.org/10.1016/0360-3016(92)90565-y).
- [137] Ben-Josef E, Shamsa F, Williams AO, Porter AT. Radiotherapeutic management of osseous metastases: a survey of current patterns of care. *Int J Radiat Oncol Biol Phys* 1998;40:915–21. [https://doi.org/10.1016/s0360-3016\(97\)00927-9](https://doi.org/10.1016/s0360-3016(97)00927-9).
- [138] Koswig S, Budach V. [Remineralization and pain relief in bone metastases after after different radiotherapy fractions (10 times 3 Gy vs. 1 time 8 Gy). A prospective study]. *Strahlenther Onkol* 1999;175:500–8. <https://doi.org/10.1007/s000660050061>.
- [139] van der Linden YM, Lok JJ, Steenland E, Martijn H, van Houwelingen H, Marijnen CAM, et al. Single fraction radiotherapy is efficacious: a further analysis of the Dutch Bone Metastasis Study controlling for the influence of retreatment. *Int J Radiat Oncol Biol Phys* 2004;59:528–37. <https://doi.org/10.1016/j.ijrobp.2003.10.006>.
- [140] Shimoyama T, Katagiri H, Harada H, Murata H, Wasa J, Hosaka S, et al. Fracture after radiation therapy for femoral metastasis: incidence, timing and clinical features. *J Radiat Res* 2017;58:661–8. <https://doi.org/10.1093/jrr/rrx038>.
- [141] Tatar Z, Soubrier M, Dillies AF, Verrelle P, Boisgard S, Lapeyre M. Assessment of the risk factors for impending fractures following radiotherapy for long bone metastases using CT scan-based virtual simulation: a retrospective study. *Radiat Oncol* 2014;9:227. <https://doi.org/10.1186/s13014-014-0227-1>.