



**Universiteit
Leiden**
The Netherlands

Unraveling the genetic architecture of migraine: exploring the vascular components

Boer, I. de

Citation

Boer, I. de. (2025, June 12). *Unraveling the genetic architecture of migraine: exploring the vascular components*. Retrieved from <https://hdl.handle.net/1887/4248759>

Version: Publisher's Version

License: [Licence agreement concerning inclusion of doctoral thesis in the Institutional Repository of the University of Leiden](#)

Downloaded from: <https://hdl.handle.net/1887/4248759>

Note: To cite this publication please use the final published version (if applicable).



9

CHAPTER 9

Spectral domain optical coherence tomography in RVCL-S, a monogenic small vessel disease

Irene de Boer¹, Sylvie R. Steenmeijer², Nadine Pelzer¹, Mays Al-Nofal², Greet Dijkman², Irene C. Notting^{2,#}, Gisela M. Terwindt^{1,#}

Affiliations:

¹Department of Neurology, Leiden University Medical Center, Leiden, The Netherlands

²Department of Ophthalmology, Leiden University Medical Center, Leiden, The Netherlands

[#]Authors contributed equally as last author.

J Neuroophthalmol. 2022;42:e130-e136.

Abstract

Objective: Retinal Vasculopathy with Cerebral Leukoencephalopathy and Systemic manifestations (RVCL-S) is a monogenic small vessel disease caused by mutations in *TREX1*. Several organs, including retina and brain, are affected. Analyzing retinal anatomy is increasingly used as a biomarker for ophthalmological and neurological disorders (due to their shared embryological origin of retina and brain). Optical coherence tomography (OCT) provides a non-invasive cross-sectional visualization of optic disc and macula. We aimed to use OCT to investigate retinal layer thickness in RVCL-S.

Methods: Cross-sectional, 17 *TREX1* mutation carriers (34 eyes) and 9 controls (18 eyes) underwent comprehensive ophthalmologic assessment followed by spectral domain OCT for measuring peripapillary retinal nerve fiber layer (pRNFL) thickness and total macular volume (TMV). Secondary outcomes included thickness of individual macular retinal layers and peripapillary sectors. Findings were analyzed using generalized estimating equations (GEE) to account for intereye correlation.

Results: *TREX1* mutation carriers had decreased pRNFL thickness (median (IQR) 76 (60-99) vs 99 (87-108) μm , $p < 0.001$), and TMV (8.1 (7.4-8.5) vs 8.7 (8.4-8.8) mm^3 , $p = 0.006$) compared to controls. With the exception of the temporal sector, the thickness of all peripapillary sectors were decreased in *TREX1* mutation carriers. Ganglion cell layer (30 (22-37) vs 39 (36-41) μm , $p < 0.001$) and inner plexiform layer (27 (24-34) vs 34 (31-35), $p = 0.001$), were thinner in *TREX1* mutation carriers. Notably, in 9 out of 12 eyes with normal fundoscopic examination, retinal thinning was already detected.

Conclusion: RVCL-S, which may serve as a vascular retinopathy model, is associated with retinal thinning in the peripapillary and macular area. OCT findings can potentially serve as early biomarkers for RVCL-S and other vascular retinopathies.

Introduction

Retinal Vasculopathy with Cerebral Leukoencephalopathy and Systemic manifestations (RVCL-S) is a rare monogenic small vessel disease caused by C-terminal truncating mutations in *TREX1*.^{1,2} RVCL-S is characterized by progressive vascular retinopathy and focal and diffuse brain dysfunction.

Decreased visual acuity and/or visual field defects due to vascular retinopathy are the most common presenting symptoms of RVCL-S.² Despite classic onset of disease between ages 35-50, early signs of vascular retinopathy without symptomatology have been demonstrated in patients in their early twenties.^{2,3} Therefore, ophthalmologists play an important role in recognizing this underdiagnosed condition. Vascular retinopathy in RVCL-S is characterized in the early stages by telangiectasia, micro-aneurysms, and cotton wool spots. Later, perifoveal capillary obliterations and neovascularizations can occur. As the disease progresses secondary glaucoma and macula edema can develop as complications of retinopathy.² Fluorescein angiography often shows focal and extended areas of ischemia, capillary obliteration and microaneurysms, neovascularization, telangiectasias and fluorescein leaks. These findings are less likely to be due to a vasculitis but show similarity to diabetic retinopathy.²⁻⁴ Ophthalmological treatment is similar to diabetic retinopathy and often involves retinal laser photocoagulation (peripheral retina mostly) and intravitreal anti-vascular endothelial growth factor (anti-VEGF) therapy. Treatment for secondary glaucoma may be required.

Functional tests demonstrated impaired endothelial function, consistent with the wide range of other systemic manifestations, including liver and kidney disease, anemia and Raynaud's phenomenon.^{1,2,5,6} Currently, there are only symptomatic treatment options available and symptoms can progress rapidly towards middle age resulting in a premature death.^{2,6} RVCL-S serves as a monogenic model for common vascular retinopathies and brain disorders such as diabetic retinopathy and vascular dementia.

Currently, no biomarker is available to predict clinical onset or progression of RVCL-S. Nevertheless, treatment can already be necessary before visual defects occur. Therefore, patients need to be followed up by an ophthalmologist in order to prevent or postpone severe visual complications. With the development of new non-invasive tools to evaluate retinal anatomy in patients at risk of vascular retinopathy this opens promising avenues for ophthalmologists.⁷ Additionally, analyzing retinal anatomy has been demonstrated to possibly serve as a biomarker for multiple neurodegenerative

disorders.^{8,9} Optical coherence tomography (OCT) provides a non-invasive high-resolution visualization of retinal layers and may thus provide a useful biomarker for neuro-ophthalmological disorders.¹⁰

We aimed to evaluate spectral domain (SD)-OCT findings in RVCL-S, a monogenetic model for vasculopathy in both retina and brain, by investigating the peripapillary and macular regions by measuring the peripapillary retinal nerve fiber layer (pRNFL) and macular layers.

Methods

Patients and controls

For this cross-sectional cohort study, patients with proven RVCL-S *TREX1* mutations were recruited. Participants were ≥ 18 years of age and provided informed consent. Controls were selected consecutively from an ophthalmological cohort at the Leiden University Medical Center to obtain a similar age and sex distribution. Exclusion criteria were history of diabetes mellitus, age-related macular degeneration, macular dystrophy, eye trauma, primary glaucoma, other optic neuropathies, and media opacity preventing optimal imaging (severe dry eye, cataract, etc.). Controls were excluded if they had (a history of) ocular, systemic, metabolic or cerebrovascular diseases or were related to RVCL-S patients. To evaluate using SD-OCT measurements as early biomarkers, eyes without signs of retinopathy were also assessed. The study was conducted in accordance with the Declaration of Helsinki and Ethics Committee approval was obtained.

Ophthalmologic examinations

Mutation carriers (MC) underwent an ophthalmologic examination by a neuro-ophthalmologist (ICN) including slit lamp examination, applanation tonometry and ophthalmoscopy. Intraocular pressure (IOP) was measured using Goldmann applanation tonometry after instillation of topical oxybuprocaine monofree 0.4% and fluorescein dye. Subsequently, pupils were dilated (tropicamide monofree 0.5% and phenylephrine monofree 5.0%). Afterwards, color and red-free photographs of optic disc and macula were taken (TRC-50DX, Topcon Europe Medical BV) and assessed for retinopathy. Controls underwent standard ophthalmologic examination and fundus photography.

SD-Optical Coherence Tomography

The optic disc and macula were analyzed in both eyes using SD-OCT (Heidelberg Spectralis, Heidelberg Engineering) with image alignment eye tracking software (TruTrack Active Eye Tracking, Heidelberg Engineering). Software (Heidelberg Eye Explorer v1.9.10.0) rendered retinal images with minimum resolution of 768x768 pixels with field of view set at 30°. The pRNFL was analyzed with a circular scan with a diameter of 3.5 mm centered on the optic disc. Secondly, sectorial analyses were performed for different peripapillary segments. Macula retinal layers were measured while focusing on the fovea centralis by divided the area into nine sectors, using a 1-, 3-, and 6-mm grid.¹¹ Individual retinal layers were automatically demarcated, qualitatively assessed and quantified by segmentation software (figure 1B). Primarily, total macular volume (TMV) was measured to evaluate the retina as a whole, and not only macular thinning due to neuronal loss. As secondary outcomes total macular thickness (TMT) and thickness of the individual macula layers were evaluated. Lastly, we evaluated the pattern of retinal thinning. Scans were obtained by blinded examiners in single session. We used APOSTEL recommendations for reporting.¹²

Statistical analyses

Statistical analyses were performed using SPSS 23.0 (IBM Corporation, Armonk, NY). Demographics were compared using Mann-Whitney U test and Fisher's exact test. SD-OCT parameters were analyzed using generalized estimating equations (matrix: exchangeable) to account for intereye correlations within participants. To ensure results were not caused by secondary glaucoma or photocoagulation treatment in the scanned region, we conducted separate analyses for primary outcomes after exclusion of affected eyes. A p-value of <0.05 was considered significant.

Results

Patients and controls

We included 34 eyes of 17 *TREX1* MC and 18 eyes of 9 controls. MC and controls did not differ in age (median age (IQR) 54 (45-62) vs 58 years (54-65), $p=0.11$) or sex (65 vs 56% female, $p=0.69$). Retinopathy was observed in 22 eyes (from 12 RVCL-S patients), no controls showed signs of retinopathy. Fourteen eyes of RVCL-S patients had undergone previous photocoagulation treatment, three in scanned region. Five eyes were affected by secondary glaucoma. Median IOP (IQR) in RVCL-S patients was 14mmHg (13-16). Median visual acuity (IQR) in RVCL-S patients was 0.0 LogMAR (0.0-0.2).

Mean peripapillary RNFL and TMV

The pRNFL was significantly thinner in *TREX1* MC compared to controls (median (IQR) 76 (60-99) vs 99 (87-108) μm , $p < 0.001$) (figure 1C). Furthermore, all sectors, with exception of the temporal sector, showed significant thinning in *TREX1* MC (figure 1A, table 1). TMV was decreased in *TREX1* MC compared to controls (median (IQR) 8.1 (7.4-8.5) vs 8.7 (8.4-8.8) mm^3 , $p = 0.006$) (figure 1D). After exclusion of eyes affected by secondary glaucoma and photocoagulation treatment in scanned regions pRNFL (median (IQR) 78 (62-99) vs 99 (87-108), $p = 0.003$) and TMV (median (IQR) 8.2 (7.5-8.5) vs. 8.7 (8.4-8.8), $p = 0.029$) remained thinner. We demonstrated that decreased pRNFL thickness and reduction of TMV already occurs as early as age 42 (figure 2).

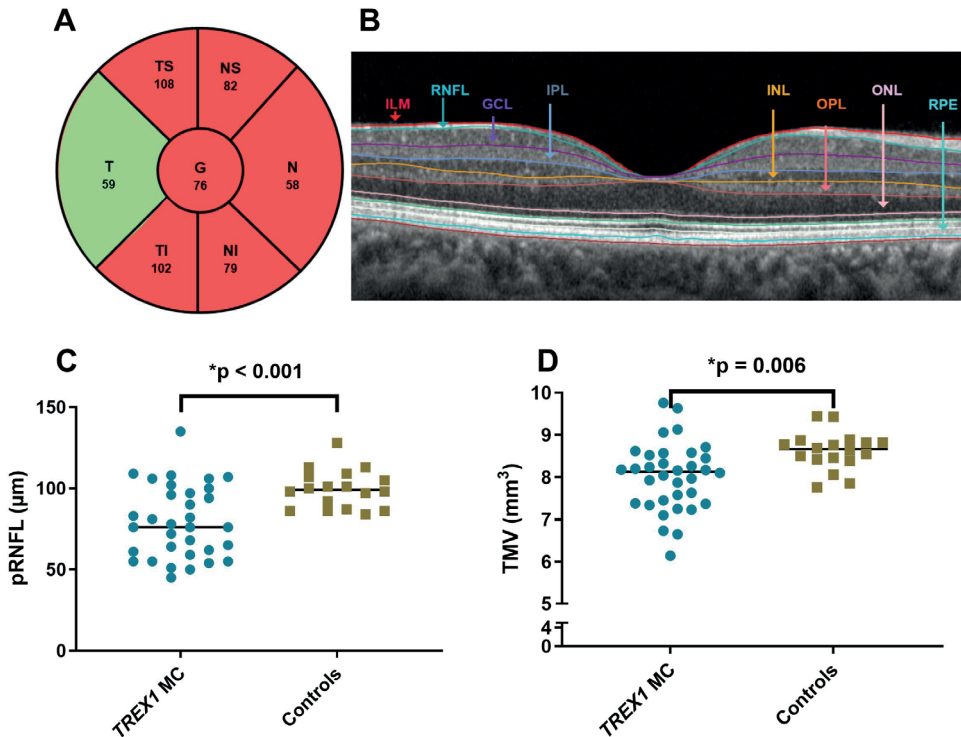


Figure 1. SD-OCT measurements in *TREX1* mutation carriers.

Median of all mutation carriers peripapillary retinal nerve fiber layer (pRNFL) per sector (dark grey indicates decreased thickness) (A). Individual macular layers (B). Median pRNFL (C) and total macular volume (TMV) (D) were reduced in *TREX1* mutation carriers. Global (G); temporal (T); nasal (N); inferior (I), superior (S); inner limiting membrane (ILM); retinal nerve fiber layer (RNFL); ganglion cell layer (GCL); inner plexiform layer (IPL); inner nuclear layer (INL); outer plexiform layer (OPL); outer nuclear layer (ONL); retinal pigment epithelium (RPE).

Table 1. Thickness of peripapillary sectors in *TREX1* mutation carriers.

	<i>TREX1</i> MC median(IQR) (μm) (n=33 [†])	Controls median(IQR) (μm) (n=18)	Estimate	CI	P-value
Nasal sup.	82 (63-97)	102 (90-114)	-23.3	-42.0;-4.7	0.014*
Nasal	58 (45-78)	79 (68-104)	-26.5	-42.8;-10.1	0.002**
Nasal inf.	79 (60-109)	124 (90-143)	-34.4	-56.6;-12.2	0.002**
Temporal inf.	102 (64-131)	135 (120-144)	-32.6	-52.7;-12.5	0.001**
Temporal	59 (51-73)	62 (57-70)	-1.5	-12.5;9.5	0.79
Temporal sup.	108 (77-130)	131 (123-143)	-21.6	-39.1;-4.1	0.016*

Mutation carrier (MC); Interquartile range (IQR); confidence interval (CI). [†]In one patient measurements of one eye were not possible due to the patient's inability to focus. * $p < 0.05$, ** $p < 0.01$.

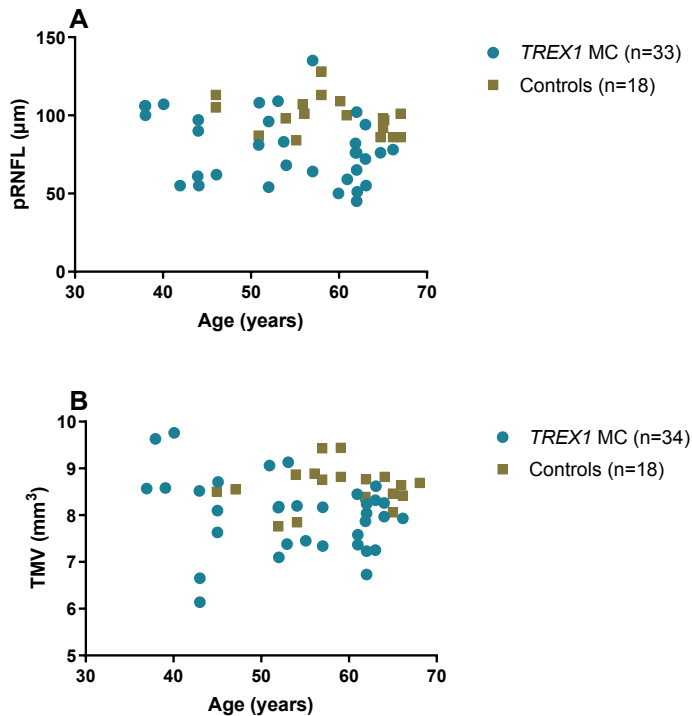


Figure 2. Distribution of peripapillary retinal nerve fiber layer thickness (A) and total macular volume (B) with age in *TREX1* mutation carriers and controls.

Mutation carriers (MC); peripapillary retinal nerve fiber layer (pRNFL); total macular volume (TMV).

Inner retinal layers

Decrease in TMT and individual retina layers thickness was demonstrated for the ganglion cell layer and inner plexiform layer (table 2). The ganglion cell layer showed the most striking reductions. While the majority of patients demonstrated patchy thinning of the GCL, four patients demonstrated sectorial thinning. Three of these patients had no overt signs of retinopathy at the time of scanning.

Table 2. Thickness of macula layers in *TREX1* mutation carriers.

	<i>TREX1</i> MC median (IQR) (μm) (n=34)	Controls median (IQR) (μm) (n=18)	Estimate	CI	P-value
Total macular thickness	296 (267-314)	316 (308-323)	-21.8	-38.1;-5.6	0.009*
Macular RNFL	23 (20-27)	26 (24-27)	-2.7	-5.6;0.2	0.07
Ganglion cell layer	30 (22-37)	39 (36-41)	-8.7	-13.2;-4.2	<0.001**
Inner plexiform layer	27 (24-34)	34 (31-35)	-5.1	-8.1;-2.2	0.001*
Inner nuclear layer	35 (30-38)	35 (34-39)	-1.8	-4.8;1.3	0.25
Outer plexiform layer	29 (26-31)	29 (28-30)	-0.3	-1.8;1.2	0.70
Outer nuclear layer	69 (65-74)	70 (63-74)	-0.2	-6.3;6.0	0.96
Retinal pigment epithelium	14 (13-15)	14 (13-15)	-0.2	-1.2;0.8	0.68

Mutation carrier (MC); Interquartile range (IQR); confidence interval (CI); retinal nerve fiber layer (RNFL). * $p < 0.01$, ** $p < 0.001$.

SD-OCT measurements as early biomarkers for RVCL-S

Importantly, in 9 out of 12 eyes in which funduscopic examination did not detect signs of retinopathy, decreased pRNFL thickness or reduction of TMV could already be detected.

Discussion

We demonstrated decreased pRNFL thickness and reduction of TMV in RVCL-S. The pRNFL contains unmyelinated axons of ganglion cells found in the ganglion cell layer, thus showing loss of intraocular axonal integrity in RVCL-S. Additionally, we found a thinning of the inner plexiform layer, where dendrites from inner nuclear layer neurons are located. Our study findings indicate also an effect of RVCL-S on retinal neurons. Indicating that OCT findings might provide useful biomarkers, as well as pathophysiologic insight in the mechanism of RVCL-S and possibly other vasculopathies.

As very little is known about OCT findings in RVCL-S, we chose one primary outcome focusing on one overall measurement of the peripapillary region (pRNFL thickness),

while the other focused on the macular region (TMV). We deliberately did not choose the GCL as primary outcome as we were not only interested in macular thinning due to neuronal loss. As TMV is frequently used in the literature with similar conditions we chose this outcome to more easily compare the results across diseases.¹³ As TMT and TMV are highly correlated, we included TMT as a secondary outcome.

As RVCL-S is both a retinal vasculopathy and a neurodegenerative disorder, it is difficult to determine whether GCL loss is due to retinal disease or retrograde trans-synaptic degeneration. That most patients display a patchy pattern of GCL loss is most consistent with retinal disease. Nonetheless, that GCL loss already is apparent without overt retinal disease, and that this can also occur in a sectorial pattern may suggest that retrograde trans-synaptic degeneration could also play a role. Our findings may suggest that retrograde trans-synaptic degeneration occurs (and might be objectifiable in early disease stages), but also that retinal damage may be the main reason for further GCL thinning when retinopathy becomes more apparent. Studying (pre)symptomatic patients over time and relating OCT findings to MRI-imaging markers will help further elucidate these mechanisms for retinal loss.

There have been inconsistent reports on whether neurodegeneration of the retina occurs in diabetes mellitus. It appears that individual patient characteristics (e.g. diabetes type, control of disease and duration) might favor neurodegeneration. Nonetheless, several studies found thinning of the pRNFL and GCL.¹⁴ Moreover, in early stages of diabetes before retinal vascular damage manifests OCT findings have suggested that retinal neurodegeneration already occurs.⁷ Patients with hypertensive retinopathy also have lower central macular thickness and pRNFL thickness compared to controls.¹⁵ Interestingly, patients with end-organ damage had significantly lower SD-OCT measurements, indicating its use as a diagnostic biomarker. Vascular retinopathy seen in RVCL-S is similar to diabetic and hypertensive retinopathy. We now demonstrate that the findings on optical coherence tomography are also similar.

Moreover, pRNFL thinning has also been reported in other hereditary cerebral angiopathies, including Cerebral Autosomal Dominant Arteriopathy with Subcortical Infarcts and Leukoencephalopathy (CADASIL) and hereditary Cerebral Amyloid Angiopathy-Dutch type (D-CAA).^{13,16} In these disorders, macula thinning was not found. However, in other disorders with multisystemic inflammatory involvement, such as Behçet's disease, an inflammatory multisystemic chronic vasculitis, and systemic lupus erythematosus (SLE) decreased macular and RNFL thickness was demonstrated.^{17,18} OCT findings are also promising biomarkers for neurodegenerative

disorders, such as Alzheimer's disease. In patients with Alzheimer's disease a reduction of macular volume correlated with cognitive impairment, and in a population-based study thinner pRNFL was associated with increased risk of developing dementia.^{8,9} Additionally, macular and ganglion cell complex thickness were found to associate with the presence of dementia.¹⁹ Taken together, this indicates a promising role for retinal thickness as a diagnostic and prognostic biomarker not only for rare but also for common neurovascular disorders of the eye and brain.

This exploratory study may have some limitations. Firstly, invasive fluorescence angiography was not performed as we focused on non-invasive techniques. Therefore, we cannot report on for instance capillary drop out and the size of foveal avascular zone while this would have been interesting. However, fluorescence angiography is a procedure with possible side effects that only depicts the current vascular status at time of investigation and does not allow for evaluation of retinal tissue. OCT in contrast, captures the permanent scar-like tissue damage, which is still present even in inactive disease stages. Nonetheless, in further studies it may still be useful to systematically evaluate findings on fluorescence angiography and to compare these to non-invasive tools such as OCT techniques. Secondly, we cannot fully exclude an influence of photocoagulation treatment on OCT measurements. As patients with more severe retinal vasculopathy are more likely to receive photocoagulation treatment the distinction of causality for retinal thinning may be difficult. However, the majority of our patients that received laser photocoagulation treatment were treated only in the periphery, and for our secondary analyses only eyes for which the regions of interest were not treated by photocoagulation were selected, thus theoretically decreasing the effect of treatment on our findings. Our findings are further supported by what has been shown in diabetic retinopathy. Laser treatment is used less frequently and thinning of the pRNFL on OCT has still been demonstrated, even before other signs of diabetic retinopathy appear.^{20,21} A third limitation of our study is the relatively small sample size due to the rarity of the disorder, this also led to limited availability of individuals aged below 50 years. As such, currently no definite conclusion can be formulated about using SD-OCT findings as very early biomarkers from our exploratory study. Moreover, our study might have been underpowered for subtle retinal changes. Nonetheless, patients in their forties already have retinal thinning while funduscopic examination detected no signs of retinopathy. Finally, as is justified by the exploratory nature of our study, the significance level was kept at 0.05 even though multiple statistical tests were performed. We did perform adjustment for inter-eye correlation. A major strength of our study is the use of a unique hereditary neurovascular model for retinopathy and vascular dementia in which different disease stages can be studied in mutation carriers.

Currently, the retinopathy seen in RVCL-S is classified based on results of fundoscopy (and if indicated fluorescein angiography).^{3,22} That almost all eyes without signs of retinopathy already demonstrated retinal thinning highlights the need to update retinopathy criteria with the use of new ophthalmological techniques such as OCT in general and specifically for RVCL-S.

It is vital for RVCL-S patients that they are recognized by ophthalmologists. Not only is ophthalmological monitoring critical, neurological monitoring and treatment for anemia, hypertension and kidney failure might be necessary. If the diagnosis is not recognized this can lead to unnecessary, possibly harmful, biopsies (including, but not limited to brain and kidney biopsies). Furthermore, misdiagnosis can have severe treatment implications. The diagnosis of RVCL-S should be suspected in adult patients of middle age presenting with vascular retinopathy and/or focal or global neurologic deficits, particularly in the setting of a positive family history of retinopathy or neurological diseases.^{2,6,23} Given that patients often present with vision loss, the ophthalmologist should be cautious in cases of vascular retinopathy without an apparent etiology. Of note, a negative family history does not exclude RVCL-S, since *de novo* pathogenic variants can occur.²⁴ Furthermore, family members with RVCL-S may be misdiagnosed with other conditions (e.g., neurodegenerative disorders, vascular dementia, brain tumor, multiple sclerosis, hypertensive retinopathy and diabetic retinopathy).

This study demonstrated retinal thinning in RVCL-S patients in the peripapillary and macular area, even when fundoscopic examination was normal. As OCT is a safe, noninvasive, and precise diagnostic tool, we expect an increasing impact of OCT on the future diagnostic workup of RVCL-S patients. Moreover, SD-OCT measurements may be used as preclinical biomarker in RVCL-S but also in common neurovascular conditions such as diabetic retinopathy and vascular dementia, for which RVCL-S serves as a monogenic model.

Conflict of interest

I. de Boer, S.R. Steenmeijer, N. Pelzer, M. Al-Nofal, G. Dijkman, I.C. Notting report no disclosures. G.M. Terwindt reports independent support from Dutch Heart Foundation, and Dutch Brain Foundation.

Disclosure of funding

Supported by grants of International Retinal Research Foundation (IRRF) [G.M.T.,I.C.N.,I.B.], Dioraphte [20010407 G.M.T.,I.C.N.]. The funding organizations had no role in the design or conduct of this research.

References

- Richards A, van den Maagdenberg AM, Jen JC, et al. C-terminal truncations in human 3'-5' DNA exonuclease TREX1 cause autosomal dominant retinal vasculopathy with cerebral leukodystrophy. *Nat Genet.* 2007;39:1068-70.
- Stam AH, Kothari PH, Shaikh A, et al. Retinal vasculopathy with cerebral leukoencephalopathy and systemic manifestations. *Brain.* 2016;139:2909-22.
- Storimans CW, Van Schooneveld MJ, Oosterhuis JA, Bos PJ. A new autosomal dominant vascular retinopathy syndrome. *Eur J Ophthalmol.* 1991;1:73-8.
- Cohn AC, Kotschet K, Veitch A, Delatycki MB, McCombe MF. Novel ophthalmological features in hereditary endotheliopathy with retinopathy, nephropathy and stroke syndrome. *Clin Exp Ophthalmol.* 2005;33:181-3.
- de Boer I, Stam AH, Buntinx L, et al. RVCL-S and CADASIL display distinct impaired vascular function. *Neurology.* 2018;91:e956-e63.
- Pelzer N, Hoogeveen ES, Haan J, et al. Systemic features of retinal vasculopathy with cerebral leukoencephalopathy and systemic manifestations: a monogenic small vessel disease. *J Intern Med.* 2019;285:317-32.
- Safi H, Safi S, Hafezi-Moghadam A, Ahmadi H. Early detection of diabetic retinopathy. *Surv Ophthalmol.* 2018;63:601-8.
- Iseri PK, Altinas O, Tokay T, Yuksel N. Relationship between cognitive impairment and retinal morphological and visual functional abnormalities in Alzheimer disease. *J Neuroophthalmol.* 2006;26:18-24.
- Mutlu U, Colijn JM, Ikram MA, et al. Association of Retinal Neurodegeneration on Optical Coherence Tomography With Dementia: A Population-Based Study. *JAMA Neurol.* 2018;75:1256-63.
- Drexler W, Morgner U, Ghanta RK, Kartner FX, Schuman JS, Fujimoto JG. Ultrahigh-resolution ophthalmic optical coherence tomography. *Nat Med.* 2001;7:502-7.
- Early Treatment Diabetic Retinopathy Study research group. Photocoagulation for diabetic macular edema. Early Treatment Diabetic Retinopathy Study report number 1. *Arch Ophthalmol.* 1985;103:1796-806.
- Cruz-Herranz A, Balk LJ, Oberwahrenbrock T, et al. The APOSTEL recommendations for reporting quantitative optical coherence tomography studies. *Neurology.* 2016;86:2303-9.
- van Etten ES, de Boer I, Steenmeijer SR, Al-Nofal M, Wermer MJH, Notting IC, Terwindt GM. Optical coherence tomography detects retinal changes in hereditary cerebral amyloid angiopathy. *Eur J Neurol.* 2020;27:2635-40.
- Jonsson KB, Frydkjaer-Olsen U, Grauslund J. Vascular Changes and Neurodegeneration in the Early Stages of Diabetic Retinopathy: Which Comes First? *Ophthalmic Res.* 2016;56:1-9.
- Simsek EE, Kanar HS, Kanar BG, Cetin H, Arsan A, Tigen MK. Can ocular OCT findings be as a predictor for end-organ damage in systemic hypertension? *Clin Exp Hypertens.* 2020;42:733-7.
- Rufa A, Pretegianni E, Frezzotti P, De Stefano N, Cevenini G, Dotti MT, Federico A. Retinal nerve fiber layer thinning in CADASIL: an optical coherence tomography and MRI study. *Cerebrovasc Dis.* 2011;31:77-82.
- Liu GY, Utset TO, Bernard JT. Retinal nerve fiber layer and macular thinning in systemic lupus erythematosus: an optical coherence tomography study comparing SLE and neuropsychiatric SLE. *Lupus.* 2015;24:1169-76.
- Ataş M, Yuvacı I, Demircan S, et al. Evaluation of the Macular, Peripapillary Nerve Fiber Layer and Choroid Thickness Changes in Behçet's Disease with Spectral-Domain OCT. *J Ophthalmol.* 2014;2014:865394.
- Ito Y, Sasaki M, Takahashi H, et al. Quantitative Assessment of the Retina Using OCT and Associations with Cognitive Function. *Ophthalmology.* 2020;127:107-18.
- Shi R, Guo Z, Wang F, Li R, Zhao L, Lin R. Alterations in retinal nerve fiber layer thickness in early stages of diabetic retinopathy and potential risk factors. *Curr Eye Res.* 2018;43:244-53.
- Garcia-Martin E, Cipres M, Melchor I, Gil-Arribas L, Vilades E, Polo V, Rodrigo MJ, Satue M. Neurodegeneration in Patients with Type 2 Diabetes Mellitus without Diabetic Retinopathy. *J Ophthalmol.* 2019;2019:1825819.

22. Terwindt GM, Haan J, Ophoff RA, et al. Clinical and genetic analysis of a large Dutch family with autosomal dominant vascular retinopathy, migraine and Raynaud's phenomenon. *Brain*. 1998;121:303-16.
23. de Boer I, Pelzer N, Terwindt G. Retinal Vasculopathy with Cerebral Leukoencephalopathy and Systemic Manifestations. In: Adam MP, Ardinger HH, Pagon RA, Wallace SE, Bean LJH, Stephens K, et al., editors. GeneReviews((R)). Seattle (WA): University of Washington, Seattle. University of Washington, Seattle. GeneReviews is a registered trademark of the University of Washington, Seattle. All rights reserved.; 1993.
24. DiFrancesco JC, Novara F, Zuffardi O, et al. TREX1 C-terminal frameshift mutations in the systemic variant of retinal vasculopathy with cerebral leukodystrophy. *Neurol Sci*. 2015;36:323-30.