



Universiteit
Leiden
The Netherlands

Brain matters in twin-twin transfusion syndrome
Spruijt, M.S.

Citation

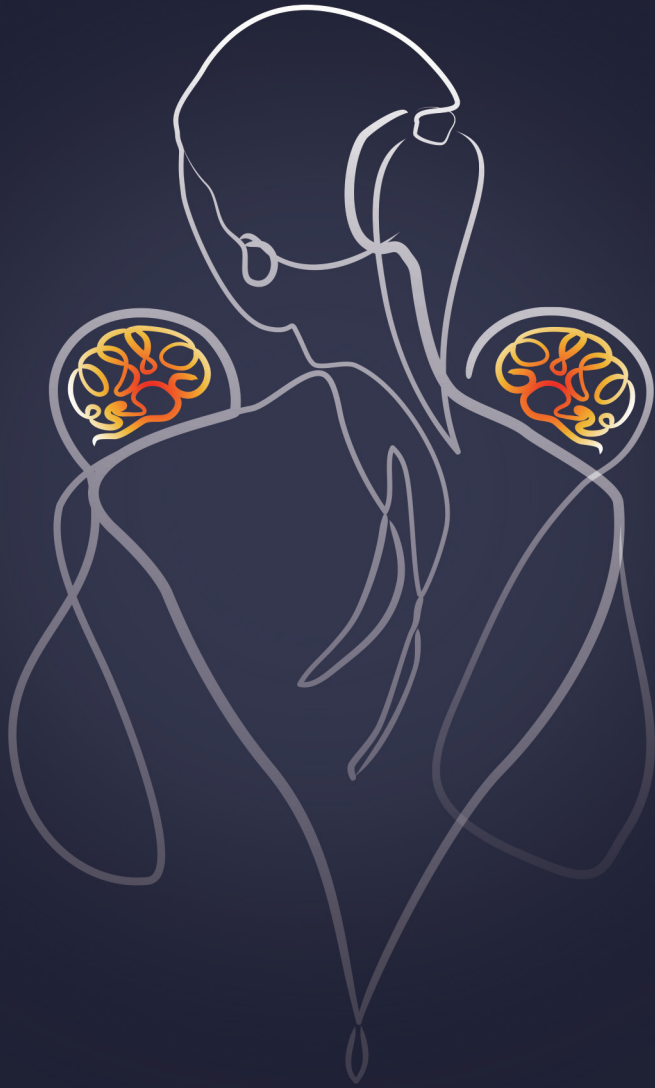Spruijt, M. S. (2025, January 15). *Brain matters in twin-twin transfusion syndrome*. Retrieved from <https://hdl.handle.net/1887/4175821>

Version: Publisher's Version

License: [Licence agreement concerning inclusion of doctoral thesis in the Institutional Repository of the University of Leiden](#)

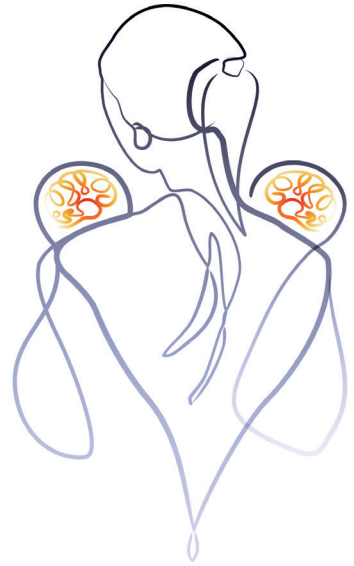Downloaded from: <https://hdl.handle.net/1887/4175821>

Note: To cite this publication please use the final published version (if applicable).



Part TWO

Review



Chapter 1

Twin-twin transfusion syndrome in the era of fetoscopic laser surgery: antenatal management, neonatal outcome and beyond

Marjolijn S. Spruijt
Enrico Lopriore
Sylke J. Steggerda
Femke Slaghekke
Jeanine M.M. van Klink

Expert Review of Hematology 2020;13(3):259-267

Abstract

Introduction

Twin-twin transfusion syndrome (TTTS) is a devastating complication of monochorionic twin pregnancy and remains a major challenge for worldwide fetal medicine specialists. In TTTS, intertwin transfusion through vascular anastomoses in the shared placenta leads to severe hemodynamic imbalance. This review summarizes the current knowledge of TTTS.

Areas covered

The most recent insights concerning the management of TTTS, as well as fetal and neonatal complications are described. Relevant articles were selected based on a Pubmed search using the keywords below. Understanding of the underlying pathophysiology has improved greatly as a result of placental injection studies. Advancements in antenatal management have led to increased perinatal survival and a decreased incidence of neonatal complications, including brain injury and neurodevelopmental impairment.

Expert opinion

Further opportunities for improvement comprise technological innovations in laser procedures and the prevention of preterm rupture of membranes with subsequent prematurity. A noninvasive treatment such as high-intensity focused ultrasound (HIFU) seems to hold promise for the future treatment of TTTS. Fetal MRI studies are important to improve our understanding of fetal brain injury and should relate their findings to long-term neurodevelopment. International collaboration and centralization of care are of paramount importance to ensure the best care for our patients.

Keywords

Laser surgery; neurodevelopment; outcome; monochorionic twins; twin-twin transfusion syndrome

Introduction

Twins are at increased risk of perinatal death and long-term neurologic morbidity, and this risk is highest for monochorionic (MC) twins.(1-3) A large part of the increased risk for MC twins is attributable to twin-twin transfusion syndrome (TTTS). TTTS is one of the most lethal conditions in fetal medicine and remains a major challenge for obstetricians and neonatologists across the world.(4, 5) The implementation of strict protocols for the management of MC twin pregnancies have increased the opportunity for early diagnosis and timely management of TTTS.(6, 7) The management of this devastating disease has advanced considerably since the introduction of fetoscopic laser surgery in the 1990s, leading to increased perinatal survival and more favorable neonatal and long-term outcomes.(8, 9)

TTTS results from an unbalanced blood flow through placental vascular anastomoses connecting the two fetal circulations. These vascular anastomoses in the shared placenta are present in virtually all monochorionic (MC) twin pregnancies, but only in about 10% lead to TTTS. The net transfusion of blood is at the expense of the so-called donor twin, who becomes hypovolemic and anemic, whereas the recipient twin becomes hypervolemic and polycythemic. This leads to the quick development of a significant discordance in amniotic fluid volume between the twins, described as twin polyhydramnios-oligo-hydramnios sequence (TOPS). Hormonal dysregulation has been implicated to play a role in the further development of the syndrome.(10, 11) TOPS can be detected with prenatal ultrasound and is the hallmark of TTTS diagnosis. TTTS is staged using the criteria of Quintero, ranging from stage I disease characterized by TOPS with the donor's bladder still visible, to stage V in which there is fetal demise of one or both twins.(12, 13) The current review aims to summarize the knowledge gained in the last decade, its main focus being on pathophysiology, antenatal management, fetal and neonatal brain injury as well as long-term neurodevelopment after TTTS.

Literature search

Relevant papers were selected based on a Pubmed search of articles published after 2009, using combinations of the following search terms: twin-twin transfusion, laser, outcome, brain injury and neurodevelopment. Relevant literature references of the selected articles were identified and used for historic perspective in a few cases.

Placental injection studies

Although the exact mechanism by which TTTS develops is still poorly understood, placental injection studies using colored dye have much improved our knowledge of MC placentas in the past decade.(14-16) Vascular anastomoses in MC placentas are either arterio-arterial (AA), arterio-venous (AV) or veno-venous (VV) in nature. Injection studies were able to show a relationship between the type, number and size of placental anastomoses and the risk of developing TTTS and other MC pregnancy complications. TTTS placentas have significantly fewer AA anastomoses compared to uncomplicated MC placentas.(15, 17) AA anastomoses allow for bidirectional flow of blood, compensating for any imbalance in inter-twin blood volume caused by AV anastomoses, hereby reducing, but not eliminating, the risk of TTTS.

Placental injection studies have played an important role in the discovery of another form of inter-twin transfusion in MC pregnancy termed twin anemia-polycythemia sequence (TAPS).(18) Like TTTS, TAPS results from unbalanced blood flow through placental anastomoses. However, because TAPS is characterized by the presence of only very small anastomoses, transfusion in TAPS is much slower, allowing time for hemodynamic compensatory mechanisms to take effect and thus preventing the development of hypovolemia in the donor and hypervolemia in the recipient. Therefore, the essential difference between TTTS and TAPS is the absence of oligohydramnios/polyhydramnios in TAPS.(19, 20) TAPS can be diagnosed antenatally by measurement of the middle cerebral artery peak systolic velocity (MCA-PSV) in both twins. In a recent study, it was shown that the difference in MCA-PSV between the donor and recipient is the most accurate predictor of postnatal TAPS with high sensitivity (83%) and specificity (100%). Based on these findings, a new antenatal classification system was proposed using a delta MCA-PSV of > 0.5 multiples of the median (MoM) as criterion for Stage 1 TAPS. Postnatally, TAPS is present when the intertwin hemoglobin difference is > 8 g/dL, combined with either a reticulocyte count ratio > 1.7 or the presence of only very small (< 1 mm) placental anastomoses.(21) TAPS can occur spontaneously (3-5% of MC pregnancies) or after laser for TTTS.(22)

Antenatal management of TTTS

Before the development of fetoscopic laser surgery, antenatal treatment in TTTS was mainly based on serial amnioreduction to reduce polyhydramnios and the consequent risk of preterm delivery.(4) However, short and long-term outcome after serial amnioreduction were poor. Perinatal survival rates usually did not exceed 50% and the risk of neurodevelopmental injury in survivors was high, up to 25%.(23-26)

Fetoscopic laser surgery

Fetoscopic laser surgery is now considered the best available treatment for advanced stages (Quintero stage ≥ 2) TTTS.(24, 27-30) The technique using a fetoscopic laser to disrupt blood flow through the vascular communications was developed in the 1980s and it soon became clear that this therapy would become a 'game changer' in the field of TTTS.(31) In contrast to serial amnioreduction, laser surgery is the only causative treatment, aiming to stop the intertwin fetal transfusion process. The first laser procedures were performed under general anesthesia and required laparotomy and hysterotomy for introduction of the endoscope, followed by laser photocoagulation. Since then, many developments have taken place. Laser technique has evolved from so-called 'non-selective' ablation of all vessels at the chorionic surface close to the intertwin membrane, to the selective technique in which the goal is to only coagulate anastomotic vessels at the vascular equator.(29, 32-35) In TTTS, the vascular equator is at some distance from the intertwin membrane due to the discordant amniotic fluid volumes between the twins. Laser surgery in TTTS is now minimally invasive, usually with local or regional anesthesia and percutaneous fetoscopy under continuous ultrasound guidance, thereby minimizing the risk of maternal complications.(36) Whether laser treatment is the best option for stage I TTTS is uncertain, as different groups have reported different results.(37) A multicenter RCT of stage I disease has recently been carried out and the results will hopefully answer this important question.

Figure 1 illustrates how a laser procedure is performed in a case of TTTS.

Sequential selective laser surgery

In 2007, Quintero and colleagues described a laser technique in which they choose to target the anastomoses in a specific order based on the physiological assumption that further hemodynamic shifts during the laser procedure might contribute to post-laser fetal demise, especially of the donor. They called this technique the sequential selective laser photocoagulation of

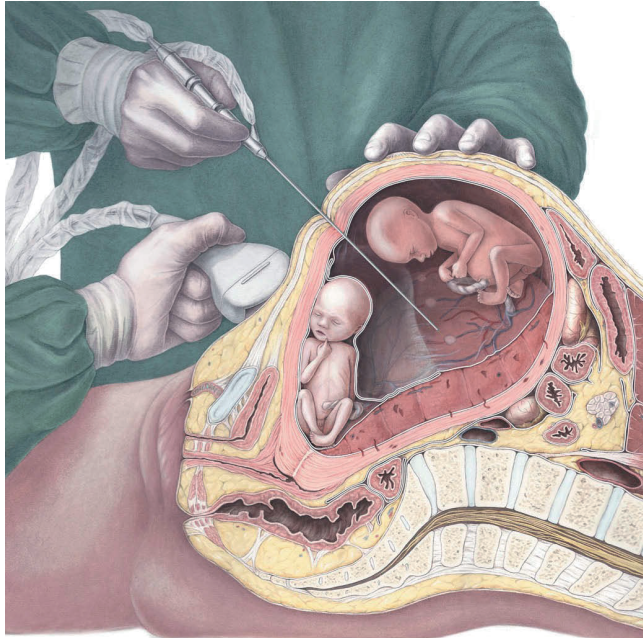


Figure 1. Realistic depiction of a modern-time laser procedure under ultrasound guidance.

Courtesy of Amanda Gautier.

communicating vessels and reported positive results in terms of post-laser IUFD and dual survival rates.(38) A systematic review in 2015 concluded that although data from three cohort studies suggest that dual survival was higher (75% versus 52%) and fetal demise rates were lower after sequential selective laser as compared to standard selective laser surgery, these results must be interpreted with caution, as no randomized controlled trials (RCT) were done and the three included studies had a high risk of bias due to methodological limitations.(39)

Solomon technique

Placental injection studies after laser therapy have revealed that residual anastomoses are present in over 30% of placentas.(40, 41) Residual anastomoses can cause post-laser TAPS or recurrence of TTTS and these complications are linked to adverse fetal, neonatal and long-term outcomes.(42, 43) To minimize the risk of residual anastomoses, a new laser technique was developed, designed

to coagulate the entire vascular equator. This technique was termed the "Solomon technique" after the biblical story of King Solomon who, in order to determine which one of two women was its real mother, suggested to cut a baby in half, after which the true mother begged that the child would be spared and committed to the care of her rival. Obviously, the Solomon technique does not entail splitting a baby in half. It is a modification of the selective laser technique, in which a line is drawn with the laser from one edge of the placenta to the other following the vascular equator, connecting the anastomoses that were first coagulated using the selective technique. The effect is a functional 'dichorionization' of the placenta. The Solomon trial, an RCT comparing the standard selective laser technique to the Solomon technique, showed a significant reduction in post-laser TAPS and recurrence of TTTS from 16% and 7% with the selective technique to 3% and 1% with the Solomon technique, respectively.(44) A secondary analysis showed that the Solomon technique does indeed reduce the risk of residual anastomoses, but they still occur, even when the procedure is recorded to be complete by the fetal therapist. Therefore, Slaghekke and her colleagues conclude that careful follow-up of the pregnancy remains essential also after Solomon laser.(41)

Survival

In 2015, Akkermans and colleagues systematically reviewed all published reports on survival after fetoscopic laser surgery for TTTS over 25 years and found that perinatal survival improved significantly during this time. The mean survival of both twins increased from 31% in reports dating from 1990 to 1995, to 62% in reports published between 2011 and 2014. Survival of at least one twin increased from 70 to 88%.(8) This study also shows a significant improvement in double survival with the more recently developed sequential selective (64%) and Solomon laser technique (71%) compared to the older techniques. The authors argue that improved survival is likely to be multifactorial and could be the result of evolution in laser technique, a learning curve effect for fetal surgeons, and improvements in referral as well as neonatal care.

Complications of fetoscopic laser surgery

The most important complications after laser surgery are fetal demise and preterm prelabor rupture of the membranes (PPROM).(36, 45) Fetal demise rates are often not reported separately but comprise some combination of fetal demise in utero, miscarriage and selective feticide. In studies that do report the rate of fetal demise after laser, it occurs in 13 to 33% of cases. Some series report higher rates of fetal loss for donors than recipients.(46-49) Although gestational age at birth for TTTS pregnancies has become significantly

higher since the introduction of laser therapy, most series report mean gestational ages at birth to be around 32 weeks.(9) The fact that TTTS infants are still born prematurely is mostly due to PPROM after laser surgery. Iatrogenic PPROM occurs in up to 30% of cases.(50, 51) Maternal complications of laser surgery are also not consistently reported, but appear to occur in about 5% of cases and include abdominal pain after leakage of amniotic fluid into the peritoneal cavity, chorioamnionitis, bleeding, pulmonary edema and placental abruption.(45)

Neonatal outcome

As the majority of TTTS survivors are still born prematurely, TTTS neonates are at risk for morbidity associated with prematurity, including respiratory disease, necrotizing enterocolitis, retinopathy of prematurity and cerebral injury.(52, 53) Additionally, specific TTTS-related neonatal complications include cardiovascular morbidity, renal failure and hematologic disorders.(53-55) The risk of congenital heart disease is increased 12-fold in TTTS survivors compared to singletons and is attributed to severe fetal hemodynamic instability, leading to altered cardiac development.(56) Although fetal cardiac functional and/or structural abnormalities improve after successful laser surgery, they can persist beyond birth and sometimes require intervention. Cardiovascular complications are primarily seen in the recipient twin and include hypertension, cardiomyopathy, right ventricular outflow tract obstruction (which affects about 4% of recipients at birth) and persistent pulmonary hypertension of the newborn.(56, 57) However, donors may be at increased risk for aortic coarctation, possibly due to reduced flow caused by hypovolemia.(58)

The most important and dreaded complication in TTTS survivors is cerebral injury, as it may have profound and lifelong impact on these infants.

Cerebral injury

Brain injury is a feared complication of MC pregnancies in general and of TTTS in particular. It is caused by the presence of vascular anastomoses and inter-twin transfusion. The risk is highest for single survivors after intrauterine demise of their co-twin, which can cause severe hypovolemia and anemia due to the acute transfer of blood from the surviving fetus into their dying or dead sibling through patent vascular connections.(59-61) Laser surgery performed before fetal demise is protective of cerebral injury, provided that the surgery is complete and no anastomoses were missed. The incidence of

cerebral injury in TTTS has dropped considerably since the introduction of laser therapy and reported ranges are now between 2 and 18%.(24, 25, 27, 62-66) In our own center, the incidence has decreased since the start of our laser surgery program in 2000 from 14% in the first five years, to 6% in the most recently studied cohort treated between 2011 and 2014.(48, 67) Various reasons have been suggested to explain the decrease in brain injury, including improvement in laser technique and a learning curve effect, both associated with a decrease in residual anastomoses. In a large cohort of 1023 TTTS pregnancies, postoperative TAPS and recurrence of TTTS after laser, both known to be caused by residual anastomoses, were associated with an increased risk of cerebral injury.(16, 42)

Several types of cerebral injury have been described in the literature, including (cystic) periventricular leukomalacia (PVL), intraventricular hemorrhage (IVH), posthemorrhagic ventricular dilatation, cerebral atrophy and arterial ischemic stroke. Fetal and neonatal MRI studies have shed more light on brain abnormalities detected in TTTS in the last decade. Several studies have reported additional findings of MRI compared to ultrasonography alone, including polymicrogyria and other migrational disorders, sinovenous thrombosis, and more subtle and/or diffuse white matter injury.(42, 64, 68-71) Donors and recipients are equally affected by cerebral injury, although the occurrence of cerebral arterial stroke seems to be a specific risk for recipients. (42, 62, 72) The range of cerebral injury reported by different groups is quite wide. This is due to varying definitions of cerebral injury, differences in the timing and frequency of imaging, and the fact that some centers do not routinely perform cranial imaging in all TTTS survivors.

Prematurity is still more the rule than the exception in TTTS pregnancies, making survivors also prone to postnatally acquired cerebral damage related to (extreme) prematurity, especially IVH and PVL. Prematurity and low birth weight (with birth weight being strongly correlated with gestational age) have in fact been proven to be the most important risk factors for severe cerebral injuries in survivors of TTTS.(62, 66) Reduction of severe prematurity in TTTS could hypothetically be achieved by reduction of the risk of PPRM and intrauterine infection through further technical improvements in fetoscopic surgery (for example by developing smaller fetoscopic instruments). Besides postnatal brain injury caused by prematurity, antenatally acquired cerebral lesions are more common in the context of TTTS compared to dichorionic twins, presumably because of the severe hemodynamic disturbances during pregnancy.(62) When antenatal in origin, cerebral injury in donors is thought to be mainly caused by impaired cerebral perfusion as the result of hypovolemia and inter-twin shifts of blood, leading to hypoxic-ischemic insults.

Polycythemia and hyperviscosity with subsequent vascular sludging is the presumed mechanism for cerebral injury in recipients.

Given the remaining risk of cerebral injury for TTTS survivors, routine standardized antenatal and postnatal cerebral imaging protocols are strongly recommended to accurately evaluate origin, timing and type of damage. MRI may play a larger role in determining cerebral injury in the future. Increased awareness of the increased risk by neonatologists and pediatricians may improve neonatal and pediatric care for these children. The clinical relevance of neuroimaging findings should be determined using long-term neuro-developmental outcome data of all TTTS survivors until at least school age.

Long-term outcome

Definition and incidence

The ultimate goal of fetal therapy should be survival without neurodevelopmental impairment (NDI). Especially now that survival rates and short-term outcome have greatly improved, long-term follow-up of survivors is essential to evaluate whether this goal is achieved.(46, 73) Severe NDI in most studies is defined as at least one of the following: cerebral palsy (CP), severe motor and/or cognitive developmental delay, bilateral blindness, or deafness requiring amplification with hearing aids. Determining NDI requires a follow-up regimen that includes a physical and neurological examination, as well as cognitive and motor developmental assessments. Psychomotor development is ideally evaluated using standardized tests, such as the Bayley Scales for Infant and Toddler Development. However, several studies rely on the parent interview-based Ages and Stages Questionnaire (ASQ) for the evaluation of NDI. The ASQ has been shown to be a good screening tool for identifying infants who are severely delayed at 24 months of age and require neurological follow-up or intervention, but it cannot give the detailed information provided by face-to-face developmental tests performed by trained professionals.(74)

When combining studies that have clearly reported rates of NDI and/or CP after laser surgery at ≥ 2 years of age, the incidence of severe NDI in TTTS after laser surgery is 9% (range between 3 and 18%) and CP is reported at an average of 5% (range 2-12%). The results of these studies are summarized in **table 1**. The incidences of severe NDI and CP have decreased over the last two decades. Different factors may explain this improvement, including the development of stringent fetal monitoring protocols for MC pregnancies, learning curve effect of the laser procedure, increased awareness and improved neonatal care strategies for TTTS survivors.(7, 75)

Table 1. Studies of neurodevelopmental impairment and cerebral palsy in TTTS treated with laser

Reference	Country	Age (y)	Patients	NDI %	CP %	Developmental test
Sutcliffe 2001 (76)	UK	2	66	9	9	GDS
Banek 2003 (77)	Germany	2-3	89	11	11	GDS, SOT
Graef 2006 (78)	Germany	2-4	167	8	6	GDS, SOT
Lencien 2009 (25)	France	2	88	11	10	ASQ
Lopriore 2009 (79)	Netherlands	2	278	18	6	BSID-II
Salomon 2010 (23)	France	5	73	-	12	ASQ, WISC-IV
Gray 2011 (80)	Australia	2-4	113	12	4	GDS, BSID-II, Bayley-III
Graeve 2012 (81)	Germany	4-10	151	9	-	K-ABC, GNSP
Van Klink 2014 (46)*	Netherlands	2	155	6	3	Bayley-III
McIntosh 2014 (82)	Australia	1-3	50	4	2	WPPSI-III, questionnaire
Vanderbilt 2014 (83)	USA	2	100	4	3	BDI-2, ATNE
Tosello 2014 (47)	France	0-5	35	-	6	ASQ
Korsakissok 2018 (65)	France	2-7	58	9	5	ASQ
Schou 2019 (84)	Denmark	1-4	86	10	9	ASQ
Chmait 2019 (63)	USA	2	99	4	3	ATNE, BDI-2
Spruijt 2019 (48)**	Netherlands	2	258	3	2	Bayley-III
Overall				9% (151/1741)	5% (93/1695)	
Range				3-18%	2-12%	

GDS: Griffiths' Developmental Test Scales; SOT: Snijders-Oomen Non-Verbal Intelligence Test; ASQ: Ages and Stages Questionnaire; BSID: Bayley Scales of Infant Development; WISC: Wechsler Intelligence Scale for Children; K-ABC: Kaufman Assessment Battery for Children; GNSP: German National Screening Program; WPPSI: Wechsler Preschool and Primary Scale of Intelligence; BDI: Battelle Development Inventory; ATNE: Arniel-Tison Neurodevelopmental Examination

- : not assessed

* only numbers of the 2008-2010 cohort used here to prevent patient overlap with the 2009 Lopriore study

** only numbers of the 2011-2014 cohort used here to prevent patient overlap with the 2014 Van Klink study

Risk factors

Risk factors for long-term NDI identified in follow-up studies include advanced gestational age at laser surgery, Quintero stage, low gestational age at birth, low birth weight and severe cerebral injury.(48, 63, 79, 85, 86) The negative impact of advanced gestational age at laser and higher Quintero stage suggests that increasing disease severity may lead to increased long-term morbidity. Low gestational age and birth weight are well-recognized risk factors for developmental impairment in the general population as well: severe NDI is frequently found in children born preterm and is inversely associated with gestational age and birth weight.

Mild neurodevelopmental impairment

Long-term follow-up studies after TTTS have used widely varying methods with regard to inclusion criteria, timing of assessments, the definition of NDI and the used outcome measures and controls, making it difficult to compare results. Significant lost to follow-up rates are common amongst long-term follow-up studies and have the potential to cause bias, most likely causing an underestimation of developmental impairment.(87, 88) In the majority of studies children were assessed at the age of two years, adjusted for prematurity, when major developmental impairment that requires intervention can be distinguished. However, neurodevelopmental assessment during early childhood can only moderately predict longer-term developmental outcome, especially for cognitive ability and academic performance. Certain developmental problems such as learning difficulties, behavioral problems and autism spectrum disorder are not always detected until school age, when children become more socially and academically challenged. To understand the clinical relevance of milder forms of impairment diagnosed in early childhood, follow-up until at least school age is essential. Data on mild neurodevelopmental impairment are limited and inconsistent. However, because of the decreasing trend in the rate of severe NDI, attention is shifting towards more subtle problems, including mild CP and neurocognitive impairments. Minor impairments can have a significant impact on the care and educational requirements of children and are reported in up to 30% of TTTS survivors. (25, 47, 48, 77, 89, 90) In order to gain more information on the exact burden and severity of NDI after laser surgery for TTTS, we encourage international collaboration to obtain larger sample sizes and statistical power, using a standardized follow-up regimen including uniform and clearly defined criteria for long-term neurodevelopmental impairment.(91)

Conclusion

The management of TTTS has evolved significantly in the 21st century. Placental injection studies have improved our understanding of underlying placental pathophysiology. Fetoscopic laser coagulation of placental anastomoses is the primary treatment option and many advancements have been made over the past decade. Laser surgery using the Solomon technique has been proven to decrease the risk of post-laser TAPS and recurrence of TTTS. The advancements in antenatal management of TTTS have led to improved survival, higher gestational ages at birth, a lower incidence of neonatal brain injury and a decrease in severe long-term neurodevelopmental impairment.

Expert Opinion

Although the outcome of TTTS has improved greatly over the past decades, opportunities for further progress certainly still exist. The ultimate goals in the field of TTTS include prompt diagnosis or even better, accurate prediction of development of the syndrome, followed by a preferably non-invasive treatment with minimal complications. This treatment should achieve quick normalization of hemodynamic imbalance, minimizing any damage to the fetuses, without increasing the risk of PPROM and prematurity. The final goal for every TTTS pregnancy is (near-) term birth of two healthy neonates with normal long-term cognitive and motor development.

There is still a lot of ground to cover before these goals can be achieved. High-intensity focused ultrasound (HIFU) is a non-invasive technique which can be used to ablate blood flow in placental vessels, and therefore holds promise for the future treatment of TTTS. Although some preliminary experience with HIFU has been reported in animals as well as human cases of twin reversed arterial perfusion sequence (TRAP), safety and efficacy in humans with TTTS remains to be established.^(92, 93) In the meantime, technological innovations may be able to further improve visibility and accessibility of the vascular equator during laser procedures. The further development of instrumentation aimed at minimizing the risk of PPROM after laser surgery is another important focus of research in future years, hopefully helping to prolong pregnancies further beyond 32 weeks' gestation and thereby minimizing the risks associated with preterm birth. Also, as the severity of placental damage after laser surgery is associated with PPROM and earlier delivery, the further fine-tuning of laser technique using minimal energy but obtaining maximum effect can certainly contribute to even better perinatal outcome.

With concern to the neonatal outcome of TTTS survivors, fetal MRI studies have begun to shed more light on the timing and mechanisms of fetal brain injury in TTTS, but studies that link prenatal MRI findings to long-term neurodevelopment are still lacking. Knowledge on long-term development beyond the age of 2 years is also very limited, especially concerning potential risk factors for adverse outcome and mild neurodevelopmental impairment. Although follow-up programs are costly and hard to realize, TTTS remains a serious risk factor for NDI. In our opinion, the treatment of fetuses in utero comes with the responsibility of providing careful and long-term follow-up of survivors until at least school age, in order to ensure that they will receive the care they need, if they need it. Long-term follow-up studies are indispensable for the continuous evaluation of the outcome of fetal therapy in TTTS pregnancies, as well as for the facilitation of evidence-based counseling of future parents. The formation of a core outcome set by a group of international experts is an important step in the joining of forces to help TTTS fetuses survive without complications, by making it possible to compare and combine research results. As briefly discussed in our review, severe fetal hemodynamic changes in TTTS can interfere with cardiac development leading to both functional and structural cardiac abnormalities. Follow-up studies of these cardiac changes are still very limited, but are essential for determining the need for cardiac screening and long-term monitoring in TTTS survivors, as well as for the counseling of parents about the prognosis of their children.

Lastly, an important issue to address is the need for centralization of treatment for TTTS in high-output fetal therapy centers. Following the advancements of laser treatment, there is an increasing number of small centers starting up fetal therapy programs in different countries. However, centralization has proven to be vital for the quality of care in a highly technical procedure such as fetoscopic laser surgery.⁽⁹⁴⁾ The best possible care can only be realized in highly specialized centers with dedicated and experienced multidisciplinary teams, ideally comprising fetal therapists, neonatologists and psychologists and in collaboration with twin parents' organizations.

References

1. Lewi L, Van Schoubroeck D, Gratacos E, Witters I, Timmerman D, Deprest J. Monochorionic diamniotic twins: complications and management options. *Current opinion in obstetrics & gynecology*. 2003;15(2):177-94.
2. Dube J, Dodds L, Armson BA. Does chorionicity or zygosity predict adverse perinatal outcomes in twins? *American journal of obstetrics and gynecology*. 2002;186(3):579-83.
3. Pharoah PO. Risk of cerebral palsy in multiple pregnancies. *Clinics in perinatology*. 2006;33(2):301-13.
4. Glennon CL, Shemer SA, Palma-Dias R, Umstad MP. The History of Treatment of Twin-to-Twin Transfusion Syndrome. *Twin research and human genetics : the official journal of the International Society for Twin Studies*. 2016;19(3):168-74.
5. Weir PE, Ratten GJ, Beischer NA. Acute polyhydramnios--a complication of monozygous twin pregnancy. *British journal of obstetrics and gynaecology*. 1979;86(11):849-53.
6. Gratacos E, Ortiz JU, Martinez JM. A systematic approach to the differential diagnosis and management of the complications of monochorionic twin pregnancies. *Fetal diagnosis and therapy*. 2012;32(3):145-55.
7. Sueters M, Oepkes D. Diagnosis of twin-to-twin transfusion syndrome, selective fetal growth restriction, twin anaemia-polycythaemia sequence, and twin reversed arterial perfusion sequence. *Best practice & research Clinical obstetrics & gynaecology*. 2014;28(2):215-26.
8. Akkermans J, Peeters SH, Klumper FJ, Lopriore E, Middeldorp JM, Oepkes D. Twenty-Five Years of Fetoscopic Laser Coagulation in Twin-Twin Transfusion Syndrome: A Systematic Review. *Fetal diagnosis and therapy*. 2015;38(4):241-53.
9. Hecher K, Gardiner HM, Diemert A, Bartmann P. Long-term outcomes for monochorionic twins after laser therapy in twin-to-twin transfusion syndrome. *The Lancet Child & adolescent health*. 2018;2(7):525-35.
10. Galea P, Barigye O, Wee L, Jain V, Sullivan M, Fisk NM. The placenta contributes to activation of the renin angiotensin system in twin-twin transfusion syndrome. *Placenta*. 2008;29(8):734-42.
11. Djaafri F, Stirnemann J, Mediouni I, Colmant C, Ville Y. Twin-twin transfusion syndrome - What we have learned from clinical trials. *Seminars in fetal & neonatal medicine*. 2017;22(6):367-75.
12. Quintero RA, Morales WJ, Allen MH, Bornick PW, Johnson PK, Kruger M. Staging of twin-twin transfusion syndrome. *Journal of perinatology : official journal of the California Perinatal Association*. 1999;19(8 Pt 1):550-5.
13. Taylor MJ, Govender L, Jolly M, Wee L, Fisk NM. Validation of the Quintero staging system for twin-twin transfusion syndrome. *Obstetrics and gynecology*. 2002;100(6):1257-65.
14. Lopriore E, Slaghekke F, Middeldorp JM, Klumper FJ, van Lith JM, Walther FJ, et al. Accurate and simple evaluation of vascular anastomoses in monochorionic placenta using colored dye. *Journal of visualized experiments : JoVE*. 2011(55):e3208.
15. Zhao DP, de Villiers SF, Slaghekke F, Walther FJ, Middeldorp JM, Oepkes D, et al. Prevalence, size, number and localization of vascular anastomoses in monochorionic placentas. *Placenta*. 2013;34(7):589-93.
16. Lewi L, Deprest J, Hecher K. The vascular anastomoses in monochorionic twin pregnancies and their clinical consequences. *American journal of obstetrics and gynecology*. 2013;208(1):19-30.
17. Denbow ML, Cox P, Taylor M, Hammal DM, Fisk NM. Placental angioarchitecture in monochorionic twin pregnancies: relationship to fetal growth, fetofetal transfusion syndrome, and pregnancy outcome. *American journal of obstetrics and gynecology*. 2000;182(2):417-26.
18. Lopriore E, Middeldorp JM, Oepkes D, Kanhai HH, Walther FJ, Vandenbussche FP. Twin anemia-polycythemia sequence in two monochorionic twin pairs without oligo-polyhydramnios sequence. *Placenta*. 2007;28(1):47-51.
19. Lopriore E, Deprest J, Slaghekke F, Oepkes D, Middeldorp JM, Vandenbussche FP, et al. Placental characteristics in monochorionic twins with and without twin anemia-polycythemia sequence. *Obstetrics and gynecology*. 2008;112(4):753-8.

20. Slaghekke F, Kist WJ, Oepkes D, Middeldorp JM, Klumper FJ, Vanderbussche FP, et al. TAPS and TOPS: two distinct forms of feto-fetal transfusion in monochorionic twins. *Zeitschrift fur Geburtshilfe und Neonatologie*. 2009;213(6):248-54.
21. Tollenaar LSA, Lopriore E, Middeldorp JM, Haak MC, Klumper FJ, Oepkes D, et al. Improved prediction of twin anemia-polycythemia sequence by delta middle cerebral artery peak systolic velocity: new antenatal classification system. *Ultrasound in obstetrics & gynecology : the official journal of the International Society of Ultrasound in Obstetrics and Gynecology*. 2019;53(6):788-93.
22. Tollenaar LS, Slaghekke F, Middeldorp JM, Klumper FJ, Haak MC, Oepkes D, et al. Twin Anemia Polycythemia Sequence: Current Views on Pathogenesis, Diagnostic Criteria, Perinatal Management, and Outcome. *Twin research and human genetics : the official journal of the International Society for Twin Studies*. 2016;19(3):222-33.
23. Salomon LJ, Ortqvist L, Aegerter P, Bussieres L, Staracci S, Stirnemann JJ, et al. Long-term developmental follow-up of infants who participated in a randomized clinical trial of amniocentesis vs laser photocoagulation for the treatment of twin-to-twin transfusion syndrome. *American journal of obstetrics and gynecology*. 2010;203(5):444.e1-7.
24. van Klink JM, Koopman HM, van Zwet EW, Oepkes D, Walther FJ, Lopriore E. Cerebral injury and neurodevelopmental impairment after amnioreduction versus laser surgery in twin-twin transfusion syndrome: a systematic review and meta-analysis. *Fetal diagnosis and therapy*. 2013;33(2):81-9.
25. Lenclen R, Ciarlo G, Paupe A, Bussieres L, Ville Y. Neurodevelopmental outcome at 2 years in children born preterm treated by amnioreduction or fetoscopic laser surgery for twin-to-twin transfusion syndrome: comparison with dichorionic twins. *American journal of obstetrics and gynecology*. 2009;201(3):291.e1-5.
26. Li X, Morokuma S, Fukushima K, Otera Y, Yumoto Y, Tsukimori K, et al. Prognosis and long-term neurodevelopmental outcome in conservatively treated twin-to-twin transfusion syndrome. *BMC pregnancy and childbirth*. 2011;11:32.
27. Senat MV, Deprest J, Boulvain M, Paupe A, Winer N, Ville Y. Endoscopic laser surgery versus serial amnioreduction for severe twin-to-twin transfusion syndrome. *The New England journal of medicine*. 2004;351(2):136-44.
28. Roberts D, Neilson JP, Kilby MD, Gates S. Interventions for the treatment of twin-twin transfusion syndrome. *The Cochrane database of systematic reviews*. 2014(1):Cd002073.
29. Hecher K, Plath H, Bregenzler T, Hansmann M, Hackeloer BJ. Endoscopic laser surgery versus serial amniocenteses in the treatment of severe twin-twin transfusion syndrome. *American journal of obstetrics and gynecology*. 1999;180(3 Pt 1):717-24.
30. Rossi AC, D'Addario V. Survival outcomes of twin-twin transfusion syndrome stage I: a systematic review of literature. *American journal of perinatology*. 2013;30(1):5-10.
31. De Lia JE, Cruikshank DP, Keye WR, Jr. Fetoscopic neodymium:YAG laser occlusion of placental vessels in severe twin-twin transfusion syndrome. *Obstetrics and gynecology*. 1990;75(6):1046-53.
32. Quintero RA, Comas C, Bornick PW, Allen MH, Kruger M. Selective versus non-selective laser photocoagulation of placental vessels in twin-to-twin transfusion syndrome. *Ultrasound in obstetrics & gynecology : the official journal of the International Society of Ultrasound in Obstetrics and Gynecology*. 2000;16(3):230-6.
33. Quintero RA, Morales WJ, Mendoza G, Allen M, Kalter CS, Giannina G, et al. Selective photocoagulation of placental vessels in twin-twin transfusion syndrome: evolution of a surgical technique. *Obstetrical & gynecological survey*. 1998;53(12 Suppl):S97-103.
34. Ville Y, Hecher K, Ogg D, Warren R, Nicolaides K. Successful outcome after Nd : YAG laser separation of chorioangiopagus-twins under sonoendoscopic control. *Ultrasound in obstetrics & gynecology : the official journal of the International Society of Ultrasound in Obstetrics and Gynecology*. 1992;2(6):429-31.
35. Ville Y, Hyett J, Hecher K, Nicolaides K. Preliminary experience with endoscopic laser surgery for severe twin-twin transfusion syndrome. *The New England journal of medicine*. 1995;332(4):224-7.

36. Yamamoto M, El Murr L, Robyr R, Leleu F, Takahashi Y, Ville Y. Incidence and impact of perioperative complications in 175 fetoscopy-guided laser coagulations of chorionic plate anastomoses in fetofetal transfusion syndrome before 26 weeks of gestation. *American journal of obstetrics and gynecology*. 2005;193(3 Pt 2):1110-6.
37. Khalil A, Cooper E, Townsend R, Thilaganathan B. Evolution of Stage 1 Twin-to-Twin Transfusion Syndrome (TTTS): Systematic Review and Meta-Analysis. *Twin research and human genetics : the official journal of the International Society for Twin Studies*. 2016;19(3):207-16.
38. Quintero RA, Ishii K, Chmait RH, Bornick PW, Allen MH, Kontopoulos EV. Sequential selective laser photocoagulation of communicating vessels in twin-twin transfusion syndrome. *The journal of maternal-fetal & neonatal medicine : the official journal of the European Association of Perinatal Medicine, the Federation of Asia and Oceania Perinatal Societies, the International Society of Perinatal Obstet*. 2007;20(10):763-8.
39. Akkermans J, Peeters SH, Klumper FJ, Middeldorp JM, Lopriore E, Oepkes D. Is the Sequential Laser Technique for Twin-to-Twin Transfusion Syndrome Truly Superior to the Standard Selective Technique? A Meta-Analysis. *Fetal diagnosis and therapy*. 2015;37(4):251-8.
40. Lopriore E, Middeldorp JM, Oepkes D, Klumper FJ, Walther FJ, Vandenbussche FP. Residual anastomoses after fetoscopic laser surgery in twin-to-twin transfusion syndrome: frequency, associated risks and outcome. *Placenta*. 2007;28(2-3):204-8.
41. Slaghekke F, Lewi L, Middeldorp JM, Weingertner AS, Klumper FJ, Dekoninck P, et al. Residual anastomoses in twin-twin transfusion syndrome after laser: the Solomon randomized trial. *American journal of obstetrics and gynecology*. 2014;211(3):285.e1-7.
42. Stirnemann J, Chalouhi G, Essaoui M, Bahi-Buisson N, Sonigo P, Millischer AE, et al. Fetal brain imaging following laser surgery in twin-to-twin surgery. *BJOG : an international journal of obstetrics and gynaecology*. 2018;125(9):1186-91.
43. Lewi L, Jani J, Cannie M, Robyr R, Ville Y, Hecher K, et al. Intertwin anastomoses in monochorionic placentas after fetoscopic laser coagulation for twin-to-twin transfusion syndrome: is there more than meets the eye? *American journal of obstetrics and gynecology*. 2006;194(3):790-5.
44. Slaghekke F, Lopriore E, Lewi L, Middeldorp JM, van Zwet EW, Weingertner AS, et al. Fetoscopic laser coagulation of the vascular equator versus selective coagulation for twin-to-twin transfusion syndrome: an open-label randomised controlled trial. *Lancet (London, England)*. 2014;383(9935):2144-51.
45. Merz W, Tchatcheva K, Gembruch U, Kohl T. Maternal complications of fetoscopic laser photocoagulation (FLP) for treatment of twin-twin transfusion syndrome (TTTS). *Journal of perinatal medicine*. 2010;38(4):439-43.
46. van Klink JM, Koopman HM, van Zwet EW, Middeldorp JM, Walther FJ, Oepkes D, et al. Improvement in neurodevelopmental outcome in survivors of twin-twin transfusion syndrome treated with laser surgery. *American journal of obstetrics and gynecology*. 2014;210(6):540.e1-7.
47. Tosello B, Blanc J, Haumonte JB, D'Ercole C, Gire C. Short and medium-term outcomes of live-born twins after fetoscopic laser therapy for twin-twin transfusion syndrome. *Journal of perinatal medicine*. 2014;42(1):99-105.
48. Spruijt MS, Lopriore E, Tan R, Slaghekke F, Klumper F, Middeldorp JM, et al. Long-Term Neurodevelopmental Outcome in Twin-to-Twin Transfusion Syndrome: Is there still Room for Improvement? *Journal of clinical medicine*. 2019;8(8).
49. Chmait RH, Kontopoulos EV, Korst LM, Llanes A, Petisco I, Quintero RA. Stage-based outcomes of 682 consecutive cases of twin-twin transfusion syndrome treated with laser surgery: the USFetus experience. *American journal of obstetrics and gynecology*. 2011;204(5):393.e1-6.
50. Beck V, Lewi P, Gucciardo L, Devlieger R. Preterm prelabor rupture of membranes and fetal survival after minimally invasive fetal surgery: a systematic review of the literature. *Fetal diagnosis and therapy*. 2012;31(1):1-9.

51. Malshe A, Snowise S, Mann LK, Boring N, Johnson A, Bebbington MW, et al. Preterm delivery after fetoscopic laser surgery for twin-twin transfusion syndrome: etiology and risk factors. *Ultrasound in obstetrics & gynecology : the official journal of the International Society of Ultrasound in Obstetrics and Gynecology*. 2017;49(5):612-6.
52. Halvorsen CP, Ek S, Dellgren A, Grunewald C, Kubickas M, Westgren M, et al. Survival and neonatal outcome after fetoscopic guided laser occlusion (FLOC) of twin-to-twin transfusion syndrome (TTTS) in Sweden. *Journal of perinatal medicine*. 2012;40(5):533-8.
53. Lopriore E, Oepkes D, Walther FJ. Neonatal morbidity in twin-twin transfusion syndrome. *Early human development*. 2011;87(9):595-9.
54. Verbeek L, Slaghekke F, Sueters M, Middeldorp JM, Klumper FJ, Haak MC, et al. Hematological disorders at birth in complicated monochorionic twins. *Expert review of hematology*. 2017;10(6):525-32.
55. Wohlmuth C, Boudreaux D, Moise KJ, Jr., Johnson A, Papanna R, Bebbington M, et al. Cardiac pathophysiology in twin-twin transfusion syndrome: new insights into its evolution. *Ultrasound in obstetrics & gynecology : the official journal of the International Society of Ultrasound in Obstetrics and Gynecology*. 2018;51(3):341-8.
56. Gijtenbeek M, Shirzada MR, Ten Harkel ADJ, Oepkes D, M CH. Congenital Heart Defects in Monochorionic Twins: A Systematic Review and Meta-Analysis. *Journal of clinical medicine*. 2019;8(6).
57. Manning N, Archer N. Cardiac Manifestations of Twin-to-Twin Transfusion Syndrome. *Twin research and human genetics : the official journal of the International Society for Twin Studies*. 2016;19(3):246-54.
58. van den Boom J, Battin M, Hornung T. Twin-twin transfusion syndrome, coarctation of the aorta and hypoplastic aortic arch: a case series report. *Journal of paediatrics and child health*. 2010;46(3):76-9.
59. Hillman SC, Morris RK, Kilby MD. Co-twin prognosis after single fetal death: a systematic review and meta-analysis. *Obstetrics and gynecology*. 2011;118(4):928-40.
60. van Klink JM, van Steenis A, Steggerda SJ, Genova L, Sueters M, Oepkes D, et al. Single fetal demise in monochorionic pregnancies: incidence and patterns of cerebral injury. *Ultrasound in obstetrics & gynecology : the official journal of the International Society of Ultrasound in Obstetrics and Gynecology*. 2015;45(3):294-300.
61. Adegbite AL, Castille S, Ward S, Bajoria R. Prevalence of cranial scan abnormalities in preterm twins in relation to chorionicity and discordant birth weight. *European journal of obstetrics, gynecology, and reproductive biology*. 2005;119(1):47-55.
62. Spruijt M, Steggerda S, Rath M, van Zwet E, Oepkes D, Walther F, et al. Cerebral injury in twin-twin transfusion syndrome treated with fetoscopic laser surgery. *Obstetrics and gynecology*. 2012;120(1):15-20.
63. Chmait RH, Chon AH, Schragger SM, Llanes A, Hamilton AH, Vanderbilt DL. Neonatal cerebral lesions predict 2-year neurodevelopmental impairment in children treated with laser surgery for twin-twin transfusion syndrome. *The journal of maternal-fetal & neonatal medicine : the official journal of the European Association of Perinatal Medicine, the Federation of Asia and Oceania Perinatal Societies, the International Society of Perinatal Obstet*. 2019;32(1):80-4.
64. Quarello E, Molho M, Ville Y. Incidence, mechanisms, and patterns of fetal cerebral lesions in twin-to-twin transfusion syndrome. *The journal of maternal-fetal & neonatal medicine : the official journal of the European Association of Perinatal Medicine, the Federation of Asia and Oceania Perinatal Societies, the International Society of Perinatal Obstet*. 2007;20(8):589-97.
65. Korsakissok M, Groussolles M, Dicky O, Alberge C, Casper C, Azogui-Assouline C. Mortality, morbidity and 2-years neurodevelopmental prognosis of twin to twin transfusion syndrome after fetoscopic laser therapy: a prospective, 58 patients cohort study. *Journal of gynecology obstetrics and human reproduction*. 2018;47(10):555-60.
66. Vanderbilt DL, Schragger SM, Llanes A, Chmait RH. Prevalence and risk factors of cerebral lesions in neonates after laser surgery for twin-twin transfusion syndrome. *American journal of obstetrics and gynecology*. 2012;207(4):320.e1-6.

67. Lopriore E, van Wezel-Meijler G, Middeldorp JM, Sueters M, Vandenbussche FP, Walther FJ. Incidence, origin, and character of cerebral injury in twin-to-twin transfusion syndrome treated with fetoscopic laser surgery. *American journal of obstetrics and gynecology*. 2006;194(5):1215-20.
68. Ascherl R, Sorge I, Thome U, Hirsch FW, Blaser A, Kiess W, et al. Severe gyration and migration disorder in fetofetal transfusion syndrome: two case reports and a review of the literature on the neurological outcome of children with lesions on neuroimaging. *Child's nervous system : ChNS : official journal of the International Society for Pediatric Neurosurgery*. 2018;34(1):155-63.
69. Merhar SL, Kline-Fath BM, Meinzen-Derr J, Schibler KR, Leach JL. Fetal and postnatal brain MRI in premature infants with twin-twin transfusion syndrome. *Journal of perinatology : official journal of the California Perinatal Association*. 2013;33(2):112-8.
70. Griffiths PD, Sharrack S, Chan KL, Bamfo J, Williams F, Kilby MD. Fetal brain injury in survivors of twin pregnancies complicated by demise of one twin as assessed by in utero MR imaging. *Prenatal diagnosis*. 2015;35(6):583-91.
71. Robinson A, Teoh M, Edwards A, Fahey M, Goergen S. Fetal brain injury in complicated monochorionic pregnancies: diagnostic yield of prenatal MRI following surveillance ultrasound and influence on prognostic counselling. *Prenatal diagnosis*. 2017;37(6):611-27.
72. Rossi AC, D'Addario V. Comparison of donor and recipient outcomes following laser therapy performed for twin-twin transfusion syndrome: a meta-analysis and review of literature. *American journal of perinatology*. 2009;26(1):27-32.
73. Rossi AC, Vanderbilt D, Chmait RH. Neurodevelopmental outcomes after laser therapy for twin-twin transfusion syndrome: a systematic review and meta-analysis. *Obstetrics and gynecology*. 2011;118(5):1145-50.
74. Gollenberg AL, Lynch CD, Jackson LW, McGuinness BM, Msall ME. Concurrent validity of the parent-completed Ages and Stages Questionnaires, 2nd Ed. with the Bayley Scales of Infant Development II in a low-risk sample. *Child: care, health and development*. 2010;36(4):485-90.
75. Morris RK, Selman TJ, Harbidge A, Martin WI, Kilby MD. Fetoscopic laser coagulation for severe twin-to-twin transfusion syndrome: factors influencing perinatal outcome, learning curve of the procedure and lessons for new centres. *BJOG : an international journal of obstetrics and gynaecology*. 2010;117(11):1350-7.
76. Sutcliffe AG, Sebire NJ, Pigott AJ, Taylor B, Edwards PR, Nicolaidis KH. Outcome for children born after in utero laser ablation therapy for severe twin-to-twin transfusion syndrome. *BJOG : an international journal of obstetrics and gynaecology*. 2001;108(12):1246-50.
77. Banek CS, Hecher K, Hackeloer BJ, Bartmann P. Long-term neurodevelopmental outcome after intrauterine laser treatment for severe twin-twin transfusion syndrome. *American journal of obstetrics and gynecology*. 2003;188(4):876-80.
78. Graef C, Ellenrieder B, Hecher K, Hackeloer BJ, Huber A, Bartmann P. Long-term neurodevelopmental outcome of 167 children after intrauterine laser treatment for severe twin-twin transfusion syndrome. *American journal of obstetrics and gynecology*. 2006;194(2):303-8.
79. Lopriore E, Ortibus E, Acosta-Rojas R, Le Cessie S, Middeldorp JM, Oepkes D, et al. Risk factors for neurodevelopment impairment in twin-twin transfusion syndrome treated with fetoscopic laser surgery. *Obstetrics and gynecology*. 2009;113(2 Pt 1):361-6.
80. Gray PH, Poulsen L, Gilshenan K, Soong B, Cincotta RB, Gardener G. Neurodevelopmental outcome and risk factors for disability for twin-twin transfusion syndrome treated with laser surgery. *American journal of obstetrics and gynecology*. 2011;204(2):159 e1-6.
81. Graeve P, Banek C, Stegmann-Woessner G, Maschke C, Hecher K, Bartmann P. Neurodevelopmental outcome at 6 years of age after intrauterine laser therapy for twin-twin transfusion syndrome. *Acta paediatrica (Oslo, Norway : 1992)*. 2012;101(12):1200-5.
82. McIntosh J, Meriki N, Joshi A, Biggs V, Welsh AW, Challis D, et al. Long term developmental outcomes of pre-school age children following laser surgery for twin-to-twin transfusion syndrome. *Early human development*. 2014;90(12):837-42.

83. Vanderbilt DL, Schragger SM, Llanes A, Hamilton A, Seri I, Chmait RH. Predictors of 2-year cognitive performance after laser surgery for twin-twin transfusion syndrome. *American journal of obstetrics and gynecology*. 2014;211(4):388 e1-7.
84. Schou KV, Lando AV, Ekelund CK, Jensen LN, Jorgensen C, Norgaard LN, et al. Long-Term Neurodevelopmental Outcome of Monochorionic Twins after Laser Therapy or Umbilical Cord Occlusion for Twin-Twin Transfusion Syndrome. *Fetal diagnosis and therapy*. 2019;46(1):20-7.
85. van Klink JM, Koopman HM, Rijken M, Middeldorp JM, Oepkes D, Lopriore E. Long-Term Neurodevelopmental Outcome in Survivors of Twin-to-Twin Transfusion Syndrome. *Twin research and human genetics : the official journal of the International Society for Twin Studies*. 2016;19(3):255-61.
86. Sananes N, Gabriele V, Weingertner AS, Ruano R, Sanz-Cortes M, Gaudineau A, et al. Evaluation of long-term neurodevelopment in twin-twin transfusion syndrome after laser therapy. *Prenatal diagnosis*. 2016;36(12):1139-45.
87. Aylward GP, Hatcher RP, Stripp B, Gustafson NF, Leavitt LA. Who goes and who stays: subject loss in a multicenter, longitudinal follow-up study. *J Dev Behav Pediatr*. 1985;6(1):3-8.
88. Wolke D, Sohne B, Ohrt B, Riegel K. Follow-up of preterm children: important to document dropouts. *Lancet (London, England)*. 1995;345(8947):447.
89. Mullers SM, McAuliffe FM, Kent E, Carroll S, Mone F, Breslin N, et al. Outcome following selective fetoscopic laser ablation for twin to twin transfusion syndrome: an 8 year national collaborative experience. *European journal of obstetrics, gynecology, and reproductive biology*. 2015;191:125-9.
90. Campos D, Arias AV, Campos-Zanelli TM, Souza DS, Dos Santos Neto OG, Peralta CF, et al. Twin-twin transfusion syndrome: neurodevelopment of infants treated with laser surgery. *Arquivos de neuro-psiquiatria*. 2016;74(4):307-13.
91. Perry H, Duffy JMN, Umadia O, Khalil A. Outcome reporting across randomized trials and observational studies evaluating treatments for twin-twin transfusion syndrome: systematic review. *Ultrasound in obstetrics & gynecology : the official journal of the International Society of Ultrasound in Obstetrics and Gynecology*. 2018;52(5):577-85.
92. Shaw CJ, Civale J, Botting KJ, Niu Y, Ter Haar G, Rivens I, et al. Noninvasive high-intensity focused ultrasound treatment of twin-twin transfusion syndrome: A preliminary in vivo study. *Science translational medicine*. 2016;8(347):347ra95.
93. Seo K, Ichizuka K, Okai T, Dohi S, Nakamura M, Hasegawa J, et al. Treatment of twin-reversed arterial perfusion sequence using high-intensity focused ultrasound. *Ultrasound in obstetrics & gynecology : the official journal of the International Society of Ultrasound in Obstetrics and Gynecology*. 2019;54(1):128-34.
94. Diehl W, Diemert A, Grasso D, Sehner S, Wegscheider K, Hecher K. Fetoscopic laser coagulation in 1020 pregnancies with twin-twin transfusion syndrome demonstrates improvement in double-twin survival rate. *Ultrasound in obstetrics & gynecology : the official journal of the International Society of Ultrasound in Obstetrics and Gynecology*. 2017;50(6):728-35.

