



Universiteit
Leiden
The Netherlands

Demographics and additional haematologic cancers of patients with histiocytic/dendritic cell neoplasms

Kemps, P.G.; Kester, L.; Scheijde-Vermeulen, M.A.; Noesel, C.J.M. van; Verdijk, R.M.; Diepstra, A.; ... ; Halteren, A.G.S. van

Citation

Kemps, P. G., Kester, L., Scheijde-Vermeulen, M. A., Noesel, C. J. M. van, Verdijk, R. M., Diepstra, A., ... Halteren, A. G. S. van. (2024). Demographics and additional haematologic cancers of patients with histiocytic/dendritic cell neoplasms. *Histopathology*, 84(5), 837-846. doi:10.1111/his.15127











Version: Publisher's Version

License: [Creative Commons CC BY-NC-ND 4.0 license](https://creativecommons.org/licenses/by-nc-nd/4.0/)

Downloaded from: <https://hdl.handle.net/1887/4109098>

Note: To cite this publication please use the final published version (if applicable).

Demographics and additional haematologic cancers of patients with histiocytic/dendritic cell neoplasms

Paul G Kemps,^{1,2}  Lennart Kester,²  Marijn A Scheijde-Vermeulen,² 
Carel J M van Noesel,³  Robert M Verdijk,^{1,4}  Arjan Diepstra,⁵ 
Ariënne M W van Marion,⁶ Natasja Dors,² Cor van den Bos,²  Annette H Bruggink,⁷ 
Pancras C W Hogendoorn¹  & Astrid G S van Halteren^{1,2,8} 

¹Department of Pathology, Leiden University Medical Center, Leiden, ²Princess Máxima Center for Pediatric Oncology, Utrecht, ³Department of Pathology, Amsterdam University Medical Centers, Amsterdam, ⁴Department of Pathology, Erasmus MC University Medical Center Rotterdam, Rotterdam, ⁵Department of Pathology, University Medical Center Groningen, Groningen, ⁶Department of Pathology, VieCuri Medical Center, Venlo, ⁷Palga (Dutch Nationwide Pathology Databank), Houten and ⁸Department of Internal Medicine, Section Clinical Immunology, Erasmus MC University Medical Center Rotterdam, Rotterdam, the Netherlands

Date of submission 12 October 2023

Accepted for publication 13 December 2023

Kemps P G, Kester L, Scheijde-Vermeulen M A, van Noesel C J M, Verdijk R M, Diepstra A, van Marion A M W, Dors N, van den Bos C, Bruggink A H, Hogendoorn P C W & van Halteren A G S

(2024) *Histopathology* 84, 837–846. <https://doi.org/10.1111/his.15127>

Demographics and additional haematologic cancers of patients with histiocytic/dendritic cell neoplasms

Aims: The discovery of somatic genetic alterations established many histiocytic disorders as haematologic neoplasms. We aimed to investigate the demographic characteristics and additional haematologic cancers of patients diagnosed with histiocytic disorders in The Netherlands.

Methods and results: We retrieved data on histiocytosis patients from the Dutch Nationwide Pathology Databank (Palga). During 1993 to 2022, more than 4000 patients with a pathologist-assigned diagnosis of a histiocytic disorder were registered in Palga. Xanthogranulomas were the most common subtype, challenging the prevailing assumption that Langerhans cell histiocytosis (LCH) is the most common histiocytic disorder. LCH and juvenile xanthogranuloma (JXG) had a peak incidence in the first years of life; males were overrepresented among all histiocytosis subgroups. 118 patients had a histiocytic disorder and an additional haematologic malignancy, including 107 (91%) adults at the time of histiocytosis

diagnosis. In 16/118 patients, both entities had been analysed for the same genetic alteration(s). In 11 of these 16 patients, identical genetic alterations had been detected in both haematologic neoplasms. This included two patients with *PAX5* p.P80R mutated B cell acute lymphoblastic leukaemia and secondary histiocytic sarcoma, further supporting that *PAX5* alterations may predispose (precursor) B cells to differentiate into the myeloid lineage. All 4/11 patients with myeloid neoplasms as their additional haematologic malignancy had shared *N/KRAS* mutations.

Conclusions: This population-based study highlights the frequency of xanthogranulomas. Furthermore, our data add to the growing evidence supporting clonal relationships between histiocytic/dendritic cell neoplasms and additional myeloid or lymphoid malignancies. Particularly adult histiocytosis patients should be carefully evaluated for the development of these associated haematologic cancers.

Keywords: bone marrow diseases, bone neoplasms, demography, dendritic cells, histiocytosis, leukaemia, lymphoma

Address for correspondence: P G Kemps, Department of Pathology, Leiden University Medical Center, PO Box 9600, Leiden 2300 RC, the Netherlands. e-mail: p.g.kemps@lumc.nl

© 2024 The Authors. *Histopathology* published by John Wiley & Sons Ltd.

This is an open access article under the terms of the [Creative Commons Attribution-NonCommercial-NoDerivs](https://creativecommons.org/licenses/by-nc-nd/4.0/) License, which permits use and distribution in any medium, provided the original work is properly cited, the use is non-commercial and no modifications or adaptations are made.

Introduction

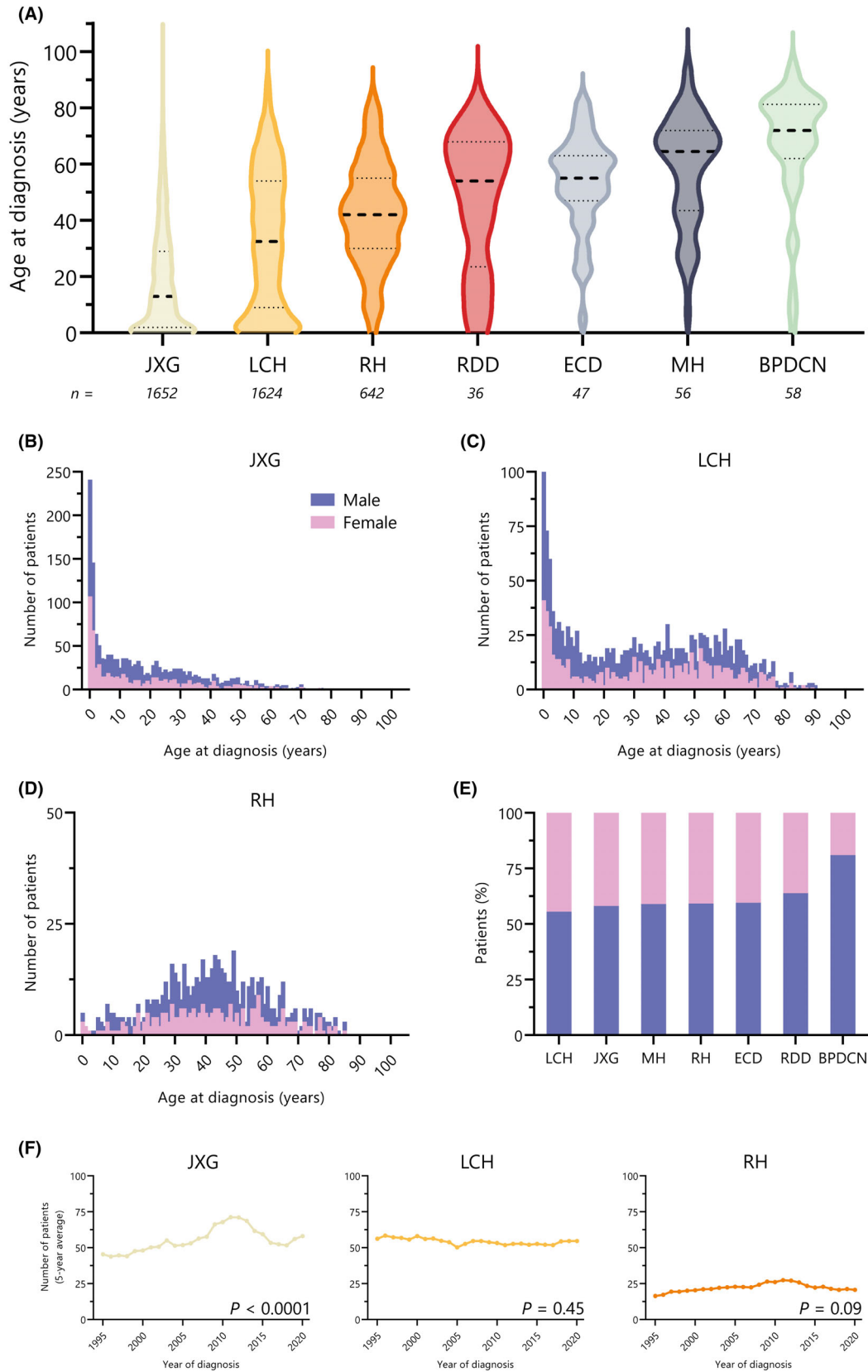
Histiocytic disorders are a group of rare diseases characterized by tissue accumulation of monocyte-, macrophage-, or dendritic cell-differentiated cells.¹ The discovery of somatic genetic alterations established many of these diseases as haematologic neoplasms, which are collectively referred to as histiocytic/dendritic cell neoplasms in the latest World Health Organization (WHO) Classification of Haematolymphoid Tumours.² The genetic alterations often comprise activating mutations in genes of the mitogen-activated protein kinase (MAPK) signalling pathway or in genes encoding for receptor tyrosine kinases.^{3–5} Unfortunately, many histiocytic disorders have not been comprehensively registered by cancer registries (Figure S1), hampering population-based studies of these rare diseases. In The Netherlands, however, a unique digital archive of histo- and cytopathology reports exists, with nationwide coverage from 1991 onwards.^{6,7} Using data from this Dutch Nationwide Pathology Databank (Palga), we investigated the demographic characteristics and additional haematologic cancers of patients diagnosed with diverse histiocytic disorders during 30 years in The Netherlands.

Methods

For this study, we retrieved all pathology reports registered in Palga from 1971 until (and including) 2022 with a pathologist-assigned diagnostic code for one of the various histiocytic disorders. Using the unique Palga pseudonym for each patient, cases with a first pathology report during 1993 until (and including) 2022 were included. Thus, cases with a primary pathologic diagnosis before 1993, but with a histologically-confirmed relapse during or after 1993, were excluded. Diagnostic codes for LCH, juvenile xanthogranuloma (JXG), reticulohistiocytoma (RH), Rosai–Dorfman disease (RDD), Erdheim–Chester disease (ECD), malignant histiocytosis (MH), histiocytic sarcoma (HS), interdigitating dendritic cell sarcoma (IDCS), and blastic plasmacytoid dendritic cell neoplasm (BPDCN) were used and reported previously.⁷ Diagnostic codes for Langerhans cell sarcoma (LCS),

indeterminate dendritic cell histiocytosis or ALK-positive histiocytosis are not available in Palga. Diagnostic codes for xanthogranuloma/xanthogranulomatous inflammation/lipogranuloma (SNOMED CT 448285003) and (fibrosing) histiocytosis (SNOMED CT 60657004) were considered too aspecific and therefore excluded. Unlike other dendritic cell neoplasms (e.g. LCH), BPDCN is not always considered part of histiocytic disorders.¹ For example, BPDCN is classified separately from the group of histiocytic/dendritic cell neoplasms in the International Consensus Classification.⁸ Yet it is classified within the group of histiocytic/dendritic cell neoplasms in the latest WHO classification²; therefore, we considered BPDCN as a histiocytosis subtype and included it in our study. HS and IDCS are histologic variants of MH¹; therefore, they were grouped together with MH. Similarly, RH is a subtype of xanthogranuloma¹; therefore, JXG and RH were also grouped together in certain analyses. Demographic analyses were performed for JXG and RH separately (Figure 1), and for JXG/RH diagnosed during child- or adulthood (Figure S2). For MH/HS/IDCS (hereafter collectively referred to as MH), only patients diagnosed from 2002 until (and including) 2022 were included, because prior diagnoses often constitute misdiagnosed lymphomas.⁷ Using the Palga pseudonym, we also retrieved all additional pathology reports of included patients issued during 1993–2022 with a pathologist-assigned diagnostic code for any haematologic malignancy. Consistent with prior literature,⁹ any haematologic malignancy other than a histiocytic disorder was considered an “additional” or “associated” haematologic malignancy; those diagnosed after the date of histiocytosis diagnosis were termed “second” or “secondary” cancers. The terms “transformation” and “transdifferentiation” were considered to implicate a clonal relationship between neoplasms. Manual review was performed of all pathology reports of patients with a registered diagnosis of a rare histiocytosis (ECD, RDD, MH, or BPDCN), patients with diagnostic codes for two or more histiocytoses, and patients with a registered diagnosis of an additional haematologic malignancy. Given the large number of identified cases, a manual review of pathology reports of all patients with a registered diagnosis of LCH or JXG/RH was not feasible; therefore, these diagnoses were assumed accurate.

Figure 1. Demographics of Dutch histiocytosis patients. (A) Violin plot showing age at diagnosis of patients with diverse histiocytosis subtypes. Thick dashed lines indicate medians; thin dotted lines indicate interquartile ranges. (B–D) Numbers of patients with JXG, LCH, or RH by age at diagnosis and sex. The number of male and female patients (per age at diagnosis) are stacked. (E) Proportions of male and female patients by histiocytosis subtype. Numbers of patients are depicted in panel A. (F) Five-year moving averages of the numbers of patients diagnosed with JXG, LCH, or RH each year.



Trends over time in LCH, JXG, or RH frequency were evaluated by Poisson regression; correlations between patients' age at histiocytosis diagnosis and their age at diagnosis of the additional haematologic malignancy were evaluated by linear regression. Information on molecular analyses was retrieved from pathology reports; for specific cases of interest, detailed molecular results and tissue slides were obtained from the relevant pathology department through the "Palga intermediary procedure",¹⁰ as described previously.⁷ This study was approved by the Palga Scientific Council and Privacy Committee (LZV-2016-183) and the Institutional Review Board of Leiden University Medical Center (B19.074); the requirement for informed consent was waived.

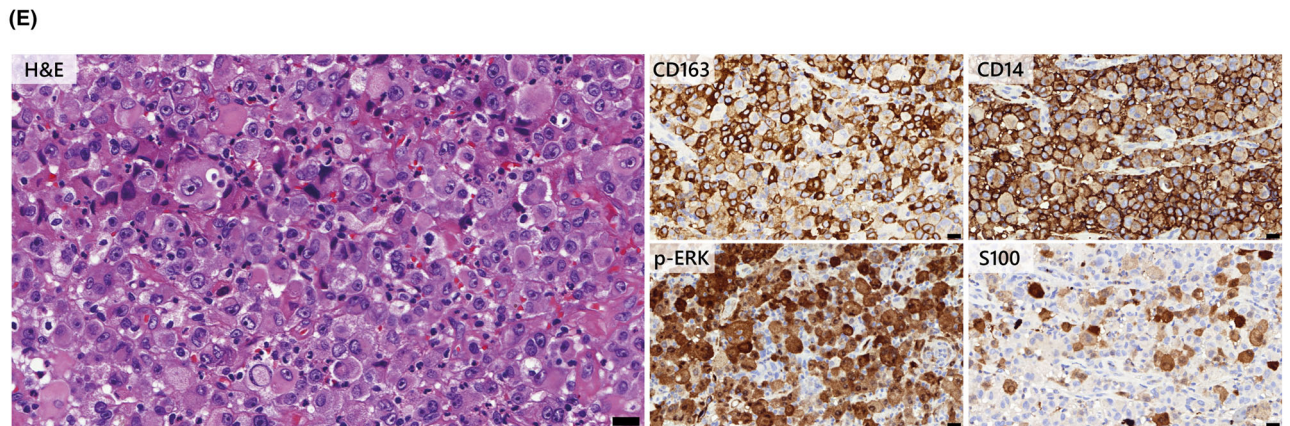
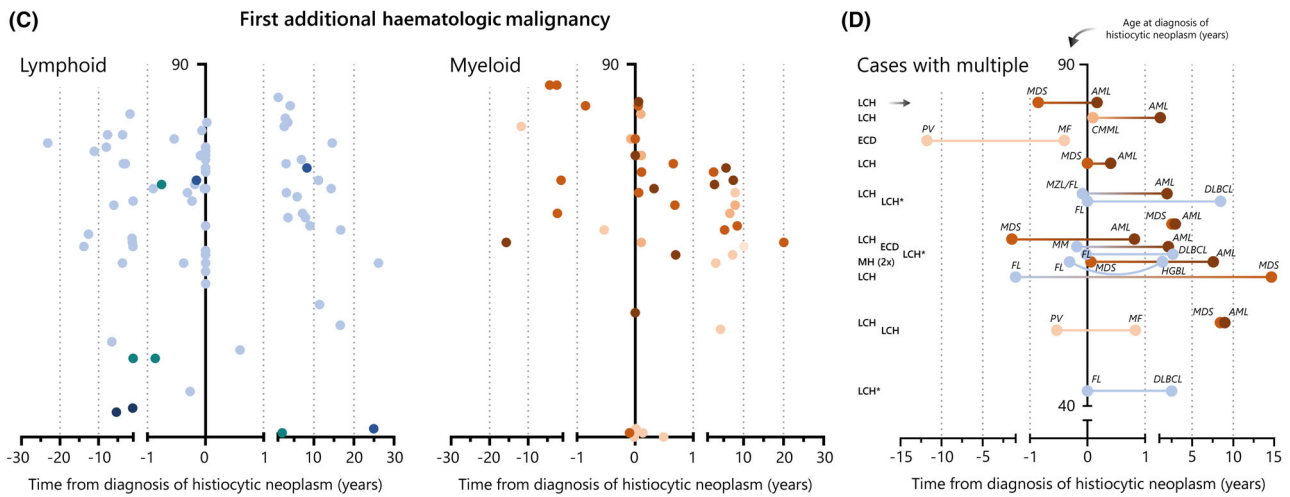
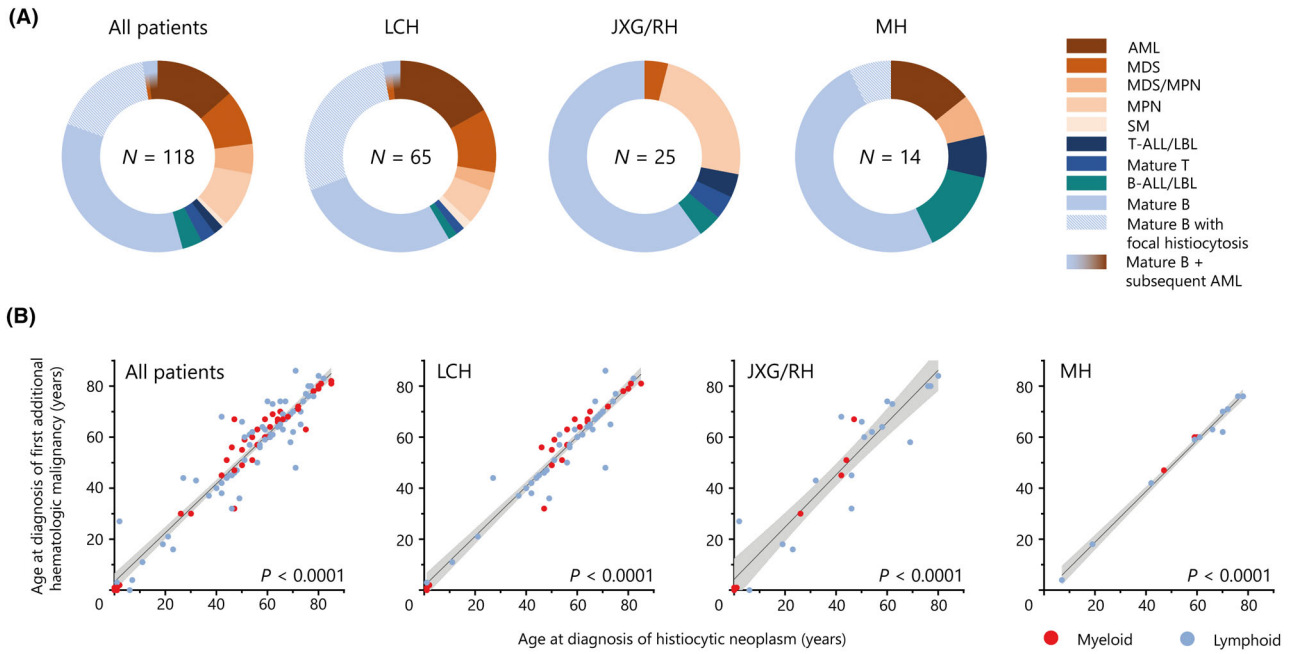
Results

We identified 1652 patients with a registered diagnosis of JXG, 1624 with LCH, 642 with RH, 58 with BPDCN, 56 with MH, 47 with ECD, and 36 with RDD (Figure 1A). Among patients with MH, the disease was described by pathologists as HS in 48/56 patients and IDCS in 5/56 patients, whereas an indeterminate cell phenotype was noted in two cases and an RDD phenotype was reported in one case.¹¹ The median age at diagnosis was 13 years (interquartile range [IQR]: 2–29) for JXG, 32.5 years (IQR: 9–54) for LCH, 42 years (IQR: 30–55) for RH, 54 years (IQR: 23.5–68) for RDD, 55 years (IQR: 47–63) for ECD, 64.5 years (IQR: 43.5–72) for MH, and 72 years (IQR: 62–81.25) for BPDCN (Figure 1A). When combining JXG and RH (as xanthogranuloma family lesions¹), the median age at diagnosis of this subgroup of patients was 22 years (IQR: 5–41). Thus, across major histiocytosis subgroups, most patients were diagnosed at adult age. Yet, there was a peak incidence of LCH and JXG in the first years of life (Figure 1B–D). Among all histiocytosis subgroups, males were (slightly) overrepresented, ranging from

55.5% of patients with LCH to 81.0% of patients with BPDCN (Figure 1E). The number of patients diagnosed with LCH each year was stable during 1993 to 2022 ($P = 0.45$), whereas the number of patients diagnosed with JXG increased over time ($P < 0.0001$; Figure 1F). The number of patients diagnosed with RH each year appeared to slightly increase, but this was not statistically significant ($P = 0.09$). When investigating time trends in the frequency of paediatric or adult xanthogranuloma, both were statistically significant (Figure S2F). Diagnostic codes for other histiocytoses were mostly assigned in recent years, with $\geq 50\%$ of patients with ECD diagnosed in 2014 or later, $\geq 50\%$ of patients with MH diagnosed in 2017 or later, and $\geq 50\%$ of patients with RDD or BPDCN diagnosed in 2018 or later.

Among this cohort of histiocytosis patients, 118 patients with a histologically-confirmed additional haematologic malignancy were identified (Figure 2A). This group included 65 patients with LCH, 25 with JXG/RH, 14 with MH, eight with BPDCN, three with ECD, two with RDD, and one with mixed LCH/ECD. The 118 patients had diverse additional haematologic malignancies, including lymphoid cancers in 70 (59%) cases, additional myeloid cancers in 45 (38%) cases, and both in three (3%) cases. Notably, 20 (17%) patients had a mature B-cell lymphoma with an accompanying histiocytic lesion in the same tissue sample,¹² which was assigned by the pathologist as LCH in 18/20 patients, and RDD or MH (Figure S3) in single cases. Strikingly, 107/118 (91%) patients were adults at the time of histiocytosis diagnosis. The median age at histiocytosis diagnosis was 59 years (range: 0–85); the median age at diagnosis of the (first-occurring) additional haematologic malignancy was 61 years (range: 0–86). Across histiocytosis subtypes, there was a strong correlation ($P < 0.0001$) between the patients' age at histiocytosis diagnosis and their age at diagnosis of the additional haematologic malignancy (Figure 2B). However, this analysis was limited by selection bias, given that only

Figure 2. Histiocytosis patients with additional haematologic malignancies. (A) Pie charts depicting the types of additional haematologic malignancies for the overall cohort and major histiocytosis subgroups. For the seven histiocytosis patients with AML after prior MDS or CMML, the AML is depicted. (B) Scatterplots depicting age at histiocytosis diagnosis and age at diagnosis of the first-occurring additional haematologic malignancy for all patients and major histiocytosis subgroups. (C) Scatterplots depicting the time between the diagnosis of the histiocytic neoplasm and the diagnosis of the first-occurring additional haematologic malignancy on the *x*-axis, as well as the patients' age at histiocytosis diagnosis on the *y*-axis. Dots are coloured according to the colour coding depicted in panel A. (D) Scatterplot depicting the 16 histiocytosis patients with multiple additional haematologic malignancies. *These cases had a mature B-cell lymphoma with an accompanying histiocytic lesion in the same tissue sample.¹² (E) Photomicrographs of haematoxylin and eosin (H&E), CD163, CD14, phosphorylated-ERK (p-ERK), and S100 stained tissue slides of the histiocytic sarcoma of Case #7. Shown are atypical cells with large round to oval nuclei, prominent nucleoli, and eosinophilic cytoplasm. Some cells are multinucleated, and there is focal emperipolesis. The atypical cells are strongly positive for CD163, CD14, and p-ERK. S100 stained a minor subset of atypical cells; shown is an area with a relatively high number of positive cells. All photomicrographs were taken at 40 \times ; the black bars in the bottom right corners indicate 20 μ m.



additional malignancies occurring within the study period (i.e. a maximum of 30 years before or after the histiocytosis) were captured. This selection bias results in an overestimation of the association. Regarding lymphoid cancers, 5/6 lymphoblastic leukaemias presented before the histiocytic neoplasm (Figure 2C), and mature B-cell lymphomas were diagnosed on or before the date of the histiocytosis diagnosis in 42/64 (66%) cases (Figure 2C). In contrast, 33/45 (73%) patients with myeloid cancer as their first additional haematologic malignancy received this diagnosis on or after the date of histiocytosis diagnosis (Figure 2C). Finally, 16 patients had multiple additional haematologic malignancies, including nine with secondary acute myeloid leukaemia (Figure 2D). In many cases, the second additional cancer concerned a higher-grade variant.

In 16/118 histiocytosis patients with an additional haematologic malignancy, both entities were analysed for the same genetic alteration(s). The majority of these 16 patients had been diagnosed with histiocytosis during or after 2017. In 11 patients, identical genetic alterations were identified in both haematologic neoplasms (Table 1). Six of these 11 patients have been reported previously.^{7,13–15} The remaining five cases comprised one patient with *KRAS* p.G12A mutated ECD and chronic myelomonocytic leukaemia and four patients with MH and B-lineage lymphoid cancers harbouring identical immunoglobulin gene rearrangements (Figures S3–S6). In one case (Case #7) of a 19-year-old male with B-cell acute lymphoblastic leukaemia (B-ALL) and secondary HS (Figure 2E), identical *NRAS* p.G12V and *PAX5* p.P80R mutations were also detected in the B-ALL and HS. Furthermore, several genetic alterations unique to the HS (*BRAF* p.G469R, *BRAF* p.D594N, and *MTOR* p.S2215Y) were detected. Similarly, in another patient (Case #8) with a mature B-cell lymphoma and secondary HS harbouring identical immunoglobulin gene rearrangements, a *KRAS* p.A146T mutation was detected in the HS, but not in the prior lymphoma.

Discussion

Our study, based on the Dutch Nationwide Pathology Databank, provides an unbiased look into the demographic characteristics and additional haematologic cancers of patients with histiocytic disorders in The Netherlands. Because the underlying cause of histiocytoses has been a decades-long enigma, and the question of whether (specific) histiocytic/dendritic neoplasms represent cancers or not remains a matter

of debate, many histiocytic disorders have not been comprehensively registered by cancer registries. These registries are generally based on the International Classification of Diseases for Oncology (ICD-O), which in turn is based on the WHO Classifications of Tumours. In the latest ICD-O classification (v. 3.2, published in 2019), disseminated LCH, ECD, MH, HS, LCS, IDCS, and BPDCN are classified as malignant diseases (Figure S1). Nondisseminated LCH was classified as “malignant” in the previous classification (ICD-O-3.1, published in 2013), but is no longer assigned malignant behaviour in ICD-O-3.2. Thus, the much-welcomed registration of the entire spectrum of LCH in cancer registries was only short-lived.¹⁶ Likewise, JXG/RH and RDD are not classified as “malignant”, and therefore not registered by cancer registries. Although there may be valid arguments against classification of all histiocytoses as *bona fide* cancers (e.g. their mild clinical manifestation or limited biological hallmarks of cancer), this lack of comprehensive registration of these rare diseases is highly unfortunate. Similarly, inconsistent terminology of histiocytic disorders has been hindering the field; therefore, we advocate for standardization of classification systems and nomenclature to increase awareness and advance research on these rare conditions.

Using the unique Dutch Nationwide Pathology Databank, we were able to get an impression of the frequency of histiocytic disorders and the demographics of patients with these diseases. We observed a peak incidence of LCH and JXG in the first years of life, as previously noted for LCH in national registry studies from England¹⁶ and France.¹⁷ In contrast to common assumption,¹⁸ JXG and not LCH was the most common histiocytic disorder. It should be noted that pathologists have also assigned the JXG diagnostic code to adults with xanthogranulomas (Figure 1A). Considering that both JXG and RH represent xanthogranulomas,¹ it is evident that xanthogranulomas occurred more frequently than LCH. The observed male overrepresentation across histiocytosis subgroups is in accordance with previous cohort studies,^{5,15,16,19} with the extreme male predominance in BPDCN recently linked to X chromosomal mutations in *ZRSR2*.²⁰ The underlying mechanisms in other histiocytoses remain to be defined. Finally, the fact that 65/1652 patients with LCH compared to 25/2294 patients with JXG/RH had an additional haematologic malignancy suggests that specific histiocytoses may be more associated with second haematologic cancers than others, although the absence of follow-up data in the Dutch Nationwide Pathology Databank precludes a conclusive analysis.

TABLE 1. Histiocytic disorders and additional haematologic malignancies analysed for the same genetic alteration(s)

Case	Histologic presentation	Histiocytic neoplasm (age at diagnosis)	Additional malignancy (age at diagnosis)	Shared genetic alteration(s)	Unique genetic alteration(s)	Findings supporting a clonal relationship	Reference
1	Both	ECD (61)	AML (63)*	• <i>NRAS</i> ^{Q61R}	–	Yes	7
2	Separate	ECD (54)	CMML (60)	• <i>KRAS</i> ^{G12A}	–	Yes	–
3	Separate	ICH (68)	CMML (68)	• <i>NRAS</i> ^{G12V}	ICH (relapse [†]): <i>BRAF</i> ^{L597R}	Yes	7
4	Both	HS (47)	CMML (47)	• <i>KRAS</i> ^{A59E}	HS: <i>MAP2K1</i> ^{F53L} , and <i>RAF1</i> ^{S257L}	Yes	7
5	Separate	Non-LCH/HS (7)	T-ALL (4)	• <i>TRB</i> and <i>TRG</i> rearrangements • <i>CDKN2A</i> mono-allelic loss • <i>ACACB</i> ^{A507T} , <i>ARHGEF11</i> (5' UTR C>T), <i>IGFN1</i> ^{G12V} , <i>MEIS1</i> ^{G64G} , <i>ODAM</i> ^{R22H} and <i>PPP5C</i> ^{D453N}	T-ALL: <i>TRB</i> DJ rearrangement; bi-allelic <i>CDKN2A</i> loss non-LCH: 32 Mb deletion on chromosome 8q (<i>MYC</i>) HS: gains of parts of chromosomes 5p-q, 11p, 21q, and 22q; <i>C6orf211</i> ^{R1231} and <i>KIAA1644</i> ^{R49W}	Yes	13
6	Separate	HS (61)	B-ALL (60)	• <i>IGH</i> and <i>IGK</i> rearrangements • <i>KRAS</i> ^{G12D} • <i>CDKN2A</i> loss [‡] • <i>PAX5</i> ^{P80R} & <i>PAX5</i> loss	HS: <i>RAF1</i> ^{R391W} B-ALL: <i>CDKN2A</i> ^{V51fs} , <i>NRAS</i> ^{G13R} , and multiple <i>PTPN11</i> mutations	Yes	14
7	Separate	HS (19)	B-ALL (18)	• <i>IGH</i> rearrangements • <i>NRAS</i> ^{G12V} • <i>PAX5</i> ^{P80R}	HS (after disease progression): <i>BRAF</i> ^{G469R} (calcaneus), <i>BRAF</i> ^{D594N} (iliac bone), and <i>MTOR</i> ^{S2215Y} (iliac bone) B-ALL: <i>CDKN2A</i> and <i>PAX5</i> loss [§]	Yes	–
8	Separate	HS (72)	B-NHL, NC (71)	• <i>IGH</i> and <i>IGK</i> rearrangements	HS: <i>KRAS</i> ^{A146T}	Yes	–
9	Separate	HS (66) [¶]	B-NHL, NC (63) [¶]	• <i>IGH</i> and <i>IGK</i> rearrangements	–	Yes	–
10	Intermixed	IDCS (70)	SLL/CLL (70)	• <i>IGH</i> and <i>IGK</i> rearrangements	–	Yes	–
11	Separate	LCH (53)	DLBCL (57)	• <i>IGH</i> rearrangements	LCH: <i>BRAF</i> ^{V600E} DLBCL: <i>BCL2</i> translocation, <i>CARD11</i> ^{S250P} , <i>CREBBP</i> ^{R1446L} , <i>MYD88</i> ^{S219C} , and <i>TP53</i> ^{R282W}	Yes	15
12	Separate	LCH (61)	AML (64)	–	LCH: <i>BRAF</i> ^{V600E}	No	–
13	Separate	LCH (56)	MDS (57)	• <i>CBL</i> p.R420Q (potentially)**	LCH: <i>BRAF</i> ^{V600E}	Potentially	–
14	Separate	BPDCN (65)	CD30 ⁺ ALK ⁻ ALCL (74)	–	BPDCN: <i>TET2</i> ^{R1214W} and <i>TET2</i> ^{R1216*} , and <i>SRSF2</i> ^{P95L} ALCL: <i>TRB</i> and <i>TRG</i> rearrangements, <i>NF1</i> (c.4835+1G>A; p.(?)), <i>SMC3</i> ^{R99*} , and an <i>IRF4::DUSP22</i> (6p25.3) translocation ^{††}	No	–
15	Both	HS (42)	SLL/CLL (42)	–	HS: <i>KRAS</i> ^{Q61H}	No	–
16	Separate	HS (59)	FL (59) and HGBL (61)	–	FL and HGBL: <i>BCL2</i> translocation	No	7 ^{†††}

TABLE 1. (Continued)

ICH, Indeterminate cell histiocytosis; AML, Acute myeloid leukaemia; CMML, Chronic myelomonocytic leukaemia; T-ALL, T-cell acute lymphoblastic leukaemia; B-NHL, B-cell non-Hodgkin lymphoma; NC, Not classifiable; SLL/CLL, Small lymphocytic lymphoma/chronic lymphocytic leukaemia; DLBCL, Diffuse large B-cell lymphoma; MDS, Myelodysplastic syndrome; ALCL, Anaplastic large-cell lymphoma; FL, Follicular lymphoma; HGBL, High-grade B-cell lymphoma; VAF, Variant allele frequency; WES, Whole-exome-sequencing; WTS, Whole-transcriptome-sequencing; NGS, Next-generation-sequencing.

*This patient was initially diagnosed with concurrent ECD and multiple myeloma. Molecular analysis of the multiple myeloma was precluded by the absence of cryopreserved material.⁷

[†]Novel finding, not described in the prior study.⁷

[‡]In the HS sample, bi-allelic loss of *CDKN2A* was detected. In the B-ALL sample, mono-allelic loss of *CDKN2A* was detected, but it could not be excluded that bi-allelic loss was present in a small subclone.

[§]The following aberrations were detected in the B-ALL by karyotyping/SNP-array: del(9p), gain(20p), and aUPD(20q). *CDKN2A* and *PAX5* are both located on chromosome 9p. The deletion of 9p21.3 (*CDKN2A*) was homozygous. The region with copy number loss at 9p24.3-p13.1 was 39 Mb in size, partially homozygous, and in ~80% present as a mosaic genetic alteration. Similarly, the copy number alterations of 20p13-p11.1 (26 Mb) and 20q11.21-q13.33 (34 Mb) were ~80% present as mosaic genetic alterations. The HS samples were not tested by karyotyping/SNP-array, but no *PAX5* or *CDKN2A* loss was detected by WES of an iliac bone sample taken after disease progression. In this iliac bone sample, however, the VAF of the *NRAS* p.G12V mutation was 1% by WES (and 14% by WTS), compared to 12% in the diagnostic HS sample and 40% in a calcaneus HS biopsy by DNA-NGS. Thus, it cannot be ruled out that the copy number losses of *CDKN2A* and *PAX5* were also present in the HS.

[¶]Although the morphology and immunophenotype supported a diagnosis of histiocytic sarcoma (Figure S4), the very high proliferation index was unusual and raised concern for a more immature neoplasm/myeloid sarcoma. Regarding the B-NHL, considered subtypes were hairy cell leukaemia variant, splenic diffuse red pulp small B-cell lymphoma/leukaemia, and (leukaemic) splenic marginal zone lymphoma.

**The *CBL* p.R420Q mutation was detected with a VAF of 11% in the LCH diagnostic bone marrow biopsy. In this tissue sample, a *BRAF* p.V600E mutation was also detected with a VAF of 4.5%. The same *CBL* p.R420Q mutation, but not the *BRAF* p.V600E mutation, was subsequently detected in the diagnostic MDS bone marrow biopsy, with a VAF of 16%. Thus, the *BRAF* mutated LCH-cells might have originated from the *CBL* mutated haematopoietic clone, but the absence of cryopreserved material precluded molecular analysis of sorted LCH-cells to confirm this.

^{††}The BPDCN was not tested for the *DUSP22* translocation. Furthermore, the pathogenic *TET2* and *SRSF2* variants were detected with low variant allele frequencies (<5%) in the ALCL sample and therefore considered to derive from blood admixture. Lastly, identical variants of unknown significance in *NF1* and *STAG2* were detected in both the BPDCN and ALCL.

^{‡‡‡}Cases 5–9 from this prior study⁷ are not depicted because only the LCH sample was molecularly analysed (Case 5), or because the specimen that was molecularly analysed contained both the histiocytic lesion and associated lymphoma (Cases 6–9), without selection for a specific cell population.

The detection of identical genetic alterations in histiocytic/dendritic cell neoplasms and additional myeloid or lymphoid cancers strongly suggests a shared clonal origin of these haematologic diseases (Table 1). Both entities may derive from a common progenitor, such as haematopoietic stem cells with clonal haematopoiesis of indeterminate potential (CHIP)-associated mutations in cases with second myeloid cancers.¹⁹ Alternative mechanisms are dedifferentiation or transdifferentiation of lineage-committed haematopoietic cells,⁷ which may occur in cases with lymphoid malignancies and secondary (malignant) histiocytoses.²¹ Interestingly, we report the second case of *PAX5* p.P80R mutated B-ALL and secondary histiocytic sarcoma, further supporting that *PAX5* alterations may predispose (precursor) B cells to differentiate into the myeloid lineage.^{14,22} Furthermore, the frequent observation of shared *N/KRAS* mutations is remarkable (Table 1), suggesting that patients with activating mutations in these oncogenes may be particularly at risk of developing clonally related second cancers.⁷ In addition to shared genetic alterations, several

mutations unique to either the histiocytic/dendritic cell neoplasm or associated haematologic malignancy were detected—which might have contributed to the transformation to the secondary neoplasm (Table 1). In accordance with previous observations,⁷ these unique alterations often comprised MAPK gene alterations in the histiocytic/dendritic cell neoplasms.

There are several limitations to our study.⁷ First, pathologists may assign incorrect or nonspecific diagnostic codes to pathology reports. Particularly for rare histiocytosis subtypes (e.g. ECD and RDD), our study certainly does not include all patients in The Netherlands during the 30-year period. This is also influenced by nomenclature changes and gradually improved recognition of these rare entities. Specifically, the diagnosis of ECD requires the integration of xanthogranuloma histology, together with appropriate clinical and radiographic findings (and preferably molecular support). Hence, in the absence of clinical and radiographic information, pathological specimens of patients with ECD might have been incorrectly assigned as JXG/RH. Furthermore, haematological malignancies are not always histologically

confirmed, and thus included in the Dutch Nationwide Pathology Databank. Finally, this databank does not contain data on clinical features, treatment, and survival of patients.

Conclusion

Our study highlights the frequency of xanthogranuloma family lesions (JXG/RH), which are not registered by cancer registries. Furthermore, our data add to the growing evidence supporting clonal relationships between histiocytic/dendritic cell neoplasms and additional myeloid or lymphoid malignancies. Future studies should identify which histiocytosis patients are at high risk of developing these associated haematologic cancers.⁹

Acknowledgements

We thank Sharon Thijssen (Maastricht University Medical Center) and Monique Ursem-Oud (Amsterdam University Medical Centers) for providing plots of immunoglobulin gene rearrangement PCR assays performed in their institutions.

Author contributions

PGK, PCWH, and AGSH wrote the Palga study protocol. PGK analysed the dataset, drafted the article, and made the figures and tables. LK, MAS-V, CJMN, RMV, AD, AMWM, ND, and CB were involved in the (molecular) pathologic evaluation or clinical care of reported patients. AHB helped in selecting the Palga search strategy and assisted in the Palga intermediary procedure. PCWH and AGSH supervised the study and revised the drafted article. All authors approved the final version of the article.

Funding information

Paul G. Kemps received an MD/PhD grant from Leiden University Medical Center.

Conflict of interest

All authors declare no competing interests.

Data availability statement

Original data are available upon reasonable request from the corresponding author.

References

- Emile J-F, Abla O, Fraitag S *et al.* Revised classification of histiocytoses and neoplasms of the macrophage-dendritic cell lineages. *Blood* 2016; **127**: 2672–2681.
- Khouri JD, Solary E, Abla O *et al.* The 5th edition of the World Health Organization classification of haematolymphoid tumours: myeloid and histiocytic/dendritic neoplasms. *Leukemia* 2022; **36**: 1703–1719.
- Durham BH, Lopez Rodrigo E, Picarsic J *et al.* Activating mutations in CSF1R and additional receptor tyrosine kinases in histiocytic neoplasms. *Nat. Med.* 2019; **25**: 1839–1842.
- Kemps PG, Picarsic J, Durham BH *et al.* ALK-positive histiocytosis: a new clinicopathologic spectrum highlighting neurologic involvement and responses to ALK inhibition. *Blood* 2022; **139**: 256–280.
- Kemps PG, Zondag TCE, Arnardóttir HB *et al.* Clinicogenomic associations in childhood Langerhans cell histiocytosis: an international cohort study. *Blood Adv.* 2023; **7**: 664–679.
- Casparie M, Tiebosch ATMG, Burger G *et al.* Pathology databanking and biobanking in The Netherlands, a central role for PALGA, the nationwide histopathology and cytopathology data network and archive. *Cell. Oncol.* 2007; **29**: 19–24.
- Kemps PG, Hebeda KM, Pals ST *et al.* Spectrum of histiocytic neoplasms associated with diverse haematological malignancies bearing the same oncogenic mutation. *J. Pathol. Clin. Res.* 2021; **7**: 10–26.
- Arber DA, Campo E, Jaffe ES. Advances in the classification of myeloid and lymphoid neoplasms. *Virchows Arch.* 2023; **482**: 1–9.
- Bagnasco F, Zimmermann SY, Egeler RM *et al.* Langerhans cell histiocytosis and associated malignancies: a retrospective analysis of 270 patients. *Eur. J. Cancer* 2022; **172**: 138–145.
- Verjans R, Bruggink AH, Kibbelaar R *et al.* The Dutch National TissueArchive Portal enables efficient, consistent, and transparent procurement of diagnostic tissue samples for scientific use. *Cell Tissue Bank.* 2021; **22**: 727–736.
- Ravindran A, Dasari S, Ruan GJ *et al.* Malignant histiocytosis comprises a phenotypic spectrum that parallels the lineage differentiation of monocytes, macrophages, dendritic cells, and Langerhans cells. *Mod. Pathol.* 2023; **36**: 100268.
- Pina-Oviedo S, Medeiros LJ, Li S *et al.* Langerhans cell histiocytosis associated with lymphoma: an incidental finding that is not associated with BRAF or MAP2K1 mutations. *Mod. Pathol.* 2017; **30**: 734–744.
- Waanders E, Hebeda KM, Kamping EJ *et al.* Independent development of lymphoid and histiocytic malignancies from a shared early precursor. *Leukemia* 2016; **30**: 955–958.
- Kroeze LI, Scheijen B, Hebeda KM *et al.* PAX5 P80R-mutated B-cell acute lymphoblastic leukemia with transformation to histiocytic sarcoma: clonal evolution assessment using NGS-based immunoglobulin clonality and mutation analysis. *Virchows Arch.* 2023; **483**: 105–110.
- Acosta-Medina AA, Kemps PG, Zondag TCE *et al.* BRAF V600E is associated with higher incidence of second cancers in adults with Langerhans cell histiocytosis. *Blood* 2023; **142**: 1570–1575.
- Liu H, Stiller CA, Crooks CJ *et al.* Incidence, prevalence and survival in patients with Langerhans cell histiocytosis: a national registry study from England, 2013–2019. *Br. J. Haematol.* 2022; **199**: 728–738.
- Donadieu J, Héritier S. Histiocytose langerhansienne de l'enfant. *Presse Med.* 2017; **46**: 85–95.

18. Allen CE, Merad M, McClain KL. Langerhans-cell histiocytosis. *N. Engl. J. Med.* 2018; **379**: 856–868.
19. Cohen Aubart F, Roos-Weil D, Armand M *et al.* High frequency of clonal hematopoiesis in Erdheim-Chester disease. *Blood* 2021; **137**: 485–492.
20. Togami K, Chung SS, Madan V *et al.* Sex-biased ZRSR2 mutations in myeloid malignancies impair plasmacytoid dendritic cell activation and apoptosis. *Cancer Discov.* 2022; **12**: 522–541.
21. Feldman AL, Arber DA, Pittaluga S *et al.* Clonally related follicular lymphomas and histiocytic/dendritic cell sarcomas: evidence for transdifferentiation of the follicular lymphoma clone. *Blood* 2008; **111**: 5433–5439.
22. Coorens THH, Collord G, Treger TD *et al.* Clonal origin of KMT2A wild-type lineage-switch leukemia following CAR-T cell and blinatumomab therapy. *Nat. Cancer* 2023; **4**: 1095–1101.

Supporting Information

Additional Supporting Information may be found in the online version of this article:

Figure S1. Classification of histiocytic disorders in the ICD-O.

Figure S2. Main figure with JXG/RH segregated into paediatric or adult xanthogranuloma.

Figure S3. Histologic and molecular findings in Case #10.

Figure S4. Histologic findings in Case #9.

Figure S5. Molecular findings in Case #9.

Figure S6. Molecular findings in Case #8.