



Universiteit  
Leiden  
The Netherlands

## **POCUS series: E-point septal separation, a quick assessment of reduced left ventricular ejection fraction in a POCUS setting**

Boon, S.C.; Matta, J.E.L.; Kraemer, C.V.E.; Tuinman, P.R.; Westerloo, D.J. van

### **Citation**

Boon, S. C., Matta, J. E. L., Kraemer, C. V. E., Tuinman, P. R., & Westerloo, D. J. van. (2020). POCUS series: E-point septal separation, a quick assessment of reduced left ventricular ejection fraction in a POCUS setting. *Netherlands Journal Of Critical Care*, 28(3), 139-141. Retrieved from <https://hdl.handle.net/1887/3278251>

Version: Publisher's Version

License: [Licensed under Article 25fa Copyright Act/Law \(Amendment Taverne\)](#)

Downloaded from: <https://hdl.handle.net/1887/3278251>

**Note:** To cite this publication please use the final published version (if applicable).

# POCUS series: E-point septal separation, a quick assessment of reduced left ventricular ejection fraction in a POCUS setting

S.C. Boon<sup>1</sup>, J.E. López Matta<sup>1,2</sup>, C.V. Elzo Kraemer<sup>1,2</sup>, P.R. Tuinman<sup>2,3</sup>, D.J. van Westerloo<sup>1,2</sup>

<sup>1</sup> Department of Intensive Care, Leiden University Medical Center, Leiden University, Leiden, the Netherlands,

<sup>2</sup> Amsterdam Leiden Intensive Care Focused Echography (ALIFE)

<sup>3</sup> Department of Intensive Care, Amsterdam UMC, Vrije Universiteit Amsterdam, Amsterdam, the Netherlands

## Correspondence

D. van Westerloo - djvanwesterloo@lumc.nl

**Keywords** - ultrasound, EPSS, ejection fraction, heart failure, POCUS

## Abstract

In the last decade ultrasound has found its place in the intensive care unit. Initially ultrasound was used primarily to increase safety and efficacy of line insertion but now many intensivists use point-of-care ultrasound (POCUS) to aid in diagnosis, assessment of therapy and therapeutic interventions. In this series we aim to highlight one specific POCUS technique at a time, which we believe will prove to be useful in your clinical practice. In this issue our aim is to provide you with a short and practical description of the measurement of E-point septal separation to identify a severely reduced left ventricular ejection fraction.

## Introduction

Point-of-care ultrasound (POCUS) is increasingly adopted by emergency physicians and intensivists to assess cardiac function in patients admitted to the ICU or emergency department. Initially, ultrasound was used primarily to increase safety and efficacy of line insertions but now many intensivists use POCUS to aid in diagnosis, assessment of therapy and therapeutic interventions.<sup>[1]</sup> This article is part of the POCUS series in the Netherlands Journal of Critical Care, in which we aim to highlight POCUS techniques that will improve decision-making in daily clinical practice on the ICU. We aim to provide intensivists with an overview of easy, quick and reliable methods which may be useful in their practice and in this issue we will focus on a simple, albeit quick and dirty technique to assess left ventricular ejection fraction (LVEF) in patients admitted to the ICU.

An estimate of LVEF is of great importance in patients admitted to the ICU since decreased LVEF directly impacts on clinical management. Several parameters are readily available to help intensivists determine whether a patient is in shock, such as physical examination, plasma lactate and SvO<sub>2</sub>. However, none

of these parameters in themselves are diagnostic as to the cause of shock and therefore ultrasound is frequently used to image the heart with the goal to identify patients suffering from heart failure as a cause for shock.

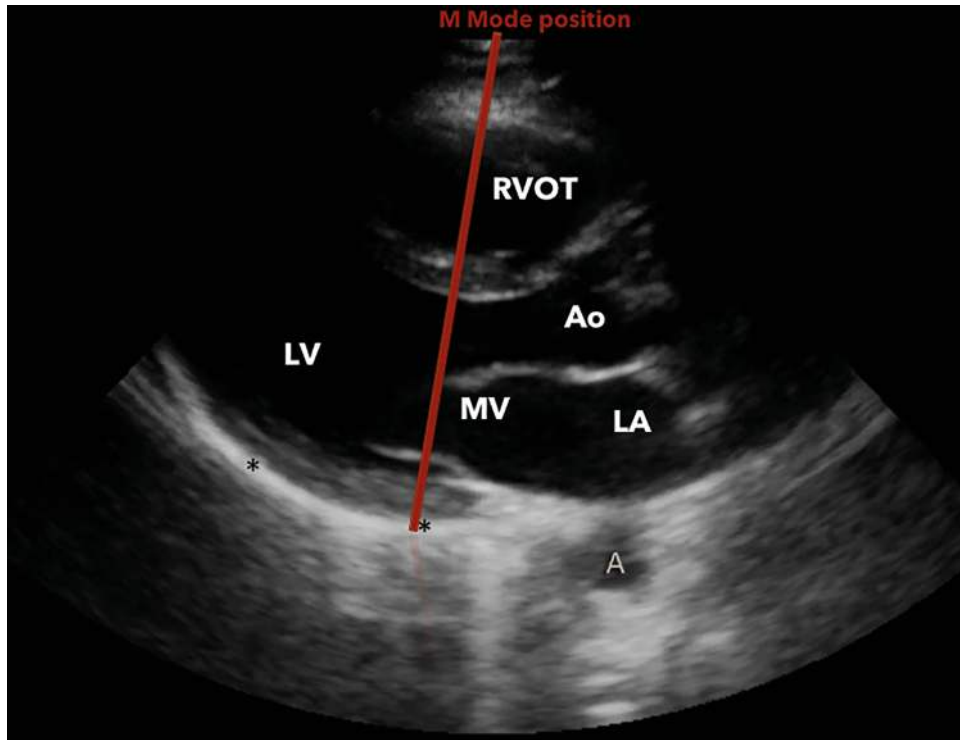
When performing cardiac ultrasound several measurements can be performed to roughly estimate LVEF, such as 'eyeballing', the Simpson method or measurement of mitral annular plane systolic excursion (MAPSE). Clinicians often 'eyeball' the left ventricle in order to estimate the LVEF. Eyeballing has several important pitfalls since it is known that although it may be a reliable way of estimating LVEF in trained and experienced observers, such as cardiologists, it is quite unreliable in inexperienced observers, which intensivists frequently are. Eyeballing is not only operator dependent, it is hard to repeat over time to monitor treatment response and it requires at least two views of the heart. And, as we know, in ICU patients it can be hard to obtain more than one image due to suboptimal conditions.<sup>[2-4]</sup> Classic genuine LVEF measurements, such as the Simpson method, require training and experience which most intensivists lack.<sup>[3,4]</sup> Nowadays, automatic tracking algorithms are available which automatically define endocardial borders. However, in most of our units such sophisticated machines are not yet available. MAPSE can be used as a parameter for left ventricular function and subsequently for LVEF. It has shown to be a relatively easy, reliable and quick method to assess left ventricular function and is well worth using in an ICU POCUS setting. MAPSE can be falsely positive in patients with aortic stenosis or hypertension.<sup>[5-7]</sup>

Apart from MAPSE, which we may discuss in another part of the series, intensivists are in need of an additional quick, easy and reliable method to assess LVEF in order to rapidly identify those patients who have reduced LVEF and would benefit from inotropic support.

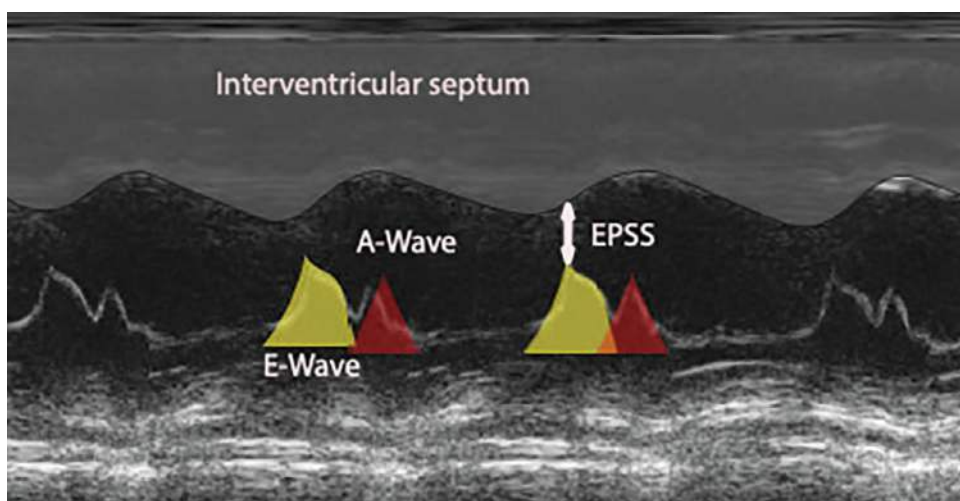
**E-point septal separation as a crude quick measurement of LVEF**

Assessing LVEF by using the E-point septal separation (EPSS) method has shown to be a reliable way of objectivising (severely) reduced LVEF (<50%).<sup>[2,3,8-10]</sup> EPSS is a quick and easy measurement which we can use to rapidly identify those

patients in whom the ejection fraction is significantly reduced and who may benefit from inotropic treatment. It is a quick and rather dirty method to get an indication of whether significantly reduced LVEF is present, nothing more and nothing less. It is not a sophisticated measurement and is not advocated in cardiology guidelines, but in a setting of ICU POCUS with a clearly defined



**Figure 1.** Parasternal long axis, location of M-mode placement through top of the mitral valve is shown. RVOT = right ventricular outflow tract; Ao = aorta; MV = mitral valve; LA = left atrium; LV = left ventricle.



**Figure 2.** EPSS measurement in M-mode. The E wave represents early filling of the left ventricle by passive blood flow from the left atrium. The A wave represents the atrial kick. The distance between the E wave and the septum is the EPSS and considered to be <7 mm in healthy individuals. In order to meet the criteria for heart failure, this distance needs to be over 7 mm.

question such as ‘is there an indication for significantly reduced LVEF?’ EPSS may well be suitable. In fact, studies have shown that EPSS by an inexperienced operator is just as good as quick eyeballing by an experienced cardiologist.<sup>[10]</sup> EPSS measures the distance between the most apical point of the anterior leaflet of the mitral valve and the septum at diastole (figure 1, video 1). In healthy individuals, there is a pressure gradient between the left atrium and left ventricle, which results in passive blood flow towards the left ventricle followed by atrial contraction in diastole. In case of reduced LVEF, the diastolic pressure inside the left ventricle increases because the left ventricle can no longer eject the same amount of blood during systole. This leads to an increasing end-diastolic volume and therefore end-diastolic pressure. This diminishes the A-V gradient in diastole, and leads to reduced opening of the mitral valve. Also, these ventricles dilate. The combination of less mitral opening because of a diminished gradient, but also because of remodelling of the mitral valve apparatus and tethering forces with left ventricular dilatation as well as the dilatation of the left ventricle itself with the septum moving far from the valve tips, leads to low EPSS. EPSS per se does not measure function, it is a surrogate measure of

how much a left ventricle remodels in the course of significant systolic dysfunction.

EPSS is performed in M-mode (*figure 2 and video 1*). The operator will be provided with an overview of the distance between the mitral valve and septum during diastole and systole over time. An EPSS less than 7 mm is considered normal, 7-12 mm suggests decreased LVEF, and >12 mm indicates a low LVEF.<sup>[11]</sup> An EPSS measurement >7 mm is uniformly sensitive in identifying patients with LVEF <50%.<sup>[11]</sup>

### Limitations

EPSS is not suitable to monitor the effect of a given treatment. For example: LVEF increases from 20% to 30%, but it still remains severely decreased and an abnormal EPSS will be found. If you want to monitor for fluid responsiveness, for example, serial measurement of left ventricular outflow tract velocity time integral is a much better test, as discussed previously.<sup>[12]</sup> In addition, in the presence of some conditions, EPSS may be overestimated or underestimated; valvular diseases which decrease the mobility of the mitral valve leaflets, left ventricular hypertrophy or asymmetric septal hypertrophy all may result in false interpretations concerning LVEF.

### Instructions for the EPSS measurement combined with M-mode

An instructional video accompanies this article (*video 1*) link & QRcode

1. Obtain a parasternal long-axis view of the heart (*figure 1*).
2. Activate M-mode and place the cursor on the most apical tip of the anterior leaflet of the mitral valve cutting through the septum (*figure 1*).
3. The M-mode will demonstrate the movement of the anterior leaflet during the heart cycle (*figure 2*).
4. A time/distance graph is shown, where time is on the X-axis and distance on the Y-axis (*figure 2*).

### Conclusion

E-point septal separation as part of point-of-care ultrasound may be used in conjunction with other tests in order to quickly detect reduced LVEF in patients admitted on the ICU. It should

not be used to monitor treatment effect but will help in those patients in whom shock is, in part, of cardiac nature and who may benefit from inotropes.

### Disclosures

All authors declare no conflict of interest. No funding or financial support was received.

### References

1. Malbrain M, Tavernier B, Haverals S, et al. Executive summary on the use of ultrasound in the critically ill: consensus report from the 3rd Course on Acute Care Ultrasound (CACU). *Anestezjologia Intensywna Terapii*. 2014;49.
2. Melamed R, Sprengle MD, Ulstad VK, Herzog CA, Leatherman JW. Assessment of left ventricular function by intensivists using hand-held echocardiography. *Chest*. 2009;135:1416-20.
3. Weekes AJ, Reddy A, Lewis MR, Norton HJ. E-point septal separation compared to fractional shortening measurements of systolic function in emergency department patients. *J Ultrasound Med*. 2012;31:1891-7.
4. Moore CL, Rose GA, Tayal VS. Determination of left ventricular function by emergency physician echocardiography of hypotensive patients. *Acad Emerg Med*. 2002;9:186-93.
5. Rydberg E, Gudmundsson P, Kennedy L, Erhardt L, Willenheimer R. Left atrioventricular plane displacement but not left ventricular ejection fraction is influenced by the degree of aortic stenosis. *Heart*. 2004;90:1151-5.
6. Weidemann F, Herrmann S, Störk S, et al. Impact of Myocardial Fibrosis in Patients With Symptomatic Severe Aortic Stenosis. *Circulation*. 2009;120:577-84.
7. Xiao HB, Kaleem S, McCarthy C, Rosen SD. Abnormal regional left ventricular mechanics in treated hypertensive patients with 'normal left ventricular function'. *Int Cardiol*. 2006;112:316-21.
8. Massie BM, Schiller NB, Ratshin RA, Parmley WW. Mitral-septal separation: New echocardiographic index of left ventricular function. *Am J Cardiol*. 1977;39:1008-16.
9. Satılmış Siliv N, Yamanoglu A, Pinar P, Celebi Yamanoglu NG, Torlak F, Parlak I. Estimation of cardiac systolic function based on mitral valve movements: An accurate bedside tool for emergency physicians in dyspneic patients. *J Ultrasound Med*. 2019;38:1027-38.
10. Secko MA, Lazar JM, Saliccioli LA, Stone MB. Can junior emergency physicians use E-point septal separation to accurately estimate left ventricular function in acutely dyspneic patients? *Acad Emerg Med*. 2011;18:1223-6.
11. McKaigney CJ, Krantz MJ, La Rocque CL, Hurst ND, Buchanan MS, Kendall JL. E-point septal separation: a bedside tool for emergency physician assessment of left ventricular ejection fraction. *Am J Emerg Med*. 2014;32:493-7.
12. López Matta JE, Elzo Kraemer CV, Tuinman PR, van Westerloo DJ. The use of velocity time integral in assessing cardiac output and fluid responsiveness. *Neth J Crit Care*. 2019;58.

### Video 1.



<https://njcc.nl/sites/nvic.nl/files/19-63%20Westerloo%20video.mp4>