



Universiteit
Leiden
The Netherlands

The prognostic value of extracranial vascular characteristics on procedural duration and revascularization success in endovascularly treated acute ischemic stroke patients

Holswilder, G.; Stuart, M.P.M.E.; Dompeling, T.; Kruyt, N.D.; Goeman, J.J.; Lugt, A. van der; ... ; MR CLEAN

Citation

Holswilder, G., Stuart, M. P. M. E., Dompeling, T., Kruyt, N. D., Goeman, J. J., Lugt, A. van der, ... Walderveen, M. A. A. van. (2022). The prognostic value of extracranial vascular characteristics on procedural duration and revascularization success in endovascularly treated acute ischemic stroke patients. *European Stroke Journal*, 7(1), 48-56.
doi:10.1177/23969873211067662

Version: Publisher's Version
License: [Creative Commons CC BY 4.0 license](https://creativecommons.org/licenses/by/4.0/)
Downloaded from: <https://hdl.handle.net/1887/3502276>

Note: To cite this publication please use the final published version (if applicable).




The prognostic value of extracranial vascular characteristics on procedural duration and revascularization success in endovascularly treated acute ischemic stroke patients

European Stroke Journal
2022, Vol. 7(1) 48–56
© European Stroke Organisation 2022



Article reuse guidelines:
sagepub.com/journals-permissions
DOI: 10.1177/23969873211067662
journals.sagepub.com/home/eso



Ghislaine Holswilder¹ , Maaïke PME Stuart¹, Tine Dompeling¹, Nyika D Kruyt² , Jelle J Goeman³, Aad van der Lugt⁴, Wouter J Schonewille⁵, Geert J Lycklama à Nijeholt⁶, Charles BLM Majoie⁷, Lonneke SF Yo⁸, Frederick JA Meijer⁹ , Henk A Marquering⁷, Marieke JH Wermer^{2,*}, Marianne AA van Walderveen^{1,*} and on behalf of the MR CLEAN Registry investigators[†]

Abstract

Introduction: Vascular anatomy might affect endovascular treatment success in acute ischemic stroke patients with large vessel occlusion. We investigated the prognostic value of extracranial vascular characteristics on procedural time and revascularization success in patients with large vessel occlusion in the anterior cerebral circulation.

Patients and methods: We included 828 patients endovascularly treated within 6.5 hours of symptom onset from the Dutch MR CLEAN-Registry. We evaluated aortic arch configuration, stenosis and tortuosity of supra-aortic arteries, and internal carotid arteries (ICAs) on pre-intervention CTA. We constructed logistic prediction models for outcome variables procedural duration (≥ 60 minutes) and non-successful revascularization (extended thrombolysis in cerebral infarction (eTICI) of 0–2A) using baseline characteristics and assessed the effect of extracranial vascular characteristics on model performance.

Results: Cervical ICA tortuosity and stenosis $\geq 99\%$ improved prediction of long procedural duration compared with baseline characteristics from area under the curve of 0.61 (95% CI: 0.57–0.65) to 0.66 (95% CI: 0.62–0.70) ($P < 0.001$). Cervical ICA tortuosity was significantly associated with non-successful recanalization. Prediction of non-successful revascularization did not improve after including aortic arch elongation, acute take-off angle, aortic variant, origin stenosis of supra-aortic arteries, and cervical ICA tortuosity, with an area under the curve of 0.63 (95% CI: 0.59–0.67) compared with 0.59 (95% CI: 0.55–0.63) ($P = 0.11$).

Conclusion: Extracranial vascular characteristics have additional prognostic value for procedural duration, but not for revascularization success, compared with baseline characteristics. Performance of both prediction models is limited in patients treated for large vessel occlusion.

¹Department of Radiology, Leiden University Medical Center, Leiden, Netherlands

²Department of Neurology, Leiden University Medical Center, Leiden, Netherlands

³Department of Biomedical Data Sciences, Leiden University Medical Center, Leiden, Netherlands

⁴Department of Radiology, Erasmus MC University Medical Center, Rotterdam, Netherlands

⁵Department of Neurology, Sint Antonius Hospital, Nieuwegein, Netherlands

⁶Department of Radiology, Haaglanden MC, the Hague, Netherlands

⁷Department of Radiology and Nuclear Medicine, Amsterdam University Medical Center, University of Amsterdam, Amsterdam, Netherlands

⁸Department of Radiology, Catharina Hospital, Eindhoven, Netherlands

⁹Department of Radiology and Nuclear Medicine, Radboud University Medical Center, Nijmegen, Netherlands

*shared last author

[†]A list of the MR CLEAN Registry investigators is included in the supplementary materials

Corresponding author:

Ghislaine Holswilder; Department of Radiology, Leiden University Medical Center, Albinusdreef 2, PO Box 9600, Leiden 2300 RC, the Netherlands.
Email: G.Holswilder@lumc.nl

Keywords

Stroke, Endovascular treatment, aortic arch, carotid arteries, tortuosity

Date received: 21 September 2021; accepted: 1 December 2021

Introduction

Endovascular treatment (EVT) is highly effective in patients with acute ischemic stroke with large vessel occlusion (LVO) in the anterior circulation. Patient recovery after EVT is closely related to successful revascularization as this is associated with improved functional outcome.¹ Also, time to revascularization is important as the probability of functional independence decreases 7.7% with every hour delay from symptom onset to revascularization.² The goal of EVT is, therefore, to achieve the highest degree of revascularization with the shortest possible delay.³ Current recommendations state that procedural time should not exceed 60 minutes and the target should be successful recanalization defined as restored antegrade flow of $\geq 50\%$ of the territory of the previously occluded artery.⁴

Recent studies demonstrated that unfavorable extracranial vascular anatomy, including complex configuration of the aortic arch and tortuosity of the supra-aortic vessels, prolongs procedural duration,^{5–7} and negatively influences revascularization success.^{5,7,8} However, these studies were performed with small sample sizes leaving uncertainty about the true association between vascular characteristics and procedural duration and revascularization success, especially in addition to baseline predictors. Knowledge of these associations would be of value in clinical practice, especially when this information can be derived from pre-intervention CT angiography (CTA), to better direct arterial access approaches for EVT of LVO ischemic stroke patients.

We aimed to associate extracranial vascular characteristics on pre-intervention CTA with procedural duration and revascularization success and assess their added value in prediction models compared with baseline predictors in a large population of patients with LVO treated with EVT.

Patients and methods

Patients were included from the Multicenter Randomized Controlled Trial of Endovascular Treatment for Acute Ischemic Stroke in the Netherlands (MR CLEAN) Registry from March 2014 until June 2016.⁹ The MR CLEAN Registry was an observational registry containing prospectively recorded data from 16 centers in the Netherlands that perform EVT. Patients were included when they were ≥ 18 years, had a diagnosis of acute ischemic stroke due to an LVO in the anterior cerebral circulation, and received EVT within 6.5 hours of symptom onset. Baseline clinical data, including patient history and stroke

characteristics (e.g., stroke risk factors, National Institutes of Health Stroke Scale (NIHSS)) were available.⁹ Baseline imaging (non-contrast brain CT, CTA of the aorta, cervical, and cerebral vessels) and follow-up radiological data (post-intervention extended thrombolysis in cerebral infarction (eTICI)) were assessed by an imaging core laboratory.⁹ A detailed description of the registry procedures is published elsewhere.⁹ For this study, patients were excluded when EVT was not performed because the LVO was no longer present on digital subtraction angiography (DSA) (e.g., because the thrombus had dissolved, either spontaneously or because of IV thrombolysis treatment, or had migrated distally) or if the intervention was technically possible but stopped for other reasons (e.g., vessel perforation during catheterization). Furthermore, patients were excluded when baseline CTA was not available, did not include the aortic arch and/or cervical vessels, or was of insufficient quality. (Figure 1).

CTA analysis

For this study, CTA of aortic arch, supra-aortic, and internal carotid arteries (ICAs) were retrospectively analyzed (Picture Archiving and Communicating System, Sectra IDS7 18.2, Linköping, Sweden) by trained students (MPMES and TD) under supervision of MAAW (neuroradiologist with >20 years of experience in CTA analysis). Interobserver agreement of vascular characteristics was determined in a random selection of 100 patients with Cohen's kappa (κ); values 0.41–0.60 were considered moderate agreement, 0.61–0.80 good agreement, and >0.80 excellent agreement. All observers were blinded to clinical information except for patients' sex, age, and side of intracranial occlusion. Window and level settings for CTA analysis were standardized at W:750, C:200.¹⁰ Based on the literature, the following vascular characteristics were selected: aortic arch variants,¹¹ aortic arch elongation,^{12,13} tortuosity^{12–15} and stenosis¹² of supra-aortic arteries (innominate artery (IA), common carotid arteries (CCA)), and tortuosity^{12–15} and stenosis¹² of the ICA.

Aortic arch variants were defined as: type A) the IA, left CCA, and left subclavian artery branch directly from the aortic arch; type B) the IA and left CCA share a common origin; or type C) the left CCA branches from the IA.¹¹ Aortic arch elongation was assessed according to previous studies and divided into three types (aortic arch type I, II, or III; a more detailed description is provided in Figure S1A of the Supplementary material).^{12,13}

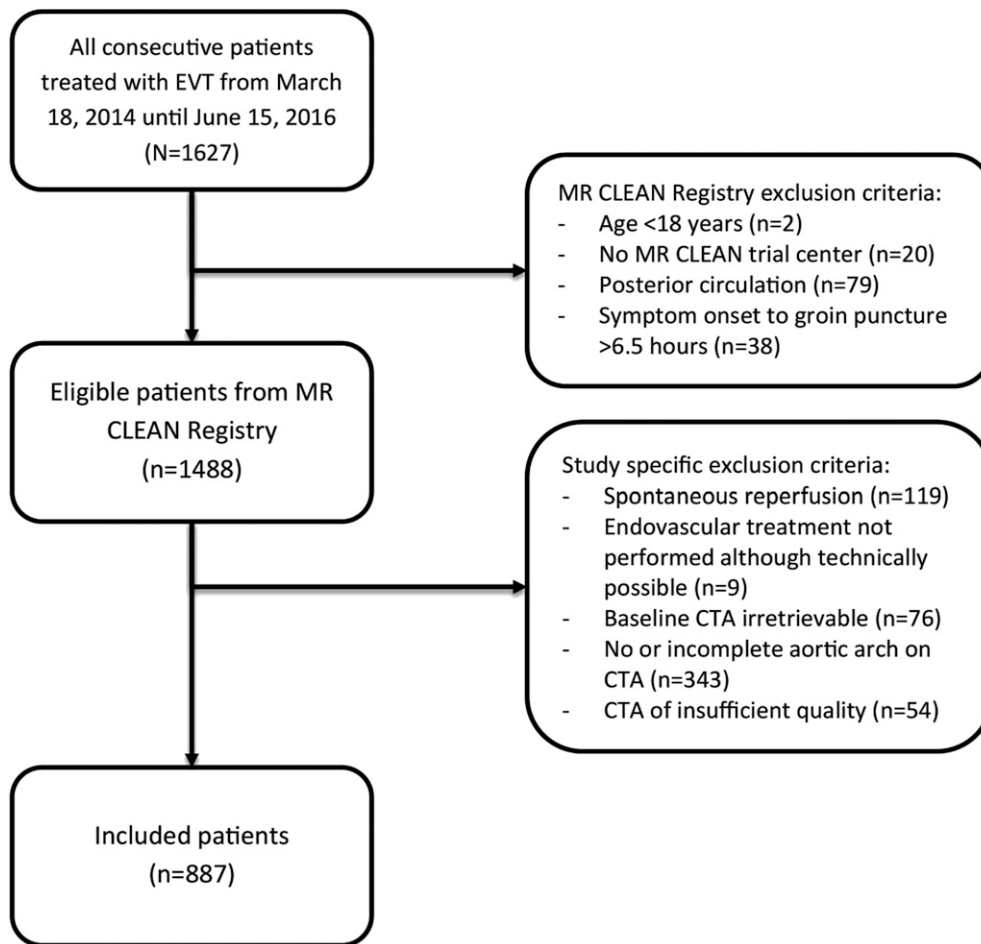


Figure 1. Inclusion flowchart. From the MR CLEAN Registry, 1488 patients were available for analysis of which 601 patients were excluded based on study specific criteria, leading to the final inclusion of 887 patients. CTA: CT angiography; EVT: endovascular treatment.

The take-off angle from the aorta to the supra-aortic artery ipsilateral to the side of the LVO, was measured in an adjusted projection to show the maximal angle of the aortic arch and the origin of the supra-aortic artery.¹³ (Figure S1B and S1C). A normal angle was defined as a 90° angle and a difficult take-off angle was defined, based on expert opinion, as an acute angle measuring $\geq 135^\circ$.

Tortuosity of supra-aortic arteries (IA/CCA) and ICA, ipsilateral to the side of the intracranial occlusion, was evaluated by assessing the angulation of these vessels.^{13–15} Tortuosity was defined as the presence of at least one angle measuring $\geq 90^\circ$; in addition, presence of two angles or more measuring $\geq 90^\circ$ was assessed. (Figure S1D).

Stenosis was assessed for IA/CCA, cervical, and intracranial ICA ipsilateral to the side of the intracranial occlusion. Stenosis was visually determined at the origin of the supra-aortic arteries (IA/CCA) and dichotomized into $<50\%$ and $\geq 50\%$.¹² Presence of stenosis of the cervical ICA was

measured according to the North American Symptomatic Carotid Endarterectomy Trial (NASCET) criteria and dichotomized into $<99\%$ and $\geq 99\%$ (including occlusion).¹⁶ Intracranial ICA stenosis was visually determined and dichotomized into $<50\%$ and $\geq 50\%$.

Outcome measures

Procedural duration was defined as the duration of EVT from groin puncture to removal of the catheter sheath and dichotomized into <60 minutes and ≥ 60 minutes, based on current recommendations that procedure time should not exceed 60 minutes.⁴ Procedural duration cannot be defined in patients in whom the occlusion site could not be reached by transfemoral approach; these patients were therefore not included in the analysis for procedural duration. Non-successful revascularization after EVT was defined as eTICI grade 0–2A on the final DSA run.^{1,17} To grade eTICI $\geq 2B$, the final run had to contain both anteroposterior

and lateral views; presence of only one view resulted in a maximal grade of 2A.

Statistical analysis

Baseline characteristics were reported as number (%), mean (standard deviation; SD), or median (interquartile range; IQR). To analyze the effect of vascular characteristics on pre-intervention CTA on outcome parameters, we first assessed associations by logistic regression and adjusted for covariates known prior to EVT. For procedural duration, we adjusted for age,^{12,18} hypertension,¹⁹ and clot burden score (CBS)²⁰; for non-successful revascularization, we adjusted for age, hypertension, CBS, intravenous thrombolysis (IVT),¹⁸ pre-stroke eTICI, and collateral score.²¹ Multiple imputation with 10 imputations was performed to obtain unbiased analyses, using the Markov chain Monte Carlo method (variables are described in [Table S1](#)).²²

Second, we constructed logistic prediction models to assess which combination of vascular characteristics is associated with the outcome parameters. We started with baseline prediction models with covariates used for adjustments. We developed final prediction models using backward selection of vascular characteristics; variables were kept in the model when the effect in the model showed a p -value < 0.20 . Finally, performance of the final models was assessed using the receiver operating characteristic (ROC) curve and area under the curves (AUC) (pooled with Rubin's Rule). Whether final models had significantly increased goodness-of-fit compared with baseline models was assessed with the likelihood ratio test (pooled for all imputations).

Results

We included 887 patients (mean age: 69 years, 52% men) ([Figure 1](#)). Baseline characteristics for included and excluded patients are shown in [Table S2](#) of the [Supplementary material](#). The occlusion site was not reached via the transfemoral approach in 59 patients (7%). Procedural duration ≥ 60 minutes was present in 456 patients (61%) and revascularization after EVT was non-successful (eTICI 0–2A) in 395 patients (45%) ([Table 1](#)); in 84% of all patients, DSA included both anteroposterior and lateral views. Baseline characteristics for the groups sorted by outcome measures are shown in [Table 1](#).

Vascular characteristics

Tortuosity of the cervical ICA (adjusted odds ratio (aOR): 1.9, 95% CI: 1.4–2.7) was significantly associated with procedural duration after adjustment for baseline characteristics ([Table 2](#)). All patients with IA/CCA origin stenosis $\geq 50\%$ and 59% of patients without origin stenosis

had a procedural duration ≥ 60 minutes (Fisher's exact test $P = 0.01$) ([Supplementary material](#)). In addition, cervical ICA stenosis $\geq 99\%$ was significantly associated with procedural duration ≥ 60 minutes (aOR: 3.0, 95% CI: 1.6–5.9). Tortuosity of the cervical ICA (aOR: 1.5, 95% CI: 1.1–2.0) was significantly associated with non-successful revascularization (eTICI 0–2A) after adjustment for baseline characteristics. ([Table 2](#), [Supplementary material](#)). Inter-observer agreement was excellent for aortic variant (κ : 0.90) and acute take-off angle $\geq 135^\circ$ (κ : 0.85), good for aortic arch elongation (κ : 0.79) and tortuosity of at least one angle measuring $\geq 90^\circ$ (κ : 0.73), and moderate for intracranial ICA stenosis $\geq 50\%$ (κ : 0.45) and cervical ICA stenosis $\geq 99\%$ (κ : 0.58).

Prediction models and ROC analyses

The baseline prediction model of procedural duration ≥ 60 minutes with age, hypertension, and CBS resulted in an AUC of 0.61 (95% CI: 0.57–0.65). After backward regression, the following characteristics remained in the final model: tortuosity of the cervical ICA and cervical ICA stenosis $\geq 99\%$. This final model had an AUC of 0.66 (95% CI: 0.62–0.70). ([Figure 2A](#)). Regression coefficients and intercept are shown in [Table S4](#) of the [Supplementary material](#). The likelihood ratio test indicated a significant difference in model performance between the final and baseline model ($P < 0.001$).

Baseline prediction model of non-successful revascularization (eTICI 0–2A) with age, hypertension, IVT, collateral score, CBS, and eTICI prior to EVT treatment resulted in an AUC of 0.59 (95% CI: 0.55–0.63). Following backward selection, the following characteristics remained in the final model: acute take-off angle $\geq 135^\circ$, aortic variant, the presence of IA/CCA origin stenosis $\geq 50\%$, tortuosity of the IA/CCA, tortuosity of the cervical ICA, and cervical ICA stenosis $\geq 99\%$. This final model had an AUC of 0.63 (95% CI: 0.59–0.67). ([Figure 2B](#)). Regression coefficients and intercept are shown in [Table S5](#) of the [Supplementary material](#). The likelihood ratio test indicated no difference in model performance between the final and baseline model ($P = 0.27$).

Discussion

We showed that tortuosity of the cervical ICA was associated with long procedural duration (≥ 60 minutes) and non-successful revascularization in a large cohort of consecutive acute anterior circulation ischemic stroke patients treated with EVT. In addition, cervical ICA stenosis $\geq 99\%$ (including occlusion) was independently associated with procedural duration ≥ 60 minutes. Although extracranial vascular characteristics increased model performance compared to baseline characteristics, this difference was

Table 1. Baseline and outcome characteristics of the total population (N = 887), divided by procedural duration (≥ 60 vs. < 60 minutes) (n = 745) and by revascularization success (eTICI 0–2A vs. eTICI 2B–3) (n = 877).

Patient characteristic	Total N = 887	≥ 60 minutes n = 456	< 60 minutes n = 289	eTICI 0–2A n = 395	eTICI 2B–3 n = 482
Age (mean, SD)	68.7 (14.4)	68.5 (14.1)	67.6 (15.2)	69.7 (14.2)	67.9 (14.5)
Men (n, %)	461 (52%)	245 (54%)	151 (51%)	203 (51%)	254 (53%)
Previous stroke (n, %)	159 (18%)	66 (15%)	63 (21%)	69 (18%)	87 (18%)
Diabetes mellitus (n, %)	136 (15%)	67 (15%)	43 (15%)	61 (16%)	73 (15%)
Hypertension (n, %)	446 (51%)	240 (54%)	138 (47%)	204 (52%)	239 (50%)
Atrial fibrillation (n, %)	202 (23%)	100 (22%)	79 (27%)	98 (25%)	103 (22%)
Current smoking (n, %)	214 (24%)	116 (26%)	70 (24%)	90 (23%)	121 (25%)
Pre-mRS ≥ 1 (n, %)	286 (33%)	149 (33%)	98 (33%)	133 (34%)	150 (32%)
NIHSS at baseline (median, IQR)	16 (12–20)	16 (12–20)	15 (12–19)	16 (12–20)	15 (11–19)
Radiological characteristics					
Pre-intervention eTICI ≥ 1 (n, %)	83 (10%)	43 (10%)	29 (11%)	33 (9%)	49 (11%)
Collateral score $\geq 50\%$ (n, %)	512 (60%)	256 (59%)	183 (64%)	209 (55%)	296 (64%)
ASPECTS ≤ 7 (n, %)	256 (29%)	144 (32%)	79 (27%)	117 (30%)	137 (29%)
CBS ≤ 7 (n, %)	548 (72%)	284 (73%)	176 (69%)	241 (72%)	300 (72%)
Intervention characteristics					
IVT administered (n, %)	683 (77%)	352 (77%)	222 (75%)	298 (75%)	376 (78%)
EVT under general anesthesia (n, %)	231 (27%)	121 (28%)	89 (31%)	79 (22%)	150 (32%)
Symptom onset to groin puncture, min (median, IQR)	210 (159–265)	207 (160–260)	210 (155–261)	214 (159–275)	200 (160–255)
Outcome characteristics					
Procedural duration, min (median, IQR)	65 (45–90)	85 (70–105)	40 (31–50)	80 (60–105)	55 (37–75)
mRS after 3 months 3–6	504 (59%)	290 (66%)	131 (45%)	287 (77%)	212 (45%)
eTICI 0–2A	395 (45%)	239 (53%)	58 (20%)	-	-

ASPECTS: Alberta Stroke Program Early CT Score; CBS: clot burden score; eTICI: extended thrombolysis in cerebral infarction; EVT: endovascular treatment; IQR: interquartile range; IVT: intravenous thrombolysis; mRS: modified Rankin Scale; NIHSS: National Institutes of Health Stroke Scale; SD: standard deviation.

Numbers might not add up due to missing values.

only significant for procedural duration. Also, performance of the prediction models was only moderate for both procedural duration and non-successful revascularization.

Our study confirms the associations between tortuosity of the cervical ICA and long procedural duration shown by others.^{5,6} Moreover, other studies showed associations for aortic arch elongation and aortic variants,^{5–8} which were not found in our population. This difference might be due to the relative low prevalence of severe aortic arch elongation (17%) compared with two other studies (30%–39%),^{7,8} and the relatively low prevalence of aortic variant C (11%) in our study.⁷

Tortuosity of the cervical ICA was also significantly associated with non-successful revascularization, which is consistent with previous studies.^{7,23} The final prediction model for non-successful revascularization included acute take-off angle, aortic variant, and IA/CCA tortuosity, indicating an association that is consistent with previous research.^{7,8} In addition, our model also showed an independent association with tortuosity and stenosis $> 99\%$ of

the cervical ICA. However, including these factors did not increase model performance and multivariate effects were only small and non-significant. One reason that we did not find a similar effect of arch elongation compared with other studies^{7,8} might have been the relative low prevalence of severe aortic arch elongation (17%) in our study. In addition, other studies were small,^{5–7} while we analyzed a large and unselected multicenter cohort. Recent studies also showed moderate performance of prediction models for revascularization after EVT,^{24,25} and our study indicates that there is no improvement after adding extracranial vascular anatomical characteristics.

Performance of our prediction models for both procedural duration and non-successful revascularization was only moderate. This might, partially, be explained by the restriction of our model to variables available prior to the start of treatment. Periprocedural factors, including the number of passes required to retrieve the thrombus, occurrence of periprocedural complications (e.g., distal emboli in other vascular territories), and thrombus

Table 2. Odds ratios of procedural duration ≥ 60 minutes ($n = 828$) and non-successful revascularization (eTICI 0–2A) ($n = 887$) in the presence versus absence of extracranial vascular characteristics.

	Duration ≥ 60 minutes		eTICI 0–2A	
	Unadjusted OR (95% CI)	Adjusted OR (95% CI)	Unadjusted OR (95% CI)	Adjusted OR (95% CI)
Aortic arch elongation				
Type II vs. I	1.1 (0.7–1.6)	1.1 (0.7–1.6)	0.9 (0.7–1.3)	0.8 (0.6–1.2)
Type III vs. I	1.1 (0.7–1.8)	1.1 (0.7–2.0)	1.2 (0.8–1.9)	1.0 (0.6–1.6)
Take-off angle $\geq 135^\circ$	1.4 (0.8–2.5)	1.5 (0.8–2.7)	1.3 (0.8–2.2)	1.4 (0.8–2.3)
Aortic variants				
Variant B vs. A	1.1 (0.7–1.7)	1.1 (0.7–1.8)	0.8 (0.6–1.2)	0.9 (0.6–1.3)
Variant C vs. A	1.0 (0.6–1.7)	1.0 (0.6–1.7)	1.5 (0.9–2.3)	1.5 (0.9–2.3)
Tortuosity right IA and CCA, or left CCA^{b,c}				
Presence of ≥ 1 angles $\geq 90^\circ$	1.2 (0.9–1.6)	1.1 (0.8–1.5)	1.3 (1.0–1.8) ^a	1.3 (0.9–1.7)
Presence of ≥ 2 angles $\geq 90^\circ$	1.1 (0.7–1.6)	1.0 (0.6–1.6)	1.3 (0.9–2.0)	1.3 (0.8–1.9)
Tortuosity cervical ICA^b				
Presence of ≥ 1 angles $\geq 90^\circ$	2.0 (1.5–2.8) ^a	1.9 (1.4–2.7) ^a	1.6 (1.2–2.1) ^a	1.5 (1.1–2.0) ^a
Presence of ≥ 2 angles $\geq 90^\circ$	2.0 (1.3–3.1) ^a	2.0 (1.3–3.0) ^a	1.4 (1.0–2.0) ^a	1.4 (0.9–1.9)
Vessel stenosis				
IA/CCA origin stenosis $\geq 50\%$ ^d	-	-	3.1 (0.7–13.7)	3.1 (0.7–13.3)
ICA stenosis $\geq 99\%$	3.3 (1.7–6.3) ^a	3.0 (1.6–5.9) ^a	1.3 (0.8–2.1)	1.3 (0.8–2.2)
Intracranial ICA stenosis $\uparrow \geq 50\%$	1.1 (0.7–1.6)	0.9 (0.6–1.4)	1.4 (0.9–2.1)	1.3 (0.9–1.9)

CCA: common carotid arteries; eTICI: extended thrombolysis in cerebral infarction; IA: innominate artery; ICA: internal carotid artery; OR: odds ratio. Numbers might not add up due to missing values. ORs were adjusted for age, hypertension and CBS for procedural duration, and—in addition to these—for intravenous thrombolysis, pre-stroke eTICI and collateral score for non-successful revascularization.

^aIndicates significant OR.

^bThe IA and left or right CCA were measured ipsilateral to the side of the intracranial vessel occlusion.

^cPresence of ≥ 1 angles $\geq 90^\circ$ was compared with no angle $\geq 90^\circ$; presence of ≥ 2 angles $\geq 90^\circ$ was compared with no or 1 angle $\geq 90^\circ$.

^d(adjusted) OR could not be calculated for procedural duration; Fisher's exact test resulted in $P = 0.01$.

characteristics are also related to procedural duration and non-successful revascularization and were not taken into account.^{26–29}

Limitations of our study are the exclusion of a substantial number of patients, mainly due to incomplete depiction of the aortic arch with CTA because imaging of the aortic arch is inconsistently performed in the diagnostic workup in different hospitals. We expect this to be a random selection. In addition, we excluded patients with failed occlusion access via the transfemoral approach for the analysis of procedural duration. This exclusion possibly resulted in selection bias as this is likely related to difficult vascular anatomy. However, including these patients would have led to a higher number of patients with inconsistently shorter procedural duration. Also, model performance is likely an overestimation of the true performance, since we did not validate our prediction models.

Also, tortuosity is difficult to quantify. An additional limitation of our study is therefore that, although we introduced simple cut-off values to measure vessel tortuosity, the measurement of this parameter in routine clinical practice will still be a challenge. So far, preliminary work

showed that a semi-automated method can be used to quantify tortuosity of the aortic arch and supra-aortic arteries on CTA.³⁰ This technique could be useful for the identification of patients with difficult vascular anatomy but needs further development. In addition, the associations between vascular characteristics and procedural outcomes may be different for patients treated via a transradial approach. Increasing evidence suggest that EVT via the transradial approach is a safe alternative to the transfemoral approach.³¹ In both approaches, similar vascular characteristics are associated with revascularization success and increased procedural duration.³² In addition, patients with specific characteristics, especially difficult arch anatomy, might be better treated with a transradial approach,^{33,34} but this requires further research.

Also, we did not include experience of the interventionalist and, although patients were treated according to standard clinical practice, neurointerventional experience and equipment have improved over time. Whether intracranial anatomical characteristics (e.g., diameter of the proximal middle cerebral artery) are associated with successful revascularization was outside the scope of our

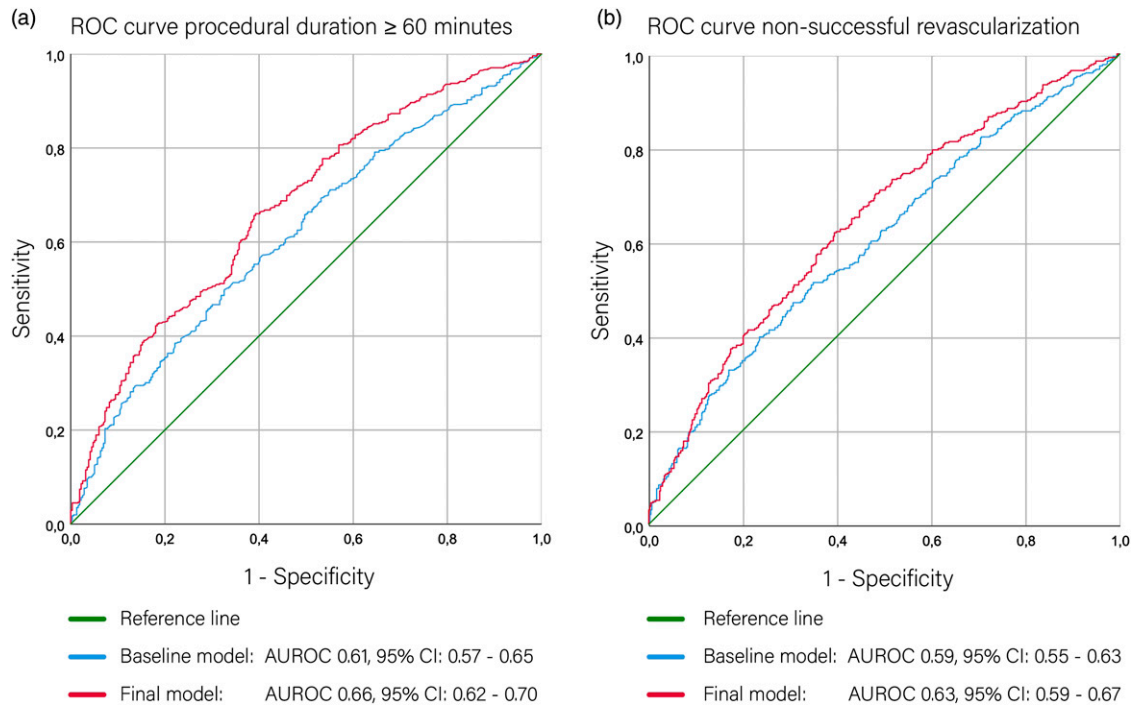


Figure 2. Receiver operating characteristic (ROC) curves of the baseline model and final model for (a) prediction of procedural duration ≥ 60 minutes and (b) non-successful revascularization (eTICI 0–2A). ROC curves represent averaged curves and area under the curve (AUC) values represent pooled AUC's of all 10 imputations. Baseline models are indicated by blue lines and final models with red lines.

analyses.³⁵ Finally, we limited our analyses to the aorta, supra-aortic and cervical vessels that are visible on pre-intervention CTA. Challenging vascular anatomy in the descending aorta and iliac arteries may significantly decrease trackability of the catheter and is probably associated with revascularization and procedural duration. However, these vessels were not included in the field-of-view of the CTA scans. Hard or resistant occlusions can be another reason for unsuccessful revascularization,³⁶ but whether characteristics on pre-intervention CT, such as hyperdense vessel sign, are related to treatment success is not clear³⁷ and thrombus density measures are only recently improved for use in clinical practice.³⁸ Both factors were therefore outside the scope of our analyses.

Strengths of our study include the use of extracranial vascular characteristics available prior to EVT on pre-intervention CTA. Also, we simplified the measured characteristics by choosing binary cut-off values, providing interventionalists with an easy and quick method to identify difficult anatomical characteristics prior to the start of EVT. In addition, results are likely generalizable to other LVO populations as data were derived from a large multicenter cohort of patients treated according to standard clinical practice with varying imaging and treatment protocols. Moreover, the large number of

patients provided us with sufficient statistical power to assess the associations of all vascular characteristics from the aorta until the skull base with both procedural duration and non-successful revascularization.

Conclusion

Our study showed that extracranial vascular characteristics had additional prognostic value compared with baseline characteristics for procedural duration but not for non-successful revascularization. Moreover, performance of both prediction models was limited in patients with anterior cerebral circulation LVO treated with EVT.

Acknowledgments

We thank the MR CLEAN Registry investigators for their support.

Contributorship

Conception and design of the study: GH, NDK, AL, WJS, GJLN, CBLMM, HAM, MJHW, and MAAW. Acquisition, analysis or interpretation of the data: GH, MPMS, TD, NDK, JJG, LSFY, FJAM, MJHW, and MAAW. Drafting of the article: GH, MS, and TD. Critical revision of the article: NDK, JJG, AL, WJS, GJLN, CBLMM, LSFY, FJAM, HAM, MJHW, and MAAW. All authors

approved of the final version. MR CLEAN Registry investigators are group authors and responsible for acquisition of the data, revising the article and final approval.

Declaration of Conflicting Interests

The author(s) declared the following potential conflicts of interest with respect to the research, authorship, and/or publication of this article: AL received grants from: Cerenovus, Penumbra, Stryker, Medtronic, Dutch Heart Foundation, The Netherlands Organisation for Health Research and Development, Health Holland Top Sector Life Sciences & Health and from Dutch Brain Foundation. CBLMM received grants during the conduct of the study (paid to institution) from TWIN Foundation and outside of the submitted work (paid to institution) from CVON/Dutch Heart Foundation, European Commission, Dutch Health Evaluation Program and from Stryker; and is shareholder of Nico.Lab. HAM is co-founder and shareholder of Nico.Lab. GH, MPMES, TD, NDK, JJG, WJS, GJLN, LSFY, FJAM, MJHW and MAAW declared no conflict interest.

Funding

The MR CLEAN Registry was partly funded by TWIN Foundation, Erasmus MC University Medical Center, Maastricht University Medical Center, and Amsterdam UMC.

Ethics approval

Central medical ethics committee of the Erasmus Medical Centre Rotterdam, the Netherlands, granted permission to perform the study as a registry (MEC-2014-235).

Informed consent

Patients or their representatives were informed about the study orally and in writing. The need for patient written informed consent has been waived.

Guarantor

MAAW.

ORCID iDs

Ghislaine Holswilder  <https://orcid.org/0000-0002-9788-4345>

Nyika D Kruyt  <https://orcid.org/0000-0002-2320-0932>

Frederick JA Meijer  <https://orcid.org/0000-0001-5921-639X>

Supplemental material

Supplemental material for this article is available online.

References

1. Liebeskind DS, Bracard S, Guillemin F, et al. eTICI reperfusion: defining success in endovascular stroke therapy. *Journal of NeuroInterventional Surgery* 2019; 11: 433–438. DOI: [10.1136/neurintsurg-2018-014127](https://doi.org/10.1136/neurintsurg-2018-014127).
2. Mulder MJHL, Jansen IGH, Goldhoorn R-JB, et al. Time to Endovascular Treatment and Outcome in Acute Ischemic Stroke. *Circulation* 2018; 138: 232–240. DOI: [10.1161/CIRCULATIONAHA.117.032600](https://doi.org/10.1161/CIRCULATIONAHA.117.032600).
3. Saver JL, Goyal M, van der Lugt A, et al. Time to Treatment With Endovascular Thrombectomy and Outcomes From Ischemic Stroke: A Meta-analysis. *JAMA* 2016; 316: 1279–1288. DOI: [10.1001/jama.2016.13647](https://doi.org/10.1001/jama.2016.13647).
4. Sacks D, Sacks D, Baxter B, et al. Multisociety Consensus Quality Improvement Revised Consensus Statement for Endovascular Therapy of Acute Ischemic Stroke. *American Journal of Neuroradiology* 2018; 39: E61–E76. DOI: [10.3174/ajnr.A5638](https://doi.org/10.3174/ajnr.A5638).
5. Kaymaz Z., Nikoubashman O., Brockmann M, et al. Influence of carotid tortuosity on internal carotid artery access time in the treatment of acute ischemic stroke. *Interventional Neuroradiology* 2017; 23: 583–588. DOI: [10.1177/1591019917729364](https://doi.org/10.1177/1591019917729364).
6. Knox JA, Alexander MD, McCoy DB, et al. Impact of aortic arch anatomy on technical performance and clinical outcomes in patients with acute ischemic stroke. *American Journal of Neuroradiology* 2020; 41: 268–273. DOI: [10.3174/ajnr.A6422](https://doi.org/10.3174/ajnr.A6422).
7. Snelling BM, Sur S, Shah SS, et al. Unfavorable Vascular Anatomy Is Associated with Increased Revascularization Time and Worse Outcome in Anterior Circulation Thrombectomy. *World Neurosurgery* 2018; 120: 976–e983. DOI: [10.1016/j.wneu.2018.08.207](https://doi.org/10.1016/j.wneu.2018.08.207).
8. Dumont TM and Bina RW. Difficult vascular access anatomy associated with decreased success of revascularization in emergent thrombectomy. *Journal of Vascular and Interventional Neurology* 2018; 10: 11–14.
9. Jansen IGH, Mulder MJHL, Goldhoorn R-JB, et al. Endovascular treatment for acute ischaemic stroke in routine clinical practice: prospective, observational cohort study (MR CLEAN Registry). *BMJ* 2018; 360: k949. DOI: [10.1136/bmj.k949](https://doi.org/10.1136/bmj.k949).
10. Saba L and Mallarini G. MDCTA of carotid plaque degree of stenosis: evaluation of interobserver agreement. *American Journal of Roentgenology* 2008; 190: W41–W46. DOI: [10.2214/AJR.07.2604](https://doi.org/10.2214/AJR.07.2604).
11. Layton KF, Kallmes DF, Cloft HJ, et al. Bovine aortic arch variant in humans: clarification of a common misnomer. *AJNR. American Journal of Neuroradiology* 2006; 27: 1541–2.
12. Lam RC, Lin SC, DeRubertis B, et al. The impact of increasing age on anatomic factors affecting carotid angioplasty and stenting. *Journal of Vascular Surgery* 2007; 45: 875–880. DOI: [10.1016/j.jvs.2006.12.059](https://doi.org/10.1016/j.jvs.2006.12.059).
13. Müller MD, Ahlhelm FJ, von Hessling A, et al. Vascular anatomy predicts the risk of cerebral ischemia in patients randomized to carotid stenting versus endarterectomy. *Stroke* 2017; 48: 1285–1292. DOI: [10.1161/STROKEAHA.116.014612](https://doi.org/10.1161/STROKEAHA.116.014612).

14. Ikeda G, Tsuruta W, Nakai Y, et al. Anatomical risk factors for ischemic lesions associated with carotid artery stenting. *Interventional Neuroradiology* 2014; 20: 746–754. DOI: [10.15274/INR-2014-10075](https://doi.org/10.15274/INR-2014-10075).
15. Roubin GS, Iyer S, Halkin A, et al. Realizing the potential of carotid artery stenting. *Circulation* 2006; 113: 2021–2030. DOI: [10.1161/CIRCULATIONAHA.105.595512](https://doi.org/10.1161/CIRCULATIONAHA.105.595512).
16. North American Symptomatic Carotid Endarterectomy Trial. North American symptomatic carotid endarterectomy trial. methods, patient characteristics, and progress. *Stroke* 1991; 22: 711–20. DOI: [10.1161/01.str.22.6.711](https://doi.org/10.1161/01.str.22.6.711).
17. Goyal M, Fargen KM, Turk AS, et al. 2C or not 2C: defining an improved revascularization grading scale and the need for standardization of angiography outcomes in stroke trials. *Journal of NeuroInterventional Surgery* 2014; 6: 83–86. DOI: [10.1136/neurintsurg-2013-010665](https://doi.org/10.1136/neurintsurg-2013-010665).
18. Bourcier R, Goyal M, Liebeskind DS, et al. Association of Time From Stroke Onset to Groin Puncture With Quality of Reperfusion After Mechanical Thrombectomy. *JAMA Neurology* 2019; 76: 405–411. DOI: [10.1001/jamaneurol.2018.4510](https://doi.org/10.1001/jamaneurol.2018.4510).2019/01/23
19. Pancera P, Ribul M, Presciuttini B, et al. Prevalence of carotid artery kinking in 590 consecutive subjects evaluated by Echocolordoppler. Is there a correlation with arterial hypertension?. *Journal of Internal Medicine* 2000; 248: 7–12. DOI: [10.1046/j.1365-2796.2000.00611.x](https://doi.org/10.1046/j.1365-2796.2000.00611.x).
20. Li G, Wu G, Qin Z, et al. Prognostic Value of Clot Burden Score in Acute Ischemic Stroke after Reperfusion Therapies: A Systematic Review and Meta-Analysis. *J Stroke Cerebrovasc Dis* 2019. DOI: [10.1016/j.jstrokecerebrovasdis.2019.07.009](https://doi.org/10.1016/j.jstrokecerebrovasdis.2019.07.009).
21. Liebeskind DS, Jahan R, Nogueira RG, et al. Impact of collaterals on successful revascularization in Solitaire FR with the intention for thrombectomy. *Stroke* 2014; 45: 2036–2040. DOI: [10.1161/STROKEAHA.114.004781](https://doi.org/10.1161/STROKEAHA.114.004781).
22. Moons KGM, Donders RART, Stijnen T, et al. Using the outcome for imputation of missing predictor values was preferred. *Journal of Clinical Epidemiology* 2006; 59: 1092–1101. DOI: [10.1016/j.jclinepi.2006.01.009](https://doi.org/10.1016/j.jclinepi.2006.01.009).
23. Benson JC, Brinjikji W, Messina SA, et al. Cervical internal carotid artery tortuosity: A morphologic analysis of patients with acute ischemic stroke. *Interv Neuroradiol* 2019. DOI: [10.1177/1591019919891295](https://doi.org/10.1177/1591019919891295).
24. Hilbert A, Ramos LA, van Os HJA, et al.. Data-efficient deep learning of radiological image data for outcome prediction after endovascular treatment of patients with acute ischemic stroke. *Computers in Biology and Medicine* 2019; 115: 103516. DOI: [10.1016/j.compbiomed.2019.103516](https://doi.org/10.1016/j.compbiomed.2019.103516).
25. van Os HJA, Ramos LA, Hilbert A, et al. Predicting Outcome of Endovascular Treatment for Acute Ischemic Stroke: Potential Value of Machine Learning Algorithms. *Frontiers in Neurology* 2018; 9: 784–2018. DOI: [10.3389/fneur.2018.00784](https://doi.org/10.3389/fneur.2018.00784).
26. Dobrocky T, Piechowiak E, Cianfoni A, et al. Thrombectomy of calcified emboli in stroke. Does histology of thrombi influence the effectiveness of thrombectomy?. *Journal of NeuroInterventional Surgery* 2018; 10: 345–350. DOI: [10.1136/neurintsurg-2017-013226](https://doi.org/10.1136/neurintsurg-2017-013226).
27. Fennell VS, Setlur Nagesh SV, Meess KM, et al. What to do about fibrin rich 'tough clots'? Comparing the Solitaire stent retriever with a novel geometric clot extractor in an in vitro stroke model. *Journal of NeuroInterventional Surgery* 2018; 10: 907–910. DOI: [10.1136/neurintsurg-2017-013507](https://doi.org/10.1136/neurintsurg-2017-013507).
28. Kaesmacher J, Gralla J, Mosimann PJ, et al. Reasons for reperfusion failures in stent-retriever-based thrombectomy: registry analysis and proposal of a classification system. *American Journal of Neuroradiology* 2018; 39: 1848–1853. DOI: [10.3174/ajnr.A5759](https://doi.org/10.3174/ajnr.A5759).
29. Seker F, Pfaff J, Wolf M, et al. Correlation of Thrombectomy Maneuver Count with Recanalization Success and Clinical Outcome in Patients with Ischemic Stroke. *American Journal of Neuroradiology* 2017; 38: 1368–1371. DOI: [10.3174/ajnr.A5212](https://doi.org/10.3174/ajnr.A5212).
30. Mokin M, Waqas M, Chin F, et al. Semi-automated measurement of vascular tortuosity and its implications for mechanical thrombectomy performance. *Neuroradiology* 2021; 63: 381–389. DOI: [10.1007/s00234-020-02525-6](https://doi.org/10.1007/s00234-020-02525-6).
31. Peterson C and Waldau B. Transradial access for thrombectomy in acute stroke: A systematic review and meta-analysis. *Clinical Neurology and Neurosurgery* 2020; 198: 106235–2020. DOI: [10.1016/j.clineuro.2020.106235](https://doi.org/10.1016/j.clineuro.2020.106235).
32. Chen SH, Snelling BM, Sur S, et al. Transradial versus transfemoral access for anterior circulation mechanical thrombectomy: comparison of technical and clinical outcomes. *Journal of NeuroInterventional Surgery* 2019; 11: 874–878. DOI: [10.1136/neurintsurg-2018-014485](https://doi.org/10.1136/neurintsurg-2018-014485).2019/01/24
33. Cho HW and Jun HS. Can Transradial Mechanical Thrombectomy Be an Alternative in Case of Impossible Transfemoral Approach for Mechanical Thrombectomy? A Single Center's Experience. *Journal of Korean Neurosurgical Society* 2021; 64: 60–68. DOI: [10.3340/jkns.2020.0240](https://doi.org/10.3340/jkns.2020.0240).
34. Khanna O, Velagapudi L, Das S, et al. A comparison of radial versus femoral artery access for acute stroke interventions. *Journal of Neurosurgery* 2021; 135: 727–732. DOI: [10.3171/2020.7.JNS201174](https://doi.org/10.3171/2020.7.JNS201174).
35. Srivatsa S, Duan Y, Sheppard JP, et al. Cerebral vessel anatomy as a predictor of first-pass effect in mechanical thrombectomy for emergent large-vessel occlusion. *Journal of Neurosurgery* 2021; 134: 576–584. DOI: [10.3171/2019.11.JNS192673](https://doi.org/10.3171/2019.11.JNS192673).
36. Leischner H, Flottmann F, Hanning U, et al. Reasons for failed endovascular recanalization attempts in stroke patients. *Journal of NeuroInterventional Surgery* 2018; 11: 439–442. DOI: [10.1136/neurintsurg-2018-014060](https://doi.org/10.1136/neurintsurg-2018-014060).
37. Jing M, Yeo JYP, Holmin S, et al. Preprocedural Imaging. *Clinical Neuroradiology* 2021. DOI: [10.1007/s00062-021-01095-1](https://doi.org/10.1007/s00062-021-01095-1).
38. Qazi S, Qazi E, Wilson AT, et al. Identifying Thrombus on Non-Contrast CT in Patients with Acute Ischemic Stroke. *Diagnostics* 2021; 11: 1919. DOI: [10.3390/diagnostics11101919](https://doi.org/10.3390/diagnostics11101919).