



Universiteit  
Leiden  
The Netherlands

## **Inflammation in the posterior elements, in particular the facet joint and facet joint ankylosis over 2-year follow-up in radiographic axial spondyloarthritis**

Hooge, M. de; Stal, R.; Sepriano, A.; Baraliakos, X.; Reijnierse, M.; Braun, J.; ... ; Ramiro, S.

### **Citation**

Hooge, M. de, Stal, R., Sepriano, A., Baraliakos, X., Reijnierse, M., Braun, J., ... Ramiro, S. (2024). Inflammation in the posterior elements, in particular the facet joint and facet joint ankylosis over 2-year follow-up in radiographic axial spondyloarthritis. *Rmd Open: Rheumatic And Musculoskeletal Diseases*, 10(2). doi:10.1136/rmdopen-2024-004199

Version: Publisher's Version









License: [Creative Commons CC BY-NC 4.0 license](https://creativecommons.org/licenses/by-nc/4.0/)

Downloaded from: <https://hdl.handle.net/1887/3768944>

**Note:** To cite this publication please use the final published version (if applicable).

## SHORT REPORT

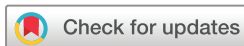# Inflammation in the posterior elements, in particular the facet joint and facet joint ankylosis over 2-year follow-up in radiographic axial spondyloarthritis

Manouk de Hooge <sup>1</sup>, Roos Stal,<sup>2</sup> Alexandre Sepriano <sup>2,3</sup>, Xenofon Baraliakos <sup>4</sup>, Monique Reijniere <sup>5</sup>, Jürgen Braun <sup>6,7</sup>, Désirée van der Heijde <sup>2</sup>, Floris A van Gaalen <sup>2</sup>, Sofia Ramiro <sup>2,8</sup>

**To cite:** de Hooge M, Stal R, Sepriano A, *et al.* Inflammation in the posterior elements, in particular the facet joint and facet joint ankylosis over 2-year follow-up in radiographic axial spondyloarthritis. *RMD Open* 2024;**10**:e004199. doi:10.1136/rmdopen-2024-004199

► Additional supplemental material is published online only. To view, please visit the journal online (<https://doi.org/10.1136/rmdopen-2024-004199>).

Received 7 February 2024  
Accepted 21 May 2024



© Author(s) (or their employer(s)) 2024. Re-use permitted under CC BY-NC. No commercial re-use. See rights and permissions. Published by BMJ.

For numbered affiliations see end of article.

### Correspondence to

Dr Manouk de Hooge;  
msmdehooge@gmail.com

### ABSTRACT

**Objectives** To assess the association of posterior element (PE) and facet joint (FJ) inflammation with subsequent new FJ ankylosis (FJA) on MRI, in patients with radiographic axial spondyloarthritis (r-axSpA).

**Methods** Patients from the Sensitive Imaging in Ankylosing Spondylitis cohort, inclusion criteria r-axSpA and  $\geq 1$  radiographic spinal syndesmophyte, were studied. MRI of the full spinal was performed at baseline, 1 and 2 years. PE/FJ inflammatory lesions and FJA were assessed per vertebral unit (VU) level by three readers. With multilevel time-lagged autoregressive generalised estimated equations, the association between PE/FJ inflammation and the subsequent development of FJA was investigated, taking the reader and VU levels into account.

**Results** Out of the 58 patients with at least 2 reader scores available, mean age 49 (SD 10) years, 84% men, 59% had baseline PE inflammation, 24% had FJ inflammation and 26% had FJA. PE inflammation was more prevalent in the lower thoracic spine and FJ inflammation in the upper thoracic spine. VU with PE or FJ inflammation showed subsequent new FJA in two and one VU levels, respectively. The probability of developing FJA doubled with prior FJ inflammation. In multilevel analysis, FJ inflammation was associated with subsequent FJA (OR=3.8, 95% CI: 1.5 to 9.8), while no association was found between PE inflammation and new FJA (OR=1.2 (0.6–2.4)).

**Conclusions** FJ inflammation is rare in severe r-axSpA, but when present, the likelihood of developing subsequent FJA is over three times higher compared with FJ without inflammation. This finding contributes to the understanding of the relationship between inflammation and ankylosis at the same anatomical location in patients with axSpA.

### INTRODUCTION

Axial spondyloarthritis (axSpA) is an inflammatory rheumatic and musculoskeletal disease characterised by inflammation and subsequent structural damage in the sacroiliac joints and the spine.<sup>1 2</sup> In radiographic

### WHAT IS ALREADY KNOWN ON THIS TOPIC

⇒ Inflammation in vertebral bodies progresses into syndesmophyte formation over time.

### WHAT THIS STUDY ADDS

⇒ Inflammation/ankylosis in facet joints (FJs), seen on MRI, is rare in patients with radiographic axial spondyloarthritis (axSpA).  
⇒ FJ ankylosis develops more frequently when inflammation is reported 1 year earlier.

### HOW THIS STUDY MIGHT AFFECT RESEARCH, PRACTICE OR POLICY

⇒ These findings underline the pathophysiological relationship between FJ inflammation and ankylosis in axSpA.

axSpA (r-axSpA), bone formation in the form of syndesmophytes is the most distinct form of spinal structural damage. Radiography and CT are considered the best imaging techniques to assess spinal cortical bone lesions such as syndesmophytes as well as typical lesions such as vertebral endplate sclerosis (shiny corners) and erosions. However, a drawback of these imaging techniques, especially in research setting, is the patient's exposure to radiation. Unlike radiography and CT, MRI is radiation free and it captures both inflammatory and structural lesions. However, the assessment of lesions such as syndesmophytes or erosions on MRI has been proven challenging.<sup>3</sup>

Not only lesions in the vertebra but also erosions and ankylosis of the facet joints (FJs), which are part of the posterior elements (PEs) of the spine, are common findings in r-axSpA.<sup>4 5</sup> Inflammatory and structural lesions in these joints are associated with decreased functional status and restricted spinal mobility, affecting patient's daily

activities.<sup>6</sup> Nevertheless, FJ damage in axSpA is often neglected.

In the Sensitive Imaging in Ankylosing Spondylitis (SIAS) cohort, a study population also used in the current study, inflammation in the vertebral body has been shown to progress into syndesmophyte formation over time.<sup>2</sup> Therefore, it is possible, but not yet tested, that inflammation in FJ also leads to new bone formation (ankylosis). Our hypothesis is that FJ ankylosis (FJA) follows the same progressive disease pattern as syndesmophytes in the vertebral units (VUs). Hence, the objective of this study to assess whether inflammation of the PE, in particular in the FJ, is associated with subsequent new FJA on MRI in patients with r-axSpA.

## METHODS

Adult patients with a diagnosis of r-axSpA recruited from the Netherlands (Leiden) and Germany (Herne) were included in the SIAS prospective cohort.<sup>7</sup> Additionally to radiographic sacroiliitis, all patients had  $\geq 1$  inflammatory lesion on MRI of the spine and 1–18 syndesmophytes evaluated on cervical and lumbar conventional radiographs. There was a 2-year follow-up period during which patients attended three visits (baseline, 1 year and 2 years) and were treated at the discretion of their rheumatologist. Patients were excluded when pregnant or if there were contraindications for performing MRI. Patients were only included in the current study if MRI scores of  $\geq 2$  readers in  $\geq 2$  time points were available.

### MRI assessment

MRI details have been published.<sup>8</sup> MRI of the spine was performed at baseline, 1-year and 2-year follow-up. MRI images were acquired in Leiden and Herne, respectively, on a 3T MRI (Philips Medical systems, Best, the Netherlands) and 1.5T MRI (Siemens, Erlangen, Germany) scanner. The focus of this study was on PE abnormalities only. All PE lesions were assessed in the sagittal plane, using short tau inversion recovery and T1-weighted sequences. PE lesions were assessed according to the Canada–Denmark scoring methods for spinal lesions,<sup>9,10</sup> meaning that the presence of inflammation in the PE, including the FJ, and FJA were assessed per VU. As the FJs are part of the PE, all PE lesions were assessed simultaneously; lesions in the FJ were not assessed separately. From C2–C3 to C6–C7, PE inflammation is assessed in the pedicles and posterior soft tissues at enthesal attachments, as the posterior arch is treated as a single structure in the cervical spine. In the thoracic (from C7–T1 to T11–T12) and lumbar spine (from T12–L1 to L5–S1), inflammatory changes are identified in four components: pedicles, FJ, combined transverse and spinous processes, and posterior soft tissues. FJ inflammation was defined as an increased signal in bone marrow on short tau inversion recovery or T2-weighted fat-suppressed MRI sequence in  $\geq 1$  facet of an FJ. No differentiation between left or right FJ was made. FJA was assessed throughout the whole spine

(from C2–C3 to L5–S1). Inflammatory lesions and FJA were scored dichotomously as 0 (absent) or 1 (present) per VU level by three readers independently and blinded for time sequence. All readers had  $>7$  years experience in MRI assessment in axSpA.

All the scores provided in this study were original. Once all MRIs had been collected for baseline and follow-up, the images were assessed. The readings used in this study were part of the CRF for MRI assessment.

### Statistical analyses

First, the frequency of PE inflammation and FJA was analysed using heat maps, reflecting the proportion of patients with affected VUs. For descriptive purposes, lesions were reported when  $\geq 2$  out of 3 readers agreed on the scores (consensus score).

The development of FJA could be either from baseline to year 1 or from year 1 to year 2. The analyses focused exclusively on new FJA, therefore considering only VUs without preceding FJA. The probability of developing FJA after one year was described conditional on the presence or absence of PE or FJ inflammation 1 year before. To investigate the association between PE (or FJ) inflammation and the development of new FJA at VU level, multilevel time-lagged autoregressive generalised estimating equations (GEE) models were used, with a 1 year lag between inflammation and new ankylosis. Applying this method allowed us to use all scores (ie, from all time points) of all VU levels as well as the individual reader scores, taking into account the correlations within a reader and patient (eg, VUs from the same patient are associated) using an exchangeable correlation structure.

Analyses were performed with STATA V.17.

## RESULTS

In total, 58 patients were included with available follow-up data; 6 patients had 2 time points and 52 had 3 time points; 1 patient had 2 readers' scores instead of 3. The mean age was 49 (SD 10) years, 84% men, 84% Human Leukocyte Antigen-B (HLA-B27) positive (online supplemental table 1). Reliability data showed a moderate agreement between readers for inflammation (intraclass correlation coefficient (ICC)=0.69) and ankylosis (ICC=0.68).

Figure 1 shows the number of patients with PE abnormalities per VU based on consensus reader scores. Baseline inflammation in any part of the PE, in at least one VU, was seen in 34 (59%) patients and in 14 (24%) patients FJ inflammation was reported. PE inflammation was distributed throughout the whole spine, but most prevalent in the lower part of the thoracic spine (9%–16% of patients, depending on the time point). FJ inflammation was infrequently present and was more often reported in the upper thoracic spine (2%–5% of patients) (figure 1). FJA was reported in 15 (26%) patients at baseline and 17 (29%) patients at follow-up. FJA was mainly reported in the upper half of the spine (figure 1).



	VU	Baseline			1 year visit			2 years visit			VU
		Posterior element inflammation	Facet joint inflammation	Facet joint ankylosis	Posterior element inflammation	Facet joint inflammation	Facet joint ankylosis	Posterior element inflammation	Facet joint inflammation	Facet joint ankylosis	
C2-C3	1	0	Not assessed	1	0	Not assessed	2	0	Not assessed	2	1
C3-C4	2	0	Not assessed	5	1	Not assessed	6	1	Not assessed	5	2
C4-C5	3	0	Not assessed	6	1	Not assessed	7	1	Not assessed	7	3
C5-C6	4	0	Not assessed	5	1	Not assessed	6	1	Not assessed	6	4
C6-C7	5	1	Not assessed	6	1	Not assessed	6	1	Not assessed	6	5
C7-T1	6	2	0	6	2	0	6	2	1	7	6
T1-T2	7	3	2	11	1	0	11	3	1	11	7
T2-T3	8	2	2	10	4	0	10	5	3	12	8
T3-T4	9	6	1	8	5	1	7	6	0	8	9
T4-T5	10	5	2	6	6	3	8	9	1	8	10
T5-T6	11	4	1	6	8	2	7	4	0	10	11
T6-T7	12	9	2	6	8	0	5	4	1	7	12
T7-T8	13	9	1	5	7	0	6	6	3	6	13
T8-T9	14	5	0	6	5	0	6	5	0	6	14
T9-T10	15	9	0	3	7	1	4	5	0	4	15
T10-T11	16	9	0	1	8	1	1	7	0	1	16
T11-T12	17	9	1	2	3	0	3	5	0	3	17
T12-L1	18	2	0	2	2	2	1	2	1	1	18
L1-L2	19	2	0	0	0	0	0	2	0	1	19
L2-L3	20	2	1	0	1	0	0	3	0	2	20
L3-L4	21	2	0	1	3	1	1	4	3	2	21
L4-L5	22	3	0	0	3	1	0	4	0	1	22
L5-S1	23	0	0	0	1	0	0	2	0	1	23

Legend: Colour intensity represents the magnitude of patients with posterior element lesions according to consensus score (2 out of 3 readers)

No lesions present Maximum number of patients with lesions present

**Figure 1** Patients with posterior element inflammation and/or facet joint ankylosis on MRI across 23 vertebral units (VUs) over 2-year follow-up in radiographic axial spondyloarthritis patients, based on consensus reader scores.

In 19 patients (33%), the development of new FJA over 1 or 2 years was seen by at least 1 reader, in at least 1 VU. Patients who developed FJA showed similar baseline characteristics compared with those without new FJA, with a slightly higher frequency of extra-musculoskeletal and peripheral manifestations as well as conventional synthetic disease-modifying antirheumatic drugs/tumor necrosis factor inhibitors use in those with FJA (online supplemental table 1).

At the VU level, there were 7751 VU in which the development of FJA was possible given the absence of prior FJA. The vast majority (7706/7751) showed no facet ankylosis development over 1 year according to at least 1 reader, regardless of the presence of previous inflammation. Of the 513 VU levels with PE inflammation, only 2 VU levels showed new FJA after 1 year. There are 6066 VU in which FJ inflammation could be assessed, of which only 39 demonstrated new FJA. Among these, 38 FJ displayed no inflammation 1 year prior to ankylosis, while inflammation preceded ankylosis in only one FJ. FJ inflammation was observed in 94 VU levels, of which 93 did not develop FJA over time. Nevertheless, the probability of developing FJA was almost two times as high if preceded by FJ inflammation 1 year before (1.1% vs 0.6%). This trend was not seen with inflammation in any part of the PE (table 1). These findings are confirmed by the multilevel analyses, as there was no association between PE inflammation and the development of FJA at the same level after 1 year (OR=1.15, 95% CI: 0.55 to 2.42). However, FJ inflammation was associated with new FJA 1 year later (OR=3.79, 95% CI: 1.47 to 9.75). Figure 2 shows an example of the development from FJ inflammation to FJA 1 year later.

## DISCUSSION

The findings of this study underline the relationship between inflammation and ankylosis in axSpA, demonstrating that the presence of FJ inflammation is associated with higher odds for the development of subsequent FJA at the same spinal location. This association persists despite the low frequency of lesions in the FJ.

To the best of our knowledge, this is the first study to focus on the concept of inflammation in PE progressing to FJA in MRI. Generally, the literature on FJ damage among patients with axSpA is limited. Studies on established axSpA report FJA in 25% and 18% of patients with r-axSpA having average disease durations of 16 and 7 years, respectively, both relying on radiography and concentrating on cervical FJ.<sup>4,11</sup> Conversely, low dose CT data show that >50% of patients with axSpA (symptom duration >10 years) have ≥1 ankylosed FJ.<sup>12,13</sup> In our study, the prevalence of FJA was 26% at baseline and 29% at follow-up, aligning with average ranges reported in studies using radiography.

Concerning inflammation in the PE, our study's 59% prevalence aligns with the existing literature, although reported lesions vary substantially across studies, ranging from 8% (nr-axSpA) to 26% (r-axSpA) to outlying studies reporting 76% and 88% in patients with r-axSpA.<sup>14-16</sup> This diversity likely stems from the varied study populations and imaging methods. In contrast, Lee *et al* found <5% FJ inflammation in patients with axSpA with recent back pain, while our study identified a 24% prevalence in severe patients with r-axSpA with longer disease duration, suggesting FJ inflammation may be more common in severe cases.<sup>17</sup>

**Table 1** Probability and OR of developing FJ ankylosis with and without PE inflammation 1 year prior, in patients with radiographic axial spondyloarthritis

Inflammation in any part of the PEs					
PE inflammation	New FJ ankylosis after 1 year	N*	Probability of FJ ankylosis conditional on PE inflammation P (FJ ankylosis   PE inflammation)	Multilevel model OR (95% CI)	
0	0	7195	P (FJ ankylosis   0)=43/7238=0.6%	1.15 (0.55 to 2.42)	
0	1	43			
1	0	511	P (FJ ankylosis   1)=2/513=0.4%		
1	1	2			
Inflammation in the FJ					
FJ inflammation	New FJ ankylosis after 1 year	N†	Probability of FJ ankylosis conditional on FJ inflammation P (FJ ankylosis   FJ inflammation)	Multilevel model OR (95% CI)	
0	0	5934	P (FJ ankylosis   0)=38/5972=0.6%	3.79 (1.47 to 9.75)	
0	1	38			
1	0	93	P (FJ ankylosis   1)=1/94=1.1%		
1	1	1			

How to read the table: this table needs to be read from left to right. Every line represents a condition. For example, there are 7195 VU in which there is no PE inflammation and no FJ ankylosis. The last two columns contain the probability of FJ ankylosis if there was or was not PE inflammation, and the corresponding OR from the GEE model.

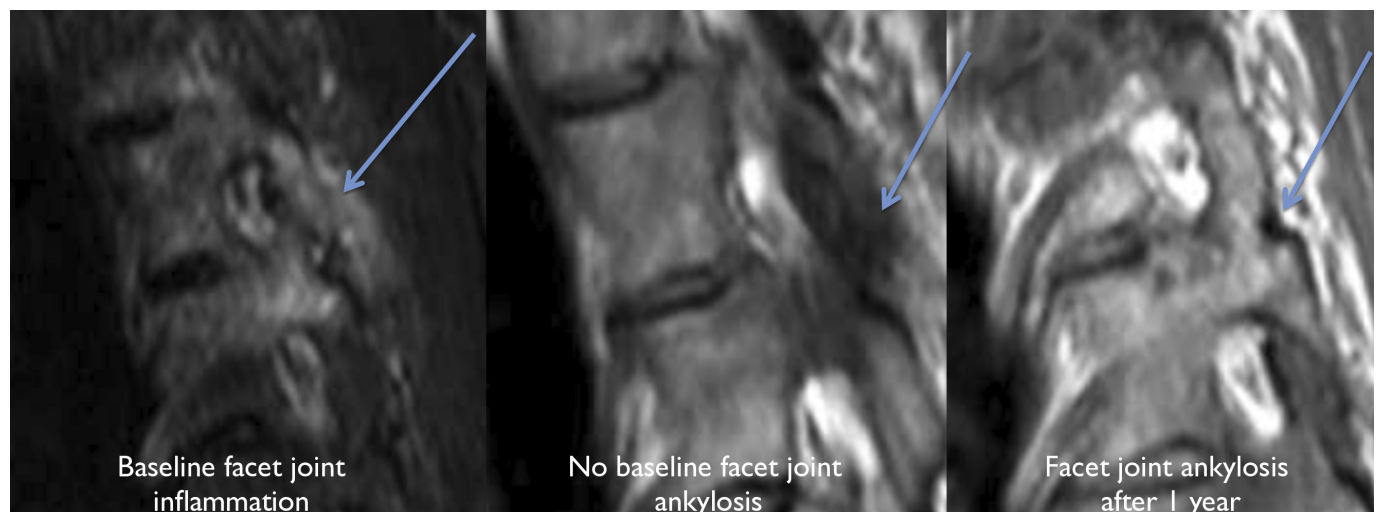\*Number of VU levels with inflammation in at least one part of the PEs (pedicle, FJ, processes spinosi, soft tissue).

†Number of FJs.

FJ, facet joint; P, probability (scale 0–1); PE, posterior elements.

This study reports a moderate number of patients with inflammatory lesions of the PE and FJA. However, the vast majority of VU exhibit no PE abnormalities. To address the objective of this study, we assessed the development of newly ankylosed FJ, which was also low. Of the VU levels with PE or FJ inflammation, only very few showed new FJA after 1 year: two and one VU levels, respectively. Nevertheless, the probability of developing FJA was almost two times as high if preceded by FJ inflammation 1 year before (1.1% vs 0.6%). It is important to emphasise that these proportions are descriptive and do

not account for various dependencies between factors, such as readers or the interdependence of VU levels within each subject. To address this, we used multilevel longitudinal models considering interdependence when assessing the relationship using all cases and considering all within-patient and within-reader correlations. Hence, the models also account for the most frequent situations of absence of FJA following the absence of FJ inflammation. In line with what the descriptive data showed, no association was observed between inflammation anywhere in the PE and the development of FJA. It



**Figure 2** The development for facet joint inflammation to facet joint ankylosis after 1 year in a patient with severe radiographic axial spondyloarthritis.

suggests that considering inflammation in any part of the PE is overly broad and lacks the specificity needed to be linked to new FJA. Inflammation in different parts of the PE may have diverse underlying pathological mechanisms, making it challenging to establish a direct link to new FJA. Also, PE encompass various anatomical regions, each potentially responding differently to inflammation.

Among the various PE, FJ plays a crucial role. They govern and guide vertebral motion, facilitate load transmission onto the spine and contribute to spinal stability.<sup>18</sup> FJ damage is frequently observed in ageing individuals. Given that our cohort consists of older individuals, degeneration may be a contributing factor to the reported damage. Nevertheless, degenerative changes in the FJ are commonly prevalent in the lumbosacral area, as opposed to the FJ damage mostly at the thoracic level reported in this study, suggesting a higher likelihood of being secondary to axSpA. Given the specific role of FJ, it is logical to assume that explicitly FJ inflammation may play a role in the bone proliferation within these joints. Indeed, our observations support this assumption; the likelihood of new FJA 1 year later is over three times higher (OR=3.79) when FJ inflammation at the same level is seen. Furthermore, these results carry conceptual significance, as they underline the pathophysiological link between bone inflammation and bone damage. While previous studies have indicated this in vertebral bodies, our study provides evidence of this phenomenon in the FJ.<sup>1 2 19</sup>

A limitation to this study is the lack of a radiologist in the reading evaluation. One could argue that identifying structural lesions on MRI in general is a challenging task, even for an experience radiologist, especially when assessing spinal lesions, because of complex differential diagnoses. This should be taken into account when evaluating results on structural MRI lesions in general. Nevertheless, the reader team had >7 years experience in MRI structural lesion assessment in axSpA. The current study cohort was previously used to investigate whether the presence of bridging syndesmophytes increased the risk of FJA and vice versa using CT. Though not the primary objective of the study, the disease course phenomenon in FJ was reported, showing a twofold increase in likelihood of new FJA on CT when inflammation in the PE was present 2 years prior.<sup>8</sup> CT imaging offers superior detail regarding bone structure and is highly sensitive to ligamentous calcifications.<sup>20</sup> MRI excels in evaluating inflammation but may be less sensitive in assessing structural lesions. Syndesmophytes are more reliably assessed on CT compared with MRI. However, the present study examined both inflammatory and structural lesions using MRI due to the advantages it offers. While low-dose CT exists, it still involves radiation, unlike MRI, which is radiation free. Additionally, obtaining an MRI of the spine in clinical practice is more feasible compared with obtaining both a CT (for

structural lesion assessment) and an MRI (for inflammatory lesion assessment).

It is important to exercise caution when extrapolating the findings of this study to other (radiographic) axSpA populations as the generalisability of these findings is limited due to the specific study population of patients with longstanding r-axSpA in whom active and structural spinal damage was present at baseline.

In summary, this study reports a moderate number of patients with r-axSpA with inflammatory or structural lesions in the FJ mainly at the thoracic level, consistent with the literature. However, on VU level, lesions are infrequently observed. Nevertheless, in patients with r-axSpA with FJ inflammation, there is a threefold increased risk of developing FJA at the same site 1 year later. This finding contributes to our understanding of the pathophysiological relationship between inflammation and ankylosis at the same anatomical location of the axial skeleton in patients with axSpA.

#### Author affiliations

- <sup>1</sup>Department of Rheumatology, UZ Gent, Gent, Oost-Vlaanderen, Belgium
- <sup>2</sup>Department of Rheumatology, LUMC, Leiden, Zuid-Holland, The Netherlands
- <sup>3</sup>CHRC Campus Nova Medical School, Lisboa, Portugal
- <sup>4</sup>Rheumazentrum Ruhrgebiet, Ruhr University Bochum, Herne, Germany
- <sup>5</sup>Department of Radiology, LUMC, Leiden, Zuid-Holland, The Netherlands
- <sup>6</sup>Rheumatologisches Versorgungszentrum Steglitz, Berlin, Germany
- <sup>7</sup>Ruhr University Bochum, Bochum, Germany
- <sup>8</sup>Zuyderland Medical Centre, Heerlen, Limburg, The Netherlands

**Contributors** Conceptualisation: MdH, DvdH, FAvG and SR. Formal analysis: MdH. Investigation: MdH. Methodology: MdH, RS, AS, DvdH, FAvG and SR. Supervision: SR. Discussion and interpretation of results: MdH, RS, AS, XB, MR, JB, DvdH, FAvG and SR. Review and approval of manuscript: All authors.

**Funding** The SIAS cohort was funded by 'ReumaNederland' (Dutch Rheumatism Foundation).

**Competing interests** None declared.

**Patient consent for publication** Not applicable.

**Ethics approval** This study involves human participants. Ethics approval for the study was obtained from the institutional review board at each centre (Leiden Medisch Ethische Toetsings Commissie number: P10.021; Herne Ethikkommission der Ruhr Universität Bochum number: 4366-12). Participants gave informed consent to participate in the study before taking part.

**Provenance and peer review** Not commissioned; externally peer reviewed.

**Supplemental material** This content has been supplied by the author(s). It has not been vetted by BMJ Publishing Group Limited (BMJ) and may not have been peer-reviewed. Any opinions or recommendations discussed are solely those of the author(s) and are not endorsed by BMJ. BMJ disclaims all liability and responsibility arising from any reliance placed on the content. Where the content includes any translated material, BMJ does not warrant the accuracy and reliability of the translations (including but not limited to local regulations, clinical guidelines, terminology, drug names and drug dosages), and is not responsible for any error and/or omissions arising from translation and adaptation or otherwise.

**Open access** This is an open access article distributed in accordance with the Creative Commons Attribution Non Commercial (CC BY-NC 4.0) license, which permits others to distribute, remix, adapt, build upon this work non-commercially, and license their derivative works on different terms, provided the original work is properly cited, appropriate credit is given, any changes made indicated, and the use is non-commercial. See: <http://creativecommons.org/licenses/by-nc/4.0/>.

#### ORCID iDs

- Manouk de Hooge <http://orcid.org/0000-0002-0652-9808>
- Alexandre Sepriano <http://orcid.org/0000-0003-1954-0229>
- Xenofon Baraliakos <http://orcid.org/0000-0002-9475-9362>
- Monique Reijnen <http://orcid.org/0000-0002-6906-1851>
- Jürgen Braun <http://orcid.org/0000-0002-9156-5095>



Désirée van der Heijde <http://orcid.org/0000-0002-5781-158X>  
 Floris A van Gaalen <http://orcid.org/0000-0001-8448-7407>  
 Sofia Ramiro <http://orcid.org/0000-0002-8899-9087>

## REFERENCES

- Machado PM, Baraliakos X, van der Heijde D, et al. MRI vertebral corner inflammation followed by fat deposition is the strongest contributor to the development of new bone at the same vertebral corner: A Multilevel longitudinal analysis in patients with Ankylosing Spondylitis. *Ann Rheum Dis* 2016;75:1486–93.
- Stal R, Baraliakos X, van der Heijde D, et al. Role of vertebral corner inflammation and fat deposition on MRI on Syndesmophyte development detected on whole spine low-dose CT scan in radiographic axial Spondyloarthritis. *RMD Open* 2022;8:e002250.
- Reijniers M. Radiographic/MR imaging correlation of Paravertebral Ossifications in Ligaments and bony vertebral Outgrowths: anatomy, early detection, and clinical impact. *Magn Reson Imaging Clin N Am* 2019;27:641–59.
- Maas F, Spoorenberg A, Brouwer E, et al. Radiographic damage and progression of the Cervical spine in Ankylosing Spondylitis patients treated with TNF-A inhibitors: facet joints vs. vertebral bodies. *Semin Arthritis Rheum* 2017;46:562–8.
- Stal R, van Gaalen F, Sepriano A, et al. Facet joint Ankylosis in R-axSpA: detection and 2-year progression on whole spine low-dose CT and comparison with Syndesmophyte progression. *Rheumatology (Oxford)* 2020;59:3776–83.
- Chui ETF, Tsang HHL, Lee KH, et al. MRI inflammation of facet and Costovertebral joints is associated with restricted spinal mobility and worsened functional status. *Rheumatology (Oxford)* 2020;59:2591–602.
- de Bruin F, de Koning A, van den Berg R, et al. Development of the CT Syndesmophyte score (CTSS) in patients with Ankylosing Spondylitis: data from the SIAS cohort. *Ann Rheum Dis* 2018;77:371–7.
- Stal R, Sepriano A, van Gaalen FA, et al. Associations between Syndesmophytes and facet joint Ankylosis in radiographic axial Spondyloarthritis patients on low-dose CT over 2 years. *Rheumatology (Oxford)* 2022;61:4722–30.
- Ostergaard M, Maksymowich WP, Pedersen SJ, et al. Structural lesions detected by magnetic resonance imaging in the spine of patients with Spondyloarthritis - definitions, assessment system, and reference image set. *The Journal of Rheumatology Supplement* 2009;84:18–34.
- Lambert RGW, Pedersen SJ, Maksymowich WP, et al. Active inflammatory lesions detected by magnetic resonance imaging in the spine of patients with Spondyloarthritis - definitions, assessment system, and reference image set. *The Journal of Rheumatology Supplement* 2009;84:3–17.
- Lee T-H, Lee S, Koo BS, et al. Radiographic involvement of Cervical facet joints in Ankylosing Spondylitis: a longitudinal analysis in correlation with vertebral body lesions. *BMC Rheumatol* 2023;7:11.
- Jung J-Y, Kim M-Y, Hong YS, et al. Association between facet joint Ankylosis and functional impairment in patients with radiographic axial Spondyloarthritis. *Semin Arthritis Rheum* 2021;51:1005–10.
- Lee B-W, Jung J-Y, Kim M-Y, et al. Prevalence and associated factors of facet joint Ankylosis in patients with axial Spondyloarthritis. *J Rheumatol* 2023;50:763–8.
- Althoff CE, Sieper J, Song I-H, et al. Active inflammation and structural change in early active axial Spondyloarthritis as detected by whole-body MRI. *Ann Rheum Dis* 2013;72:967–73.
- Maksymowich WP, Crowther SM, Dhillon SS, et al. Systematic assessment of inflammation by magnetic resonance imaging in the posterior elements of the spine in Ankylosing Spondylitis. *Arthritis Care & Research* 2010;62:4–10.
- Bochkova AG, Levshakova AV, Bunchuk NV, et al. Spinal inflammation lesions as detected by magnetic resonance imaging in patients with early Ankylosing Spondylitis are more often observed in posterior structures of the spine. *Rheumatology (Oxford)* 2010;49:749–55.
- Lee S, Lee JY, Hwang JH, et al. Clinical importance of inflammatory facet joints of the spine in Ankylosing Spondylitis: a magnetic resonance imaging study. *Scand J Rheumatol* 2016;45:491–8.
- Yang KH, King AI. Mechanism of facet load transmission as a hypothesis for low-back pain. *Spine* 1984;9:557–65.
- van der Heijde D, Machado P, Braun J, et al. MRI inflammation at the vertebral unit only marginally predicts new Syndesmophyte formation: A Multilevel analysis in patients with Ankylosing Spondylitis. *Ann Rheum Dis* 2012;71:369–73.
- Hermann K-GA, Althoff CE, Schneider U, et al. Spinal changes in patients with Spondyloarthritis: comparison of MR imaging and radiographic appearances. *RadioGraphics* 2005;25:559–69.