



Universiteit
Leiden
The Netherlands

Congenital heart defects: from a prenatal perspective

Nisselrooij, A.E.L. van

Citation


Nisselrooij, A. E. L. van. (2024, June 20). *Congenital heart defects: from a prenatal perspective*. Retrieved from <https://hdl.handle.net/1887/3764455>

Version: Publisher's Version

License: [Licence agreement concerning inclusion of doctoral thesis in the Institutional Repository of the University of Leiden](#)

Downloaded from: <https://hdl.handle.net/1887/3764455>

Note: To cite this publication please use the final published version (if applicable).



CHAPTER 6

Postnatal outcome of fetal isolated ventricular size disproportion in the absence of aortic coarctation

Amber E.L van Nisselrooij, Lieke Rozendaal, Ingeborg H. Linskens,
Sally-Ann Clur, Jarda Hruda, Eva Pajkrť, Christine L. van Velzen,
Nico A. Blom, Monique C. Haak

Ultrasound Obstet Gynecol. 2018 Nov;52(5):593-598.

ABSTRACT

Objectives

Cardiac ventricular size disproportion is a fetal marker for aortic coarctation (CoA), but approximately 50% of fetuses do not have CoA after birth. The aim of this study was to evaluate the postnatal outcome of cases with fetal ventricular size disproportion in the absence of CoA after birth.

Methods

All cases with fetal isolated ventricular size disproportion diagnosed between 2002 and 2015 were extracted from a regional registry with prenatal congenital heart defects. Cases were stratified according to presence (CoA) or absence (non-CoA) of aortic arch anomalies after birth. Postnatal outcome of non-CoA cases was evaluated by assessing the presence of cardiac and other congenital malformations, genetic syndromes and other morbidity after birth. Non-CoA cases were further classified according to whether they had cardiovascular pathology requiring medication or intervention.

Results

Seventy-seven cases with fetal ventricular size disproportion were identified, of which 46 (60%) did not have CoA after birth. Of these, 35 did not require cardiovascular intervention or medication, whereas 11 did. Of the 46 non-CoA cases, six presented with clinical pulmonary hypertension requiring treatment after birth, 24 cases had cardiac defects and four presented syndromic features. Overall, 43% of all non-CoA children were still under surveillance at the end of the study period.

Conclusions

The postnatal course of cases with fetal ventricular size disproportion is complicated by prenatally undetected congenital defects (46%) and pulmonary or transition problems (35%) in a significant number of cases that do not develop CoA. Proper monitoring of these cases is therefore warranted and it is advisable to incorporate the risks for additional morbidity and neonatal complications in prenatal counseling.

INTRODUCTION

Aortic coarctation (CoA) accounts for approximately 4-6% of all congenital heart defects and frequently requires surgery in the first year of life.^{1,2} Prenatal diagnosis of CoA is important as timely management with prostaglandins after birth can prevent clinical deterioration of the neonate before surgery, resulting in a lower mortality rate.³ Ventricular and semilunar valve-size disproportion, with a smaller left side on fetal ultrasound are considered predictors of CoA.⁴ However, given the moderate sensitivity and low specificity of these ultrasonographic signs⁴⁻⁹, the prenatal diagnosis remains challenging. The low specificity can be attributed to the difficulty in differentiating between physiological enlargement of the right ventricle and pathological ventricular size disproportion.¹⁰

Over the past decade, most studies in this area have focused on the improvement of prenatal detection of CoA.¹⁰⁻¹⁴ Despite a false-positive rate of around 50% for the finding of fetal cardiac disproportion¹²⁻¹³, hardly any studies have assessed the postnatal course and long-term outcome of fetuses with ventricular size disproportion for whom aortic surgery was not required.

We hypothesize that ventricular size disproportion is accompanied by, or is the result of, an altered fetal circulation that may have an effect on cardiac and pulmonary development. The main objective of this study was to explore the postnatal outcome, with a focus on pulmonary complications in particular, of cases diagnosed prenatally with isolated fetal ventricular size disproportion in the absence of CoA postnatally.

METHODS

The tertiary care centers of the regions Amsterdam and Leiden, including the Leiden University Medical Center and the Amsterdam University Medical Centers, collaborate in the care for children with congenital heart defects. This collaboration is named Center for Congenital Heart Defects Amsterdam Leiden (CAHAL) and covers an area of approximately 40% of all live births in the Netherlands, which is equivalent to 72 000 infants per year. Since 2002, all fetuses and infants diagnosed in CAHAL with a *severe* congenital heart defect (CHD) have been registered. A severe CHD is defined as cases born with a CHD requiring a therapeutic cardiac intervention or cardiac surgery in the first year of life. All pregnant women are seen by both a pediatric cardiologist and a fetal medicine specialist, who collaborate closely in the care of fetuses with CHD in these centers. The prevalence of severe congenital heart defects in this registry is 2,0 per 1000 live births, which corresponds with the generally accepted prevalence of severe CHDs.^{1,2} Data collection for the CAHAL regional cohort registry has been described previously.¹⁵

All cases with fetal ventricular size disproportion, diagnosed between 2002 and 2015, were extracted from this registry. We included all cases diagnosed with isolated ventricular size disproportion in which parents were counseled about the possibility that the neonate might develop CoA after birth and postnatal intensive care admission was initiated to monitor ductal closure. Since only cases with isolated ventricular size disproportion were included, no other antenatally detected cardiac or non-cardiac defects were present. Cases with ventricular disproportion with persistent left superior vena cava (PLSVC) were included if it was decided prenatally to admit the neonate for ductal closure monitoring.¹⁶ Cases born before 36 weeks' gestational age were excluded, as it is difficult to distinguish whether morbidity is due to prematurity or ventricular disproportion in these cases.

Cases were classified into those that developed CoA or hypoplastic aortic arch requiring aortic arch surgery within the first year postpartum (CoA group) and those that did not develop aortic arch anomaly (non-CoA group). For the cases that did not develop CoA postnatally, the aortic valve (AoV) and pulmonary valve (PV) diameters were extracted from the database. If these measurements could not be retrieved from the patient file, original images or videoclips were obtained and the measurements were performed on these. The AoV/PV ratio was calculated to rule out the effect of both gestational age and small- or large-for-gestational age, and the measurements were also converted to Z-scores based on gestational age.¹⁷ In cases with serial measurements, the last complete echocardiogram before delivery was used.

According to postnatal outcome, non-CoA cases were subsequently stratified according to whether they required cardiovascular intervention or medication (treatment) or not (non-treatment). The treatment group included cases that required medication or an intervention to treat cardiovascular diseases that were not or could not have been detected prenatally.

Pediatric charts were assessed to retrieve data on postnatal outcome. We assessed baseline characteristics such as age and sex in both the non-CoA and the CoA groups. To evaluate the outcome in the non-CoA group in particular, we assessed the postnatal presence of cardiac and extracardiac (congenital) malformations, syndromes or other chromosomal anomalies, the presence of neonatal pulmonary hypertension, drug administration, number of interventions and number of admissions to the hospital in the first year after birth.

Pulmonary hypertension (PH) was defined as failure of the normal postnatal decline of pulmonary vascular resistance that may be associated with oxygenation failure or right ventricular dysfunction. The severity of PH was based on its duration. PH was defined as need for respiratory support or vasodilators, with or without use of diuretics. The duration of PH was scored as either self-limiting (< 6 weeks) or persistent (> 6 weeks). If PH developed at a later stage as the consequence of a cardiac malformation, rather than as a result of alterations in hemodynamics during transition, it was scored as 0. The following grading system for PH was used: 0 = absence of PH; 1 = self-limiting PH; 2 = persistent PH.

Baseline characteristics in both groups were analyzed using SPSS Statistics 22.0 (IBM Corp., Armonk, NY, USA). An independent *t*-test was used to test numeric variables for significance. The chi-square test was used to compare categorical variables and calculate odds ratios. A *P*-value of < 0.05 was considered statistically significant. For all other variables, descriptive statistics were used to outline the expected heterogeneity in possible outcomes.

RESULTS

Between 1 January 2002 and 31 December 2015, 100 women were referred to one of the three centers because of a prenatally diagnosed ventricular left-right disproportion. Additional cardiac and non-cardiac abnormalities were present in 11 cases (non-isolated), disproportion normalized during pregnancy in 8 cases and a premature birth (<36 weeks) occurred in 4 cases. Thus, 23 cases were excluded, leaving 77 cases available for analysis (Figure 1).

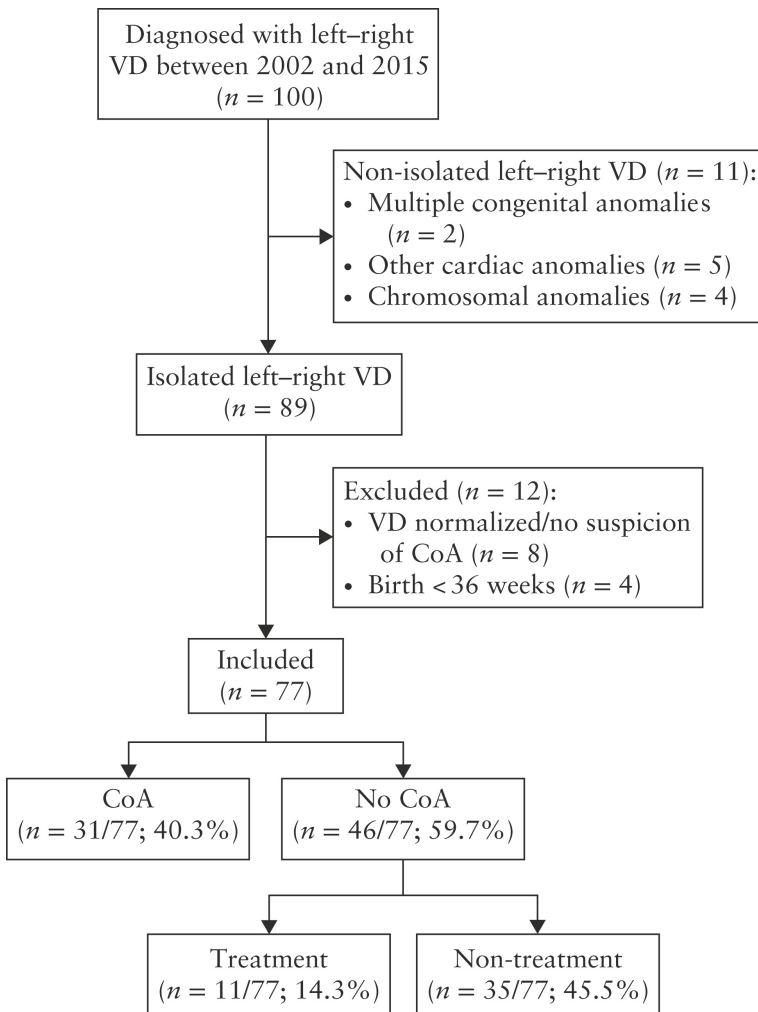


Figure 1: Flowchart showing inclusion in study and postnatal outcome of pregnancies diagnosed prenatally with left-right ventricular size disproportion (VD).

CoA, aortic coarctation.

All 77 cases with isolated prenatal ventricular size disproportion were initially admitted to the neonatal ward for observation upon ductal closure. Forty-six cases (60%) did not develop an aortic arch anomaly that required surgery (non-CoA group), whereas 31 cases (40%) required surgical intervention for aortic arch anomalies (CoA group). The prenatal presence of the findings PLSVC (12/77, 16%) and restricted or closed foramen ovale (9/77, 12%) did not differ significantly between both groups, as shown in Table 1. A significant difference was encountered in the incidence of postnatally diagnosed bicuspid aortic valve between the non-CoA (3/46, 7%) and CoA group (10/31, 32%), resulting in an odds ratio of 6,8 for CoA in the presence of a bicuspid aortic valve.

Table 1. Baseline characteristics of fetus diagnosed with left-right ventricular disproportion (n=77), divided by postnatal diagnosis

	Non-CoA (n=46)	CoA (n=31)	P (95% CI)	OR (95% CI)
Male sex	26 (56,5)	18 (58,0)	0,89	
Age at end of study period (years)	4.9 (0.3–12.0)	4.7 (0.3–14.3)	0.82 (–1.95 to 1.54)	
Additional prenatal findings				
Prematurely restricted or closed FO	6 (13,0)	3 (9,7)	0,65	0,74 (0,17 - 3,10)
PLSVC	9 (19,6)	4 (12,9)	0,44	0,61 (0,17 - 2,19)
Additional postnatal finding				
Bicuspid aortic valve	3 (6,5)	10 (32,3)	0,003*	6,8 (1,7 - 27,5)

Data are given as n (%) or mean (range). * p-value <0,05

Non-CoA: group without aortic arch anomalies postpartum, CoA: group with aortic arch anomalies postpartum, OR odds ratio, FO: foramen ovale, PLSVC: persistent left superior vena cava.

Non-CoA group

The AoV and PV diameters could be obtained in 45 of the 46 non-CoA cases. In 40 (89%) cases, both AoV and PV were retrieved from the fetal database and in five (11%) cases the AoV or the PV was measured on stored images. In the other case, AoV and PV diameters were not noted and original images were lost due to a change of storage systems. The AoV was smaller than the PV in all cases, with a mean AoV/PV ratio of 0.66 (95% CI, 0.36–0.96). The computed mean Z-scores for AoV and PV were 0.59 and 1.32, respectively.

Amongst non-CoA cases, undetected cardiovascular anomalies were encountered in 19 (41%) cases. These included valve anomalies (9/46), septal defects (4/46), anomalous pulmonary venous return (APVR) (2/46), other vascular anomalies or pathology (2/46) and decreased cardiac function (2/46), requiring medication (angiotensin converting enzyme (ACE) inhibitor/diuretics).

Genetic or syndromic features were seen in four cases, including one case with Down syndrome and three with dysmorphic features, such as syndactyly with undergrowth of digit IV, humeral exostosis and several facial dysmorphic features. Overall, 43% of all non-CoA children were still under surveillance at the end of the study period (December 2015).

Non-treatment group

Of the 46 cases that did not develop aortic arch anomalies postnatally, 35 did not require cardiovascular treatment. Of these, 18 (39%) cases did not have structural cardiac anomalies and 17 had minor cardiac or extracardiac abnormalities but intervention or medication for cardiovascular pathology was not required. In the latter subgroup, abnormal morphology of the semilunar valves was found in six cases, three had isolated PLSVC, one a small ventricular septal defect (VSD) together with PLSVC and one an isolated atrial septal defect type II. Furthermore, genetic syndromes or dysmorphic features were diagnosed in four cases and other anomalies in two (Table 2). All cases with PLSVC were identified prenatally. The mean observation period in this group was 7 days and only five of these cases needed readmission to the hospital. Follow-up visits were ongoing in nine cases, of which five were still under the age of 2 years at the end of the study period, and 26 cases did not have follow-up visits planned after the second year after birth.

Treatment group

The pathology encountered in 11 cases in the non-CoA group that required cardiovascular intervention or medication is outlined in Table 3. Ten neonates received medication, including ACE-inhibitors, diuretics and anticoagulants, because of renal vein and sagittal sinus thrombi. Five cases required cardiac surgery, including surgical correction of a total APVR (TAPVR) or partial APVR (PAPVR), aortic valve stenosis, mitral valve stenosis and multiple VSDs. The mean duration of initial hospital admission in this group was 35 days, varying from 2 to 189 days, and 18 re-admissions were required.

Table 2. Outcome of 'non-CoA' cases that did not require cardiovascular treatment postnatally (n=35).

Diagnosis	Value
No structural abnormality	18
Abnormal morphology of aortic,pulmonary or tricuspid valve*	6
Isolated PLSVC	3
VSD and PLSVC	1
Isolated ASD-II	1
Genetic disorder/dysmorphic features	
Down syndromet	1
Facial dysmorphic features withthoracic scoliosis	1
Syndactyly with undergrowth ofdigit IV‡	1
Humeral exostosis	1
Other	2
Hospital visits	
Number of admissions	43
Postnatal duration of admission (days)	
Mean	6.5 (2–37)
Total	229
Follow-up visits§	
Yes	10
No	25
Pulmonary support	
Postnatal respiratory support	10
PH	
No PH	33
Clinical PH¶ (self-limiting)	2

Data are given as n or mean (range).

* In four cases, ASD-II occurred together with other anomalies.

† Pulmonary valve stenosis was also present in this case.

‡ VSD was also present in this case.

§ Consultation with medical specialist scheduled, as estimated at time of end of study period (December 2015).

¶ Defined as desaturation requiring respiratory support, vasodilators or other drugs supporting cardiac function.

ASD-II, atrial septal defect type-II; PH, pulmonary hypertension; PLSVC, persistent left superior vena cava; VSD, ventricular septal defect.

Table 3. Outcome of 'non-CoA' cases that did require cardiovascular treatment postnatally (n=11).

Patient	PH score*	Diagnosis	Treatment	Hospital visits			Age at last visit
				Admissions (n)	Stay (days)†	Consultation‡	
1	1	TAPVR	Intubation, surgical correction of TAPVR and ASD-II	2	39	Yes	6 mo
2	2	PAPVR, VSD	Surgical correction of PAPVR, ASD and VSDs, sildenafil, diuretics	1	47	Yes	3 yrs
3	0	NCCM	Heparin, enalapril, carvedilol, salbutamol	6	51	Yes	2 yrs
4	0	Aortic valve stenosis, cardiac failure due to post-intervention aortic insufficiency (need for intervention 5 mo after birth)	Balloon valvuloplasty, Ross procedure, enalapril, diuretics	4	65	Yes	1 yr
5	0	Mitral valve stenosis (developed 3 mo after birth)	Mitral valve replacement, pacemaker implantation, diuretics	4	87	Yes	8 mo
6	0	Multiple VSDs, persistent and recurrent vomiting, growth deficiency	Pulmonary artery banding, sildenafil, diuretics, enteral tube feeding	4	76	Yes	4 mo
7	0	Borderline increased LV dimension with high LA pressure (normalized within 2 mo)	Diuretics	1	20	Yes	3 yrs

Table 3. (Continued)

Patient	PH score*	Diagnosis	Treatment	Hospital visits			
				Admissions (n)	Stay (days)†	Consultation‡	Age at last visit
8	2	Pulmonary hypertension, cor pulmonale, severe AITP and AIN	Diagnostic heart catheterization (NO), respiratory support, bosentan, sildenafil, IVIG, filgrastim	2	190	Yes	10 mo
9	1	Isolated increased pulmonary pressure, hearing loss	Respiratory support, diuretics	2	16	No	6 yrs
10	0	Isolated increased severe pulmonary pressure	Diuretics	1	6	No	5 yrs
11	0	RVT and CVST, hypertension, hearing loss, delayed language development	Postnatal respiratory support, left kidney nephrectomy, tinzaparine, elanapril, special educational needs	5	23	Yes	6 yrs

* Pulmonary hypertension (PH) scored according to grading system: 0 = absence of PH; 1 = self-limiting PH; 2 = persistent PH.

† Total number of days in hospital during all admissions combined.

‡ Consultations with medical specialist scheduled, as estimated at time of end of study period (December 2015).

AIN, autoimmune neutropenia; AITP, autoimmune thrombocytopenia; ASD(-II), atrial septal defect (type II); CVST, cerebral venous sinus thrombosis; IVIG, intravenous immunoglobulin; LA, left atrial; LV, left ventricular; mo, months; NCCM, non-compaction cardiomyopathy; NO, nitric oxide; PAPVR, partial anomalous pulmonary venous return; RVT, renal vein thrombosis; TAPVR, total anomalous pulmonary venous return; VSD, ventricular septal defect; yrs, years.

Pulmonary hypertension

A high rate of need for respiratory support was observed. PH requiring respiratory support or vasodilators was present in 6/46 (13%) non-CoA cases (Table S1). Even in the group without need for cardiovascular intervention or medication, two cases required respiratory support for the treatment of PH because of ductal right-left shunting. Temporary respiratory support on the first day was given in 10 cases within this subgroup (Table 2). Amongst the cases in the treatment group, PH was present in four cases. This was persistent in two, including one case with PAPVR and one with cor pulmonale (Table 3). If the case with TAPVR had been diagnosed prenatally, and therefore had not been included in this cohort, the number of cases with clinical PH would have corresponded to 5/45 (11%) of all non-CoA cases.

DISCUSSION

This study shows that prenatal counseling in ventricular disproportion should include the significant risk of additional pathology, as 46% of cases that did not develop aortic arch anomalies were diagnosed with cardiovascular diseases or dysmorphic features that were undetected prenatally. Previous studies have focused mainly on improving the identification of cases that require aortic arch surgery.¹⁰⁻¹⁴

We encountered a relatively high incidence (46%) of prenatally undetected congenital malformations amongst cases without CoA, which mainly comprised cardiac defects. The association of left-right ventricular disproportion with both cardiac and extracardiac pathology has been reported before by Hornung *et al.*¹⁸ and Axt-Friedner *et al.*¹⁹, who found a considerable incidence of other CHDs, such as VSD, PLSVC, pulmonary or aortic valve stenosis and chromosomal diseases in these patients. These studies, however, included cases of both isolated and non-isolated ventricular size disproportion, resulting in a considerably higher incidence of severe cardiac and extracardiac pathology and genetic syndromes, and a higher termination and mortality rate compared with our findings. The presented frequency and severity of pathology encountered in this cohort represents the incidence of pathology only amongst cases of prenatally isolated ventricular size disproportion.

Additionally, our data suggest that this prenatal finding can have a considerable impact on both the neonatal period and following years, as evidenced by the number of children requiring antihypertensive drugs, diuretics and long-term follow-up visits. This number could, however, have been slightly lower if TAPVR had been recognized prenatally as the cause of the ventricular disproportion in one case. This case was from the early years of the cohort (2009), but underlines the importance of careful examination of these fetuses, as this diagnosis should not be missed in left-right disproportion. Other cardiac anomalies involved PAPVR, non-compaction cardiomyopathy, mild aortic valve and mitral valve stenosis, VSDs, bicuspid aortic valve and tricuspid valve dysplasia. These are all conditions known to be difficult to diagnose in the prenatal period, and may be progressive with advancing gestation or become apparent after birth, which can lead to long-term consequences. Furthermore, our findings showed that a prematurely closed or restrictive foramen ovale or PLSVC was found more often in cases that did not develop aortic arch anomalies rather than in CoA cases. A bicuspid aortic valve occurred in 32% of cases of the CoA compared with 7% of the non-CoA group, which is in accordance with the known association between bicuspid aortic valve and CoA.^{4,11,20}

Pulmonary pathology in general was also encountered frequently. This varied from need for respiratory support in the neonatal period in 30% to clinically important PH requiring vasodilators, diuretics and respiratory support in 13% of the non-CoA cases, of which 4% even required long-term PH treatment. Overall, 35% of all non-CoA cases coped with respiratory problems and only 41% did not need postnatal support of any kind or other clinical intervention during the neonatal observation. It is therefore recommended to alert parents, as early as during prenatal counseling, of potential transition problems and the occurrence of other minor or major defects, as they may experience the transient need for respiratory support as a stressful event. The fact that all neonates were admitted to a neonatal intensive care unit for observation of ductal closure might, however, have resulted in a slightly lower threshold to provide respiratory support in these cases.

Although the exact mechanism behind prenatal left-right ventricular disproportion in the development of CoA is unknown, one of the hypotheses is that CoA results from an imbalance between the flow over the left ventricular outflow tract and the ductus arteriosus, causing decreased flow through the aortic isthmus.¹⁴ We hypothesize that the altered hemodynamics in fetal life, with right ventricular dominance and a cardiac output larger than usual entering the pulmonary circulation, might have an effect on pulmonary development. The increased flow towards the pulmonary vascular system could influence the pulmonary vascular development during fetal life, potentially causing both short-term, in the transition phase from fetus to newborn, and long-term effects. This theory is supported by the rare situation in which constriction of the fetal ductus arteriosus *in utero* can cause idiopathic pulmonary hypertension.^{21,22} Uterine constriction of this fetal shunt results in a pulmonary overflow, which causes remodeling of pulmonary vasculature with vascular wall thickening and smooth muscle hypoplasia.²³ Fetal ventricular disproportion also reflects an imbalance in pulmonary and aortic flow, possibly leading to comparable, but less severe, symptoms. This hypothesis might explain the high percentage of cases needing respiratory support (30%), due to either transition problems or PH. The prevalence of PH in this group (13%) is very high, compared with the reported prevalence in unselected cohorts (1.9 per 1000 live births).^{24,25}

Finally, 45% of all cases with prenatal ventricular size disproportion did not require medication or intervention for cardiovascular disease after observation. In this series, ventricular size disproportion, known to precede a postnatal diagnosis of CoA²⁶, did not result in a coarctation after ductal closure in 60% of cases, which is consistent with previous publications, reporting rates from 33% up to 65%. The range can be

explained by the subjectivity of the finding and differences in inclusion and exclusion criteria.^{5-7,9,11,26-28}

A limitation of this study is the lack of specific measurements of the cardiac ventricles to calculate ratios or Z-scores and define cases suspected for CoA more objectively. It is thereby important in cases with ventricular disproportion to measure cardiac structures and not only assume the left side is small. A large prospective cohort study, including the outcome of non-CoA cases, based on specific measurements, may be beneficial to support these findings with additional details.

In conclusion, despite the absence of aortic arch anomalies in cases with prenatal left-right ventricular disproportion, the number of neonates requiring intensive care postnatally and the frequency of additional cardiac and extracardiac morbidity is considerable. Proper monitoring of these infants is therefore warranted and incorporation of the risk for additional morbidity and neonatal complications into prenatal counseling should be considered.

REFERENCES

1. Hoffman JL, Kaplan S. The incidence of congenital heart disease. *J Am Coll Cardiol* 2002; 39 : 1890-900.
2. Samánek M, Slavík Z, Zborilová B, Hrobonová V, Vorísková M, Skovránek J. Prevalence, treatment, and outcome of heart disease in live-born children: A prospective analysis of 91,823 live-born children. *Pediatr Cardiol* 1989; 10 : 205-211.
3. Franklin O, Burch M, Manning N, Sleeman K, Gould S, Archer N. Prenatal diagnosis of coarctation of the aorta improves survival and reduces morbidity. *Heart* 2002; 87 : 67-69.
4. Matsui H, Mellander M, Roughton M, Jicinska H, Gardiner HM. Morphological and physiological predictors of fetal aortic coarctation. *Circulation* 2008; 118 : 1793-1801.
5. Gabbay-Benziv R, Cetinkaya Demir B, Crimmins S, Esin S, Turan OM, Turan S. Retrospective case series examining the clinical significance of subjective fetal cardiac ventricular disproportion. *Int J Gynaecol Obstet* 2016; 135 :28-32.
6. Quartermain MD, Cohen MS, Dominguez TE, Tian Z, Donaghue DD, Rychik J. Left ventricle to right ventricle size discrepancy in the fetus: the presence of critical congenital heart disease can be reliably predicted. *J Am Soc Echocardiogr* 2009; 22 : 1296-1301.
7. Brown DL, Durfee SM, Hornberger LK. Ventricular discrepancy as a sonographic sign of coarctation of the fetal aorta: how reliable is it? *J Ultrasound Med* 1997; 16 : 95-9.
8. Benacerraf BR1, Saltzman DH, Sanders SP. Sonographic sign suggesting the prenatal diagnosis of coarctation of the aorta. *J Ultrasound Med* 1989; 8 : 65-9.
9. Allan LD, Chita SK, Anderson RH, Fagg N, Crawford DC, Tynan MJ. Coarctation of the aorta in prenatal life: an echocardiographic, anatomical, and functional study. *Br Heart J* 1988; 59 : 356-360.
10. Buyens A, Gyselaers W, Coumans A, Al Nasiry S, Willekes C, Boshoff D, Frijns JP, Witters I. Difficult prenatal diagnosis: fetal coarctation. *Facts Views Vis Obygn* 2012; 4 : 230-236.
11. Sivanandam S, Nyholm J, Wey A, Bass JL. Right Ventricular Enlargement In Utero: Is It Coarctation? *Pediatr Cardiol* 2015; 36 : 1376-81.
12. Gómez-Montes E, Herraiz I, Mendoza A, Escribano D, Galindo A. Prediction of coarctation of the aorta in the second half of pregnancy. *Ultrasound Obstet Gynecol* 2013; 41 :298-305.
13. Weber RW, Ayala-Arnez R, Atiyah M, Etoom Y, Manlhiot C, McCrindle BW, Hickey EJ, Jaeggi ET, Nield LE. Foetal echocardiographic assessment of borderline small left ventricles can predict the need for postnatal intervention. *Cardiol Young* 2013 Feb; 23 : 99-107.
14. Quarello E, Stos B, Fermont L. Diagnostic prénatal dese coarctations de l'aorte. *Gynecol Obstet Fertil* 2011; 39 : 442-453.
15. van Velzen CL, Clur SA, Rijlaarsdam MEB, Bax CJ, Pajkrt E, Heymans MW, Bekker MN, Hruda J, de Groot CJM, Blom NA, Haak MC. Prenatal detection of congenital heart disease—results of a national screening programme. *BJOG* 2016; 123 : 400-407.
16. Pasquini L, Fichera A, Tan T, Ho SY, Gardiner H. Left superior caval vein: a powerful indicator of fetal coarctation. *Heart* 2005; 91 : 539-540.
17. Schneider C, McCrindle BW, Carvalho JS, Hornberger LK, McCarthy KP, Daubeney PE. Development of Z-scores for fetal cardiac dimensions from echocardiography. *Ultrasound Obstet Gynecol* 2005; 26: 599-605.
18. Hornung TS, Heads A, Hunter AS. Right ventricular dilatation in the fetus: a study of associated features and outcome. *Pediatr Cardiol* 2001; 22 : 215-217.

19. Axt-Fliedner R, Hartge D, Krapp M, Berg C, Geipel A, Koester S, Noack F, Germer U, Gembruch U. Course and outcome of fetuses suspected of having coarctation of the aorta during gestation. *Ultraschall Med* 2009; 30 : 269-276.
20. Durand I, Deverriere G, Thill C, Lety AS, Parrod C, David N, Barre E, Hazelzet T. Prenatal Detection of Coarctation of the Aorta in a Non-selected Population: A Prospective Analysis of 10 Years of Experience. *Pediatr Cardiol* 2015; 36 : 1248-54.
21. Alano MA, Ngougma E, Ostrea EM, Jr., Konduri GG. Analysis of nonsteroidal antiinflammatory drugs in meconium and its relation to persistent pulmonary hypertension of the newborn. *Pediatrics* 2001; 107 : 519-523.
22. Levin DL, Mills LJ, Parkey M, Garriott J, Campbell W. Constriction of the fetal ductus arteriosus after administration of indomethacin to the pregnant ewe. *J Pediatr* 1979; 94 : 647-650.
23. Steinhorn RH, Farrow KN. Pulmonary hypertension in the neonate. *Neoreviews* 2007; 8: e14-e21.
24. Steurer MA, Jelliffe-Pawlowski LL, Baer RJ, Partridge JC, Rogers EE, Keller RL. Persistent Pulmonary Hypertension of the Newborn in Late Preterm and Term Infants in California. *Pediatrics* 2017; 139 : e20161165.
25. Walsh-Sukys MC1, Tyson JE, Wright LL, Bauer CR, Korones SB, Stevenson DK, Verter J, Stoll BJ, Lemons JA, Papile LA, Shankaran S, Donovan EF, Oh W, Ehrenkranz RA, Fanaroff AA. Persistent pulmonary hypertension of the newborn in the era before nitric oxide: practice variation and outcomes. *Pediatrics* 2000; 105 : 14-20.
26. Allan LD, Hornberger L, Sharland G. *Textbook of Fetal Cardiology*. Cambridge: Cambridge University Press; 2000. p. 596.
27. Head CE, Jowett VC, Sharland GK, Simpson JM. Timing of presentation and postnatal outcome of infants suspected of having coarctation of the aorta during fetal life. *Heart* 2005; 91 : 1070-1074.
28. Carrilho MC, Barros FS, Araujo Júnior E. Increasing isolated right heart chambers in second trimester ultrasound: always a warning sign? *Rev Bras Cir Cardiovasc* 2014; 29 : 4-5.

SUPPLEMENTAL INFORMATION

Table S1. Case description and treatment of six patients diagnosed prenatally with left-right ventricular size disproportion, who did develop aortic coarctation but required treatment for pulmonary hypertension (PH) postnatally

PH	Patient	Group	Diagnosis	PH treatment
Persistent	2	Treatment	PAPVR, ASD, VSD Left-to-right shunt (5:1) causing pulmonary flow hypertension	Sildenafil, diuretics and fluid restriction(Surgical correction PAPVR, ASD, VSDs)
	8	Treatment	Right heart failure Dilated RV with moderate systolic function, L-R systolic and R-L diastolic shunt over VSD, increased pressure RV	Respiratory support, bosentan, sildenafil(Diagnostic heart catheterization (NO))
Self-limiting	9	Treatment	Isolated increased pulmonary pressure Ductal R-L shunt and RV>LV	Respiratory support, diuretics
	1	Treatment	TAPVR RV dilatation, increased pressure RV, ductal R-L shunt	Intubation, inotropes, diuretics(Surgical correction TAPVR and ASD-II)
	X	No treatment	Isolated increased pulmonary pressure Dilated RV and RA, ductal systolic R-L shunt and diastolic L-R shunt	Respiratory support
	X	No treatment	Pulmonary valve stenosis with RV hypertrophy(Down syndrome)	Respiratory support

ASD, atrial septal defect; NO, nitric oxide; PAPVR, partial anomalous pulmonary venous return; TAPVR, total anomalous pulmonary venous return; VSD, ventricular septal defect.w

Isolated ventricular size disproportion in the absence of aortic coarctation