



Universiteit  
Leiden

The Netherlands

## Neonatal Brachial Plexus Palsy: the role of diminished sensibility of the hand on functional recovery

Buitenhuis, S.M.

### Citation

Buitenhuis, S. M. (2024, June 11). *Neonatal Brachial Plexus Palsy: the role of diminished sensibility of the hand on functional recovery*. Retrieved from <https://hdl.handle.net/1887/3762692>

Version: Publisher's Version

License: [Licence agreement concerning inclusion of doctoral thesis in the Institutional Repository of the University of Leiden](#)

Downloaded from: <https://hdl.handle.net/1887/3762692>

**Note:** To cite this publication please use the final published version (if applicable).

# **Chapter 1**

## **General Introduction**



## **INTRODUCTION**

The aim of the studies reported on in this thesis is to get a better understanding of the long-term consequences of a brachial plexus injury that occurred during birth, a so-called neonatal brachial plexus palsy (NBPP). NBPP can affect the motor and sensory functions of the shoulder, arm and hand.

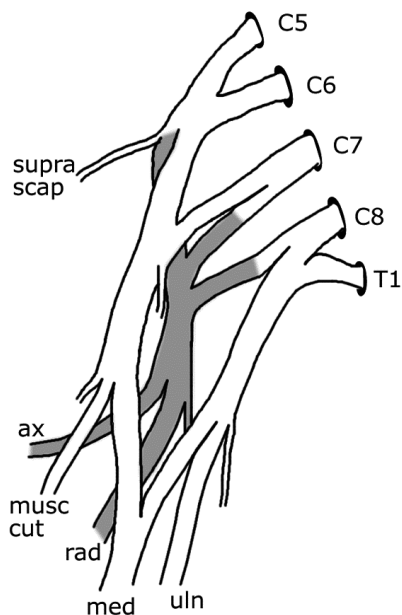
The evaluation of sensation following a NBPP has so far not received much attention.

Research was merely focused on the outcome in terms of motor function and improving the performance of various motor tasks. Standards for the assessment of sensory outcomes are lacking, which hampers adequate evaluation of sensation and thereby also the development of strategies to improve sensation. Optimization of treatment strategies for NBPP is only possible when all aspects are included, both motor and sensory. This thesis focusses on the assessment of both sensory outcome and motor development, and the relationship between these two.

## **NEONATAL BRACHIAL PLEXUS PALSY**

The brachial plexus is the nerve network connecting the spinal cord with the muscle and sensory end-organs in the shoulder, arm and hand. The plexus is formed by the spinal cord nerves C5 to T1 and the various end-nerves are formed in an elaborate branching pattern.

(Figure 1)



*Figure 1 The brachial plexus originates from the spinal nerves C5 to T1  
suprascap-suprascapular nerve; ax-axillary nerve; musc cut-musculocutaneous  
nerve; rad-radial nerve; med-median nerve; uln-ulnar nerve. (from Pondaag<sup>1</sup>)*

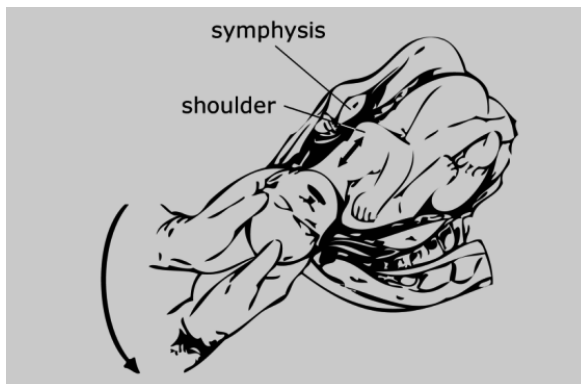
A neonatal brachial plexus palsy (NBPP) is a stretch injury that occurs during delivery when the baby's shoulder is blocked by the mother's symphysis. (Figure 2) Due to lateral movement of the head of the baby, the angle between the neck and shoulder becomes too wide, causing traction to the brachial plexus. The incidence of NBPP is 0.5 to 2.6 per 1000 live births.<sup>2</sup>

Assuming a birth rate of 169,000 live births a year, we can estimate that 85-450 children with a NBPP are born in the Netherlands each year. While the majority will recover spontaneously, 50-150 children will have incomplete recovery, resulting in life-long deficits. The main risk factor for NBPP is high birth weight. In a cohort from our center, we showed a significant correlation between a higher birth weight and a more extensive plexus lesion.<sup>3</sup> Other risk factors, such as gestational diabetes, probably have an indirect effect as they are related to a high birth weight.

Breech delivery carries a high risk of a specific injury type, namely root avulsion of the upper nerves. If a root is avulsed, the nerve root filaments are pulled out of the spinal cord.<sup>4</sup>

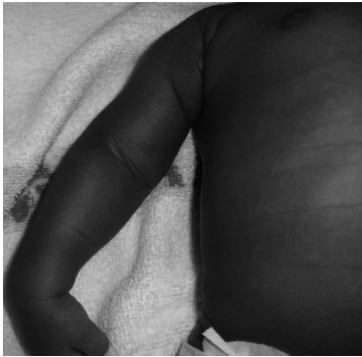General textbooks state that the spontaneous recovery of NBPP is good in an estimated 90%

of cases, with complete or nearly complete recovery. A systematic review, however, showed that 20% to 30% of children probably do not recover that well, but have a persistent neurological deficit throughout life.<sup>5</sup> The differences in reported outcomes among studies can be explained by differences in the definition of complete recovery they use and the age of the child at which the level of recovery is established.<sup>6</sup>

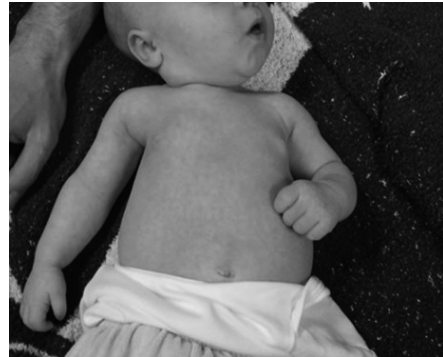

*Figure 2 Trauma mechanism of neonatal brachial plexus palsy: the infant's shoulder becomes stuck behind the mother's symphysis during delivery as forces are applied to deliver the child.*

The most common lesion type, found in around 80% of the cases, is a lesion of the two upper spinal nerves (C5 and C6) of the brachial plexus. This lesion type results in weakness of the shoulder (deltoid, supraspinatus and infraspinatus muscles) and the elbow flexors (biceps, brachialis and brachio-radialis muscles). Immediately after birth, the position of the arm is typically in extension, internal rotation and adduction. When spinal nerve C7 is also damaged, the extensors of the wrist and fingers are weakened as well, leaving the wrist and fingers in a permanently flexed position. This typical position of the arm is commonly referred to as 'Waiter's tip position'. (Figure 3a) In more severe lesions, C8 and T1 are involved as well, which results in a loss of hand function. The most severe lesion form is a complete paralysis of the arm and hand, which is usually called a flail arm. (Figure 3b)<sup>7</sup> Hand function is impaired in about 15 % of patients.<sup>5</sup>



a) Lesion of C5 C6 C7, with the typical 'Waiter's tip' position of the arm



b) Lesion of C5 up to T1: flail arm

*Figure 3 Typical arm position in relation to the number of damaged nerves*

### **Classification of nerve injuries**

The severity of the nerve injury was classified into three degrees by Seddon in 1942. His classification is still widely used<sup>8</sup>

- Neurapraxia: the structure of the nerve has remained intact and the function will recover completely within a few days.
- Axonotmesis: rupture of axons but basal lamina tubes remain intact. In these lesions, Wallerian degeneration will occur distal to the rupture site. The severed axon will re-grow from proximal to distal to its end-organ, guided by the original basal lamina tube. Depending on the distance between lesion site and end-organ, functional recovery will occur over the course of months. (Figure 4)
- Neurotmesis: axons and basal lamina tubes are ruptured, and in more extended lesions even the perineurium and epineurium are damaged. Axonal elongation is not possible due to the lack of guidance through the basal lamina tube. A neuroma is formed at the lesion site. (Figure 5)

This classification was expanded to five degrees by Sir Sydney Sunderland in 1951.<sup>9</sup> Sunderland's first-degree lesion corresponds with Seddon's neurapraxia, and his fifth degree with Seddon's neurotmesis. Sunderland defined an intermediate degree between axonotmesis and neurotmesis in more detail. In the third-degree injury, not all axons recover; additionally, axonal misdirection will occur, further compromising

recovery. Muscle weakness and/or sensory defect remain. In a Sunderland grade 4 lesion, the internal architecture of the nerve is lost, but the epineurium remains intact. A so-called neuroma-in-continuity is formed.

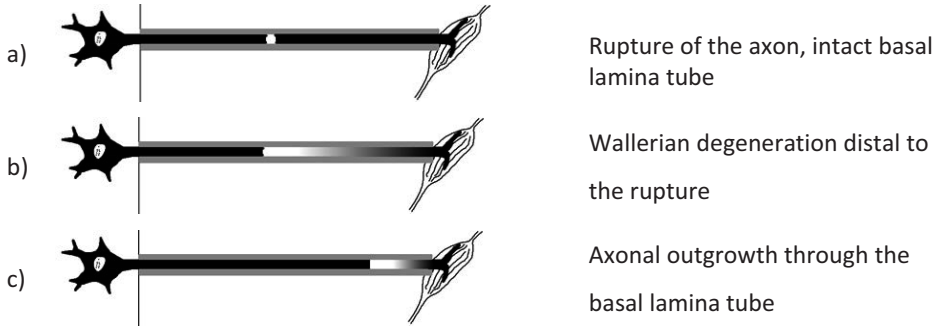


Figure 4 Axonotmesis, schematic representation of one neuron.

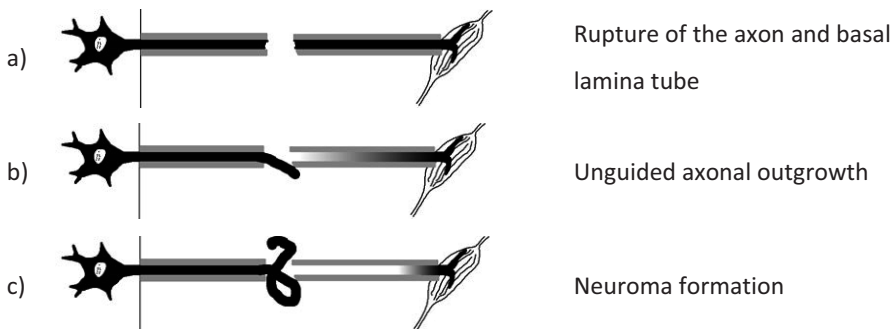
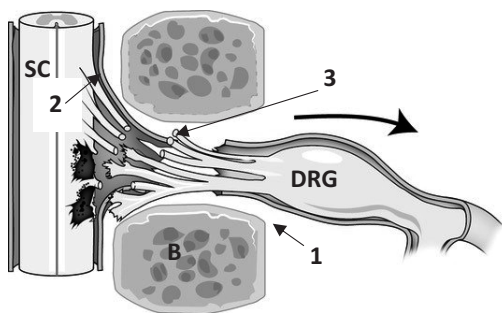


Figure 5 Neurotmesis, schematic representation of one neuron. (from Pondaag<sup>1</sup>)

A type of nerve injury which is specific to brachial plexus traction injuries is root avulsion, which is a pre-ganglionic injury in which the root filaments are torn out of the spinal cord. (Figure 6)





In successive order, rupture takes place at:

- (1) the fibrous connections between nerve and foramen,
- (2) the dura and
- (3) the rootlets.

DRG-dorsal root ganglion; B-bony foramen;  
SC-spinal cord

Figure 6 Avulsion (Copyright ZenuwCentrum LUMC)

### ***Differences between traumatic brachial plexus lesions in adults and NBPP***

In contrast to a traumatic plexus lesion in adults, a birth-related lesion will usually not result in complete rupture of the nerve elements. The typical lesion is a neuroma-in-continuity, an intermediate form between Sunderland's grades 3 and 4.<sup>10, 11</sup> Some axons may successfully bridge the neuroma-in-continuity, but their number is reduced and their routing is insufficient. Further focal deficits of myelination have been found in neuroma-in-continuity, contributing to the failure of functional recovery.<sup>10</sup> Some of the damaged axons grow through the neuroma to their original target, but other axons will grow to an incorrect target, which is called misrouting. This phenomenon may explain typical clinical features of NBPP, such as co-contraction of agonistic and antagonistic muscles.<sup>12</sup> Apart from incorrect innervation of motor axons, they may also end up in basal lamina tubes towards a sensory target. Such erroneous outgrowth does not lead functional recovery. In NBPP, the absence of motor control and sensory feedback during the time of development of central motor programs can cause developmental apraxia,<sup>13</sup> whereas in adults these programs are already fully developed.

### ***Prognosis***

NBPP is a closed stretch injury of the brachial plexus, with varying severity and extent. A mild nerve damage<sup>11</sup> (neurapraxia/axonotmesis) will completely recover in time, but a severe damage (neurotmesis/avulsion) will cause permanent loss of arm function. The severity of the nerve damage can, at present, not be assessed with certainty at an early

stage, not even with the help of imaging or other ancillary investigations. The severity only becomes clear by observing neurological recovery in the course of time. The difficulty lies in the fact that the end stage of recovery may be only reached after 18 months to three years. In case recovery is limited and nerve reconstructive surgery is indicated, a critical amount of time has then been lost. After all, the results of nerve surgery are inversely related to the time between trauma and repair.<sup>14</sup> The window of opportunity for nerve reconstruction is limited, due to the intrinsically limited recovery potential of the nerves, and the deleterious effects of denervation on muscles, leading to irreversible atrophy and failure of the development of cerebral control. There is agreement amongst medical specialists that nerve surgery is indicated if spontaneous recovery is insufficient, or severely delayed,<sup>14, 15</sup> and that the time interval after birth is preferentially kept as short as possible. The neurological deficits in mild and severe nerve lesions are initially the same, but the occurrence and speed of recovery will reflect the lesion severity.

### ***Indications for nerve surgery***

There are different approaches to assessing recovery, and thus to selecting infants for nerve surgery. The first indicator of poor recovery was defined by Prof. A. Gilbert from Paris: when the biceps muscle (mainly innervated by spinal nerve C6) has not recovered by the age of 3 months, nerve surgery is indicated.<sup>16</sup> Prof. H. Clarke introduced a combined sum score of different movements in an 'active movement scale' at different ages up to 9 months, which is used to decide whether a child should be operated.<sup>17</sup> These algorithms estimate the severity of the nerve lesion from the extent and speed of neurological recovery, and serve to support the decision to perform surgical nerve repair in a timely fashion.

### ***The LUMC cohort study (2011)***

The Leiden University Medical Centre serves as a tertiary referral center in the Netherlands for complex nerve lesions. We sought to improve early prognostication for children with an NBPP and undertook a cohort study with national recruitment. Children were assessed at the outpatient nerve clinic at three different time points, namely at the ages of one week, one month, and three months. The infants' passive and active joint movements were

assessed, and an electromyography study of the biceps, triceps and deltoid muscles was performed.<sup>18</sup>

These prospectively gathered parameters were then correlated to the presence of a severe nerve lesion, defined as neurotmesis or avulsion, during surgery. Children who were not operated on were followed for two years to ensure that spontaneous recovery occurred. We included 48 infants in the study, which resulted in a model with a correct prediction in 94% of children at the age of one month.<sup>18</sup> We called it the Leiden three-item test.

**When to refer to a specialized nerve center: the Leiden three-item test**

It is important that children with a severe NBPP with neurotmesis or root avulsion are diagnosed as early as possible, enabling timely referral to a center with the necessary expertise. The three-item test was developed to assess prognosis at one month of age.<sup>18</sup> (Figure 7)

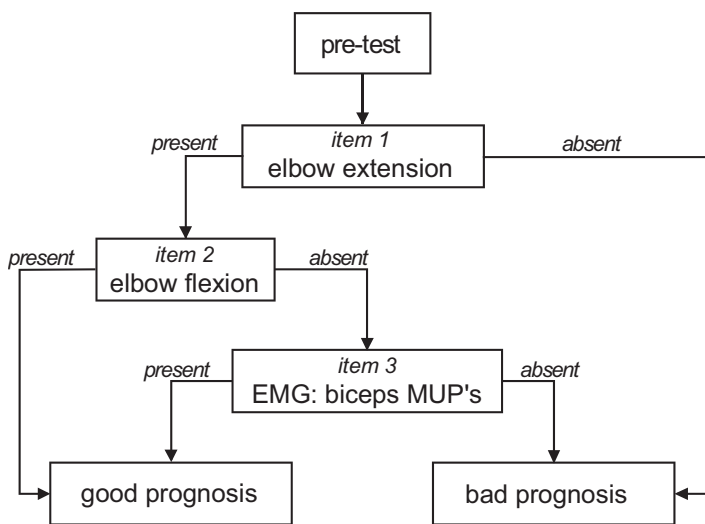
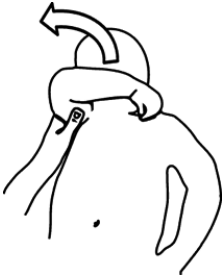

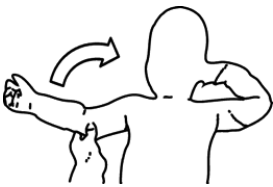Figure 7 Flow diagram of NBPP assessment at one month of age using the Leiden three-item test. (from Pondaag<sup>18</sup>)

In current practice, children are assessed clinically by the referring paediatrician, neurologist or physical therapist, while an electromyogram (EMG) of these very young children is usually performed at our center. The three-item test (Figure 7) starts with clinical examination of elbow extension. (Figure 8)



*Figure 8 Testing of elbow extension (mainly triceps muscle): in supine position, bring the arm in anteflexion with the elbow in flexion, and assess active elbow extension.*

Failure of elbow extension at one month of age reflects paralysis of the triceps muscle, which signifies involvement of the C7 / C8 / T1 roots, and carries a poor prognosis. These children should be referred to a specialized center. When active elbow extension is present, the second item to test is elbow flexion. (Figure 9)



*Figure 9 Testing of elbow flexion (mainly biceps muscle): in supine position, bring the arm in 90° abduction and external rotation, and assess active elbow flexion.*

If elbow flexion is present (or has already recovered) at one month of age, the prognosis is considered favourable. If elbow flexion is absent, the next step is to perform an EMG of the biceps muscle. The presence of motor unit potentials (MUPs) signifies that subclinical recovery of the biceps has taken place and the prognosis for recovery is good. If no MUPs are found, the prognosis is poor.

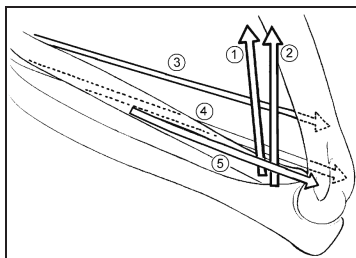
The three-item test is used for prognostication at the age of 4-6 weeks, and is highly helpful to inform parents of the expected outlook at an early stage. Additionally, it helps in the planning of ancillary investigations (MRI) and surgery.

Irrespective of the estimated prognosis, children are re-examined at the age of three months for a definite indication for nerve surgery. If hand function remains diminished (involvement of C8 or C8 and T1), there is an absolute indication for surgical reconstruction of the nerve. In other cases, lack of recovery of the biceps muscle is a reliable indicator of

severe lesion of the upper nerves (C5 and C6). In this respect it is of eminent importance that ‘trick’ movements are recognized during the execution of elbow flexion, as they wrongly suggest recovery of the biceps muscle (and thus of C5 and C6 spinal nerves), but are in fact executed by other muscles (and other nerves). A commonly observed trick movement to flex the elbow in supine position is by swinging the arm forward using the pectoralis muscle. The elbow will then flex and the hand can be brought to the child’s mouth using the effects of gravity and relaxation of the triceps muscle, whereas it suggests active elbow flexion based on biceps muscle recovery.

*Trick movements: the Steindler effect*

A frequently seen trick movement has been named ‘the Steindler effect’. The name is derived from the operation according to Steindler, in which the origin of the wrist and finger flexor muscles is moved more proximally on the humerus. As a result, the forearm flexor muscles will also act as flexors of the elbow joint. Likewise, some infants are able to flex the elbow by other muscles than the original prime movers, especially by the extensor carpi radialis muscle (in combination with the pronator teres muscle), when its origin is located just above the elbow joint. One main characteristic of elbow flexion based on the Steindler effect is that the lower arm is in pronation. The extensor carpi radialis muscle can act in this way, as it is a bi-articular muscle spanning both wrist and elbow. (Figure 10)

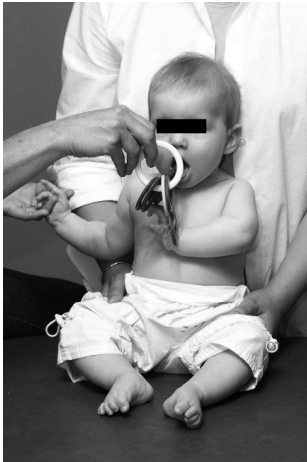

- 1 *biceps brachii muscle (C5) / C6 – musculocutaneous nerve*
- 2 *brachialis muscle (C5) / C6 – musculocutaneous nerve*
- 3 *brachioradialis muscle C6 – radial nerve*
- 4 *extensor carpi radialis longus muscle C7 – radial nerve*
- 5 *pronator teres muscle C7 – median nerve*

*Figure 10 Elbow flexion can be executed by other muscles than the biceps brachialis and brachioradialis muscles.*

We performed a study to assess which type of nerve lesion (axonotmesis, neurotmesis or root avulsion) was found in children who clinically showed elbow flexion using the Steindler effect.<sup>19</sup> We identified 28 children with NBPP (born between 1997 and 1999) at our outpatient clinic at the LUMC who executed elbow flexion partially or completely using the

Steindler effect. Among these children, 20 (72%) were found to have a severe nerve lesion, for which nerve reconstruction proved necessary. Six weeks after their surgery, in which the nerves to the biceps, brachialis and brachioradialis muscles were interrupted, these children could still bend their elbow with the same Steindler effect. This finding proved that it is possible to flex the elbow without using the biceps, brachialis, or brachio-radialis muscles. (Figure 11)



*Figure 11 Child flexing the elbow with a Steindler trick at the age of 3 months.*

*Legend Figure 11*

Six weeks after surgery with nerve grafting of the C6 nerve outflow towards the biceps muscle, the child was still able to flex her elbow using the Steindler trick. This finding proved that it is possible to flex the elbow without the m. biceps, as it was too early after nerve surgery for the latter to be reinnervated.

From this study we learned that proper differentiation between elbow flexion based on biceps muscle activity and the Steindler effect is crucial to avoid inadequate neurological assessment. Imprecise assessment may lead to underestimation of the severity of the nerve lesion, while a severe lesion carrying an indication for surgical nerve repair may actually be present.

Some children may use a combination of flexing the elbow and the Steindler effect, and with some biceps as shown by the hand position in supination. These children may be in a recovery phase. Palpation of the biceps muscle to see whether it contracts during flexion may be difficult and is therefore not always reliable. We recommend that children in whom it is difficult to differentiate between elbow flexion based on biceps function and on a

Steindler effect should be monitored by a specialized team to evaluate whether neurological recovery occurs.

We clinically observed that many children in the first month of their life flex their elbow with a 'natural' Steindler effect, alternating between flexion with and without supination.

Perhaps supination of the forearm would be a better criterion to assess recovery of the biceps, and thereby of the superior trunk, but this has not been sufficiently studied.

A variant of the Steindler effect has been observed where elbow extension is executed in a situation in which the triceps muscle is paralyzed. The extension is then executed with the flexor carpi ulnaris muscle. This trick ('reversed Steindler effect') can be recognized by noticing that the wrist is moved into ulnar deviation.

## TREATMENT OPTIONS

### *Nerve surgery*

Severe nerve injuries (neurotmesis / Sunderland grade 4 lesion or root avulsion) will not recover spontaneously, and nerve surgery may improve the outcome significantly compared to what the natural course would have been. Nerve surgical repair techniques which can be used include nerve grafting and nerve transfer. Nerve grafting consists of resection of scar tissue and the neuroma and subsequently bridging the gap between the proximal and distal stumps with a nerve graft. The graft serves as a guide for the outgrowing axons. (Figure 12)

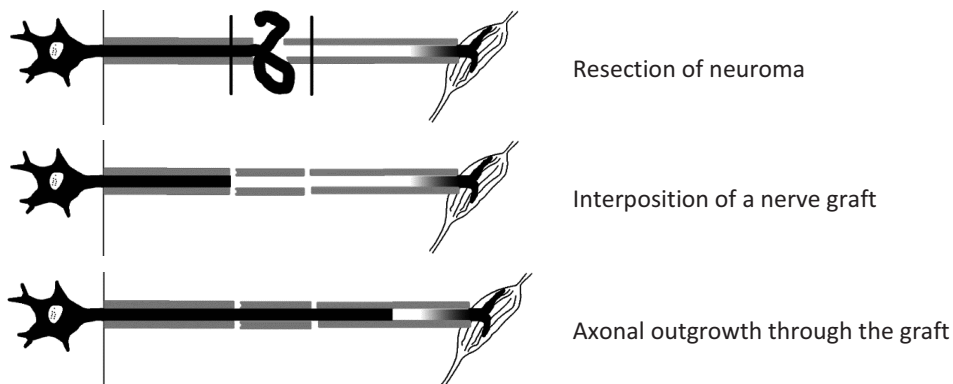


Figure 12 The principle of nerve grafting (from Pondaag<sup>1</sup>)

The best graft to bridge the gap is an autologous nerve, for which the patients' sural nerve is usually used. In our hospital, we harvest the sural nerves using an endoscope, via three

incisions in the leg, the scar being hardly visible after one year.<sup>20</sup> The use of the sural nerve causes loss of sensation on the lateral side of the foot, which does not compromise the function of the leg and foot.<sup>21</sup> A prerequisite for nerve grafting is the availability of a healthy proximal nerve stump that can serve as an outlet, so this technique cannot be employed in avulsion injuries. In such lesions, a nerve transfer can be applied. This technique involves cutting a healthy nerve in close proximity to the damaged nerve and coapting the healthy proximal stump to the denervated distal stump of the damaged nerve. (Figure 13)

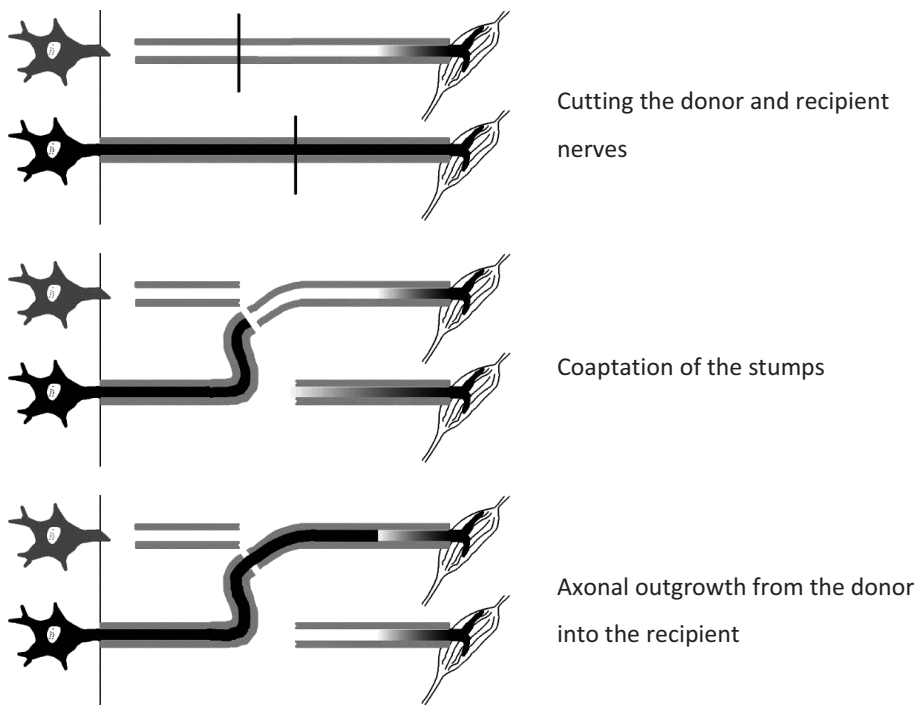


Figure 13 The principle of nerve transfer (from Pondaag<sup>1</sup>)

At the Leiden University Medical Center, nerve surgery is performed preferably at an age of 3 to 5 months. After the surgery, the baby is immobilized to prevent loss of the nerve repair. For the first two weeks, the baby is immobilized in a synthetic shell, followed by three weeks with the arm under the shirt. (see Figure 14)





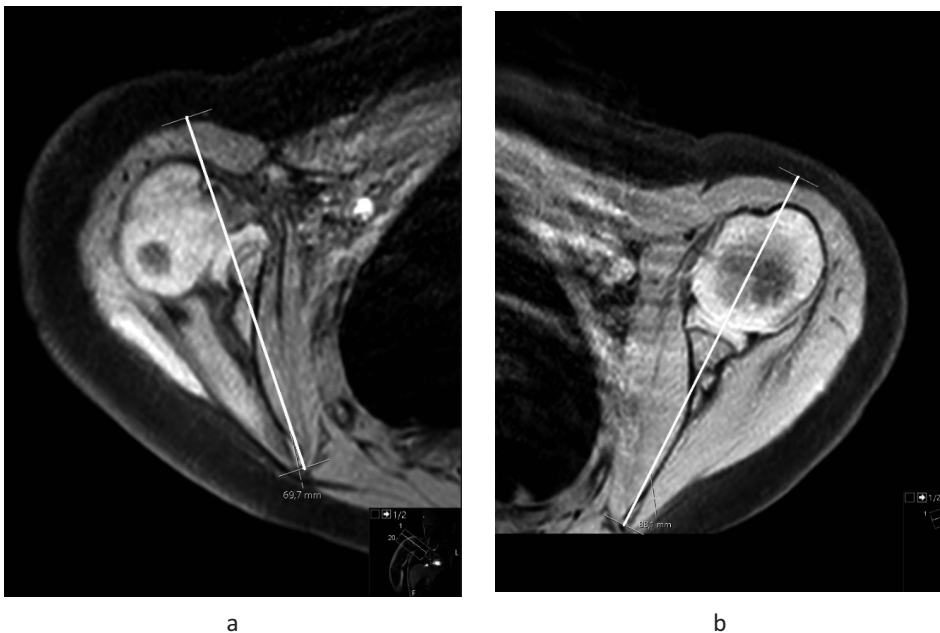
*Figure 14 Immobilized arm after nerve surgery using a synthetic shell*

Neurological recovery takes place only after the axons have reached the target end-organ. As axons grow approximately 1 mm per day under ideal laboratory conditions, recovery of function following NBPP repair can take up to 2.5 years for an upper brachial plexus lesion and 5 years for a total brachial plexus lesion.

The results of nerve surgery of the upper brachial plexus lesion are generally good. Results of elbow flexion recovery are excellent: approximately 95% of children will regain elbow flexion against gravity (unpublished data). On the other hand, true glenohumeral external rotation will only recover in 40% of children after reconstruction of the suprascapular nerve. A functional analysis after nerve surgery, however, found that 90% of the children can reach their mouth with their hand, and 75% are able to put their hand on their head.<sup>22</sup> Hand function restoration after nerve reconstruction in case of a total lesion is feasible. We found that recovery to the functional level of an assisting hand is around 65%.<sup>23</sup>

### **Secondary surgery**

Secondary surgery to improve function involves bone, joint or tendon surgery. The principle of a tendon transfer is that a functioning muscle's tendon is detached from its original insertion and attached to a muscle that is not working. The indication for secondary surgery procedures may be either to treat joint deformities, or to improve function in case of insufficient neurological recovery. The most frequent indications for secondary surgery are addressed below. Concerning the shoulder, one of the key challenges is to keep the glenohumeral joint mobile. Recovery of the infraspinatus muscle following suprascapular nerve reconstruction is usually poor.<sup>22</sup> An ongoing internal rotation position may lead to secondary deformity of the shoulder joint. This may be an indication for internal contracture release and tendon transfer of the latissimus dorsi and/or teres major muscles.<sup>24, 25</sup> Surgical treatment of a progressive internal rotation contracture is only possible when the glenoid and head of the humerus are not dislocated or deformed. (Figure 15)



*Figure 15 a) Affected shoulder with dislocated and deformed glenoid and head of the humerus;  
b) the non-affected shoulder for comparison.  
(Copyright ZenuwCentrum LUMC)*

## Chapter 1

In case of a fixed supination deformity, a pronation osteotomy of the ulna and/or radius can be performed to improve the functional position of the hand.<sup>26, 27</sup> When the wrist extension is weakened, a better grip function can be obtained by tendon transfer of the pronator teres muscle to the extensor carpi radialis longus and brevis muscles.<sup>28</sup>

To treat weakness of the extension of the fingers and thumb, a muscle transfer of the flexor carpi radialis muscle to the extensor communis muscle and of the palmaris longus to the extensor pollicis longus muscle may be performed.<sup>27-29</sup>

### ***Splinting / bracing***

There are two indications for splinting following an NBPP. The first is to functionally support a weak joint, for example using a brace that keeps the wrist in neutral position to improve functionality of the hand. The second is to treat contractures. The contracture that we encounter most frequently is the elbow flexion contracture. The prevalence of elbow flexion contracture, defined as a fixed position of the elbow, is nearly 50%.<sup>30</sup> Severe elbow flexion contracture, defined as more than 30 degrees, has been found in 21% to 36%.<sup>30, 31</sup> The etiology is multifactorial. It is presumed to result from a combination of passive tissue restrictions (the joint itself, the muscle fascia, the subcutis and the skin), active resistance caused by muscle contraction and poor coordination between m. biceps and m. triceps. There is strong evidence that elbow flexion contractures are largely due to the effects of denervation, which causes failure of the growth of the affected flexor muscles.<sup>30</sup> The muscle phenotype in elbow flexion contracture has been compared in children with NBPP and children with cerebral palsy. Both contractures are caused by lack of muscle length rather than excess of muscle strength.<sup>32</sup> These findings imply that contracture treatments should aim to lengthen rather than weaken the affected muscles. The efficacy of treating an elbow flexion contracture did not differ between serial casting and a dynamic orthosis.<sup>33</sup> It has been suggested that contracture of the glenohumeral joint can be prevented by applying the SupER splint.<sup>34, 35</sup> This SupER splint holds the arm in supination and in externally rotated position, and is recommended to be worn 22 hours per day. Unfortunately, long-term results of the SupER splint have not been analyzed.

***Botulinum toxin***

Botulinum toxin is a neurotoxic protein produced by the bacterium *Clostridium botulinum*. It prevents the release of the neurotransmitter acetylcholine at the neuromuscular junction. It causes a flaccid paralysis that lasts for several months. In children with NBPP there are a few indications for this treatment, although controversy exists regarding its efficacy.<sup>36</sup> Firstly, Botulinum toxin can be used to counter a progressive internal rotation contracture.<sup>37</sup> At our center, children with limited dysplasia of the glenohumeral joint are treated with Botulinum toxin injection of the m. subscapularis.<sup>38</sup> This procedure is performed under general anaesthesia, immediately after MRI imaging of the shoulder has been performed to determine the severity of the shoulder dysplasia. We found that it may be effective in preventing the need for tendon transfers in selected patients<sup>38</sup>, but other authors found that the effect of Botulinum toxin was not sufficiently sustained over time to be of clinical benefit.<sup>36</sup> A second indication for Botulinum toxin is the treatment of co-contractions of agonist and antagonist muscles after misrouted reinnervation. Currently, the most common indication is the treatment of co-contractions of the biceps and triceps muscles. The triceps muscle is weakened by the injection of Botulinum toxin, followed by rigorous physiotherapy training of elbow flexion.<sup>36</sup>

**OUTCOME ASSESSMENT*****Outcome and functioning: the ICF model***

Outcome assessment for children with NBPP may include a number of aspects, which can be classified according to the International Classification of Functioning, Disability and Health, which is a model developed by the World Health Organization. (Figure 16) The model includes a number of domains. The first domain is 'Body Functions and Body Structures' which includes features like motor function, strength, sensibility, contractures, pain, but also cosmetic deformity and developmental apraxia. Outcomes in the 'Activity and Participation' domain include aspects like self-care, mobility, school and leisure activities. The domains are influenced by 'Personal factors' and 'Environmental factors'. Ideally, outcome is assessed for all domains and factors. A systematic review, however, showed that the majority of studies focus on 'Body Functions and Body Structures' only.<sup>39</sup> Recent papers have started to assess outcomes in other domains.<sup>6, 40, 41</sup> Each domain of the ICF model is relevant for all ages, but one should realize that treatment priority may shift from 'Body

structures and functions’ at early ages (from birth to toddler) to ‘Activity and Participation’ as the child gets older.<sup>6</sup> Perspectives of functioning and health in the ICF model may differ between patients and their parents versus healthcare professionals.<sup>42</sup>

Most children had little knowledge of the etiology of the brachial plexus birth lesion. The health care specialist needed to explain the parents and their child about the cause of the condition.<sup>40</sup> Impact on the parents and family of having a child with a NBPP is an environmental factor that health care specialists should take into account to provide effective care from an early stage on.<sup>41</sup>

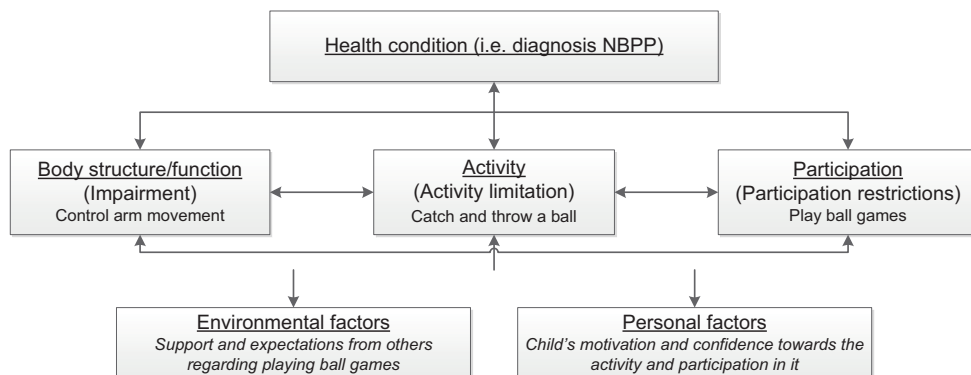


Figure 16 ICF model in relation to possible NBPP problems (Holst, van der<sup>43</sup>)

### Outcome evaluation

A large number of measures have been used to assess outcomes.<sup>39</sup> This is why it is difficult to compare studies, or pool data from different centers. In this respect, it would be desirable to have a standardized core outcome set. The Leiden Nerve Center has launched the first initiative towards such a core outcome set, which was named: iPLUTO: international Plexus Outcome Study group.<sup>44</sup> A Delphi round of surveys was employed using a nine-point Likert scale to rate the suitability of different outcome measures. Consensus was defined as a rating of 7/8/9 out of 10 by >75 % of the participants. International consensus was reached that evaluation should take place at specified follow-up moments based on the age of the child, namely 1, 3, 5, 7 and 15 years. The evaluation should include (1) passive range of motion (measured in degrees) of joint excursions; (2) active range of motion (also

measured in degrees); and (3) the Mallet score.<sup>45</sup> The Active Movement Scale and MRC grading of strength did not receive sufficient support to be endorsed in this survey.

In the first iPluto study, consensus was only reached on motor items from the 'Body Function and Structure' domain. Consensus regarding additional ICF domains (functionality, quality of life), will be addressed in future research.<sup>44</sup>

## **THE PEDIATRIC PHYSIOTHERAPIST**

The ICF model can be applied at all ages. The treatment priorities after NBPP, however, typically shift from a strong emphasis on body structure and body function in infancy toward greater emphasis on activity and participation as the child gets older.<sup>6</sup> The main goal for pediatric physiotherapists has been defined for different ages of the child: baby, toddler, pre-school, school age and adolescent. Depending on the setting, pediatric physiotherapists or occupational therapists perform these tasks in some countries.

### ***Babies***

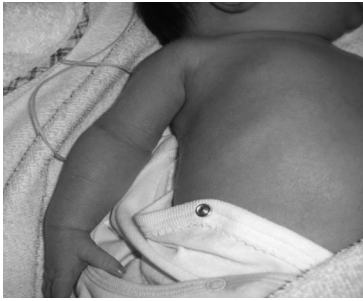The focus in this period is on the domains of body structure, active functioning and environmental factors. The environment involved consists mainly of the child's parents. As early as possible (preferably within one week after birth) a baby with a brachial plexus lesion will be assessed by a physiotherapist. In the early phase, the treatment primarily consists of providing information about the nerve lesion to the parents. It usually takes a great deal of repetition for the parents to grasp all available information. Most parents have experienced the birth as a traumatic life event. Feelings of guilt and failure may have emerged, besides feelings of anger towards the gynecologist, obstetrician, or midwife. The second objective is to perform exercises to prevent contractures. It is of eminent importance to start exercising as soon as possible. Joint movements relating to the paralyzed muscles must be applied by the parents multiple times a day. The parents are often afraid to move the affected arm, as they think that the nerve lesion may worsen or that rest is better to allow the nerves to recover faster. The only indication for immobilization of the affected arm is a clavicle or humerus fracture, and it will usually last for three weeks. In all other situations, the arm has to be moved at the joints as much as possible to prevent contractures. Comparison of joint excursions with the unaffected arm

## Chapter 1

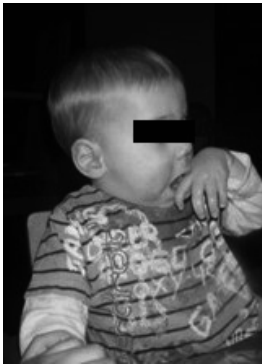can thereby be very helpful. The advice is to perform the exercises during every diaper change, resulting in practicing at least six times a day, for around five minutes. The joint movements at risk for contracture in case of a lesion of C5 and C6 are: external rotation, abduction, elbow flexion and supination. When C7, C8 or T1 are damaged too, care should be taken to include mobilization of wrist extension and radial abduction. When the hand is paretic or paralyzed, the joints of the fingers should be mobilized as well: ossa metacarpi (MCP) in flexion, but also phalanx proximal (PIP) and the phalanx distal (DIP) in extension. The physiotherapist provides the parents with instructions and advice on how to dress, undress, lift and bathe the child, with special focus on handling of the affected arm. In the early phase, these basic procedures may be challenging for the parents. The rule of thumb is that the postures and movements of the healthy side should be reproduced at the affected side. Care should be taken to prevent unphysiological positions or extreme movements, especially in case of a flail arm.

The child often exhibits a gaze preference towards the unaffected side, perhaps because it perceives movements of the unaffected arm and hand and successfully brings the unaffected hand to the mouth. (Figure 17) The physiotherapist must instruct the parents on how to stimulate the child to also look towards the affected side. This can be done by turning the head in that direction, or by drawing visual attention to the affected side.

The third objective is to help the child gain awareness of the affected arm and hand, so that the child can incorporate the affected side in their cerebral body image. This can be achieved and stimulated by bringing the child's affected hand in contact with different kinds of materials. It is important to stimulate playing with two hands together and engage the affected hand in activities. Providing stimuli drives sensibility development. Figure 18 shows an example of how a child brings his affected hand to his mouth to lick yoghurt from his fingers.



*Figure 17 One-week-old baby with a NBPP*



*Figure 18 Child (NBPP C5 to T1) brings his affected hand to his mouth, because he wants to lick yoghurt, an exercise helping the child to be aware of his hand.*

#### *Postoperative regimen after nerve surgery*

Immobilization is indicated during the first weeks after nerve reconstruction. Different hospitals apply different immobilization schemes. In our hospital, the baby's head, shoulder and arm are strictly immobilized in a cast for two weeks. (see Figure 14) This period is followed by three weeks of relative immobilization, where the head and neck can move freely, but abduction and external rotation in the glenohumeral joint are immobilized by putting the arm under the shirt. After this period, the physiotherapist and parents can restart the exercises to treat joint contractures.

#### ***Toddlers, pre-school and school age***

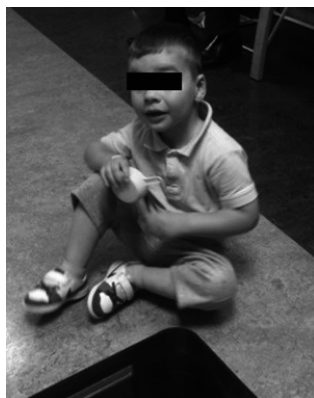The shift in treatment goals once the toddler age is reached is towards the domains of activity and participation, paying attention to environmental and personal factors. The end stage of neurological recovery is reached between the ages of 2 and 4 years, either from



## Chapter 1

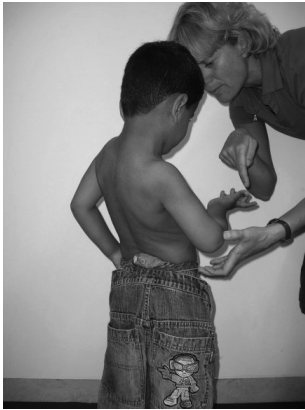natural recovery or recovery after surgery. In case of diminished hand function, recovery will take even longer.

Some situations may require special attention. At toddler age, a diminished balance may develop due to a favourite position veering towards the healthy side. (Figure 19) The reflex to break a fall by stretching out the arm is impeded by the NBPP and may necessitate extra support in learning how to walk.<sup>46</sup>



*Figure 19 A child with a right-sided NBPP of C5 to C7 puts his body weight on the non-affected left site. His right knee is supporting his affected arm to keep it in elbow flexion.*

Most children compensate for the lack of glenohumeral movement (both active and passive) by compensatory activity of the scapula. Such superfluous scapular movements, combined with internal rotation contracture and/or abduction contracture, are sometimes referred to as winging of the scapula. Another form of compensation can occur at the level of the spine, resulting in a compensatory scoliosis. (Figure 20)



*Figure 20* Rotation of the spine, because the child compensated for the lack of active glenohumeral external rotation

Riding a bike is sometimes a challenge, due to the asymmetric arm positions. When this is caused by the elbow flexion contracture, a night brace can help to reduce the contracture. If the difference in position between the two arms persists, an adjustment of the handlebar is an option to allow the child to sit straight on the bike. (Figure 21)



*Figure 21* Adjustment of a bicycle handlebar for a child with a right-sided NBPP

Self-care requiring bimanual activities, such as dressing or making a ponytail, may need extra support. Participation in sports and gymnastics at school (like throwing and catching a ball with two hands) may be hindered, in which case the gymnastics teacher (or swimming teacher) may need extra education and explanations.

Determining the best hand to write with may be troublesome in school. Most children with a right-sided NBPP will change the dominant hand to left side.<sup>47, 40, 48</sup>

### ***Adolescents***

Adolescence may warrant extra guidance and advice to make choices regarding sports<sup>49</sup>, education and future profession.<sup>50</sup> It is important to help adolescents find a balance between ability and capacity, which may be needed to prevent the development of pain and stress due to overuse. Health care professionals should be on the alert for signals of mental problems, as adolescents with NBPP may experience being different from their peers, or they may be teased or bullied because of their arm, which may cause disability-related distress and worries.<sup>48</sup> Regularly explaining what has happened to their arm is necessary for children and adolescent to learn about their own capacities.

### ***Teamwork***

It is important that children with an NBPP are treated early after birth by specialized health care professionals. The pediatric physiotherapist is the starting point for diagnosis and monitoring of these children, especially within specialized brachial plexus teams. Such multidisciplinary teams should also include specialized surgeons who can perform nerve repair and secondary surgery. Other treating specialists in the team may be a neurologist, and an occupational therapist. Early treatment may prevent a delay in sensorimotor development and secondary joint disorders. Early interventions may help the child integrate the arm as much as possible into its own body image. Possible psychological problems in children and parents can be recognized and treated in a timely manner.

## **CHILDREN WITH A NBPP AND THEIR SENSIBILITY**

### ***Importance of sensibility***

The importance of the sensibility of the hand was expressed by Lundborg as follows: “A hand without sensibility is usually a hand without function”.<sup>51</sup> The hand can be regarded as the interface between the brain and the environment, and the philosopher Descartes consequently called it “the outer brain”.<sup>52</sup> The mechanoreceptors in the hand react to tactile stimulation, and the resulting neural impulses are conducted by the peripheral nerves along the spinal cord to the somatosensory cortex of the brain. Sensory functions may be categorized as localization of touch and discrimination of touch, enabling the recognition of objects without using the eyes. Roughly speaking, one could say that vital

sensibility can warn against external influences which may disrupt the normal course of life, while gnostic sensibility serves to analyze these influences in more detail.

### ***Current knowledge about sensibility***

In many facets of the ICF domains of impairment, activity and participation, recovery of motor function is the primary focus. There is currently a knowledge gap as regards the sensibility of the hand in children with NBPP. Studies reporting assessment of sensibility have been rare and reported conflicting outcomes. Some of these studies described normal sensibility<sup>53-56</sup>, while others reported diminished sensibility.<sup>57-59</sup> These different studies are described in detail in the Appendix to this thesis. We felt that the currently available studies fell short in terms of methodology. One major limitation is that only two studies employed a control group.<sup>59, 60</sup> In many studies, the contralateral arm was used as control, which may be affected by the effect of a limb preference shift, which often occurs. We chose to include a control group and compare the affected arm with the non-dominant arm in the controls. A normal sensory input to the somatosensory cortex in early life is essential for the development of motor skills.<sup>13, 61</sup> The hypothesis in the present thesis is that the sensory development of children with NBPP is affected to a significant degree, and this in turn will have a major effect on motor performance, as the NBPP lesion occurs during a critical time window of brain development. The sensibility of the hand provides crucial feedback information to the central nervous system during development. Erroneous sensory input to the brain will lead to central apraxia or dyspraxia.<sup>13</sup> One example is the absence of automated swing of the affected arm when the child is walking or running, even when this movement can be executed voluntarily.<sup>62, 63</sup>

## **PAIN**

The literature on pain in children with a NBPP is scarce. It seems that the issue of pain is less important to assess for treating physicians than it is for patients.<sup>42</sup> One often-cited paper found 'no evidence of chronic pain behavior' in their cohort, although pain was not assessed at all during outpatient evaluation; it was simply not spontaneously reported by the children or their parents.<sup>53</sup> One study that actively and systematically documented pain in a cohort of 65 surgically treated children found a lifetime prevalence of 66%.<sup>64</sup> These authors reported no difference between children with upper or total plexus lesion. Another

## Chapter 1

study reported that 78% of the 37 children with NBPP (22 with orthopedic reconstructive surgery, 9 with orthopedic and nerve surgery, 1 with nerve surgery only and 5 with no surgical intervention) aged between 8 and 18 years experienced pain.<sup>65</sup> A factor that may play a role is that children may not only experience pain in a different way than adults, but that they may also use other words to describe pain.<sup>64</sup> Children may express pain as 'pain', but also as an 'unpleasant feeling' .

Self-mutilation may be considered another form of pain behavior. The incidence of biting fingers following NBPP was reported to be 11% (4/37 ) in children with a total NBPP and 2% (2/90) of children with a upper NBPP.<sup>66</sup> None of the children who exhibited this form of self-mutilation reported spontaneous pain. The third form of pain is that reported by adolescents or adults who experience pain of the affected shoulder caused by overuse of the muscles or shoulder joint. This pain is usually regarded as musculo-skeletal, and is thus not discussed in further detail here.

## OUTLINE OF THIS THESIS

**Chapter 2** describes the results of the assessment of the hand sensibility in healthy young children using instruments validated for adults. Testing in healthy children enabled us to identify which test tools are suitable, to adapt them as necessary, and to compare the dominant and nondominant sides.

After this standard had been set, the study reported on in **Chapter 3** assessed the sensibility of the hand in children with NBPP involving the upper nerves C5 and C6, and correlated the results with dexterity. **Chapter 4** describes an in-depth analysis of tactile hand sensibility, to correctly localize a sensory stimulus on the fingers. **Chapter 5** focusses on subjective experience of both the children and their parents regarding the perception of touching their hands.

In the study reported on in **Chapter 6**, we assessed the grip force of children with a C5 - C6 NBPP. Such an upper lesion should only affect shoulder muscles and elbow flexor muscles. Our clinical observation was, however, that children with an upper NBPP employed their hand less often in daily life. This is why we were interested in grip force and dexterity of the hand (as assessed in Chapter 3).

The consequences of NBPP regarding hand function cannot be explained solely by action mechanisms involving the peripheral nerves; the development of cortical programs must be involved as well.

Chapters 7 and 8 discuss other aspects of cortical development. In the study reported on in **Chapter 7**, we assessed whether children with NBPP have a higher incidence of central developmental disability compared to the general population, and related central delay to fidgety movements.

**Chapter 8** concerns one gross motor milestone in children with NBPP, namely the age of walking independently, which we compared with a control group from the literature.

**Chapter 9** summarizes all aspects, followed by a general discussion, and suggestions for further research. **Chapter 10** comprises a summary of this thesis in Dutch.

## REFERENCES

1. Pondaag W. Obstetric brachial plexus lesions : a framework for therapy [Docteral]. Leiden University - Scholarly Publication: Leiden University Medical Center; 2012.
2. Walle T, Hartikainen-Sorri AL. Obstetric shoulder injury. Associated risk factors, prediction and prognosis. *Acta Obstet Gynecol Scand.* 1993;72(6):450-4.
3. Pondaag W, Allen RH, Malessy MJ. Correlating birthweight with neurological severity of obstetric brachial plexus lesions. *BJOG.* 2011;118(9):1098-103.
4. Geutjens G, Gilbert A, Helsen K. Obstetric brachial plexus palsy associated with breech delivery. A different pattern of injury. *J Bone Joint Surg Br.* 1996;78(2):303-6.
5. Pondaag W, Malessy MJ, van Dijk JG, Thomeer RT. Natural history of obstetric brachial plexus palsy: a systematic review. *Dev Med Child Neurol.* 2004;46(2):138-44.
6. Duff SV, DeMatteo C. Clinical assessment of the infant and child following perinatal brachial plexus injury. *J Hand Ther.* 2015;28(2):126-33; quiz 34.
7. Malessy MJ, Pondaag W. Obstetric brachial plexus injuries. *Neurosurg Clin N Am.* 2009;20(1):1-14, v.
8. Seddon HJ. A Classification of Nerve Injuries. *Br Med J.* 1942;2(4260):237-9.
9. Sunderland S. A classification of peripheral nerve injuries producing loss of function. *Brain.* 1951;74(4):491-516.
10. van Vliet AC, Tannemaat MR, van Duinen SG, Verhaagen J, Malessy MJ, De Winter F. Human Neuroma-in-Continuity Contains Focal Deficits in Myelination. *J Neuropathol Exp Neurol.* 2015;74(9):901-11.
11. Chen L, Gao SC, Gu YD, Hu SN, Xu L, Huang YG. Histopathologic study of the neuroma-in-continuity in obstetric brachial plexus palsy. *Plast Reconstr Surg.* 2008;121(6):2046-54.
12. Malessy MJ, Pondaag W, Van Dijk JG. Electromyography, nerve action potential, and compound motor action potentials in obstetric brachial plexus lesions: validation in the absence of a "gold standard". *Neurosurgery.* 2009;65(4 Suppl):A153-A9.
13. Brown T, Cupido C, Scarfone H, Pape K, Galea V, McComas A. Developmental apraxia arising from neonatal brachial plexus palsy. *Neurology.* 2000;55(1):24-30.
14. Pondaag W, Malessy MJA. Evidence that nerve surgery improves functional outcome for obstetric brachial plexus injury. *J Hand Surg Eur Vol.* 2021;46(3):229-36.
15. Bialocerkowski A, Gelding B. Lack of evidence of the effectiveness of primary brachial plexus surgery for infants (under the age of two years) diagnosed with obstetric brachial plexus palsy. *JB Libr Syst Rev.* 2006;4(10):1-37.
16. Gilbert A, Tassin JL. [Surgical repair of the brachial plexus in obstetric paralysis]. *Chirurgie.* 1984;110(1):70-5.
17. Clarke HM, Curtis CG. An approach to obstetrical brachial plexus injuries. *Hand Clin.* 1995;11(4):563-80; discussion 80-1.
18. Malessy MJ, Pondaag W, Yang LJ, Hofstede-Buitenhuis SM, le Cessie S, van Dijk JG. Severe obstetric brachial plexus palsies can be identified at one month of age. *PLoS One.* 2011;6(10):e26193.
19. Hofstede-Buitenhuis SM, Malessy MJA, Pondaag W, Wijlen-Hempel vMS, Boer dK, Nelissen RGHH, et al. "Het Steindler-effect bij het obstetrisch plexus-brachialisletsel. *Tijdschrift voor kindergeneeskunde.* 2011;79(4):106-10.
20. Pondaag W, Groen JL, Malessy MJA. Endoscopic harvest of sural nerve for grafting in infants with brachial plexus birth injury. *J Hand Surg Eur Vol.* 2022;47(8):865-6.

21. Lapid O, Ho ES, Goia C, Clarke HM. Evaluation of the sensory deficit after sural nerve harvesting in pediatric patients. *Plast Reconstr Surg.* 2007;119(2):670-4.
22. Pondaag W, de Boer R, van Wijlen-Hempel MS, Hofstede-Buitenhuis SM, Malessy MJ. External rotation as a result of suprascapular nerve neurotization in obstetric brachial plexus lesions. *Neurosurgery.* 2005;57(3):530-7; discussion -7.
23. Pondaag W, Malessy MJ. Recovery of hand function following nerve grafting and transfer in obstetric brachial plexus lesions. *J Neurosurg.* 2006;105(1 Suppl):33-40.
24. Hogendoorn S, van Overvest KL, Watt I, Duijsens AH, Nelissen RG. Structural changes in muscle and glenohumeral joint deformity in neonatal brachial plexus palsy. *J Bone Joint Surg Am.* 2010;92(4):935-42.
25. Waters PM, Smith GR, Jaramillo D. Glenohumeral deformity secondary to brachial plexus birth palsy. *J Bone Joint Surg Am.* 1998;80(5):668-77.
26. Metsaars WP, Nagels J, Pijls BG, Langenhoff JM, Nelissen RG. Treatment of supination deformity for obstetric brachial plexus injury: a systematic review and meta-analysis. *J Hand Surg Am.* 2014;39(10):1948-58 e2.
27. Sebastin SJ, Chung KC. Pathogenesis and management of deformities of the elbow, wrist, and hand in late neonatal brachial plexus palsy. *Journal of pediatric rehabilitation medicine.* 2011;4(2):119-30.
28. van Alphen NA, van Doorn-Loogman MH, Maas H, van der Sluijs JA, Ritt MJ. Restoring wrist extension in obstetric palsy of the brachial plexus by transferring wrist flexors to wrist extensors. *Journal of pediatric rehabilitation medicine.* 2013;6(1):53-7.
29. Ruchelsman DE, Ramos LE, Price AE, Grossman LA, Valencia H, Grossman JA. Outcome after tendon transfers to restore wrist extension in children with brachial plexus birth injuries. *J Pediatr Orthop.* 2011;31(4):455-7.
30. Ho ES, Kim D, Klar K, Anthony A, Davidge K, Borschel GH, et al. Prevalence and etiology of elbow flexion contractures in brachial plexus birth injury: A scoping review. *Journal of pediatric rehabilitation medicine.* 2019;12(1):75-86.
31. Sheffler LC, Lattanza L, Hagar Y, Bagley A, James MA. The prevalence, rate of progression, and treatment of elbow flexion contracture in children with brachial plexus birth palsy. *J Bone Joint Surg Am.* 2012;94(5):403-9.
32. Nikolaou S, Garcia MC, Long JT, Allgier AJ, Goh Q, Cornwall R. Brachial plexus birth injury and cerebral palsy lead to a common contracture phenotype characterized by reduced functional muscle length and strength. *Front Rehabil Sci.* 2022;3:983159.
33. Op de Coul LS, Bleeker S, de Groot JH, Nelissen R, Steenbeek D. Elbow flexion contractures in neonatal brachial plexus palsy: A one-year comparison of dynamic orthosis and serial casting. *Clin Rehabil.* 2022:2692155221121011.
34. Durlacher KM, Bellows D, Verchere C. Sup-ER orthosis: an innovative treatment for infants with birth related brachial plexus injury. *J Hand Ther.* 2014;27(4):335-39; quiz 40.
35. Yefet L, Bellows D, Bucevska M, Courtemanche R, Durlacher K, Hynes S, et al. Can the Sup-ER Protocol Decrease the Prevalence and Severity of Elbow Flexion Deformity in Brachial Plexus Birth Injuries? *Hand (N Y).* 2022:15589447221093673.
36. Arad E, Stephens D, Curtis CG, Clarke HM. Botulinum toxin for the treatment of motor imbalance in obstetrical brachial plexus palsy. *Plast Reconstr Surg.* 2013;131(6):1307-15.



37. Michaud LJ, Louden EJ, Lippert WC, Allgier AJ, Foad SL, Mehlman CT. Use of botulinum toxin type A in the management of neonatal brachial plexus palsy. *PM R*. 2014;6(12):1107-19.
38. Duijnsveld BJ, van Wijlen-Hempel MS, Hogendoorn S, de Boer KS, Malessy MJ, Keurentjes JC, et al. Botulinum Toxin Injection for Internal Rotation Contractures in Brachial Plexus Birth Palsy. A Minimum 5-Year Prospective Observational Study. *J Pediatr Orthop*. 2017;37(3):e209-e15.
39. Sarac C, Duijnsveld BJ, van der Weide A, Schoones JW, Malessy MJ, Nelissen RG, et al. Outcome measures used in clinical studies on neonatal brachial plexus palsy: A systematic literature review using the International Classification of Functioning, Disability and Health. *Journal of pediatric rehabilitation medicine*. 2015;8(3):167-85; quiz 85-6.
40. Sarac C, Bastiaansen E, Van der Holst M, Malessy MJ, Nelissen RG, Vliet Vlieland TP. Concepts of functioning and health important to children with an obstetric brachial plexus injury: a qualitative study using focus groups. *Dev Med Child Neurol*. 2013;55(12):1136-42.
41. van der Holst M, Steenbeek D, Pondaag W, Nelissen RG, Vliet Vlieland TP. Neonatal Brachial Plexus Palsy in Children Aged 0 to 2.5 Years; Parent-Perceived Family Impact, Quality of Life, and Upper Extremity Functioning. *Pediatr Neurol*. 2016;62:34-42.
42. Sarac C, Nelissen R, van der Holst M, Malessy MJA, Pondaag W. Differences in the perspectives of functioning and health in the ICF model between patients with brachial plexus birth injury and their parents versus healthcare professionals. *Disability and rehabilitation*. 2022:1-6.
43. van der Holst M. Neonatal Brachial Plexus Palsy [Doctoral]: Leiden University Medical Center; 2017.
44. Pondaag W, Malessy MJA. Outcome assessment for Brachial Plexus birth injury. Results from the iPluto world-wide consensus survey. *J Orthop Res*. 2018;36(9):2533-41.
45. Mallet J. Obstetrical paralysis of the brachial plexus. II. Therapeutics. Treatment of sequelae. Priority for the treatment of the shoulder. Method for the expression of results. [in French]. *Rev Chir Orthop Reparatrice Appar Mot*. 1972;58 Suppl 1:166-8.
46. Bellows D, Bucevska M, Verchere C. Coordination and balance in children with birth-related brachial plexus injury: a preliminary study. *Physiother Can*. 2015;67(2):105-12.
47. Yang LJ, Anand P, Birch R. Limb preference in children with obstetric brachial plexus palsy. *Pediatr Neurol*. 2005;33(1):46-9.
48. Strombeck C, Fernell E. Aspects of activities and participation in daily life related to body structure and function in adolescents with obstetrical brachial plexus palsy: a descriptive follow-up study. *Acta paediatrica (Oslo, Norway : 1992)*. 2003;92(6):740-6.
49. Bae DS, Zurakowski D, Avallone N, Yu R, Waters PM. Sports participation in selected children with brachial plexus birth palsy. *J Pediatr Orthop*. 2009;29(5):496-503.
50. van der Holst M, Groot J, Steenbeek D, Pondaag W, Nelissen RG, Vliet Vlieland TP. Participation restrictions among adolescents and adults with neonatal brachial plexus palsy: the patient perspective. *Disability and rehabilitation*. 2018;40(26):3147-55.
51. Lundborg G, Rosen B. Hand function after nerve repair. *Acta Physiol (Oxf)*. 2007;189(2):207-17.
52. Lundborg G, Richard P. Bunge memorial lecture. Nerve injury and repair--a challenge to the plastic brain. *J Peripher Nerv Syst*. 2003;8(4):209-26.

53. Anand P, Birch R. Restoration of sensory function and lack of long-term chronic pain syndromes after brachial plexus injury in human neonates. *Brain*. 2002;125(Pt 1):113-22.
54. Strombeck C, Remahl S, Krumlind-Sundholm L, Sejersen T. Long-term follow-up of children with obstetric brachial plexus palsy II: neurophysiological aspects. *DevMed Child Neurol*. 2007;49(3):204-9.
55. Strombeck C, Krumlind-Sundholm L, Forssberg H. Functional outcome at 5 years in children with obstetrical brachial plexus palsy with and without microsurgical reconstruction. *Dev Med Child Neurol*. 2000;42(3):148-57.
56. Palmgren T, Peltonen J, Linder T, Rautakorpi S, Nietosvaara Y. Sensory evaluation of the hands in children with brachial plexus birth injury. *DevMed Child Neurol*. 2007;49(8):582-6.
57. Ho ES, Curtis CG, Clarke HM. Sensory Outcome in Children with Total Brachial Plexus Palsy Following Microsurgical Reconstruction. Annual Meeting of the American Society of Peripheral Nerve 2017.
58. Strombeck C, Krumlind-Sundholm L, Remahl S, Sejersen T. Long-term follow-up of children with obstetric brachial plexus palsy I: functional aspects. *Dev Med Child Neurol*. 2007;49(3):198-203.
59. Brown SH, Wernimont CW, Phillips L, Kern KL, Nelson VS, Yang LJ. Hand Sensorimotor Function in Older Children With Neonatal Brachial Plexus Palsy. *Pediatr Neurol*. 2016;56:42-7.
60. Anguelova GV, Malessy MJ, Van Dijk JG. A cross-sectional study of hand sensation in adults with conservatively treated obstetric brachial plexus lesion. *DevMed Child Neurol*. 2013;55(3):257-63.
61. Strombeck C, Krumlind-Sundholm L, Forssberg H. Functional outcome at 5 years in children with obstetrical brachial plexus palsy with and without microsurgical reconstruction. *Dev Med Child Neurol*. 2000;42(3):148-57.
62. Anguelova GV, Malessy MJ, Buitenhuis SM, van Zwet EW, van Dijk JG. Impaired Automatic Arm Movements in Obstetric Brachial Plexus Palsy Suggest a Central Disorder. *J Child Neurol*. 2016;31(8):1005-9.
63. Anguelova GV, Rombouts S, van Dijk JG, Buur PF, Malessy MJA. Increased brain activation during motor imagery suggests central abnormality in Neonatal Brachial Plexus Palsy. *Neurosci Res*. 2017;123:19-26.
64. Ho ES, Curtis CG, Clarke HM. Pain in children following microsurgical reconstruction for obstetrical brachial plexus palsy. *J Hand Surg Am*. 2015;40(6):1177-83.
65. Brown H, Quick TJ. The Characteristics of Pain Reported by Children with Brachial Plexus Birth Injuries. *APCP*. 2020;11(3):9.
66. Al-Qattan MM. Self-mutilation in children with obstetric brachial plexus palsy. *J Hand Surg Br*. 1999;24(5):547-9.