



Universiteit
Leiden
The Netherlands

A novel pathogenic IGSF1 variant in a patient with GH and TSH deficiency diagnosed by high IGF-I values at transition to adult care

Kardelen, A.D.; Özturan, E.K.; Poyrazoglu, S.; Bas, F.; Ceylaner, S.; Joustra, S.D.; ... ; Darendeliler, F.

Citation

Kardelen, A. D., Özturan, E. K., Poyrazoglu, S., Bas, F., Ceylaner, S., Joustra, S. D., ... Darendeliler, F. (2023). A novel pathogenic IGSF1 variant in a patient with GH and TSH deficiency diagnosed by high IGF-I values at transition to adult care. *Journal Of Clinical Research In Pediatric Endocrinology*, 15(4), 431-437.
doi:10.4274/jcrpe.galenos.2022.2021-12-3

Version: Publisher's Version
License: [Creative Commons CC BY-NC-ND 4.0 license](#)
Downloaded from: <https://hdl.handle.net/1887/3762619>

Note: To cite this publication please use the final published version (if applicable).

A Novel Pathogenic IGSF1 Variant in a Patient with GH and TSH Deficiency Diagnosed by High *IGF-I* Values at Transition to Adult Care

Aslı Derya Kardelen¹, Esin Karakılıç Özturan¹, Şükran Poyrazoğlu¹, Firdevs Baş¹, Serdar Ceylaner², Sjoerd D. Joustra³, Jan M. Wit³, Feyza Darendeliler¹

¹Istanbul University, Istanbul Faculty of Medicine, Department of Pediatric Endocrinology, Istanbul, Turkey

²Intergen Genetic Research Center, Ankara, Turkey

³Willem-Alexander Children's Hospital; Leiden University Medical Center, Department of Pediatrics, Division of Pediatric Endocrinology, Leiden, Netherlands

What is already known on this topic?

IGSF1 deficiency is a recently discovered disorder and data on long-term follow-up are scarce. Patients are known to have central hypothyroidism (CeH), prolactin deficiency, disharmonious pubertal development, and adult macroorchidism. Some of the patients exhibit short stature and growth hormone (GH) deficiency. However, GH deficiency is transient, and adult patients may have increased GH secretion and acromegaly-like features.

What this study adds?

Genetic analysis revealed a novel c.3559C > T (p.Q1187*) variant causing a stop codon in *IGSF1*. We suggest genetic analysis of *IGSF1* in patients with CeH, especially when accompanied by the clinical and laboratory features associated with the syndrome. Notably, children with CeH and GHD who show high insulin-like growth factor 1 levels at transition to adult care, should prompt analysis of *IGSF1*.

Abstract

IGSF1 deficiency is a rare X-linked condition characterized by central hypothyroidism and a wide variety of other clinical features with variable prevalence, including a delayed pubertal testosterone rise and growth spurt in the context of normal or accelerated testicular growth, and adult macroorchidism with relatively low serum testosterone concentrations. Other features include increased waist circumference, attention deficit, prolactin deficiency and transient partial growth hormone (GH) deficiency in childhood, contrasting with an increased GH secretion in adulthood. Patients with this disorder are not detected shortly after birth if neonatal screening programs are based on thyroid-stimulating hormone (TSH) concentrations. A 13.2-year-old male patient was referred to pediatric endocrinology for evaluation of short stature. He was born large for gestational age into a nonconsanguineous family. During work-up for short stature, deficiencies of TSH, prolactin and GH were detected, leading to treatment with levothyroxine and GH. At 16.9 years, GH treatment was stopped and during transition to adult care, his insulin-like growth factor 1 level was above the normal range. This prompted an analysis of IGSF1, in which a novel hemizygous variant causing a stop codon at c.3559C > T (p.Q1187*) was found, confirming the diagnosis of *IGSF1* deficiency syndrome. In this report, we describe his clinical and hormonal characteristics at presentation and during long-term follow-up.

Keywords: *IGSF1*, central hypothyroidism, short stature, large for gestational age, growth hormone deficiency, prolactin deficiency



Address for Correspondence: Aslı Derya Kardelen MD, Istanbul University, Istanbul Faculty of Medicine, Department of Pediatric Endocrinology, Istanbul, Turkey
E-mail: aslidyakardelen@gmail.com **ORCID:** orcid.org/0000-0003-0594-8741

Conflict of interest: None declared

Received: 14.12.2021

Accepted: 29.03.2022



©Copyright 2023 by Turkish Society for Pediatric Endocrinology and Diabetes / The Journal of Clinical Research in Pediatric Endocrinology published by Galenos Publishing House.
Licensed under a Creative Commons Attribution-NonCommercial-NoDerivatives 4.0 (CC BY-NC-ND) International License.

Introduction

Immunoglobulin superfamily member 1 (*IGSF1*) is a plasma membrane glycoprotein encoded by *IGSF1*. It consists of 20 exons and is located in the Xq26.1 region (1,2). Pathogenic *IGSF1* variants cause the X-linked *IGSF1* deficiency syndrome (MIM #300888) and characteristic features in hemizygous male patients include central hypothyroidism (CeH), delayed pubertal testosterone rise and growth spurt in the context of normal or accelerated testicular growth (disharmonious pubertal development) and adult macroorchidism with relatively low serum testosterone concentrations. A variable proportion of affected males show prolactin deficiency, increased waist circumference, decreased attentional control, with short stature and in 16 % there is growth hormone (GH) deficiency (3). However, GH deficiency is transient, and adult patients may exhibit increased GH secretion (4). The degree and age at presentation of CeH are variable, with some patients presenting in infancy or childhood and some patients being diagnosed with mild hypothyroidism at older age based on family studies (2,3,5,6). Given the rarity of this syndrome, the full spectrum of its phenotype and pathophysiology remain subjects of investigation (7).

Here we report a patient who presented with short stature, CeH and GH deficiency treated with levothyroxine and GH, in whom high plasma insulin-like growth factor-1 (IGF-1) levels during transition to adult care ultimately led to the identification of a novel *IGSF1* variant. We present longitudinal data of the patient with respect to pubertal development and anthropometric measurements, as well as clinical and laboratory features from his parents and brother.

Case Report

A 13.2-year-old male patient was referred to the endocrinology clinic for evaluation of short stature. He was born as the second child into a non-consanguineous family at 38 gestational weeks by Caesarean section, with a birth weight of 4400 g [3.0 standard deviation score (SDS)] (8). The first child had died one day after birth due to respiratory distress. Neonatal screening for hypothyroidism based on thyroid-stimulating hormone (TSH) measurement was normal. Neuromotor development was normal and, except for allergic bronchiolitis, the medical history revealed no abnormalities.

At presentation, the initial physical examination was normal (Table 1). His height was 1.44 m (-1.9 SDS), considerably shorter than target height (0.0 SDS). Body proportions and

weight were normal. Bilateral testicular volume assessed by the Prader orchidometer was 5 mL [-1.1 SDS, (9)] and pubic hair was at Tanner stage 2 (-0.7 SDS according to Dutch references) (10).

During workup for short stature (Table 2), his total blood count and biochemistry including electrolytes and lipids were within reference ranges. Plasma free thyroxine (fT4) concentration was below the normal range, while plasma TSH concentration was normal, leading to the diagnosis of CeH. The adrenocorticotrophic hormone stimulation test showed a normal peak cortisol of 19.5 mcg/dL. Levothyroxine treatment was started and led to normalisation of fT4. Low levels of plasma IGF-1 (180 ng/mL, -2.0 SDS) (11), and prolactin were detected. Low IGF-1 levels of 168 ng/mL (-2.3 SDS) persisted after levothyroxine treatment had started. Cranial and pituitary magnetic resonance images did not reveal any pathology.

At follow-up his growth velocity decreased (4.3 cm/year, -1.1 SDS) and GH stimulation tests were performed, showing a peak GH level of 6.87 ng/mL after insulin and 2.67 ng/mL after clonidine. Serum IGF-1 was 168 ng/mL (-2.3 SDS). GH treatment was started and consequently growth velocity increased to 8.9 cm/year (1.5 SDS) in the first year. Molecular analysis for *PROPI* and *POUIF1* genes was normal.

During pubertal evaluation, orchidometric testicular volume was 6 mL (-1.5 SDS) at 14 years, 15 mL (-1.7 SDS) at 16 years and 25 mL (0.0 SDS) at 17 years. At 15 years of age patient's follicle stimulating hormone (FSH) level was 5.5 mIU/L, luteinizing hormone (LH) level was 2.4 mIU/mL and testosterone level was 4.96 ng/mL. At 17.9 years testicular volume was at least 25 mL bilaterally (25 mL being the largest bead on the orchidometer) and measured 6 cm in length. Pubic hair was at Tanner stage 5 and testosterone level was 16.9 nmol/L. A testis ultrasound, performed at 22.8 years and using a similar formula to calculate testicular volume as used for the reference population, resulted in a normal testicular volume [right testis 16.2 mL (0.9 SDS), left testis 12.9 mL (-0.1 SDS)] (9). We performed a dual-energy X-ray absorptiometry scan and L1-L4 bone mineral density was 0.891 g/cm² (Z-score -1.8 SDS). GH was stopped at 16.9 years. Anthropometric measurements and pubertal stages of the patient are presented in Table 1.

At transition to adult care, six years after the cessation of GH therapy, plasma IGF-1 level had increased to 2.6 SDS (396 ng/mL) (Table 2), raising the suspicion of a possible *IGSF1* variant. Genetic analysis was performed and a novel hemizygous variant causing a premature stop codon (c.3559C > T, p.Gln1187*) was found (Figure 1). We established the diagnosis of the *IGSF1* deficiency syndrome,

Table 1. Anthropometric measurements and pubertal stage of the patient

Age (years)	13.2	15.9	16.9	22.8
Height, m (SDS)	1.44 (-1.9)	1.63 (-1.5)	1.69 (-0.9)	1.77 (0.2)
Weight, kg (SDS)	46.5 (0.4)	60.5 (-0.6)	60.7 (-0.9)	86.3 (1.3)
BMI, kg/m ² (SDS)	22.4 (0.7)	22.7 (0.3)	21.3 (-0.4)	27.5 (1.2)
SH/height (SDS)	0.54 (1.1)	0.52 (-0.6)	0.52 (-0.8)	0.51 (-1.2)
Arm span, cm	NA	NA	NA	180.5
Bone age, years	12.5	14	14	NA
PAH, m	1.69	1.76	1.82	NA
Tanner stage	T 5/5 mL PH 2 SPL 4 cm	T 15/15 mL PH 4 SPL 8 cm	T 25/25 mL PH 5 SPL 8 cm	T 30/25 mL PH 5 SPL 9 cm

BMI: body mass index, NA: not available, PAH: predicted adult height, PH: pubic hair, SH: sitting height, SDS: standard deviation score, SPL: stretched penile length, T: testis volume by orchidometer

Table 2. Hormonal evaluation of the patient

	At presentation (13.2 years)	Last evaluation (22.8 years)	Reference range
Prolactin (ng/mL)	2.3	2.9	4.8-23.3
TSH (mIU/L)	3.2	< 0.015*	0.66-4.14
ft4 (pmol/L)	10.1	13.3*	11.6-21.5
Cortisol (µg/dL)	11.5	11.8	2.8-23
DHEAS (µmol/L)	287	NA	114-296 at 13 years
IGF-1 (ng/mL)	180 ^a	396 ^b	^a 183-850 ^b 116-358
IGFBP-3 (µg/mL)	10.6 ^a	7.46 ^b	^a 3.1-9.5 ^b 3.4-7.8
FSH (IU/L)	NA	5.8	2.6-11
LH (IU/L)	NA	2.8	0.4-7.0
Testosterone (nmol/L)	NA	23.6	6.1-27.1
SHBG (nmol/L)	NA	40.5	14.5-48.4
AMH (ng/mL)	NA	7.78	0.73-16.05

*During suppletion with 150 µg levothyroxine (1.7 µg/kg) once daily.

AMH: anti-mullerian hormone, DHEAS: dehydroepiandrosterone sulfate, FSH: follicle-stimulating hormone, ft4: free thyroxine, IGF-1: insulin-like growth factor-1, IGFBP-3: insulin-like growth factor binding protein 3, LH: luteinizing hormone, SHBG: sex hormone binding globulin, TSH: thyroid stimulating hormone

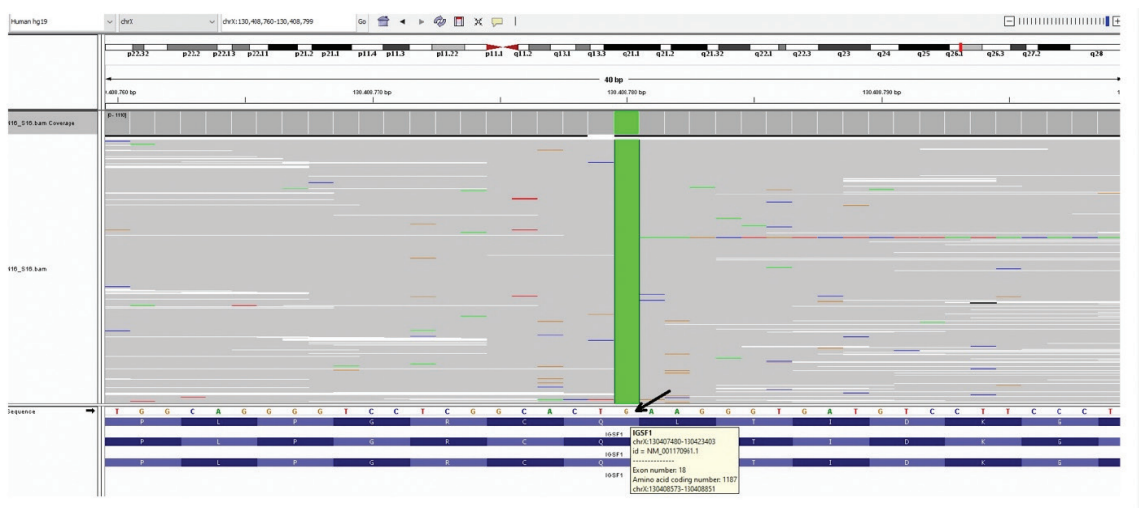


Figure 1. Next gene sequencing image of the novel hemizygous c.3559C > T (p.Q1187*) change in *IGSF1* gene of the patient

consistent with the combination of CeH, hypoprolactinemia, transient GH deficiency, short stature, large for gestational age at birth, and high IGF-1 levels in adulthood. The patient complained of clumsiness but did not report any attention problems, and currently works as a teacher. He had subtle facial coarsening without facial puffiness. At 22.8 years his waist circumference was 1.9 SDS (12) and body mass index (BMI) was 1.2 SDS (13).

The patient's mother is a heterozygous carrier for the *IGSF1* variant and her serum prolactin and fT4 levels were in the lower end of the reference range, while lipid profile was normal. Her age at menarche was 13 years. Her height was 1.58 m (-0.9 SDS) and weight was 94.8 kg (3.8 SDS). His younger brother did not consent to genetic analysis, but his fT4 was at the lower end of the reference range. His prolactin and lipid profile were in the normal ranges. His height was 1.89 m (2.0 SDS) and weight was 120 kg (3.3 SDS). The proband's father's thyroid function tests, prolactin levels and lipid profile did not reveal any pathology and he had a normal weight and height.

Molecular Analysis

Written informed consent was obtained from the patient and parents. Genomic DNA was extracted according to the manufacturer's standard procedure using the QIAamp DNA Blood Midi Kit (Qiagen, Hilden, Germany). *IGSF1* gene coding exon sequencing was performed on the MiSeq platform (Illumina inc, San Diego, CA, USA) with 150-bp pair-end reads.

Discussion

We identified a novel hemizygous *IGSF1* mutation variant in a male patient who initially presented with borderline short stature and a history of a high birth weight, in whom further investigations revealed CeH, GH deficiency and low serum prolactin. At that time, the *IGSF1* deficiency syndrome had not yet been clearly defined (2), and only recently information became available about the surprisingly broad phenotypic spectrum of *IGSF1* deficiency syndrome (3). If similar patients presented today, the combination of CeH (100%), prolactin deficiency (61%), increased birth weight (26%), and partial/transient GH deficiency (16%) would probably have led to genetic testing for *IGSF1*. In our case, the suspicion of *IGSF1* deficiency syndrome was triggered by a relatively novel and unusual observation, that of elevated plasma IGF-1 in adulthood, which has been described in 20% of patients with this syndrome (3,4).

Interestingly, several relatively frequent features of the syndrome were absent in this patient. The most prominent

of these is the normal testicular development in terms of testicular size and serum testosterone, while in a cohort of 69 males (3) low-normal testosterone concentrations and macroorchidism in adulthood were reported in 88%, and a delayed pubertal testosterone rise and early/normal timing of testicular growth in 75%. Other features that were absent included mild problems with attentional control (reported in 75%), a small thyroid gland (74%), increased waist circumference in adults (59%) and decreased dehydroepiandrosterone sulfate (40-50%).

Regarding the reported mild problems with attentional control in the *IGSF1* deficiency syndrome (14), it has been hypothesized that this may be related to inadequate prenatal T4 concentrations during critical periods of brain maturation (15,16). *IGSF1* is expressed (although in low quantity) in the adult rat cerebral cortex, striatum, subfornical organ, amygdala and glial cells of the hypothalamus, possibly having a direct effect on executive functioning (17). Our patient did not mention attention deficits. However, he did complain of clumsiness, which has also been described previously (3).

CeH is a rare condition and can result from dysfunctioning of the hypothalamus or pituitary gland. It can be part of multiple pituitary hormone deficiencies or be isolated. Isolated CeH is very rare and genetic causes include variants in *TSHB*, *TRHR*, *TBL1X* or *IGSF1*, the latter being the most common. The combination of CeH and prolactin deficiency are particularly suspicious for *IGSF1* deficiency, but are also observed in *TRH* receptor variants and may be a part of multiple hormone deficiency caused by a variant in *POU1F1*, *PROP1*, *HESX1* or *LHX3* (18). *IGSF1* deficiency is the most frequent inherited cause of CeH (18). The incidence of CeH caused by *IGSF1* deficiency is estimated to be 1:100,000 in the Netherlands and 1:80,000 in Japan (5,19). We therefore suggest performing genetic analysis for this gene in any case of non-acquired CeH, but especially if there are additional suggestive features of this syndrome (3). Detection of CeH by neonatal screening programs requires both fT4 and TSH determinations (20). In the Netherlands, neonatal screening for congenital hypothyroidism consists of fT4, TSH, and thyroxine-binding globulin since 1995. Our patient demonstrates the importance of determining both fT4 and TSH in screening and diagnosing all forms of hypothyroidism.

Growth of patients with the *IGSF1* deficiency syndrome resembles the growth pattern of constitutional delay of growth and puberty (CDGP), as characterized by growth retardation in early adolescence and a late pubertal growth spurt (3,6); in both conditions circulating testosterone levels are low. However, in *IGSF1* deficiency syndrome there is a

normal or even early start of testicular growth, while this is delayed in CDGP. It is unclear whether the slow growth in adolescence of males with *IGSF1* deficiency can be completely explained by the low circulating testosterone concentrations, or whether the partial GH deficiency also plays a role. Using current criteria for GHD, this was reported in 16% of children in *IGSF1* deficiency (3,4), but in all cases GHD was transient. Similarly, a recently published Turkish patient with *IGSF1* deficiency was treated with GH for two years, but during adolescence his GHD proved transient (21). Remarkably, in adult *IGSF1* deficient patients IGF-1 levels are generally in the upper half or even above the reference range, with increased GH secretion and variable mild acromegalic features in late adulthood (3,4,6). During childhood, our patient had short stature and low GH responses to pharmacological stimuli, but in adulthood plasma IGF-1 level was high. He had minimal facial coarsening however he did not have other acromegalic features. The underlying mechanism of transient GH deficiency and somatotrope hyperfunction in adulthood is unknown. As *IGSF1* is expressed in rat hypothalamus, including ~19% of Ghrh-expressing neurons, as well as in pituitary somatotropes, it may be implicated either in hypothalamic regulation of GH or play a somatotrope-specific role in GH production or secretion (4). As pathogenic *IGSF1* variants were not prevalent in a cohort of patients with CDGP without CeH or macroorchidism, testing for *IGSF1* variants in the absence of those symptoms is not recommended (22).

Delayed testosterone production and macroorchidism after adolescence are characteristic features of *IGSF1* deficiency (2). On ultrasonographic examination, most pediatric patients had testicular volumes in the upper half of the reference range, and 87% of adults showed macroorchidism (3,6). Our patient was at an early stage of puberty at presentation and it took about 2.5 years for his testes to enlarge from 4-5 mL to at least 25 mL at 22.8 years (an increase from -1.1 to +1.5 SDS). Thus, true macroorchidism was not diagnosed with the orchidometer in this patient. However, the upper limit of normal testicular volume in adults is 32 mL (9), and as the largest bead of a typical orchidometer is 25 mL, this device is not suitable for diagnosing adult macroorchidism. At physical examination, the length of the patient's adult testis was 6 cm. When assuming a corresponding width of 3.5 cm, the orchidometric volume would be estimated at 38.5 mL ($\pi/6 \times \text{length} \times \text{width}^2$) (9), thus above the reference range. The reasons for a lower Z-score measured with ultrasound is unclear.

It is not known why macroorchidism occurs in *IGSF1* deficient patients. It has been suggested that an increased

FSH to LH ratio plays a role (23), although both are generally within normal ranges, as was the case in our patient. An alternative explanation may be that FSH action is increased, either through increased sensitivity of gonadotropins to TRH (24) or by hypothyroidism, which lengthens the period of Sertoli cell proliferation and leads to an increase in Sertoli cell number and testes size (25). However, macroorchidism is also observed in *IGSF1* deficient patients treated with levothyroxine since birth. Although *IGSF1* deficient patients without macroorchidism have been reported (26), testicular growth in this condition typically starts at a normal or even advanced age, and shows a faster and longer growth period. Remarkably, testosterone secretion, pubic hair development and growth spurt start late. In all patients fertility was preserved, except one patient who was diagnosed with azoospermia and was resistant to treatment with FSH and LH (3).

Increased waist circumference and obesity are common in patients with *IGSF1* deficiency (3). In a previous report, an untreated patient with *IGSF1* deficiency showed profound hypercholesterolemia, with improvement after starting levothyroxine (27). Also, seven out of 69 (10.1%) male *IGSF1* patients were diagnosed with dyslipidemia, two of whom were on levothyroxine treatment (3). Our patient had a normal BMI and lipid profile before and after the levothyroxine was started.

Heterozygous female carriers are reported to have milder phenotypes, with low ft4, mild prolactin deficiency, increased BMI, and increased waist circumference. No fertility issues were reported among the female carriers (3). The mother of the index case was a carrier, and her prolactin and ft4 levels were at the lower tertile of the reference range and she did not have problems while lactating.

Since *IGSF1* deficiency has only been recognized for 10 years, data on long-term follow-up are scarce. Phenotype and genotype relation of patients with *IGSF1* deficiency has not been determined yet and clinical findings varied with the same mutation within families (3). Recently, Roche et al. (28) reported the largest family of *IGSF1* deficiency (c.2318T>C, p.L773P) with ten hemizygous males and 11 heterozygous females. Patients had classical endocrine manifestations of *IGSF1* deficiency however the penetrance of thyroid dysfunction (mild to moderate) and prolactin deficiency were variable.

Conclusion

In summary, we report a patient with a novel, pathogenic *IGSF1* variant who presented with CeH, hypoprolactinemia, borderline short stature and normal pubertal development

with an increasing testicular volume SDS over time, as well as a striking reversal of GH deficiency in adolescence to increased IGF-1 levels in adulthood. We suggest genetic analysis of *IGSF1* in any patient with CeH, especially when accompanied by any of the clinical and laboratory features associated with the *IGSF1* deficiency syndrome. Clinicians should keep in mind that these patients may exhibit high IGF-1 levels, acromegaly-like features, and macroorchidism in adulthood.

Acknowledgments

The authors wish to express their gratitude to the patient and his parents and family who participated in this study.

Ethics

Informed Consent: Written informed consent was obtained from the patient and the family.

Peer-review: Externally peer-reviewed.

Authorship Contributions

Concept: Aslı Derya Kardelen, Şükran Poyrazoğlu, Firdevs Baş, Feyza Darendeliler, Design: Aslı Derya Kardelen, Feyza Darendeliler, Data Collection or Processing: Aslı Derya Kardelen, Esin Karakılıç Özturan, Firdevs Baş, Serdar Ceylaner, Analysis or Interpretation: Aslı Derya Kardelen, Sjoerd D. Joustra, Jan M. Wit, Feyza Darendeliler, Literature Search: Aslı Derya Kardelen, Sjoerd D. Joustra, Jan M. Wit, Writing: Aslı Derya Kardelen, Sjoerd D. Joustra, Jan M. Wit.

Financial Disclosure: The authors declared that this study received no financial support.

References

1. Frattini A, Faranda S, Redolfi E, Allavena P, Vezzoni P. Identification and genomic organization of a gene coding for a new member of the cell adhesion molecule family mapping to Xq25. *Gene* 1998;214:1-6.
2. Sun Y, Bak B, Schoenmakers N, van Trotsenburg AS, Oostdijk W, Voshol P, Cambridge E, White JK, le Tissier P, Gharavy SN, Martinez-Barbera JP, Stokvis-Brantsma WH, Vulsma T, Kempers MJ, Persani L, Campi I, Bonomi M, Beck-Peccoz P, Zhu H, Davis TM, Hokken-Koelega AC, Del Blanco DG, Rangasami JJ, Ruivenkamp CA, Laros JF, Kriek M, Kant SG, Bosch CA, Biermasz NR, Appelman-Dijkstra NM, Corssmit EP, Hovens GC, Pereira AM, den Dunnen JT, Wade MG, Breuning MH, Hennekam RC, Chatterjee K, Dattani MT, Wit JM, Bernard DJ. Loss-of-function mutations in *IGSF1* cause an X-linked syndrome of central hypothyroidism and testicular enlargement. *Nat Genet* 2012;44:1375-1381. Epub 2012 Nov 11
3. Joustra SD, Heinen CA, Schoenmakers N, Bonomi M, Ballieux BE, Turgeon MO, Bernard DJ, Fliers E, van Trotsenburg AS, Losekoot M, Persani L, Wit JM, Biermasz NR, Pereira AM, Oostdijk W; *IGSF1* Clinical Care Group. *IGSF1* Deficiency: Lessons From an Extensive Case Series and Recommendations for Clinical Management. *J Clin Endocrinol Metab* 2016;101:1627-1636. Epub 2016 Feb 3. Erratum in: *J Clin Endocrinol Metab* 2017;102:2125.
4. Joustra SD, Roelfsema F, van Trotsenburg ASP, Schneider HJ, Kosilek RP, Kroon HM, Logan JG, Butterfield NC, Zhou X, Toufaily C, Bak B, Turgeon MO, Brülé E, Steyn FJ, Gurnell M, Koulouri O, Le Tissier P, Fontanaud P, Duncan Bassett JH, Williams GR, Oostdijk W, Wit JM, Pereira AM, Biermasz NR, Bernard DJ, Schoenmakers N. *IGSF1* Deficiency Results in Human and Murine Somatotrope Neurosecretory Hyperfunction. *J Clin Endocrinol Metab* 2020;105:70-84.
5. Tajima T, Nakamura A, Ishizu K. A novel mutation of *IGSF1* in a Japanese patient of congenital central hypothyroidism without macroorchidism. *Endocr J* 2013;60:245-249. Epub 2013 Jan 30
6. Joustra SD, Schoenmakers N, Persani L, Campi I, Bonomi M, Radetti G, Beck-Peccoz P, Zhu H, Davis TM, Sun Y, Corssmit EP, Appelman-Dijkstra NM, Heinen CA, Pereira AM, Varewijck AJ, Janssen JA, Ender E, Hennekam RC, Lombardi MP, Mannens MM, Bak B, Bernard DJ, Breuning MH, Chatterjee K, Dattani MT, Oostdijk W, Biermasz NR, Wit JM, van Trotsenburg AS. The *IGSF1* deficiency syndrome: characteristics of male and female patients. *J Clin Endocrinol Metab* 2013;98:4942-4952. Epub 2013 Oct 9
7. Bernard DJ, Brülé E, Smith CL, Joustra SD, Wit JM. From Consternation to Revelation: Discovery of a Role for *IGSF1* in Pituitary Control of Thyroid Function. *J Endocr Soc*. 2018;2:220-231. Erratum in: *J Endocr Soc* 2018;2:408.
8. Kurtoğlu S, Hatipoğlu N, Mazıcıoğlu MM, Akın MA, Çoban D, Gökoğlu S, Baştuğ O. Body weight, length and head circumference at birth in a cohort of Turkish newborns. *J Clin Res Pediatr Endocrinol* 2012;4:132-139. Epub 2012 May 4
9. Joustra SD, van der Plas EM, Goede J, Oostdijk W, Delemarre-van de Waal HA, Hack WW, van Buuren S, Wit JM. New reference charts for testicular volume in Dutch children and adolescents allow the calculation of standard deviation scores. *Acta Paediatr* 2015;104:271-278. Epub 2015 Mar 11
10. van Buuren S. Growth charts of human development. *Stat Methods Med Res* 2014;23:346-368. Epub 2013 Mar 12
11. Elmlinger MW, Kühnel W, Weber MM, Ranke MB. Reference ranges for two automated chemiluminescent assays for serum insulin-like growth factor I (IGF-I) and IGF-binding protein 3 (IGFBP-3). *Clin Chem Lab Med* 2004;42:654-664.
12. Hatipoğlu N, Ozturk A, Mazıcıoğlu MM, Kurtoglu S, Seyhan S, Lokoglu F. Waist circumference percentiles for 7- to 17-year-old Turkish children and adolescents. *Eur J Pediatr* 2008;167:383-389. Epub 2007 May 9
13. Bundak R, Furman A, Gunoz H, Darendeliler F, Bas F, Neyzi O. Body mass index references for Turkish children. *Acta Paediatr* 2006;95:194-198.
14. Joustra SD, Andela CD, Oostdijk W, van Trotsenburg AS, Fliers E, Wit JM, Pereira AM, Middelkoop HA, Biermasz NR. Mild deficits in attentional control in patients with the *IGSF1* deficiency syndrome. *Clin Endocrinol (Oxf)* 2016;84:896-903. Epub 2015 Oct 15
15. Kooistra L, van der Meere JJ, Vulsma T, Kalverboer AF. Sustained attention problems in children with early treated congenital hypothyroidism. *Acta Paediatr* 1996;85:425-429.
16. Simic N, Asztalos EV, Rovet J. Impact of neonatal thyroid hormone insufficiency and medical morbidity on infant neurodevelopment and attention following preterm birth. *Thyroid* 2009;19:395-401.
17. Joustra SD, Meijer OC, Heinen CA, Mol IM, Laghmani el H, Sengers RM, Carreno G, van Trotsenburg AS, Biermasz NR, Bernard DJ, Wit JM, Oostdijk W, van Pelt AM, Hamer G, Wagenaar GT. Spatial and temporal expression of immunoglobulin superfamily member 1 in the rat. *J Endocrinol* 2015;226:181-191. Epub 2015 Jul 10
18. Persani L, Cangiano B, Bonomi M. The diagnosis and management of central hypothyroidism in 2018. *Endocr Connec* 2019;8:44-54.

19. Joustra SD, van Trotsenburg AS, Sun Y, Losekoot M, Bernard DJ, Biermasz NR, Oostdijk W, Wit JM. IGSF1 deficiency syndrome: A newly uncovered endocrinopathy. *Rare Dis* 2013;1:e24883.
20. Léger J, Olivieri A, Donaldson M, Torresani T, Krude H, van Vliet G, Polak M, Butler G; ESPE-PES-SLEP-JSPE-APEG-APPES-ISPAE; Congenital Hypothyroidism Consensus Conference Group. European Society for Paediatric Endocrinology consensus guidelines on screening, diagnosis, and management of congenital hypothyroidism. *J Clin Endocrinol Metab* 2014;99:363-384. Epub 2014 Jan 21
21. Türkkahraman D, Karataş Torun N, Randa NC. A Case of Congenital Central Hypothyroidism Caused by a Novel Variant (Gln1255Ter) in IGSF1 Gene. *J Clin Res Pediatr Endocrinol* 2021;13:353-357. Epub 2020 Aug 10
22. Joustra SD, Wehkalampi K, Oostdijk W, Biermasz NR, Howard S, Silander TL, Bernard DJ, Wit JM, Dunkel L, Losekoot M. IGSF1 variants in boys with familial delayed puberty. *Eur J Pediatr* 2015;174:687-692. Epub 2014 Oct 30
23. Joustra SD, Roelfsema F, Endert E, Ballieux BE, van Trotsenburg AS, Fliers E, Corssmit EP, Bernard DJ, Oostdijk W, Wit JM, Pereira AM, Biermasz NR. Pituitary Hormone Secretion Profiles in IGSF1 Deficiency Syndrome. *Neuroendocrinology* 2016;103:408-416. Epub 2015 Aug 25
24. Weber G, Vigone MC, Stroppa L, Chiumello G. Thyroid function and puberty. *J Pediatr Endocrinol Metab* 2003;16(Suppl 2):253-257.
25. Holsberger DR, Cooke PS. Understanding the role of thyroid hormone in Sertoli cell development: a mechanistic hypothesis. *Cell Tissue Res* 2005;322:133-140. Epub 2005 Nov 3
26. Hughes JN, Aubert M, Heatlie J, Gardner A, Gecz J, Morgan T, Belsky J, Thomas PQ. Identification of an IGSF1-specific deletion in a five-generation pedigree with X-linked Central Hypothyroidism without macroorchidism. *Clin Endocrinol (Oxf)* 2016;85:609-615. Epub 2016 Jun 9
27. Heinen CA, Zwaveling-Soonawala N, Fliers E, Turgeon MO, Bernard DJ, van Trotsenburg ASP. A Novel IGSF1 Mutation in a Boy With Short Stature and Hypercholesterolemia: A Case Report. *J Endocr Soc* 2017;1:731-736.
28. Roche EF, McGowan A, Koulouri O, Turgeon MO, Nicholas AK, Heffernan E, El-Khairi R, Abid N, Lyons G, Halsall D, Bonomi M, Persani L, Dattani MT, Gurnell M, Bernard DJ, Schoenmakers N. A novel IGSF1 mutation in a large Irish kindred highlights the need for familial screening in the IGSF1 deficiency syndrome. *Clin Endocrinol (Oxf)* 2018;89:813-823. Epub 2018 Oct 1