



Universiteit
Leiden
The Netherlands

Robot-assisted and fluorescence-guided remnant-cholecystectomy: a prospective dual-center cohort study

Gijssen, A.F.; Vaassen, H.G.M.; Vahrmeijer, A.L.; Geelkerken, R.H.; Liem, M.S.L.; Bockhorn, M.; ... ; Lips, D.J.

Citation

Gijssen, A. F., Vaassen, H. G. M., Vahrmeijer, A. L., Geelkerken, R. H., Liem, M. S. L., Bockhorn, M., ... Lips, D. J. (2023). Robot-assisted and fluorescence-guided remnant-cholecystectomy: a prospective dual-center cohort study. *Hpb*, 25(7), 820-825.
doi:10.1016/j.hpb.2023.03.015

Version: Publisher's Version

License: [Licensed under Article 25fa Copyright Act/Law \(Amendment Taverne\)](#)

Downloaded from: <https://hdl.handle.net/1887/3762317>

Note: To cite this publication please use the final published version (if applicable).

ORIGINAL ARTICLE

Robot-assisted and fluorescence-guided remnant-cholecystectomy: a prospective dual-center cohort study

Anton F. Gijsen^{1,2}, Harry G.M. Vaassen^{1,3}, Alexander L. Vahrmeijer⁴, Robert H. Geelkerken^{1,3}, Mike S.L. Liem¹, Maximilian Bockhorn², Nader El-Sourani², J. Sven D. Mieog⁴ & Daan J. Lips¹

¹Department of Surgery, Medisch Spectrum Twente, Enschede, The Netherlands, Koningsstraat 1, Po-Box 50000, 7500 KA, Enschede, the Netherlands, ²Department of General and Visceral Surgery, University Medical Centre Oldenburg, Oldenburg, Germany, Rahel-Straus-Straße 10, 26133 Oldenburg, Germany, ³Multi-Modality Medical Imaging Group, TechMed Centre, University of Twente, Enschede, The Netherlands, Hallenweg 5, 7522 NH, Enschede, the Netherlands, and ⁴Department of Surgery, Leiden University Medical Centre, Leiden, The Netherlands, Albinusdreef 2, Po-Box 9600, 2300 RC, Leiden, the Netherlands

Abstract

Background: Abdominal symptoms after cholecystectomy may be caused by gallstones in a remnant gallbladder or a long cystic duct stump. Resection of a remnant gallbladder or cystic duct stump is associated with an increased risk of conversion and bile duct or vascular injuries. We prospectively investigated the additional value of robotic assistance and fluorescent bile duct illumination in redo biliary surgery.

Methods: In this prospective two-centre observational cohort study, 28 patients were included with an indication for redo biliary surgery because of remnant stones in a remnant gallbladder or long cystic duct stump. Surgery was performed with the da Vinci X® and Xi® robotic system. The biliary tract was visualised in the fluorescence Firefly® mode shortly after intravenous injection of indocyanine green.

Results: There were no conversions or perioperative complications, especially no vascular or bile duct injuries. Fluorescence-based illumination of the extrahepatic bile ducts was successful in all cases. Symptoms were resolved in 27 of 28 patients. Ten patients were treated in day care and 13 patients were discharged the day after surgery.

Conclusion: Robot-assisted fluorescence-guided surgery for remnant gallbladder or cystic duct stump resection is safe, effective and can be done in day-care setting.

Received 7 August 2022; accepted 23 March 2023

Correspondence.

Daan J. Lips, Department of Surgery, Medisch Spectrum Twente, Enschede, The Netherlands, Koningsstraat 1, Po-Box 50000, 7500 KA, Enschede, the Netherlands. E-mail: D.Lips@mst.nl

a.gijsen@mst.nl (A.F. Gijsen), Harry.Vaassen@mst.nl (H.G.M. Vaassen), a.l.vahrmeijer@lumc.nl (A.L. Vahrmeijer), R.Geelkerken@mst.nl (R.H. Geelkerken), M.Liem@mst.nl (M.S.L. Liem), maximilian.bockhorn@uni-oldenburg.de (M. Bockhorn), nader.el-sourani@uni-oldenburg.de (N. El-Sourani), [J.S.D. Mieog@lumc.nl](mailto:J.S.D.Mieog@lumc.nl) (J.S.D. Mieog)

Introduction

Laparoscopic cholecystectomy is considered as a safe and effective treatment of symptomatic gallstone disease. However, up to 35 percent of patients develop post-cholecystectomy syndrome.^{1–3} One of the possible causes of post-cholecystectomy syndrome is the cystic duct stump syndrome (CDS), which involves the presence of gallstones in a long cystic duct stump or remnant gallbladder. Symptoms of CDS include upper

abdominal pain, biliary colic, jaundice due to Mirizzi's syndrome, cholangitis, biliary pancreatitis and remnant cholecystitis.⁴ The incidence of incomplete gallbladder resection is very low following conventional cholecystectomy, but it is reported in up to 16% after the laparoscopic approach.^{5,6} One of the reasons for this high figure is that subtotal cholecystectomy is a commonly employed strategy when challenging gallbladder anatomy is encountered.⁷

If CDS symptoms are disabling for the patient, resection of the remnant gallbladder or cystic duct stump is a possible treatment.^{5,6,8–10} Nevertheless, the distorted anatomy following primary surgery makes laparoscopic redo biliary surgery challenging with reported rates of bile leakage in up to 9%, conversion in up to 17% and the need for a choledochoduodenostomy in up to 22% of patients.^{8,9,11,12}

Indocyanine green (ICG) is a water-soluble fluorescent contrast agent that, after intravenous injection, can be visualized *in vivo* using near-infrared (NIR) fluorescence imaging systems.¹³ Since it is predominantly eliminated by the liver and excreted through the biliary system, it enables intraoperative illumination of the extra-hepatic biliary anatomy, potentially decreasing common bile duct injury during cholecystectomies.^{14–17} Testing of ICG in the setting of redo biliary surgery has not been systemically performed.¹⁸

In this study, we prospectively investigated the value of robotic surgery together with the use of ICG-based fluorescence cholangiography in redo biliary surgery. The aim was to evaluate safety and efficacy. Our expectation was that real-time visualization of bile duct anatomy, together with the specific characteristics of robot-assisted surgery, would better enable the surgeon to perform this challenging procedure, resulting in reduced complications and earlier recovery.

Methods

This prospective two-centre observational study was conducted within the hepatobiliary units of Medisch Spectrum Twente and Leiden University Medical Centre. The study conformed to the ethics guidelines of the Declaration of Helsinki. Study protocol and data collection were approved by the institutional ethics committees and the need for written informed consent was waived under local regulations [K22-19].

Patient inclusion and data acquisition

During the period between December 2018 and September 2021, we included all consecutive patients over 18 years of age with an indication for redo surgery based on abdominal complaints after cholecystectomy and a remnant gallbladder or long cystic duct stump with gallstones on imaging. Patients were excluded if they had a known iodine allergy.

Baseline characteristics and data on initial surgery, imaging, redo-surgery and pathology were retrospectively collected from medical records. All patients were assessed after surgery in the outpatient clinic with a minimum follow-up one month. Additional diagnostic tests were performed when indicated by persistent abdominal symptoms.

The primary endpoint was occurrence of intra- or postoperative complications, defined and graded according to the Clavien-Dindo classification system.¹⁹ Secondary endpoints were conversion, defined as any laparotomy, length of procedure, defined as the time from incision until wound closure, length of

hospital admission, visualisation of the extra hepatic bile duct anatomy and bile leakage using NIR as determined by the operating surgeon, pathology outcomes and resolution of symptoms that were acknowledged at initial presentation before surgery.

Statistical analysis

Descriptive statistics are expressed using the mean with standard deviation (SD) or median with interquartile range (IQR). Correlation on decreasing operating time was expressed using Pearson correlation coefficient.

Surgical technique

Robotic surgery was performed using the da Vinci X® and Xi® system (Intuitive Surgical, Sunnyvale, CA, USA) by two experienced robot-trained gastrointestinal surgeons. A summary of the procedure can be seen in the supplemental video.

Before skin incision, between 2.5 mg and 5 mg ICG (Verdye, Diagnostic Green GmbH, Aschheim-Dornach, Germany) was administered intravenously. The camera port was placed periumbilical using an open technique. After placement of four additional ports, the da Vinci robot was docked. The attending surgeon had unrestricted access to the fluorescence signal channel (Firefly modus) during the identification of the extra-hepatic biliary tract including the remnant gallbladder or long cystic duct stump. Under fluorescent guidance the cystic duct or remnant gallbladder was skeletonized upon the junction with the common hepatic duct and secured with two clips, resected and sent for pathology (Image 1 and 2). In case of doubt of the arterial location or difficult identification of arterial structures, an additional bolus intravenous injection of 2.5 mg ICG could be administered. After resection, possible leakage of fluorescent bile was inspected with NIR imaging.

Results

A total of 28 patients were included (Table 1). There were no exclusions. The indication for primary surgery was symptomatic cholelithiasis (15/28), cholecystitis (9/28) and biliary pancreatitis (4/28). In the majority of patients, initial cholecystectomy was performed in an elective setting (20/28). Notably, in ten patients (10/28) the anatomy in Calot's triangle was reported to be unclear. Four patients (4/28) had a documented subtotal cholecystectomy. The indications for redo surgery were biliary colic (18/28), pancreatitis (6/28), remnant cholecystitis (3/28) and Mirizzi syndrome (1/28). Diagnosis of CDS was made with transabdominal ultrasound (5/28), endoscopic ultrasound (12/28) and MRCP (11/28). Fig. 1 shows indications for both the primary and redo procedures.

The conversion rate was zero during redo surgery and no intra- or postoperative complications and vascular injuries occurred in the 28 patients. The extra-hepatic biliary anatomy was adequately visualized with NIR fluorescence in all patients.

Table 1 Data on patient characteristics, primary surgery and redo surgery

Characteristic	Data (n = 28)
Age (years; mean ± SD)	51 ± 13.3
Gender	
Female	20
BMI (kg/m ² ; mean ± SD)	31 ± 6.8
ASA classification (%)	
I-II	23
III-IV	5
Primary Surgery	Data (n = 28)
Indication	
Symptomatic cholelithiasis	15
Cholecystitis	4
Biliary pancreatitis	4
Timing	
Acute	5
Elective	21
Unknown	2
Approach	
Laparotomy	4
Laparoscopy	22
Conversion	2
Subtotal cholecystectomy	4
Unclear anatomy in Calot's triangle	10
Redo surgery	Data (n = 28)
Anatomical indication	
Cystic duct stump	13
Remnant gallbladder	15
Clinical indication	
Cholecystolithiasis	18
Cholecystitis	3
Biliary pancreatitis	6
Mirizzi's syndrome	1
Imaging	
Transabdominal ultrasound	5
Endoscopic ultrasound	12
MRCP	11
Timespan (months; mean ± SD)	
Primary surgery to complaints	75 ± 96
Complaints to diagnosis	8.5 ± 13
Diagnosis to redo-surgery	3 ± 3
Primary surgery to redo-surgery	77 ± 74

ASA, American Society of Anaesthesiologists; BMI, body mass index; SD, standard deviation.

Pathologic examination showed biliary tissue in all specimens, inflammation in nine and gallstones in 18. The mean length of either the cystic duct stump or remnant gallbladder length was 2.9 cm (SD 0.91).

Duration of the procedure had a mean of 61 (SD 21.4) minutes and a significant decrease over time (Pearson's $R = -0.56$, $p = 0.002$; Fig. 2). Patients were routinely admitted one night after surgery during the initial phase of the study and were treated in day care with increasing experience. Ten patients (10/28) were ultimately treated in day care and thirteen (13/28) were discharged on the day after surgery. The median length of admission was one day. Five patients (5/28) had a longer admission due to the need for analgesia.

Twenty two patients were directly relieved of their initial symptoms after surgery. At follow-up, six patients (6/28) presented with postoperative complaints following a mean period of 25 days after surgery (range 7–63 days), all of whom showed no remnant gallbladder or cystic duct stump on imaging. Three patients (3/6) were diagnosed with choledocholithiasis and successfully treated with endoscopic retrograde cholangiopancreatography. One patient (1/6) was successfully treated with a proton pump inhibitor after ruling out other causes by laboratory tests and a MRCP. One patient (1/6) had spontaneous resolution of complaints and one patient (1/6) had persistent complaints with no clear cause despite an extensive diagnostic workup. Twenty-seven patients (27/28) were eventually completely relieved of their symptoms after surgery.

Discussion

In this study we demonstrated the value of robot assistance and fluorescent guidance during redo biliary surgery with no conversions or perioperative complications in 28 procedures and a success rate of 96%. Fluorescence assistance allowed us to adequately visualize the extrahepatic biliary anatomy in all patients. Furthermore we were able to reduce admission time to day care.

We believe several factors contributed to these favourable outcomes. The robotic arms allow for meticulous dissection in the small operative field, opposed to the rather blunt dissection with laparoscopic instruments. Three-dimensional view of the operating field provides better depth perception and anatomical detection. Real-time visualization of the biliary anatomy with NIR fluorescence allowed for safer dissection in an area of challenging anatomy. In addition, potential bile leakage due to iatrogenic injury could be ruled out intraoperatively.

Even though both operating surgeons were experienced in robot-assisted hepatobiliary surgery, a learning curve in the duration of the procedure was observed. With growing confidence in the accuracy of fluorescence guided surgery, dissection

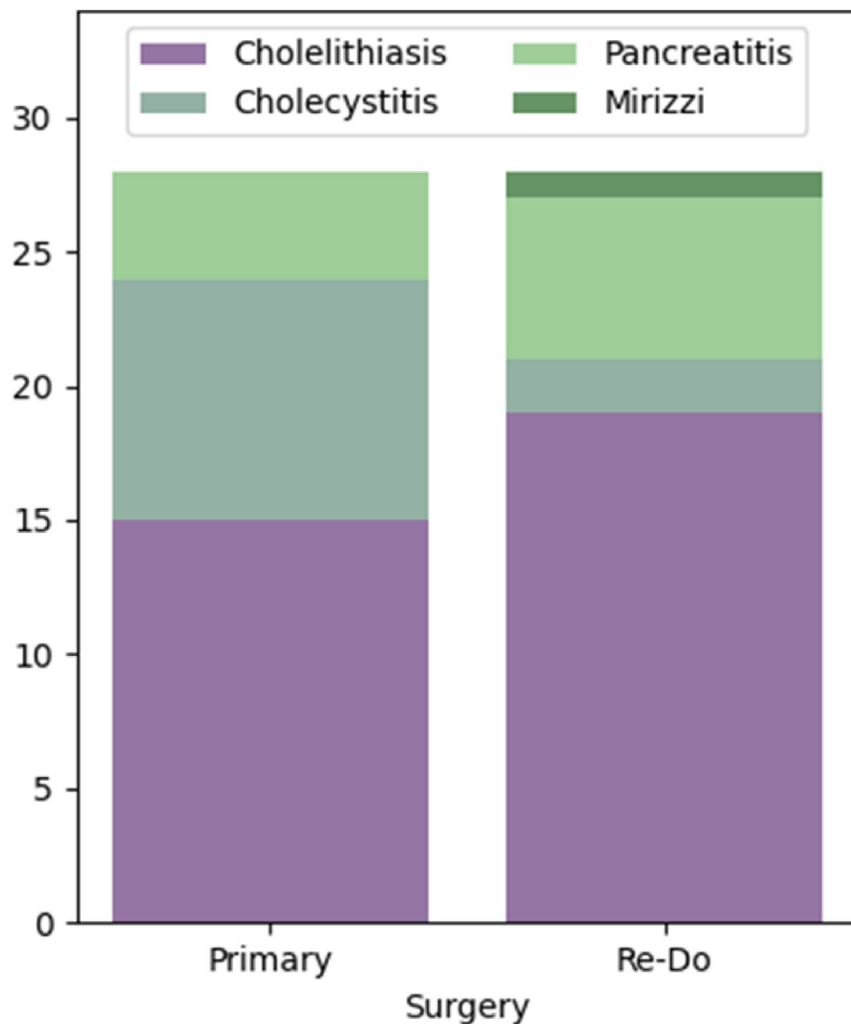


Figure 1 Indication for primary and redo surgery of all included patients

could be performed more rapidly. Our minimally invasive approach allowed us to have a short admission time and more than one third of patients was treated in day care. In our current clinical practice cystic duct stump resections are planned in day care surgery with robot assistance and fluorescence guidance.

In this study, one of 28 patients was not relieved of symptoms by surgery. Indeed, persisting symptoms after surgery for CDS is a familiar phenomenon.^{4,5,8} Despite having a remnant gallbladders with lithiasis on imaging, it is likely that the cause of this patients' post-cholecystectomy syndrome was not CDS. As observed in this and other studies, post-cholecystectomy syndrome a condition with heterogeneity in cause, and can additionally take a long time to develop and be diagnosed after cholecystectomy. This contributes to a lack of surgical success in a proportion of patients.^{4,5,8–12,20} However, patients with CDS due to a biliary pancreatitis originating from a cystic-duct-

stump-stone and remnant gallbladder inflammation have a clear indication for surgery. These patients too can have post-operative complaints confirming the heterogeneity of post-cholecystectomy syndrome. Similar to other studies, we observed patients with postoperative choledocholithiasis, possibly due to dislodgement of stones from the cystic duct or remnant gall bladder during surgery or due to formation in the intrahepatic bile system.^{10–12} Consequently, it is advised to have choledocholithiasis in the differential diagnosis of patients with postoperative complaints.

An interesting observation was that most primary cholecystectomies were done for symptomatic cholelithiasis in an elective setting. Notably, the anatomy in Calot's triangle was unclear in more than one third of patients and four patients had a documented subtotal cholecystectomy. This shows that an elongated cystic duct stump or remnant gallbladder, as a result of unclear

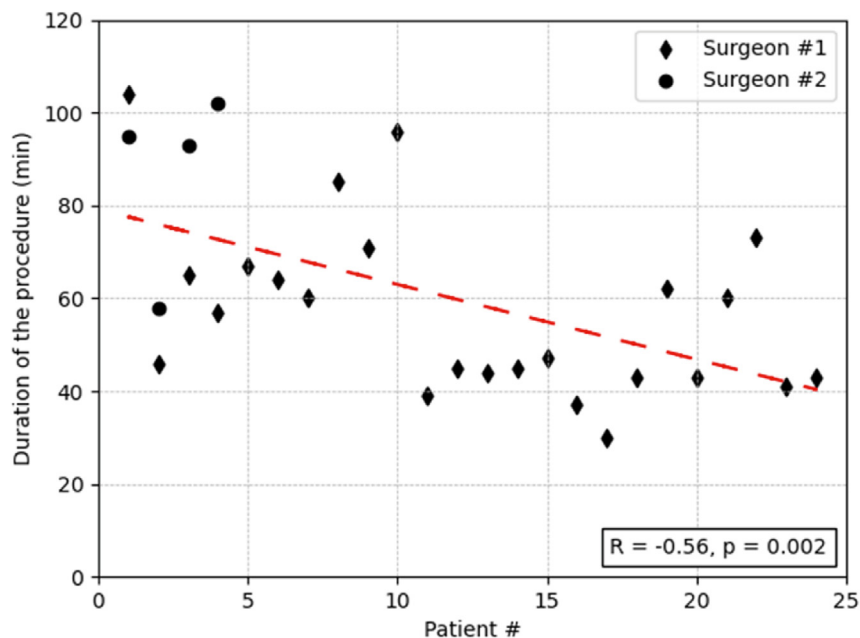


Figure 2 Duration of redo biliary surgery procedures in chronological order. The red dotted line represents a linear trendline fitting

anatomy, is not limited to complex and acute cholecystectomies. In none of these patients, fluorescence-guidance was used at the initial cholecystectomy.

Pathologic assessment in our study agreed with the definition of elongated cystic duct stump as being over 1.0 cm, since all specimens showed a longer stump.⁴ To prevent CDS, some studies have advocated a maximum cystic duct stump length of 0.5 cm, by dissecting thoroughly in Calot's triangle.¹² We would alternatively recommend focussing on preventing biliary injury, and perform re-intervention in an elective setting in case of persisting complaints due to lithiasis in a cystic duct remnant. The presented results show that this can be done safely and in day care, making it an accessible treatment strategy.

This study presents some limitations; First, we studied a single cohort in an observational setting without a control group. Furthermore, questions may be raised in consideration of the heterogeneity of the underlying disease conditions; however, the data reflects the clinical daily practice.

In conclusion, our series shows that robotic surgery with the assistance of fluorescence based illumination of biliary anatomy is safe and associated with a high success rate and short hospital stay. We believe this approach should be employed more often for indications after gallbladder surgery.

Funding sources

None.

Conflict of interest

None to declare.

References

1. van Dijk AH, Wennmacker SZ, de Reuver PR, Latenstein CSS, Buyne O, Donkervoort SC *et al.* (2019) Restrictive strategy versus usual care for cholecystectomy in patients with gallstones and abdominal pain (secure): a multicentre, randomised, parallel-arm, non-inferiority trial. *Lancet* 393:2322–2330. [https://doi.org/10.1016/S0140-6736\(19\)30941-9](https://doi.org/10.1016/S0140-6736(19)30941-9).
2. Lamberts MP, Lugtenberg M, Rovers MM, Roukema AJ, Drenth JPH, Westert GP *et al.* (2013) Persistent and de Novo symptoms after cholecystectomy: a systematic review of cholecystectomy effectiveness. *Surg Endosc* 27:709–718. <https://doi.org/10.1007/s00464-012-2516-9>.
3. Lamberts MP, Den Ouden BL, Gerritsen JJGM, Roukema JA, Westert GP, Drenth JPH *et al.* (2015) Prospective multicentre cohort study of patient-reported outcomes after cholecystectomy for uncomplicated symptomatic cholelithiasis. *Br J Surg* 102:1402–1409. <https://doi.org/10.1002/bjs.9887>.
4. Bodvall B, Overgaard B. (1966) Cystic duct remnant after cholecystectomy: incidence studied by cholegraphy in 500 cases, and significance in 103 reoperations. *Ann Surg* 163:382. <https://doi.org/10.1097/0000658-196603000-00009>.
5. Rogy MA, Függer R, Herbst F, Schulz F. (1991) Reoperation after cholecystectomy. The role of the cystic duct stump. *HPB Surg* 4: 129–135. <https://doi.org/10.1155/1991/57017>.
6. Rozsos I, Magyaródi Z, Orbán P. (1997) Cystic duct syndrome and minimally invasive surgery. *Orv Hetil* 138:2397–2401.

7. Elshaer M, Gravante G, Thomas K, Sorge R, Al-Hamali S, Ebdewi H. (2015) Subtotal cholecystectomy for 'difficult gallbladders': systematic review and meta-analysis. *JAMA Surg* 150:159–168. <https://doi.org/10.1001/jamasurg.2014.1219>.
8. Kar A, Gulati S, Mohammed S, Valappil MV, Sarala BB, Ghatak S *et al.* (2018) Surgical management of cystic duct stump stone or gall bladder remnant stone. *Indian J Surg* 80:284–287. <https://doi.org/10.1007/s12262-018-1724-5>.
9. Saroj SK, Kumar S, Afaque Y, Bhartia A, Bhartia VK. (2016) The laparoscopic Re-exploration in the management of the gallbladder remnant and the cystic duct stump calculi. *J Clin Diagn Res* 10:PC06. <https://doi.org/10.7860/JCDR/2016/20154.8342>, 8.
10. Walsh RM, Ponsky JL, Dumot J. (2002) Retained gallbladder/cystic duct remnant calculi as a cause of postcholecystectomy pain. *Surg Endosc Other Interv Tech* 16:981–984. <https://doi.org/10.1007/s00464-001-8236-1>.
11. Chowbey PK, Sharma A, Khullar R, Mann V, Bajjal M, Vashistha A. (2000) Laparoscopic subtotal cholecystectomy: a review of 56 procedures. *J Laparoendosc Adv Surg Tech Part A* 10:31–34. <https://doi.org/10.1089/lap.2000.10.31>.
12. Palanivelu C, Rangarajan M, Jategaonkar PA, Madankumar MV, Anand NV. (2009) Laparoscopic management of remnant cystic duct calculi: a retrospective study. *Ann R Coll Surg Engl* 91:25–29. <https://doi.org/10.1308/003588409X358980>.
13. Alander JT, Kaartinen I, Laakso A, Pättilä T, Spillmann T, Tuchin VV *et al.* (2012) A review of indocyanine green fluorescent imaging in surgery. *Int J Biomed Imag*. <https://doi.org/10.1155/2012/940585>, 2012.
14. Lim SH, Tan HTA, Shelat VG. (2021) Comparison of indocyanine green dye fluorescent cholangiography with intra-operative cholangiography in laparoscopic cholecystectomy: a meta-analysis. *Surg Endosc* 35: 1511–1520. <https://doi.org/10.1007/s00464-020-08164-5>.
15. Boogerd LSF, Handgraaf HJM, Huurman VAL, Lam HD, Mieog JSD, Van Der Made WJ *et al.* (2017) The best approach for laparoscopic fluorescence cholangiography: overview of the literature and optimization of dose and dosing time. *Surg Innovat* 24:386–396. <https://doi.org/10.1177/1553350617702311>.
16. Dip F, LoMenzo E, Sarotto L, Phillips E, Todeschini H, Nahmod M *et al.* (2019) Randomized trial of near-infrared incisionless fluorescent cholangiography. *Ann Surg* 270:992–999. <https://doi.org/10.1097/SLA.0000000000003178>.
17. Lehrskov LL, Westen M, Larsen SS, Jensen AB, Kristensen BB, Bisgaard T. (2020) Fluorescence or X-ray cholangiography in elective laparoscopic cholecystectomy: a randomized clinical trial. *Br J Surg* 107:655–661. <https://doi.org/10.1002/bjs.11510>.
18. Van Manen L, Tummers QRJG, Inderson A, Bhalla A, Vahrmeijer AL, Bonsing BA *et al.* (2019) Intraoperative detection of the remnant cystic duct during robot-assisted surgery using near-infrared fluorescence imaging: a case report. *BMC Surg* 19:104. <https://doi.org/10.1186/s12893-019-0567-8>.
19. Dindo D, Demartines N, Clavien PA. (2004) Classification of surgical complications: a new proposal with evaluation in a cohort of 6336 patients and results of a survey. *Ann Surg* 240:205–213. <https://doi.org/10.1097/01.sla.0000133083.54934.ae>.
20. Chowbey P, Soni V, Sharma A, Khullar R, Bajjal M. (2010) Residual gallstone disease - laparoscopic management. *Indian J Surg* 72: 220–225. <https://doi.org/10.1007/s12262-010-0058-8>.

Appendix A. Supplementary data

Supplementary data to this article can be found online at <https://doi.org/10.1016/j.hpb.2023.03.015>.