



Universiteit
Leiden
The Netherlands

Near-infrared fluorescence angiography with indocyanine green for perfusion assessment of DIEP and msTRAM flaps: a Dutch multicenter randomized controlled trial

Tange, F.P.; Verduijn, P.S.; Mulder, B.G.S.; Capelle, L. van; Koning, S.; Driessen, C.; ... ; Vorst, J.R. van der

Citation


Tange, F. P., Verduijn, P. S., Mulder, B. G. S., Capelle, L. van, Koning, S., Driessen, C., ... Vorst, J. R. van der. (2023). Near-infrared fluorescence angiography with indocyanine green for perfusion assessment of DIEP and msTRAM flaps: a Dutch multicenter randomized controlled trial. *Contemporary Clinical Trials Communications*, 33. doi:10.1016/j.conctc.2023.101128

Version: Publisher's Version

License: [Creative Commons CC BY 4.0 license](https://creativecommons.org/licenses/by/4.0/)

Downloaded from: <https://hdl.handle.net/1887/3762096>

Note: To cite this publication please use the final published version (if applicable).



Near-infrared fluorescence angiography with indocyanine green for perfusion assessment of DIEP and msTRAM flaps: A Dutch multicenter randomized controlled trial

F.P. Tange^{a,1}, P.S. Verduijn^{b,1}, B.G. Sibinga Mulder^b, L. van Capelle^a, S. Koning^a, C. Driessen^c, M.A.M. Mureau^d, A.L. Vahrmeijer^a, J.R. van der Vorst^{a,*}

^a Department of Surgery, Leiden University Medical Center, Albinusdreef 2, 2333 ZA, Leiden, the Netherlands

^b Department of Plastic and Reconstructive Surgery, Leiden University Medical Center, Albinusdreef 2, 2333 ZA, Leiden, the Netherlands

^c Department of Plastic and Reconstructive Surgery, Amsterdam University Medical Center, Meibergdreef 9, 1105 AZ, Amsterdam, the Netherlands

^d Department of Plastic and Reconstructive Surgery, Erasmus MC Cancer Institute, University Medical Center Rotterdam, Doctor Molewaterplein 40, 3015GD, Rotterdam, the Netherlands

ARTICLE INFO

Keywords:

Breast reconstruction
Free flap surgery
Near-infrared fluorescence
Indocyanine green
Perfusion
Fat necrosis
Reconstructive surgery
Quantification

ABSTRACT

Background: A common complication after a DIEP flap reconstruction is the occurrence of fat necrosis due to inadequate flap perfusion zones. Intraoperative identification of ischemic zones in the DIEP flap could be optimized using indocyanine green near-infrared fluorescence angiography (ICG-NIR-FA). This randomized controlled trial aims to determine whether intraoperative ICG-NIR-FA for the assessment of DIEP flap perfusion decreases the occurrence of fat necrosis.

Design/methods: This article describes the protocol of a Dutch multicenter randomized controlled clinical trial: the FAFI-trial. Females who are electively scheduled for autologous breast reconstruction using DIEP or muscle-sparing transverse rectus abdominis muscle (msTRAM) flaps are included. A total of 280 patients will be included in a 1:1 ratio between both study arms. In the intervention arm, the intraoperative assessment of flap perfusion will be based on both regular clinical parameters and ICG-NIR-FA. The control arm consists of flap perfusion evaluation only through the regular clinical parameters, while ICG-NIR-FA images are obtained during surgery for which the surgeon is blinded. The main study endpoint is the difference in percentage of clinically relevant fat necrosis between both study arms, evaluated two weeks and three months after reconstruction.

Conclusion: The FAFI-trial, a Dutch multicenter randomized controlled clinical trial, aims to investigate the clinical added value of intraoperative use of standardized ICG-NIR-FA for assessment of DIEP/msTRAM flap perfusion in the reduction of fat necrosis.

Clinical trial registration number: NCT05507710; NL 68623.058.18.

1. Introduction

Over the past 20 years the deep inferior epigastric perforator (DIEP) flap has increasingly been used for breast reconstruction with natural results and superior patient-reported outcomes [1–5]. When the calibre and quality of the perforator(s) is/are judged insufficient, extra muscle around the perforator(s) is transplanted by means of a muscle sparing transverse rectus abdominis muscle (msTRAM) flap [6,7]. A common complication after autologous breast reconstruction is the occurrence of fat necrosis in the transplanted flap due to zones of inadequate flap

perfusion or ischemia reperfusion injury [8,9]. In the current literature the reported incidence of fat necrosis in abdominal-based free flaps varies, ranging from 10% to 35% [10–13]. In addition, there is no consequent definition of fat necrosis used in previous clinical studies, which might explain the large variation in reported percentages. Fat necrosis has several levels of severity and can lead to major morbidity, infections, pain, delays in further oncologic treatment, and need for reinterventions. Furthermore, fat necrosis can result in poor aesthetic outcomes or cause fear and anxiety by mimicking breast cancer, also leading to additional invasive diagnostics [14,15]. Minimization of

* Corresponding author.

E-mail address: j.r.van_der_vorst@lumc.nl (J.R. van der Vorst).

¹ Both authors contributed equally and share first authorship.

these complications could be achieved by more accurate assessment of flap perfusion. Preoperative CT angiography for identification of perforators is currently standard of care [16]. Intraoperatively, subjective clinical assessment of perfusion is based on capillary refill, colour, temperature and handheld Doppler. Several intraoperative techniques for objective evaluation of flap perfusion have been analysed, including indocyanine green near-infrared fluorescence angiography (ICG--NIR-FA) [17,18]. Studies which investigated this clinically available technology for perfusion assessment demonstrated the potential of decreasing fat necrosis and flap failure rates [19–25].

This technique is still not used consistently, possibly because ICG-NIR-FA elongates operation time and reliable data on consequent reduction of fat necrosis is not available. In addition, all studies were performed with low patient numbers and without a clear definition of fat necrosis. This study protocol describes a randomized controlled trial that aims to investigate the clinical added value of intraoperative use of standardized ICG-NIR-FA for assessment of DIEP/msTRAM flap perfusion in the reduction of fat necrosis.

2. Methods

2.1. Primary aim

The primary aim of this study is to investigate whether intraoperative perfusion assessment of DIEP or msTRAM flaps using ICG-NIR-FA decreases the occurrence of fat necrosis compared to standard clinical perfusion assessment only.

2.2. Hypothesis

It is hypothesised that intraoperative perfusion assessment of the free DIEP/msTRAM flap using ICG-NIR-FA will decrease the occurrence of clinically relevant fat necrosis.

2.3. Study design

This study is a multicenter single-blinded randomized controlled trial. Eligible patients will undergo an uni- or bilateral autologous breast reconstruction using DIEP or msTRAM flaps. For randomization no distinction or stratification will be made for the type of flap. A total of 280 flaps will be randomised in a 1:1 ratio between assessment of flap perfusion with ICG-NIR-FA (intervention arm) and a standard DIEP procedure (control arm). In this study ICG administration is named intervention arm, however, ICG is not experimental and is standard of care and should therefore not be confused with experimental interventions. Patients will be stratified by institution.

2.4. Sample size calculation

Sample size calculation was performed for the primary endpoint, the occurrence of fat necrosis. The historical fat necrosis rate for the control arm, based on data of the department of Plastic Surgery of the LUMC and Erasmus MC, is approximately 15%. It is hypothesised this can be reduced to 5%. In order to decrease the incidence of fat necrosis with 10% (80% power and 2-sided significance level $\alpha = 0.05$), a total of 280 patients should be enrolled in the study.

2.5. Study population

Female patients of 18 years and older who are electively scheduled for one- or two-sided autologous breast reconstruction using DIEP or msTRAM flaps after mastectomy are included. Patient will have to sign informed consent. In case of a bilateral breast reconstruction, the flaps should be bilaterally anastomosed. Exclusion criteria are known allergy for ICG, iodine or shellfish, and impaired renal function ($eGFR < 50 \text{ mL/min/1.73m}^2$). Patients will also be excluded if there is any medical

condition that in the opinion of the investigators could potentially jeopardize the safety of the patient. Subjects can leave the study at any time for any reason if they wish to do so without any consequences. The investigator can decide to withdraw a subject from the study for urgent medical reasons.

2.6. Spectrum fluorescence imaging system

Imaging is performed using the Quest Spectrum fluorescence imaging system (Quest Medical Imaging, Middenmeer, the Netherlands). This system consist of three wavelength-isolated light sources, including a “white” light source and two separate NIR light sources. Colour video and fluorescence images are acquired simultaneously by separate sensors and are displayed in real time using custom-built optics and software, thereby displaying colour video and NIR fluorescence images separately. A pseudo-coloured (lime green) merged image of the colour video and fluorescence images can be generated also. The camera is attached to a freely moveable arm. During surgery, the camera and moveable arm are enclosed in a sterile shield and drape (Medical Technique Inc., Tucson, AZ, U.S.A.).

2.7. Randomisation, blinding and treatment allocation

Patients will be randomized in a 1:1 ratio between the intervention and the control group. All participants will receive ICG. Flaps in the control group will be assessed based on the current standard of care with only clinical evaluation. A recording of the flap will be made after anastomosis in the control group, but without the surgeon being present in the room and the recording will have no consequence for the procedure. In the intervention group, the surgeon is present in the room and is able to adjust the flap shape based on fluorescence imaging. A schematic overview of the study design is displayed in Fig. 1.

After all eligibility criteria are verified and written informed consent is obtained, patients are randomized through the internet-based randomization tool in Castor. Castor uses a variable block randomization method and patients will be allocated a unique study number. Furthermore, all needed information, study parameters and information from the case report forms will be collected in a CASTOR database.

In patients who undergo a bilateral reconstruction, with both flaps being anastomosed to the mammarial artery and vein of either side, the patient will firstly be randomized to determine in which arm the patient is included. Subsequently, the randomization tool determines which flap

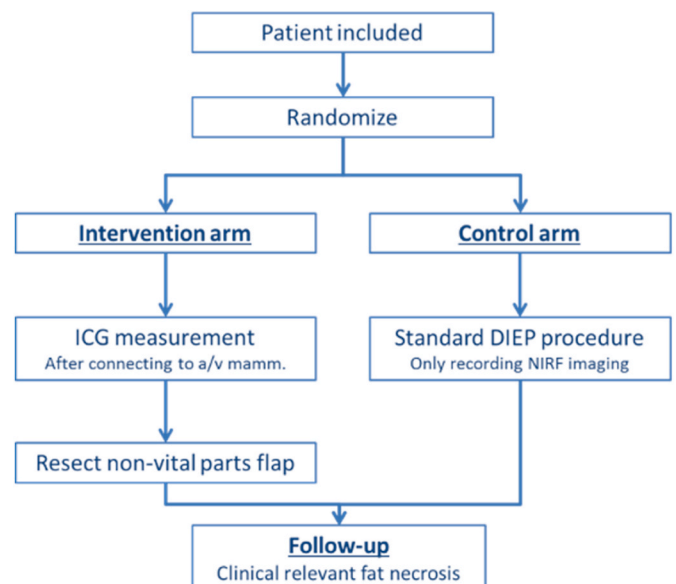


Fig. 1. Schematic representation of the study design.

is included in the study (left or right). Both breasts undergo the procedure according to the assigned study arm. The data of only one breast is included in the database, because otherwise the baseline characteristics of patients who undergo bilateral reconstruction will be weighed twice.

Patients will be blinded for the randomization and will be unblinded one year after the procedure. Hereby, bias is prevented since the patient's opinion about development of fat necrosis may affect the primary outcome.

2.8. Study procedures

Surgery of patients in the interventional arm will be performed according to local protocol. The DIEP flap composed of abdominal skin and fat is elevated from the abdomen with minimal trauma to the abdominal fascia and rectus abdominis muscle. Based on the desired volume of the DIEP flap, the perforator or perforators to be used is/are chosen. All other perforators are ligated and the DIEP vessels are dissected. After dissection the flap is clinically evaluated for viability and the parts with arterial or venous insufficiency are marked.

Flap viability during adequate hemodynamic conditions is evaluated as standard of care by assessing: capillary refill, turgor, temperature, colour and bleeding. Meanwhile, the acceptor vessels (e.g. internal mammary vessels) are exposed.

After anastomosis of the flap blood vessels, but before the inset, ICG-NIR-FA images are made. In case of a control arm patient, the surgeon will temporarily leave the operating room during the fluorescence imaging. A standard bolus of 7.5 mg ICG is intravenously injected and directly flushed with saline. The ICG-NIR-FA images are made using a standardized imaging protocol in which the camera settings are fixed and the camera is perpendicularly positioned at a distance of 60 cm from the flap. In case of an 'intervention-arm' patient, the flap is marked according to the fluorescence imaging, and insufficiently perfused parts are resected. The remaining flap will be shaped and used for breast reconstruction. After completing the surgery, the surgeon will have to fulfil the NASA TASK questionnaire to assess the work load.

2.9. Follow-up

Standard-of-care follow-up at the outpatient clinic will be conducted. Patients are seen two weeks and approximately three months after discharge by the surgeon. During the appointment three months after discharge, the patient will also be seen by an independent blinded breast surgeon who will determine whether clinically relevant fat necrosis is present. BREAST-Q questionnaires will be taken directly after inclusion and 3 months after the operation to measure patient satisfaction.

2.10. Outcome measures

2.10.1. Primary outcome

The primary objective is to determine whether ICG-NIR-FA for the assessment of DIEP/msTRAM flap perfusion during surgery decreases the occurrence of clinically relevant fat necrosis compared to standard clinical assessment of flap perfusion. Clinically relevant fat necrosis is defined as a palpable mass, either painful or not, and with or without aesthetic complaints, which has developed within three months after surgery. The fat necrosis grading system according to Lie et al. is used [26] and displayed in Table 1. Only grade III to IV is classified as clinically relevant fat necrosis. In case the surgeon or independent breast surgeon suspects fat necrosis, an ultrasound guided biopsy will be performed by a radiologist. Subsequently, the pathologist will assess the biopsy for histological confirmation of fat necrosis. The presence of fat necrosis will be noted as well as the potential need for re-intervention.

Table 1

Fat necrosis grading system according to Lie et al. [26].

Grade	Description	Flap involvement	Clinical findings	Surgical management
I	Minimal impact on final outcome	<5%	Nonmalignant lump <2 cm diameter	Conservative
II	Minor aesthetic defects	5–15%	Minor contour defects (single)	Debridement/excision and closure
III	Major compromised reconstructive outcome	15–50%	Major contour defects (multiple)	Debridement, secondary procedure
IV	Subtotal poor reconstructive outcome	>50%	Skin defects, inadequate volume, volume loss	Second local flap/re-intervention initial flap
V	Unviable	100%	No/poor flow, prolonged ischemia, patient unwell	Flap removal

2.10.2. Secondary outcomes

- To quantify flap perfusion, based on ICG-NIR-FA recordings in both study arms, correlated to the development of fat necrosis.
- To determine clinical and treatment-related factors that could contribute to the risk of developing fat necrosis.
- To assess intra-patient differences in percentage of fat necrosis in patients with bilateral breast reconstruction in whom one breast is randomized in the intervention arm.

The noted operation details consist of blood pressure and pulse during the fluorescence measurement, operation time, duration of flap ischemia, the type (retrograde/antegrade) and amount of arterial/venous anastomosis, total flap weight and the resected flap volume.

Between the study arms, the incidence of partial or total flap loss, duration of surgery, percentage of resected tissue of initial flap (weight), personal experience/opinion of surgeon performing surgery and patient satisfaction will be compared.

2.11. Statistical analysis

2.11.1. Baseline characteristics

All main analyses will be performed according to the intention to treat principle. Patients initially randomized but considered ineligible afterwards based on information that should have been available before randomization, will be excluded from all analyses. A two-sided p-value of 0.05 is considered statistically significant.

Descriptive statistics for patient demographics, baseline disease status, and patient disposition will be provided. Continuous demographic variables (age, height, weight, BMI) will be summarized by descriptive statistics (n, mean, SD, median, min, max). Qualitative demographic characteristics (sex, race/ethnicity) will be summarized by counts and percentages.

The endpoint for the primary analysis is the occurrence of clinical relevant fat necrosis. The formal test for comparing the fat necrosis percentages of the interventional arm with the control arm will be performed with a categorical frequency comparison, using the Chi-square test.

2.11.2. Secondary study parameters

- A univariable logistic regression analysis will be performed for the determination of clinical and treatment-related factors contributing to the risk of developing fat necrosis. Significant variables will be included in a multivariable logistic regression analysis.

- Intra-patient differences in percentage of fat necrosis in patients with bilateral breast reconstruction in whom one breast is randomized in the intervention arm.
- Incidence of partial or total flap loss will be compared with a Fisher exact or chi-square test.
- Duration of surgery will be compared with a T-test or Wilcoxon test.
- Percentage of resected tissue of initial flap (weight) will be compared with a Fisher exact or chi-square test.
- Personal experience/opinion of surgeon performing surgery with ICG-NIR-FA will be compared with a T-test or Wilcoxon test.
- Satisfaction of patients based on questionnaire BREAST-Q: the BREAST-Q score will be calculated using the Q-score program, converting the raw survey scores to continuous scores of 0–100. An unpaired *t*-test will be used to examine the significance of changes in mean scores of satisfaction with breast appearance, psychosocial well-being, sexual well-being, and physical well-being between the preoperative and postoperative surveys.
- Fisher's exact test will be used to detect any significant differences between pre-reduction and post-reduction satisfaction for a dichotomous outcome. A Pearson's correlation coefficient will be calculated to determine whether satisfaction in the overall outcomes section of the postoperative survey correlated with any other section.

2.12. Ethical consideration

This protocol has been approved by the Medical Ethical Committee Leiden-Den Haag-Delft (METC-LDD) and is registered at [ClinicalTrials.gov](https://www.clinicaltrials.gov). The investigator will ensure that this study is conducted in full compliance with the Subjects Act (WMO) and with the other laws and regulations of the country in which the clinical research is conducted.

Funding

This project is co-funded by the PPP Allowance made available by Health~Holland, Top Sector Life Sciences & Health, to stimulate public-private partnerships and by the H2020 project Photonics grant agreement id: 871,908.

Declaration of competing interest

The authors declare that they have no known competing financial interests or personal relationships that could have appeared to influence the work reported in this paper.

References

- [1] C. Healy, R.J. Allen, Sr, The evolution of perforator flap breast reconstruction: twenty years after the first DIEP flap, *J. Reconstr. Microsurg.* 30 (2) (2014) 121–125.
- [2] N.G. Patel, V. Ramakrishnan, Microsurgical tissue transfer in breast reconstruction, *Clin. Plast. Surg.* 44 (2) (2017) 345–359.
- [3] T. Hauck, R.E. Horch, M. Schmitz, et al., Secondary breast reconstruction after mastectomy using the DIEP flap, *Surg Oncol* 27 (3) (2018) 513.
- [4] C.A.E. Kouwenberg, K.M. de Lig, L.W. Kranenburg, et al., Long-term health-related quality of Life after four common surgical treatment options for breast cancer and the effect of complications: a retrospective patient-reported survey among 1871 patients, *Plast. Reconstr. Surg.* 146 (1) (2020) 1–13.
- [5] T.H. Damen, R. Timman, E.H. Kunst, et al., High satisfaction rates in women after DIEP flap breast reconstruction, *J. Plast. Reconstr. Aesthetic Surg.* 63 (1) (2010) 93–100.
- [6] D.W. Chang, Breast reconstruction with microvascular MS-TRAM and DIEP flaps, *Arch Plast Surg* 39 (1) (2012) 3–10.
- [7] M.Y. Nahabedian, B. Momen, G. Galdino, et al., Breast Reconstruction with the free TRAM or DIEP flap: patient selection, choice of flap, and outcome, *Plast. Reconstr. Surg.* 110 (2) (2002) 466–475. ; discussion 76-7.
- [8] A.S. Scheer, C.B. Novak, P.C. Neligan, et al., Complications associated with breast reconstruction using a perforator flap compared with a free TRAM flap, *Ann. Plast. Surg.* 56 (4) (2006) 355–358.
- [9] H. Bhullar, D.J. Hunter-Smith, W.M. Rozen, Fat necrosis after DIEP flap breast reconstruction: a review of perfusion-related causes, *Aesthetic Plast. Surg.* 44 (5) (2020) 1454–1461.
- [10] I. Khansa, A.O. Momoh, P.P. Patel, et al., Fat necrosis in autologous abdomen-based breast reconstruction: a systematic review, *Plast. Reconstr. Surg.* 131 (3) (2013) 443–452.
- [11] A. Hembd, S.S. Teotia, H. Zhu, et al., Optimizing perforator selection: a multivariable analysis of predictors for fat necrosis and abdominal morbidity in DIEP flap breast reconstruction, *Plast. Reconstr. Surg.* 142 (3) (2018) 583–592.
- [12] W.J. Peeters, L. Nanhekan, C. Van Ongeval, et al., Fat necrosis in deep inferior epigastric perforator flaps: an ultrasound-based review of 202 cases, *Plast. Reconstr. Surg.* 124 (6) (2009) 1754–1758.
- [13] S.O. Hofer, T.H. Damen, M.A. Mureau, et al., A critical review of perioperative complications in 175 free deep inferior epigastric perforator flap breast reconstructions, *Ann. Plast. Surg.* 59 (2) (2007) 137–142.
- [14] W.J. Casey 3rd, A.M. Rebecca, A. Silverman, et al., Etiology of breast masses after autologous breast reconstruction, *Ann. Surg Oncol.* 20 (2) (2013) 607–614.
- [15] K.M. Patel, L.M. Hill, M.E. Gatti, et al., Management of massive mastectomy skin flap necrosis following autologous breast reconstruction, *Ann. Plast. Surg.* 69 (2) (2012) 139–144.
- [16] J. Masia, J.A. Clavero, J.R. Larranaga, et al., Multidetector-row computed tomography in the planning of abdominal perforator flaps, *J. Plast. Reconstr. Aesthetic Surg.* 59 (6) (2006) 594–599.
- [17] R.F. Lohman, C.N. Ozturk, C. Ozturk, et al., An analysis of current techniques used for intraoperative flap evaluation, *Ann. Plast. Surg.* 75 (6) (2015) 679–685.
- [18] J.M. Smit, V.L. Negenborn, S.M. Jansen, et al., Intraoperative evaluation of perfusion in free flap surgery: a systematic review and meta-analysis, *Microsurgery* 38 (7) (2018) 804–818.
- [19] C. Holm, M. Mayr, E. Hofter, et al., Assessment of the patency of microvascular anastomoses using microscope-integrated near-infrared angiography: a preliminary study, *Microsurgery* 29 (7) (2009) 509–514.
- [20] N. Parmeshwar, S.M. Sultan, E.A. Kim, et al., A systematic review of the utility of indocyanine angiography in autologous breast reconstruction, *Ann. Plast. Surg.* 86 (5) (2021) 601–606.
- [21] E. Lauritzen, T.E. Damsgaard, Use of Indocyanine Green Angiography decreases the risk of complications in autologous- and implant-based breast reconstruction: a systematic review and meta-analysis, *J. Plast. Reconstr. Aesthetic Surg.* 74 (8) (2021) 1703–1717.
- [22] C. Driessen, T.H. Arnardottir, A.R. Lorenzo, et al., How should indocyanine green dye angiography be assessed to best predict mastectomy skin flap necrosis? A systematic review, *J. Plast. Reconstr. Aesthetic Surg.* 73 (6) (2020) 1031–1042.
- [23] I. Ludolph, A. Arkudas, M. Schmitz, et al., Cracking the perfusion code?: laser-assisted Indocyanine Green angiography and combined laser Doppler spectrophotometry for intraoperative evaluation of tissue perfusion in autologous breast reconstruction with DIEP or ms-TRAM flaps, *J. Plast. Reconstr. Aesthetic Surg.* 69 (10) (2016) 1382–1388.
- [24] N.C. Munabi, O.B. Olorunnipa, D. Goltzman, et al., The ability of intra-operative perfusion mapping with laser-assisted indocyanine green angiography to predict mastectomy flap necrosis in breast reconstruction: a prospective trial, *J. Plast. Reconstr. Aesthetic Surg.* 67 (4) (2014) 449–455.
- [25] A. Losken, M.R. Zenn, J.A. Hammel, et al., Assessment of zonal perfusion using intraoperative angiography during abdominal flap breast reconstruction, *Plast. Reconstr. Surg.* 129 (4) (2012), 618e-24e.
- [26] K.H. Lie, A.S. Barker, M.W. Ashton, A classification system for partial and complete DIEP flap necrosis based on a review of 17,096 DIEP flaps in 693 articles including analysis of 152 total flap failures, *Plast. Reconstr. Surg.* 132 (6) (2013) 1401–1408.