



Universiteit  
Leiden  
The Netherlands

## **Unipolar voltage mapping in right ventricular cardiomyopathy: pitfalls, solutions and advantages**

Hoogendoorn, J.C.; Venlet, J.; Riva, M. de; Wijnmaalen, A.P.; Piers, S.R.D.; Zeppenfeld, K.

### **Citation**

Hoogendoorn, J. C., Venlet, J., Riva, M. de, Wijnmaalen, A. P., Piers, S. R. D., & Zeppenfeld, K. (2023). Unipolar voltage mapping in right ventricular cardiomyopathy: pitfalls, solutions and advantages. *Ep Europace*, 25(3), 1035-1040. doi:10.1093/europace/euac278

Version: Publisher's Version

License: [Creative Commons CC BY-NC 4.0 license](https://creativecommons.org/licenses/by-nc/4.0/)

Downloaded from: <https://hdl.handle.net/1887/3759924>

**Note:** To cite this publication please use the final published version (if applicable).

# Unipolar voltage mapping in right ventricular cardiomyopathy: pitfalls, solutions and advantages

Jarieke C. Hoogendoorn <sup>1,2</sup>, Jeroen Venlet <sup>1,2</sup>, Marta de Riva<sup>1,2</sup>,  
Adrianus P. Wijnmaalen<sup>1,2</sup>, Sebastiaan R.D. Piers <sup>1,2</sup>,  
and Katja Zeppenfeld <sup>1,2\*</sup>

<sup>1</sup>Department of Cardiology, Heart Lung Center, Leiden University Medical Center, Albinusdreef 2, 2333ZA, Leiden, The Netherlands; and <sup>2</sup>Willem Einthoven Center for Arrhythmia Research and Management, Leiden University Medical Center, Albinusdreef 2, 2333 ZA, Leiden, The Netherlands; and Aarhus University Hospital, Palle Juul-Jensens Boulevard 99, DK-8200 Aarhus N, Denmark

Received 6 October 2022; accepted after revision 19 December 2022; online publish-ahead-of-print 14 January 2023

## Aims

Endocardial unipolar and bipolar voltage mapping (UVM/BVM) of the right ventricle (RV) are used for transmural substrate delineation. However, far-field electrograms (EGMs) and EGM changes due to injury current may influence automatically generated UVM. Epicardial BVM is considered less accurate due to the impact of fat thickness (FT). Data on epicardial UVM are sparse. The aim of the study is two-fold: to assess the influence of the manually corrected window-of-interest on UVM and the potential role of epicardial UVM in RV cardiomyopathies.

## Methods and results

Consecutive patients who underwent endo-epicardial RV mapping with computed-tomography (CT) integration were included. Mapping points were superimposed on short-axis CT slices and correlated with local FT. All points were manually re-analysed and the window-of-interest was adjusted to correct for false high unipolar voltage (UV). For opposite endo-epicardial point-pairs, endo-epicardial bipolar voltage (BV) and UV were correlated for different FT categories. A total of 3791 point-pairs of 33 patients were analysed. In 69% of endocardial points and 63% of epicardial points, the window-of-interest needed to be adjusted due to the inclusion of far-field EGMs, injury current components, or RV-pacing artifacts. The Pearson correlation between corrected endo-epicardial BV and UV was lower for point-pairs with greater FT; however, this correlation was much stronger and less influenced by fat for UV.

## Conclusion

At the majority of mapping sites, the window-of-interest needs to be manually adjusted for correct UVM. Unadjusted UVM underestimates low UV regions. Unipolar voltage seems to be less influenced by epicardial fat, suggesting a promising role for UVM in epicardial substrate delineation.

## Keywords

Right ventricle • Unipolar voltage • Epicardial fat • Window-of-interest • RV pacing

## What's new?

- Automatic measurement overestimates the unipolar voltage (UV) in the majority of points due to far-field electrograms, injury current components, or right ventricular pacing artifacts. Therefore, manual adjustment of the window-of-interest is needed for correct UV analysis.
- Epicardial UV is less influenced by epicardial fat and less dependent on the endo-epicardial wavefront compared with bipolar voltage. As such, the role of epicardial UV mapping is promising.

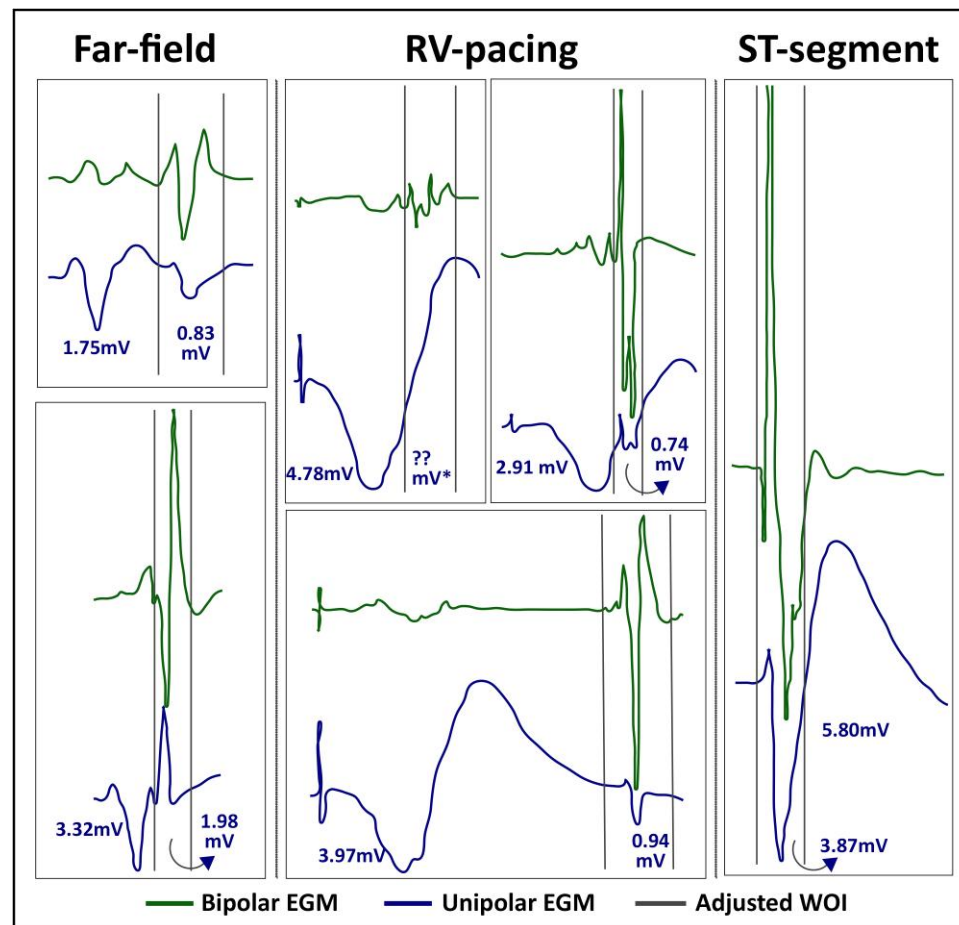
## Introduction

Three-dimensional (3D) voltage mapping (VM) is an important pillar to delineate scar during ventricular tachycardia (VT) ablation.<sup>1</sup> Low voltage areas may guide to VT-related sites in unmappable VTs. In the right ventricle (RV), VM may have an adjuvant role in determining the underlying aetiology of right ventricular cardiomyopathy.<sup>2–5</sup> Combining endocardial bipolar and unipolar voltage mapping (BVM/UVM) has been used to identify subepicardial scar, particularly for the thinner-walled RV.<sup>6,7</sup> Moreover, VM has been proved useful to increase the diagnostic yield of endomyocardial biopsies in RV cardiomyopathies.<sup>8</sup>

\* Corresponding author. Tel: +31 71 526 2020. E-mail address: k.zeppenfeld@lumc.nl

© The Author(s) 2023. Published by Oxford University Press on behalf of the European Society of Cardiology.

This is an Open Access article distributed under the terms of the Creative Commons Attribution-NonCommercial License (<https://creativecommons.org/licenses/by-nc/4.0/>), which permits non-commercial re-use, distribution, and reproduction in any medium, provided the original work is properly cited. For commercial re-use, please contact [journals.permissions@oup.com](mailto:journals.permissions@oup.com)



**Figure 1** Examples of adjustment of the WOI. The automatically and manually adjusted WOI UV values are shown. \*In this unipolar EGM, the near-field is completely obscured within the far-field signal caused by RV pacing, and therefore, the unipolar amplitude cannot be determined. EGM, electrogram; RV, right ventricle; UV, unipolar voltage; WOI, window-of-interest.

Bipolar voltage (BV) is influenced by the electrode size, spacing, catheter contact, activation wavefront, and the angle of catheter incidence.<sup>9</sup> Of note, at the epicardium, the mapping catheter is typically orientated parallel to the epicardial surface and *perpendicular* to an endo-epicardial wavefront.<sup>10</sup> Importantly, epicardial BV is significantly attenuated by epicardial fat. As a consequence, suggested epicardial bipolar cut-off values for abnormal voltages are usually lower (BV < 1.0 mV) and less accurate considering the highly variable fat thickness (FT).<sup>11,12</sup>

Unipolar voltage (UV) is less wavefront dependent, is considered to have a wider field of view, and may be less influenced by epicardial fat compared with BV, although data on epicardial UVM are sparse.<sup>11</sup> Based on the assumptions of wavefront independency, a transmural field of view of UV for the thinner-walled RV and lesser influence of epicardial fat, simultaneous recorded endo-epicardial UV at opposite sites should produce a similar amplitude of the electrogram (EGM).

Three-dimensional mapping systems display the largest peak-to-peak EGM amplitude within the window-of-interest, usually set from the QRS onset. Artifacts, far-field EGMs, and EGM changes due to a mechanically induced injury current may influence automatically generated UVM, but cannot be identified by current algorithms.

The aim of this study was two-fold: (i) to evaluate the influence of manual adjustment of the window-of-interest on the amplitude of

UV recorded in the endocardial and epicardial RV and (ii) to assess the correlation between adjusted endo- and epicardial UV in the RV and the influence of epicardial FT.

## Methods

Consecutive patients between 2006 and 2015 with RV scar-related VT who underwent combined endo- and epicardial RV mapping and ablation, with computed-tomography (CT) integration, were included. A 3D mesh of epicardial FT was reconstructed and pre-procedurally imported in CARTO. The ostium of the left main coronary artery was used as a landmark together with the endocardial surfaces for correct alignment. Post-procedural, all mapping points were superimposed on the short-axis CT using Mass (V2013-EXP, LEKB, Leiden) and Matlab (software version 2014-b). This method is routinely practised in our centre and has been described in detail before.<sup>13,14</sup>

Each endocardial point was linked to the closest epicardial point, based on the shortest Euclidean distance between 3D coordinates. Therefore, one epicardial point could be linked to  $\geq 1$  endocardial point. Only point-pairs with a distance < 10 mm were included and point-pairs at ablation or location-only sites were excluded from the analysis. Point-pairs were subdivided according to local FT categories (FT < 1, 1–2.7, and  $\geq 2.8$  mm) based on previous studies.<sup>11,13</sup>

### Review of mapping points and adjustment of window-of-interest

The unipolar EGMs of all included points were reviewed and re-analysed in CARTO. The window-of-interest was manually adjusted to include the near-field BV and local UV, and thus excluding (i) far-field signals, (ii) RV-pacing or other artifacts, and (iii) EGM components due to mechanically induced injury current from the measurements of the EGM amplitude (Figure 1). The corrected UV was collected and used for further data analysis.

### Data analysis

The absolute difference between the automatically generated UV within the standard window-of-interest and the corrected UV was calculated. Next, the number of points re-categorized as scar after adjustment was calculated, based on the previously suggested cut-offs for endocardial UV in the RV, namely 5.5,<sup>6</sup> 4.4,<sup>7</sup> and 3.8 mV.<sup>15</sup>

Endocardial voltages were correlated with the corresponding epicardial voltages using Pearson correlation per fat category for both UV and BV. In addition, the absolute difference (voltage<sub>epi</sub> minus voltage<sub>endo</sub>) and the ratio (voltage<sub>epi</sub> divided by voltage<sub>endo</sub>) between corresponding endo- and epicardial voltages were calculated. The endo-epicardial ratio for UV and BV in different FT was compared using the Wilcoxon signed-rank test.

To minimize the influence of fat and to allow comparison of voltages at precisely facing endocardial-epicardial recording positions, a separate

analysis was performed for point-pairs with a distance <5 mm and FT <1 mm. A P-value ≤0.05 was considered significant. Statistical analysis was performed using IBM SPSS version 25 (IBM Corporation, New York, USA).

## Results

### Study population

Thirty-three patients were included (mean age 50 ± 14 years, 79% male).<sup>13</sup> The underlying aetiology was arrhythmogenic right ventricular cardiomyopathy (n = 18), athlete’s right ventricular outflow tract scar (n = 9), cardiac sarcoidosis (n = 3), scar of unknown origin (n = 2), and post-myocarditis (n = 1). Mapping was performed during sinus rhythm or conducted supraventricular rhythm in 30 patients and during RV pacing in 3 patients. In total, 3791 point-pairs with a distance <10 mm were included and re-analysed, consisting of 3791 unique endocardial points and 1798 unique epicardial points.

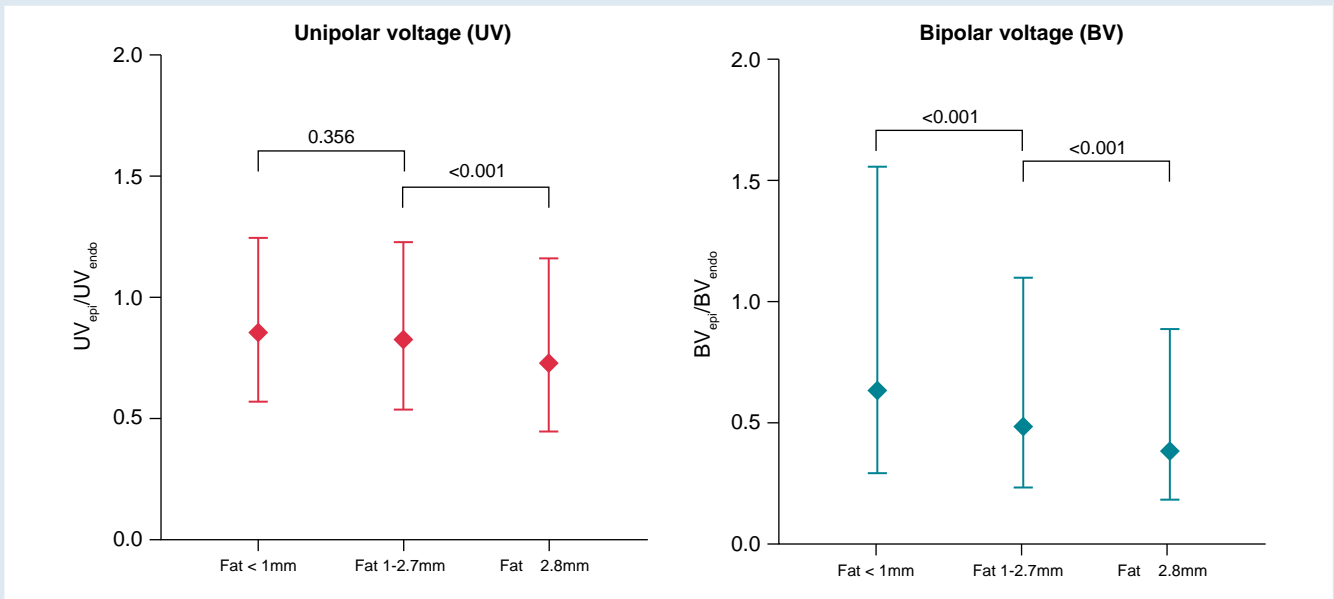
### Adjustment window-of-interest

For 2631 (69%) endocardial points and 1125 (63%) epicardial points, the window-of-interest needed to be adjusted. Reasons for adjustment

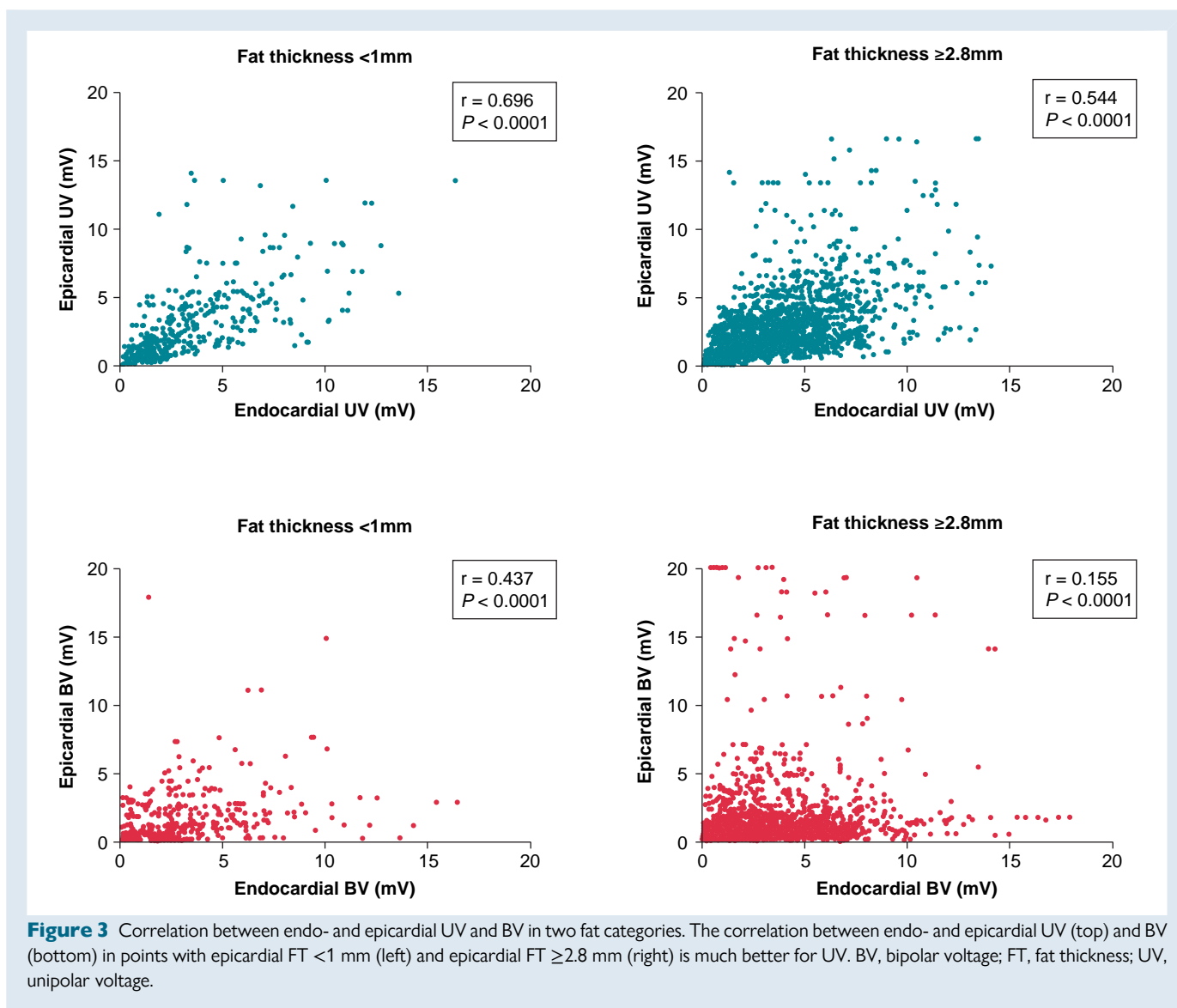
**Table 1** Absolute difference and ratio between endo-epicardial voltages in different fat categories

	BV <sub>epi</sub> –BV <sub>endo</sub> (mV)	UV <sub>epi</sub> –UV <sub>endo</sub> (mV)	P-value	BV <sub>epi</sub> /BV <sub>endo</sub>	UV <sub>epi</sub> /UV <sub>endo</sub>	P-value
FT <1 mm (n = 444)	–0.36 (–2.03–0.23)	–0.21 (–1.05–0.36)	<0.001	0.63 (0.29–1.55)	0.86 (0.58–1.25)	0.089
FT 1–2.7 mm (n = 1227)	–0.92 (–2.90–0.05)	–0.43 (–1.78–0.37)	<0.001	0.48 (0.23–1.09)	0.83 (0.54–1.23)	<0.001
FT ≥2.8 mm (n = 1774)	–1.29 (–3.36–0.06)	–0.60 (–2.00–0.30)	<0.001	0.38 (0.18–0.88)	0.73 (0.45–1.16)	<0.001
FT <1 mm + distance <5 mm (n = 173)	–0.29 (–1.73–0.20)	–0.23 (–1.02–0.21)	0.003	0.64 (0.26–1.45)	0.83 (0.58–1.11)	0.403

Numbers expressed as median (IQR).  
BV, bipolar voltage; FT, fat thickness; UV, unipolar voltage.



**Figure 2** Ratio between endo- and epicardial voltages among three epicardial fat categories. The median (IQR) ratio between endo- and epicardial voltages for UV on the left and BV on the right. The ratio is more towards 1 among the different fat categories (especially <2.7 mm) for UV compared with BV. BV, bipolar voltage; UV, unipolar voltage.



were 'inclusion of far-field' in 1182 (31%) endocardial and 646 (36%) epicardial points; 'inclusion of changes due to mechanically induced injury current' in 1209 (32%) endocardial and 315 (18%) epicardial points; RV-pacing artifact in 240 (6%) endocardial and 113 (6%) epicardial points; and miscellaneous in 51 (3%) epicardial points (Figure 1).

The median difference between the 'automatically generated' UV and the 'adjusted' UV was 0.84 mV [interquartile range (IQR): 0.42–1.46] for the endocardial points and 0.54 mV (IQR: 0.27–0.94) for the epicardial points. In 312 (8%) endocardial points, UV was changed from ≥5.5 to <5.5 mV; in 388 (10%) points from ≥4.4 to <4.4 mV; and in 369 (10%) points from ≥3.8 to <3.8 mV.<sup>6,7,15</sup> Bipolar voltage did not change after adjustment of the window-of-interest.

## Correlation of endocardial and epicardial voltages

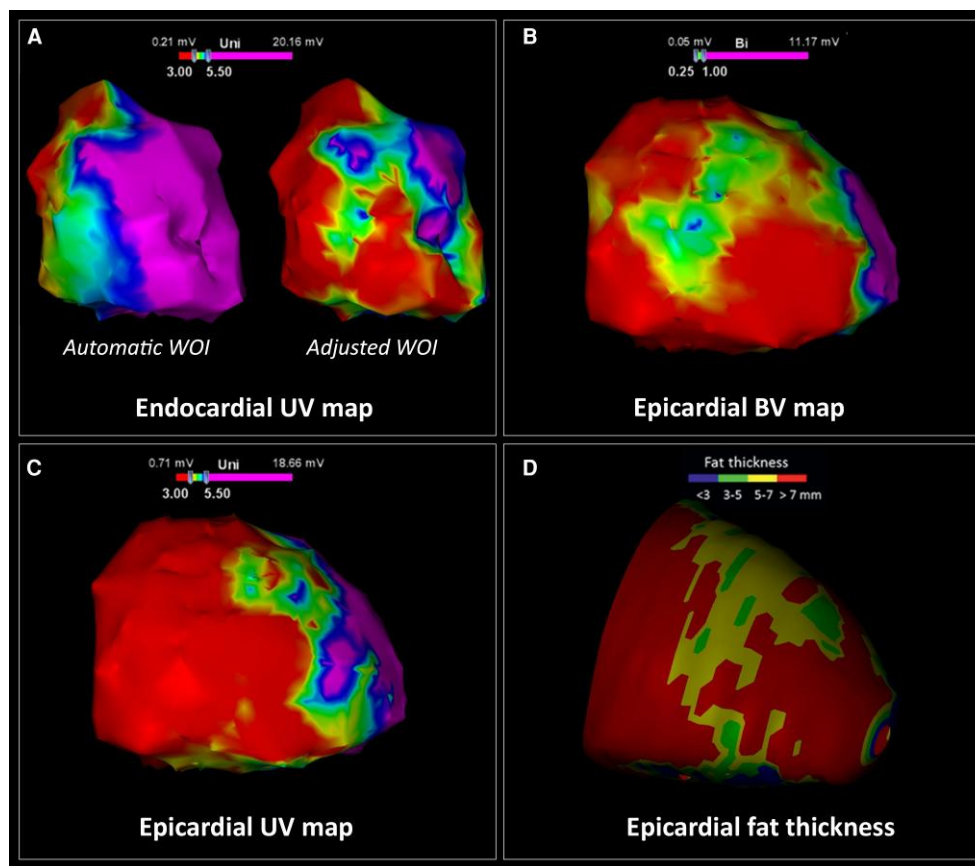
After excluding 346 point-pairs collected during RV pacing, for 3445 point-pairs corrected endo-epicardial voltages were correlated (444 point-pairs FT < 1 mm; 1227 point-pairs FT 1–2.7 mm; 1774 point-pairs FT ≥ 2.8 mm). The median UV irrespective of FT was 2.26 mV (IQR: 1.17–4.04) on the epicardium vs. 3.10 mV (IQR: 1.45–4.94) on the

endocardium ( $P < 0.001$ ). The median epicardial BV was 0.89 mV (IQR: 0.44–1.87) vs. 2.22 mV (IQR: 0.89–3.84) for endocardial BV ( $P < 0.001$ ).

The absolute difference and ratio between endo-epicardial voltages are shown in Table 1. The median absolute difference between epi-endocardial voltages was significantly larger for BV compared with UV [−1.02 mV (IQR: −3.01–0.02) vs. −0.47 mV (IQR: −1.84–0.34),  $P < 0.001$ ], despite the fact that absolute UVs are higher.

The median ratio between endo-epicardial voltages (voltage<sub>epi</sub> divided by voltage<sub>endo</sub>) remained the same for UV for FT < 1 mm vs. FT 1–2.7 mm: 0.86 (0.58–1.25) vs. 0.83 (0.54–1.23),  $P = 0.356$  (Figure 2). However, for BV, the median ratio decreased significantly with increasing FT: 0.63 (0.29–1.55) for FT < 1 mm vs. 0.48 (0.23–1.09) for FT 1–2.7 mm ( $P < 0.001$ ). Also, for FT ≥ 2.8 mm, the ratio was much higher (towards 1) for UV compared with BV: 0.73 (0.45–1.16) vs. 0.38 (0.18–0.88), respectively ( $P < 0.001$ ).

For both UV and BV, the correlation between endo- and epicardial voltages was lower for point-pairs with a greater FT (Figure 3). However, this correlation was stronger and less influenced by fat for UV compared with BV (the Pearson coefficient for UV is 0.696 for FT < 1 mm and 0.544 for FT ≥ 2.8 mm; for BV, 0.437 and 0.155, respectively).



**Figure 4** Example of the importance of adjusting the WOI and the role of epicardial UV mapping. Endocardial and epicardial mapping during RV pacing in a patient with arrhythmogenic right ventricular cardiomyopathy in modified right anterior oblique view. (A) Endocardial UV map using the automatic WOI on the left and the UV map after adjusting the WOI on the right, clearly demonstrating the underestimation of scar using the automatic WOI. (B) Epicardial BV map. (C) Adjusted epicardial UV map. (D) Epicardial FT map, based on CT. Notable, UV (see C) is less influenced by the thick epicardial fat layer at the apex, compared with BV (see B). BV, bipolar voltage; CT, computed tomography; FT, fat thickness; UV, unipolar voltage; WOI, window-of-interest.

Last, a sub-analysis of point-pairs with a distance < 5 mm and FT < 1 mm was performed ( $n = 173$ ). In this group, the Pearson coefficient was 0.789 for UV and 0.525 for BV. The median ratio epi-endo was 0.83 (IQR: 0.58–1.11) for UV compared with 0.64 (IQR: 0.26–1.45) for BV ( $P = 0.403$ ).

## Discussion

This is the first study to investigate the pitfalls and potential advantages of UVM in the thin-walled RV. The main findings are (i) using the automatic window-of-interest, the unipolar amplitude is overestimated in up to 70% of endo- and epicardial points; (ii) RV pacing causes huge artifacts in the unipolar signal; (iii) at opposite endo-epicardial sites, UV amplitudes are more similar compared with BV, and (iv) epicardial UV is less influenced by epicardial fat compared with epicardial BV.

## Window-of-interest

Unipolar voltage mapping is increasingly performed to delineate VT substrate in non-ischaemic cardiomyopathies. It has also been suggested as a diagnostic tool in RV cardiomyopathies.<sup>4,16,17</sup> As a consequence, correct measurement of the local EGM amplitude is crucial.

Using 3D mapping systems for VM, the window-of-interest is typically set from the onset of the earliest QRS complex of the surface electrocardiogram to a variable time interval after the offset of the QRS. Within this window-of-interest, the peak-to-peak amplitude of both BV and UV is calculated. However, far-field components, artifacts, and mechanically induced injury currents are not automatically excluded. Especially in RV cardiomyopathies, high amplitude far-field EGMs from the thicker-walled (and usually healthy) left ventricle (LV) may be present. Besides, RV apical pacing may cause huge artifacts, mainly in the UV signal, which may completely obscure and overestimate the local UV signal (Figures 1 and 4A). Finally, mechanically induced injury currents may overestimate the local signal by causing ST-elevation.<sup>18</sup>

Our study shows that in the majority of both endo- and epicardial points, the window-of-interest needed to be manually adjusted for correct UV amplitude measurement.

## Epicardial unipolar voltage: potential advantages

Epicardial scar delineation during VM is challenging. Epicardial fat may cause low BV, mistakenly identified as scar tissue.<sup>11</sup> Besides, BV is directionally sensitive and, therefore, influenced by the activation wavefront



relative to the catheter orientation.<sup>19</sup> At the epicardium, catheters are typically orientated parallel to the surface and perpendicular to the endo-epi activation wavefront. This might be another possible explanation for why suggested cut-offs to delineate epicardial scar by BV mapping are lower (<1.0 mV) compared with endocardial BV cut-off values.<sup>12</sup>

Unipolar voltage is considered to have a wider field of view.<sup>9</sup> We, therefore, hypothesized that in the thin-walled RV simultaneously collected UV amplitudes may be similar, reflected by a ratio between endo-epicardial voltages towards 1. Indeed, the median ratio between endo-epicardial UV was  $\geq 0.73$  for all fat categories showing similar endo-epicardial UVs. In FT < 2.7 mm, UV was found to be more robust compared with BV. Moreover, in areas with FT  $\geq 2.8$  mm, we found that the ratio between endo- and epicardial UV was much higher compared with BV. This suggests that UV is less influenced by epicardial fat (Figure 4B–D). This is in line with previous studies, showing the same UV across different fat categories.<sup>11,14</sup>

Finally, the sub-analysis including points with no fat and distance < 5 mm shows a better endo-epicardial correlation for UV. In these point-pairs, the effect of the field of view of UV and local FT plays a minor role. Accordingly, in the thin-walled RV, the similar endo-epi UV at opposite sites, reduced influence of epicardial fat on the local UV and wavefront independency of UV support a promising role for epicardial UV mapping.

## Future perspectives

First, this study shows that manual adjustment of the window-of-interest is needed for correct UV analysis. However, this is time-consuming, especially with the increasing use of multi-electrode catheters.<sup>20</sup> Therefore, there is an urgent need for new mapping algorithms for correct voltage amplitude calculation. One potential solution might be a software algorithm which will set the window-of-interest around the local activation time (maximum dV/dt in the unipolar signal) or which will use the sharp deflection of the bipolar signal as a reference for the window-of-interest.

Our study suggests a promising role for epicardial UV mapping. This may be of particular interest in the thicker-walled LV, where endo-epi UV at opposite sites may be different due to the impact of the local wall thickness. In these areas, epicardial UV may provide additional information.

## Conclusions

Unadjusted UV mapping may lead to underestimation of low UV regions which can be, in particular, important when UV is used to predict epicardial scar or to guide biopsies. Moreover, adjusted UV mapping may provide important complementary information for improved scar delineation, especially on the epicardium, because epicardial UV is less influenced by epicardial fat and the endo-epicardial wavefront. Therefore, the role of UV in epicardial substrate mapping is promising and needs attention in further studies.

**Conflict of interest:** None declared.

## Data availability

The data underlying this article are available upon request.

## References

- Cronin EM, Bogun FM, Maury P, Peichl P, Chen M, Namboodiri N et al. 2019 HRS/EHRA/APHRS/LAHRs expert consensus statement on catheter ablation of ventricular arrhythmias. *Europace* 2019;**21**:1143–4.
- Corrado D, Basso C, Leoni L, Tokajuk B, Bauce B, Frigo G et al. Three-dimensional electroanatomic voltage mapping increases accuracy of diagnosing arrhythmogenic right ventricular cardiomyopathy/dysplasia. *Circulation* 2005;**111**:3042–50.
- Boulos M, Lashevsky I, Gepstein L. Usefulness of electroanatomical mapping to differentiate between right ventricular outflow tract tachycardia and arrhythmogenic right ventricular dysplasia. *Am J Cardiol* 2005;**95**:935–40.
- Hoogendoorn JC, Sramko M, Venlet J, Siontis KC, Kumar S, Singh R et al. Electroanatomical voltage mapping to distinguish right-sided cardiac sarcoidosis from arrhythmogenic right ventricular cardiomyopathy. *JACC Clin Electrophysiol* 2020;**6**:696–707.
- Kirubakaran S, Biscaglia C, Silberbauer J, Oloriz T, Santagostino G, Yamase M et al. Characterization of the arrhythmogenic substrate in patients with arrhythmogenic right ventricular cardiomyopathy undergoing ventricular tachycardia ablation. *Europace* 2017;**19**:1049–62.
- Polin GM, Haqqani H, Tzou W, Hutchinson MD, Garcia FC, Callans DJ et al. Endocardial unipolar voltage mapping to identify epicardial substrate in arrhythmogenic right ventricular cardiomyopathy/dysplasia. *Heart Rhythm* 2011;**8**:76–83.
- Tokuda M, Tedrow UB, Inada K, Reichlin T, Michaud GF, John RM et al. Direct comparison of adjacent endocardial and epicardial electrograms: implications for substrate mapping. *J Am Heart Assoc* 2013;**2**:e000215.
- Casella M, Bergonti M, Dello Russo A, Maranga R, Gasperetti A, Compagnucci P et al. Endomyocardial biopsy: the forgotten piece in the arrhythmogenic cardiomyopathy puzzle. *J Am Heart Assoc* 2021;**10**:e021370.
- Berte B, Zeppenfeld K, Tung R. Impact of micro-, mini- and multi-electrode mapping on ventricular substrate characterisation. *Arrhythm Electrophysiol Rev* 2020;**9**:128–35.
- Durrer D, van Dam RT, Freud GE, Janse MJ, Meijler FL, Arzbaeher RC. Total excitation of the isolated human heart. *Circulation* 1970;**41**:899–912.
- Desjardins B, Morady F, Bogun F. Effect of epicardial fat on electroanatomical mapping and epicardial catheter ablation. *J Am Coll Cardiol* 2010;**56**:1320–7.
- Cano O, Hutchinson M, Lin D, Garcia F, Zado E, Bala R et al. Electroanatomic substrate and ablation outcome for suspected epicardial ventricular tachycardia in left ventricular nonischemic cardiomyopathy. *J Am Coll Cardiol* 2009;**54**:799–808.
- Venlet J, Piers SRD, Kapel GFL, de Riva M, Pauli PFG, van der Geest RJ et al. Unipolar endocardial voltage mapping in the right ventricle: optimal cutoff values correcting for computed tomography-derived epicardial fat thickness and their clinical value for substrate delineation. *Circ Arrhythm Electrophysiol* 2017;**10**:e005175.
- van Huls van Taxis CF, Wijngaalen AP, Piers SR, van der Geest RJ, Schalijs MJ, Zeppenfeld K. Real-time integration of MDCT-derived coronary anatomy and epicardial fat: impact on epicardial electroanatomic mapping and ablation for ventricular arrhythmias. *JACC Cardiovasc Imaging* 2013;**6**:42–52.
- Lee AC, Strugnell W, Vittinghoff E, Hamilton-Craig C, Haqqani HM. Right ventricular electrogram characteristics in a T1 mapping-validated normal population: implications for unipolar voltage mapping. *JACC Clin Electrophysiol* 2020;**6**:711–21.
- Venlet J, Piers SR, Jongbloed JD, Androulakis AF, Naruse Y, den Uijl DW et al. Isolated subepicardial right ventricular outflow tract scar in athletes with ventricular tachycardia. *J Am Coll Cardiol* 2017;**69**:497–507.
- Marra MP, Leoni L, Bauce B, Corbetti F, Zorzi A, Migliore F et al. Imaging study of ventricular scar in arrhythmogenic right ventricular cardiomyopathy: comparison of 3D standard electroanatomical voltage mapping and contrast-enhanced cardiac magnetic resonance. *Circ Arrhythm Electrophysiol* 2012;**5**:91–100.
- Ikeda A, Nakagawa H, Lambert H, Shah DC, Fonck E, Yulzari A et al. Relationship between catheter contact force and radiofrequency lesion size and incidence of steam pop in the beating canine heart: electrogram amplitude, impedance, and electrode temperature are poor predictors of electrode-tissue contact force and lesion size. *Circ Arrhythm Electrophysiol* 2014;**7**:1174–80.
- Gaeta S, Bahnon TD, Henriquez C. Mechanism and magnitude of bipolar electrogram directional sensitivity: characterizing underlying determinants of bipolar amplitude. *Heart Rhythm* 2020;**17**:777–85.
- Barkagan M, Sroubek J, Shapira-Daniels A, Yavin H, Jang J, Nezafat R et al. A novel multi-electrode catheter for high-density ventricular mapping: electrogram characterization and utility for scar mapping. *Europace* 2020;**22**:440–9.