



Universiteit  
Leiden  
The Netherlands

## Quantification of near-infrared fluorescence imaging with indocyanine green in free flap breast reconstruction

Hoven, P. van den; Verduijn, P.S.; Capelle, L. van; Tange, F.P.; Michi, M.; Corion, L.U.M.; ... ; Vorst, J.R. van der

### Citation

Hoven, P. van den, Verduijn, P. S., Capelle, L. van, Tange, F. P., Michi, M., Corion, L. U. M., ... Vorst, J. R. van der. (2022). Quantification of near-infrared fluorescence imaging with indocyanine green in free flap breast reconstruction. *Journal Of Plastic, Reconstructive And Aesthetic Surgery*, 75(6), 1820-1825. doi:10.1016/j.bjps.2021.12.004

Version: Publisher's Version

License: [Creative Commons CC BY 4.0 license](https://creativecommons.org/licenses/by/4.0/)

Downloaded from: <https://hdl.handle.net/1887/3566974>

**Note:** To cite this publication please use the final published version (if applicable).



# Quantification of near-infrared fluorescence imaging with indocyanine green in free flap breast reconstruction

P. Van Den Hoven<sup>a,1</sup>, P.S. Verduijn<sup>b,1</sup>, L. Van Capelle<sup>a</sup>,  
F.P. Tange<sup>a</sup>, M. Michi<sup>b</sup>, L.U.M. Corion<sup>b</sup>, B.G. Sibinga Mulder<sup>b</sup>,  
M.A.M. Mureau<sup>c</sup>, A.L. Vahrmeijer<sup>a</sup>, J.R. Van Der Vorst<sup>a,\*</sup>

<sup>a</sup>Department of Surgery, Leiden University Medical Center, Leiden, the Netherlands

<sup>b</sup>Department of Plastic & Reconstructive Surgery, Leiden University Medical Center, Leiden, the Netherlands

<sup>c</sup>Department of Plastic & Reconstructive Surgery, Erasmus MC Cancer Institute, University Medical Center Rotterdam, Rotterdam, the Netherlands

Received 22 July 2021; accepted 19 December 2021

## KEYWORDS

Near-infrared  
fluorescence imaging;  
Indocyanine green;  
Free flap surgery;  
Breast reconstruction;  
Perfusion;  
Quantification

**Summary** *Background:* One of the complications of free flap breast reconstruction is the occurrence of skin and fat necrosis. Intra-operative use of near-infrared (NIR) fluorescence imaging with Indocyanine Green (ICG) has the potential to predict these complications. In this study, the quantification of the fluorescence intensity measured in free flap breast reconstruction was performed to gain insight into the perfusion patterns observed with ICG NIR fluorescence imaging.

*Methods:* ICG NIR fluorescence imaging was performed in patients undergoing free flap breast reconstruction following mastectomy. After completion of the arterial and venous anastomosis, 7.5 mg ICG was administered intravenously. The fluorescence intensity over time was recorded using the Quest Spectrum Platform®. Four regions of interest (ROI) were selected based on location and interpretation of the NIR fluorescence signal: (1) The perforator, (2) normal perfusion, (3) questionable perfusion, and (4) low perfusion. Time-intensity curves were analyzed, and two parameters were extracted: T<sub>max</sub> and T<sub>max</sub> slopes.

*Results:* Successful ICG NIR fluorescence imaging was performed in 13 patients undergoing 17 free flap procedures. Region selection included 16 perforators, 17 normal perfusions, 8 questionable perfusions, and 5 low perfusion ROIs. Time-intensity curves of the perforator ROIs

<sup>1</sup>Authors contributed equally and share first authorship.

\* Corresponding author at: Department of Surgery, Leiden University Medical Center, Albinusdreef 2, 2333 ZA Leiden, The Netherlands.  
E-mail address: [j.r.van\\_der\\_vorst@lumc.nl](mailto:j.r.van_der_vorst@lumc.nl) (J.R. Van Der Vorst).

were comparable to the ROIs of normal perfusion and demonstrated a fast inflow. No outflow was observed for the ROIs with questionable and low perfusion.

**Conclusion:** This study provides insight into the perfusion patterns observed with ICG NIR fluorescence imaging in free flap breast reconstruction. Future studies should correlate quantitative parameters with clinical perfusion assessment and outcome.

© 2022 British Association of Plastic, Reconstructive and Aesthetic Surgeons. Published by Elsevier Ltd. This is an open access article under the CC BY license (<http://creativecommons.org/licenses/by/4.0/>)

## Introduction

Breast cancer accounts for 30 percent of newly diagnosed malignancies in female patients, and it is the leading cause of death among middle-aged women<sup>1</sup>. The surgical treatment of breast cancer is performed either with breast-conserving surgery or mastectomy. For reconstructive surgery following mastectomy, the use of autologous tissue is gaining popularity<sup>2</sup>. Commonly performed autologous breast reconstruction procedures include deep inferior epigastric artery perforator (DIEP), superficial inferior epigastric artery (SIEA), and profunda artery perforator (PAP) flap reconstructions<sup>3,4</sup>. The advantages of successful autologous breast reconstruction, including long-term beneficial outcome, are evident. However, free flap surgery following mastectomy is also associated with complications including skin and fat necrosis<sup>5,6</sup>. In the assessment of tissue perfusion during free flap surgery, the surgeon relies on subjective observations including skin color, capillary refill, and the occurrence of bleeding. Possible techniques to aid the surgeon while assessing tissue perfusion include laser doppler and near-infrared (NIR) fluorescence imaging with Indocyanine Green (ICG)<sup>7</sup>. ICG NIR fluorescence imaging is a technique that measures fluorescence in the NIR light spectrum (700-900 nm), which is characterized by deep tissue penetration and low autofluorescence<sup>8</sup>. Following intravenous administration of ICG, a fluorophore with an absorption and excitation peak in the NIR light spectrum, a time-intensity curve of the measured fluorescence intensity can be generated. The feasibility of ICG in perfusion assessment is explained by its confinement to the vascular component due to binding with serum proteins including albumin<sup>9</sup>. For patients undergoing breast (reconstructive) surgery, the intra-operative use of ICG NIR fluorescence imaging was demonstrated to aid surgeons in their assessment of skin viability, thereby reducing the occurrence of skin necrosis in several studies<sup>10,11</sup>. This reduction in necrosis can be explained by the intra-operative removal of tissue with diminished fluorescence intensity observed with ICG NIR fluorescence imaging. The localization of areas with diminished perfusion is based on subjective evaluation of the measured fluorescence intensity by the surgeon<sup>12</sup>. However, to objectively assess tissue perfusion and enhance the reliability of this technique, the quantification of the fluorescence intensity is of paramount importance. Quantification studies on the use of ICG NIR fluorescence imaging in reconstructive surgery mainly have focused on absolute and relative fluorescence intensity parameters<sup>10,13,14</sup>. However, there is no consensus on which parameter is most accurate for the assessment of tissue perfusion. In the search for determin-

ing cut-off values for tissue perfusion, more information is needed about the perfusion patterns observed with ICG NIR fluorescence imaging. Therefore, the aim of this study was to gain insight into these perfusion patterns by performing a quantitative assessment of the ICG NIR fluorescence imaging used in free flap breast reconstruction.

## Materials and methods

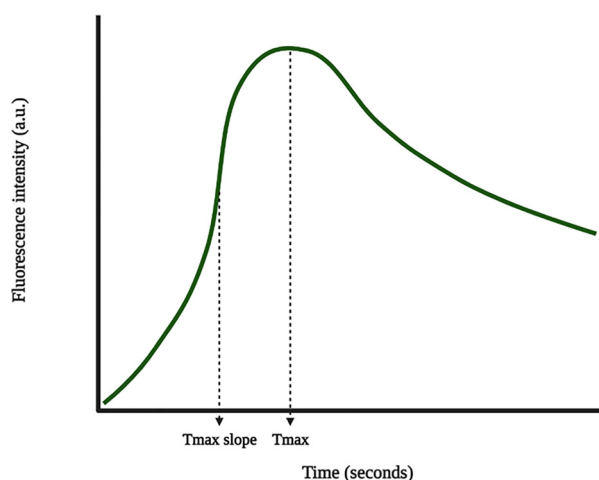
This pilot cohort study was approved by the Medical Research and Ethics Committee of the Leiden University Medical Center and was conducted in accordance with the Declaration of Helsinki. Patients undergoing autologous breast reconstruction between February and September 2019 in a single tertiary hospital in the Netherlands were included. Exclusion criteria were allergy to ICG, iodine, or shellfish and impaired renal function. This study adhered to the STROBE statement on the report of cohort studies<sup>15</sup>.

## ICG NIR fluorescence imaging measurement

Intra-operative ICG NIR fluorescence imaging was performed using the Quest Spectrum Platform® (Quest Medical Imaging, Middenmeer, The Netherlands). This camera system consists of a laser with a camera that measures light in the visible and NIR light spectrum (700-830 nm). Directly following an intravenous bolus injection of 7.5 mg ICG (VERDYE 25 mg, Diagnostic Green GmbH, Aschheim-Dornach, Germany), the fluorescence intensity of the anastomosed free flap was recorded for 3 min according to protocol. The perforator, including artery and vein, was marked with a staple. Measurements were performed with the camera placed perpendicular to the flap surface at a distance of approximately 50 cm. The operating room was cleared of ambient light throughout the measurement.

## Data analysis

Postoperatively, a reconstructive surgeon (PV) evaluated the fluorescence intensity videos and, if observed, selected four regions of interest (ROI): (1) Perforator, (2) normal perfusion, (3) questionable perfusion (possible resection), and 4. low perfusion (resection). The selected ROIs were analyzed using the Quest Research Framework® (Quest Medical Imaging, Middenmeer, the Netherlands). For the selected ROIs, the software creates a time-intensity curve of the measured intensity in arbitrary units (a.u.). Videos were analyzed for 3 min following start of intensity increase. Two



**Figure 1** Time-intensity curve with extracted parameters.

**Table 1** Patient characteristics.

| Characteristics                      | Number of patients ( $n = 13$ ) |
|--------------------------------------|---------------------------------|
| <b>Mean age (years, SD)</b>          | 50.4 (10.6)                     |
| <b>Diabetes mellitus</b>             | 0                               |
| <b>Hypertension</b>                  | 2                               |
| <b>Active smoking</b>                | 1                               |
| <b>Type of breast reconstruction</b> |                                 |
| <b>DIEP flap</b>                     | 10                              |
| <b>PAP flap</b>                      | 2                               |
| <b>SIEA flap</b>                     | 1                               |

Abbreviations: SD, standard deviation; DIEP, deep inferior epigastric perforator; PAP, profunda artery perforator; SIEA, superficial inferior epigastric artery.

parameters were extracted (Figure 1): time to maximum intensity ( $T_{max}$ ) and time to maximum slope ( $T_{max\ slope}$ ). Baseline subtraction was applied to all time-intensity curves. A tracker synchronized the ROI with movement. Videos without data on camera settings were excluded. Statistical analyses were performed using IBM SPSS Statistics 25 (IBM Corp. Released 2017. IBM SPSS Statistics for Windows, Version 25.0. Armonk, NY, USA: IBM Corp.). Results for the four ROIs were compared using the Kruskal-Wallis test.

## Results

Successful ICG NIR fluorescence imaging was performed in 13 patients undergoing 13 DIEP, 3 PAP, and 1 SIEA flap reconstruction(s). Four patients underwent a bilateral free flap reconstruction. The patient characteristics are displayed in Table 1. An example of a normal perfusion pattern is shown in Figure 2 and Video 1, in which the fluorescence intensity change over time in a 65-year-old patient undergoing a DIEP flap reconstruction is displayed. The video is accelerated elevenfold and demonstrates the NIR fluorescence intensity change during the measurement of 3 min. An example of a normal and questionably perfused ROI in a 55-year-old patient following DIEP flap surgery is shown in Figure 3. The ROI selection included 16 perforators, 17 normal perfusions,

8 questionable perfusions, and 5 low perfusion areas. In one patient undergoing a DIEP flap reconstruction, two perforators were used.

## Time-intensity curves

The time-intensity curves for the four selected ROIs are shown in Figure 4. For the perforator ROI, the majority of curves display a steep ingress followed by a steep egress. The egress phase is reached within 180 s for all time-intensity curves in this ROI. For the time-intensity curves in the ROIs marked as normal perfusion, an inflow pattern similar to the perforator ROI can be observed. Furthermore, comparable to the perforator ROI, the egress phase is reached within 180 s in the majority of ROIs with normal perfusion. For both ROIs, there is a widespread distribution among measured maximum fluorescence intensity between curves. For the ROIs with questionable and low perfusion, a clearly lower maximum fluorescence intensity is demonstrated compared to the perforator and normal perfusion ROIs. Moreover, the curves for questionable and low perfusion ROIs are characterized by a prolonged inflow, and the egress phase is not reached for all time-intensity curves in these ROIs.

## Quantitative analysis

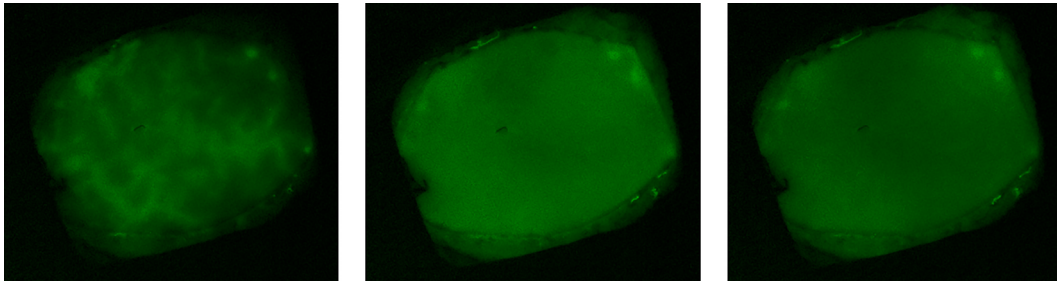
The results on quantitative analysis of the time-intensity curves for the four ROIs are depicted in Figure 5 and Table 2. The  $T_{max}$  was reached earliest in the perforator ROI (63.9 s, standard deviation 47.8). For the  $T_{max\ slope}$ , results between the perforator and normal perfusion ROIs were similar 7.2 and 6.8 s.  $T_{max}$  and  $T_{max\ slope}$  were prolonged in the ROI with low perfusion (164.9 and 99.1 s, respectively). Differences between the ROIs were statistically significant for both parameters ( $T_{max}$ :  $p < 0.001$ ,  $T_{max\ slope}$ :  $p = 0.006$ ).

## Clinical outcome and follow-up

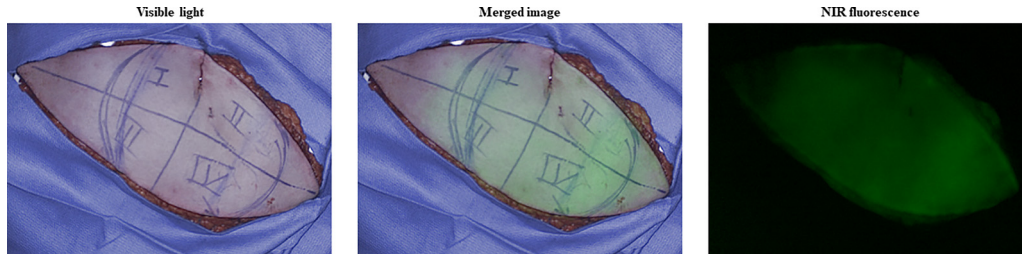
Flap loss occurred in one patient undergoing a bilateral DIEP flap reconstruction. In this 44-year-old female, the DIEP flap on the right side had to be removed, after a failed salvage procedure, on the fourth day postoperatively due to venous congestion. No low or questionable perfusion ROIs were observed with ICG NIR fluorescence imaging intra-operatively.

## Discussion

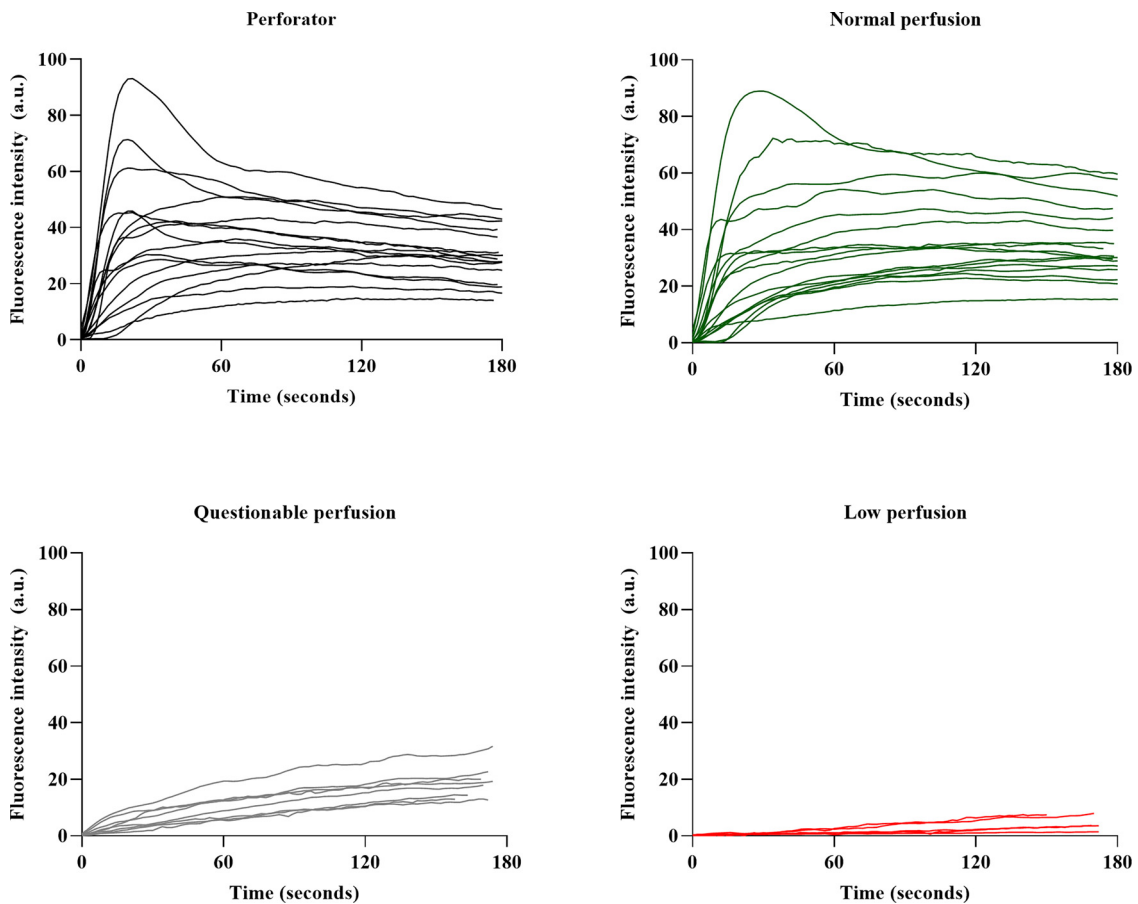
This study on the quantitative evaluation of ICG NIR fluorescence imaging in free flap breast reconstruction provides insight into the perfusion patterns of free flaps as observed by the surgeon. Interestingly, time-intensity curves for the perforator region were comparable to the regions classified as normal perfusion. Furthermore, these are the only observed regions in which outflow was observed. The current use of ICG NIR fluorescence imaging in free flap breast



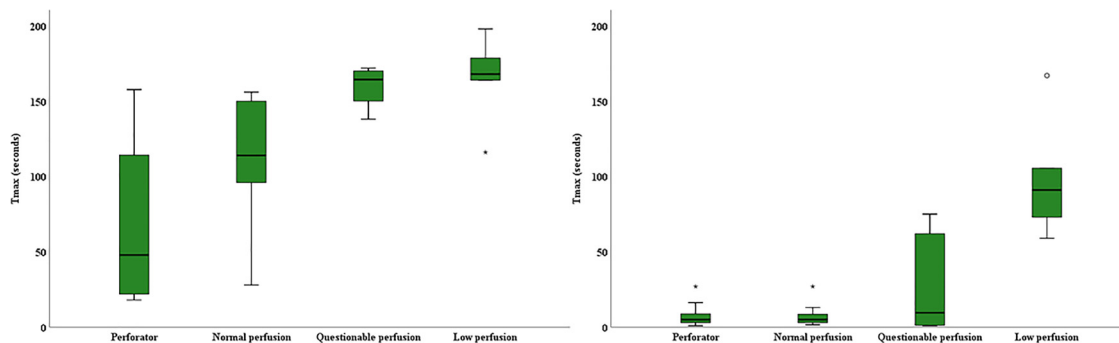
**Figure 2** Example of the fluorescence intensity change over time in a DIEP flap of a 65-year-old patient. The fluorescence intensity at 5-, 30-, and 60 s is displayed for the left, middle, and right images, respectively.



**Figure 3** ICG NIR fluorescence imaging in a patient undergoing a DIEP flap reconstruction showing the visible (left), merged (middle), and NIR fluorescence (right) output. Hence, the diminished fluorescence intensity in the left corner of the flap, which was marked as questionable perfusion.



**Figure 4** Pooled time-intensity curves for each ROI.



**Figure 5** Quantitative analysis of the four ROIs displaying the boxplots of the Tmax (mean) and Tmax slopes (mean).

**Table 2** Quantitative assessment of ICG NIR fluorescence imaging.

|                                      | Perforator  | Normal perfusion | Questionable perfusion | Low perfusion |
|--------------------------------------|-------------|------------------|------------------------|---------------|
| <b>Mean Tmax, seconds (SD)</b>       | 63.9 (47.8) | 111.4 (42.2)     | 159.9 (12.7)           | 164.9 (30.4)  |
| <b>Mean Tmax slope, seconds (SD)</b> | 7.2 (6.5)   | 6.8 (6.3)        | 27.7 (33.4)            | 99.1 (41.8)   |

Abbreviation: SD, standard deviation.

reconstruction relies on the qualitative and therefore subjective judgment of the NIR signal by the surgeon. However, to aid in decision-making and enhance the reliability of ICG NIR fluorescence imaging in these patients, quantitative analysis is required. For quantitative assessment of tissue perfusion in breast surgery, studies on mastectomy skin flap necrosis have shown relative perfusion deficits to be predictive of tissue necrosis<sup>16-18</sup>. Relative parameters are described as a percentage of the measured maximum intensity in the target area. For patients undergoing autologous breast reconstruction, relative parameters were used as a cut-off value by Alstrup et al. to guide intra-operative decision-making on the excision of poorly perfused tissue<sup>19</sup>. However, this study found no significant differences regarding skin necrosis between patients with and without the use of ICG NIR fluorescence imaging. Relative parameters are influenced by the measured fluorescence intensity and therefore subjective to various influencing factors including camera angle, camera distance, and ICG dosage<sup>13,20</sup>. Moreover, relative intensity parameters provide no data about intensity change over time. For the assessment of perfusion in free flaps following microvascular anastomosis, it seems reasonable time-related parameters are more appropriate in predicting in and outflow. This was observed in a study on the perfusion of fibular free flaps for reconstruction of hemimandibulectomy defects, in which an increased post-operative slope was found following surgical revision due to venous thrombosis<sup>21</sup>. Concerning the quantitative analysis of ICG NIR fluorescence imaging in free flap breast reconstruction, one study assessed various perfusion patterns in DIEP flap surgery and found an increased fluorescence intensity as well as the fluorescence intensity inflow rate for perforator regions compared to more distal regions of the flap<sup>22</sup>. These results are similar to the findings in this study, in which an increased inflow was observed for the perforator and normal perfusion ROIs. However, in exploring the value of inflow parameters in the assessment of perfusion and pre-

diction of clinical outcome, a larger cohort is needed, which is a limitation of this study. Furthermore, only one event of flap loss occurred in this study, precluding evaluation of the predictive value of quantitative assessment of ICG NIR fluorescence imaging for this outcome. Correlating quantitative parameters with clinical assessment and outcome can identify cut-off values for reliable tissue perfusion. Moreover, in this search towards valid and reliable use of ICG NIR fluorescence imaging for perfusion assessment, it is of paramount importance that comparability studies are performed between different camera systems. As shown in a review by Dsouza et al., commercially available ICG NIR fluorescence imaging systems differ in settings, including the excitation source and light sensors<sup>23</sup>. Therefore, comparing the perfusion patterns in free flaps measured with various camera systems will provide insight into the applicability of this technique. Despite these limitations, the present study provides insight into the observed perfusion patterns for various regions which is a step towards the quantification of tissue perfusion in free flap surgery. Future studies should focus on the standardization of ICG NIR fluorescence imaging in free flap surgery and correlate quantitative parameters with clinical perfusion assessment and clinical outcome, including fat necrosis and flap viability. When performed in large cohorts, these studies can identify perfusion patterns correlated with these clinical outcomes. This possible early-stage prediction of fat necrosis and flap viability using ICG NIR fluorescence imaging will have a significant impact on patient outcome.

## Conclusion

This study provides insight into the perfusion patterns observed with ICG NIR fluorescence imaging in free flap breast reconstruction. Future studies with this technique in free flap surgery should focus on the correlation of quantita-

tive parameters with clinical perfusion assessment and outcome.

Video 1. ICG NIR fluorescence imaging video showing the fluorescence intensity change over time, accelerated elevenfold, in a DIEP flap of a 65-year-old patient.

## Declaration of Competing Interest

All authors state to have no conflict of interest.

## Funding

The collaboration project is co-funded by the PPP Allowance made available by Health~Holland, Top Sector Life Sciences & Health, to stimulate public-private partnerships.

## Supplementary materials

Supplementary material associated with this article can be found, in the online version, at doi:[10.1016/j.bjps.2021.12.004](https://doi.org/10.1016/j.bjps.2021.12.004).

## References

1. Siegel RL, Miller KD, Fuchs HE, Jemal A. Cancer Statistics, 2021. *CA Cancer J Clin* 2021;71:7-33.
2. Nahabedian MY, Patel K. Autologous flap breast reconstruction: surgical algorithm and patient selection. *J Surg Oncol* 2016;113:865-74.
3. Rose J, Puckett Y. Breast reconstruction free flaps. *StatPearls*; 2021. Treasure Island (FL).
4. Qian B, Xiong L, Li J, et al. A systematic review and meta-analysis on microsurgical safety and efficacy of profunda artery perforator flap in breast reconstruction. *J Oncol* 2019;2019:9506720.
5. Bhullar H, Hunter-Smith DJ, Rozen WM. Fat necrosis after DIEP flap breast reconstruction: a review of perfusion-related causes. *Aesthetic Plast Surg* 2020;44:1454-61.
6. Wilkins EG, Hamill JB, Kim HM, et al. Complications in postmastectomy breast reconstruction: one-year outcomes of the mastectomy reconstruction outcomes consortium (MROC) study. *Ann Surg* 2018;267:164-70.
7. Smit JM, Negenborn VL, Jansen SM, et al. Intraoperative evaluation of perfusion in free flap surgery: a systematic review and meta-analysis. *Microsurgery* 2018;38:804-18.
8. Frangioni JV. In vivo near-infrared fluorescence imaging. *Curr Opin Chem Biol* 2003;7:626-34.
9. Landsman ML, Kwant G, Mook GA, Zijlstra WG. Light-absorbing properties, stability, and spectral stabilization of indocyanine green. *J Appl Physiol* 1976;40:575-83.
10. Driessen C, Arnardottir TH, Lorenzo AR, Mani MR. How should indocyanine green dye angiography be assessed to best predict mastectomy skin flap necrosis? A systematic review. *J Plast Reconstr Aesthet Surg* 2020;73:1031-42.
11. Lauritzen E, Damsgaard TE. Use of Indocyanine Green Angiography decreases the risk of complications in autologous- and implant-based breast reconstruction: a systematic review and meta-analysis. *J Plast Reconstr Aesthet Surg* 2021.
12. Komorowska-Timek E, Gurtner GC. Intraoperative perfusion mapping with laser-assisted indocyanine green imaging can predict and prevent complications in immediate breast reconstruction. *Plast Reconstr Surg* 2010;125:1065-73.
13. Goncalves LN, van den Hoven P, van Schaik J, et al. Perfusion parameters in near-infrared fluorescence imaging with indocyanine green: a systematic review of the literature. *Life (Basel)* 2021;11.
14. Munabi NC, Olorunnipa OB, Goltsman D, Rohde CH, Ascherman JA. The ability of intra-operative perfusion mapping with laser-assisted indocyanine green angiography to predict mastectomy flap necrosis in breast reconstruction: a prospective trial. *J Plast Reconstr Aesthet Surg* 2014;67:449-55.
15. von Elm E, Altman DG, Egger M, et al. The strengthening the reporting of observational studies in epidemiology (STROBE) statement: guidelines for reporting observational studies. *Lancet* 2007;370:1453-7.
16. Moyer HR, Losken A. Predicting mastectomy skin flap necrosis with indocyanine green angiography: the gray area defined. *Plast Reconstr Surg* 2012;129:1043-8.
17. Johnson AC, Colakoglu S, Chong TW, Mathes DW. Indocyanine green angiography in breast reconstruction: utility, limitations, and search for standardization. *Plast Reconstr Surg Glob Open* 2020;8:e2694.
18. Newman MI, Samson MC, Tamburrino JF, Swartz KA. Intraoperative laser-assisted indocyanine green angiography for the evaluation of mastectomy flaps in immediate breast reconstruction. *J Reconstr Microsurg* 2010;26:487-92.
19. Alstrup T, Christensen BO, Damsgaard TE. ICG angiography in immediate and delayed autologous breast reconstructions: perioperative evaluation and postoperative outcomes. *J Plast Surg Hand Surg* 2018;52:307-11.
20. Lutken CD, Achiam MP, Svendsen MB, Boni L, Nerup N. Optimizing quantitative fluorescence angiography for visceral perfusion assessment. *Surg Endosc* 2020;34:5223-33.
21. Hitier M, Cracowski JL, Hamou C, Righini C, Bettega G. Indocyanine green fluorescence angiography for free flap monitoring: a pilot study. *J Craniomaxillofac Surg* 2016;44:1833-41.
22. Girard N, Delomenie M, Malhaire C, et al. Innovative DIEP flap perfusion evaluation tool: qualitative and quantitative analysis of indocyanine green-based fluorescence angiography with the SPY-Q proprietary software. *PLoS ONE* 2019;14:e0217698.
23. DS AV, Lin H, Henderson ER, Samkoe KS, Pogue BW. Review of fluorescence guided surgery systems: identification of key performance capabilities beyond indocyanine green imaging. *J Biomed Opt* 2016;21:80901.