



Universiteit
Leiden
The Netherlands

Variation in the management of benign liver tumors: a European survey and case vignette study

Haring, M.P.D.; Haas, R.J. de; Vilsteren, F.G.I. van; Klaase, J.M.; Duiker, E.W.; Blokzijl, H.; ... ; Cuperus, F.J.C.

Citation

Haring, M. P. D., Haas, R. J. de, Vilsteren, F. G. I. van, Klaase, J. M., Duiker, E. W., Blokzijl, H., ... Cuperus, F. J. C. (2023). Variation in the management of benign liver tumors: a European survey and case vignette study. *Clinics And Research In Hepatology And Gastroenterology*, 47(3). doi:10.1016/j.clinre.2023.102094

Version: Publisher's Version

License: [Creative Commons CC BY-NC-ND 4.0 license](https://creativecommons.org/licenses/by-nc-nd/4.0/)


Downloaded from: <https://hdl.handle.net/1887/3753507>

Note: To cite this publication please use the final published version (if applicable).



Available online at
ScienceDirect
 www.sciencedirect.com

Elsevier Masson France
EM|consulte
 www.em-consulte.com



ORIGINAL ARTICLE

Variation in the management of benign liver tumors: A European survey and case vignette study



Martijn P.D. Haring^a, Robbert J. de Haas^b, Frederike G.I. van Vilsteren^c,
 Joost M. Klaase^a, Evelien W. Duiker^d, Hans Blokzijl^c, Koert P. de Jong^a,
 Vincent E. de Meijer^{a,1,*}, Frans J.C. Cuperus^{c,*,1}, collaborators

^a Department of Surgery, University of Groningen, University Medical Center Groningen, Groningen, the Netherlands

^b Department of Radiology, University of Groningen, University Medical Center Groningen, Groningen, the Netherlands

^c Department of Gastroenterology and Hepatology, University of Groningen, University Medical Center Groningen, Groningen, the Netherlands

^d Department of Medical Biology and Pathology, University of Groningen, University Medical Center Groningen, Groningen, the Netherlands

Available online 11 February 2023

KEYWORDS

Liver neoplasms;
 Hepatic adenoma;
 Focal nodular hyperplasia;
 Surveys and questionnaires

Abstract

Background: Management of focal nodular hyperplasia (FNH) and hepatocellular adenoma (HCA), is multidisciplinary and subject to practice variation. We aimed to evaluate variation in clinical management of FNH and HCA in Europe.

Methods: We distributed an online survey (November 2021–March 2022) among 294 European experts. The survey included questions on local practice and included eight clinical vignettes. The clinical vignettes focused on FNH or HCA management in the setting of sex, lifestyle modification, and pregnancy.

Results: The response rate was 32% and respondents included surgeons (38%), gastroenterologists/hepatologists (25%), radiologists (32%), and pathologists (1.6%) from ten European countries. We observed practice variation with regard to lifestyle modification and imaging follow-up in patients with FNH, and with regard to the management of HCA >5 cm before and during

Abbreviations: BLT, benign liver tumors; FNH, focal nodular hyperplasia; HCA, hepatocellular adenoma; OCP, oral contraceptive pill; CE-MRI, contrast enhanced magnetic resonance imaging; b-HCA, beta-catenin activated hepatocellular adenoma; EASL, European association for the study of the liver; MDT, multidisciplinary team; I-HCA, inflammatory hepatocellular adenoma; H-HCA, hepatocyte nuclear factor 1A inactivated hepatocellular adenoma; U-HCA, unclassified hepatocellular adenoma; CEUS, contrast enhanced ultrasound; US, ultrasound; CT, computed tomography; TAE, transarterial embolization.

* Corresponding authors.

E-mail addresses: v.e.de.meijer@umcg.nl (V.E. de Meijer), f.j.c.cuperus@umcg.nl (F.J. Cuperus).

¹ Shared senior authorship

<https://doi.org/10.1016/j.clinre.2023.102094>

2210-7401 / © 2023 Published by Elsevier Masson SAS.

pregnancy. Finally, the management of HCA >5 cm after lifestyle modification deviated from EASL guideline recommendations.

Conclusion: Our survey illustrates variability in FNH and HCA management in Europe. Several areas were identified for future research and guideline recommendations, including FNH follow-up and the management of HCA >5 cm. We propose the organization of Delphi consensus meetings to prioritize areas of research and update current guidelines to optimize management for all patients with benign liver tumors.

© 2023 Published by Elsevier Masson SAS.

Introduction

Benign liver tumors (BLT) are increasingly detected due to the use of diagnostic imaging [1–3]. The diagnosis and management of BLT is challenging due to the heterogeneity in tumor (sub)types and the variable risk of adverse outcomes [4]. Currently, there is a single European guideline for management of BLT, published by the European Association for the Study of the Liver (EASL).

The majority of clinically relevant BLT are focal nodular hyperplasia (FNH) and hepatocellular adenoma (HCA) [3]. FNH are typically solitary, well-circumscribed, non-encapsulated tumors [4–6]. FNH are not at risk of malignant transformation or hemorrhage – neither in male, nor in female [4,6]. Oral contraceptive pill (OCP) use and pregnancy do not affect FNH size, or number [7]. Due to these characteristics, follow-up of FNH is not recommended by the EASL guideline [4]. The challenge of FNH management is its differentiation from HCA on diagnostic imaging. Contrast-enhanced magnetic resonance imaging (CE-MRI) with hepatobiliary contrast agent has the best HCA-FNH differentiating ability [8,9]. The EASL guideline only recommends invasive FNH treatment in case of (significant) mechanical complaints by compression of abdominal viscera or exophytic or pedunculated growth [4,10].

HCA are most frequently diagnosed in middle-aged women [3,4]. HCA are associated with sustained high estrogen exposure, by prolonged use of OCP, and/or obesity [10,11].

The main complications of HCA, *i.e.* hemorrhage and transformation to hepatocellular carcinoma [4,12–15], are related to adenoma size and subtype. Both complications are extremely rare in HCA <5 cm. Key to non-invasive management is HCA-regression after estrogen reduction by the cessation of OCP intake and/or weight loss [16,17]. In female patients with HCA >5 cm (without signs of pre-malignancy on MRI [*e.g.* diffusion restriction] or histopathology [*e.g.* cellular atypia]), cessation of OCP intake and weight loss is advised, and tumor size is evaluated after six months. In male patients, however, immediate invasive treatment of all HCA is recommended irrespective of tumor size due to the high risk of malignant transformation [4]. The risk of malignant transformation in male patients is associated with the male sex itself and due to higher prevalence of beta-catenin activated HCA (b-HCA) subtype [12,14,18].

Currently, there are no data available on European daily clinical management of FNH and HCA. Insight into real-world management strategies of FNH and HCA may identify areas of improvement for future research, guideline adjustment, and guideline implementation. We therefore conducted an online survey among European medical specialists involved

in BLT treatment. Our study aimed to evaluate potential variation in clinical practice and real-world management of FNH and HCA in Europe.

Material and methods

Study design

A obligatory survey study was performed among European BLT experts. Experts and expert centers were selected and contacted based on authorship on a FNH or HCA oriented publication, identified by one author (MPDH) from the MEDLINE database (PubMed) using the following search query: “focal nodular hyperplasia OR FNH OR “Focal Nodular Hyperplasia”[Mesh] OR hepatocellular adenoma OR hepatic adenoma OR “Adenoma, Liver Cell”[Mesh]” on September 15th 2021.

Survey design and data collection

The survey was designed and tested by a hepatologist (FJCC), hepatobiliary surgeon (VEM), and radiologist (RJDH), and reviewed by other specialists. The survey (Supplementary File 1) included general questions regarding medical specialty, level of training, and experience in treating FNH and HCA. Thereafter, the survey consisted of two parts: (1) an enquiry regarding local daily clinical practice, including organization of the local multidisciplinary team (MDT), available diagnostic techniques and treatment strategies for FNH and HCA patients; and (2) eight fictive clinical vignettes of FNH or HCA patients, enquiring on diagnostic and treatment strategies.

Vignette case description included information on: patient sex, patient age, patient weight (body mass index; BMI), (previous) use of estrogen-containing OCP, pregnancy, imaging modality and results, and tumor behavior during a specified follow-up period (Table 1, Supplementary File 1). None of the patients experienced tumor-related symptoms and tumor markers were within normal range. Imaging by CE-MRI with liver-specific contrast agents was available for all patients, and all tumors were described as pathognomonic on imaging, without any atypia. Respondents were advised to manage the vignette scenarios regardless of the modalities available for the respondent in daily practice. Agreement on management of the clinical vignettes was defined as $\geq 75\%$ agreement between respondents. Management decisions were categorized: additional diagnostics, non-invasive treatment (*e.g.* weight loss, OCP cessation, other), (minimally) invasive treatment, and follow-up. Vignettes were categorized into three clinical categories:

Table 1 Overview of included fictive FNH & HCA patients.

Vignette	Age (year)	Sex	BMI (kg/m ²) [#]	Age of OCP use	Pregnancy	PA	Imaging (interval)
FNH							
Case 1: FNH in male patient	31	M	26	N/A	N/A	–	CE-MRI with liver specific contrast [†] : 1 FNH 6.0 cm
Case 2: Growing FNH in female patient, current OCP use	28	F	24	16	No	–	First MRI: 1 FNH 4.0cm Second (6 months later), CE-MRI with liver specific contrast [†] : 1 FNH 7.0 cm, +75% growth
Case 3: Stable FNH during pregnancy	31	F	22	15–29	2nd trimester	IHC	First (3 months pre-pregnancy), CE-MRI with liver specific contrast [†] : 1 FNH 6.0 cm Second (6 months, 2 nd trimester), US: 1 FNH 6.0 cm
HCA before or during pregnancy							
Case 4: Stable HCA >5 cm and wish to become pregnant	31	F	24	17–28	Strong wish	–	First (stop OCP), CE-MRI with liver specific contrast [†] : 1 HCA 6.8 cm Second (six months later), CE-MRI with liver specific contrast [†] : 1 HCA 6.5 cm Third (12 months after 2nd), CE-MRI with liver specific contrast [†] : 1 HCA 6.6 cm
Case 5: Growing HCA >5 cm during pregnancy	28	F	28	16–26	2nd trimester	–	First CE-MRI with liver specific contrast [†] : HCA 4.5 cm Second (12 months later, 8 weeks gestation), US: 1 HCA 5.0 cm Third (6 weeks after 2nd, 14 weeks gestation), US: 1 HCA 6.0 cm, +33% growth Fourth (6 weeks after 3rd, 20 weeks gestation), US: 1 HCA 7.0 cm, +56% total growth
Case 6: Stable exophytic HCA >5 cm and wish to become pregnant	32	F	24	15–31	No	I-HCA on NGS	First (stop OCP), CE-MRI with liver specific contrast [†] : 1 exophytic HCA 7.1 cm + 5 HCA <5.0 cm Second (6 months later), CE-MRI with liver specific contrast [†] : 1 exophytic HCA 7.0 cm + 5 HCA <5.0 cm
HCA >5 cm, 6 months after OCP stop and weight loss							
Case 7: HCA >5 cm, and <30% regression [*]	26	F	27 (32)	16–26 [§]	No	–	First (stop OCP), CE-MRI with liver specific contrast [†] : 1 HCA 9.0 cm Second (6 months later), CE-MRI with liver specific contrast [†] : 1 HCA 7.6 cm, –16% regression
Case 8: HCA >5 cm, and >30% regression [*]	24	F	26 (28)	17–24 [§]	No	–	First (stop OCP), CE-MRI with liver specific contrast [†] : 1 HCA 12.0 cm Second (6 months after 1st), CE-MRI with liver specific contrast [†] : 1 HCA 8.1 cm, –32.5% regression

^{*} According to RECISTv1.1 criteria 30% regression defines (clinically relevant) “partial response”²⁵.

[#] BMI six months after first imaging in brackets.

[§] OCP stopped six months before second imaging.

[†] Hepatobiliary contrast equals liver specific contrast agents e.g. Primovist or Eovist. Abbreviations: FNH, focal nodular hyperplasia; HCA, hepatocellular adenoma; BMI, body mass index; OCP, oral contraceptive pill; PA, histopathology; M, male; F, female; IHC, immunohistochemistry; CE-MRI, contrast enhanced magnetic resonance imaging; US, ultrasound; NGS, next generation sequencing.

(1) male and female patients with FNH; (2) HCA during pregnancy; and (3) female patients with HCA ≥ 5 cm.

CHERRIES guidelines were adhered to in study design and manuscript preparation [19]. The study was registered in the University Medical Center (UMCG) research registry (UMCG RR#201900347) and was reviewed and approved by the UMCG ethical committee (MEC 2019-290). A collaboration was offered for all respondents who returned a completed survey.

Survey invitations were only distributed by email and collected using REDCap (Vanderbilt University, Tennessee, USA) electronic data capture tools hosted at the UMCG [20,21]. The voluntary survey was open for inclusions from November 2021-March 2022. Three reminders were sent by email after the initial invitation. Conditional questions were used, e.g. preferred follow-up modality was only displayed if respondents opted for follow-up at all. The survey included 216 items, although not all were shown to each respondent due to conditionality. The survey consisted of 11 web pages: background information and instructions (page 1, 3 items), personal information (page 2, 9 items), part I – local practices (page 3, 44 items), and part 2 – cases 1–8 (pages 4–11, 160 items). A REDcap integrated completeness check was used. Respondents were able to review and change answers through a “back” button. All participants received a unique survey weblink. No visitor rates were monitored. No cookies, IP checks, log file analyses, or registrations were used. No questionnaire timestamp analysis was performed.

Statistical analyses

Only fully completed surveys were included in final analysis. Dichotomous data were presented as proportions. Variable distribution was assessed by plotting histograms. Categorical variables were expressed as number (n) and percentage (%).

Variables were analyzed using appropriate statistical tests for variable type and distribution. Parameters with two-tailed $p < 0.05$ were considered statistically significant. No statistical corrections or weightings were applied. All analyses were performed in R version 4.1.0.® (R Core Team (2021). R Foundation, Vienna, Austria).

Results

A link to the survey was emailed to 294 European experts. Ninety-five (32%) experts responded. Thirty-three experts were excluded from analysis due to declining of the invitation ($n = 22$), or partial completion of the survey ($n = 12$). Sixty-one (21%) respondents were included in the final analysis (Fig. 1A).

Profile of respondents

The 61 included respondents originated from a total of ten European countries (Fig. 1B), and included 24 (39%) surgeons, 15 (25%) gastroenterologists/hepatologists, 19 (32%) (interventional) radiologists, 1 pathologist (1.6%), and 2 research associates (3.3%). Ninety-eight percent of respondents worked in tertiary referral hospitals or university medical centers. Ninety percent of respondents currently works as attending/consultant specialist, and 59% had more than 10 years of experience in treatment of BLT (Table 2).

Survey results part I; general questionnaire

Local practice

Fifty-three respondents (87%) participated in a MDT, of whom 96% had weekly meetings and all of whom included a gastroenterologist or hepatologist and a surgeon. Fifty-two

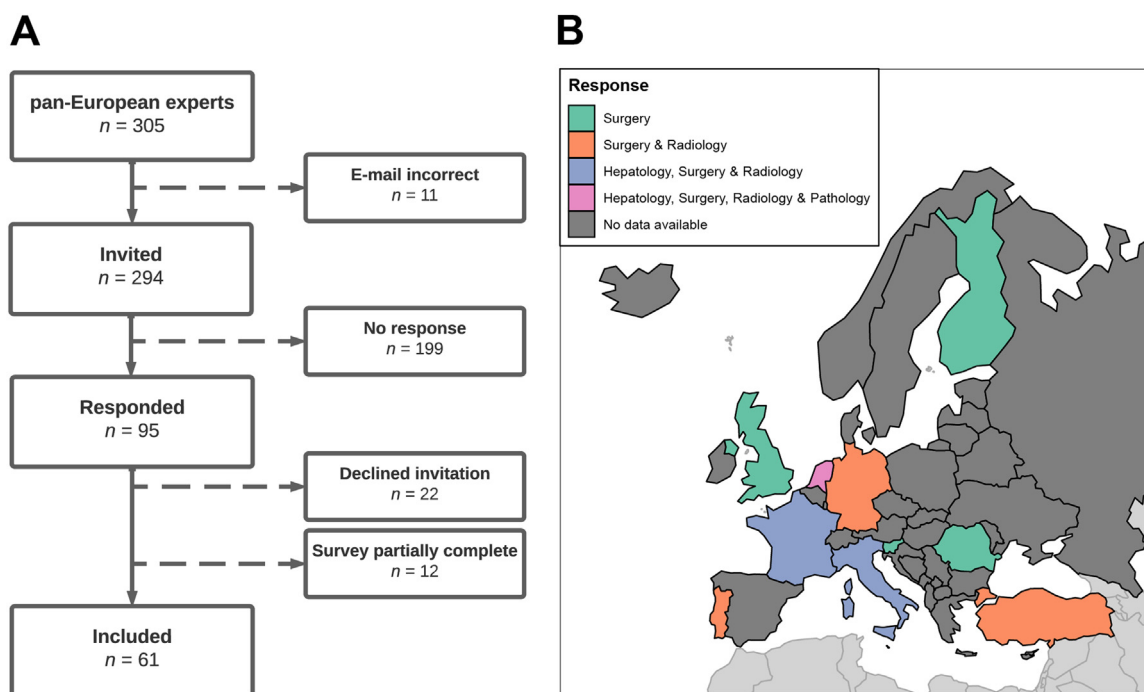


Fig. 1 Overview of participating European experts on BLT. (A) Flowchart of survey responses. (B) Participating medical specialists per included European country. Abbreviations: BLT, benign liver tumors.

Table 2 Baseline characteristics of included European FNH & HCA experts.

Characteristic			
Country of origin (n, %)			
	Finland	1	(1.6)
	France	8	(13)
	Germany	4	(6.6)
	Italy	5	(8.2)
	Netherlands	33	(54)
	Portugal	2	(3.3)
	Romania	1	(1.6)
	Slovenia	1	(1.6)
	Turkey	2	(3.3)
	United Kingdom	1	(1.6)
	Unknown	3	(4.9)
Type of medical center (n, %)			
	Regional hospital	1	(1.6)
	Referral hospital /University medical center	60	(98)
Level of training (n, %)			
	Resident	5	(8.2)
	Fellow	1	(1.6)
	Staff/attending	55	(90)
Type of specialty (n, %)			
	Gastroenterologist or hepatologist	15	(25)
	Surgeon (general or HPB)	23	(38)
	Radiologist (general or interventional)	19	(32)
	Pathologist	1	(1.6)
	Other	3	(4.9)
Years of experience in treating FNH & HCA (n, %)			
	<5 years	7	(11)
	5–10 years	18	(30)
	>10 years	36	(59)
Use of MDT meetings (n, %)		53	(87)
Use of EASL recommended BLT-MDT		31	(51)
Frequency of MDT meetings (n, %)			
	Weekly	51	(84)
	Every 2 weeks	1	(1.9)
	Other	1	(1.9)
Treatment of HCA/FNH in outpatient setting (n, %)			
	Gastroenterologist/hepatologist	12	(20)
	Surgeon (general or HPB)	3	(4.9)
	Both gastroenterologist/hepatologist & surgeon	46	(75)

Abbreviations: FNH, focal nodular hyperplasia; HCA, hepatocellular adenoma; MRI, magnetic resonance imaging; HPB, hepatobiliary; MDT, multidisciplinary team; EASL, European association for the study of the liver; BLT, benign liver tumor.

(98%) respondents participated in an MDT that included a radiologist, 42 (79%) participated in an MDT that included an interventional radiologist and/or a pathologist, and 18 (34%) respondents participated in an MDT that included other specialists, namely radiotherapists (11%), oncologists (44%), or nuclear medicine physicians (17%). Thirty-one (51%) respondents participated in an MDT that included a gastroenterologist or hepatologist, hepatobiliary surgeon, diagnostic radiologist, interventional radiologist, and pathologist (*i.e.* EASL guideline BLT-MDT recommendation). Outpatient BLT patients were managed by gastroenterologists/hepatologists and surgeons (75% of the respondents), gastroenterologists/hepatologists only (20%), or surgeons only (4.9%) (Table 2).

Diagnostic techniques

All (100%) respondents preferred a hepatobiliary contrast agent to differentiate FNH from HCA. Sixteen (26%) respondents used contrast-enhanced ultrasound (CEUS) as additional tool for FNH—HCA differentiation.

HCA subtype diagnosis on CE-MRI was accepted if the diagnosis was inflammatory (I-HCA) by 29 (48%) respondents, by 28 (46%) for H—HCA, and by 19 (31%) for b-HCA/b-IHCA. Molecular diagnostics on histopathology was available for 50 (82%) respondents', and was used on all HCA samples by 60% of the respondents. Twelve (20%) respondents used this technique mainly when b-HCA/b-IHCA was suspected on immunohistochemistry, 6 (9.8%) when b-HCA/b-IHCA was diagnosed on immunohistochemistry, and 14 (23%) when no

subtype could be identified on immunohistochemistry (unclassified HCA; U-HCA).

Clinical management of FNH

Thirty-seven (61%) respondents would discharge male asymptomatic FNH patients from follow-up when diagnosed with hepatobiliary CE-MRI. Female patients with an asymptomatic FNH (diagnosed by hepatobiliary CE-MRI) were discharged without follow-up by 50 (82%) of the respondents, whereas 11 (18%) would continue follow-up, and 3 (4.9%) of the respondents would advise life-style interventions. The proposed follow-up included CE-MRI ($n = 3$), unenhanced MRI ($n = 1$), or US ($n = 4$) for 6 months up to 3 years at intervals of 6–12 months. Four (6.6%) respondents commented follow-up would stop if FNH proved stable after 1–3 years.

Clinical management of HCA and pregnancy

For patients with CE-MRI- or biopsy-proven HCA <5 cm with a pregnancy wish, 54 (89%) respondents recommended follow-up according to the algorithm used in the PALM study protocol (*i.e.* evaluation of pregnant patients with HCA < 5 cm by ultrasound (US) at 14 (± 3), 20, 26, 32, and 38 weeks of gestation, and 6–12 weeks postpartum) [22,23]. Other respondents would advise follow-up by US every 1 ($n = 1$), 2 ($n = 1$), 3 ($n = 1$), or 6 ($n = 1$) months, or “according to the follow-up scheme by the gastroenterologist” or “close follow-up, but not according to the PALM study protocol”. Two respondents recommended pre-emptive treatment (transarterial embolization, radiofrequency ablation, or surgery).

For patients with CE-MRI- or biopsy-proven HCA 5–10 cm pre-emptive treatment was recommended by 52 (85%) of the respondents, and 7 (12%) recommended follow-up without pre-emptive treatment according to the PALM study protocol [22,23].

For HCA >10 cm pre-emptive treatment was recommended by 55 (90%) respondents, 4 (6.6%) recommended follow-up without pre-emptive treatment according to the PALM study protocol, and the remaining 2 (3.3%) respondents would await the six-month effect of stopping OCP or could not decide on a specific treatment. HCA >5 cm (non-exophytic) on itself was considered a contraindication for pregnancy by 11 (18%) respondents.

Clinical management of large (> 5 cm) HCA

Forty-eight (79%) respondents advised against routine HCA resection, regardless of tumor regression, when tumor size remained >5 cm after six months of weight loss and stopping OCP. Fifty-two (85%) respondents would continue follow-up of a female patient with HCA <5 cm while still ovulating, compared with 56% for a post-menopausal patient. Follow-up duration for ovulating women varied from 1 to 10 years or “up to menopause”. For post-menopausal patients, follow-up duration varied from 1 to 15 years.

Survey results part II: clinical vignette-based questionnaire

Clinical vignettes 1–3: FNH

FNH in a male patient. The respondents agreed (agreement defined as >75% consensus) that additional diagnostics, weight loss, or invasive treatment were unnecessary. Six (9.8%) respondents advised additional diagnostic testing by either percutaneous biopsy ($n = 4$) or additional imaging ($n = 4$) (Fig. 2, Supplementary Tables 1 and 2 – Case 1). One respondent (1.6%) opted for surgical resection. Follow-up imaging was advised by 23 (38%) respondents, mostly by US (13%), or CE-MRI (18%). The advised follow-up interval was mainly 3 ($n = 5$) or 6-months ($n = 11$) (Supplementary Tables 1 and 2).

Growing FNH <5 cm during OCP use

The respondents agreed that additional diagnostics, weight loss, or invasive treatment were not necessary. Thirteen (21%) respondents advised additional diagnostic testing by percutaneous liver biopsy ($n = 10$), or additional imaging ($n = 3$) (Fig. 2, Supplementary Tables 1 and 2 – Case 2). Twenty-three (38%) respondents would cease OCP intake and 11 (18%) advised weight loss. Four (4.9%) respondents opted for invasive treatment, either by resection ($n = 3$) or embolization ($n = 1$). Follow-up imaging was advised by 45 (74%) respondents, mostly by CE-MRI ($n = 27$) or US ($n = 12$). The advised follow-up interval was mainly 3 (26%) or 6 months (62%).

Stable FNH during pregnancy. The respondents agreed that additional diagnostics, weight loss, or invasive treatment were not necessary. Only two (3.3%) respondents advised additional diagnostic testing by hepatobiliary CE-MRI ($n = 1$), or hepatobiliary CE-MRI and CEUS ($n = 1$) (Fig. 2, Supplementary Tables 1 and 2 – Case 3). Only 1 (1.6%) respondent advised weight loss. Almost two-third ($n = 50$) of the respondents advised against follow-up imaging of the patient, whereas 18 (30%) respondents would advise follow-up imaging by US, mostly (61%) according to PALM study protocol. Four (6.6%) respondents would rather use liver-specific CE-MRI for follow-up.

Clinical vignettes 4–6: HCA during pregnancy

Stable HCA >5 cm and wish to become pregnant. The respondents agreed on starting follow-up, and on not discouraging pregnancy. Twenty-one (34%) respondents would perform additional diagnostic testing, mostly by percutaneous liver biopsy ($n = 16$) or CE-MRI ($n = 5$) (Fig. 2, Supplementary Tables 1 and 2 – Case 4). Forty (66%) respondents recommended pre-emptive invasive treatment, either by resection ($n = 26$), embolization ($n = 13$), or ablation ($n = 1$). Fifty respondents (82%) would perform follow-up imaging, mostly by CE-MRI ($n = 24$) or US ($n = 20$). The suggested follow-up interval was either 3 ($n = 8$), 6 ($n = 15$), or 12 ($n = 14$) months (Supplementary Tables 1 and 2).

Growing HCA >5 cm during pregnancy. The respondents agreed that additional diagnostics or weight loss were not necessary, and agreed on starting follow-up. Fourteen (23%) respondents would perform additional diagnostic testing, either by unenhanced MRI ($n = 5$), CE-MRI ($n = 4$), US ($n = 3$), or by CEUS ($n = 1$) (Fig. 2, Supplementary Tables 1 and 2 – Case 5). Eleven (18%) respondents advised weight loss.

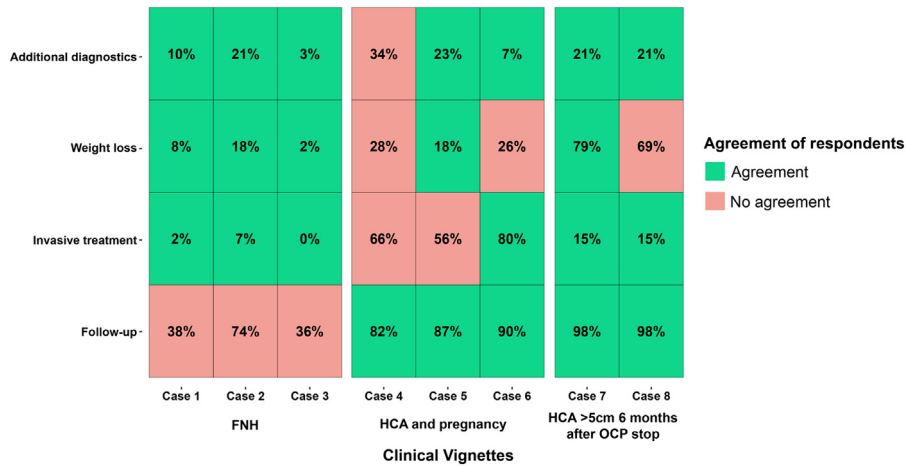


Fig. 2 Response of included European experts to eight fictive clinical vignettes on FNH and HCA patients. Values represent percentage of respondents opting for management options, i.e. additional diagnostics or follow-up per case. Management agreement was defined as $\geq 75\%$ of respondents opting for either yes or no.

- Case 1: Hepatobiliary CE-MRI diagnosed FNH in male patient.
- Case 2: Growing hepatobiliary CE-MRI diagnosed FNH in female patient with OCP use.
- Case 3: Stable CE-MRI diagnosed FNH in pregnant patient.
- Case 4: Stable hepatobiliary CE-MRI diagnosed HCA > 5 cm and pregnancy wish.
- Case 5: Growing hepatobiliary CE-MRI diagnosed HCA > 5 cm during pregnancy.
- Case 6: Stable exophytic hepatobiliary CE-MRI diagnosed HCA > 5 cm and pregnancy wish.
- Case 7: Hepatobiliary CE-MRI diagnosed HCA > 5 cm with <30% regression 6 months after OCP stop[†]
- Case 8: Hepatobiliary CE-MRI diagnosed HCA > 5 cm with >30% regression 6 months after OCP stop[†]

Abbreviations: CE-MRI, contrast enhanced magnetic resonance imaging; FNH, focal nodular hyperplasia; HCA, hepatocellular adenoma; OCP, oral contraceptive pill.

[†]30% regression is defined as a clinically relevant, “partial response” according to RECISTv1.1 [24].

Thirty-four (56%) respondents would perform invasive treatment, either by embolization ($n = 19$) or resection ($n = 14$). Almost 90% of respondents would closely follow the patient during pregnancy, mostly (77%) according to the PALM study protocol. Twelve (20%) respondents proposed an alternative follow-up protocol: either by US ($n = 6$), by CE-MRI ($n = 4$), by unenhanced MRI ($n = 1$), or by unenhanced computed tomography (CT; $n = 1$), with follow-up after 1–2 months ($n = 7$) or 6 months ($n = 5$).

Stable exophytic HCA > 5 cm and wish to become pregnant.
The respondents agreed that additional diagnostics were not necessary, and agreed on advising invasive treatment and on starting follow-up. Four (6.6%) respondents would perform additional diagnostics either by percutaneous biopsy ($n = 3$) or CE-MRI ($n = 1$). Sixteen (26%) of respondents would advise weight loss (Fig. 2, Supplementary Tables 1 and 2 – Case 6). Forty-nine (80%) respondents opted for invasive therapy, mostly resection ($n = 44$). Fifty-five (90%) respondents would closely follow the patient during pregnancy, 24 (39%) respondents according to the PALM study protocol. Thirty-one respondents (51%) proposed an alternative follow-up protocol: either by CE-MRI ($n = 19$), by US ($n = 6$), by unenhanced MRI ($n = 3$), by CEUS ($n = 2$), or by unenhanced CT ($n = 1$), with follow-up after 3 ($n = 6$), 6 ($n = 19$), or 12 months ($n = 6$).

Clinical vignettes 7 and 8: HCA ≥ 5 cm after six months of lifestyle therapy

On both clinical vignettes of female patients with HCA > 5 cm after six months of conservative therapy,

respondents agreed that additional diagnostics or invasive treatment were not necessary and opted to monitor patients by follow-up imaging. Recommendations were comparable for HCA > 5 that showed more (Case 8) or less (Case 7) than 30% regression (i.e. the RECISTv1.1 cut-off for partial tumor regression [24]) after six months of lifestyle interventions (Fig. 2, Supplementary Tables 1 and 2 – Case 7 & 8). Nine respondents (15%) would perform invasive therapy, of whom 8 would consider resection, and 1 transarterial embolization (TAE). Follow-up was proposed by $\geq 95\%$ of respondents, 58% of whom would use CE-MRI, 20% unenhanced MRI, and 20% US. Respondents advised to follow-up patients after 6 months (70%), or 12 months (22%).

Conclusion

This survey study demonstrates variation in the European management of FNH and HCA. We observed variation with regard to lifestyle modification and imaging follow-up in patients with FNH, and with regard to the management of larger (> 5 cm) HCA before and during pregnancy. Most (> 75%) respondents advised against routine resection of HCA > 5 cm after lifestyle modifications, which deviates from EASL guideline recommendations.

The first part of the survey consisted of general questions regarding local practice, diagnostic techniques, and clinical management of FNH and HCA, while the second part consisted of fictitious vignettes in three categories: FNH (in male

and female patients), HCA before and during pregnancy, and HCA >5 cm six months after lifestyle modification.

Almost 90% of the respondents participated in a MDT that included a gastroenterologist/hepatologist and a surgeon. Only 59% of the respondents, however, participated in a BLT-MDT as defined by the EASL guideline, which also includes (at least) a diagnostic and interventional radiologist and a pathologist. CEUS, a modality excellent at FNH—HCA differentiation in tumors <3 cm, was only used by 21% of respondents [25,26]. CEUS can be considered prior to biopsy when results from hepatobiliary CE-MRI prove inconclusive. Most (82%) respondents had molecular (*i.e.* next generation sequencing) HCA subtype diagnostics available in their center, a technique that can reveal b-catenine mutations unobserved on immunohistochemistry [27]. Interestingly, non-invasive subtype diagnosis on CE-MRI was also accepted for b-HCA/b-IHCA by about a third of respondents. Although non-invasive HCA subtype identification with MRI has made significant progress in recent years [28,29], no large studies on MRI-based b-HCA/b-IHCA identification have been performed, and biopsy should always be considered if b-HCA/b-IHCA are suspected.

Although the respondents agreed that additional diagnostics, weight loss, or invasive treatment were not necessary in FNH in all clinical vignettes, respondents disagreed on the need to follow-up FNH patients in both the general and vignette-based part of or survey. Indeed, a significant minority of respondents would continue imaging follow-up in male (almost 40% of respondents) and female (18% of respondents) patients with FNH. In addition, 74% of the respondents would continue imaging follow up and 38% would cease OCP intake in female FNH patients using OCP when tumor growth was reported, whilst OCP has been proven to have no influence on FNH number or size, and FNH might grow and reduce in size spontaneously [7]. Although FNH was described as pathognomonic on imaging in our survey, lingering uncertainty on potential HCA occurrence instead of FNH, which carries significant clinical consequences, might explain these results. Regarding HCA before or during pregnancy, respondents agreed that additional diagnostics (*i.e.* biopsy) were unnecessary, that close follow-up (according to PALM-protocol) should be advised during pregnancy, that treatment of stable HCA < 5 cm is not warranted, and that pre-emptive invasive treatment of exophytic HCA should be performed. No agreement was observed regarding the need for invasive treatment of HCA >5 cm before and during pregnancy, although the majority of the respondents opted for invasive therapy. The latter observation illustrates the limited amount of evidence on HCA >5 cm during and after pregnancy, whilst HCA <5 cm have been observed as safe during pregnancy and the postpartum period [23,30].

Several respondents opted for minimal invasive HCA treatment through arterial embolization or percutaneous tumor ablation, both of which have been proven effective and safe [18,31]. The current EASL guideline recommends invasive treatment of all HCA >5 cm after six months of OCP cessation and weight loss. Most (85%) respondents, however, advised against routine invasive treatment of these HCA, provided that these tumors decreased in size. Respondents provided similar responses with regards to intervention and follow-up between the two vignettes with more or less than 30% tumor diameter reduction (*i.e.* the RECISTv1.1 cut-off for partial

tumor regression) [24]. Follow-up of HCA after OCP cessation is safe [17], and six months wait-and-see might be too short for large HCA (*i.e.* >7–10 cm) to regress to sub-5 cm size. Consequently, prolongation of the six-month period has been suggested [32]. Half of the respondents would advise to continue follow-up of postmenopausal patients with HCA <5 cm, although there is evidence for safety and good prognosis of HCA after menopausal onset, which has been argued to allow for safe discontinuation of follow-up [33]. A few respondents advised CE-MRI for pregnant patients. Although MRI without gadolinium seems relatively safe, the teratogenicity of CE-MRI has not been refuted and pregnancy is still considered a relative contraindication for CE-MRI [34]. If truly indicated, an unenhanced MRI may be performed, preferably from the second trimester onwards.

The current study may be limited by its relatively low response rate. As half of the respondents were from the Netherlands, this might create regional bias which may affect the analysis. Also, the current survey was sent to European clinical practitioners only and did not include experts from other continents. In addition, although we aimed to focus on the most relevant and controversial clinical situations, only a limited number of clinical vignettes could be presented due to constraints of time for the respondents to fill in the survey. Also HCA subtypes have been excluded in the current clinical vignettes. As HCA tumor behavior and complication profiles differ distinctly between subtypes, HCA subtype should be included in future case vignette studies [4,14,34,35]. Lastly, the current analysis did not focus on inter-specialty comparison of management, or the comparison of management of different HCA subtypes.

There was a large extent of variance between management strategies between European experts in the current study. Future studies and clinical practice guidelines could focus on the areas with variance uncovered in the current survey to provide additional data for European professionals. Using the Delphi method could improve clinical (and scientific) consensus on management using currently available data as well as identify areas of future research [36]. These areas include diagnostic and follow-up strategies for FNH—HCA differentiation, HCA >5 cm before, during, and after pregnancy, HCA in post-menopausal women, management of HCA >5 cm after six-months of lifestyle changes, histopathological and/or molecular definitions of HCA subtypes, and duration of follow-up in HCA <5 cm. Reduction of European clinical ambiguity on BLT may decrease unwarranted treatment variation and could improve patient care.

In conclusion, our survey illustrates substantial variability in FNH and HCA management among European expert centers. Several areas were identified for future research and guideline recommendations, including FNH follow-up and the management of HCA >5 cm. We propose the organization of Delphi consensus meetings to prioritize new areas of research and update current guidelines in order to optimize management for all patients with benign liver tumors.

Sources of funding/grant support/This may be Funding Agency. Please check financial disclosure

None to be reported.

Data availability

The data that support the findings of this study are available from the corresponding authors, FJCC & VEDM, upon reasonable request.

Declaration of Competing Interest

None to be reported.

CRedit authorship contribution statement

Martijn P.D. Haring: Visualization, Writing – original draft, Formal analysis, Supervision. **Robbert J. de Haas:** Validation, Supervision, Writing – original draft. **Frederike G.I. van Vilsteren:** Validation, Supervision, Writing – original draft. **Joost M. Klaase:** Validation, Supervision, Writing – original draft. **Evelien W. Duiker:** Validation, Supervision, Writing – original draft. **Koert P. de Jong:** Validation, Supervision, Writing – original draft. **Vincent E. de Meijer:** Visualization, Writing – original draft. **Frans J.C. Cuperus:** Visualization, Writing – original draft.

Acknowledgments

The authors thank all participating experts for their response.

Supplementary materials

Supplementary material associated with this article can be found in the online version at [doi:10.1016/j.clinre.2023.102094](https://doi.org/10.1016/j.clinre.2023.102094).

References

- [1] Gore RM, Pickhardt PJ, Morteale KJ, Fishman EK, Horowitz JM, Fimmel CJ, et al. Management of incidental liver lesions on CT: a white paper of the ACR incidental findings committee. *J Am Coll Radiol* 2017;14:1429-37. doi: [10.1016/j.jacr.2017.07.018](https://doi.org/10.1016/j.jacr.2017.07.018).
- [2] Koea JB. Hepatic incidentaloma: the rule of tens. *HPB* 2013;15:379-83. doi: [10.1111/j.1477-2574.2012.00595.x](https://doi.org/10.1111/j.1477-2574.2012.00595.x).
- [3] Kaltenbach TEM, Engler P, Kratzer W, Oeztuerk S, Seufferlein T, Haenle MM, et al. Prevalence of benign focal liver lesions: ultrasound investigation of 45,319 hospital patients. *Abdom Radiol* 2016;41:25-32. doi: [10.1007/s00261-015-0605-7](https://doi.org/10.1007/s00261-015-0605-7).
- [4] Colombo M, Forner A, IJzermans J, Paradis V, Reeves H, Vilgrain V, et al. EASL clinical practice guidelines on the management of benign liver tumours. *J Hepatol* 2016;65:386-98. doi: [10.1016/j.jhep.2016.04.001](https://doi.org/10.1016/j.jhep.2016.04.001).
- [5] Belghiti J, Cauchy F, Paradis V, Vilgrain V. Diagnosis and management of solid benign liver lesions. *Nat Rev Gastroenterol Hepatol* 2014;11:737-49. doi: [10.1038/nrgastro.2014.151](https://doi.org/10.1038/nrgastro.2014.151).
- [6] Roncalli M, Sciarra A, di Tommaso L. Benign hepatocellular nodules of healthy liver: focal nodular hyperplasia and hepatocellular adenoma. *Clin Mol Hepatol* 2016;22:199-211. doi: [10.3350/cmh.2016.0101](https://doi.org/10.3350/cmh.2016.0101).
- [7] Mathieu D, Kobeiter H, Maison P, Rahmouni A, Cherqui D, Zafrani ES, et al. Oral contraceptive use and focal nodular hyperplasia of the liver. *Gastroenterology* 2000;118:560-4. doi: [10.1016/s0016-5085\(00\)70262-9](https://doi.org/10.1016/s0016-5085(00)70262-9).
- [8] Grazioli L, Bondioni MP, Haradome H, Motosugi U, Tinti R, Frittoli B, et al. Hepatocellular adenoma and focal nodular hyperplasia: value of gadoteric acid-enhanced MR imaging in differential diagnosis. *Radiology* 2012;262:520-9. doi: [10.1148/radiol.11101742](https://doi.org/10.1148/radiol.11101742).
- [9] Suh CH, Kim KW, Kim GY, Shin YM, Kim PN, Park SH. The diagnostic value of Gd-EOB-DTPA-MRI for the diagnosis of focal nodular hyperplasia: a systematic review and meta-analysis. *Eur Radiol* 2015;25:950-60. doi: [10.1007/s00330-014-3499-9](https://doi.org/10.1007/s00330-014-3499-9).
- [10] Edmondson HA, Henderson B, Benton B. Liver-cell adenomas associated with use of oral contraceptives. *N Engl J Med* 1976;294:470-2. doi: [10.1056/NEJM197602262940904](https://doi.org/10.1056/NEJM197602262940904).
- [11] Gevers TJG, Marcel Spanier BW, Veendrick PB, Vrolijk JM. Regression of hepatocellular adenoma after bariatric surgery in severe obese patients. *Liver Int* 2018;38:2134-6. doi: [10.1111/liv.13934](https://doi.org/10.1111/liv.13934).
- [12] Farges O, Ferreira N, Dokmak S, Belghiti J, Bedossa P, Paradis V. Changing trends in malignant transformation of hepatocellular adenoma. *Gut* 2011;60:85-9. doi: [10.1136/gut.2010.222109](https://doi.org/10.1136/gut.2010.222109).
- [13] Bieze M, Phoa SSKS, Verheij J, van Lienden KP, van Gulik TM. Risk factors for bleeding in hepatocellular adenoma. *Br J Surg* 2014;101:847-55. doi: [10.1002/bjs.9493](https://doi.org/10.1002/bjs.9493).
- [14] Nault JC, Couchy G, Balabaud C, Morcrette G, Caruso S, Blanc JF, et al. Molecular classification of hepatocellular adenoma associates with risk factors, bleeding, and malignant transformation. *Gastroenterology* 2017;152:880-94. doi: [10.1053/j.gastro.2016.11.042](https://doi.org/10.1053/j.gastro.2016.11.042).
- [15] Stoot JHMB, Coelen RJS, de Jong MC, Dejong CHC. Malignant transformation of hepatocellular adenomas into hepatocellular carcinomas: a systematic review including more than 1600 adenoma cases. *HPB* 2010;12:509-22. doi: [10.1111/j.1477-2574.2010.00222.x](https://doi.org/10.1111/j.1477-2574.2010.00222.x).
- [16] Edmondson HA, Reynolds TB, Henderson B, Benton B. Regression of liver cell adenomas associated with oral contraceptives. *Ann Intern Med* 1977;86:180-2. doi: [10.7326/0003-4819-86-2-180](https://doi.org/10.7326/0003-4819-86-2-180).
- [17] Haring MPD, Gouw ASH, de Haas RJ, Cuperus FJC, de Jong KP, de Meijer VE. The effect of oral contraceptive pill cessation on hepatocellular adenoma diameter: a retrospective cohort study. *Liver Int* 2019;39:905-13. doi: [10.1111/liv.14074](https://doi.org/10.1111/liv.14074).
- [18] van Rosmalen BV, Klompenhouwer AJ, de Graeff JJ, Haring MPD, de Meijer VE, Rifai L, et al. Safety and efficacy of transarterial embolization of hepatocellular adenomas. *Br J Surg* 2019;106:1362-71. doi: [10.1002/bjs.11213](https://doi.org/10.1002/bjs.11213).
- [19] Eysenbach G. Improving the quality of web surveys: the checklist for reporting results of internet E-surveys (CHERRIES). *J Med Internet Res* 2004;6:e132. doi: [10.2196/jmir.6.3.e34](https://doi.org/10.2196/jmir.6.3.e34).
- [20] Harris PA, Taylor R, Thielke R, Payne J, Gonzalez N, Conde JG. Research electronic data capture (REDCap)—a metadata-driven methodology and workflow process for providing translational research informatics support. *J Biomed Inform* 2009;42:377-81. doi: [10.1016/j.jbi.2008.08.010](https://doi.org/10.1016/j.jbi.2008.08.010).
- [21] Harris PA, Taylor R, Minor BL, Elliott V, Fernandez M, O'Neal L, et al. The REDCap consortium: building an international community of software platform partners. *J Biomed Inform* 2019;95:103208. doi: [10.1016/j.jbi.2019.103208](https://doi.org/10.1016/j.jbi.2019.103208).
- [22] van Aalten SM, Bröker MEE, Busschbach JJv, de Koning HJ, de Man RA, Steegers EAP, et al. Pregnancy and liver adenoma management: pALM-study. *BMC Gastroenterol* 2012;12:82. doi: [10.1186/1471-230X-12-82](https://doi.org/10.1186/1471-230X-12-82).
- [23] Gaspersz MP, Klompenhouwer AJ, Broker MEE, Thomeer MGJ, van Aalten SM, Steegers E, et al. Growth of hepatocellular adenoma during pregnancy: a prospective study. *J Hepatol* 2020;72:119-24. doi: [10.1016/j.jhep.2019.09.011](https://doi.org/10.1016/j.jhep.2019.09.011).
- [24] Eisenhauer EA, Therasse P, Bogaerts J, Schwartz LH, Sargent D, Ford R, et al. New response evaluation criteria in solid

- tumours: revised RECIST guideline (version 1.1). *Eur J Cancer* 2009;45:228-47. doi: [10.1016/j.ejca.2008.10.026](https://doi.org/10.1016/j.ejca.2008.10.026).
- [25] Roche V, Pigneur F, Tselikas L, Roux M, Baranes L, Djabbari M, et al. Differentiation of focal nodular hyperplasia from hepatocellular adenomas with low-mechanical-index contrast-enhanced sonography (CEUS): effect of size on diagnostic confidence. *Eur Radiol* 2015;25:186-95. doi: [10.1007/s00330-014-3363-y](https://doi.org/10.1007/s00330-014-3363-y).
- [26] Bertin C, Egels S, Wagner M, Huynh-Charlier I, Vilgrain V, Lucidarme O. Contrast-enhanced ultrasound of focal nodular hyperplasia: a matter of size. *Eur Radiol* 2014;24:2561-71. doi: [10.1007/s00330-014-3280-0](https://doi.org/10.1007/s00330-014-3280-0).
- [27] van Rosmalen BV, Furumaya A, Klompenhouwer AJ, Tushuizen ME, Braat AE, Reinten RJ, et al. Hepatocellular adenoma in men: a nationwide assessment of pathology and correlation with clinical course. *Liver Int* 2021;41:2474-84. doi: [10.1111/liv.14989](https://doi.org/10.1111/liv.14989).
- [28] Auer TA, Fehrenbach U, Grieser C, Penzkofer T, Geisel D, Schmelzle M, et al. Hepatocellular adenomas: is there additional value in using Gd-EOB-enhanced MRI for subtype differentiation? *Eur Radiol* 2020;30:3497-506. doi: [10.1007/s00330-020-06726-8](https://doi.org/10.1007/s00330-020-06726-8).
- [29] Bise S, Frulio N, Hocquet A, Alberti N, Blanc JF, Laurent C, et al. New MRI features improve subtype classification of hepatocellular adenoma. *Eur Radiol* 2019;29:2436-47. doi: [10.1007/s00330-018-5784-5](https://doi.org/10.1007/s00330-018-5784-5).
- [30] Haring MPD, Spijkerboer CS, Cuperus FJC, Duiker EW, de Jong KP, de Haas RJ, et al. Behavior and complications of hepatocellular adenoma during pregnancy and puerperium: a retrospective study and systematic review. *HPB* 2021;23:1152-63. doi: [10.1016/j.hpb.2021.04.019](https://doi.org/10.1016/j.hpb.2021.04.019).
- [31] Mironov O, Jaber A, Beecroft R, Kachura JR. Retrospective single-arm cohort study of patients with hepatocellular adenomas treated with percutaneous thermal ablation. *Cardiovasc Intervent Radiol* 2018;41:935-41. doi: [10.1007/s00270-018-1893-4](https://doi.org/10.1007/s00270-018-1893-4).
- [32] Klompenhouwer AJ, Bröker MEE, Thomeer MGJ, Gaspersz MP, de Man RA, IJzermans JNM. Retrospective study on timing of resection of hepatocellular adenoma. *Br J Surg* 2017;104:1695-703.
- [33] Klompenhouwer AJ, Sprengers D, Willemsen FEJA, Gaspersz MP, IJzermans JNM, de Man RA. Evidence of good prognosis of hepatocellular adenoma in post-menopausal women. *J Hepatol* 2016;65:1163-70. doi: [10.1016/j.jhep.2016.07.047](https://doi.org/10.1016/j.jhep.2016.07.047).
- [34] Nault JC, Paradis V, Ronot M, Zucman-Rossi J. Benign liver tumours: understanding molecular physiology to adapt clinical management. *Nat Rev Gastroenterol Hepatol* 2022;19:703-16. doi: [10.1038/S41575-022-00643-5](https://doi.org/10.1038/S41575-022-00643-5).
- [35] Bioulac-Sage P, Gouw ASH, Balabaud C, Sempoux C. Hepatocellular adenoma: what we know, what we do not know, and why it matters. *Histopathology* 2022;80:878-97. doi: [10.1111/HIS.14605](https://doi.org/10.1111/HIS.14605).
- [36] Hsu CC, Sandford BA. The Delphi Technique: making Sense of Consensus. *Pract Assess Res Eval* 2019;12:10. doi: [10.7275/pdz9-th90](https://doi.org/10.7275/pdz9-th90).