



Universiteit
Leiden
The Netherlands

Increasing evidence for the safety of fovea-involving half-dose photodynamic therapy for chronic central serous chorioretinopathy

Feenstra, H.M.A.; Diederer, R.M.H.; Lamme, M.J.C.M.; Tsonaka, R.; Fauser, S.; Yzer, S.; ... ; Boon, C.J.F.

Citation

Feenstra, H. M. A., Diederer, R. M. H., Lamme, M. J. C. M., Tsonaka, R., Fauser, S., Yzer, S., ... Boon, C. J. F. (2023). Increasing evidence for the safety of fovea-involving half-dose photodynamic therapy for chronic central serous chorioretinopathy. *Retina: The Journal Of Retinal And Vitreous Diseases*, 43(3), 379-388. doi:10.1097/IAE.0000000000003686

Version: Publisher's Version
License: [Creative Commons CC BY-NC-ND 4.0 license](https://creativecommons.org/licenses/by-nc-nd/4.0/)
Downloaded from: <https://hdl.handle.net/1887/3748580>

Note: To cite this publication please use the final published version (if applicable).

INCREASING EVIDENCE FOR THE SAFETY OF FOVEA-INVOLVING HALF-DOSE PHOTODYNAMIC THERAPY FOR CHRONIC CENTRAL SEROUS CHORIORETINOPATHY

HELENA M. A. FEENSTRA, MD,* ROSELIE M. H. DIEDEREN, MD, PhD,† MARTINE J. C. M. LAMME, MSc,* ROULA TSONAKA, PhD,‡ SASCHA FAUSER, MD, PhD,§¶ SUZANNE YZER, MD, PhD,** THOMAS VAN RIJSSSEN, MD, PhD,* THEODORA GKIKA, MD,†† SUSAN M. DOWNES, MD,††‡‡ REINIER O. SCHLINGEMANN, MD, PhD,†§§ CAREL B. HOYNG, MD, PhD,** ELON H. C. VAN DIJK, MD, PhD,* CAMIEL J. F. BOON, MD, PhD*†

Purpose: A retrospective study was performed with data from the prospective randomized controlled trials, PLACE and SPECTRA, assessing the risk of foveal atrophy and the likelihood of structural and functional improvement on optical coherence tomography, after foveal half-dose photodynamic therapy in chronic central serous chorioretinopathy.

Methods: A total of 57 chronic central serous chorioretinopathy patients received a single half-dose photodynamic therapy with a treatment spot that included the fovea. Optical coherence tomography scans and fundus autofluorescence images were analyzed for structural improvement and possible atrophy development, at baseline and at several visits after treatment. Main outcome measures were integrity of the external limiting membrane and ellipsoid zone on optical coherence tomography and hypoautofluorescence on fundus autofluorescence.

Results: The subfoveal external limiting membrane was graded as continuous in 21 of 57 of patients (36.8%) at baseline, and the subfoveal ellipsoid zone was graded as continuous in 5 of 57 patients (8.8%) at first visit, which improved to 50 of 51 (98.0%) and 32 out of 51 (62.7%) at the final visit at 2 years, respectively (both $P < 0.001$). Hypoautofluorescent changes on fundus autofluorescence were present in 25 of 55 patients (45.5%) at baseline and in 23 of 51 patients (45.1%) at the final visit ($P = 0.480$).

Conclusion: In patients with chronic central serous chorioretinopathy who received a single, foveal, half-dose photodynamic therapy, a significant improvement in structure and function was seen at the final follow-up. None of the patients developed foveal atrophy.

RETINA 43:379–388, 2023

Central serous chorioretinopathy (CSC) is a chorioretinal disease primarily affecting middle-aged men.¹ It is characterized by the accumulation of subretinal fluid (SRF), often in the macula. Although the exact pathophysiologic assessment is still unknown, CSC is believed to be caused by hyperpermeability of the choroidal vessels, causing dysfunction of the retinal pigment epithelial (RPE) outer blood–retinal barrier and SRF accumulation.^{2,3} Central serous chorioretinopathy can roughly be categorized into acute and chronic CSC (cCSC), with acute CSC typically resolving spontaneously within several months. This is in contrast to

cCSC, in which persistence of SRF and more extensive retinal and choroidal abnormalities are seen, which may lead to subsequent central vision loss and decreased quality of life.⁴ Therefore, early treatment and diagnosis is important to prevent the loss of visual function.

Currently, the primary evidence-based treatment for cCSC is half-dose photodynamic therapy (PDT).^{1,5–7} This treatment uses the photosensitive drug verteporfin, that is administered intravenously, and induces a release of free oxygen radicals when activated by an infrared laser. The exact mechanism of PDT in the treatment of cCSC is still unclear, but the release of

these radicals are believed to cause choroidal vascular remodeling and may therefore lead to decreased choroidal hyperpermeability and may reduce fluid leakage into the subretinal space.¹

In general, half-dose PDT is regarded as a safe and effective treatment for CSC.^{1,8} Since the introduction of PDT, several PDT algorithms have been studied to find the optimal settings that lead to minimal side effects. Currently, half-dose PDT, which requires 3 mg/m² of verteporfin rather than 6 mg/m², is more

often used than full-dose PDT because this approach minimizes the already low risk of systemic side effects associated with verteporfin infusion.¹ An extremely rare but severe ocular complication that has been described after PDT is atrophy of the RPE.⁹ Of importance, this has been mostly described in relatively old studies in which patients had been treated with full-dose PDT rather than half-dose PDT.^{9–12} Despite the abundant number of studies on half-dose PDT in cCSC patients, there is still a striking worldwide variability in preferred treatment approaches for cCSC.^{13,14} In the case of PDT for cCSC, some ophthalmologists are still hesitant to include the fovea in the PDT treatment spot because of the presumed risk of foveal RPE atrophy development, although this potential risk has never been thoroughly assessed.^{1,14}

Recently, two large randomized controlled trials (RCTs) have demonstrated half-dose PDT to be an effective treatment for anatomical (inducing a complete SRF resolution on optical coherence tomography [OCT]) and functional parameters. First, the PLACE trial showed a superiority of half-dose PDT compared with high-density subthreshold micropulse laser treatment at 7 to 8 months after treatment for complete SRF resolution and retinal sensitivity on microperimetry.⁶ In addition, the SPECTRA trial concluded that half-dose PDT is markedly superior to oral eplerenone treatment in cCSC treatment, both as primary and as crossover treatment.^{5,15} In both the PLACE and SPECTRA trial, the fovea was allowed to be included in the half-dose PDT treatment spot, if necessary based on the hyperfluorescent abnormalities on indocyanine green angiography (ICGA). In this study, conducted with prospectively collected data from these two RCTs, we have evaluated the safety of half-dose PDT in which the fovea was included in the treatment spot, by reviewing multimodal imaging for signs of development of foveal RPE atrophy after treatment.

Methods

This study included data and multimodal imaging of cCSC patients enrolled in the multicenter randomized PLACE and SPECTRA studies.^{5,6} The PLACE trial was conducted at five academic medical centers in Europe. Eligible patients of the SPECTRA trial were enrolled at three academic medical centers in the Netherlands. The studies were conducted in accordance with the tenets of the Declaration of Helsinki, and all participating centers received approval from their respective institutional review board and ethics committee (clinicalTrials.gov identifier, NCT03079141 [PLACE trial]; NCT01797861 [SPECTRA trial]).

From the *Department of Ophthalmology, Leiden University Medical Center, Leiden, the Netherlands; †Department of Ophthalmology, Amsterdam University Medical Centers, Amsterdam, the Netherlands; ‡Department of Biomedical Data Sciences, Leiden University Medical Center, Leiden, the Netherlands; §Department of Ophthalmology, University Hospital of Cologne, Cologne, Germany; ¶F. Hoffmann-La Roche, Basel, Switzerland; **Department of Ophthalmology, Radboud University Medical Center, Nijmegen, the Netherlands; ††Oxford Eye Hospital, John Radcliffe Hospital, Oxford University Hospitals NHS Foundation Trust, Oxford, United Kingdom; ‡‡Nuffield Laboratory of Ophthalmology, Nuffield Department of Clinical Neuroscience, University of Oxford, Oxford, United Kingdom; and §§Department of Ophthalmology, University of Lausanne, Jules-Gonin Eye Hospital, Fondation Asile des Aveugles, Lausanne, Switzerland.

H. M. A. Feenstra was supported by the Blindenhulp Fellowship from Stichting Blindenhulp (The Hague, the Netherlands). This research was also supported by the following foundations: Stichting Ooglijders (Rotterdam, the Netherlands); Stichting Macula Fonds; Retina Nederland Onderzoek Fonds; Stichting Blinden-Penning; Algemene Nederlandse Vereniging ter Voorkoming van Blindheid; Landelijke Stichting voor Blinden en Slechtzienden, which contributed through UitZicht (Delft, the Netherlands); Rotterdamse Stichting Blindenbelangen (Rotterdam, the Netherlands); Stichting Leids Oogheelkundig Ondersteuningsfonds (Leiden, the Netherlands); the Oxford NIHR Biomedical Research Center (Oxford, United Kingdom); the Gisela Thier Fellowship of Leiden University (Leiden, the Netherlands [C. J. F. Boon]); and the Netherlands Organization for Scientific Research (VENI grant to C. J. F. Boon). These funding organizations provided unrestricted grants and had no role in the design or conduct of this research. This investigator-initiated study received funding from Novartis Pharma B.V. (Arnhem, the Netherlands) solely for the purchase of verteporfin (Visudyne) to enable half-dose photodynamic therapy treatment at the Oxford site because photodynamic therapy currently is not reimbursed routinely by the U.K. National Health Service for treating central serous chorioretinopathy. Novartis Pharma B.V. had no role in funding, designing, conducting, or evaluating the study, nor in the writing of this manuscript.

Paper presented at the Annual Macula Society Meeting 2022, Berlin, Germany.

S. Fauser is an employee of F. Hoffmann-La Roche. None of the authors has any financial/conflicting interests to disclose.

Supplemental digital content is available for this article. Direct URL citations appear in the printed text and are provided in the HTML and PDF versions of this article on the journal's Website (www.retinajournal.com).

This is an open access article distributed under the terms of the Creative Commons Attribution-Non Commercial-No Derivatives License 4.0 (CCBY-NC-ND), where it is permissible to download and share the work provided it is properly cited. The work cannot be changed in any way or used commercially without permission from the journal.

Reprint requests: Camiel J. F. Boon, MD, PhD, Department of Ophthalmology, Leiden University Medical Center, PO Box 9600, 2300 RC Leiden, the Netherlands; e-mail: camiel.boon@amsterdamumc.nl

Participants

Both the PLACE and SPECTRA trial enrolled adult previously untreated cCSC patients with foveal SRF at the baseline visit. Visual loss related to CSC was interpreted as the onset of disease and was required to be present for at least 6 weeks. Patients were excluded if continuous or progressive vision loss lasting >18 months or SRF on OCT lasting >18 months was present. In addition, one or more regions of active focal leakage together with RPE window defects on fluorescein angiography, as well as compatible hyperfluorescent changes typical of cCSC on ICGA, had to be present. This study included cCSC patients who had been treated in these two trials with half-dose PDT. Inclusion of the fovea in the PDT treatment spot at least partially was mandatory. For this study, the fovea was defined as an area of 1,500 μm in diameter centered on the foveal depression. Whether the PDT treatment spot included the fovea was determined by first using the Heidelberg built-in caliper tool to draw a circle with a diameter of 1,500 μm centered on central foveal depression on the infrared image, which corresponded to the enhanced-depth imaging spectral-domain OCT (Spectralis HRA + OCT Heidelberg Engineering GmbH, Heidelberg, Heidelberg Retina Angiograph, Germany) scan obtained at the baseline visit. This image was subsequently overlapped with the treatment plans for half-dose PDT that were depicted in Adobe Photoshop 21.1.1 (Adobe Inc, San Jose, CA) as part of both RCTs, to be able to establish whether the half-dose PDT treatment spot covered the central fovea either completely or partially, or not at all (Figure 1).

The inclusion and exclusion criteria of the PLACE and SPECTRA trials have previously been published.^{5,6} Additional exclusion criteria for this study included a second half-dose PDT or crossover treatment within the trial period, a follow-up period less than 8 months, and persistence of SRF on OCT at the follow-up visits after half-dose PDT because persistence of SRF may lead to atrophic retinal changes.

Procedures

At the baseline visit of both the PLACE and SPECTRA trial, demographics and medical history were taken, and an ophthalmologic examination and imaging were performed. This extensive ophthalmologic examination included best-corrected visual acuity in Early Treatment of Diabetic Retinopathy Study letters, and retinal and foveal sensitivity on microperimetry (Macular Integrity Assessment microperimetry, Centervue, Padova, Italy). Imaging included OCT scans, fundus autofluorescence, fundus photographs, fluorescein angiography, ICGA, and were made by certified medical photographers. Patients

were randomized to treatment with half-dose PDT or either eplerenone (SPECTRA trial) or high-density sub-threshold micropulse laser (PLACE trial). For half-dose PDT, the area to be treated was determined by the central reading center based on hyperfluorescent areas on ICGA compatible with SRF on OCT and leakage on fluorescein angiography.

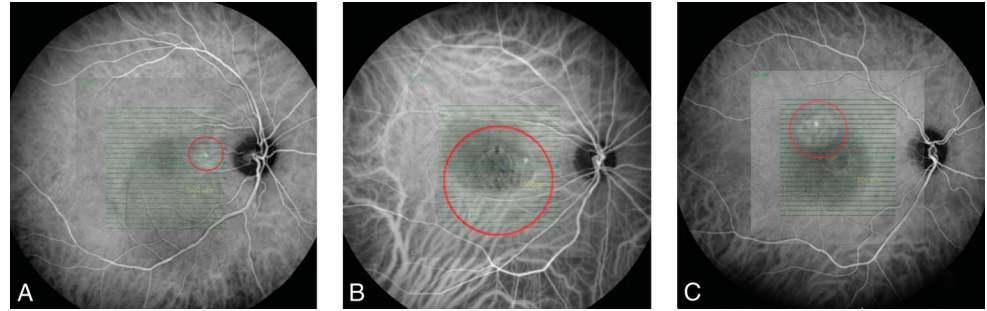
Before the start of the half-dose PDT, the pupil of the eye to be treated was dilated with topical 1.0% tropicamide and 2.5% phenylephrine. Afterward, 3 mg/m² body surface verteporfin (Visudyne; Novartis Pharma AG, Basel, Switzerland) was administered over 10 minutes through an intravenous drip. Fifteen minutes after the starting the verteporfin infusion, an anesthetic drop containing oxybuprocaine 0.4% was administered before placing a PDT contact lens ($\times 1.5$; Volk Optical, Mentor, OH) on the eye. Finally, half-dose PDT was performed in the target treatment area with a standard fluency of 50 J/cm², wavelength of 689 nm, and duration of 83 seconds.

At the first visit (6 weeks to 3 months after baseline and treatment) and at the 1-year visit (at 8–12 months after treatment), patients underwent ophthalmologic examination and imaging again. Data of the follow-up at 2 years after the baseline were also collected if present, in most cases, as a final follow-up in the trial setting, but also as a routine follow-up in the clinic.

Outcomes

The macular OCT scans that were taken at the baseline visit, first visit, 1-year visit, and 2-year visit were analyzed for this study. Different characteristics on the central macular cross-sectional OCT scan were assessed, both within the fovea and outside the fovea and included the following: presence of hyperreflective intraretinal foci (defined as small, well-circumscribed dot-shaped lesion, with equal or greater reflectivity than the RPE), integrity of the external limiting membrane (ELM), and ellipsoid zone (EZ). The ELM and EZ were graded as either “continuous”, “irregular”, or “indiscernible” (Figure 2). If the ELM or EZ was graded as irregular both at baseline and the last available follow-up, but still had improved or worsened significantly, this was also documented. Furthermore, the subfoveal choroidal thickness (distance from the outer part of the hyperreflective RPE layer to the hyperreflective line of the inner surface of the sclera) and central retinal thickness (distance from the internal limiting membrane [ILM] to the hyperreflective line of the EZ) were measured as described by van Rijssen et al.¹⁶ Finally, the presence of an increased penetrance of the OCT laser light into the choroid through an area of atrophic RPE was

Fig. 1. Assessment of the location of the half-dose PDT treatment spot and its relation to the fovea in cCSC patients. All images (A–C) comprise infrared images with the central foveal area, defined as a circle with a diameter of 1,500 μm centered on the central foveal depression, demarcated in yellow. The half-dose PDT treatment spot was depicted on this infrared image to determine the exact location of the treatment spot. On the first image (A), the half-dose PDT treatment spot did not overlap the fovea. On the second image (B), the PDT treatment spot completely included the fovea, whereas this was partially the case on the third image (C).



documented (“comet tail”; see **Supplemental Digital Content 1**, <http://links.lww.com/IAE/B870>).¹⁷

At all visits, fundus autofluorescence images were scored for the presence of hyperautofluorescence and hypoautofluorescence inside and outside the fovea. The diameter of 1,500 μm centered on the central foveal depression was again measured using the built-in Heidelberg caliper tool. At the baseline visit and first visit after treatment, fluorescein angiography and ICGA images were analyzed for the presence of a window defect and for the fluorescence in the fovea, respectively.

All scans were reviewed independently by two researchers (H.M.A.F. and M.J.C.M.L.). A referee (C.J.F.B.) was consulted in cases where their evaluations did not correspond. The main outcome measures of this study were decrease of the integrity of the ELM and EZ in the fovea and increase of hypoautofluorescence on fundus autofluorescence, indicating an increased risk of developing foveal atrophy.

Statistical Analysis

All statistical analyses were performed using IBM SPSS Statistics 25.0 (SPSS 25, IBM, New York, NY). A linear mixed model was used to compare all parameters between baseline and the 2-year visit

because of missing data at the 2-year visit. To compare the aspect of the ELM and EZ on OCT at baseline and 2-year visit, the outcome measures “irregular” and “indiscernible” were analyzed as one combined group and compared with the outcome “continuous” in a mixed effects binary logistic regression. In all performed tests, a *P* value of ≤ 0.05 was considered statistically significant (*P* ≤ 0.0033 after Bonferroni correction).

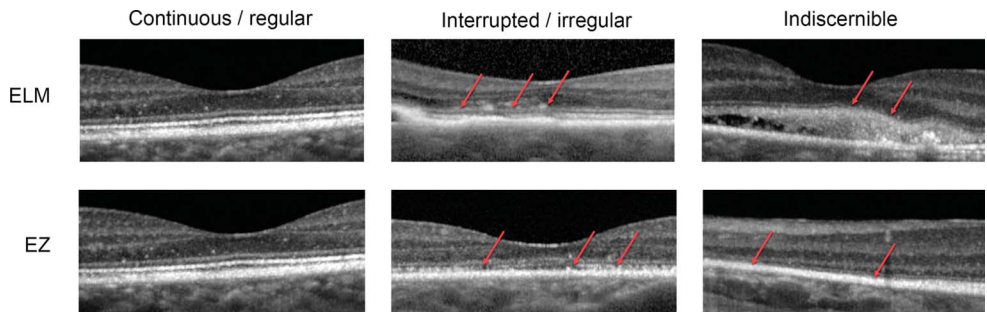
Results

Patients and Treatment

Of the 133 cCSC patients from SPECTRA and PLACE trials who were randomized to half-dose PDT between November 2013 and August 2019, 57 patients could be included in this study after applying the exclusion criteria (Figure 1). The mean age at enrollment in the trial in this group was 46.9 ± 9.6 years, with 50 (87.7%) of the patients being male. Other baseline characteristics are summarized in Table 1. The mean total follow-up time at the last available follow-up (either 1-year visit or 2-year visit) was 22.1 ± 3.9 months (range 8.1–27.6 months, *n* = 57).

The mean PDT laser spot size was 4466.7 μm (range 1,100–9,100 μm). In 32 of 57 patients (56.1%), the PDT

Fig. 2. Grading of the integrity of the ELM and EZ on the central macular cross-sectional OCT scan of cCSC patients. The integrity of the ELM and EZ were graded on the central macular cross-sectional OCT scan, both within the fovea (diameter of 1,500 μm centered on the central foveal depression) and outside the fovea. The EZ could only reliably be assessed after the complete resolution of SRF, at the first visit after half-dose PDT. The ELM and EZ were graded as “continuous” if it had a regular, normal aspect, and the term “irregular” was used when a part of the retinal layer was interrupted or had an irregular or thinned aspect. For the ELM of EZ to be graded as “indiscernible”, a substantial amount of the retinal layer should not be recognizable despite sufficient quality of the imaging.



“continuous” if it had a regular, normal aspect, and the term “irregular” was used when a part of the retinal layer was interrupted or had an irregular or thinned aspect. For the ELM of EZ to be graded as “indiscernible”, a substantial amount of the retinal layer should not be recognizable despite sufficient quality of the imaging.

spot covered the fovea completely, whereas in 25 of 57 patients (43.9%), the fovea was covered partially.

Optical Coherence Tomography Characteristics

At the baseline visit, the aspect of the subfoveal ELM was graded as “continuous” in 21 of 57 patients (36.8%), improving to 50 of 51 (98.0%) at the 2-year visit (<0.001) (Table 2 and Figure 3). This number was 33 of 57 (57.9%) at baseline and 41 of 51 (80.4%) at the 2-year visit for the extrafoveal ELM (<0.001). At the last available follow-up (either 1-year visit or 2-year visit), the subfoveal ELM had improved in 37 of 57 patients (64.9%) and had remained stable in 20 of 57 patients (35.1%). The aspect of the extrafoveal ELM had improved in 20 of 57 patients (35.1%), had remained stable in 36 of 57 (63.1%), and had worsened in 1 of 57 (1.8%).

The subfoveal EZ was first graded at first visit after half-dose PDT when complete SRF resolution had occurred and was considered “continuous” in 5 of 57 patients (8.8%), increasing to 32 of 51 patients (62.7%) at the 2-year visit (*P* < 0.001). The aspect of the EZ outside the fovea followed the same pattern, with 8 of 57 patients (14.0%) being graded as “continuous” at the first visit after PDT and with 29 of 51 patients (56.9%) at the 2-year visit (<0.001). At the last available follow-up, the subfoveal EZ had improved in 49 of 57 patients (86.0%) and had remained stable in 8 of 57 patients (14.0%). The extrafoveal EZ had improved in 42 of 57 (73.7%), had remained stable in 14 of 57 (24.6%), but had worsened slightly in one patient.

Variable degrees of hypoautofluorescence on fundus autofluorescence was observed in 25 of 55 patients

(45.5%) at the baseline visit (of whom, it was solely located in the fovea in eight patients) and in 23 of 51 patients (45.1%) at the 2-year visit (of whom, it was located in the fovea in only five patients). A very mild increase in preexistent foveal hypoautofluorescence was seen in four patients, which did not correspond to the PDT treatment spot (Figure 4).

Functional Outcomes

The mean best-corrected visual acuity of the study eyes at baseline was 80.8 ± 8.2 Early Treatment of Diabetic Retinopathy Study letters, increasing to 88.6 ± 5.4 at the 2-year visit (*P* < 0.001) (Table 2). At the baseline visit, the mean retinal sensitivity was 22.6 ± 4.2 decibel (dB), and this increased significantly to 27.3 ± 2.9 dB at the 2-year visit (*P* < 0.001). The foveal sensitivity also increased at the 2-year visit compared with the baseline visit (25.9 ± 3.6 dB and 19.7 ± 5.0 dB, respectively), although this was not significant after correction for multiple testing (*P* = 0.035).

Discussion

Half-dose or half-fluence PDT is considered the treatment of choice for cCSC, when available.^{1,14} Nevertheless, to date, some ophthalmologists still fear a risk of development of PDT-associated RPE atrophy in CSC. This study, conducted with data from two large RCTs that evaluated the safety of half-dose PDT with a treatment spot overlapping the fovea, showed no signs of possible development of foveal atrophy or vision loss after one application of half-dose PDT in any of the 57 patients after a mean follow-up of 22.1 months, even in patients who had preexistent atrophic RPE changes. On the contrary, apart from a high degree of SRF resolution after treatment, there was a significant improvement in the integrity of the ELM and EZ, as well as CRT, at the 2-year visit compared with the baseline visit. This marked structural improvement was associated with a significant increase in functional outcome (visual acuity and retinal sensitivity).

Foveal atrophy after treatment with PDT has been believed to be caused by choroidal hypoperfusion and choriocapillaris atrophy. Studies have shown that short-term choriocapillaris hypoperfusion may occur after treatment with PDT, before promoting choriocapillaris recovery, and reduced leakage.^{18,19} In neovascular age-related macular degeneration, some cases of choroidal ischemia after PDT using standard treatment settings (6 mg/m² verteporfin) have been described in the past.^{20,21} However, overall, in neovascular age-

Table 1. Baseline Characteristics of Patients Included in this Study

Eyes (n)	57
Age (years)	46.9 ± 9.6
Male gender	50/57 (87.7%)
BCVA in study eyes (ETDRS letters)	80.8 ± 8.2 (n = 57)
BCVA in fellow eyes (ETDRS letters)	89.2 ± 6.8 (n = 57)
Retinal sensitivity study eyes on microperimetry (dB)	22.6 ± 4.2 (n = 54)
Foveal sensitivity study eyes on microperimetry (dB)	19.7 ± 5.0 (n = 54)
Retinal sensitivity fellow eyes on microperimetry (dB)	27.7 ± 2.9 (n = 54)
Foveal sensitivity fellow eyes on microperimetry (dB)	26.3 ± 3.4 (n = 54)

Data are either n (%), or mean ± SD. BCVA, best-corrected visual acuity; dB, decibel; ETDRS, Early Treatment of Diabetic Retinopathy Study; PED, pigment epithelial detachment.

Downloaded from http://journals.lww.com/retinajournal by BhdMfsePHkav1zEoun1tQJN4a+KLLHEZqbslHo4XWl0 hOwWCX1AWNjXopI/QHhD3i3DD0dRvITV5F14C13VCA/OA1pDda8KkGK1V07my+78= on 04/29/2024

Table 2. Clinical and Multimodal Imaging Characteristics of cCSC Patients During Follow-up After Treatment With Half-Dose PDT

	Baseline Visit (n = 57)	First Visit After Half-Dose PDT (n = 57)	1-Year Visit (n = 57)	2-Year Visit (n = 51)	P*
<i>Clinical characteristics</i>					
BCVA (ETDRS)	80.8 ± 8.2 (n = 57)	86.4 ± 6.3 (n = 57)	87.5 ± 7.5 (n = 57)	88.6 ± 5.4 (n = 51)	<0.001
Retinal sensitivity on microperimetry (dB)	22.6 ± 4.2 (n = 54)	25.5 ± 3.2 (n = 56)	26.5 ± 3.4 (n = 56)	27.3 ± 2.9 (n = 47)	<0.001
Foveal sensitivity on microperimetry (dB)	19.7 ± 5.0 (n = 54)	24.4 ± 4.2 (n = 55)	25.6 ± 3.9 (n = 56)	25.9 ± 3.6 (n = 36)	0.035
<i>OCT characteristics</i>					
SFCT (μm)	380.7 ± 73.2 (n = 41)	325.1 ± 77.4 (n = 46)	325.6 ± 86.1 (n = 49)	302.0 ± 80.9 (n = 43)	0.001
CRT (μm)	109.5 ± 20.1 (n = 57)	117.2 ± 23.5 (n = 57)	122.6 ± 23.1 (n = 57)	129.9 ± 37.3 (n = 51)	0.001
Presence of hyperreflective foci at fovea	37/57 (64.9%)	29/57 (50.9%)	25/57 (43.9%)	20/51 (39.2%)	0.002
Presence of "comet tail" ELM normal under central foveal depression	5/57 (8.8%)	5/57 (8.8%)	3/57 (5.3%)	3/51 (5.9%)	0.251
Aspect of subfoveal ELM	43/57 (75.4%)	52/57 (91.2%)	56/57 (98.2%)	51/51 (100%)	<0.001
Aspect of subfoveal ELM					
Continuous/regular	n = 57 21 (36.8%)	n = 57 49 (86.0%)	n = 57 56 (98.2%)	n = 51 50 (98.0%)	<0.001
Irregular	34 (59.6%)	8 (14.0%)	1 (1.8%)	1 (2.0%)	
Indiscernible	2 (3.5%)	0 (0%)	0 (0%)	0 (0%)	
Aspect ELM outside fovea					
Continuous/regular	n = 57 33 (57.9%)	n = 57 43 (75.4%)	n = 57 46 (80.7%)	n = 51 41 (80.3%)	<0.001
Irregular	24 (42.1%)	14 (24.6%)	10 (17.5%)	10 (19.6%)	
Indiscernible	0 (0%)	0 (0%)	1 (1.8%)	0 (0%)	
EZ normal under central foveal depression	N/A	37/57 (64.9%)	53/57 (93.0%)	47/51 (92.2%)	0.028
Aspect subfoveal EZ					
Continuous/regular	N/A	n = 57 5 (8.8%)	n = 57 30 (52.6%)	n = 51 32 (62.7%)	<0.001
Irregular	N/A	52 (91.2%)	27 (47.4%)	19 (37.3%)	
Indiscernible	N/A	0 (0%)	0 (0%)	0 (0%)	
Aspect EZ outside fovea					
Continuous/regular	N/A	n = 57 8 (14.0%)	n = 57 25 (43.9%)	n = 51 29 (56.9%)	<0.001
Irregular	N/A	46 (80.7%)	30 (52.6%)	20 (39.2%)	
Indiscernible	N/A	3 (5.3%)	2 (3.5%)	2 (3.9%)	
<i>FAF characteristics</i>					
Hypofluorescence	25/55 (45.5%)	25/57 (43.9%)	25/56 (44.6%)	23/51 (45.1%)	0.480
Located in the fovea					
Located only outside the fovea	8 17	8 17	4 21	5 18	
Hyperfluorescence	45/55 (81.8%)	48/57 (84.2%)	44/56 (78.6%)	40/51 (78.4%)	0.777
Located in the fovea					
Located only outside the fovea	29 16	30 18	24 20	23 17	
<i>FA characteristics</i>					
Window defect	1/57 (1.8%)	1/57 (1.8%)	N/A	N/A	N/A
Located in the fovea					
	0/1 (0%)	0/1 (0%)	N/A	N/A	
<i>ICGA characteristics</i>					
Fluorescence in the fovea	n = 57	n = 56	N/A	N/A	N/A
Normal					
Hypofluorescence	11 (19.3%)	15 (26.8%)	N/A	N/A	
Hyperfluorescence	5 (8.8%)	7 (12.5%)	N/A	N/A	
Hyperfluorescence and hypofluorescence	13 (22.8%)	6 (10.7%)	N/A	N/A	
	28 (49.1%)	28 (50.0%)	N/A	N/A	

Quantitative outcome measures are expressed as mean ± SD.

*A linear mixed model was used to compare the parameters between baseline and the 2-year visit, apart from the aspect of the EZ, in which the first visit after PDT was compared with the 2-year visit. A P value of 0.05 was considered significant ($P < 0.0033$ after Bonferroni correction; statistically significant P-values are presented in bold).

BCVA, best-corrected visual acuity; CRT, central retinal thickness; dB, decibel; ETDRS, Early Treatment of Diabetic Retinopathy Study; FA, fluorescein angiography; FAF, fundus autofluorescence; POS, photoreceptor outer segments; SFCT, subfoveal choroidal thickness.

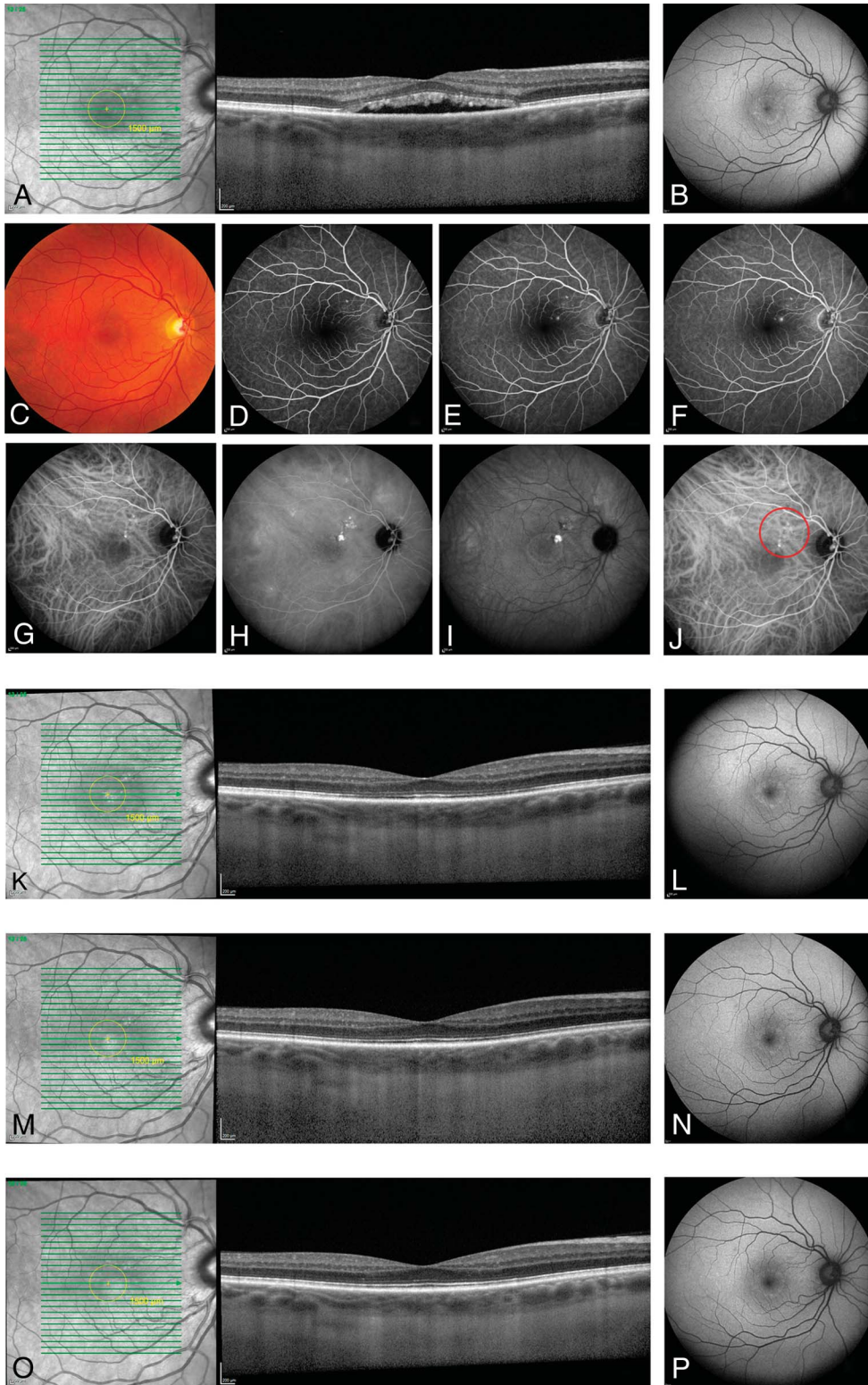


Fig. 3. Example of a cCSC patient treated with half-dose PDT, in which the PDT treatment spot partially overlapped the fovea. At the baseline visit (A–I), SRF was present under the fovea, which was visible on the OCT (A) scan and on fundus photography (C). The FAF (B) image showed parafoveal hyperautofluorescence. One focal leakage point was visible on fluorescein angiography (D–F, early, mid, and late phase, respectively). Multifocal hyperfluorescent lesions with an indistinct border that are characteristic of cCSC were present on indocyanine green angiography (G and I, early-, mid-, and late-phase, respectively). After the baseline visit, half-dose PDT was performed based on the hyperfluorescent lesions on ICGA. The red circle presents the half-dose PDT treatment spot (J). At the subsequent visit at 3 months after the treatment, the SRF on OCT had disappeared (K), and parafoveal hyperautofluorescent areas on FAF had remained stable (L). At the 1-year visit, the subfoveal ELM and EZ on OCT had improved compared with the baseline visit and compared with first visit after the treatment (M), and hyperautofluorescent changes on FAF had decreased (N). Finally, at the 2-year visit after half-dose PDT, the structure of the subfoveal ELM and EZ on OCT had improved compared with baseline, with a significant thicker aspect of both layers (O). The parafoveal hyperautofluorescent changes on FAF had decreased but was still present (P). FAF, fundus autofluorescence.

related macular degeneration, the risk of PDT-associated choroidal ischemia and RPE atrophy was low, despite the use of one or more PDT treatments

with standard settings in this elderly population with often a preexisting thin choroid and diseased RPE.^{22,23} The reason why choroidal ischemia and RPE atrophy

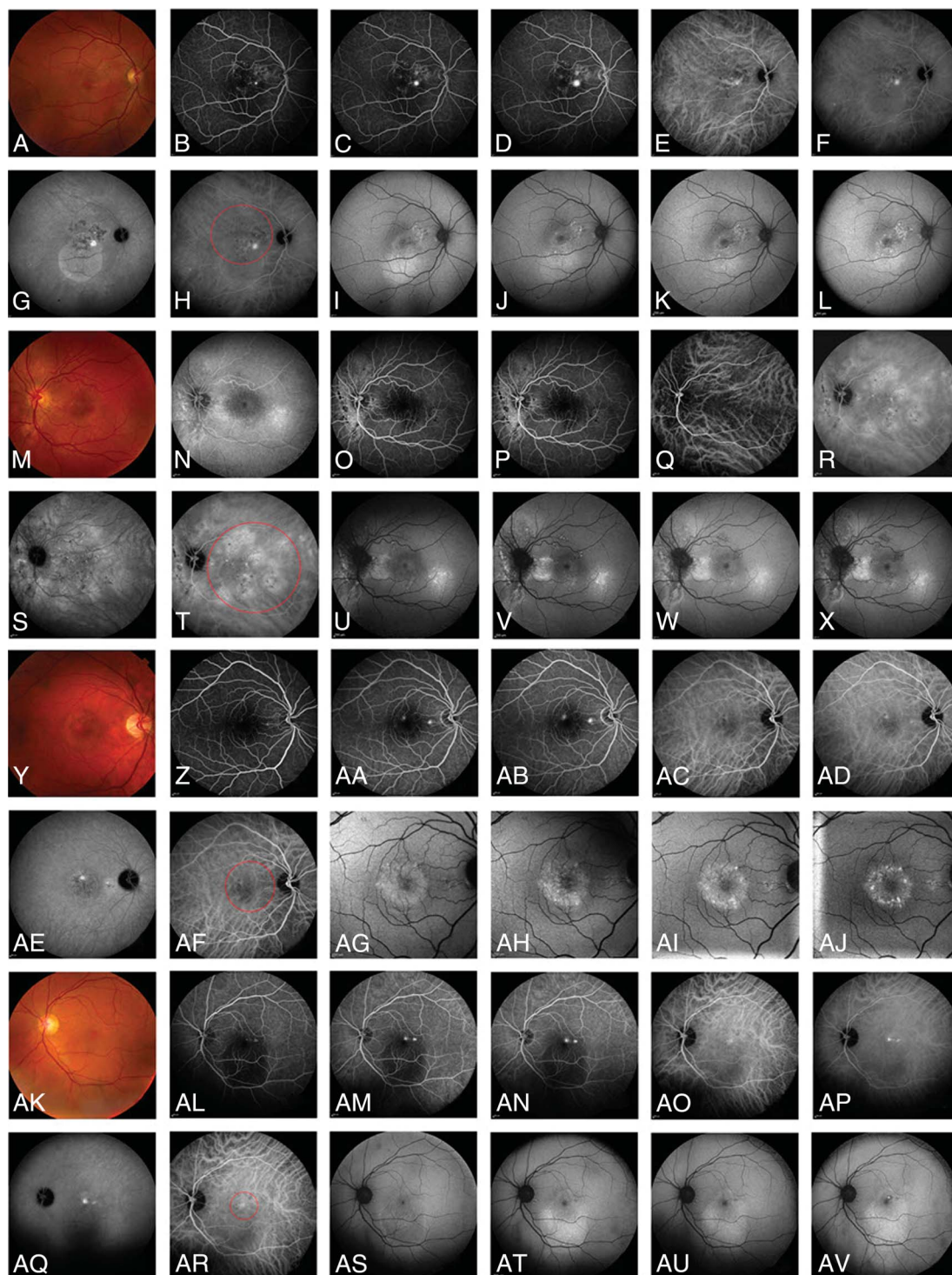


Fig. 4. Multimodal imaging of four cCSC patients who had a very mild increase in foveal hypoautofluorescence on FAF after half-dose PDT. Multimodal imaging of four patients included this study who had a very mild increase in preexisting foveal hypoautofluorescence on FAF after half-dose PDT: Patient 1 (A–L), Patient 2 (M–X), Patient 3 (Y–AJ), and Patient 4 (AK–AV). Multimodal imaging at the baseline visit included (in order of appearance): Fundus photography (A, M, Y, and AK), early phase (B, N, Z, and AL), mid phase (C, O, AA, and AM), and late-phase FA (D, P, AB, and AN), and early phase (E, Q, AC, and AO), mid phase (F, R, AD, and AP), and late-phase indocyanine green angiography (G, S, AE, and AQ), half-dose PDT treatment spot (red circle; H, T, AF, and AR), and fundus autofluorescence (I, U, AG, and AS). In addition, the FAF images were taken at first visit after PDT (J, V, AH, and AT), at 1-year visit (K, W, AI, and AU), and at 2-year visit (L, X, AJ, and AV). An increase in preexisting foveal hypoautofluorescence on FAF can be seen comparing I–L (Patient 1), U–X (Patient 2), AG–AJ (Patient 3), and AS–AV (Patient 4). FA, fluorescein angiography; FAF, fundus autofluorescence.

after half-dose PDT in cCSC is extremely rare probably lies in the fact that the choroid in CSC shows significant thickening (“pachychoroid”) and leakage on OCT and ICGA, which are the hallmark features that lie at the basis of CSC.^{11,24} PDT seems to be able to address these primary underlying choroidal abnormalities in CSC by unknown mechanisms, reducing the choroidal thickness to a closer-to-normal level and decreasing choroidal leakage.²⁵ The risk of adverse events such as RPE atrophy are also minimized through the use of reduced settings such as half-dose verteporfin compared with standard setting (3 mg/m² verteporfin vs. 6 mg/m²). Still, PDT with standard settings also seems to have an excellent safety profile in cCSC, even in full-dose PDT.^{26,27} This might explain why foveal atrophy following half-dose did not occur in our study population of cCSC patients because these patients had a relatively large mean SFCT of $380.7 \pm 73.2 \mu\text{m}$.

The results of this study therefore further support the use and safety of half-dose PDT to treat cCSC.^{1,5} Furthermore, in this study, the foveal integrity of the EZ and ELM improved significantly after half-dose PDT in many patients and, importantly, no patients experienced a deterioration in the aspect of these retinal layers. It should be noted that atrophic RPE changes are part of the natural course of cCSC, which may be induced by prolonged separation of the neuroretinal layers and choroidal dysfunction, for instance, because adequate treatment such as PDT are postponed.²⁸ Moreover, a previous study by van Rijssen et al²⁹ showed that half-dose PDT in cCSC patients with pre-existing fovea-involving atrophy is less likely to lead to functional improvements. Therefore, inducing complete SRF resolution using half-dose PDT is likely to prevent additional damage to photoreceptors and subsequent persistent and severe visual complaints, while also reducing the risk of recurrences.^{29,30}

Our study has several strengths. First, this study used prospectively collected data from two large RCTs, which resulted in a relatively large study population with extensive multimodal imaging. Second, most patients had a relatively long follow-up (mean of 22.1 months). Finally, all multimodal imaging was evaluated by two independent graders. The study also has limitations. First, the integrity of the EZ and the ELM was graded on a single horizontal OCT scan instead of the complete fovea, to facilitate the comparison between these measurements at different visits. Second, we did not include patients who had received crossover treatment with either oral eplerenone or high-density subthreshold micropulse laser treatment, to enable us to study solely the effect of half-dose PDT on the retina, which may have caused some selection bias. In addition,

our study did not include an untreated control group to compare the development of foveal atrophy in cCSC patients without treatment with half-dose PDT, as a part of the natural progression of this disease.²⁸ This could be a topic of future studies, especially in a period in which verteporfin shortage is present, or in countries where PDT is unavailable.¹⁴ Future studies could also include detailed imaging of the choroidal vascularity and perfusion changes on ICGA. Finally, it would be informative to review the imaging of cCSC patients who have received fovea-involving PDT more than once.

In conclusion, patients who received a single fovea-involving half-dose PDT for cCSC in two RCTs not only had a high probability of complete SRF resolution but also showed marked improvement in outer retinal structures. This was accompanied by significant improvement in best-corrected visual acuity and retinal sensitivity. None of the patients showed signs of developing atrophic RPE changes on OCT after a follow-up of 22 months. A single session of foveal half-dose PDT was safe and effective in this study of cCSC patients, and therefore, it has to be considered the treatment of choice.

Key words: adverse event, chronic central serous chorioretinopathy, chorioretinal atrophy, foveal atrophy, fundus autofluorescence, optical coherence tomography, photodynamic therapy.

References

1. van Rijssen TJ, van Dijk EHC, Yzer S, et al. Central serous chorioretinopathy: towards an evidence-based treatment guideline. *Prog Retin Eye Res* 2019;73:100770.
2. Spaide RF, Gemmy Cheung CM, Matsumoto H, et al. Venous overload choroidopathy: a hypothetical framework for central serous chorioretinopathy and allied disorders. *Prog Retin Eye Res* 2022;86:100973.
3. Brinks J, van Dijk EHC, Meijer OC, et al. Choroidal arteriovenous anastomoses: a hypothesis for the pathogenesis of central serous chorioretinopathy and other pachychoroid disease spectrum abnormalities. *Acta Ophthalmol* 2022;100:946–959.
4. Breukink MB, Dingemans AJ, den Hollander AI, et al. Chronic central serous chorioretinopathy: long-term follow-up and vision-related quality of life. *Clin Ophthalmol* 2016;11:39–46.
5. van Rijssen TJ, van Dijk EHC, Tsonaka R, et al. Half-dose photodynamic therapy versus eplerenone in chronic central serous chorioretinopathy (SPECTRA): a randomized controlled trial. *Am J Ophthalmol* 2022;233:101–110.
6. van Dijk EHC, Fauser S, Breukink MB, et al. Half-dose photodynamic therapy versus high-density subthreshold micropulse laser treatment in patients with chronic central serous chorioretinopathy: the PLACE trial. *Ophthalmology* 2018; 125:1547–1555.
7. Lotery A, Sivaprasad S, O’Connell A, et al. Eplerenone for chronic central serous chorioretinopathy in patients with active, previously untreated disease for more than 4 months (VICI): a randomised, double-blind, placebo-controlled trial. *Lancet* 2020;395:294–303.

8. van Dijk EHC, van Rijssen TJ, Subhi Y, Boon CJF. Photodynamic therapy for chorioretinal diseases: a practical approach. *Ophthalmol Ther* 2020;9:329–342.
9. Lee PY, Kim KS, Lee WK. Severe choroidal ischemia following photodynamic therapy for pigment epithelial detachment and chronic central serous chorioretinopathy. *Jpn J Ophthalmol* 2009;53:52–56.
10. Piccolino FC, Eandi CM, Ventre L, et al. Photodynamic therapy for chronic central serous chorioretinopathy. *Retina* 2003;23:752–763.
11. Koytak A, Erol K, Coskun E, et al. Fluorescein angiography-guided photodynamic therapy with half-dose verteporfin for chronic central serous chorioretinopathy. *Retina* 2010;30:1698–1703.
12. Reibaldi M, Cardascia N, Longo A, et al. Standard-fluence versus low-fluence photodynamic therapy in chronic central serous chorioretinopathy: a nonrandomized clinical trial. *Am J Ophthalmol* 2010;149:307–315 e2.
13. Mehta PH, Meyerle C, Sivaprasad S, et al. Preferred practice pattern in central serous chorioretinopathy. *Br J Ophthalmol* 2017;101:587–590.
14. Sirks MJ, van Dijk EHC, Rosenberg N, et al. Clinical impact of the worldwide shortage of verteporfin (Visudyne®) on ophthalmic care. *Acta Ophthalmol* 2022;100:e1522–e1532.
15. Feenstra HMA. Crossover to half-dose photodynamic therapy or eplerenone in chronic central serous chorioretinopathy patients (SPECS). *Ophthalmol Retina* 2022;6:930–938.
16. van Rijssen TJ, Mohabati D, Dijkman G, et al. Correlation between redefined optical coherence tomography parameters and best-corrected visual acuity in non-resolving central serous chorioretinopathy treated with half-dose photodynamic therapy. *PLoS One* 2018;13:e0202549.
17. Schutze C, Wedl M, Baumann B, et al. Progression of retinal pigment epithelial atrophy in antiangiogenic therapy of neovascular age-related macular degeneration. *Am J Ophthalmol* 2015;159:1100–1114 e1.
18. Ho M, Lai FHP, Ng DSC, et al. Analysis of choriocapillaris perfusion and choroidal layer changes in patients with chronic central serous chorioretinopathy randomised to micropulse laser or photodynamic therapy. *Br J Ophthalmol* 2021;105:555–560.
19. Nassisi M, Lavia C, Alovisei C, et al. Short-term choriocapillaris changes in patients with central serous chorioretinopathy after half-dose photodynamic therapy. *Int J Mol Sci* 2017;2018:2468.
20. Rishi P, Kasinathan N, Sahu C. Foveal atrophy and macular hole formation following intravitreal ranibizumab with/without photodynamic therapy for choroidal neovascularization secondary to age-related macular degeneration. *Clin Ophthalmol* 2011;5:167–170.
21. Wachtlin J, Behme T, Heimann H, et al. Concentric retinal pigment epithelium atrophy after a single photodynamic therapy. *Graefes Arch Clin Exp Ophthalmol* 2003;241:518–521.
22. Bressler NM, Treatment of Age-Related Macular Degeneration with Photodynamic Therapy TAP Study Group. Photodynamic therapy of subfoveal choroidal neovascularization in age-related macular degeneration with verteporfin: two-year results of 2 randomized clinical trials-tap report 2. *Arch Ophthalmol* 2001;119:198–207.
23. Gattoussi S, Cougnard-Gregoire A, Korobelnik JF, et al. Choroidal thickness, vascular factors, and age-related macular degeneration: the ALIENOR Study. *Retina* 2019;39:34–43.
24. Cheung CMG, Lee WK, Koizumi H, et al. Pachychoroid disease. *Eye (Lond)* 2019;33:14–33.
25. Maruko I, Iida T, Sugano Y, et al. Subfoveal choroidal thickness after treatment of central serous chorioretinopathy. *Ophthalmology* 2010;117:1792–1799.
26. Vasconcelos H, Marques I, Santos AR, et al. Long-term chorioretinal changes after photodynamic therapy for chronic central serous chorioretinopathy. *Graefes Arch Clin Exp Ophthalmol* 2013;251:1697–1705.
27. Silva RM, Ruiz-Moreno JM, Gomez-Ulla F, et al. Photodynamic therapy for chronic central serous chorioretinopathy: a 4-year follow-up study. *Retina* 2013;33:309–315.
28. Wang MS, Sander B, Larsen M. Retinal atrophy in idiopathic central serous chorioretinopathy. *Am J Ophthalmol* 2002;133:787–793.
29. van Rijssen TJ, van Dijk EHC, Scholz P, et al. Outcome of half-dose photodynamic therapy in chronic central serous chorioretinopathy with fovea-involving atrophy. *Graefes Arch Clin Exp Ophthalmol* 2021;259:905–910.
30. Rijssen TJ, Dijk EHC, Scholz P, et al. Long-term follow-up of chronic central serous chorioretinopathy after successful treatment with photodynamic therapy or micropulse laser. *Acta Ophthalmol* 2021;99:805–811.