



**Universiteit  
Leiden**  
The Netherlands

## **Early recognition of characteristic conventional and amplitude-integrated EEG patterns of seizures in SCN2A and KCNQ3-related epilepsy in neonates**

Pijpers, J.A.; Au, P.Y.B.; Weeke, L.C.; Vein, A.A.; Smit, L.S.; Vilan, A.; ... ; Peeters-Scholte, C.M.P.C.D.

### **Citation**

Pijpers, J. A., Au, P. Y. B., Weeke, L. C., Vein, A. A., Smit, L. S., Vilan, A., ... Peeters-Scholte, C. M. P. C. D. (2023). Early recognition of characteristic conventional and amplitude-integrated EEG patterns of seizures in SCN2A and KCNQ3-related epilepsy in neonates. *Seizure - European Journal Of Epilepsy*, 110, 212-219. doi:10.1016/j.seizure.2023.06.016

Version: Publisher's Version

License: [Creative Commons CC BY 4.0 license](#)

Downloaded from: <https://hdl.handle.net/1887/3748073>

**Note:** To cite this publication please use the final published version (if applicable).



Contents lists available at ScienceDirect

## Seizure: European Journal of Epilepsy

journal homepage: [www.elsevier.com/locate/seizure](http://www.elsevier.com/locate/seizure)

## Early recognition of characteristic conventional and amplitude-integrated EEG patterns of seizures in *SCN2A* and *KCNQ3*-related epilepsy in neonates

Judith A. Pijpers<sup>a,\*</sup>, Ping Yee Billie Au<sup>c</sup>, Lauren C. Weeke<sup>e</sup>, Alla A. Vein<sup>a</sup>, Liesbeth S. Smit<sup>e,f</sup>, Ana Vilan<sup>g</sup>, Elke Jacobs<sup>f</sup>, Linda S. de Vries<sup>b</sup>, Sylke J. Steggerda<sup>b</sup>, Maria Roberta Cilio<sup>h</sup>, Evelina Carapancea<sup>h</sup>, Marie-Coralie Cornet<sup>i</sup>, Juan P. Appendino<sup>d,#</sup>, Cacha M.P.C.D. Peeters-Scholte<sup>a,#</sup>

<sup>a</sup> Departments of Neurology and Clinical Neurophysiology, Leiden University Medical Center, PO Box 9600, Leiden 2300 RC, the Netherlands

<sup>b</sup> Departments of Neonatology, Leiden University Medical Center, the Netherlands

<sup>c</sup> Departments of Medical Genetics, Cumming School of Medicine, University of Calgary, Canada

<sup>d</sup> Departments of Pediatric Neurology, Cumming School of Medicine, University of Calgary, Canada

<sup>e</sup> Departments of Neonatology, Erasmus Medical Center, the Netherlands

<sup>f</sup> Departments of Neurology, Erasmus Medical Center, the Netherlands

<sup>g</sup> Department of Neonatology, Centro Hospitalar Universitário São João, Faculty of Medicine, University of Porto, Portugal

<sup>h</sup> Division of Pediatric Neurology, Department of Pediatrics, Catholic University of Louvain, Brussels, Belgium

<sup>i</sup> Division of Neonatology, Department of Pediatrics, Benioff Children's Hospital, University of California, San Francisco, CA, USA

## ARTICLE INFO

## Keywords:

Neonates

Seizures

Channelopathy

EEG

Precision treatment

Anti-seizure medication

Amplitude-integrated EEG

*KCNQ2**KCNQ3**SCN2A*

## ABSTRACT

**Purpose:** Early recognition of seizures in neonates secondary to pathogenic variants in potassium or sodium channel coding genes is crucial, as these seizures are often resistant to commonly used anti-seizure medications but respond well to sodium channel blockers. Recently, a characteristic ictal amplitude-integrated electroencephalogram (aEEG) pattern was described in neonates with *KCNQ2*-related epilepsy. We report a similar aEEG pattern in seizures caused by *SCN2A*- and *KCNQ3*-pathogenic variants, as well as conventional EEG (cEEG) descriptions.

**Methods:** International multicentre descriptive study, reporting clinical characteristics, aEEG and cEEG findings of 13 neonates with seizures due to pathogenic *SCN2A*- and *KCNQ3*-variants. As a comparison group, aEEGs and cEEGs of neonates with seizures due to hypoxic-ischemic encephalopathy ( $n = 117$ ) and other confirmed genetic causes affecting channel function ( $n = 55$ ) were reviewed.

**Results:** In 12 out of 13 patients, the aEEG showed a characteristic sequence of brief onset with a decrease, followed by a quick rise, and then postictal amplitude attenuation. This pattern correlated with bilateral EEG onset attenuation, followed by rhythmic discharges ending in several seconds of post-ictal amplitude suppression. Apart from patients with *KCNQ2*-related epilepsy, none of the patients in the comparison groups had a similar aEEG or cEEG pattern.

**Discussion:** Seizures in *SCN2A*- and *KCNQ3*-related epilepsy in neonates can usually be recognized by a characteristic ictal aEEG pattern, previously reported only in *KCNQ2*-related epilepsy, extending this unique feature to other channelopathies. Awareness of this pattern facilitates the prompt initiation of precision treatment with sodium channel blockers even before genetic results are available.

## 1. Introduction

In neonates, most seizures are attributable to acquired non-genetic causes, including hypoxic-ischemic encephalopathy (HIE), vascular

events or infectious diseases. A considerable subgroup, however, has a genetic basis. Many epilepsy-related genes encode ion channels, and epilepsies caused by pathogenic variants in this group are often referred to as channelopathies [1–3]. Many of the channelopathies-related

\* Corresponding author.

E-mail address: [j.a.pijpers@lumc.nl](mailto:j.a.pijpers@lumc.nl) (J.A. Pijpers).

# Equally shared senior authorship.

<https://doi.org/10.1016/j.seizure.2023.06.016>

Received 18 February 2023; Received in revised form 30 May 2023; Accepted 19 June 2023

Available online 22 June 2023

1059-1311/© 2023 The Author(s). Published by Elsevier Ltd on behalf of British Epilepsy Association. This is an open access article under the CC BY license (<http://creativecommons.org/licenses/by/4.0/>).

epilepsies are associated with defects of voltage-gated sodium, potassium or calcium channels. Neonatal-onset epilepsies due to channelopathies are most frequently caused by mutations in the *KCNQ2* and *SCN2A* genes, and to a lesser extent in the *KCNQ3* gene [4–6]. Variants in these genes are now known to be associated with a spectrum of phenotypes, ranging from self-limited (familial) neonatal epilepsy to severe neonatal epilepsy syndromes, including developmental and epileptic encephalopathy (DEE) [7,8]. Accordingly, the prognosis regarding seizure control also comprises a wide spectrum, from self-limited or well-controlled to drug-resistant seizures [9].

Seizures associated with these channelopathies are typically less responsive to common first choice anti-seizure medications (ASMs), such as phenobarbital and benzodiazepines. However, the administration of sodium channel blockers, including oxcarbazepine, carbamazepine, phenytoin, and lidocaine can provide seizure freedom or a significant reduction in the majority of neonates [8,10]. As a lower seizure burden may be associated with better developmental outcome, regardless of the etiology or severity of neurological illness [11], a sodium channel blocker should be initiated as soon as possible when a channelopathy, particularly due to *KCNQ2*, *KCNQ3*, or *SCN2A* gene defect, is suspected [8,10,12]. This emphasizes the critical need for early recognition of this disorder to ensure adequate early seizure control in both the self-limited and severe phenotypes.

Recognition of *KCNQ2*, *KCNQ3* and *SCN2A*-associated epilepsy can be based on seizure semiology, typically comprising asymmetric tonic posturing, associated apnea and desaturation, often followed by unilateral or bilateral asynchronous clonic jerks [7,8]. However, distinction with seizures due to other aetiologies solely based on clinical semiology may be difficult. Recently, seizures in *KCNQ2*-related epilepsy in neonates were shown to have a characteristic pattern on the amplitude-integrated EEG (aEEG) with a sudden rise in amplitude, followed by a marked prolonged postictal attenuation [13]. This unique aEEG pattern can be quickly recognised by neonatologists at the bedside [13]. In our descriptive study of thirteen newborns with *SCN2A* and *KCNQ3*-related epilepsy, we demonstrate a similar pattern on the aEEG and cEEG, extending this unique feature to other channelopathies. These features, in combination with clinical semiology may allow for early recognition, not only by the bedside team but also by the neurology, neurophysiology, and genetic team.

## 2. Methods

This is a retrospective, descriptive case series of 13 neonates with seizures secondary to confirmed (likely) pathogenic *SCN2A* or *KCNQ3* variants from five different centers ((Leiden University Medical Center, the Netherlands (LUMC); Erasmus Medical Center, the Netherlands (EMC); Alberta Children's Hospital in Calgary, Canada (ACH); Benioff Children's Hospital, University of California, San Francisco (USCF); Hospital São João in Porto, Portugal (HSJ)). Patients were included consecutively in each center. All patients were admitted to their respective Neonatal Intensive Care Units (NICUs) because of seizure onset between January 1, 2013 and October 31, 2021. All individuals identified within this time frame at the participating institutions had been offered standard of care clinical genetic testing in case of unknown etiology of seizures, and all individuals with a likely pathogenic or pathogenic variant in *SCN2A* and *KCNQ3* were included. In each center, a complete clinical assessment was performed, including detailed physical examination and family history. Extensive diagnostic work-up, including a brain MRI, investigations for infections (blood, urine and CSF culture), and metabolic disorders (including CSF, blood and urine analysis) were performed in all patients. Only patient 12 did not have a brain MRI. Continuous brain function monitoring was carried out as per local protocols in each center. At LUMC, continuous aEEG monitoring was performed routinely, using a 2-channel digital device (F3-P3, F4-P4) in patients 1–3 (NicoletOne, Natus System, Pleasanton, CA, USA). Restricted 10–20 system bipolar EEG, including eleven electrodes Fp1,

Fp2, T3, T4, T7, T8, C3, C4, Cz, O1, O2, was completed for at least one hour in all patients using EEG-1200, Nihon Kohden, Tokyo, Japan. At EMC, patients 4 and 5 were continuously monitored with a 2-channel (F3-P3, F4-P4) aEEG monitor (Brainz BRM3 Brain Monitor, Natus System, San Carlos, CA, USA). At ACH, patients 6–8 and 10–11 were continuously monitored with conventional 11-electrodes restricted 10–20 neonatal EEG montage including the following leads Fp1, Fp2, C3, C4, T7, T8, O1, O2, Pz, Cz, Fz (NeuroWorks – Natus System. Persyst 12 software. Natus, Pleasanton, CA, USA). At UCSF neonates were monitored with continuous video-EEG using a Nicolet One vEEG system (patient 9) or Natus Networks system (patient 12); both using a total of nine electrodes including Fp1, Fp2, C3, C4, T7, T8, O1, O2, and Cz. At HSJ, patient 13 was continuously monitored with a 2-channel digital device (F3 - P3, F4 - P4) (NicoletOne, Natus System, Pleasanton, CA, USA). Rapid trio whole exome sequencing or comprehensive epilepsy gene panel diagnostics was performed in all patients via clinical laboratories. Where possible, variants were clinically segregated in parents to determine inheritance. All variants were reviewed for pathogenicity according to ACMG criteria [14].

To assess whether the described (a)EEG findings are specific for *KCNQ2*-, *KCNQ3*- and *SCN2A*-related epilepsy, aEEGs and cEEGs of two comparison groups were reviewed, all patients meeting criteria within the defined time frame: i) neonates with seizures due to HIE, treated with therapeutic hypothermia and admitted at the NICU of ACH between April 1, 2015 and October 31, 2020, and ii) patients with neonatal seizures due to confirmed likely pathogenic or pathogenic genetic variant affecting channel function and associated with epilepsy, admitted at the NICU of ACH in Calgary between January 1, 2012 and March 31, 2023.

Parental informed consent was obtained and signed for all patients included in the case series. As individual data is not shown for the comparison groups, parental informed consent was not required. Research Ethics Board approval was obtained in Calgary for this collaborative research (#REB16–1783).

## 3. Results

### 3.1. Clinical and neuroradiological features

Thirteen neonates, 6 male and 7 female, were included in this study. Clinical, aEEG, EEG and neuroradiological features are summarised in Table 1. All patients were born at term or late preterm, following an uncomplicated pregnancy and delivery. Family history for seizures was negative in 9 patients. Seizure onset was at day 1–3 for the 9 neonates with *SCN2A* variants (patients 1–9) and at day 1–6 for the 4 neonates with *KCNQ3* variants (patients 10–13). Interictal neurological examination was normal in 8 patients but demonstrated mild to severe axial hypotonia and decreased spontaneous movements in 5 patients, all with *SCN2A* variants. Seizure semiology typically included asymmetric tonic posturing (all patients), accompanied by apnea, desaturation or cyanosis (9/13 patients). Other observed features, usually preceding or following the tonic posturing, included stereotypic behavior, head deviation, eye movements or staring.

Infections and inborn errors of metabolism were excluded by laboratory testing in all patients, and MRI was normal in most patients (8/12 patients). In four patients, all with *SCN2A* variants, MRI showed restricted diffusion in the medial thalamus the right caudate nucleus, periventricular white matter abnormalities or a thin corpus callosum (Table 1).

In all patients, various ASMs were trialed before adequate seizure control was reached (median number of used ASM 4; range 1–6). In 12 out of 13 patients, a sodium channel blocker was the last type of ASM introduced, achieving significant seizure reduction in all patients: nine patients were seizure free upon an adequate dosage, and three patients had a partial reduction in seizures (>50% reduction in the number of seizures). One patient became seizure-free on phenobarbitone. In seven

**Table 1**  
Clinical characteristics of 13 patients with neonatal-onset epilepsy related to *SCN2A* and *KCNQ3* mutations.

Patient No.	1 (NLL1)	2 (NLL2)	3. (NLL3)	4 (NLR1)	5 (NLR2)	6 (CAA1)	7 (CAA2)	8 (CAA6)	9 (USF2)	10 (CAA4)	11 (CAA5)	12 (USF1)	13 (POP1)
Mutation	<i>SCN2A</i> de novo c.4644G>C, p (Met1548Ile)	<i>SCN2A</i> de novo: c.2306T>C, p. (Ile769Thr)	<i>SCN2A</i> de novo c.5528A>T, p. (Asp1843Val)	<i>SCN2A</i> de novo c.4061T>C, p. (Met1354Thr)	<i>SCN2A</i> unknown c.3967A>G, p. (Met1323Val)	<i>SCN2A</i> de novo mosaic for c.2635G>A, p. (Gly879Arg)	<i>SCN2A</i> unknown c.4886G>A, p. (Arg1629His)	<i>SCN2A</i> de novo c.781G>A, p. (Val261Met)	<i>SCN2A</i> de novo c.2713A>G, p. Lys905GluE	<i>KCNQ3</i> paternally inherited c.1558C>T, p. (Arg520*)	<i>KCNQ3</i> , paternally inherited, c.938C>T, p. Thr313Ile	<i>KCNQ3</i> , maternally inherited c.923 G>C, p.W308S	<i>KCNQ3</i> de novo c.956A>G, p. (Tyr319Cys)
Family history	negative	negative	negative	negative	negative	negative	negative	negative	negative	positive, possible paternal history of seizure	positive, father had childhood Sz	positive, febrile seizures in mother	negative
GA, sex Apgar score	full-term/M 9,10	full -term/F 8,8	full -term/M 9,10	full -term/F 9,10	full-term/M 9,10	full -term/F 9,9	full -term/M 5,9	full-term/M 9,9	36w4d/F 9,9	full -term/M 7,8	full -term/F 8,9	full-term/F 8/9	full -term/F 9,10
Brain MRI	normal	restricted diffusion medial left thalamus	small periventricular white matter lesion	normal	normal	restricted diffusion right caudate nucleus	normal	normal	thin corpus callosum	normal	normal	not performed	normal
Age at onset Sz type	day 2 multifocal tonic or tonic-clonic or stereotype behavior	day 2 multifocal tonic, desaturation	day 2 focal tonic, desaturation, followed by stereotype behavior, head deviation and clonic movements	day 2 generalised clonic and tonic, blinking, apnea	day 3 generalised tonic posturing, head deviation, yawning, and at the end a few clonic movements	day 1 generalised tonic posturing, movement of the eyes, apnea, desaturation with cyanosis.	day 3 apnea, desaturation with cyanosis followed by bilateral tonic posturing	day 2 unilateral focal tonic or tonic- clonic, then, sequential whole body tonic posturing followed by tonic-clonic ending	day 1 eye deviation, sometimes followed by tonic extension of the extremities and brief self- resolving desaturation	day 1 tonic-clonic	day 6 opening eyes, staring, apnea with cyanosis, focal tonic posturing to bilateral tonic, desaturation	day 4 tonic phase with cyanosis followed by bilateral asynchronous clonic jerks	day 3 tonic posturing with cyanosis
Interictal neurological examination	encephalopathyaxial and limb hypotonia with alternating opisthotonos	axial hypotonia	axial hypotonia	normal	normal	axial and limb hypotonia proximal > distal.	normal	Normal, mild encephalopathy due to med loads	axial hypotonia	normal	normal	normal	normal
Ictal aEEG Interictal aEEG background pattern	characteristic <sup>1</sup> BS	characteristic <sup>1</sup> CNV	characteristic <sup>1</sup> CNV	characteristic <sup>1</sup> CNV	characteristic <sup>1</sup> CNV	characteristic <sup>1</sup> CNV	non- characteristic CNV	characteristic <sup>1</sup> CNV	characteristic <sup>1</sup> BS	characteristic <sup>1</sup> CNV	characteristic <sup>1</sup> CNV	characteristic <sup>1</sup> CNV	characteristic <sup>1</sup> CNV
ASMs in neonatal period	PB, PN, LVT, OXC	PB, PN, LVT, lidocaine, OXC	PB, LVT, OXC	PB, CBZ	PB, CBZ, LEV, MDZ, OXC, PHT	LVT, TPM, FPHT, PB, PN, CBZ	PB, LVT, OXC	PB, LVT, PHT, CBZ	PB, LVT, PN, CLB, VGB, CBZ	PB, CBM, LVT, FPHT,	LVT, PB	CBZ	PB, CBZ
Effective ASM (dosage)	PB partially effective (7.5 mg/kg in 2 doses, after loading doses) OXC effective (30 mg/kg in 2 doses)	OXC effective (30 mg/kg in 2 doses)	OXC effective (30 mg/kg in 2 doses)	CBZ effective (7 mg/kg in 2 doses)	CBZ (20 mg/kg in 2 doses), OXC (35 mg/ kg in 2 doses) and PHT (13 mg/kg in 2 doses after loading doses) all partially effective	CBZ partially effective (30 mg/kg in 3 doses + FPHT 5 mg/kg/day in 2 doses)	OXC effective (18 mg/kg in 2 doses)	PHT (20 mg/kg/ load), CBZ (10 mg/kg/day)	CBZ partially effective (40 mg/kg/day)	PB and load FPHT effective (FPHT load 10 mg/kg, maintenance 5 mg/kg/day PB 5 mg/kg/ day in 2 doses)	PB effective (load 20 mg/ kg; maintenance in 2 doses)	CBZ effective (10 mg/kg/d)	CBZ effective (15 mg/kg in 3 doses)
Serum concentrations	OXC <0.5 mg/l;10- OH—CBZ 11 mg/l (NV 10–35 mg/l, day 30, dosage 31 mg/kg/	OXC undetectable; 10-OH—CBZ 6 mg/l (NV	unknown	unknown	CBZ 2.3 mg/l (NV 4–12, dosage 20 mg/ kg/day)	CBZ 79 umol/L (NV <50 umol/L, dosage 30 mg/	unknown	unknown (not performed due to low maintenance	unknown	unknown	PB 125 umol/L (NV 65 – 170 umol/L,	unknown	CBZ 5,77 ug/ ml (4–12 ug/ ml, day 9, dosage

(continued on next page)

Table 1 (continued)

Patient No.	1 (NLL1)	2 (NLL2)	3. (NLL3)	4 (NLR1)	5 (NLR2)	6 (CAA1)	7 (CAA2)	8 (CAA6)	9 (USF2)	10 (CAA4)	11 (CAA5)	12 (USF1)	13 (POP1)
	day)	10–35 mg/l, day 3, dosage 10 mg/kg/day dosage) OXC <0.5; 10-OH—CBZ 24 (day 11, dosage 30 mg/kg/day)			OXC 21,7 mg/l (NV 10–35, dosage 35 mg/kg/day)	kg/day) + Free Phenytoin 5.4 umol/L (NV 4–8 umol/L, dosage 5 mg/kg/day)		dose)			dosage 5 mg/kg/day)		15 mg/kg/day)
Sz outcome (offset age)	sz-free (day 18)	sz-free (day 19)	sz-free (day 10)	sz-free (day 3)	Almost sz-free (14 months)	Seizures controlled with CBD oil (5 y.o.)	sz-free (6 weeks)	sz-free (day 14)	several seizures per week (n.a.)	sz-free (day 7)	sz-free (day 8)	Sz-free (day 4)	sz-free (day 8)
Time between initiation effective ASM and Sz outcome	6 days	11 days	2 days	<24 h	4,5 weeks	<24 h	<48h	1 day	n/a	<24h	<24h	<24h	1 day
Duration of hospitalization	28 days	29 days	12 days	4 days	11 weeks	21 days	4 days	21 days	5 weeks	3 days	3 days	4 days	6 days
Duration of initial ASM therapy	2 years 4 months	1 year 4 months	6 months	9 months	ongoing (OXC)	ongoing	ongoing	1 year 6 months	ongoing	ongoing (switch to CBM, week 4). Last Sz 4 mo prior to last F/U	12 months	1 year	ongoing
Recurrence upon initial seizure-free state (age)	yes SWAS (4 years)	yes two unprovoked seizures (2 years)	no only provoked seizures	yes (day 14, addition CBM)	n/a	Evolved into epilepsy of infancy with migrating focal seizures (day 10). Controlled at 4y.o. w/CBD oil.	yes (6 months, OXC dose adjusted to 30 mg/Kg/day, free since)	No	n/a	yes (4, 6, and 20 months)	no	no	no
Recurrence upon discontinuation of ASM therapy	yes	yes	no	no	n/a	2 weeks after D/C of CBD oil. Controlled again w/CBD oil	n/a	No	n/a	n/a	no	no	n/a
Developmental outcome (Last FU: age)	severe developmental delay (6 years)	Very mild developmental delay (5 years)	normal development (3 years)	Severe developmental delay, hypotonia (2 years)	Moderate impaired motor development (1 year 2 months)	severe impaired motor and speech development (5 years 1 month). GMFCS 5	expressive-receptive language, mild gross motor. (1 year 2 months)	normal (3 years 4 months)	severe intellectual disability, non-verbal, non-ambulant (7 years)	normal development (2 years)	normal development (4 year 7 months)	normal development (4 years)	normal development (1 year 8 months)

<sup>1</sup> Characteristic means the typical pattern of a sudden attenuation, then rise in amplitude, followed by a marked postictal suppression, as described in Fig. 1. ASMs anti-seizure medications; BS burst suppression; CAA Canada Calgary; CBZ carbamazepine; CBM Clobazam; CNV continuous normal voltage; DNV discontinuous normal voltage, SWAS spike-wave activation in sleep; F female; FPHT fosphenytoin; FU follow-up; GA gestational age; LVT levetiracetam; M male; MDZ midazolam; n/a not applicable; NLL Netherlands Leiden; NLR Netherlands Rotterdam; NV normal value; OXC oxcarbazepine; PB phenobarbitone; POP Portugal Porto; PHT: phenytoin; PN pyridoxine; sz: seizure; TPM topiramate; VGB vigabatrin. All SCN2A variants reported on transcript NM\_021007.3. All KCNQ3 variants reported on transcript NM\_004519.3.

patients (3–5, 7–8, 12–13), a sodium channel blocker was the second or third line ASM, when the treating physicians recognised the unique aEEG pattern suspecting a channelopathy. Median follow-up was over 3 years (range 14 months – 7 years). One child (patient 6) developed epilepsy of infancy with migrating focal seizures at day 10. In seven patients the ASM was discontinued (after maintenance therapy of 6 months – 2.5 years), upon which 5 children remained seizure free. One of the children with epilepsy recurrence (patient 1) developed SWAS after 4 years of age, responding well to oral prednisolone treatment. Development ranges from normal to severe developmental delay (Table 1). All 4 individuals with *KCNQ3* variants had a normal outcome.

Regarding the comparison groups, 123 patients with HIE and hypothermia protocol were identified, of which 117 patients had aEEG and cEEG monitoring. Out of these 117 patients, 82 patients had seizures during EEG monitoring: either electroclinical seizures ( $n = 55$ ), and / or electrical seizures without clinical correlate ( $n = 75$ ). As for the comparison group of patients with a confirmed genetic cause affecting channel function and associated with epilepsy, 55 patients were identified. Out of these 55 patients, 11 patients had seizures in the neonatal period. In these patients, (likely) pathogenic variants were found in the *KCNQ2* ( $n = 6$ ), *ATP1A3* ( $n = 1$ ), *CACNA1A* ( $n = 1$ ), *GABRB3* ( $n = 1$ ), *KCNT1* ( $n = 1$ ), *SCN8A* ( $n = 1$ ) genes.

### 3.2. Genetic findings

All variants found in the *SCN2A* or *KCNQ3* genes were pathogenic or likely pathogenic according to the ACMG classification [14]. For patient 10, the *KCNQ3* variant was interpreted as likely pathogenic but this was in the context of recessive disease and it is unclear in the context of dominant disease. We identified six new protein variants that were not previously published (Supplementary Table S1). An individual with a variant affecting the same residue as patient 4 and 9 has been previously published [15,16], and functional studies and characterization of epilepsy in patient 11 were recently reported [17,15]. Furthermore, patients 6–8 and 12 have been previously published [18–23].

### 3.3. aEEG and EEG findings

The ictal recording showed a characteristic pattern in the aEEG in all except one patient (patient 7). This typical pattern is shown for a patient with *SCN2A*- (Fig. 1A) and *KCNQ3*-related epilepsy (Fig. 1B). On the aEEG, a seizure can be recognized by a brief decrease in the upper margin, then a sudden rise in both the lower and the upper margin, followed by the characteristic marked postictal attenuation (decreased of both margins). When increasing the speed of the aEEG (from 6 to 15 cm/h), the pattern may become even more obvious. This pattern is different from aEEG findings in symptomatic seizures, in which a gradual rise of the upper and lower margin is seen at onset with usually longer duration without postictal attenuation (Supplementary Fig. S1).

Interictally, most patients (11 out of 13) had a continuous normal voltage background on their aEEG, with 1 patient showing intermittent episodes of suppression lasting 3–4 s.

The typical ictal aEEG pattern correlates to findings on the cEEG shown in Fig. 2, and Supplementary video 1. At the onset of seizures, a desynchronised diffuse background attenuation is seen (corresponding to the lowering of the upper margin in the aEEG), followed by gradual amplitude increase of rhythmic discharges (seen as both upper and lower margin increases on aEEG) and a post-ictal attenuation-suppression (correlating to the attenuation on the aEEG, both margins being low). For patient 7, there was a single recorded seizure with a partially similar EEG pattern of focal attenuation onset and, 5 s later, being followed by diffused 2 Hz delta rhythmic discharges. This was followed by minimal postictal suppression. Once medicated, his seizure pattern changed to a more diffused theta rhythmic activity without onset attenuation or post-ictal suppression.

Interictally, the EEG may range from almost normal (Fig. 3A), to a

typical sustained suppression-burst pattern (Fig. 3B).

In the comparison group of neonates with HIE, none of the patients had a similar pattern on aEEG or cEEG. Likewise, none of the patients in the genetic channelopathy comparison group, apart from patients with *KCNQ2*-associated epilepsy had the above described pattern.

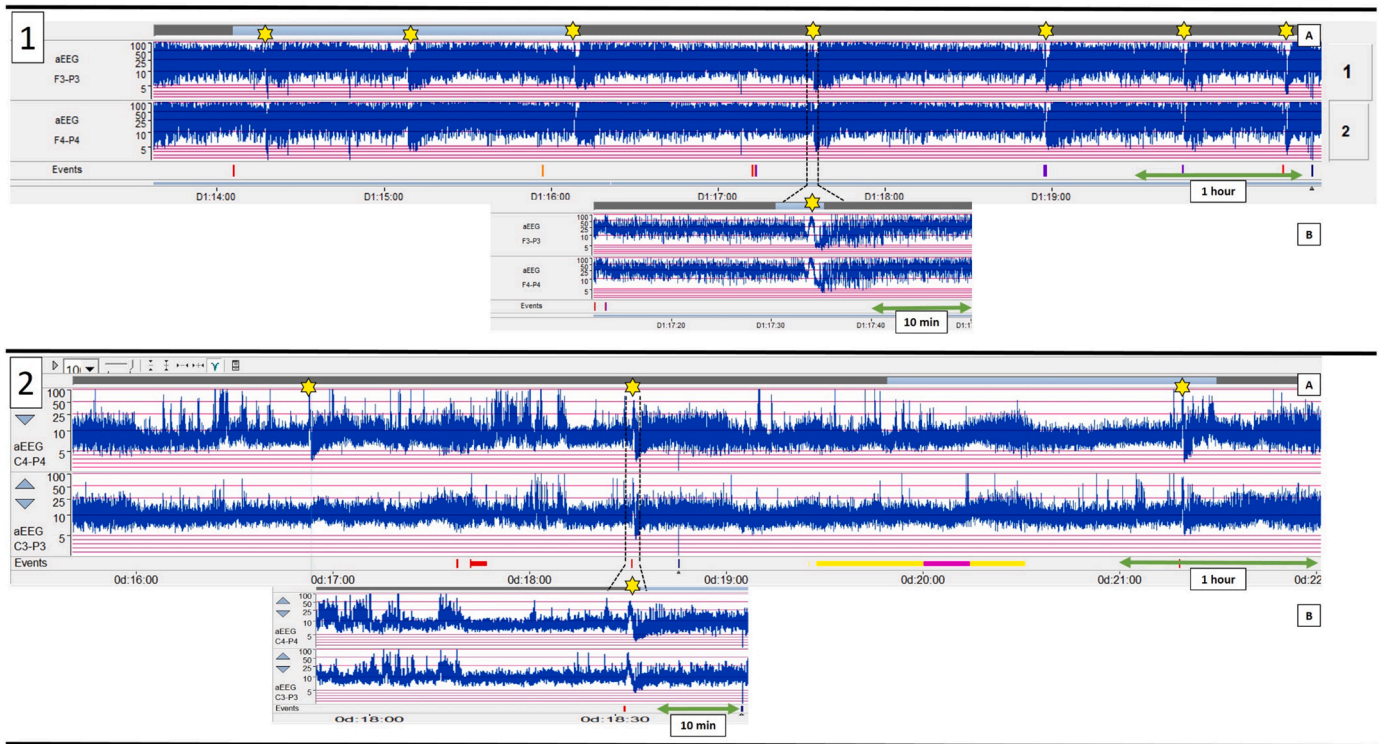
## 4. Discussion

We describe 13 patients with neonatal-onset seizures caused by pathogenic or likely pathogenic variants in either the *SCN2A* or *KCNQ3* genes, and demonstrate that seizures due to these two channelopathies are typically, at some point, characterized by a specific pattern on aEEG and cEEG. This typical ictal pattern consists of brief onset with an initial decrease, and then a quick rise in aEEG amplitude, followed by postictal attenuation. This correlates to a period of bilateral attenuation on the conventional EEG at onset, followed by rhythmic focal or bilateral discharges ending in post-ictal amplitude suppression for several seconds. These findings are similar to the ictal pattern described in patients with *KCNQ2*-related epilepsies [13]. Apart from patients with *KCNQ2*-related epilepsy, none of the patients with seizures in the neonatal period with other genetic channelopathies in our comparison group had a similar pattern on aEEG or cEEG.

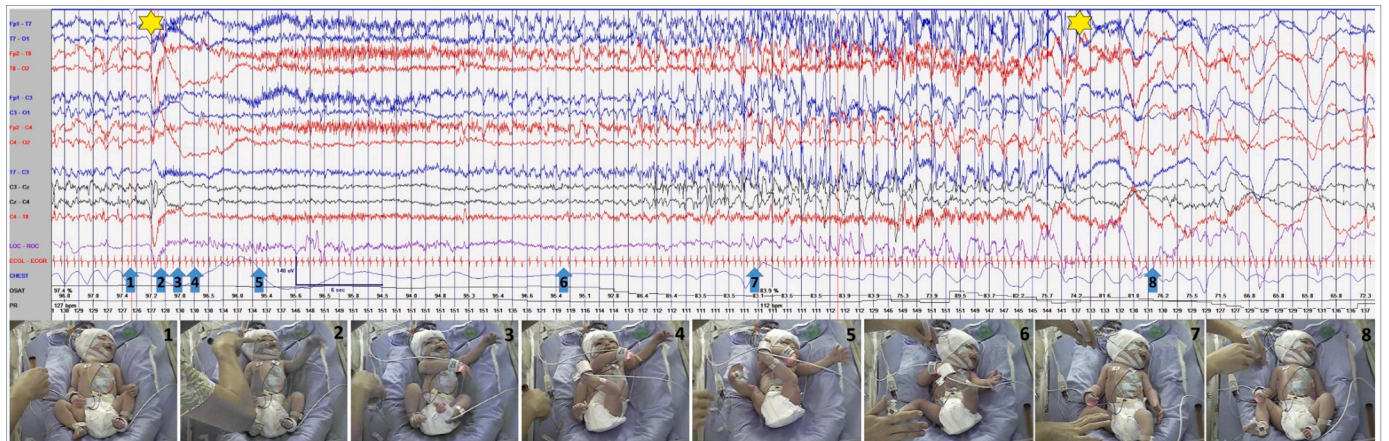
In combination with the seizure semiology, this characteristic ictal pattern on aEEG and cEEG should raise high suspicion for a *KCNQ2*-, *KCNQ3* or *SCN2A*-related epilepsy. However, since not all patients have this specific aEEG or cEEG pattern, the absence of the ictal EEG pattern, does not rule out these channelopathies. In our study, some patients had focal seizures at onset but only at a later time developed the characteristic pattern described here (i.e. patient 8). While we cannot fully exclude the possibility of missed cases of *KCNQ2*-, *KCNQ3* or *SCN2A* channelopathy, either with or without the characteristic aEEG pattern, we suspect selection bias for this study is low. Standard of care at the participating institutions during the indicated time frame would have included EEG monitoring and all individuals with unknown etiology of seizures would have been offered genetic testing for these genes. All individuals with neonatal seizures that had genetic testing identifying a relevant variant would have been identified.

Seizures associated with channelopathies are often resistant to commonly used ASM, but do respond well to sodium channel blockers [8,10,24]. Therefore, the characteristic ictal aEEG pattern can alert clinicians to this type of seizures/etiology, and facilitates the prompt initiation of precision treatment with sodium channel blockers, even prior to the return of genetic test results, which can typically take up to several weeks. Additionally, in centers where access to broad based genetic testing is not readily or rapidly available, recognition of this aEEG pattern may permit targeted gene testing or at least a clinical diagnosis of channelopathy to help guide clinical management. Finally, the high specificity of this EEG pattern may help increase or decrease suspicion for pathogenicity if there are variants of uncertain significance identified in these genes.

Both on aEEG and cEEG, the attenuation at onset of the seizures and the profound postictal suppression are unique characteristics compared to findings in seizures in neonates due to other more common etiologies [25–27]. No patients from the two comparison groups had a similar pattern on aEEG and cEEG, with exception of those with *KCNQ2*-related epilepsy. Patients in the second comparison group had likely pathogenic variants in the *ATP1A3*, *CACNA1A*, *GABRB3*, *KCNT1*, and *SCN8A*, which are other known genes affecting channel function, and we did not find a similar EEG pattern. However, the comparison group is quite small due to the very low incidence of other channelopathies as causative of seizures in the neonatal period, and we cannot fully exclude that in future more channelopathies will be found to be associated with this ictal EEG pattern. The pathophysiological substrate of this ictal pattern remains unknown and it is hitherto not described in other channelopathies. Remarkably, this EEG feature, also described as an icicle on quantitative analysis of cEEG, is also recently described in a 16-year-old



**Fig. 1.** Characteristic ictal aEEG pattern in *SCN2A* (A) and *KCNQ3* (B)-associated epilepsy. 1 aEEG at a regular paper speed (A. upper panel 6 cm/h) and increased paper speed (B. lower panel 15 cm/h) of patient 1. Seizures are marked by asterisks, showing bilateral synchronic discharge with a sudden decreased, then rise in both the lower and upper margin, followed by the characteristic marked postictal attenuation. 2 aEEG at a regular paper speed (A. upper panel 6 cm/h) and increased paper speed (B. lower panel 15 cm/h) of patient 13. The characteristic pattern, with the sudden rise and postictal attenuation, preceded by a short decrease in amplitude, can be seen although less clear than in sample A.



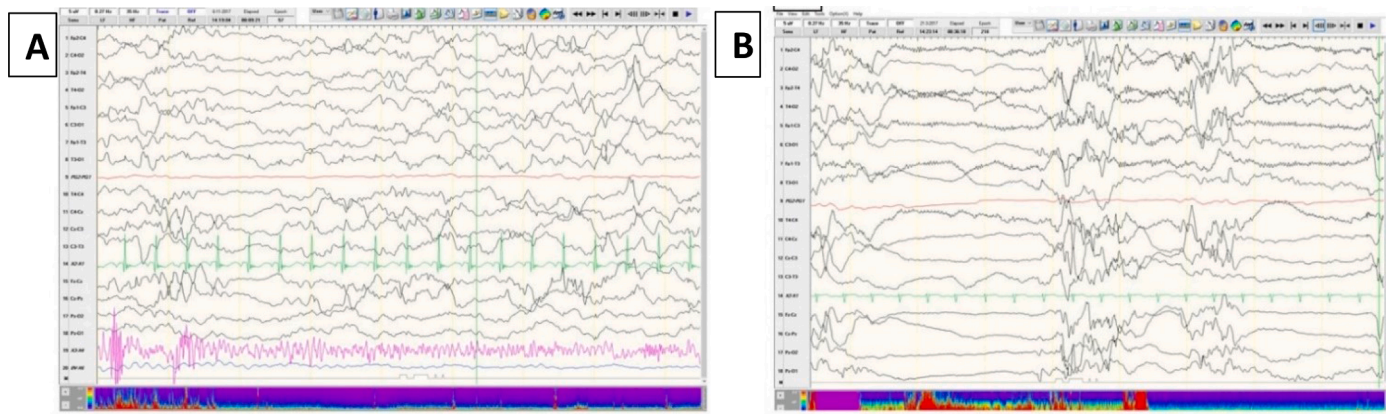
**Fig. 2.** Ictal EEG recording of a patient with *SCN2A*-associated epilepsy. Ictal continuous video EEG recording of patient 6 with pathogenic variant in *SCN2A* gene showing the EEG and clinical findings. 1. Pre-ictal phase with normal background activity and resting clinical state. 2 - 5. Seizure onset with quick sequential tonic posturing starting with the left arm (3), right arm (3), left leg (4), and right leg (5) over 6 s with synchronic diffused background attenuation and superimposed low amplitude fast activity. 6 - 7. The patient begins to relax the diffused tonic posturing, decreasing O2 saturation as product of ictal apnea and the EEG shows gradual increase of cortico-thalamic organization (6) showing rhythmic discharges with a gradual increase of amplitude and frequency of 1 – 3 Hz delta spike and slow wave discharges while the patient became hypotonic (7). 8. Post-ictally, the patient regains muscle tone and spontaneous movements and breathing while the EEG showed diffused attenuation of fast activity with high amplitude very slow waves (<0.25 Hz). EEG settings: LFF 1 Hz, HFF 70 Hz, notch 60 Hz on, sensitivity 7 uV/mm, paper speed 10 mm/sec.

patient with *SCN2A*-related epilepsy [28].

Clinically, seizures in neonates due to genetic variants, particularly channelopathies, can be discerned from seizures provoked by acutely acquired causes by the time of onset and the seizure semiology. The onset of genetic epilepsy is typically after 24 h of life (median 60 h) as opposed to provoked (symptomatic) seizures, which generally start in

the first 24 h of life [29]. Seizure semiology typically comprises focal or sequential-generalised tonic posturing (Fig. 2) in channelopathies [7,8, 29], which was also seen in our case series.

In case of seizures in the neonatal period, it is appropriate to perform a brain MRI, in clinical practice usually preceded by cranial ultrasound, to rule out other causes of seizures [30]. In *SCN2A* channelopathies, MRI



**Fig. 3.** Interictal EEG patterns in patients with *SCN2A*-related epilepsy.

A. Almost normal interictal EEG pattern (patient 3) with a continuous EEG activity and brief epochs of background attenuation (trace alternant) in quiet sleep.  
 B. Severely abnormal interictal EEG pattern (Ohtahara Syndrome type), with a suppression-burst pattern (patient 1). Bursts consist of mixture of spikes, sharp waves or sharp and slow waves – voltage (100 –350uV). Frequent inter-burst intervals of 2–4 s length. The duration of suppression was increased during the sleep.  
 EEG settings: LFF 0.27 Hz, HFF 35 Hz, notch on, sensitivity 5 uV/mm, paper speed 10 mm/sec.

abnormalities including hyperintensities in brain stem, basal ganglia and white matter abnormalities [31], and a thin or atrophic corpus callosum [19], have been previously described. In our cohort patient 2 had diffusion restriction in the thalamus and caudate, which could be an additional cause for seizures [32]. However, the seizures were not consistently focal, neither responded to conventional ASM, and further suspicion of a genetic cause was raised based on the aEEG pattern, highlighting the utility of recognizing this specific pattern.

The characteristic aEEG/EEG pattern associated with *KCNQ2*, *KCNQ3* and *SCN2A*-related neonatal epilepsies were especially valuable for patients 3–5, 7–8 and 12–13, as bedside recognition of the pattern led to early and effective treatment with a sodium-channel blocker. It was also particularly valuable for patient 10 in this cohort. This patient has a heterozygous *KCNQ3* p.(Arg520\*) variant, which predicts a truncating stop gain. However, autosomal dominant *KCNQ3* variants associated with neonatal-onset epilepsies are typically missense substitutions. Although these missense substitutions also cause loss of function, this is not necessarily equivalent to truncation or haploinsufficiency of the channel. Pathogenic truncating variants have been described in the context of autosomal recessive *KCNQ3*-related epilepsy, yet in these reports, heterozygous carrier parents have been unaffected [33,34]. For patient 10, this variant was inherited from the father who had a history of paroxysmal episodes in infancy but with reportedly normal EEG. Therefore, it is unclear whether: 1) the heterozygous p.(Arg520\*) variant is causative in a dominant manner with variable penetrance, or 2) there is a second undetected variant on the other *KCNQ3* allele and this individual actually has recessive *KCNQ3* disease, or 3) the patient is only a heterozygous carrier and there is actually another cause for her seizures unrelated to *KCNQ3*. Although the EEG pattern for recessive *KCNQ3*-related epilepsy has not yet been described, the presence of the characteristic aEEG/cEEG pattern confirms that this patient likely does have *KCNQ3*-related neonatal-onset epilepsy, and that a dominant effect from this variant may indeed be possible. This demonstrates that this aEEG pattern and the reaction to sodium channel blockers may be helpful to assist in variant interpretation and to guide management when genetic results are unclear.

To date, mutations reported in the *SCN2A* gene, encoding the  $Na_v1.2$  channel, cause different overlapping phenotypes. The clinical phenotype may depend on the type of variant and whether the variant is responsible for loss or gain of function of the  $Nav1.2$  channel or more complex mixed effects [8,35]. Missense mutations with a gain-of-function are typically correlated to an early onset epilepsy (before 3 months), in which the severity of the gain-of-function effect can be correlated to the phenotype severity. Truncations and canonical

splice site mutations, and to a lesser extent missense mutations with a presumable loss-of function effects, typically correlate to later onset of epilepsy (after 3 months) [8,36]. Within this group of patients with late onset epilepsy, some were reported to have a pattern of SWAS (spike-wave activation in sleep) [8]. Interestingly, our patient 1 developed SWAS at the age of 4. As SWAS has been associated with other channelopathies [37], a low threshold of suspicion is warranted and an EEG during sleep should be performed in patients with a known channelopathy and any symptoms suggestive of SWAS (i.e. behavior changes, language regression). Missense mutations in sodium channel *SCN1A* and *SCN2A* also predispose children to encephalopathy with febrile seizures [38]. In our study, patient 3, carrying a de novo likely pathogenic *SCN2A* variant, also had febrile seizures.

In line with previous observations [8,23,36], 9 out of 13 patients in this study became seizure free after initiation of a sodium channel blocker, and 3 patients had a significant seizure reduction. One patient became seizure free with phenobarbitone. In neonates with gain-of-function *SCN2A* mutations, sodium channel blockers often lead to a clinically relevant seizure reduction or seizure freedom, whereas other ASM are less effective [8,36]. The effect is probably caused by inhibition of the increased  $Na_v1.2$  activity in cells with an excitatory function. [5] In contrast, sodium channel blockers are rarely effective in loss-of-function *SCN2A* variants associated with late onset epilepsy ( $\geq 3$  months), and can even worsen seizures [8,36]. Potassium channels encoded by the *KCNQ2* and *KCNQ3* genes ( $Kv7.2/3$  channels) regulate resting potential and prevent repetitive firing. Pathogenic mutations lead to a loss of this inhibitory effect [39]. The  $Kv7.2/3$  channels and sodium channels are suggested to have a structural and functional co-localization at the neuronal membrane in various regions of the brain [40,41], which might explain the effect of sodium channel blockers in *KCNQ2* and *KCNQ3* associated epilepsy [10,23].

Early seizure control in neonates and children is important, as a higher seizure burden is negatively associated with (long-term) neurodevelopmental outcome [11,12]. A recent meta-analysis did not find a difference in functional neurodevelopment or epilepsy at age 24 months among children whose ASM was discontinued vs continued at hospital discharge after resolution of acute provoked (symptomatic) neonatal seizures [42], but no formal studies have investigated the most appropriate duration of ASM treatment in channelopathies causing neonatal epilepsy. In our study, ASM was discontinued in seven patients (after a maintenance treatment ranging from 6 months to 2.5 years), upon which five children remained seizure free. Seizures recurred in patient 2 after 2.5 years, and patient 1 developed SWAS after 1.5 years (at the age of 4), with a good response to oral corticosteroids. In patient 3, only



provoked seizures occurred after vaccination or viral illnesses.

In conclusion, seizures in neonates with *SCN2A* and *KCNQ3* related epilepsy can be recognized by the same characteristic aEEG ictal pattern as reported in *KCNQ2*-related epilepsy, extending these unique features to other channelopathies. Recognition of this pattern together with seizure semiology facilitates the prompt initiation of precision treatment with sodium channel blockers, even before genetic test results are available. This characteristic (a)EEG pattern may also be valuable in the context of interpreting variants of uncertain significance in *SCN2A*, *KCNQ2* and *KCNQ3* genes.

### Ethical publication statement

We confirm that we have read the Journal's position on issues involved in ethical publication and affirm that this report is consistent with those guidelines

### Declaration of Competing Interest

C. M. P. C. D. Peeters-Scholte is founder and consultant at Neurophyxia BV. She holds several patents and stocks of Neurophyxia BV. None of this work has a relationship with the current manuscript.

The other authors report no conflicts of interest, according to ICMJE recommendations.

### Supplementary materials

Supplementary material associated with this article can be found, in the online version, at [doi:10.1016/j.seizure.2023.06.016](https://doi.org/10.1016/j.seizure.2023.06.016).

### References

- Vasudevan C, Levene M. Epidemiology and aetiology of neonatal seizures. *Semin Fetal Neonatal Med* 2013;18:185–91.
- Pressler RM, Cilio MR, Mizrahi EM, et al. The ILAE classification of seizures and the epilepsies: modification for seizures in the neonate. Position paper by the ILAE Task Force on Neonatal Seizures. *Epilepsia* 2021;62:615–28.
- Weeke LC, Groenendaal F, Toet MC, et al. The aetiology of neonatal seizures and the diagnostic contribution of neonatal cerebral magnetic resonance imaging. *Dev Med Child Neurol* 2015;57:248–56.
- Axeen EJT, Olson HE. Neonatal epilepsy genetics. *Semin Fetal Neonatal Med* 2018;23:197–203.
- Shellhaas RA, Wusthoff CJ, Tsuchida TN, et al. Profile of neonatal epilepsies: characteristics of a prospective US cohort. *Neurology* 2017;89:893–9.
- Helbig KL, Lauerer RJ, Bahr JC, et al. De Novo pathogenic variants in *CACNA1E* cause developmental and epileptic encephalopathy with contractures, macrocephaly, and dyskinesias. *Am J Hum Genet* 2018;103:666–78.
- Weckhuysen S, Ivanovic V, Hendrickx R, et al. Extending the *KCNQ2* encephalopathy spectrum: clinical and neuroimaging findings in 17 patients. *Neurology* 2013;81:1697–703.
- Wolff M, Johannesen KM, Hedrich UBS, et al. Genetic and phenotypic heterogeneity suggest therapeutic implications in *SCN2A*-related disorders. *Brain* 2017;140:1316–36.
- Hadar FH, Eli H, Ayelet L, et al. Lacosamide for *SCN2A*-related intractable neonatal and infantile seizures. *Epileptic Disord* 2018;20:440–6.
- Kuersten M, Tacke M, Gerstl L, Hoelz H, Stülpnagel CV, Borggraefe I. Antiepileptic therapy approaches in *KCNQ2* related epilepsy: a systematic review. *Eur J Med Genet* 2020;63:103628.
- Payne ET, Zhao XY, Frndova H, et al. Seizure burden is independently associated with short term outcome in critically ill children. *Brain* 2014;137:1429–38.
- Pressler RM, Lagae L. Why we urgently need improved seizure and epilepsy therapies for children and neonates. *Neuropharmacology* 2020;170:107854.
- Vilan A, Mendes Ribeiro J, Striano P, et al. A Distinctive ictal amplitude-integrated electroencephalography pattern in newborns with neonatal epilepsy associated with *KCNQ2* mutations. *Neonatology* 2017;112:387–93.
- Richards S, Aziz N, Bale S, et al. Standards and guidelines for the interpretation of sequence variants: a joint consensus recommendation of the American College of Medical Genetics and Genomics and the Association for Molecular Pathology. *Genet Med* 2015;17:405–23.
- Lindy AS, Stosser MB, Butler E, et al. Diagnostic outcomes for genetic testing of 70 genes in 8565 patients with epilepsy and neurodevelopmental disorders. *Epilepsia* 2018;59:1062–71.
- Carvill GL, Heavin SB, Yendle SC, et al. Targeted resequencing in epileptic encephalopathies identifies de novo mutations in *CHD2* and *SYNGAP1*. *Nat Genet* 2013;45:825–30.
- Maghera J, Li J, Lamothe SM, et al. Familial neonatal seizures caused by the Kv7.3 selectivity filter mutation T313I. *Epilepsia Open* 2020;5:562–73.
- Yang XR, Ginjupalli VKM, Theriault O, et al. *SCN2A*-related epilepsy of infancy with migrating focal seizures: report of a variant with apparent gain- and loss-of-function effects. *J Neurophysiol* 2022;127:1388–97.
- Kong Y, Yan K, Hu L, et al. Data on mutations and Clinical features in *SCN1A* or *SCN2A* gene. *Data Brief* 2019;22:492–501.
- Baasch AL, Hüning I, Gilissen C, et al. Exome sequencing identifies a de novo *SCN2A* mutation in a patient with intractable seizures, severe intellectual disability, optic atrophy, muscular hypotonia, and brain abnormalities. *Epilepsia* 2014;55:e25–9.
- Møller RS, Larsen LHG, Johannesen KM, et al. Gene panel testing in epileptic encephalopathies and familial epilepsies. *Mol Syndromol* 2016;7:210–9.
- Liao Y, Deprez L, Maljevic S, et al. Molecular correlates of age-dependent seizures in an inherited neonatal-infantile epilepsy. *Brain* 2010;133:1403–14.
- Sands TT, Balestri M, Bellini G, et al. Rapid and safe response to low-dose carbamazepine in neonatal epilepsy. *Epilepsia* 2016;57:2019–30.
- Pisano T, Numis AL, Heavin SB, et al. Early and effective treatment of *KCNQ2* encephalopathy. *Epilepsia* 2015;56:685–91.
- Hellstrom-Westas L, Rosen I, de Vries LS, Greisen G. Amplitude-integrated EEG classification and interpretation in preterm and term infants. *Neoreviews* 2006;7:e76–87.
- Hellström-Westas L. Amplitude-integrated electroencephalography for seizure detection in newborn infants. *Semin Fetal Neonatal Med* 2018;23:175–82.
- Kullmann DM. The neuronal channelopathies. *Brain* 2002;125:1177–95.
- Catenaccio E, Bennett ML, Massey SL, Abend NS, Bergqvist C. Tonic seizures in a patient with lennox-gastaut syndrome manifest as “Icicles” rather than “Flames” on quantitative EEG analysis. *J Clin Neurophysiol* 2023;40:e6–9.
- Cornet M, Morabito V, Lederer D, et al. Neonatal presentation of genetic epilepsies: early differentiation from acute provoked seizures. *Epilepsia* 2021;62:1907–20.
- Trofimova A, Milla SS, Ryan ME, et al. ACR appropriateness criteria® seizures-child. *J Am Coll Radiol* 2021;18:S199–211.
- Spagnoli C, Fusco C, Percesepe A, Leuzzi V, Pisani F. Genetic neonatal-onset epilepsies and developmental/epileptic encephalopathies with movement disorders: a systematic review. *Int J Mol Sci* 2021;22:4202.
- Laugesaar R, Vaher U, Loo S, et al. Epilepsy after perinatal stroke with different vascular subtypes. *Epilepsia Open* 2018;3:193–202.
- Lauritano A, Moutton S, Longobardi E, et al. A novel homozygous *KCNQ3* loss-of-function variant causes non-syndromic intellectual disability and neonatal-onset pharmacodependent epilepsy. *Epilepsia Open* 2019;4:464–75.
- Kothur K, Holman K, Farnsworth E, et al. Diagnostic yield of targeted massively parallel sequencing in children with epileptic encephalopathy. *Seizure* 2018;59:132–40.
- AlSaif S, Umair M, Alfadhel M. Biallelic *SCN2A* gene mutation causing early infantile epileptic encephalopathy: case report and review. *J Cent Nerv Syst Dis* 2019;11:117957351984993.
- Brunklau A, Du J, Steckler F, et al. Biological concepts in human sodium channel epilepsies and their relevance in clinical practice. *Epilepsia* 2020;61:387–99.
- Kessi M, Peng J, Yang L, et al. Genetic etiologies of the electrical status epilepticus during slow wave sleep: systematic review. *BMC Genet* 2018;19:40.
- Saitoh M, Ishii A, Ihara Y, et al. Missense mutations in sodium channel *SCN1A* and *SCN2A* predispose children to encephalopathy with severe febrile seizures. *Epilepsy Res* 2015;117:1–6.
- Maljevic S, Lerche H. Potassium channel genes and benign familial neonatal epilepsy. *Prog Brain Res* 2014:17–53.
- Pan Z, Kao T, Horvath Z, et al. A common ankyrin-G-based mechanism retains *KCNQ* and *Na V* channels at electrically active domains of the axon. *J Neurosci* 2006;26:2599–613.
- Nguyen HM, Miyazaki H, Hoshi N, et al. Modulation of voltage-gated K<sup>+</sup> channels by the sodium channel 1 subunit. *Proc Natl Acad Sci* 2012;109:18577–82.
- Glass HC, Soul JS, Chang T, et al. Safety of early discontinuation of antiseizure medication after acute symptomatic neonatal seizures. *JAMA Neurol* 2021. <https://doi.org/10.1001/jamaneurol.2021.1437>. published online May 24.