



Universiteit  
Leiden  
The Netherlands

## **EULAR recommendations for the use of imaging in large vessel vasculitis in clinical practice: 2023 update**

Dejaco, C.; Ramiro, S.; Bond, M.; Bosch, P.; Ponte, C.; Mackie, S.L.; ... ; Schmidt, W.A.

### **Citation**

Dejaco, C., Ramiro, S., Bond, M., Bosch, P., Ponte, C., Mackie, S. L., ... Schmidt, W. A. (2023). EULAR recommendations for the use of imaging in large vessel vasculitis in clinical practice: 2023 update. *Annals Of The Rheumatic Diseases*. doi:10.1136/ard-2023-224543






Version: Publisher's Version

License: [Creative Commons CC BY-NC 4.0 license](https://creativecommons.org/licenses/by-nc/4.0/)

Downloaded from: <https://hdl.handle.net/1887/3736605>

**Note:** To cite this publication please use the final published version (if applicable).

# EULAR recommendations for the use of imaging in large vessel vasculitis in clinical practice: 2023 update

Christian Dejaco <sup>1,2</sup> Sofia Ramiro <sup>3,4</sup> Milena Bond <sup>2</sup> Philipp Bosch <sup>1</sup>  
 Cristina Ponte <sup>5,6</sup> Sarah Louise Mackie<sup>7,8</sup> Thorsten A Bley<sup>9</sup>  
 Daniel Blockmans <sup>10,11</sup> Sara Brolin <sup>12,13</sup> Ertugrul Cagri Bolek <sup>14</sup>  
 Rebecca Cassie<sup>15</sup> Maria C Cid <sup>16</sup> Juan Molina-Collada <sup>17</sup>  
 Bhaskar Dasgupta <sup>18,19</sup> Berit Dalsgaard Nielsen<sup>20,21</sup> Eugenio De Miguel <sup>22</sup>  
 Haner Direskeneli <sup>23</sup> Christina Duftner <sup>24</sup> Alojzija Hočevar <sup>25,26</sup>  
 Anna Molto <sup>27,28</sup> Valentin Sebastian Schäfer <sup>29</sup> Luca Seitz<sup>30</sup>  
 Riemer H J A Slart<sup>31,32</sup> Wolfgang A Schmidt <sup>33</sup>

**Handling editor** Josef S Smolen

For numbered affiliations see end of article.

## Correspondence to

Dr Christian Dejaco, Department of Rheumatology and Immunology, Medical University of Graz, Steiermark, Austria; christian.dejaco@gmx.net

The results of this study have been presented at EULAR 2023 (LB0009).

Received 6 June 2023  
Accepted 18 July 2023

## ABSTRACT

**Objectives** To update the EULAR recommendations for the use of imaging modalities in primary large vessel vasculitis (LVV).

**Methods** A systematic literature review update was performed to retrieve new evidence on ultrasound, MRI, CT and [<sup>18</sup>F]-fluorodeoxyglucose positron emission tomography (FDG-PET) for diagnosis, monitoring and outcome prediction in LVV. The task force consisted of 24 physicians, health professionals and patients from 14 countries. The recommendations were updated based on evidence and expert opinion, iterating until voting indicated consensus. The level of agreement was determined by anonymous votes.

**Results** Three overarching principles and eight recommendations were agreed. Compared to the 2018 version, ultrasound is now recommended as first-line imaging test in all patients with suspected giant cell arteritis, and axillary arteries should be included in the standard examination. As an alternative to ultrasound, cranial and extracranial arteries can be examined by FDG-PET or MRI. For Takayasu arteritis, MRI is the preferred imaging modality; FDG-PET, CT or ultrasound are alternatives. Although imaging is not routinely recommended for follow-up, ultrasound, FDG-PET or MRI may be used for assessing vessel abnormalities in LVV patients with suspected relapse, particularly when laboratory markers of inflammation are unreliable. MR-angiography, CT-angiography or ultrasound may be used for long-term monitoring of structural damage, particularly at sites of preceding vascular inflammation.

**Conclusions** The 2023 EULAR recommendations provide up-to-date guidance for the role of imaging in the diagnosis and assessment of patients with LVV.

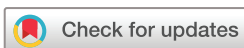emission tomography (FDG-PET) have become an integral part of the diagnosis, supported by the 2018 EULAR recommendations for the use of imaging in LVV.<sup>3</sup>

Since 2018, new studies on imaging in LVV have been published, some of them prompting a reconsideration of the original statements. FDG-PET, for example, was previously considered inadequate for the assessment of temporal arteries because of the proximity to the brain.<sup>3</sup> However, recent studies report that FDG-PET can detect temporal arteritis with high sensitivity and specificity.<sup>4–6</sup>

Glucocorticoids (GC) are the mainstay in the treatment of GCA and TAK, but recently, the interleukin-6 receptor (IL-6R) inhibitor tocilizumab has become part of the standard treatment for GCA.<sup>7</sup> Studies indicate that this drug is also effective in TAK, although approval for this indication by the Food and Drug Administration (FDA) and the European Medicines Agency is still lacking.<sup>8</sup> The IL-6 R inhibitor sarilumab has been approved by FDA for Polymyalgia rheumatica (PMR), a disease that is considered to be part of the GCA-PMR spectrum.<sup>9–10</sup> These agents interfere with the ability to produce an acute phase response as evaluated by erythrocyte sedimentation rate (ESR) or C reactive protein (CRP), reducing the impact of these biomarkers on clinical assessment of disease activity in LVV. Imaging modalities therefore may contribute to a more comprehensive assessment of patients with GCA and TAK.<sup>11</sup>

The American College of Rheumatology (ACR) has recently published management guidelines for GCA expressing their preference for TAB over ultrasound and MRI of cranial arteries in the diagnosis of GCA, which contrasts with the 2018 EULAR recommendations<sup>12</sup> and other recommendations.<sup>13–16</sup> The ACR clarifies that these recommendations relate in part to the lack of technical expertise of clinicians in the USA with these modalities.<sup>12</sup>

These and other developments have prompted us to re-evaluate and update the original EULAR recommendations, particularly addressing uncertainties about the choice of the imaging technique for diagnosis and assessment of patients with GCA



© Author(s) (or their employer(s)) 2023. No commercial re-use. See rights and permissions. Published by BMJ.

**To cite:** Dejaco C, Ramiro S, Bond M, et al. *Ann Rheum Dis* Epub ahead of print: [please include Day Month Year]. doi:10.1136/ard-2023-224543

## INTRODUCTION

Giant cell arteritis (GCA) and Takayasu arteritis (TAK) are the most common primary large vessel vasculitides (LVV).<sup>1–2</sup> Temporal artery biopsy (TAB) and conventional angiography have been considered for decades the ‘golden standards’ for diagnosing GCA and TAK, respectively. In the last years, however, imaging modalities including ultrasound, MRI and [<sup>18</sup>F]-fluorodeoxyglucose positron

## Recommendation

and TAK. The objectives, target population and target users of this update remain unchanged compared with the previous version.<sup>3</sup> These recommendations are intended to advise physicians on the use of imaging modalities in patients with suspected or established primary LVV, specifically GCA and TAK.

### METHODS

After approval by the EULAR Council, the convenors (CDejaco and WAS) and the methodologist (SR) led a task force guided by the 2014 updated EULAR Standardised Operating Procedures (SOP), complying also with the principles stipulated in the 2022 EULAR SOPs.<sup>17 18</sup> The 24 task force members from 14 countries consisted of rheumatologists, a radiologist, nuclear medicine specialists, an internist, epidemiologists, a patient representative (the second patient could not attend the meeting for health reasons), a health professional in rheumatology and 2 EMerging Eular NETwork representatives. Five members were recruited through an open call to EULAR countries via a competitive application process. All members disclosed their potential conflicts of interest before starting the process. A single face-to-face task force meeting took place. In preparation of that meeting, several online conferences of the steering committee (CDejaco, SR, WAS, MB, PB, CP and SLM) were conducted. For the systematic literature review (SLR), we used the same Population, Intervention, Control, Outcome (PICO) questions and inclusion/exclusion criteria as in the original project,<sup>19</sup> covering the role of ultrasound, MRI, CT, FDG-PET in the (1) diagnosis and (2) monitoring of inflammation and damage, (3) prediction of outcome and (4) required technical standards for imaging. The steering committee made a single modification of the original PICO questions including optical coherence tomography and fluorescein angiography (FA) as additional imaging techniques in the search.

The SLR was conducted by two fellows (MB and PB) under the guidance of the methodologist (SR). Papers published between March 2017 and 16 November 2022 were considered. Some articles were identified by both the original<sup>19</sup> and the present SLR and were therefore excluded manually from the current update. Only prospective and cross-sectional studies conducted in >20 adult patients with suspected and/or established GCA or TAK were included. We chose a cut-off of 20, because studies with a lower number of participants were concerned to be of lower quality and would therefore be less relevant for the task force. The evidence summarised in the SLR was presented to the task force in the form of tables summarising the findings, including an assessment of the risk of bias (RoB).<sup>20 21</sup> The evidence collected in the previous SLR was also considered and summarised to the task force.<sup>19</sup> Given the large number of studies included in the complete SLR (original and current update), a conscious choice was made to favour evidence stemming from studies with low RoB. The present SLR is published separately<sup>11</sup>; however, the SLR and the present recommendations manuscript form an integral and inseparable part and should be read as such.

Based on new evidence and expert opinion, the steering committee prepared proposals for updated recommendations which were subsequently discussed and refined by the entire group during the task force meeting. Following the EULAR SOP, a modification of the original statements had to be approved by >75% of the task force members, followed by a second voting on the final wording of the rephrased recommendation.<sup>18</sup> Consensus was accepted if >75% of the members voted in favour of the statement in the first round, >66% in the second round and in the third round >50% was accepted. The 2011 Oxford

Centre for Evidence Based Medicine levels of evidence (LoE) derived from the SLR were added to each recommendation.<sup>22</sup>

Finally, each task force member anonymously indicated the level of agreement via Survey Monkey (LoA, 0–10 numeric rating scale with 0=do not agree and 10=fully agree). The mean and SD of the LoA, as well as the percentage of task force members with an agreement  $\geq 8$  are presented.

The task force specified that CT and MRI also refer to the specific angiography techniques such as CT-angiography (CTA) and MR-angiography (MRA), respectively, and PET is commonly used in conjunction with CT or CTA, and occasionally in combination with MRI/MRA.

The original research agenda was checked as to whether any of the gaps in evidence have meanwhile been filled with evidence.<sup>3</sup> New issues arising during the task force meeting were added to the research agenda presented in this paper. The final manuscript was reviewed and approved by all task force members and by the EULAR Council.

### RESULTS

#### General aspects

In 2018, 12 recommendations were formulated, while the update includes three overarching principles and eight specific recommendations. Compared with the original statements, two (new numbers 5+6) remained unchanged, two underwent minor (4+8) and four major modifications (1–3, 7). The former recommendation five on CT and FDG-PET for the assessment of cranial arteries was deleted (see online supplemental table 1 for a comparison between the original and the updated statements).

The updated recommendations are depicted in [table 1](#) (including the LoE and LoA) and are explained in detail below.

#### Overarching principles

Overarching principles are statements of generic nature and are not necessarily based on direct evidence. They reflect principles of good clinical practice and build the framework for the subsequent specific recommendations.

##### Overarching principle A

In patients with suspected GCA, an early imaging test is recommended to support the clinical diagnosis of GCA, assuming high expertise and prompt availability of the imaging technique. Imaging should not delay initiation of treatment.

This statement remained largely unchanged compared with the original recommendation.<sup>3</sup> The task force emphasised that an imaging test should be considered in every patient with suspected GCA. TAB is also an adequate option, particularly when imaging is not readily available or expertise with imaging in GCA is insufficient. It is commonly believed that operator dependency is the major limitation of imaging, particularly of ultrasound. However, all diagnostic procedures including TAB are subject to operator dependency; and reproducibility can be improved by specific training.<sup>23 24</sup> In addition, a multicentre study including sonographers with a mixed level of experience revealed that inter-reader reliability of ultrasound images was comparable to that of digital histological images.<sup>25</sup>

The main point of discussion within the task force was whether treatment could be delayed while waiting for imaging to be done. It was felt that patients with strongly suspected GCA, particularly if there are ischaemic manifestations of concern (eg, transient visual loss or jaw claudication), must be treated immediately due to the risk of imminent and permanent visual

**Table 1** 2023 EULAR recommendations for the use of imaging in large vessel vasculitis in clinical practice

Overarching principles	LoA (0–10)		
	Mean (SD)	% with LoA≥8	
A. In patients with suspected GCA, an early imaging test is recommended to support the clinical diagnosis of GCA, assuming high expertise and prompt availability of the imaging technique. Imaging should not delay initiation of treatment.	9.1 (1.9)	88	
B. Imaging examination should be done by a trained specialist using appropriate equipment, standardised operational procedures and settings.	9.8 (0.4)	100	
C. In patients in whom there is a high clinical suspicion of GCA and a positive imaging result, the diagnosis of GCA may be made without an additional test (biopsy or further imaging). In patients with a low clinical probability and a negative imaging result, the diagnosis of GCA can be considered unlikely. In all other situations (including the case of an inconclusive imaging result), additional efforts towards a diagnosis are necessary.	9.4 (1.0)	96	
Recommendations	LoE		
1. Ultrasound of temporal and axillary arteries should be considered as the first imaging modality to investigate mural inflammatory changes in patients with suspected GCA.	1	9.6 (1.0)	96
2. High-resolution MRI or FDG-PET* can be used as alternatives to ultrasound for the assessment of cranial arteries† in patients with suspected GCA.	1	9.4 (1.1)	88
3. FDG-PET*, alternatively MRI or CT, can be used for the detection of mural inflammation or luminal changes of extracranial arteries in patients with suspected GCA.	1 (PET), 3 (CT), 5 (MRI)	9.6 (0.9)	92
4. In patients with suspected TAK, MRI to investigate mural inflammation or luminal changes should be used as the first imaging test to make a diagnosis of TAK.	3	9.5 (0.8)	96
5. FDG-PET, CT or ultrasound may be used as alternative imaging modalities in patients with suspected TAK. Ultrasound is of limited value for assessment of the thoracic aorta.	3 (CT) and 5 (PET and US)	9.7 (0.6)	100
6. Conventional angiography is not recommended for the diagnosis of GCA or TAK as it has been superseded by the previously mentioned imaging modalities.	5	9.8 (0.5)	100
7. In case of a suspected relapse of GCA or TAK, particularly when laboratory markers of disease activity are unreliable, ultrasound, FDG-PET or alternatively MRI may be considered for the assessment of vessel abnormalities. Imaging is not routinely recommended for patients in clinical and biochemical remission.	5	9.3 (1.4)	88
8. In patients with GCA or TAK, MRA, CTA or ultrasound of extracranial vessels may be used for long-term monitoring of structural damage, particularly at sites of preceding vascular inflammation. The frequency of screening as well as the imaging method applied should be decided on an individual basis.	5	9.5 (0.9)	96
Numbers in the columns 'LoA' indicate the mean and SD (in parenthesis) of the LoA (assessed on a scale from 0=no agreement to 10=full agreement), and the proportion of task force members with a score of at least 8/10.			
The LoE was assessed according to the Oxford Centre for Evidence-Based Medicine 2011 LoE <sup>22</sup> : LoE 1 indicates a systematic review of cross-sectional studies with consistently applied reference standard and blinding; LoE 3 reflects non-consecutive studies, or studies without consistently applied reference standards; LoE 5 indicates mechanism-based reasoning. Downgrading or upgrading of evidence levels is possible as detailed in reference 22.			
*FDG-PET is commonly combined with low-dose CT or CTA, optionally with MRI or MRA.			
†Cranial arteries: MRI of the head can visualise superficial temporal, posterior auricular, superficial occipital branches and vertebral arteries, and FDG-PET of the head can visualise superficial temporal, facial, maxillary, superficial occipital branches and vertebral arteries.			
CTA, CT-angiography; FDG-PET, [ <sup>18</sup> F]-fluorodeoxyglucose positron emission tomography; GCA, giant cell arteritis; LoA, level of agreement; LoE, Level of evidence; LV-GCA, large vessel GCA; MRA, MR-angiography; TAK, Takayasu arteritis.			

loss. Blindness and other ischaemic complications of GCA tend to occur almost exclusively before initiation of GC therapy.<sup>26</sup> For patients presenting with polymyalgia or systemic symptoms only and in whom GCA is a possible diagnosis, FDG-PET and MRI to detect large vessel involvement might not be available immediately when requested. One study demonstrated that the sensitivity of a FDG-PET for the diagnosis of GCA conducted 72 hours after the start of 60 mg prednisone remained equal to the pretreatment FDG-PET, but dropped to 36% after 10 days of GCs.<sup>27</sup> Similarly, ultrasound of temporal arteries performed within 1 day of GC therapy revealed a significantly higher intima-media thickness (IMT) than scans performed (in different patients) after 1 week.<sup>28</sup> The task force, therefore, concluded that imaging should best be performed before, or at least, within 72 hours after commencing GC therapy.

The task force urged rapid access to diagnostic imaging tests, commensurate with fast-track clinics for patients with suspected GCA.<sup>29–31</sup> While ultrasound has become a point-of-care tool in many of these fast-track services, long waiting lists are still a major limitation of other imaging modalities. The task force was reluctant to define case scenarios where treatment could be withheld until imaging becomes available. This would not only be counterproductive for the development of rapid access pathways for imaging, but would also expose people with GCA to an unnecessary risk of blindness and other ischaemic manifestations,

given that not all patients who develop GCA-related visual loss have characteristic symptoms of cranial GCA.<sup>32</sup>

**Overarching principle B**

Imaging examination should be done by a trained specialist using appropriate equipment, standardised operational procedures and settings.

Specific training in vasculitis imaging, rather than general training in musculoskeletal or vascular imaging, is pivotal to guarantee high-quality results.<sup>24</sup> A dedicated training curriculum for rheumatologists still has to be defined. According to expert opinion such a curriculum should include teaching about the signs and symptoms of LVV (in order to appropriately estimate the pretest probability of the disease), specific training in vascular ultrasound as well as instructions on how to correctly interpret the results of additional tests, including other imaging modalities. Recommended technical and operational parameters are detailed in [box 1](#).

**Overarching principle C**

In patients in whom there is a high clinical suspicion of GCA and a positive imaging result, the diagnosis of GCA may be made without an additional test (biopsy or further imaging). In patients with a low clinical probability and a



**Box 1 Suggestions for technical and operational parameters on imaging modalities in large vessel vasculitis**

**Ultrasound**

- ⇒ High-quality modern equipment is essential. Linear probes are recommended for supra-aortic arteries; sector or convex probes for ascending aorta; convex, sector or linear probes for the aortic arch; and convex or linear probes for abdominal aorta. Settings may vary slightly according to equipment.
- ⇒ The B-mode frequency should be ≥15 MHz (preferably ≥18 MHz) for temporal arteries and 7–15 MHz for extracranial supra-aortic arteries. Image depth should be 10–20 mm for temporal arteries and 30–40 mm for extracranial supra-aortic arteries.
- ⇒ The focus should be at the level of the artery. The B-mode gain should be adjusted to avoid anechoic appearance of the artery wall.
- ⇒ Colour Doppler is the preferred modality to show the blood flow, but other techniques may be used as well. The gain should be adjusted to avoid underfilling or overfilling of the vessel lumen.
- ⇒ Doppler frequency and pulse repetition frequency (PRF) settings depend on the equipment. Frequencies of 7–12 MHz and 4–8 MHz as well as PRFs of 2–7 KHz and 3–8 KHz are commonly applied for temporal and extracranial supra-aortic arteries, respectively. The colour box should be angled in longitudinal scans to avoid perpendicularity between sound waves and artery.

**CT\***

- ⇒ Multislice CT-scanner should be used.
- ⇒ Collimation 0.6 mm, individual tube voltage and tube current time product determined by automatic dose modulation.
- ⇒ Reconstruction slice thickness should be between 0.5 and 1.0 mm.
- ⇒ Patient and CT technology adapted injection of 50–100 mL of non-ionic iodinated contrast agent (≥350 mg/mL) using a power injector (≥4 mL/s).
- ⇒ Arterial phase: bolus-tracking method (threshold of 100 HU); ECG triggering.
- ⇒ Venous phase: 50 s after finishing the arterial phase acquisition.
- ⇒ Angulated reconstructions for assessment of individual vessel segments.

**MRI\***

**Cranial MRI technique\*\*:**

- ⇒ 3.0T MRI scanner, minimum 16-channel head-coil.
- ⇒ T1w Spin Echo, Gadolinium contrast enhanced, fat-suppressed, high-resolution (in-plane <1 mm<sup>2</sup>, eg, 195×260 μm<sup>2</sup>, slice thickness 3 mm, TR/TE 500/22 ms).
- ⇒ Transversal slices angulated parallel to skull base.
- ⇒ Reformatted 3D contrast-enhanced vessel-wall MRI may be considered.

**Body MRI technique:**

- ⇒ 1.5 T, preferentially 3.0 T MRI scanner, minimum 16-channel head and neck coil and 16-channel body-coil.
- ⇒ MR-angiography (MRA) of aorta and major branches from carotid bifurcation to abdominal and preferentially pelvic arteries in coronal acquisition to include axillary and brachial arteries → detection of vessel lumen (stenosis, occlusion, aneurysm).

Continued

**Box 1 Continued**

- ⇒ T1w, fat-suppressed, contrast enhanced, black blood imaging (eg, navigated 3D Turbo Spin Echo (TSE), spatial resolution 1.2×1.3×2 mm<sup>3</sup>, Repetition Time (TR) / Echo Time (TE) 1000/35 ms) → assessment of mural inflammation.
- [<sup>18</sup>F]-fluorodeoxyglucose positron emission tomography (FDG-PET)\*\*\*
- ⇒ Position of patient is supine, position of the arms should be arms down.
- ⇒ Body parts to include: from top of head to at least mid-thigh, preferably to below the knees.
- ⇒ Blood glucose levels: preferred <7 mmol/L (126 mg/dL), <10 mmol/L (180 mg/dL) acceptable.
- ⇒ Interval between FDG infusion and image acquisition should be at least 60 min, preferably 90–120 min.
- ⇒ For evaluation of the cranial arteries, 5 min instead of 2–3 min acquisition time of the head should be used in case of non-digital FDG-PET imaging.
- ⇒ Scoring of [<sup>18</sup>F]-FDG-uptake: qualitative visual grading; if result is unclear, compare it to the liver background (grading 0–3).
- ⇒ Digital FDG-PET may be used in order to reduce imaging time, radiation dose and to improve the image quality.
- ⇒ FDG-PET is commonly combined with low-dose CT, optionally with CT-angiography (CTA). It can also be combined with MRI or MRA.

\*CT and MRI also refer to specific angiography techniques such as CTA and MRA.

\*\*MRI of the head can visualise superficial temporal, posterior auricular, superficial occipital branches and vertebral arteries.

\*\*\*FDG-PET of the head can visualise superficial temporal, facial, maxillary, superficial occipital branches and vertebral arteries.

negative imaging result, the diagnosis of GCA can be considered unlikely. In all other situations (including the case of an inconclusive imaging result), additional efforts towards a diagnosis are necessary.

This statement is unchanged from the 2018 version.<sup>3</sup> It remains at the discretion of the clinician to determine the pretest probability for GCA, considering all available clinical and laboratory data. The precision of the pretest estimates depends largely on the experience of the clinician, which may (similar to imaging) be improved by specific training. A probability score combining demographic, clinical and laboratory parameters, as well as respective cut-offs defining low, intermediate and high probability for GCA has been proposed and initially validated by several centres<sup>33–35</sup>; however, this awaits further experience.

The present recommendation emphasises the dependence of the (post-test) diagnosis on the pretest probability and the imaging test result. While in clinical practice, a global report of the imaging exam is usually provided (‘positive’/‘negative’), the confidence in this result may vary. For instance, there is a lower confidence in a positive result for patients in whom a limited vessel wall thickening was documented compared with those with extensive swelling of several vessels. If imaging results are inconclusive, such as when wall thickness is only slightly above the normal cut-off or when arteriosclerosis complicates the assessment, additional testing is necessary to establish or exclude GCA. This is also the case if positive imaging occurs in situations with low

pretest probability. Additional testing is also important if GCA mimickers are suspected.<sup>36</sup> In some diseases such as granulomatosis with polyangiitis, lymphoma or amyloidosis, imaging abnormalities similar to those found in GCA have been described; relevant differential diagnoses need therefore to be excluded on clinical grounds, by laboratory exams and/or histology.<sup>37–40</sup>

## Recommendations

### Recommendation 1

Ultrasound of temporal and axillary arteries should be considered as the first imaging modality to investigate mural inflammatory changes in patients with suspected GCA.

Ultrasound is the first imaging modality for the diagnosis of GCA because of strong evidence for a high diagnostic value, with a pooled sensitivity from studies with low RoB of 88% and a specificity of 96%, using clinical diagnosis as the reference standard.<sup>11</sup> Furthermore, ultrasound is known for low resource consumption, easy and prompt availability in many institutions and the absence of radiation. Reliability of ultrasound findings has been high among trained experts,<sup>24 41</sup> and it was comparable to that of reading biopsies by pathologists.<sup>25</sup> The task force chose the term ‘should be considered’ rather than ‘should be used’ acknowledging that rapid conduction of ultrasound is not feasible in every setting, particularly in non-tertiary hospitals, and that not all specialists diagnosing GCA have sufficient training in this technique. In these situations, other imaging techniques can be used (see outlined below) and TAB is also an adequate alternative.<sup>3</sup>

While in 2018, a distinction was made between cranial and extracranial phenotypes, and ultrasound was recommended in first place for the former subset,<sup>3</sup> the task force now recognised that GCA represents a single disease spectrum with overlapping phenotypes.<sup>42</sup> Overall, 35%–80% of patients with dominant ‘cranial’ manifestations have large vessel involvement in imaging studies, and patients with predominantly ‘extracranial’ manifestations at disease onset might develop cranial disease at later stages.<sup>43–45</sup> The assessment of axillary arteries is now recommended for every patient with suspected GCA as it increases the diagnostic yield and can serve as a baseline for the comparison with possible future examinations. Studies (particularly with low RoB) investigating both temporal and axillary arteries revealed consistently higher sensitivities than those focusing on temporal arteries only.<sup>11</sup> In situations where a scan of temporal and axillary arteries is non-diagnostic, and the clinical suspicion for GCA is still high, additional vessels such as facial, occipital, carotid, vertebral, subclavian and femoral arteries as well as the aorta can be investigated.<sup>46–49</sup>

Ultrasound composite scores have recently been proposed for diagnostic and monitoring purposes in GCA.<sup>50 51</sup> One of these, the Southend score, positively correlated with the diagnostic specificity for GCA, and patients with higher scores were more likely to have positive TAB and visual complications than patients with lower scores.<sup>50 52</sup> The provisional OMERACT ultrasonography score (OGUS) has been developed for the follow-up of patients in research studies and will be described below.<sup>51</sup> Despite these interesting developments, the task force was reluctant to recommend any ultrasound composite score at this stage outside the research setting, encouraging their further validation.

The broad description ‘mural inflammatory changes’ was used in the update, rather than the term ‘non-compressible halo sign’ stipulated in the original recommendations.<sup>3</sup> The compression

sign for axillary and other extracranial arteries has not been tested in clinical studies so far, and patients with a new diagnosis of GCA may reveal signs of chronic vasculitis (eg, when GCA is newly diagnosed in a patient with long-standing PMR). The ultrasound appearance of chronic vasculitis has recently been described as ‘mid-hyperechoic wall thickening with a multilinear pattern’ that can clearly be distinguished from the ‘halo’ sign that is described as homogenous, hypoechoic wall thickening reflecting acute inflammation.<sup>53 54</sup> Cut-off values for the thickness of the intima-media complex have been proposed for follow-up studies (common superficial temporal artery 0.42–0.44 mm, parietal branch 0.29–0.36 mm, frontal branch 0.34 mm, axillary artery 1.0 mm (0.9 mm for chronic vasculitis)).<sup>55–58</sup> They may also aid in distinguishing normal from acute or chronic vasculitis; however, further studies are required to validate these values, particularly in people with advanced age or with severe arteriosclerosis.<sup>59–61</sup>

### Recommendation 2

High-resolution MRI or FDG-PET can be used as alternatives to ultrasound for the assessment of cranial arteries in patients with suspected GCA.

In the original recommendation,<sup>3</sup> the use of FDG-PET and CT were discouraged for the assessment of cranial arteries as there was insufficient evidence to suggest that these vessels were visible by these techniques. Since then, a number of studies supported the utility of FDG-PET for the diagnosis of temporal arteritis, and clinical experience indicates the potential visualisation of superficial cranial vessels by CT.<sup>4 5 62</sup> This technique, however, was not included in the updated recommendation because of the absence of prospective data.

The task force decided to maintain separate recommendations for cranial and extracranial arteries concerning MRI and FDG-PET. The evidence supports the use of high-resolution MRI for cranial arteries, with a pooled sensitivity of 81% and a specificity of 98% (studies with low RoB) using clinical diagnosis as reference standard,<sup>11</sup> while for FDG-PET, studies were mainly conducted to assess extracranial (and only to a lesser extent cranial) vessels. FDG-PET of cranial and extracranial arteries yielded a pooled sensitivity of 76% and a specificity of 95% (studies with low RoB) applying clinical diagnosis as reference standard.<sup>11</sup> The advantages of MRI and FDG-PET over ultrasound are a higher standardisation of data acquisition and the possibility to investigate multiple vessels at the same time. The main limitations are the restricted availability, high costs and possible adverse effects of contrast agents (MRI) and radiation (FDG-PET).<sup>63</sup>

It could be argued that MRI should still be preferred over FDG-PET to image cranial vessels given that at this site, MRI is supported by a higher number of studies. In addition, MRI does not imply radiation and, in some centres, it is available at lower costs.<sup>11</sup> Rapid availability of MRI, as specified in our overarching principles, is still restricted to a small number of centres with a special interest in the field. However, our recommendations might encourage the development of fast-track imaging pathways, including MRI or FDG-PET organised within a few days, ideally within 72 hours of commencing GC therapy.<sup>27</sup>

### Recommendation 3

FDG-PET, alternatively MRI or CT, can be used for the detection of mural inflammation or luminal changes of extracranial arteries in patients with suspected GCA.

FDG-PET should be considered the first imaging alternative to ultrasound of extracranial vessels because of evidence supporting a high diagnostic value (sensitivity 76%, specificity 95%, clinical diagnosis as reference standard),<sup>11</sup> and the possibility of detecting other serious pathologies such as infections or tumours, particularly in patients with atypical symptoms.<sup>5</sup> Although prospective evidence for the performance of MRI and CT of extracranial vessels is scarce,<sup>19</sup> some members of the task force reported their clinical experience that these techniques may be valid alternatives to ultrasound and FDG-PET when these are not available or inadequate. We intentionally listed CT as last in the list of recommended imaging modalities because there is no evidence that CT performs better than MRI in this indication, but exposes the patient to radiation.<sup>64</sup> On the other hand, there might be practical reasons why CT is preferred in certain situations such as the lower acquisition time and shorter waiting lists.

Direct comparisons between imaging modalities are scarce. One study reported that ultrasound of temporal arteries revealed a higher sensitivity than FDG-PET, while FDG-PET performed better at subclavian and carotid arteries.<sup>65</sup> At axillary arteries, ultrasound detected 76% of cases with vasculitis using FDG-PET as reference.<sup>66</sup> Another study concluded that in patients with LVV, FDG-PET better captures inflammatory activity, while MRI is better suited to assess disease extent.<sup>67</sup> These studies were not included in the SLR because of their case-control design, and their results need to be confirmed by prospective cohort studies before conclusions can be applied to clinical practice.

FDG-PET is usually combined with low-dose CT (or CTA) and optionally with MRI/MRA.<sup>68</sup> The evaluation of luminal changes is therefore possible with FDG-PET, however, MRA or CTA (without FDG-PET) may be sufficient for this indication.<sup>67</sup> A prospective comparison between MRA and CTA for the evaluation of arterial stenoses or aneurysms in GCA has not been conducted so far, and therefore, this aspect has been added to the research agenda.

#### Recommendation 4

In patients with suspected TAK, MRI to investigate mural inflammation or luminal changes should be used as the first imaging test to make a diagnosis of TAK.

#### Recommendation 5

FDG-PET, CT or ultrasound may be used as alternative imaging modalities in patients with suspected TAK. Ultrasound is of limited value for assessment of the thoracic aorta.

#### Recommendation 6

Conventional angiography is not recommended for the diagnosis of GCA or TAK as it has been superseded by the previously mentioned imaging modalities.

Recommendations 4–6, which concern the use of imaging methodologies for the diagnosis of TAK, remain largely unchanged compared with the 2018 version given the absence of new prospective data.<sup>3</sup> MRI is preferred over the other imaging modalities for the diagnosis of TAK because of the absence of radiation (taking into account that serial imaging is required in many patients) and because of the ability to investigate several vessels simultaneously, including the aorta. The descending thoracic aorta, which is frequently affected in patients with TAK, is not accessible to conventional ultrasound. Whether transoesophageal echocardiography, enabling a comprehensive assessment of the thoracic aorta, is helpful in these patients

needs to be studied further.<sup>69</sup> The task force emphasised that conventional angiography is indicated for vascular interventions rather than for diagnosis. It should be conducted in a quiescent phase of the disease.<sup>7</sup>

#### Recommendation 7

In case of a suspected relapse, particularly when laboratory markers of disease activity are unreliable, ultrasound, FDG-PET or alternatively MRI may be considered for the assessment of vessel abnormalities. Imaging is not routinely recommended for patients in clinical and biochemical remission.

Since the publication of the 2018 recommendations, several new studies have become available investigating the value of ultrasound and FDG-PET for the assessment of GCA patients during follow-up, and to a lesser extent of patients with TAK.<sup>11</sup> Two major ultrasound composite scores have been developed, the Southend score and the OGUS. Both include eight arterial segments (bilateral common, frontal and parietal branches of temporal arteries and axillary arteries) with semiquantitative (0–3) or quantitative scoring of each segment, respectively.<sup>50 51</sup> For FDG-PET, the PET Vascular Activity Score or Total Vascular Score have mostly been used, which evaluate nine (ascending, descending thoracic and abdominal aorta, aortic arch, brachiocephalic, bilateral carotids and subclavian arteries) or twelve (thoracic aorta, abdominal aorta, subclavian arteries, axillary arteries, carotid arteries, iliac arteries and femoral arteries) vascular territories, respectively, on a semiquantitative scale (0–3).<sup>70 71</sup> Most studies applying these imaging composite scores revealed a good sensitivity to change as well as moderate correlations with markers of disease activity.<sup>11 72</sup> No new studies were available for MRI in this regard.

Despite these important advances, the task force concluded that evidence is not strong enough to recommend imaging-based follow-up assessment of inflammation in all patients with LVV. Particularly, there are no studies demonstrating the added value of regular imaging of patients with GCA or TAK over clinical and laboratory monitoring alone. A specific situation in which imaging can be useful is the case of non-specific symptoms with increased inflammatory markers, or the occurrence of a new ischaemic event/worsening of disease-related ischemia. Another example is the evaluation of a possible relapse in patients treated with drugs blocking the interleukin-6 pathway, given that ESR and CRP are not clinically informative in these patients. The GUSTO trial, not included in the SLR because <20 patients were recruited, demonstrated an improvement of the IMT assessed by ultrasound after GC pulse therapy and subsequent worsening of the IMT once GCs were stopped.<sup>73 74</sup> During treatment with tocilizumab, which was started immediately after GC pulses, IMT gradually decreased.

Another indication for imaging is the identification of the disease subtype in TAK.<sup>75</sup> During the follow-up of patients with GCA or TAK, imaging could be used for the stratification of disease such as the identification of the number of vessels involved (including the aorta) and the graduation of inflammation at the single vessel, particularly in patients with refractory or relapsing disease.<sup>42</sup> An imaging composite score might be valuable for this purpose; however, all available imaging-based scores require further validation. Besides, imaging scores are used in a research setting, but have not yet been demonstrated to add value in daily clinical practice.<sup>50 51 76–78</sup>

Imaging is not routinely recommended to evaluate vascular inflammation in patients in clinical remission. Nevertheless, the interpretation of imaging results obtained at the time of a



suspected relapse can be facilitated by the comparison with a previous imaging examination, which also includes an assessment conducted at the time of inactive disease. The main reason for the reluctance of the task force to recommend imaging in patients in remission is the unclear clinical significance of persistent imaging abnormalities (reported by several studies), and whether these should lead to a change in treatment.<sup>70 77 78</sup> Some studies indicate that the risk of a clinical relapse is associated with the intensity of FDG-PET uptake in remission,<sup>71</sup> however, others did not confirm these findings.<sup>70 79</sup>

Another point of discussion was whether worsening of existing or new damage (eg, a new stenosis) may support the clinical suspicion of relapse. While this might sound intuitive, the question of whether pre-existing damage might progress independently of active inflammation is unclear yet; hence, this aspect has been added to the research agenda.

### Recommendation 8

In patients with GCA or TAK, MRA, CTA or ultrasound of extracranial vessels may be used for long-term monitoring of structural damage, particularly at sites of preceding vascular inflammation. The frequency of screening as well as the imaging method applied should be decided on an individual basis.

The key modification of this recommendation is the incorporation of the concept that vascular damage mainly occurs at sites of preceding vascular inflammation.<sup>3</sup> This suggestion is based on the results of one study of 32 GCA and 28 TAK patients, reporting that 80% of territories subsequently developing angiographic changes (stenosis or aneurysms) during follow-up displayed a significant FDG-uptake at baseline.<sup>80</sup> On the other hand, 92% of territories with baseline FDG-PET activity did not yield angiographic changes over time. The present statement should therefore not be understood as a recommendation to perform vascular screening by FDG-PET in every GCA or TAK patient at baseline given the absence of data on the cost-effectiveness of such an approach.

The term 'vascular damage' relates to all types of vascular structural deformities identified by imaging including stenosis, occlusion, dilatation and/or aneurysms, as well as arteriosclerosis and fibrosis. Aortic dilatation appears to be more common in patients with GCA than in the general population.<sup>81 82</sup> Mortality in GCA is increased in patients with aortic aneurysm and dissection as compared with those without.<sup>83</sup> Risk factors for aortic dilatation are male sex, hypertension, smoking history and imaging evidence of aortitis according to some studies,<sup>81 84</sup> while others found aneurysms more frequently among females aged under 70 years and positive TAB.<sup>82</sup> Despite the increased risk of aneurysm development, it is still unclear how many GCA patients need to be screened to prevent one additional rupture/dissection or to detect one additional aneurysm requiring surgery.<sup>85–87</sup> Another point of uncertainty is the frequency and minimum duration of screening, given that aortic dilatation may develop several years after GCA onset despite prolonged clinical remission.<sup>82 87</sup> Routine assessment of all patients for damage is therefore not recommended; the task force suggests, as in 2018, to screen patients with signs or symptoms of stenosis/occlusion or aneurysms for damage, as well as those with recurrent or persistent inflammation of large arteries including the aorta.

No recommendation was made on the value of imaging modalities for outcome prediction of patients with established GCA. The SLR retrieved five studies (three on ultrasound, two on FDG-PET) indicating that baseline imaging did neither predict

response to treatment, nor occurrence of relapses or ischaemic complications.<sup>11</sup>

None of the items listed in the research agenda published in 2018 has been sufficiently filled with evidence.<sup>3</sup> Based on the points of discussion during the current task force meeting, a research agenda has been proposed addressing new aspects that have emerged since the publication of the original imaging recommendations (see [box 2](#)).

### DISCUSSION

The EULAR recommendations for the use of imaging in LVV in clinical practice have been updated into a set of three overarching principles and eight recommendations. This update led to important changes in some statements from the original recommendations, particularly concerning the investigation of axillary arteries by ultrasound in patients with suspected GCA, the use of FDG-PET for the diagnosis of GCA and the use of imaging for the assessment of patients with GCA or TAK during follow-up.<sup>3</sup> As emphasised in 2018 and also in this manuscript, it is not the intention of the EULAR imaging recommendations to dismiss the role of TAB in GCA; however, when imaging is rapidly available and reveals clear signs that are in concordance with the clinical picture, the added value of performing a TAB is uncertain. In such situations, TAB would expose patients to an unnecessary, although small, risk of complications from the surgical procedure as well as to unnecessary GC treatment until histology results become available.<sup>88</sup> In contrast, the 2021 American College of Rheumatology/Vasculitis Foundation Guideline for the Management of GCA and TAK recommended that TAB should be the primary diagnostic test in GCA.<sup>12</sup> The ACR committee argued that 'rheumatologists and radiologists in the USA are less experienced in using ultrasound to diagnose temporal artery involvement in GCA compared with their counterparts in Europe'. This raises the question whether recommendations should reflect current reality or whether they can be aspirational and be used to promote a change of clinical routine, particularly when the supporting evidence is strong.<sup>11</sup>

The value of imaging for monitoring was one of the topics that were discussed most during the meeting. The task force recognised the need for new objective markers of inflammation in GCA and TAK, given that several new drugs directly influence acute phase reactants rendering them unreliable for the assessment of disease activity.<sup>89</sup> Studies investigating clinical+imaging-based monitoring in comparison to clinical monitoring alone, currently lacking, have therefore a high priority on the current research agenda. Another hot topic was the assessment of vascular damage during follow-up. While it is generally agreed that vascular damage including aortic dilatation is more common in patients with GCA than in the general population, it is less clear how many emergency surgical interventions or deaths from dissections can be prevented if regular imaging is conducted.<sup>82</sup> A related question is to what extent relapsing PMR with constitutional symptoms may be a reservoir for LV-GCA and unexplored vascular damage.<sup>10 42</sup> Other aspects that arose during the discussion were the value of imaging for treat-to-target strategies in GCA and TAK, the value of imaging for the assessment of treatment response in GCA, the role of artificial intelligence in evaluating images from vasculitis patients and the value of contrast-enhanced ultrasound for the assessment of vascular inflammation.<sup>50 51 90–93</sup> These aspects have been added to the research agenda which should stimulate investigators to address the numerous open questions in the field.



Box 2 Research agenda

- ⇒ To investigate and compare the value of imaging composite scores (total scores, (semi)quantitative (cut-off) scores, number of involved vessels, cranial vs extracranial vessels) for diagnosis, monitoring and prognosis of giant cell arteritis (GCA) and Takayasu arteritis (TAK).
- ⇒ To investigate the prognostic value of positive imaging findings in patients in clinical and biochemical remission, value of repeated imaging for comparison of imaging findings in remission and relapse.
- ⇒ To better investigate the added value of 'optical coherence tomography' and 'fluorescein angiography' for diagnosis and prognosis of GCA.
- ⇒ To investigate the value of ultrasound of all supra-aortic vessels as compared with the assessment of the axillary artery only, in addition to the temporal arteries.
- ⇒ To investigate the value of assessing the aorta for vasculitic involvement in patients with imaging evidence of cranial vasculitis versus extracranial vasculitis.
- ⇒ To investigate the timing at which imaging should be conducted to detect vessel wall damage.
- ⇒ To study the role of artificial intelligence in the assessment of large vessel vasculitis by various imaging methods.
- ⇒ To study positron emission tomography (PET) with novel tracers such as ligands targeting immune cells.
- ⇒ To study the influence of sodium-glucose cotransporter-2 inhibitors on [<sup>18</sup>F]-fluorodeoxyglucose-PET results.
- ⇒ To investigate the value (short-term and long-term outcomes) of imaging in addition to clinical monitoring versus clinical monitoring only.
- ⇒ To investigate the value of imaging in a treat-to-target approach in GCA and TAK.
- ⇒ To investigate the value of imaging for response assessment and correlation with patient-reported outcomes in GCA and TAK.
- ⇒ To investigate the association of imaging results with novel laboratory biomarkers in GCA and TAK.
- ⇒ To define remission of imaging results in GCA and TAK.
- ⇒ Validate cut-off values for intima-media thickness at several vessels in special patient populations such as those at advanced age or with severe arteriosclerosis.
- ⇒ To compare the performance of MR-angiography and CT-angiography for the evaluation of arterial stenoses and aneurysms in GCA and TAK.
- ⇒ To study the value of echocardiography (transthoracic and transoesophageal) for the diagnosis and follow-up of aortitis.
- ⇒ To investigate the optimal frequency and modality to screen for vascular damage in GCA and TAK patients; to identify predictors of vascular damage.
- ⇒ To determine the added value of very high-resolution ultrasound (≥50 MHz) of temporal arteries.
- ⇒ To calculate the number of patients needed to screen with imaging for preventing one additional aortic complication (aneurysm or dissection).
- ⇒ To investigate the sensitivity and specificity of imaging to detect ongoing or relapsing inflammation versus remodelling or structural damage of vessels.
- ⇒ To study the association between the progression of vascular damage and imaging detected inflammation, particularly

Continued

Box 2 Continued

- ⇒ whether inflammatory lesions at the aorta and other large arteries progress to structural damage once they are resolved.
- ⇒ To test imaging as an outcome tool in randomised controlled trials.

The voice of the patient representative (the second could not participate due to health reasons) was critical in the formulation of some recommendations. She particularly emphasised the importance of early treatment for patients with suspected LVV rather than withholding therapy until all diagnostic tests have been concluded. Also, the need for training of physicians and broad availability of imaging techniques, particularly ultrasound, were other important points emphasised by the task force.

A limitation of these recommendations is their restriction to GCA and TAK, excluding other types of LVV such as (vascular) Behçet's disease, IgG4-related disease or LVV secondary to rheumatoid arthritis or other rheumatic diseases. Another limitation is circular reasoning in some diagnostic studies, meaning that the imaging result was used (at least in part) by the clinician to establish the final diagnosis. While this is sometimes unavoidable because of the uncertainty related to the clinical diagnosis, it might lead to an overestimation of the value of the imaging technique. We, therefore, conducted subanalyses excluding studies with circular reasoning to confirm the robustness of the primary results.<sup>11</sup> Virtually no new evidence has been generated for the use of imaging in TAK, consequently, the respective recommendations remained largely unchanged.<sup>11</sup> Despite these limitations, we believe that the updated recommendations represent a step forward towards a better diagnosis and follow-up of patients with GCA and TAK.

Implementation of these recommendations is another critical step, as also emphasised by an EULAR initiative on the implementation of recommendations.<sup>94</sup> We plan to present and discuss the updated recommendations at national and international conferences, and to continue promoting training courses in imaging for these diseases at a national and international level. Anchoring imaging in training curricula for rheumatologists would also be a fundamental step to ensure implementation of these recommendations in practice. In addition, we envision adaptation of the recommendations to the local requirements, promoted by our task force members residing in different EULAR countries. We plan to assess possible barriers and facilitators to identify points for improvement. The lack of availability of technical equipment, specifically high-end ultrasound machines in the rheumatology outpatient clinics, might be an important barrier to implementation, and we hope that these recommendations will help to convince payors that adequate equipment is required to deliver high-quality care to patients with suspected GCA and TAK. The delay between the clinical consultation and the conduction of imaging as well as the percentage of patients with suspected LVV undergoing imaging might be important quality indicators for the level of implementation of these recommendations.

In summary, three overarching principles and eight recommendations are available to guide the use of imaging for the diagnosis and follow-up assessment of GCA and TAK in clinical practice. These recommendations are based on evidence and expert consensus. The research agenda is also an important product of this work, highlighting the gaps of knowledge and areas for further studies. The next update is expected to be

undertaken when sufficient new evidence has become available on imaging in LVV. It is our vision that these recommendations standardise and optimise the use of imaging in the diagnosis and assessment of people living with GCA and TAK.

#### Author affiliations

- <sup>1</sup>Department of Rheumatology and Immunology, Medical University of Graz, Graz, Austria
- <sup>2</sup>Department of Rheumatology, Teaching Hospital of the Paracelsus Medical University, Brunico Hospital (ASAA-SABES), Brunico, Italy
- <sup>3</sup>Department of Rheumatology, Leiden University Medical Center, Leiden, The Netherlands
- <sup>4</sup>Department of Rheumatology, Zuyderland Medical Centre Heerlen, Heerlen, The Netherlands
- <sup>5</sup>Department of Rheumatology, Centro Hospitalar Universitario Lisboa Norte EPE, Lisboa, Portugal
- <sup>6</sup>Rheumatology Research Unit, Instituto de Medicina Molecular, Lisboa, Portugal
- <sup>7</sup>Leeds Institute for Rheumatic and Musculoskeletal Medicine, University of Leeds, Leeds, UK
- <sup>8</sup>NIHR Leeds Biomedical Research Centre, Leeds Teaching Hospitals NHS Trust, Leeds, UK
- <sup>9</sup>Diagnostic and Interventional Radiology, University Medical Center, Wuerzburg, Germany
- <sup>10</sup>Clinical Department of General Internal Medicine Department, Research Department of Microbiology and Immunology, Laboratory of Clinical Infectious and Inflammatory Disorders, University Hospitals Leuven, Leuven, Belgium
- <sup>11</sup>General Internal Medicine Department, Universitair Ziekenhuis Gasthuisberg, Leuven, Belgium
- <sup>12</sup>Department of Medicine, Karolinska Institutet, Stockholm, Sweden
- <sup>13</sup>Department of Gastroenterology, Dermatology and Rheumatology, Karolinska University Hospital, Stockholm, Sweden
- <sup>14</sup>Department of Internal Medicine, Division of Rheumatology, Hacettepe Universitesi Tip Fakultesi, Ankara, Turkey
- <sup>15</sup>Patient Representative, Leicester, UK
- <sup>16</sup>Department of Autoimmune Diseases, Hospital Clínic, University of Barcelona. Institut d'Investigacions Biomèdiques August Pi i Sunyer (IDIBAPS), Barcelona, Spain
- <sup>17</sup>Department of Rheumatology, Hospital General Universitario Gregorio Marañón, Madrid, Spain
- <sup>18</sup>Rheumatology, Southend University Hospital NHS Foundation Trust, Basildon, UK
- <sup>19</sup>Anglia Ruskin University, Chelmsford, UK
- <sup>20</sup>Department of Rheumatology, Aarhus Universitetshospital, Aarhus, Denmark
- <sup>21</sup>Department of Medicine, Regional Hospital Horsens, Horsens, Denmark
- <sup>22</sup>Department of Rheumatology, La Paz University Hospital, Madrid, Spain
- <sup>23</sup>Department of Internal Medicine, Division of Rheumatology, Marmara University School of Medicine, Istanbul, Turkey
- <sup>24</sup>Department of Internal Medicine, Clinical Division of Internal Medicine II, Medical University of Innsbruck, Innsbruck, Austria
- <sup>25</sup>Department of Rheumatology, University Medical Centre, Ljubljana, Slovenia
- <sup>26</sup>Department of Rheumatology, University Medical Centre Ljubljana, Ljubljana, Slovenia
- <sup>27</sup>Department of Rheumatology, Cochin Hospital, Assistance Publique Hôpitaux de Paris, Paris, France
- <sup>28</sup>INSERM (U1153) Center of Research in Epidemiology and Statistics (CRESS), Université Paris-Cité, Paris, France
- <sup>29</sup>Clinic of Internal Medicine III, Section Rheumatology and Clinical Immunology, University Hospital Bonn, Bonn, Germany
- <sup>30</sup>Department of Rheumatology and Immunology, Inselspital, University Hospital Bern, University of Bern, Bern, Switzerland
- <sup>31</sup>Medical Imaging Centre, Department of Nuclear Medicine and Molecular Imaging, University Medical Center, Groningen, The Netherlands
- <sup>32</sup>Department of Biomedical Photonic Imaging, Universiteit Twente, Enschede, The Netherlands
- <sup>33</sup>Department of Rheumatology, Immanuel Krankenhaus Berlin, Medical Centre for Rheumatology Berlin-Buch, Berlin, Germany

**Twitter** Sofia Ramiro @sofiaramiro82, Philipp Bosch @philipp\_j\_bosch, Cristina Ponte @cristinadponte, Sarah Louise Mackie @Sarah\_L\_Mackie, Ertugrul Cagri Bolek @ertugrul\_cagri, Juan Molina-Collada @jmolinacollada, Bhaskar Dasgupta @profbdasgupta and Anna Molto @annamolto

**Acknowledgements** The authors would like to thank Louise Falzon for her work in the development of the literature search strategy. We also thank Lorna Neill, Luca Cimino and Fabrizio Gozzi for their help with the update of the PICO questions.

**Contributors** All authors were involved in the discussion and formulation of the recommendations. CDejaco wrote the first version of the manuscript. All authors reviewed it and made extensive comments and appropriate changes to it. All authors approved the final version of the manuscript.

**Funding** Funding was provided by the European Alliance of Associations for Rheumatology (Project number: QoC13).

**Disclaimer** The views expressed in this article are those of the authors and not necessarily those of the NIHR, the NIHR Leeds Biomedical Research Centre, the National Health Service or the UK Department of Health and Social Care.

**Competing interests** CDejaco has received consulting/speaker's fees from Abbvie, Eli Lilly, Janssen, Novartis, Pfizer, Roche, Galapagos, Sparrow and Sanofi; grant support from AbbVie and Novartis, all unrelated to this manuscript. He is an editorial board member of ARD. SR has received research grants and/or consultancy fees from AbbVie, Eli Lilly, Galapagos, MSD, Novartis, Pfizer, Sanofi, UCB. MB: consultancy fees from AbbVie PB has received speaker fees by Janssen and project grants by Pfizer. CP has received research grants and/or consultancy fees from AbbVie, Vifor, Roche, GlaxoSmithKline and AstraZeneca, all unrelated to this manuscript. SLM reports: Consultancy on behalf of her institution for Roche/Chugai, Sanofi, AbbVie, AstraZeneca; Investigator on clinical trials for Sanofi, GSK, Sparrow; speaking/lecturing on behalf of her institution for Roche/Chugai, Vifor, Pfizer and Novartis; chief investigator on STERLING-PMR trial, funded by NIHR; patron of the charity PMRGCAuk. No personal remuneration was received for any of the above activities. Support from Roche/Chugai to attend EULAR2019 in person and from Pfizer to attend ACR Convergence 2021 virtually. SLM is supported in part by the NIHR Leeds Biomedical Research Centre. TAB reports research grants from Deutsche Forschungsgemeinschaft (DFG) and Siemens Healthineers on behalf of his Department. He has received consulting/speaker's fees from BioTel Research, Chugai, Guerbet, Novartis, Roche, Sanofi and Siemens Healthineers. DB consultancy fees from Roche and GSK Sara Brolin: Grant from Novartis. MCC has received consulting fees from GSK, SCL-Vifor, AbbVie, AstraZeneca and Janssen, and a research grant from Kiniksa Pharmaceuticals. JM-C has received consulting/speaker's fees from Abbvie, Lilly, Janssen, Novartis, Pfizer, UCB, MSD, all unrelated to this manuscript. BD has received consultancies and educational grants from Novartis, Abbvie, Roche, Chugai, Sanofi. BDN has received consulting/speaker's fees from Roche and Novartis all unrelated to this manuscript. EDM Research funding/consulting and conferences fees from: Abbvie, Novartis, Pfizer, Roche, Janssen, Lilly, MSD, BMS, UCB, Grunental and Sanofi. CDuftner has received consulting/speaker's fees from Abbvie, AOP Orphan, Astra-Zeneca, Bristol-Myers-Squibb, Eli-Lilly, Janssen, Galapagos, Merck-Sharp-Dohme, Novartis, Pfizer, Roche, Sandoz, UCB, Vifor, and grant/research support from Eli-Lilly, Pfizer, UCB Haner Direskeneli is investigator in clinical trials for Abbvie and Novartis, had educational support from Pfizer, Amgen, Celltrion, UCB and Roche unrelated to this manuscript. AM has received research grants and/or consultancy fees from AbbVie, BMS, Biogen, Eli Lilly, Galapagos, Janssen, MSD, Novartis and UCB. LS has received grant support from the Swiss Society of Rheumatology, iQone and Sandoz and support for travel expenses from Sanofi; all unrelated to this manuscript. RHJAS has received independent research grants of Siemens Healthineers and WAS has received consultancy fees, honoraria and travel expenses from Abbvie, Chugai, GlaxoSmithKline, Medac, Novartis, Roche, and Sanofi and is principal investigator in trials sponsored by Abbvie, GlaxoSmithKline, Novartis and Sanofi.

**Patient and public involvement statement** Patient research partners were involved in the design, conduct, reporting, and dissemination plans of this research.

**Patient consent for publication** Not applicable.

**Provenance and peer review** Not commissioned; externally peer reviewed.

**Supplemental material** This content has been supplied by the author(s). It has not been vetted by BMJ Publishing Group Limited (BMJ) and may not have been peer-reviewed. Any opinions or recommendations discussed are solely those of the author(s) and are not endorsed by BMJ. BMJ disclaims all liability and responsibility arising from any reliance placed on the content. Where the content includes any translated material, BMJ does not warrant the accuracy and reliability of the translations (including but not limited to local regulations, clinical guidelines, terminology, drug names and drug dosages), and is not responsible for any error and/or omissions arising from translation and adaptation or otherwise.

#### ORCID iDs

Christian Dejaco <http://orcid.org/0000-0002-0173-0668>  
 Sofia Ramiro <http://orcid.org/0000-0002-8899-9087>  
 Milena Bond <http://orcid.org/0000-0002-5400-2955>  
 Philipp Bosch <http://orcid.org/0000-0002-6783-6422>  
 Cristina Ponte <http://orcid.org/0000-0002-3989-1192>  
 Daniel Blockmans <http://orcid.org/0000-0001-9783-1780>  
 Sara Brolin <http://orcid.org/0000-0002-1815-6033>  
 Ertugrul Cagri Bolek <http://orcid.org/0000-0003-3886-2813>  
 Maria C Cid <http://orcid.org/0000-0002-4730-0938>  
 Juan Molina-Collada <http://orcid.org/0000-0001-5191-7802>  
 Bhaskar Dasgupta <http://orcid.org/0000-0002-5523-6534>  
 Eugenio De Miguel <http://orcid.org/0000-0001-5146-1964>  
 Haner Direskeneli <http://orcid.org/0000-0003-2598-5806>  
 Christina Duftner <http://orcid.org/0000-0003-3137-8834>  
 Alojzija Hočvar <http://orcid.org/0000-0002-7361-6549>

Anna Molto <http://orcid.org/0000-0003-2246-1986>  
 Valentin Sebastian Schäfer <http://orcid.org/0000-0002-6591-5936>  
 Wolfgang A Schmidt <http://orcid.org/0000-0001-7831-8738>

REFERENCES

- 1 Berti A, Dejaco C. Update on the epidemiology, risk factors, and outcomes of systemic Vasculitides. *Best Pract Res Clin Rheumatol* 2018;32:271–94.
- 2 Pugh D, Karabayas M, Basu N, et al. Large-vessel vasculitis. *Nat Rev Dis Primers* 2022;7:93.
- 3 Dejaco C, Ramiro S, Duftner C, et al. EULAR recommendations for the use of imaging in large vessel vasculitis in clinical practice. *Ann Rheum Dis* 2018;77:636–43.
- 4 Nielsen BD, Hansen IT, Kramer S, et al. Simple dichotomous assessment of cranial artery inflammation by conventional 18F-FDG PET/CT shows high accuracy for the diagnosis of giant cell arteritis: a case-control study. *Eur J Nucl Med Mol Imaging* 2019;46:184–93.
- 5 Sammel AM, Hsiao E, Schembri G, et al. Diagnostic accuracy of positron emission tomography/computed tomography of the head, neck, and chest for giant cell arteritis: a prospective, double-blind, cross-sectional study. *Arthritis Rheumatol* 2019;71:1319–28.
- 6 Nienhuis PH, Sandovici M, Glaudemans AW, et al. Visual and semiquantitative assessment of cranial artery inflammation with FDG-PET/CT in giant cell arteritis. *Semin Arthritis Rheum* 2020;50:616–23.
- 7 Hellmich B, Agueda A, Monti S, et al. 2018 update of the EULAR recommendations for the management of large vessel vasculitis. *Ann Rheum Dis* 2020;79:19–30.
- 8 Misra DP, Singh K, Rathore U, et al. The effectiveness of tocilizumab and its comparison with tumor necrosis factor alpha inhibitors for takayasu arteritis: a systematic review and meta-analysis. *Autoimmun Rev* 2023;22:103275.
- 9 Dasgupta B, Unizony S, Warrington KJ, et al. Lb0006 Sarilumab in patients with relapsing Polymyalgia Rheumatica: a phase 3 multicenter, randomized, double blind, placebo controlled trial (Saphyr). *Ann Rheum Dis* 2022;81:210.
- 10 Tomelleri A, van der GeestKSM, Khurshid MA, et al. Disease stratification in giant cell arteritis and polymyalgia rheumatica: state of the art and future perspectives. *Nat Rev Rheumatol* 2023;19:446–59.
- 11 Bosch P, Bond M, Dejaco C, et al. Imaging in diagnosis, monitoring and outcome prediction of large vessel vasculitis: a systematic literature review and meta-analysis informing the 2023 update of the EULAR recommendations. *Ann Rheum Dis* 2023;82:124–5.
- 12 Maz M, Chung SA, Abril A, et al. 2021 American college of rheumatology/vasculitis foundation guideline for the management of giant cell arteritis and takayasu arteritis. *Arthritis Care Res (Hoboken)* 2021;73:1071–87.
- 13 Mackie SL, Dejaco C, Appenzeller S, et al. British society for rheumatology guideline on diagnosis and treatment of giant cell arteritis: executive summary. *Rheumatology (Oxford)* 2020;59:487–94.
- 14 Haaverset AB, Brekke LK, Bakland G, et al. Norwegian society of rheumatology recommendations on diagnosis and treatment of patients with giant cell arteritis. *Front Med (Lausanne)* 2022;9.
- 15 Ughi N, Padoan R, Crotti C, et al. The Italian society of rheumatology clinical practice guidelines for the management of large vessel vasculitis. *Reumatismo* 2022;73.
- 16 Schirmer JH, Aries PM, Balzer K, et al. S2K-Leitlinie: management der Großgefäßvaskulitiden. *Z Rheumatol* 2020;79:67–95.
- 17 van der Heijde D, Aletaha D, Carmona L, et al. Update of the EULAR standardised operating procedures for EULAR-endorsed recommendations. *Ann Rheum Dis* 2015;74:8–13.
- 18 EULAR council. Standard EULAR procedure (Sops) for recommendation projects. 2022. Available: <https://www.eular.org/document/share/228/44d096ad-57d8-45db-bf73-284d6fff4db4> [Accessed 16 Feb 2023].
- 19 Duftner C, Dejaco C, Sepriano A, et al. Imaging in diagnosis, monitoring and outcome prediction of large vessel vasculitis: a systematic literature review and meta-analysis informing the EULAR recommendations. *RMD Open* 2018;4.
- 20 Whiting PF, Rutjes AWS, Westwood ME, et al. QUADAS-2: a revised tool for the quality assessment of diagnostic accuracy studies. *Ann Intern Med* 2011;155:529–36.
- 21 Hayden JA, Côté P, Bombardier C. Evaluation of the quality of prognosis studies in systematic reviews. *Ann Intern Med* 2006;144:427–37.
- 22 OCEBM levels of evidence working group. The Oxford 2011 levels of evidence. 2011. Available: <https://www.cebm.ox.ac.uk/resources/levels-of-evidence/ocebml-levels-of-evidence>
- 23 De Miguele, Castillo C, Rodríguez A, et al. Learning and reliability of colour doppler ultrasound in giant cell arteritis. *Clin Exp Rheumatol*;27:S53–8.
- 24 Chrysidis S, Terslev L, Christensen R, et al. Vascular ultrasound for the diagnosis of giant cell arteritis: a Reliability and agreement study based on a standardised training programme. *RMD Open* 2020;6.
- 25 Luqmani R, Lee E, Singh S, et al. The role of ultrasound compared to biopsy of temporal arteries in the diagnosis and treatment of giant cell arteritis (TABUL): a diagnostic accuracy and cost-effectiveness study. *Health Technol Assess* 2016;20:1–238.
- 26 Salvarani C, Cimino L, Macchioni P, et al. Risk factors for visual loss in an Italian population-based cohort of patients with giant cell arteritis. *Arthritis Rheum* 2005;53:293–7.
- 27 Nielsen BD, Gormsen LC, Hansen IT, et al. Three days of high-dose glucocorticoid treatment attenuates large-vessel 18F-FDG uptake in large-vessel giant cell arteritis but with a limited impact on diagnostic accuracy. *Eur J Nucl Med Mol Imaging* 2018;45:1119–28.
- 28 Ponte C, Serafim AS, Monti S, et al. Early variation of ultrasound halo sign with treatment and relation with clinical features in patients with giant cell arteritis. *Rheumatology (Oxford)* 2020;59:3717–26.
- 29 Patil P, Williams M, Maw WW, et al. Fast track pathway reduces sight loss in giant cell arteritis: results of a longitudinal observational cohort study. *Clin Exp Rheumatol* 2015;33:S103–6.
- 30 Diamantopoulos AP, Haugeberg G, Lindland A, et al. The fast-track ultrasound clinic for early diagnosis of giant cell arteritis significantly reduces permanent visual impairment: towards a more effective strategy to improve clinical outcome in giant cell arteritis. *Rheumatology (Oxford)* 2016;55:66–70.
- 31 Monti S, Bartoletti A, Bellis E, et al. Fast-track ultrasound clinic for the diagnosis of giant cell arteritis changes the prognosis of the disease but not the risk of future relapse. *Front Med (Lausanne)* 2020;7.
- 32 Baalbaki H, Jalaledin D, Lachance C, et al. Characterization of visual manifestations and identification of risk factors for permanent vision loss in patients with giant cell arteritis. *Clin Rheumatol* 2021;40:3207–17.
- 33 Laskou F, Coath F, Mackie SL, et al. A probability score to aid the diagnosis of suspected giant cell arteritis. *Clin Exp Rheumatol* 2019;37 Suppl 117:104–8.
- 34 Sebastian A, Tomelleri A, Kayani A, et al. Probability-based algorithm using ultrasound and additional tests for suspected GCA in a fast-track clinic. *RMD Open* 2020;6.
- 35 Melville AR, Donaldson K, Dale J, et al. Validation of the Southend giant cell arteritis probability score in a Scottish single-centre fast-track pathway. *Rheumatol Adv Pract* 2022;6.
- 36 Griner PF, Mayewski RJ, Mushlin AI, et al. Selection and interpretation of diagnostic tests and procedures. *Ann Intern Med* 1981;94:557–92.
- 37 Fernández-Fernández E, Monjo-Henry I, Bonilla G, et al. False positives in the ultrasound diagnosis of giant cell arteritis: some diseases can also show the halo sign. *Rheumatology (Oxford)* 2020;59:2443–7.
- 38 Lötscher F, Pop R, Seitz P, et al. Spectrum of Large- and medium-vessel vasculitis in adults: neoplastic, infectious, drug-induced, autoinflammatory, and primary immunodeficiency diseases. *Curr Rheumatol Rep* 2022;24:293–309.
- 39 Seitz L, Seitz P, Pop R, et al. Spectrum of large and medium vessel vasculitis in adults: primary vasculitides, arthritides, connective tissue, and fibroinflammatory diseases. *Curr Rheumatol Rep* 2022;24:352–70.
- 40 Molina Collada J, Ruiz Bravo-Burquillos E, Monjo I, et al. Positive ultrasound halo sign of temporal arteries due to amyloidosis. *Rheumatology (Oxford)* 2019;58:2067–9.
- 41 Schäfer VS, Chrysidis S, Dejaco C, et al. Assessing vasculitis in giant cell arteritis by ultrasound: results of OMERACT patient-based reliability exercises. *J Rheumatol* 2018;45:1289–95.
- 42 Tomelleri A, van der Geest KSM, Sebastian A, et al. Disease stratification in giant cell arteritis to reduce relapses and prevent long-term vascular damage. *The Lancet Rheumatology* 2021;3:e886–95.
- 43 Prieto-González S, Depetris M, García-Martínez A, et al. Positron emission tomography assessment of large vessel inflammation in patients with newly diagnosed, biopsy-proven giant cell arteritis: a prospective, case-control study. *Ann Rheum Dis* 2014;73:1388–92.
- 44 Narváez J, Estrada P, López-Vives L, et al. Prevalence of ischemic complications in patients with giant cell arteritis presenting with apparently isolated Polymyalgia Rheumatica. *Semin Arthritis Rheum* 2015;45:328–33.
- 45 Fernández-Fernández E, Monjo I, Peiteado D, et al. Validity of the EULAR recommendations on the use of ultrasound in the diagnosis of giant cell arteritis. *RMD Open* 2022;8.
- 46 Diamantopoulos AP, Haugeberg G, Hetland H, et al. Diagnostic value of color doppler ultrasonography of temporal arteries and large vessels in giant cell arteritis: a consecutive case series. *Arthritis Care Res (Hoboken)* 2014;66:113–9.
- 47 Chrysidis S, Dohn UM, Terslev L, et al. Diagnostic accuracy of vascular ultrasound in patients with suspected giant cell arteritis (EUREKA): a prospective, multicentre, non-Interventional, cohort study. *The Lancet Rheumatology* 2021;3:e865–73.
- 48 Ješe R, Rotar Ž, Tomšič M, et al. The role of colour Doppler Ultrasonography of facial and occipital arteries in patients with giant cell arteritis: a prospective study. *Eur J Radiol* 2017;95:9–12.
- 49 Palmers P-J, Ameloot K, De Wever W, et al. An echocardiographic finding leading to the diagnosis of giant cell arteritis. *Eur Heart J Cardiovasc Imaging* 2013;14.
- 50 van der Geest KSM, Borg F, Kayani A, et al. Novel ultrasonographic halo score for giant cell arteritis: assessment of diagnostic accuracy and association with ocular ischaemia. *Ann Rheum Dis* 2020;79:393–9.
- 51 Dejaco C, Ponte C, Monti S, et al. The provisional OMERACT Ultrasonography score for giant cell arteritis. *Ann Rheum Dis* 2022.
- 52 van der Geest KSM, Wolfe K, Borg F, et al. Ultrasonographic halo score in giant cell arteritis: association with intimal hyperplasia and ischaemic sight loss. *Rheumatology (Oxford)* 2021;60:4361–6.



- 53 Chrysidis S, Duftner C, Dejaco C, *et al.* Definitions and reliability assessment of elementary ultrasound lesions in giant cell arteritis: a study from the OMERACT large vessel vasculitis ultrasound working group. *RMD Open* 2018;4.
- 54 Schäfer VS, Chrysidis S, Schmidt WA, *et al.* OMERACT definition and reliability assessment of chronic ultrasound lesions of the Axillary artery in giant cell arteritis. *Semin Arthritis Rheum* 2021;51:951–6.
- 55 Bosch P, Dejaco C, Schmidt WA, *et al.* Ultrasound for diagnosis and follow-up of chronic Axillary vasculitis in patients with long-standing giant cell arteritis. *Ther Adv Musculoskelet Dis* 2021;13.
- 56 Ješe R, Rotar Ž, Tomšič M, *et al.* The cut-off values for the intima-media complex thickness assessed by colour doppler sonography in seven cranial and aortic arch arteries. *Rheumatology (Oxford)* 2021;60:1346–52.
- 57 Schäfer VS, Juche A, Ramiro S, *et al.* Ultrasound cut-off values for intima-media thickness of temporal, facial and axillary arteries in giant cell arteritis. *Rheumatology (Oxford)* 2017;56:1632.
- 58 López-Gloria K, Castrejón I, Nieto-González JC, *et al.* Ultrasound intima media thickness cut-off values for cranial and Extracranial arteries in patients with suspected giant cell arteritis. *Front Med (Lausanne)* 2022;9.
- 59 De Miguel E, Beltran LM, Monjo I, *et al.* Atherosclerosis as a potential pitfall in the diagnosis of giant cell arteritis. *Rheumatology (Oxford)* 2018;57:318–21.
- 60 Milchert M, Flicinski J, Brzosko M. Intima-media thickness cut-off values depicting 'halo sign' and potential Confounder analysis for the best diagnosis of large vessel giant cell arteritis by ultrasonography. *Front Med (Lausanne)* 2022;9.
- 61 Molina-Collada J, López Gloria K, Castrejón I, *et al.* Impact of cardiovascular risk on the diagnostic accuracy of the ultrasound halo score for giant cell arteritis. *Arthritis Res Ther* 2022;24:232.
- 62 Conway R, Smyth AE, Kavanagh RG, *et al.* Diagnostic utility of computed tomographic angiography in giant-cell arteritis. *Stroke* 2018;49:2233–6.
- 63 American College of Radiology. ACR manual on contrast media. Available: 2022. [https://www.acr.org/-/media/ACR/Files/Clinical-Resources/Contrast\\_Media.pdf](https://www.acr.org/-/media/ACR/Files/Clinical-Resources/Contrast_Media.pdf) [Accessed 16 Feb 2023].
- 64 European Union Council. Council directive 2013/59/Euratom of 5 December 2013 laying down basic safety standards for protection against the dangers arising from exposure to ionising radiation, and repealing Directives 89/618/Euratom, 90/641/Euratom, 96/29/Euratom, 97/43/Euratom a. 2014. Available: <http://data.europa.eu/eli/dir/2013/59/oj>
- 65 Imfeld S, Aschwanden M, Rottenburger C, *et al.* [18F]FDG positron emission tomography and ultrasound in the diagnosis of giant cell arteritis: congruent or complementary imaging methods. *Rheumatology (Oxford)* 2020;59:772–8.
- 66 Nielsen BD, Hansen IT, Keller KK, *et al.* Diagnostic accuracy of ultrasound for detecting large-vessel giant cell arteritis using FDG PET/CT as the reference. *Rheumatology (Oxford)* 2020;59:2062–73.
- 67 Quinn KA, Ahlman MA, Malayeri AA, *et al.* Comparison of magnetic resonance angiography and <sup>18</sup>F-fluorodeoxyglucose positron emission tomography in large-vessel vasculitis. *Ann Rheum Dis* 2018;77:1165–71.
- 68 Laurent C, Ricard L, Fain O, *et al.* PET/MRI in large-vessel vasculitis: clinical value for diagnosis and assessment of disease activity. *Sci Rep* 2019;9.
- 69 Bezerra Lira-Filho E, Campos O, Lazaro Andrade J, *et al.* Thoracic aorta evaluation in patients with takayasu's arteritis by transesophageal echocardiography. *J Am Soc Echocardiogr* 2006;19:829–34.
- 70 Blockmans D, de Ceuninck L, Vanderschueren S, *et al.* Repetitive 18F-fluorodeoxyglucose positron emission tomography in giant cell arteritis: a prospective study of 35 patients. *Arthritis Rheum* 2006;55:131–7.
- 71 Grayson PC, Alehashemi S, Bagheri AA, *et al.* <sup>18</sup>F-Fluorodeoxyglucose-positron emission tomography as an imaging biomarker in a prospective, longitudinal cohort of patients with large vessel vasculitis. *Arthritis Rheumatol* 2018;70:439–49.
- 72 Nielsen BD, Therkildsen P, Keller KK, *et al.* Ultrasonography in the assessment of disease activity in cranial and large-vessel giant cell arteritis: a prospective follow-up study. *Rheumatology (Oxford)* 2023.
- 73 Seitz L, Christ L, Lötscher F, *et al.* Quantitative ultrasound to monitor the vascular response to tocilizumab in giant cell arteritis. *Rheumatology (Oxford)* 2021;60:5052–9.
- 74 Christ L, Seitz L, Scholz G, *et al.* Tocilizumab monotherapy after ultra-short glucocorticoid administration in giant cell arteritis: a single-arm, open-label, proof-of-concept study. *The Lancet Rheumatology* 2021;3:e619–26.
- 75 Hata A, Noda M, Moriwaki R, *et al.* Angiographic findings of takayasu arteritis: new classification. *Int J Cardiol* 1996;54:S155–63.
- 76 Dashora HR, Rosenblum JS, Quinn KA, *et al.* Comparing semiquantitative and qualitative methods of vascular <sup>18</sup>F-FDG PET activity measurement in large-vessel vasculitis. *J Nucl Med* 2022;63:280–6.
- 77 Sammel AM, Hsiao E, Schembri G, *et al.* Cranial and large vessel activity on positron emission tomography scan at diagnosis and 6 months in giant cell arteritis. *Int J Rheum Dis* 2020;23:582–8.
- 78 Quinn KA, Dashora H, Novakovich E, *et al.* Use of 18F-fluorodeoxyglucose positron emission tomography to monitor Tocilizumab effect on vascular inflammation in giant cell arteritis. *Rheumatology (Oxford)* 2021;60:4384–9.
- 79 Galli E, Muratore F, Mancuso P, *et al.* The role of PET/CT in disease activity assessment in patients with large vessel vasculitis. *Rheumatology (Oxford)* 2022;61:4809–16.
- 80 Quinn KA, Ahlman MA, Alessi HD, *et al.* Association of 18 F-Fluorodeoxyglucose-positron emission tomography activity with angiographic progression of disease in large vessel vasculitis. *Arthritis Rheumatol* 2023;75:98–107.
- 81 Robson JC, Kiran A, Maskell J, *et al.* The relative risk of aortic aneurysm in patients with giant cell arteritis compared with the general population of the UK. *Ann Rheum Dis* 2015;74:129–35.
- 82 Therkildsen P, de Thurah A, Nielsen BD, *et al.* Increased risk of thoracic aortic complications among patients with giant cell arteritis: a nationwide, population-based cohort study. *Rheumatology (Oxford)* 2022;61:2931–41.
- 83 Aouba A, Gonzalez Chiappe S, Eb M, *et al.* Mortality causes and trends associated with giant cell arteritis: analysis of the French national death certificate database (1980-2011). *Rheumatology (Oxford)* 2018;57:1047–55.
- 84 Blockmans D, Coudyzer W, Vanderschueren S, *et al.* Relationship between fluorodeoxyglucose uptake in the large vessels and late aortic diameter in giant cell arteritis. *Rheumatology (Oxford)* 2008;47:1179–84.
- 85 Jud P, Verheyen N, Dejaco C, *et al.* Prevalence and Prognostic factors for aortic dilatation in giant cell arteritis - a longitudinal study. *Semin Arthritis Rheum* 2021;51:911–8.
- 86 García-Martínez A, Hernández-Rodríguez J, Arguis P, *et al.* Development of aortic aneurysm/dilatation during the followup of patients with giant cell arteritis: a cross-sectional screening of fifty-four prospectively followed patients. *Arthritis Rheum* 2008;59:422–30.
- 87 García-Martínez A, Arguis P, Prieto-González S, *et al.* Prospective long term follow-up of a cohort of patients with giant cell arteritis screened for aortic structural damage (aneurysm or dilatation). *Ann Rheum Dis* 2014;73:1826–32.
- 88 Gunawardene AR, Chant H. Facial nerve injury during temporal artery biopsy. *Ann R Coll Surg Engl* 2014;96:257–60.
- 89 Stone J, Tuckwell K, Dimonaco S, *et al.* Tocilizumab for sustained glucocorticoid-free remission in giant cell arteritis. *N Engl J Med* 2017;377:317–28.
- 90 Dejaco C, Ramiro S, Touma Z, *et al.* What is a response in randomised controlled trials in giant cell arteritis. *Ann Rheum Dis* 2023;82:897–900.
- 91 Dejaco C, Kerschbaumer A, Aletaha D, *et al.* Treat-to-target recommendations in giant cell arteritis and Polymyalgia Rheumatica. *Ann Rheum Dis* 2023.
- 92 Roncato C, Perez L, Brochet-Guégan A, *et al.* Colour doppler ultrasound of temporal arteries for the diagnosis of giant cell arteritis: a multicentre deep learning study. *Clin Exp Rheumatol* 2020;38:120–5.
- 93 Ding J, Wu D, Han Q, *et al.* Follow-up contrast-enhanced ultrasonography of the carotid artery in patients with takayasu arteritis: a retrospective study. *J Rheumatol* 2022;49:1242–9.
- 94 Loza E, Carmona L, Woolf A, *et al.* Implementation of recommendations in rheumatic and musculoskeletal diseases: considerations for development and uptake. *Ann Rheum Dis* 2022;81:1344–7.