



Universiteit  
Leiden  
The Netherlands

## **Clinical outcomes and graft survival after Descemet membrane endothelial keratoplasty**

Vasiliauskaite, I.

### **Citation**

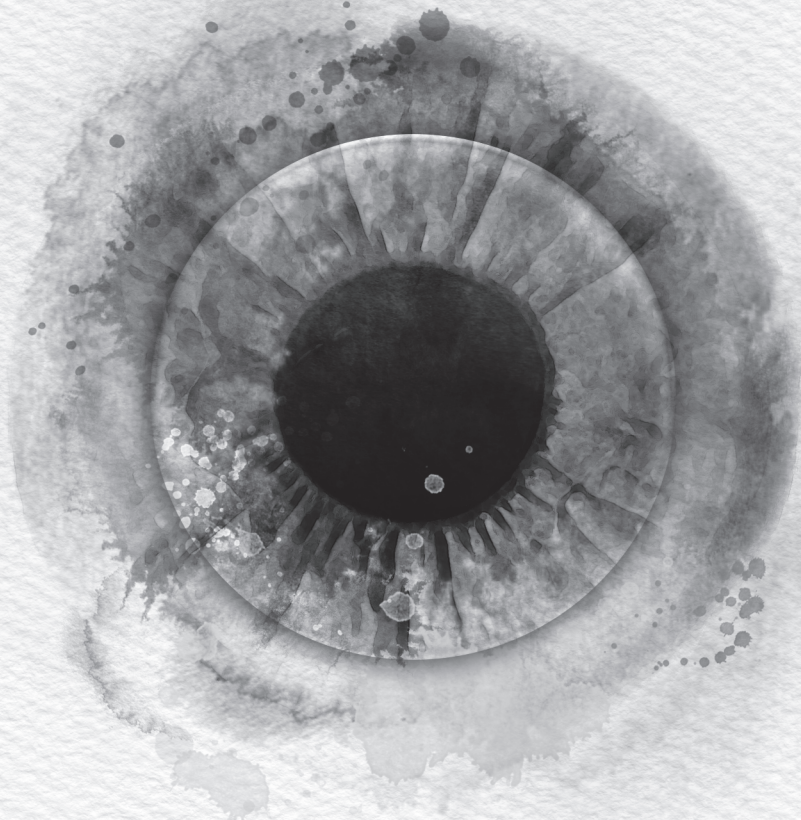
Vasiliauskaite, I. (2024, March 21). *Clinical outcomes and graft survival after Descemet membrane endothelial keratoplasty*. Retrieved from <https://hdl.handle.net/1887/3729753>

Version: Publisher's Version

License: [Licence agreement concerning inclusion of doctoral thesis in the Institutional Repository of the University of Leiden](#)

Downloaded from: <https://hdl.handle.net/1887/3729753>

**Note:** To cite this publication please use the final published version (if applicable).



# **Chapter 7**

---

Summary, discussion  
and future perspectives



## SUMMARY, DISCUSSION AND FUTURE PERSPECTIVES

Corneal blindness is one of the leading causes of blindness worldwide and especially occurs in elderly people. With aging populations, the lack of available corneal tissue and the demand for transplantation continues to increase. In 2016, a global survey of corneal transplantation and eye banking estimated that on average, one cornea is available per 70 patients in need, resulting in long waiting lists or no treatment at all.<sup>1</sup> The survey also reported strong differences between countries in terms of donor tissue availability with some countries having a surplus of donor tissue which allows them to export tissue and alleviate the shortage in other countries. In the Netherlands, the availability of corneal donor tissue is currently sufficient, but the percentage of donated corneas is still relatively low. The main reasons for the limited donation rates in the Netherlands were low donor registration rates or high refusal rates among relatives, and strict criteria for tissue donation.<sup>2</sup> Even after tissue procurement, corneal tissue may not be released for transplantation and discarded due to a positive microbiological culture or inferior endothelial cell quality or morphology.<sup>3</sup>

In 2018, the Dutch Transplant Foundation (Nederlandse Transplantatie Stichting; NTS) updated the criteria for corneal tissue donation by removing bacterial sepsis as contra-indication for donating corneas.<sup>4</sup> However, other countries still decline septic donor tissues due to the possible risk of postoperative endophthalmitis and unknown clinical outcomes after transplantation. In **Chapter 2**, we presented the discard rates for organ-cultured septic versus non-septic donor corneas and compared DMEK clinical outcomes, such as endothelial cell density (ECD), central corneal thickness (CCT), and complication rates for DMEK grafts prepared from septic versus non-septic donor corneas.<sup>5</sup> We observed that primary discard rates in the eye bank were higher for corneas from the septic group, with the main reason for discard being the poor endothelial cell quality. The 6-months postoperative ECD was lower in the septic donor group compared to non-septic donors, yet this difference did not reach statistical significance. In addition, no differences in the postoperative CCT or re-bubbling rates were seen between septic and non-septic donor corneas. Also, none of the transplanted grafts showed signs of rejection or endophthalmitis. These results suggested that with strict adherence to proper

donor screening and evaluation, the use of organ-cultured corneas from septic donors does not seem to increase the risk for the recipient after DMEK. Nevertheless, longer and larger scale studies will be needed to assess the effect of donor sepsis on the long-term outcomes as well, especially regarding the postoperative ECD. Removing sepsis as a contraindication for donation in the Netherlands in 2018 has increased the number of corneal donors by 62%, shortened the waiting time by 12%, and increased the number of corneal transplants by 17%.<sup>2,4</sup> With this in mind, if more contraindications were re-evaluated, the pool of corneal donors might expand even further, and it might help to better meet the worldwide demand for endothelial grafts.

The percentage of endothelial keratoplasties continues to rise compared to the percentage of penetrating keratoplasties.<sup>6,7</sup> This also leads to an increase in the total number of corneal transplantations performed annually since endothelial keratoplasty is often performed at an earlier disease stage due to the better and more predictable visual outcome. While earlier, with penetrating keratoplasty, subjective improvement in patient's vision was often considered an acceptable result, nowadays, patients often expect excellent near, intermediate, and distance vision of 20/20. However, patients with endothelial disorders often present with crystalline lens opacifications, which impair visual outcome. In these cases, patients are first advised to undergo phacoemulsification and lens implantation, hoping to achieve a significantly better vision through cataract extraction alone, potentially delaying the need for endothelial keratoplasty. Another motivation for performing phacoemulsification even in the absence of a clinically significant cataract was in some cases to deepen the anterior chamber and to avoid potential graft damage in case of cataract formation after DMEK. Yet, for younger patients without significant cataracts, phacoemulsification may not be indicated: these patients would benefit from preserving accommodation and avoiding potential complications after phacoemulsification, such as posterior capsule opacification and retinal detachment, for which a younger age has been shown to be a risk factor.<sup>8-10</sup> For these cases, phakic DMEK could be performed instead to preserve the space in the anterior chamber and delay the risk of cataract removal complications. However, surgical manipulations during DMEK and postoperative steroid use may increase the risk for postoperative cataract formation. If a cataract



extraction after DMEK is needed, phacoemulsification may potentially damage the DMEK graft's endothelium.<sup>11</sup> In **Chapter 3**, we assessed the incidence of cataract extraction after phakic DMEK and evaluated ECD, best-corrected visual acuity (BCVA), and complication rates in phakic DMEK eyes that underwent phacoemulsification for cataract removal.<sup>12</sup> Overall, a 17% cataract extraction probability rate was observed in the phakic eyes within ten years after DMEK. Based on the median patient age at the time of DMEK, the patient group below 57 years presented with a 12% cataract extraction probability within 10 years after DMEK, whereas patients aged 57 or above had a 22% probability. The ECD of the whole cohort decreased by 11% within 6 months after phacoemulsification, the BCVA improved, with 77% of the eyes reaching a BCVA of 20/25 or better after phacoemulsification, while CCT remained stable throughout the cohort. The phacoemulsification procedure did not induce graft detachment in any of the DMEK eyes. Overall, the incidence of cataract extraction after DMEK was relatively low, especially in patients younger than 57 years, and the clinical results suggested that phakic DMEK is a good choice for younger patients and phacoemulsification may be safe to perform in phakic DMEK eyes once needed. Price et al. even suggested that patients with advanced FECD and significant cataract could benefit from reversed staged procedures, where DMEK is performed before cataract removal. This could especially be beneficial for patients with advanced FECD, who present with central guttae and corneal edema, as that can distort the refractive effect of the eye, leading to poor preoperative intraocular lens predictions and lower postoperative visual outcomes.<sup>11</sup> Also, with rapidly developing technology better intraocular lens options, especially for the younger patients, may be developed in the future.

Nonetheless, if lens opacities are present before DMEK or if future cataract surgeries are to be avoided, the triple DMEK procedure, which combines cataract extraction, DMEK, and lens implantation, is another valid option for patients. Triple DMEK offers the advantage of one procedure and therefore is easier for the patient, is cost-effective and provides similar outcomes to staged procedures.<sup>13</sup> Even if DMEK is the most advanced corneal transplant procedure, complicated donor graft insertion and manipulation can lower the graft's ECD, which might affect graft performance. The postoperative ECD tends to experience a sharp decrease in the early postoperative period and stabilizes 1 to 6-month

postoperatively.<sup>14</sup> For PK and DSEK, the 6-month ECD outcomes are considered a benchmark parameter for late endothelial graft failure, while for DMEK the effect of 6-month ECD on late graft failure was not known.<sup>15,16</sup> Therefore, in **Chapter 4**, we analyzed how this early 6-month ECD loss affected the 5-year ECD and graft survival outcomes after DMEK in 585 patients with Fuchs endothelial corneal dystrophy (FECD).<sup>17</sup> We observed that the preoperative ECD did not influence graft survival, while high early ECD loss negatively affected both the long-term ECD and the DMEK graft survival. DMEK grafts with 6-month ECD starting from 828 cells/mm<sup>2</sup> and above resulted in almost perfect 5-year graft survival rates with  $\geq 99\%$  5-year graft survival probability, while DMEK grafts with 6-month ECD  $\leq 828$  cells/mm<sup>2</sup> were at increased risk of graft failure, with graft survival rates of 79% at 5 years postoperatively. Earlier studies in PK and DSAEK eyes found higher graft failure rates for eyes with 6-month ECD  $< 1700$  cells/mm<sup>2</sup> and  $< 1245$  cells/mm<sup>2</sup>, respectively, suggesting that the postoperative ECD functionality threshold might reside between 1245-1700 cells/mm<sup>2</sup>.<sup>15,16</sup> Our study shows that this threshold might on average be lower for DMEK eyes, but the limit may vary based on between different DMEK centers, based on surgical experience. As 6-month postoperative ECD is linked to long-term graft survival, it is important to assess which donor, patient, graft preparation or surgical factors are associated with high endothelial cell loss and how to prevent that early cell loss. It is hypothesized that the low postoperative ECD could actually be attributed to low endothelial cell viability after graft preparation or cellular stress induced during the surgery.<sup>18</sup> While early postoperative ECD loss can actually be detected as early as 1 day after DMEK<sup>14</sup> the loss of endothelial cell viability is already detected within hours of graft preparation, and the analyzed grafts showed a variability of endothelial cell viability between 57% and 97% on the day of the scheduled transplantation.<sup>18</sup> Unfortunately, the viability of endothelial cells on DMEK grafts can currently not be analyzed before implantation due to regulatory reasons, which means that the endothelial cell viability of the DMEK graft entering the patient's eye cannot be tracked. Since the introduction of DMEK, researchers aim to optimize tissue storage, graft preparation, the surgery procedure and treatment approaches to further improve the endothelial cell viability and graft longevity. Garcin et al. recently proposed using an active storage machine, called bioreactor, which



restores physiological parameters reproducing intraocular pressure and allows for continuous culture medium renewal during storage. This method of active storage has been shown to improve endothelial cell survival and increase tissue storage time and might result in better ECD outcomes after DMEK.<sup>19</sup> Higher numbers of viable endothelial cells could offer better resistance against graft handling during tissue implantation. In our study we observed that difficult graft unfolding negatively affected the 6-month ECD values, however, conflicting results have been reported between different centers.<sup>20,21</sup> Therefore, this correlation might not imply causation.

In **Chapter 5**, we extended the follow-up period and evaluated the long-term clinical outcomes of the first consecutive 100 DMEK cases performed between October 2007 and June 2009.<sup>22</sup> Our study showed a low yearly ECD decrease of 8% after DMEK. At the end of the study period, the total ECD was 903 cells/mm<sup>2</sup>, corresponding to a 68% decrease compared to preoperative values. CCT showed a slight increase of 2±6% between 5 and 10 years after DMEK. At ten years after DMEK, the graft survival rate was 79%, and 89% of eyes reached BCVA of ≥20/25 (Decimal VA ≥0.8). In addition, we observed a 4% allograft rejection rate. Overall, the majority of the eyes that underwent DMEK in the pilot stages of the procedure had excellent and stable clinical results and promising graft survival rates up to 10-years after DMEK, especially for patients diagnosed with FECD. Our study on DMEK presented BCVA and ECD outcomes that were comparable both to penetrating keratoplasty and to Descemet stripping endothelial keratoplasty, yet with lower rejection rates compared to the two predecessor techniques.<sup>23,24</sup> Interestingly, a different study from our center of 500 DMEK eyes, that also included the initial 100 from our current cohort, presented higher 5-year graft survival rates of 90% compared to the 5-year survival rate of 83% presented in Chapter 5.<sup>25</sup> Even though the first ever 25 DMEK cases were excluded from these cohorts the results suggest that the initial learning curve of DMEK technique may extend beyond those 25 cases and it may have affected the clinical outcomes presented in this chapter.<sup>26</sup> Bearing in mind that these are the results of the first cases of a new surgical technique, even better results could be anticipated in future studies, especially when performed by experienced surgeons and if corneal tissue quality is improved as well.

To further understand the impact of the surgical indication in **Chapter 6**, we have expanded the study group to 750 eyes and evaluated the effect of surgical indication and FECD severity on the clinical outcomes up to 10 years after DMEK.<sup>27</sup> We showed that BCVA, ECD, and graft survival at 1 and 5 years after DMEK were higher in patients with FECD compared to BK patients. Based on modified Krachmer grading, a moderate preoperative FECD severity resulted in better BCVA and ECD outcomes compared to advanced FECD eyes. Mean BCVA and endothelial cell loss for the entire group remained stable between 5 and 10 years after DMEK. Seventy-six percent of the eyes reached a BCVA of  $\geq 20/25$  (Decimal VA  $\geq 0.8$ ), and the average ECD was 890 cells/mm<sup>2</sup>, corresponding to a cell loss rate of -66% 10 years after DMEK. The 10-year graft survival rate was 85%, which was higher compared to the previous 10-year study described earlier.<sup>22</sup> Hypothetically, if graft functions begin to decrease at the 800 cells/mm<sup>2</sup> threshold already at 6 months postoperatively, this threshold could also be applied to the long-term graft survival predictions where any grafts with long-term ECD approaching the 800 cells/mm<sup>2</sup> threshold are at risk of graft failure. In the last two chapters, the average 10-year ECD remained above this threshold and might be predictive for good graft longevity beyond the 10-year follow-up.

Interestingly, we observed a slight shift in surgical indications over time from moderate FECD to advanced FECD and other more complicated cases, such as BK or eyes with failed previous keratoplasty eyes. As eyes with moderate FECD tend to have almost optimal outcomes, improving the results of the more complicated cases, especially the BK and failed previous keratoplasty eyes, should become an important goal for future technical improvements. This could be achieved by upgrading tissue storage methods, as mentioned earlier, and by using highest quality endothelial grafts to ensure sufficient postoperative ECD. Developing new pharmaceutical options could also improve DMEK graft longevity, especially in eyes with low postoperative ECD. Preoperative identification of possible risk factors in the aqueous humor composition of advanced cases may result in a more personalized treatment approach that could also be combined with pharmacological supplements.<sup>28</sup>

A potential therapeutic option is the Rho-associated kinase (ROCK) inhibitor, which has been reported to increase the proliferation of corneal endothelial cells (CEC) both *in vitro* and *in vivo* in an animal model and to stimulate wound healing.<sup>29</sup> The ROCK inhibition pathway is also targeted in regenerative and cell-based therapies for corneal endothelial (CE) diseases that do not require a donor graft. In young patients with mild FECD, a combination of a topical ROCK inhibitor and the Descemet stripping only (DSO) procedure could be performed instead of DMEK.<sup>30</sup> During DSO, a 4-5mm area of diseased central endothelium is removed without grafting a donor tissue and the corneal edema is resolved by regeneration and migration of peripheral endothelial cells, which are boosted by topical administration of the ROCK inhibitor.<sup>31</sup> From the first DSO case series 10 out of 13 eyes showed corneal clearance and ECD ranged from 428-864 cells/mm<sup>2</sup> at 6 to 24 months postoperatively.<sup>31</sup> Other groups observed between 62% and 100% corneal clearance rates following DSO.<sup>32</sup> DSO has no risk of rejection as it is a tissue-free treatment option, yet a bare stromal surface is not a favorable substrate for CEC migration and DSO can result in a long visual recovery period and uncertain visual results.<sup>30, 33</sup> While DSO might be an alternative therapy option for patients with early, central FECD, more studies are needed to assess the longevity of DSO. To accelerate corneal clearance and increase the success of DSO, using a denuded Descemet membrane could also be incorporated. The denuded DM would improve endothelial healing by acting as a substrate for cell migration or a scaffold for cultured CECs.<sup>34,35</sup> Other tissue-derived or synthetic scaffolds, such as anterior lens capsule, collagen-based carriers or biopolymers, have also been used in animal studies to culture endothelial cells and create a transplantable cell sheet.<sup>36,37</sup> While this scaffold-based strategy offers an efficient use of the donor tissue because cultured cells are expected to populate multiple carriers, none of the bioengineered solutions have yet been shown to be a suitable replacement for DMEK.

To deal with the challenges related to cell carriers, Kinoshita et al. introduced an alternative therapy to restore the corneal anatomy by injecting cultured human CEC in the anterior chamber.<sup>38</sup> With this technique, the abnormal Descemet membrane together with the affected endothelium is stripped from the central 8-mm-diameter area of the cornea, and  $1 \times 10^6$  passaged cells, supplemented with

ROCK inhibitor, are injected into the anterior chamber of the patient.<sup>39</sup> Five-year results showed that endothelial cell function was restored in almost all eyes, with a mean ECD of 1257 cells/mm<sup>2</sup> at the 5-year follow-up. This therapeutic option has shown promising visual acuity results, yet injecting a large number of cultured cells has potential concerns that must be addressed first. The major concern is that injected cells could pass through the trabecular meshwork and cause a partial blockage of the aqueous humor causing an elevated intraocular pressure or even enter the systemic circulation.<sup>40,41</sup> In the study performed by Kinoshita et al. authors observed elevated intraocular pressure in only one patient, which was controlled with glucocorticoids. In general, to ensure the safety of this technique, a deeper understanding of the host immunological response is necessary. All in all, cell therapies, such as cell sheet transplantation or cell injection, possess an important advantage as cultivated cells from a single donor cornea may potentially be expanded to treat multiple patients. Yet, producing good manufacturing practices-compliant cells remains challenging and costly.

An alternative for donor derived tissue is a biocompatible synthetic graft substitute such as the EndoArt implant. This artificial endothelial layer which is attached to the back of the corneal surface acts as a fluid barrier and inhibits corneal edema. Additionally, this substitute does not rely on tissue harvesting, is cost-effective and can be stored for years. Multi-center EndoArt studies have shown substantial decrease in corneal edema, yet the long-term effects especially on corneal metabolism of the nutrients, and the transparency of the EndoArt is not yet known and longer-term follow ups on larger populations are needed.<sup>42</sup>

Even with ongoing developments in CE regeneration via cell injection, cell sheet transplantation or Endoart, DMEK still remains the most efficient treatment option for endothelial disorders, as shown in our long-term studies. Both regenerative and pharmacological treatment options require more studies to ensure their clinical safety and long-term durability; therefore, encouraging tissue donation and expanding donor inclusion criteria remains the best short-term solution for treating corneal blindness. In the longer term, patient blindness could be addressed by reducing endothelial stress and increasing the tissue quality during storage.

In the future, a wide variety of treatment options could provide the most effective and tailor-made approach, based on every patient's needs.

**References:**

1. Gain P, Jullienne R, He Z, et al. Global survey of corneal transplantation and eye banking. *JAMA Ophthalmol.* 2016;134(2):167-173.
2. van Leiden HA, Erkamp B, van Eechoud R, Kishoendajal D, Mensink JW. Post mortem tissue donation in the Netherlands: a nationwide approach. *Cell Tissue Bank.* 2021;22(2):185-190.
3. Schroeter J, Rieck P. Endothelial evaluation in the cornea bank. *Dev Ophthalmol.* 2009;43:47-62.
4. Jaarverslag 2018 Nederlandse Transplantatie Stichting. Uitgever: Nederlandse Transplantatie Stichting (NTS) [online]. Available at: [NTS jaarverslag 2018 \(transplantatiestichting.nl\)](https://www.transplantatiestichting.nl)
5. Vasiliauskaitė I, Oellerich S, Ham L, et al. Descemet membrane endothelial keratoplasty: ten-year graft survival and clinical outcomes. *Am J Ophthalmol.* 2020;217:114-120.
6. Flockerzi E, Maier P, Böhringer D, et al. Trends in corneal transplantation from 2001 to 2016 in Germany: a report of the DOG-section cornea and its keratoplasty registry. *Am J Ophthalmol.* 2018;188:91-98.
7. Eye Bank Association of America: The 2021 Eye banking statistical report, available at: [Statistical Report - EBAA \(restoresight.org\)](https://www.restoresight.org)
8. Dholakia SA, Vasavada AR, Singh R. Prospective evaluation of phacoemulsification in adults younger than 50 years. *J Cataract Refract Surg.* 2005;31(7):1327-1333.
9. Clark A, Morlet N, Ng JQ, Preen DB, Semmens JB. Risk for retinal detachment after phacoemulsification: a whole-population study of cataract surgery outcomes. *Arch Ophthalmol.* 2012;130(7):882-888.
10. Chang VS, Gibbons A, Osigian C. Phacoemulsification in the setting of corneal endotheliopathies: a review. *Int Ophthalmol Clin.* 2020;60(3):71-89.
11. Price FW Jr, Price MO. Combined cataract/DSEK/DMEK: changing expectations. *Asia Pac J Ophthalmol (Phila).* 2017;6(4):388-392.
12. Vasiliauskaitė I, Dhubghaill SN, Ham L et al. Phacoemulsification after Descemet membrane endothelial keratoplasty: incidence and influence on endothelial cell density. *J Refract Surg.* 2021;37(2):119-125.
13. Tey KY, Tan SY, Ting DSJ, Mehta JS, Ang M. Effects of combined cataract surgery on outcomes of Descemet's membrane endothelial keratoplasty: a systematic review and meta-analysis. *Front Med (Lausanne).* 2022;9:857200.

14. Miron A, Bruinsma M, Ham L, et al. In vivo endothelial cell density decline in the early postoperative phase after Descemet membrane endothelial keratoplasty. *Cornea*. 2018;37(6):673-677.
15. Lass JH, Sugar A, Benetz BA, et al. Endothelial cell density to predict endothelial graft failure after penetrating keratoplasty. *Arch Ophthalmol*. 2010;128(1):63-69.
16. Patel SV, Lass JH, Benetz BA, et al. Postoperative endothelial cell density is associated with late endothelial graft failure after Descemet stripping automated endothelial keratoplasty. *Ophthalmology*. 2019;126(8):1076-1083.
17. Vasiliauskaitė I, Quilendrin R, Baydoun L et al. Effect of six-month postoperative endothelial cell density on graft survival after Descemet membrane endothelial keratoplasty. *Ophthalmology*. 2021;128(12):1689-1698.
18. Miron A, Sajet A, Groeneveld-van Beek EA, et al. Endothelial cell viability after DMEK graft preparation. *Curr Eye Res*. 2021;46(11):1621-1630.
19. Garcin T, Gauthier AS, Crouzet E, et al. Innovative corneal active storage machine for long-term eye banking. *Am J Transplant*. 2019;19(6):1641-1651.
20. Maier AK, Gundlach E, Schroeter J, et al. Influence of the difficulty of graft unfolding and attachment on the outcome in Descemet membrane endothelial keratoplasty. *Graefes Arch Clin Exp Ophthalmol*. 2015;253:895e900.
21. Gundlach E, Spiller N, Pilger D, et al. Impact of difficult unfolding and attachment of the graft lamella on the long-term outcome after Descemet membrane endothelial keratoplasty. *Graefes Arch Clin Exp Ophthalmol*. 2020;258:2459e2465.
22. Vasiliauskaitė I, Oellerich S, Ham L, et al. Descemet membrane endothelial keratoplasty: ten-year graft survival and clinical outcomes. *Am J Ophthalmol*. 2020;217:114-120.
23. Ing JJ, Ing HH, Nelson LR, Hodge DO, Bourne WM. Ten year postoperative results of penetrating keratoplasty. *Ophthalmology*. 1998;105:1855-1865.
24. Price MO, Calhoun P, Kollman C, Price FW Jr, Lass JH. Descemet stripping endothelial keratoplasty: ten-year endothelial cell loss compared with penetrating keratoplasty. *Ophthalmology*. 2016;123:1421-1427.
25. Birbal RS, Ni Dhubghaill S, Bourgonje VJA, et al. Five-year graft survival and clinical outcomes of 500 consecutive cases after Descemet membrane endothelial keratoplasty. *Cornea*. 2020;39:290-297.
26. Dirisamer M, Ham L, Dapena I, et al. Efficacy of Descemet membrane endothelial keratoplasty: clinical outcome of 200 consecutive cases after a learning curve of 25 cases. *Arch Ophthalmol*. 2011;129(11):1435-1443.



27. Vasiliauskaitė I, Kocaba V, van Dijk K et al. Long-term outcomes of Descemet membrane endothelial keratoplasty: effect of surgical indication and disease severity. *Cornea*. 2022;[published online ahead of print]
28. Matthaei M, Gillissen J, Muether PS, et al. Epithelial-mesenchymal transition (EMT)-related cytokines in the aqueous humor of phakic and pseudophakic Fuchs' dystrophy eyes. *Invest Ophthalmol Vis Sci*. 2015;56:2749-2754.
29. Meekins LC, Rosado-Adames N, Maddala R et al. Corneal endothelial cell migration and proliferation enhanced by Rho kinase (ROCK) inhibitors in vitro and in vivo models. *Invest Ophthalmol Vis Sci*. 2016;57(15):6731-6738.
30. Moloney G, Petsoglou C, Ball M, et al. Descemetorhexis without grafting for Fuchs endothelial dystrophy-supplementation with topical ripasudil. *Cornea*. 2017;36(6):642-648.
31. Borkar DS, Veldman P, Colby KA. Treatment of Fuchs endothelial dystrophy by Descemet stripping without endothelial keratoplasty. *Cornea*. 2016;35(10):1267-1273.
32. Garcerant D, Hirschall N, Toalster N, Zhu M, Wen L, Moloney G. Descemet's stripping without endothelial keratoplasty. *Curr Opin Ophthalmol*. 2019;30(4):275-285.
33. Soh YQ, Mehta JS. Regenerative therapy for Fuchs endothelial corneal dystrophy. *Cornea*. 2018;37(4):523-527.
34. Hsiue GH, Lai JY, Chen KH, Hsu WM. A novel strategy for corneal endothelial reconstruction with a bioengineered cell sheet. *Transplantation*. 2006;81(3):473-476.
35. Soh YQ, Peh G, George BL, et al. Predictive factors for corneal endothelial cell migration. *Invest Ophthalmol Vis Sci*. 2016;57(2):338-348.
36. Spinozzi D, Miron A, Lie JT, et al. In vitro evaluation and transplantation of human corneal endothelial cells cultured on biocompatible carriers. *Cell Transplant*. 2020;29:963689720923577
37. Mimura T, Yamagami S, Yokoo S, et al. Cultured human corneal endothelial cell transplantation with a collagen sheet in a rabbit model. *Invest Ophthalmol Vis Sci*. 2004;45(9):2992-2997.
38. Kinoshita S, Koizumi N, Ueno M, et al. Injection of cultured cells with a ROCK inhibitor for bullous keratopathy. *N Engl J Med*. 2018;378(11):995-1003.
39. Numa K, Imai K, Ueno M, et al. Five-year follow-up of first 11 patients undergoing injection of cultured corneal endothelial cells for corneal endothelial failure. *Ophthalmology*. 2021;128(4):504-514.

40. Hazra S, Sneha IV, Chaurasia S, Ramachandran C. In vitro expansion of corneal endothelial cells for clinical application: current update. *Cornea*. 2022;41(10):1313-1324.
41. Dana R. A new frontier in curing corneal blindness. *N Engl J Med*. 2018;378(11):1057-1058.
42. Auffarth GU, Son HS, Koch M, et al. Implantation of an artificial endothelial layer for treatment of chronic corneal edema. *Cornea*. 2021;40(12):1633-1638.