



Universiteit  
Leiden  
The Netherlands

## **Introduction to hemodynamic forces by echocardiography**

Laenens, D.; Bijl, P.; Stassen, J.; Rossi, A.C.; Pedrizzetti, G.; Reiber, J.H.C.; ... ; Bax, J.J.

### **Citation**

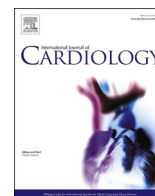
Laenens, D., Bijl, P., Stassen, J., Rossi, A. C., Pedrizzetti, G., Reiber, J. H. C., ... Bax, J. J. (2022). Introduction to hemodynamic forces by echocardiography. *International Journal Of Cardiology*, 370, 442-444. doi:10.1016/j.ijcard.2022.11.019

Version: Publisher's Version

License: [Creative Commons CC BY 4.0 license](#)

Downloaded from: <https://hdl.handle.net/1887/3729136>

**Note:** To cite this publication please use the final published version (if applicable).



Short communication

Introduction to hemodynamic forces by echocardiography<sup>☆</sup>Dorien Laenens<sup>a</sup>, Pieter van der Bijl<sup>a</sup>, Jan Stassen<sup>a</sup>, Alessandro C. Rossi<sup>b</sup>, Gianni Pedrizzetti<sup>c,e</sup>, Johan H.C. Reiber<sup>d</sup>, Nina Ajmone Marsan<sup>a</sup>, Jeroen J. Bax<sup>a,f,\*</sup><sup>a</sup> Department of Cardiology, Leiden University Medical Centre, Albinusdreef 2, 2333 ZA Leiden, the Netherlands<sup>b</sup> Medis Medical Imaging, Schuttersveld 9, 2316 XG Leiden, the Netherlands<sup>c</sup> Department of Engineering and Architecture, University of Trieste, Via Alfonso Valerio, 6/1, 34127 Trieste, TS, Italy<sup>d</sup> Department of Radiology, Leiden University Medical Centre, Albinusdreef 2, 2333 ZA Leiden, the Netherlands<sup>e</sup> Department of Biomedical Engineering, University of California, 402 E Peltason Dr, Irvine, CA 92617, USA<sup>f</sup> Heart Center, University of Turku and Turku University Hospital, Kännylykatu 4-8, FI-20520 Turku, Finland

## ARTICLE INFO

## Keywords:

Hemodynamic forces

Fluid dynamics

Advanced cardiac imaging

## ABSTRACT

Hemodynamic force (HDF) analysis represents a novel approach to quantify intraventricular pressure gradients, responsible for blood flow. A new mathematical model allows the derivation of HDF parameters from routine transthoracic echocardiography, making this tool more accessible for clinical use. HDF analysis is considered the fluid dynamics correlate of deformation imaging and may be even more sensitive to detect mechanical abnormalities. This has the potential to add incremental clinical value, allowing earlier detection of pathology or immediate evaluation of response to treatment. In this article, the theoretical background and physiological patterns of HDF in the left ventricle are provided. In pathological situations, the HDF pattern might alter, which is illustrated with a case of ST segment elevation myocardial infarction and non-ischemic cardiomyopathy with typical left bundle branch block.

## 1. Introduction

Hemodynamic force (HDF) analysis represents a novel approach to quantify intraventricular pressure gradients responsible for blood flow [1]. Until recently, HDF could only be obtained by means of contrast-enhanced echocardiography and four-dimensional flow magnetic resonance imaging (4D flow MRI). A new mathematical model has been constructed allowing HDF parameters to be derived from routine transthoracic echocardiography [2]. This model has been validated against 4D flow MRI measurements and numerical phantoms, and it makes HDF analysis more accessible for clinical use [3]. HDF parameters may be more sensitive to assess functional abnormalities (e.g. subclinical left ventricular (LV) dysfunction and dyssynchrony) than conventional imaging, allowing clinicians to detect pathology sooner and evaluate response to treatment at an earlier stage. This article is intended to provide a theoretical background of HDF analysis by echocardiography and explains how to interpret the physiological and pathological patterns in the LV. HDF parameters, generated by new proprietary software, are presented in various clinical scenarios.

## 2. Principle and physiological patterns of hemodynamic forces in the left ventricle

Evaluating HDF by echocardiography requires knowledge of the velocities over the LV endocardial boundaries and across the valves. Two-dimensional apical four-, two- and three-chamber views are used in which the endocardial boundaries are automatically traced and manually adjusted. The same principle is implemented in speckle tracking strain analysis and the HDF analysis can therefore be applied to the images acquired for deformation imaging with an optimal frame rate of 50–70 frames per second [4,5]. Subsequently, the mitral valve opening and the LV outflow tract are traced, as recommended [6]. The mean velocity across the open valves is then calculated as the LV volume rate divided by the valve area [7]. The mathematical model converting endocardial dynamics into flow forces is reported elsewhere [2]. HDF analysis studies the global driving force for blood flow in the LV. In the normal LV, HDF occurs along three planes (apical-basal, septal-lateral and inferior-anterior) with an apical-base dominance which is the most reproducible and detectable force. The apical-base direction of

<sup>☆</sup> This author takes responsibility for all aspects of the reliability and freedom from bias of the data presented and their discussed interpretation.

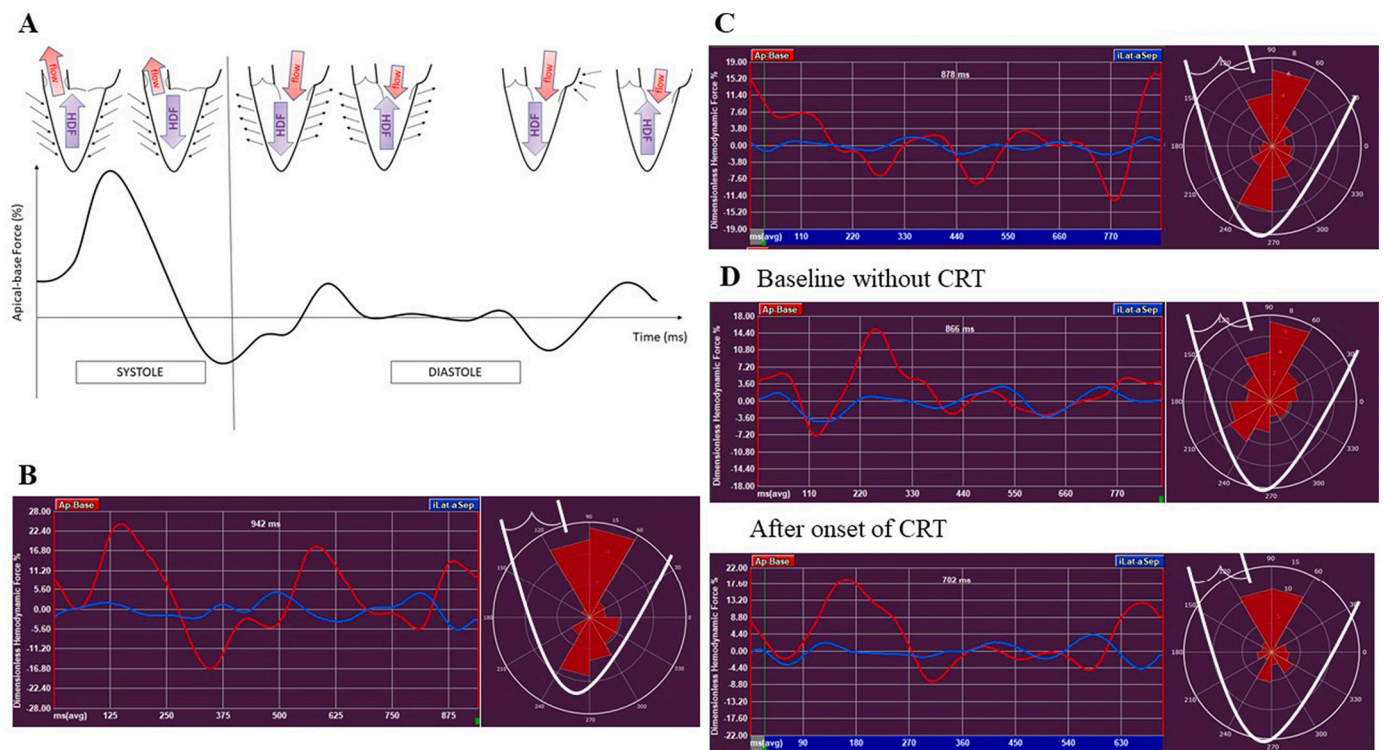
\* Corresponding author at: Department of Cardiology, Heart Lung Centre, Leiden University Medical Centre; Albinusdreef 2, 2333 ZA Leiden, the Netherlands.

E-mail address: [j.j.bax@lumc.nl](mailto:j.j.bax@lumc.nl) (J.J. Bax).<https://doi.org/10.1016/j.ijcard.2022.11.019>

Received 30 June 2022; Received in revised form 17 October 2022; Accepted 9 November 2022

Available online 14 November 2022

0167-5273/© 2022 The Author(s). Published by Elsevier B.V. This is an open access article under the CC BY license (<http://creativecommons.org/licenses/by/4.0/>).



**Fig. 1.** Representation of Hemodynamic Force analysis in different scenarios.

A. Representation of the apical-base hemodynamic force (HDF) in the left ventricle in physiological conditions. B. HDF analysis performed in a normal individual. The red curve represents the apical-base HDF, the blue curve represents the septal-lateral HDF. The polar histogram, projected on the left ventricle (LV), shows the magnitude and direction of HDF throughout the complete cardiac cycle. C. HDF analysis in an 86-year-old male patient with ST-segment elevation myocardial infarction with a severe stenosis of the left anterior descending artery showing a decline in the first systolic deflection and a HDF pattern oriented towards the LV apex in the polar histogram. D. HDF analysis in a 70-year-old female patient with non-ischemic cardiomyopathy and typical left bundle branch block referred for cardiac resynchronization. Baseline analysis shows a longer time-to-peak of the first positive systolic deflection indicating delayed activation and a more divergent pattern of HDF in the polar histogram as a reflection of mechanical dyssynchrony. After onset of CRT, the time-to-peak is shorter and the HDF pattern on the histogram is normalized. The HDF measurements were generated with new proprietary software (QStrain Echo 4.1.4.4., Medis Suite Ultrasound, Medis Medical Imaging, Leiden, The Netherlands). (For interpretation of the references to colour in this figure legend, the reader is referred to the web version of this article.)

force is represented as a curve with a positive deflection when HDF is directed towards the LV base and a negative deflection when HDF is directed towards the LV apex (Fig. 1, A). During early systole, myocardial contraction creates a higher pressure in the LV apex than in the ascending aorta. This induces a HDF directed towards the LV base that accelerates blood towards the LV outflow tract. During late systole, the pressure in the aorta rises and exceeds the pressure in the LV. The direction of the HDF inverts towards the apex and outflow of blood decelerates, represented by a negative deflection in the HDF curve. During early diastolic filling the myocardium relaxes and HDF is still directed towards the apex, followed by an early inversion of HDF leading to deceleration of inflow. Left atrial contraction changes HDF direction again towards the apex, once more turning towards the LV base at the end of the cardiac cycle. In an individual with normal LV systolic and diastolic function, HDF analysis was performed (Fig. 1, B). The red curve represents HDF in the apical-base or longitudinal direction while the septal-lateral or transversal HDF is shown in the blue curve. Inferior-anterior HDF is negligible and therefore not shown. The unit of force is Newton (N). Usually the amplitude parameters of HDF are expressed as the root mean square (RMS), including both positive and negative values. The value of HDF is first normalized to the corresponding LV volume and then divided by the fluid density and gravity acceleration. This allows representation as a percentage of gravity acceleration and facilitates comparison between patients. In this example of a normal subject, the apical-basal HDF has a RMS of 59.3 mN or 11.17% and the septal-lateral HDF has a RMS of 13.5 mN or 2.45% during the complete cardiac cycle. Timing parameters can also be registered, e.g. time-to-

peak or duration of a positive or negative deflection. Orientation parameters of HDF can be expressed as a ratio between transversal and longitudinal HDF or as an angle representing the dominant direction of the force vector throughout the entire cardiac cycle. A polar histogram is used to represent both the magnitude (red triangles) and directional distribution (angles) of HDF during the complete heart cycle. The histogram is projected onto the LV with the top ( $90^\circ$ ) representing the base of the LV and the bottom ( $270^\circ$ ) representing the apex of the LV. In this normal individual, the polar histogram shows a predominantly longitudinal force towards the LV base (Fig. 1, B).

### 3. Clinical implications

In pathological conditions, HDF patterns might be altered. When the delicate synergy of contraction between myocardial segments is disturbed, longitudinal components decline and increased transversal components of HDF appear. In the case of ST-segment elevation myocardial infarction, the HDF analysis of an 86-year-old male patient is shown, who presented to the emergency department with typical angina (Fig. 1, C). An electrocardiogram showed ST-segment elevation in the precordial leads and invasive coronary angiography demonstrated severe stenosis of the LAD (left anterior descending coronary artery) which was successfully revascularized with primary percutaneous coronary intervention. Transthoracic echocardiography showed a left ventricular ejection fraction (LVEF) of 37% with akinesia in the mid-distal LAD territory. This is reflected in a decrease of the positive deflection of the longitudinal (red) curve during systole with a diminished apical-basal

RMS of 45.3 mN (6.33%), indicating impaired myocardial contractility. The polar histogram shows that HDF have been redistributed towards the apex of the LV as a consequence of apical akinesia. Fig. 1,D represents the HDF analysis in a 70-year-old female patient with non-ischemic cardiomyopathy and a LVEF of 24% with a typical left bundle branch block (QRS = 167 ms). She was referred for cardiac resynchronization therapy (CRT). Baseline HDF analysis before CRT implantation shows delayed mechanical activation, visible in the apical-basal red curve, demonstrating a longer time-to-peak during early systole, and increased transversal components indicating dyssynchrony of myocardial deformation - visible in the blue curve and the polar histogram. Deviation from the longitudinal direction, expressed as the ratio of septal-lateral RMS to apical-basal RMS, is 37.4% in this patient. The angle of the dominant force vector throughout the cardiac cycle is 62°. One day after CRT implantation, HDF analysis showed normalization of longitudinal HDF in systole and decrease of the transversal components with a septal-lateral RMS to apical-basal RMS ratio of 24.5% and the angle of the dominant force vector rotated to 69°. Alteration of HDF can already be detected after a few paced beats, suggesting a role for these parameters in CRT optimization. Early changes in HDF patterns, e.g. after the institution of heart failure therapy, might predict cardiac remodelling at an earlier stage than conventional imaging methods.

#### 4. Conclusion

HDF analysis by echocardiography is a new technique to detect myocardial pathology by quantifying the flow-tissue interaction. Efficient blood motion is the ultimate goal of myocardial function and alteration in the driving HDF unmasks early signs of cardiac dysfunction. HDF analysis is therefore a new tool to detect pathology at an earlier stage. Systematically designed studies are necessary to determine the prognostic value of this new tool in different clinical scenarios.

#### Disclosures

The Department of Cardiology of Leiden University Medical Centre received research grants from Abbott Vascular, Bayer, Biotronik, Bioventrix, Boston Scientific, Edwards Lifesciences, GE Healthcare and Medtronic. Jeroen J. Bax received speaker fees from Abbott Vascular. Nina Ajmone Marsan received speaker fees from Abbott Vascular and GE Healthcare. The other authors have nothing to disclose.

#### References

- [1] F. Vallelonga, L. Airale, G. Tonti, E. Argulian, A. Milan, J. Narula, et al., Introduction to hemodynamic forces analysis: moving into the new frontier of cardiac deformation analysis, *J. Am. Heart Assoc.* 10 (2021), e023417.
- [2] G. Pedrizzetti, On the computation of hemodynamic forces in the heart chambers, *J. Biomech.* 95 (2019), 109323.
- [3] G. Pedrizzetti, P.M. Arvidsson, J. Töger, R. Borgquist, F. Domenichini, H. Arheden, et al., On estimating intraventricular hemodynamic forces from endocardial dynamics: a comparative study with 4D flow MRI, *J. Biomech.* 60 (2017) 203–210.
- [4] J.U. Voigt, G. Pedrizzetti, P. Lysyansky, T.H. Marwick, H. Houle, R. Baumann, et al., Definitions for a common standard for 2D speckle tracking echocardiography: consensus document of the EACVI/ASE/industry task force to standardize deformation imaging, *Eur. Heart J. Cardiovasc. Imaging* 16 (2015) 1–11.
- [5] A.J. Teske, B.W. De Boeck, P.G. Melman, G.T. Sieswerda, P.A. Doevendans, M. J. Cramer, Echocardiographic quantification of myocardial function using tissue deformation imaging, a guide to image acquisition and analysis using tissue Doppler and speckle tracking, *Cardiovasc. Ultrasound* 5 (2007) 27.
- [6] R.M. Lang, L.P. Badano, V. Mor-Avi, J. Afilalo, A. Armstrong, L. Ernande, et al., Recommendations for cardiac chamber quantification by echocardiography in adults: an update from the American Society of Echocardiography and the European Association of Cardiovascular Imaging, *J. Am. Soc. Echocardiogr.* 28 (2015) 1–39. e14.
- [7] G. Faganello, D. Colli, S. Furlotti, L. Pagura, M. Zaccari, G. Pedrizzetti, et al., A new integrated approach to cardiac mechanics: reference values for normal left ventricle, *Int. J. Card. Imaging* 36 (2020) 2173–2185.