



Universiteit  
Leiden  
The Netherlands

## **Histological chorioamnionitis and funisitis as new risk factors for retinopathy of prematurity: a meta-analysis**

Emrani, S. el; Jansen, E.J.S.; Goeman, J.J.; Lopriore, E.; Termote, J.U.M.; Schalijs-Delfos, N.E.; Meeren, L.E. van der

### **Citation**

Emrani, S. el, Jansen, E. J. S., Goeman, J. J., Lopriore, E., Termote, J. U. M., Schalijs-Delfos, N. E., & Meeren, L. E. van der. (2023). Histological chorioamnionitis and funisitis as new risk factors for retinopathy of prematurity: a meta-analysis. *American Journal Of Perinatology*. doi:10.1055/a-2215-0662

Version: Publisher's Version

License: [Creative Commons CC BY 4.0 license](https://creativecommons.org/licenses/by/4.0/)

Downloaded from: <https://hdl.handle.net/1887/3728547>

**Note:** To cite this publication please use the final published version (if applicable).



# Histological Chorioamnionitis and Funisitis as New Risk Factors for Retinopathy of Prematurity: A Meta-analysis

Salma El Emrani, BSc<sup>1,2</sup> Esther J.S. Jansen, MD<sup>3</sup> Jelle J. Goeman, PhD<sup>4</sup> Enrico Lopriore, MD, PhD<sup>2</sup>  
Jacqueline U.M. Termote, MD, PhD<sup>3</sup> Nicoline E. Schalijs-Delfos, MD, PhD<sup>1</sup>  
Lotte E. van der Meeren, MD, PhD<sup>5,6</sup>

<sup>1</sup> Department of Ophthalmology, Leiden University Medical Center, Leiden, The Netherlands

<sup>2</sup> Division of Neonatology, Department of Pediatrics, Willem-Alexander Children's Hospital, Leiden University Medical Center, Leiden, The Netherlands

<sup>3</sup> Division of Neonatology, Department of Women and Neonate, Wilhelmina Children's Hospital, University Medical Center Utrecht, Utrecht, The Netherlands

<sup>4</sup> Division of Medical Statistics, Department of Biomedical Data Science, Leiden University Medical Center, Leiden, The Netherlands

**Address for correspondence** Salma El Emrani, BSc, Department of Ophthalmology, Leiden University Medical Center, J3-5, Albinusdreef 2, 2333 ZA Leiden, The Netherlands (e-mail: s.el\_emrani@lumc.nl).

<sup>5</sup> Department of Pathology, Leiden University Medical Center, Leiden, The Netherlands

<sup>6</sup> Department of Pathology, Erasmus Medical Center, Rotterdam, The Netherlands

Am J Perinatol

## Abstract

**Objective** The role of placental inflammation in neonatal morbidities is underestimated due to lack of placental examination. This meta-analysis aims to assess the association between histological chorioamnionitis (HCA) with and without funisitis (FUN) and risk of retinopathy of prematurity (ROP).

**Study Design** Forty-five studies reporting (unadjusted) data on HCA without FUN and HCA with FUN in neonates with ROP were included. Primary outcomes were any stage ROP and severe ROP. Potential confounders explored were gestational age (GA) at birth, birthweight, maternal steroid use, necrotizing enterocolitis, sepsis (suspected/proven) and mechanical ventilation duration.

**Results** Neonates with HCA had increased risk for any stage ROP (odds ratio [OR] 1.8; 95% confidence interval [CI] 1.3–2.4) and severe ROP (OR 1.5; 95% CI 1.2–1.8) compared with neonates without HCA. The rates of any stage ROP (OR 1.8; 95% CI 1.4–2.2) and severe ROP (OR 1.4; 95% CI 1.1–1.6) were higher in neonates with FUN compared with neonates without FUN. Multivariate meta-regression analysis suggests that lower GA increases the effect size between FUN and severe ROP.

**Conclusion** This meta-analysis confirms that presence of HCA and FUN are risk factors for any stage ROP and severe ROP. Structured histological placental examination of HCA and FUN may be a tool to further refine the ROP risk profile.

## Keywords

- ▶ retinopathy of prematurity
- ▶ histological chorioamnionitis
- ▶ funisitis
- ▶ prematurity
- ▶ meta-analysis

received  
April 6, 2023  
accepted after revision  
November 15, 2023  
accepted manuscript online  
November 21, 2023

DOI <https://doi.org/10.1055/a-2215-0662>.  
ISSN 0735-1631.

© 2023. The Author(s).

This is an open access article published by Thieme under the terms of the Creative Commons Attribution License, permitting unrestricted use, distribution, and reproduction so long as the original work is properly cited. (<https://creativecommons.org/licenses/by/4.0/>)  
Thieme Medical Publishers, Inc., 333 Seventh Avenue, 18th Floor, New York, NY 10001, USA

## Key Points

- This systematic review confirms that HCA is a risk factor for ROP.
- This meta-analysis reveals that FUN results in an even higher risk for developing ROP.
- Placental examination of HCA/FUN may be a tool to further refine the ROP risk profile.

Retinopathy of prematurity (ROP) is a sight-threatening retinal disorder in premature neonates, accounting for up to 40% of worldwide childhood blindness.<sup>1</sup> This vasoproliferative disorder affects 10 to 25% of neonates born under 32 weeks of gestation, with an even higher incidence of 30 to 70% in neonates with a birthweight (BW) below 1,500 g.<sup>2</sup> The pathophysiology is primarily due to abnormal retinal vessel development and occurs in two phases. The initial phase is induced by hyperoxia exposure and decreased insulin-like growth factor-1 (IGF-1) levels due to placental disruption, followed by decreased vascular endothelial growth factor (VEGF) levels, and results in attenuation and cessation of retinal vessel growth.<sup>1,3</sup> The second phase is characterized by abnormal retinal vessel growth due to increased VEGF concentrations following retinal hypoxia and increasing IGF-1 levels.<sup>1,3</sup>

Preterm birth, one of the leading causes of ROP, is associated with chorioamnionitis (CA).<sup>4</sup> Histological chorioamnionitis (HCA) is an acute maternal inflammatory response in the placental membranes, mainly due to ascending microorganisms, while funisitis (FUN) is the fetal inflammatory response of the vessels in the umbilical cord.<sup>5,6</sup> The presence of HCA will not always lead to FUN, whereas the presence of FUN is always equivalent to the presence of HCA. Clinical chorioamnionitis (CCA) has been proven to be unreliable in diagnosing inflammation in the placenta due to high false-positive rates.<sup>7</sup> In most cases, the role of HCA in neonatal morbidities is underestimated due to lack of postpartum placental histological examination.<sup>6</sup>

The potential association between HCA and the development of ROP is believed to be a result of proinflammatory cytokines production.<sup>4,8</sup> However, establishing its specific pathophysiology is found to be challenging due to the simultaneous interplay of substantial confounders such as low gestational age (GA) at birth and BW.<sup>4</sup> Additionally, most studies do not differentiate between HCA and FUN, even though the presence of FUN is believed to have more impact on the risk of ROP development.<sup>9</sup>

Robust evidence regarding the effect of HCA and especially FUN on the development of ROP is still lacking. Hence, we performed a systematic review and meta-analysis to investigate the association between HCA with and without FUN and the risk of ROP development in premature born neonates to further adjust the risk profile for ROP screening.

## Methods

### Sources

This systematic review was conducted according to Preferred Reporting Items for Systematic Reviews and Meta-Analyses (PRISMA) guidelines and is registered in the International Prospective Register of Systematic Reviews (PROSPERO)

(CRD42022346582).<sup>10</sup> The online electronic databases PubMed, Embase, and Cochrane Library were searched up until October 2023 by using combinations of the following keywords: “Placenta,” “Chorioamnionitis,” “Risk Factors,” AND “Retinopathy of Prematurity.” Additionally, various synonyms were added as Medical Subject Headings (MESH) terms and free text words. Lastly, reference lists of key articles were manually reviewed to identify relevant articles missed by PubMed.

### Study Selection

All studies were assessed for eligibility by primarily screening the title and abstract and subsequently evaluating the full text. Studies were eligible for inclusion when (unadjusted) data were reported on HCA with or without FUN in preterm neonates (<37 weeks' GA and/or BW < 2,000 g) with ROP.<sup>11,12</sup> Articles were excluded when the study population consisted entirely of animals or multiple pregnancies due to its confounding effect.<sup>13</sup> Additionally, articles were excluded when placenta reports were unavailable to histologically confirm CA in cases with CCA, which is diagnosed by nonspecific clinical symptoms.<sup>7</sup> Further exclusion criteria were case reports, case series, reviews, editorials, and unavailable full text. To identify eligibility of inclusion, three reviewers (S.E., E.J.S.J., and J.U.M.T.) independently assessed the search results and discrepancies were resolved through discussion.

The primary outcome was ROP. Due to their known potential confounding effect on ROP, the following clinical data were included: GA at birth (weeks), BW (grams) and maternal steroid use, necrotizing enterocolitis (any stage), sepsis (suspected/proven), and mechanical ventilation duration (days).<sup>14</sup> Studies were classified as any stage ROP or severe ROP (defined as ROP  $\geq$  stage 3, Type I ROP [treatment criteria], aggressive [posterior] ROP], plus disease or ROP requiring treatment).<sup>15</sup> HCA was defined as an acute inflammation with presence of neutrophils in the placental membranes (chorion and/or amnion) and chorionic plate.<sup>5</sup> FUN, also known in literature as fetal inflammatory response or acute fetal inflammation, was defined as the presence of neutrophils in the umbilical vessel walls.<sup>5,16</sup>

The included neonates were categorized into four groups: HCA and any stage ROP, HCA and severe ROP, FUN and any stage ROP, and FUN and severe ROP. Neonates with HCA were compared with neonates without HCA, while neonates with FUN were compared with neonates without FUN (HCA without FUN or no HCA).

### Quality Assessment

The Newcastle–Ottawa Scale for case–control and cohort studies was used to assess the validity and quality of the included studies.<sup>17</sup> This assessment includes three study

aspects: selection (0–4 points), comparability (0–2 points), and exposure/outcome (0–3 points). Scoring was based on the association between HCA/FUN and ROP as the primary outcome. The comparability section relied on GA and one additional potential confounder reported in our study.

### Statistical Analysis

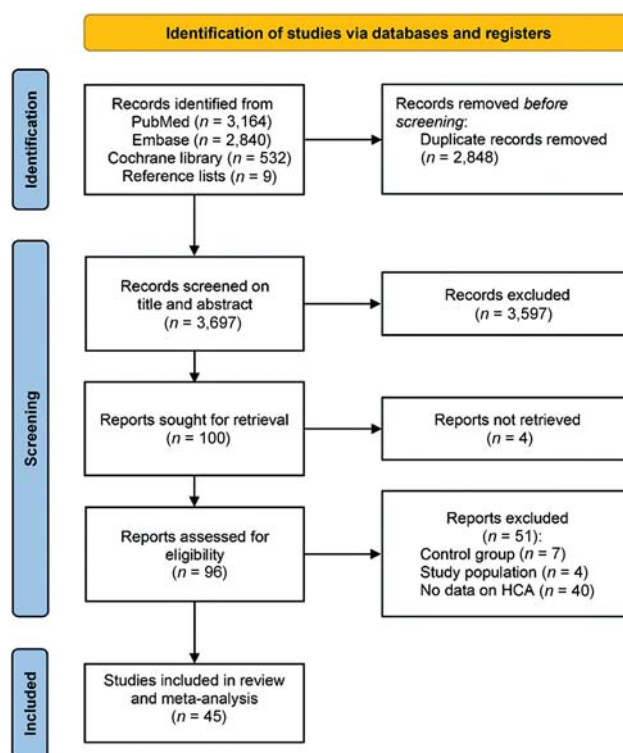
Statistical analyses were performed using R studio for Windows, version 4.2.1 (RStudio, PBC, Boston, MA) with the metafor package, assisted by a statistician (J.J.G.).<sup>18</sup> Data are presented using  $n/N$  (%) and odds ratio (OR) with 95% confidence interval (CI). The OR and 95% CI for the primary outcome were recalculated from unadjusted  $2 \times 2$  table data provided in the studies and combined using a logistic random-effects model due to anticipated heterogeneity. Heterogeneity between studies was evaluated by the  $Q$  statistics and  $I^2$  statistics, which is the total variation between studies due to heterogeneity beyond chance.  $p$ -Values  $<0.05$  were considered statistically significant. Publication bias was assessed through funnel plots, failsafe number, and trim-and-fill function in R studio.

To explain observed between-study heterogeneity, the mean/median difference for continuous variables and the incidence (%) difference for dichotomous outcomes were calculated between the HCA/FUN and no HCA/FUN groups. No distinction was made between the median and mean for continuous variables to include more studies. A univariate meta-regression model was performed to identify variables that potentially influence the effect size of HCA/FUN on ROP. The Bonferroni correction for multiple comparisons was used in univariate analysis, in which a  $p$ -value of 0.05/number of included variables was considered statistically significant.

Subsequently, variables with significant associations found in univariate analysis were included in multivariate meta-regression analysis. GA and BW are highly correlated and adjusting for both variables in multivariate analysis will undermine the statistical significance of each other. When both GA and BW are significant in univariate analysis, only one variable should be included in multivariate analysis, preferably in combination with the variable small for GA. Since data on small for GA were limited, only the highest significant variable was included to prevent multicollinearity. Data are presented using  $\beta$ -coefficient with 95% CI. Positive  $\beta$ -coefficients indicate that studies with large between-group differences in potential confounders had higher associations between HCA/FUN and ROP, while negative  $\beta$ -coefficients indicate the opposite.

### Results

The search strategy yielded 6,536 articles. Nine additional articles were included from manual search of reference lists for title and abstract screening. After excluding duplicates, 3,697 titles and abstracts were screened. Primary assessment led to exclusion of 3,597 articles based on inclusion and exclusion criteria. After full-text assessment of the remaining 100 articles, 55 articles were excluded, resulting in a total



**Fig. 1** PRISMA flowchart of study inclusion. PRISMA, Preferred Reporting Items for Systematic Reviews and Meta-Analyses.

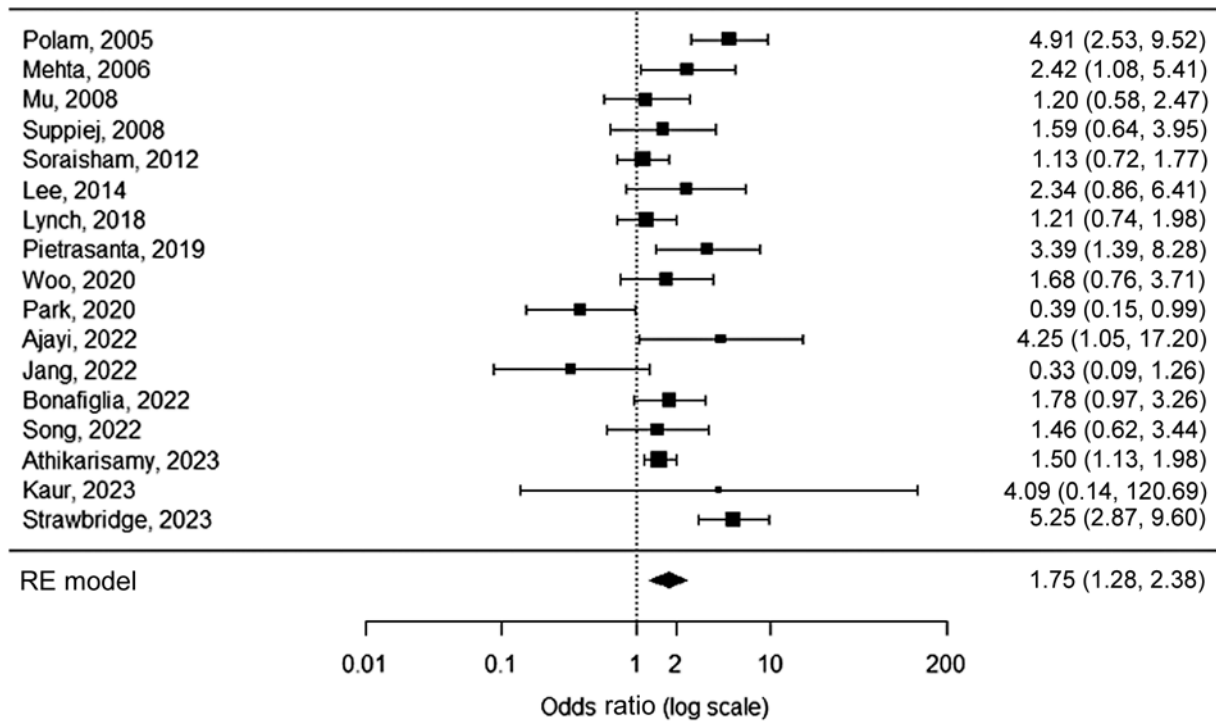
of 45 included articles in this systematic review and meta-analysis (► Fig. 1).

### Quality Analysis

Validity and quality assessment of included studies are presented in ►Supplementary Tables S1–S4 (available in the online version). Most studies ( $n=32$ ) had a moderate quality score (6–7 points), while 11 studies received a high quality score (8–9 points), and only 2 studies had a low quality score (0–5 points). Many studies lost points due to absence of confounder adjustment. Some studies that adjusted for both GA and BW in multivariate analysis lost a point since these factors are highly correlated and will undermine the statistical significance of each other. Studies also did not receive points when the definition or reference of ROP and HCA/FUN diagnosis were not reported.

### Histological Chorioamnionitis and Any Stage Retinopathy of Prematurity

Seventeen studies assessing HCA in neonates with any stage ROP compared with neonates without ROP were included, with the number of sample size ranging from 13 to 912 (►Supplementary Table S1, available in the online version).<sup>19–35</sup> HCA was detected 1.8 times as frequently in neonates with any stage ROP compared with neonates without ROP (OR 1.8, 95% CI 1.3–2.4,  $p=0.0004$ ; ►Fig. 2). Neither visual inspection and trim-and-fill number ( $n=0$ ) of the funnel plot nor the failsafe number ( $n=223$ , Kendall's tau = 0.07,  $p=0.7$ ) showed indication of publication bias (►Supplementary Fig. S1, available in the online version).



**Fig. 2** Forest plot of the association between HCA and any stage ROP. Heterogeneity:  $Q = 50.7$ ,  $I^2 = 68.5\%$ ,  $p < 0.0001$ . HCA, histological chorioamnionitis; ROP, retinopathy of prematurity; RE, random-effects.

Significant moderate heterogeneity was observed ( $Q: 50.7$ ,  $I^2: 68.5\%$ ,  $p < 0.0001$ ).

To explore the observed heterogeneity and to analyze the possible influence of potential confounders as moderators on the effect size of HCA on any stage ROP, univariate regression meta-analysis was performed (→ **Table 1**). One factor was a significant moderator in univariate meta-regression analysis for the association between HCA and any stage ROP: maternal steroids ( $\beta$ -coefficient 0.05, 95% CI 0.008–0.09,  $p = 0.02$ ).

**Histological Chorioamnionitis and Severe Retinopathy of Prematurity**

Fifteen studies assessing HCA in neonates with severe ROP compared with neonates with no/mild ROP were included, with the number of sample size ranging from 32 to 12,254 (→ **Supplementary Table S2**, available in the online version)<sup>21,23,25,27,28,32,33,36–43</sup> HCA was detected 1.5 times as frequently in neonates with severe ROP compared with

neonates with no/mild ROP (OR 1.5, 95% CI 1.2–1.8,  $p < 0.0001$ ; → **Fig. 3**). Publication bias (→ **Supplementary Fig. S2**, available in the online version) was neither detected in visual inspection and trim-and-fill number ( $n = 0$ ) of the funnel plot, nor the failsafe number ( $n = 129$ , Kendall’s tau = 0.1,  $p = 0.5$ ). Low heterogeneity was observed ( $Q: 20.2$ ,  $I^2: 30.8\%$ ,  $p = 0.1230$ ).

While using the Bonferroni correction for multiple comparisons, one factor was a significant moderator in univariate meta-regression analysis for the association between HCA and severe ROP: GA ( $\beta$ -coefficient  $-0.4$ , 95% CI  $-0.7$  to  $-0.04$ ,  $p = 0.03$ ) between the HCA group and non-HCA group (→ **Table 2**).

**Funisitis and Any Stage Retinopathy of Prematurity**

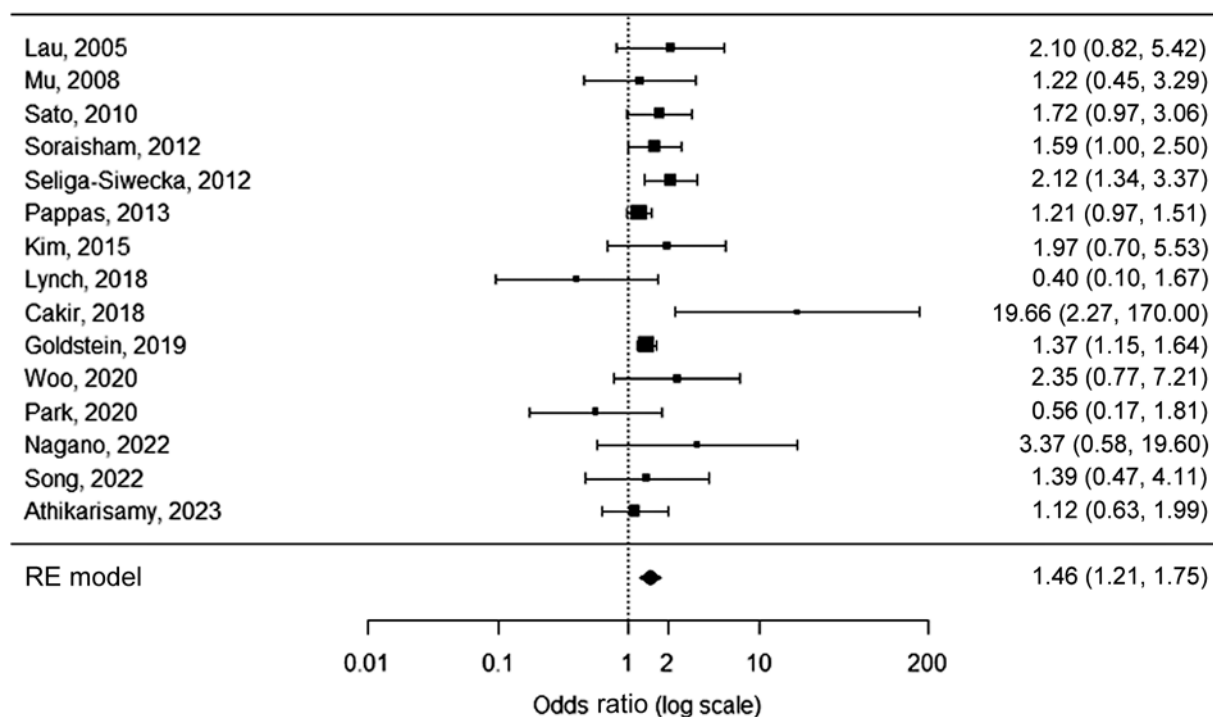
Seventeen studies assessing FUN in neonates with any stage ROP compared with neonates without ROP were included, with the number of sample size ranging from 29 to 2,009

**Table 1** Meta-regression regarding the influence of potential confounders on histological chorioamnionitis and any stage retinopathy of prematurity

| Univariate                | N | Estimate | SE     | Z-value | p-Value       | CI lower | CI higher | R <sup>2</sup> (%) | I <sup>2</sup> (%) |
|---------------------------|---|----------|--------|---------|---------------|----------|-----------|--------------------|--------------------|
| Gestational age at birth  | 8 | -0.3920  | 0.3068 | -1.2775 | 0.2014        | -0.9933  | 0.2094    | 3.26               | 74.02              |
| Birthweight               | 8 | -0.0014  | 0.0012 | -1.1361 | 0.2559        | -0.0037  | 0.0010    | 1.66               | 75.11              |
| Maternal steroids         | 8 | 0.0482   | 0.0204 | 2.3574  | <b>0.0184</b> | 0.0081   | 0.0882    | 56.87              | 53.57              |
| Necrotizing enterocolitis | 4 | 0.0489   | 0.0728 | 0.6708  | 0.5023        | -0.0939  | 0.1916    | 0.00               | 43.80              |
| Sepsis                    | 4 | 0.0381   | 0.0344 | 1.1090  | 0.2674        | -0.0293  | 0.1055    | 33.56              | 53.57              |
| Mechanical ventilation    | 3 | -0.0231  | 0.0735 | -0.3144 | 0.7532        | -0.1672  | 0.1209    | 0.00               | 78.90              |

Abbreviations: SE, standard error; CI, confidence interval.





**Fig. 3** Forest plot of the association between HCA and severe ROP. Heterogeneity:  $Q = 20.2$ ,  $I^2 = 30.8\%$ ,  $p = 0.1230$ . HCA, histological chorioamnionitis; ROP, retinopathy of prematurity; RE, random-effects.

**Table 2** Meta-regression regarding the influence of potential confounders on histological chorioamnionitis and severe retinopathy of prematurity

| Univariate                | N | Estimate | SE     | Z-value | p-Value | CI lower | CI higher | R <sup>2</sup> (%) | I <sup>2</sup> (%) |
|---------------------------|---|----------|--------|---------|---------|----------|-----------|--------------------|--------------------|
| Gestational age at birth  | 9 | -0.3910  | 0.1777 | -2.2006 | 0.0278  | -0.7393  | -0.0428   | 74.19              | 16.81              |
| Birthweight               | 8 | -0.0031  | 0.0016 | -1.9979 | 0.0457  | -0.0062  | -0.0001   | 99.85              | 0.07               |
| Maternal steroids         | 9 | 0.0108   | 0.0344 | 0.3132  | 0.7542  | -0.0567  | 0.0782    | 0.00               | 52.15              |
| Necrotizing enterocolitis | 8 | 0.0134   | 0.0317 | 0.4238  | 0.6717  | -0.0487  | 0.0755    | 0.00               | 50.26              |
| Sepsis                    | 5 | 0.0310   | 0.0153 | 2.0254  | 0.0428  | 0.0010   | 0.0610    | 43.36              | 44.48              |
| Mechanical ventilation    | 4 | -0.0314  | 0.0563 | -0.5588 | 0.5763  | -0.1417  | 0.0788    | 0.00               | 61.30              |

Abbreviations: SE, standard error; CI, confidence interval.

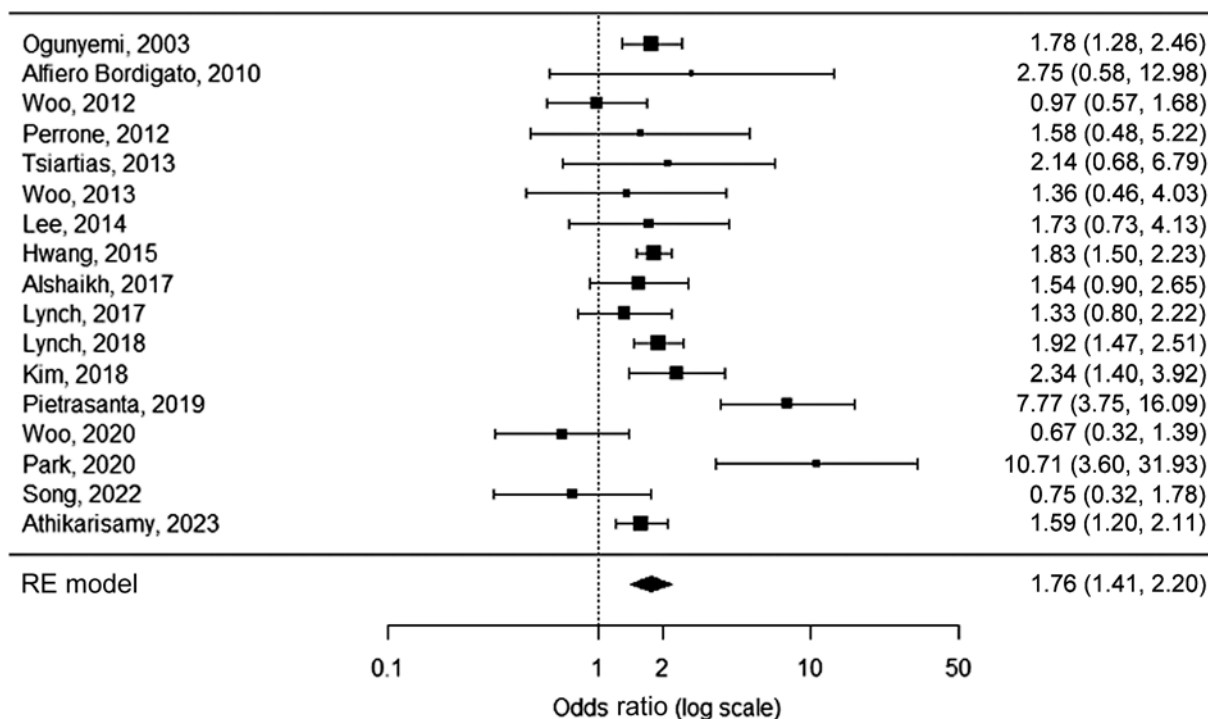
([Supplementary Table S3](#), available in the online version).<sup>24–28,32,33,44–53</sup> FUN was detected 1.8 times as frequently in neonates with any stage ROP compared with neonates without ROP (OR 1.8, 95% CI 1.4–2.2,  $p < 0.0001$ ; [Fig. 4](#)). Neither visual inspection and trim-and-fill number ( $n = 1$ ) of the funnel plot, nor the failsafe number ( $n = 472$ , Kendall's tau = 0.04,  $p = 0.8$ ) showed indication of publication bias ([Supplementary Fig. S3](#), available in the online version). Significant moderate heterogeneity was observed ( $Q: 45.8$ ,  $I^2: 65.1\%$ ,  $p < 0.0001$ ).

Secondary meta-regression analyses were performed to explore the heterogeneity found in this analysis ([Table 3](#)). Two factors were significant moderators in univariate analysis for the association between FUN and any stage ROP: GA at birth ( $\beta$ -coefficient  $-1.0$ , 95% CI  $-1.5$  to  $-0.4$ ,  $p = 0.0004$ ) and sepsis ( $\beta$ -coefficient 0.07, 95% CI 0.02–0.1,  $p = 0.006$ ). In multivariate analysis, no independent factors were found.

### Funisitis and Severe Retinopathy of Prematurity

Twenty-two studies assessing FUN in neonates with severe ROP compared with neonates with no/mild ROP were included, with the number of sample size ranging from 29 to 2,702 ([Supplementary Table S4](#), available in the online version).<sup>25,27,32,33,36,40,43–46,50,53–63</sup> FUN was detected more frequently in neonates with severe ROP compared with neonates with no/mild ROP (OR 1.4, 95% CI 1.1–1.6,  $p = 0.0008$ ; [Fig. 5](#)). Publication bias ([Supplementary Fig. S4](#), available in the online version) was neither detected in visual inspection and trim-and-fill number ( $n = 0$ ) of the funnel plot, nor the failsafe number ( $n = 151$ , Kendall's tau = 0.004,  $p = 1.0$ ). Significant moderate heterogeneity was observed ( $Q: 38.4$ ,  $I^2: 45.4\%$ ,  $p = 0.0115$ ).

In univariate meta-regression analysis, GA at birth ( $\beta$ -coefficient  $-0.7$ , 95% CI  $-1.2$  to  $-0.3$ ,  $p = 0.001$ ), BW ( $\beta$ -coefficient  $-0.004$ , 95% CI  $-0.007$  to  $-0.001$ ,  $p = 0.007$ )



**Fig. 4** Forest plot of the association between FUN and any stage ROP. Heterogeneity:  $Q = 45.8$ ,  $I^2 = 56.1\%$ ,  $p < 0.0001$ . FUN, funisitis; ROP, retinopathy of prematurity; RE, random-effects.

**Table 3** Meta-regression regarding the influence of potential confounders on funisitis and any stage retinopathy of prematurity

|                           | N | Estimate | SE     | Z-value | p-Value       | CI lower | CI higher | R <sup>2</sup> (%) | I <sup>2</sup> (%) |
|---------------------------|---|----------|--------|---------|---------------|----------|-----------|--------------------|--------------------|
| <b>Univariate</b>         |   |          |        |         |               |          |           |                    |                    |
| Gestational age at birth  | 6 | -0.9577  | 0.2725 | -3.5140 | <b>0.0004</b> | -1.4918  | -0.4235   | 100.00             | 0.00               |
| Birthweight               | 6 | 0.0010   | 0.0032 | 0.2986  | 0.7653        | -0.0053  | 0.0072    | 0.00               | 71.13              |
| Maternal steroids         | 6 | -0.0217  | 0.0273 | -0.7953 | 0.4265        | -0.0751  | 0.0318    | 16.23              | 73.71              |
| Necrotizing enterocolitis | 4 | 0.0337   | 0.1026 | 0.3289  | 0.7422        | -0.1673  | 0.2348    | 0.00               | 0.00               |
| Sepsis                    | 4 | 0.0665   | 0.0241 | 2.7622  | <b>0.0057</b> | 0.0193   | 0.1137    | 100.00             | 0.00               |
| Mechanical ventilation    | 2 | -        | -      | -       | -             | -        | -         | -                  | -                  |
| <b>Multivariate</b>       |   |          |        |         |               |          |           |                    |                    |
| Gestational age at birth  | 4 | -0.3234  | 0.9318 | -0.3471 | 0.7285        | -2.1497  | 1.5029    | 100.00             | 0.00               |
| Sepsis                    |   | 0.0501   | 0.0530 | 0.9456  | 0.3443        | -0.0538  | 0.1540    | -                  | -                  |

Abbreviations: SE, standard error; CI, confidence interval.

and maternal steroids ( $\beta$ -coefficient 0.04, 95% CI 0.01–0.07,  $p = 0.009$ ) were found to be significant moderators for the association between FUN and severe ROP (► **Table 4**). GA at birth was more significant compared with BW, which led to BW being omitted from multivariate meta-regression analysis to avoid multicollinearity with GA. In multivariate meta-regression analysis, lower GA at birth ( $\beta$ -coefficient -0.7, 95% CI -1.4 to -0.1,  $p = 0.021$ ) was found to be independently associated with the association between FUN and severe ROP.

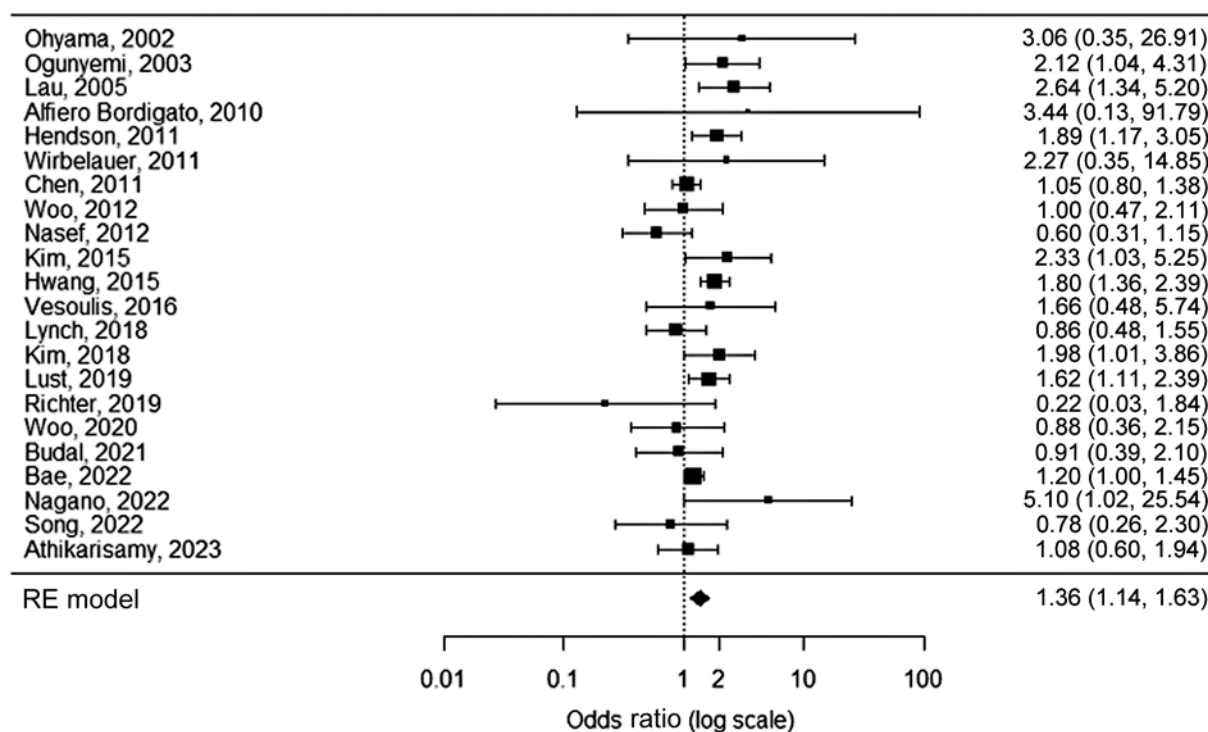
**Summary**

Neonates with HCA have a 1.8-fold increased risk for any stage ROP and 1.5-fold increased risk for severe ROP, while neonates with FUN have a 1.8-fold increased risk for any

stage ROP and 1.4-fold increased risk for severe ROP. Multivariate regression analysis suggests that lower GA increases the effect size between FUN and severe ROP.

**Discussion**

This systematic review and meta-analysis showed that neonates with HCA and/or FUN have an increased risk for any stage ROP and severe ROP. To our knowledge, this is the first meta-analysis with a relatively large number of studies demonstrating that the additional presence of the fetal response results in an even higher risk for developing ROP compared with only the maternal inflammatory response. Meta-regression analysis suggests that lower GA increases the effect size between FUN and severe ROP.



**Fig. 5** Forest plot of the association between FUN and severe ROP. Heterogeneity:  $Q = 38.4$ ,  $I^2 = 45.4\%$ ,  $p = 0.0115$ . FUN, funisitis; ROP, retinopathy of prematurity; RE, random-effects.

**Table 4** Meta-regression regarding the influence of potential confounders on funisitis and severe retinopathy of prematurity

|                           | N | Estimate | SE     | Z-value | p-Value       | CI lower | CI higher | R <sup>2</sup> (%) | I <sup>2</sup> (%) |
|---------------------------|---|----------|--------|---------|---------------|----------|-----------|--------------------|--------------------|
| <b>Univariate</b>         |   |          |        |         |               |          |           |                    |                    |
| Gestational age at birth  | 8 | -0.7285  | 0.2213 | -3.2923 | <b>0.0010</b> | -1.1622  | -0.2948   | 100.0              | 0.00               |
| Birthweight               | 8 | -0.0043  | 0.0016 | -2.7198 | <b>0.0065</b> | -0.0073  | -0.0012   | 100.0              | 0.00               |
| Maternal steroids         | 8 | 0.0392   | 0.0149 | 2.6315  | <b>0.0085</b> | 0.0100   | 0.0683    | 87.69              | 11.42              |
| Necrotizing enterocolitis | 5 | 0.1269   | 0.0707 | 1.7952  | 0.0726        | -0.0116  | 0.2654    | 100.0              | 0.00               |
| Sepsis                    | 6 | 0.0011   | 0.0491 | 0.0232  | 0.9815        | -0.0951  | 0.0973    | 0.00               | 64.12              |
| Mechanical ventilation    | 2 | -        | -      | -       | -             | -        | -         | -                  | -                  |
| <b>Multivariate</b>       |   |          |        |         |               |          |           |                    |                    |
| Gestational age at birth  | 7 | -0.7429  | 0.3206 | -2.3169 | <b>0.0205</b> | -1.3713  | -0.1144   | 100.00             | 0.00               |
| Maternal steroids         |   | 0.0039   | 0.0198 | 0.1962  | 0.8445        | -0.0349  | 0.0427    | -                  | -                  |

Abbreviations: SE, standard error; CI, confidence interval.

The pathophysiology behind this increased risk of ROP is believed to be due to production of proinflammatory cytokines, which play an important role in retinal angiogenesis, either directly or indirectly by sensitizing the retina to the effects of postnatal oxygen.<sup>64,65</sup> HCA stimulates the production of tumor necrosis factor- $\alpha$  and interleukin (IL)-1, IL-6, and IL-8, which can disrupt the blood-brain barrier and in turn lead to increased plasma protein influx and oligodendroglia damage.<sup>66,67</sup> Increased cytokine levels in the first 72 hours of life have been associated with severe ROP.<sup>68</sup> Additionally, perinatal inflammation induces decreased levels of IGF-1, which inhibit retinal vessel growth and, thus, increase the risk of ROP development.<sup>46,69,70</sup>

FUN is the histologic fetal inflammatory response of HCA, and its presence is believed to increase risk of ROP development.<sup>9</sup> However, little is known about FUN since most studies do not differentiate between HCA and FUN. HCA will not always lead to FUN, whereas FUN will always be the result of HCA. Therefore, it is plausible to hypothesize that an additional fetal inflammatory response would increase the risk of ROP compared with only the maternal inflammatory response. Our meta-analyses showed that neonates with FUN indeed had an increased risk for ROP compared with neonates without FUN (HCA without FUN or no HCA), which is based on the most extensive overview of included articles to date.



ROP is a multifactorial disease and multiple hits of antenatal and postnatal inflammation have been found to be associated with ROP.<sup>64,71,72</sup> Studies have shown that sepsis increases the risk of ROP—directly or indirectly—as a consequence of FUN or prematurity.<sup>73</sup> GA < 30 weeks and BW < 1,250 g are the main risk factors in the ROP screening program and could, therefore, partially influence the effect of HCA and FUN.<sup>74</sup> However, GA and BW could also be in the causal pathway, since HCA/FUN can lead to premature birth. The exact pathophysiology remains complex, and several studies have attempted to clarify this mechanism without conclusive evidence. Nevertheless, we have demonstrated that HCA and FUN are associated with ROP and that this association is increased when lower GA is present. Thus, GA is highly suggestive to be an effect modifier.

Three previous meta-analyses have explored the association between CA and ROP and showed opposing results.<sup>4,9,75</sup> Mitra et al reported no association between CA and ROP after adjusting for GA, while Villamor-Martinez et al (OR 1.4, 95% CI 1.1–1.7) and Bahmani et al (OR 1.5, 95% CI 1.0–2.2) showed significant associations. Villamor-Martinez et al also performed a subgroup analysis ( $n=2$ ) of FUN and found an increased risk of severe ROP (OR 2.3, 95% CI 1.2–4.3), but not any stage ROP. Notably, our methods of inclusion differed substantially. While the previous meta-analyses investigated the overall effect of CCA and HCA on ROP, we only focused on HCA and the difference between HCA and FUN. Additionally, our meta-analysis included a relatively larger number of studies ( $n=17$  for any stage ROP,  $n=22$  for severe ROP) with a longer study period (2002–2023) and, therefore, provides stronger evidence.

Remarkably, most studies investigating CA and ROP did not make a distinction between CCA and HCA, even though it has been reported that CCA is unreliable in diagnosing inflammation in the placenta. Studies have shown that intra-amniotic inflammation is only present in around 70% of patients with CCA and should, therefore not be used in scientific publications due to this high false-positive rate.<sup>76,77</sup> Furthermore, recommendations have been proposed to restrict the term CA to pathologic diagnosis, since substantial heterogeneity occurs in the criteria for CCA, and to introduce positive Gram stain, positive amniotic fluid culture and placental histology to the criteria of CA besides isolated maternal fever.<sup>7</sup> Excluding CCA cases provides stronger evidence and may explain the significantly higher odds of ROP in neonates with HCA found in our study.

Several limitations should be considered while interpreting our results. This meta-analysis mainly included retrospective studies, which may have introduced information bias and resulted in limited data on potential confounders. Additionally, severe HCA cases in the HCA group may also have had FUN, since some studies only examined the placenta for HCA. Furthermore, moderate heterogeneity existed between included studies. Nevertheless, our meta-analysis gives the most recent and elaborate overview of the association between HCA and ROP, particularly for the subgroup FUN. Additionally, the differentiation between maternal and

fetal inflammatory response demonstrated the importance of recognizing and diagnosing FUN. Lastly, by calculating unadjusted ORs from  $2 \times 2$  tables reported in studies, we have eliminated heterogeneity in confounder adjustment.

In conclusion, this meta-analysis confirms that HCA is a risk factor for any stage ROP and severe ROP. Additionally, it demonstrates the increased odds of any stage and severe ROP in neonates that have also been exposed to FUN. However, ROP is a multifactorial disease and part of the found effect may be influenced by the lower GA found in FUN cases. Future studies should define HCA based on histological placental diagnosis and report additional information on the presence of FUN. Subsequently, meta-regression analysis on potential confounders should be repeated. Nevertheless, our study introduces structured placental examination of HCA and FUN shortly after birth as a potential tool to further refine the ROP risk profile and to possibly tailor treatment interventions in a very early stage to optimize the condition for these vulnerable neonates at risk.

#### Funding

ODAS Foundation (Grant number 2021-32327). ODAS foundation had no role in the design or conduct of the study.

#### Conflict of interest

None declared.

#### References

- Carroll L, Owen LA. Current evidence and outcomes for retinopathy of prematurity prevention: insight into novel maternal and placental contributions. *Explor Med* 2020;1:4–26
- Owen LA, Morrison MA, Hoffman RO, Yoder BA, DeAngelis MM. Retinopathy of prematurity: a comprehensive risk analysis for prevention and prediction of disease. *PLoS ONE* 2017;12(02):e0171467
- Hellström A, Smith LE, Dammann O. Retinopathy of prematurity. *Lancet* 2013;382(9902):1445–1457
- Mitra S, Aune D, Speer CP, Saugstad OD. Chorioamnionitis as a risk factor for retinopathy of prematurity: a systematic review and meta-analysis. *Neonatology* 2014;105(03):189–199
- Redline RW. Inflammatory response in acute chorioamnionitis. *Semin Fetal Neonatal Med* 2012;17(01):20–25
- Han X, Du H, Cao Y, et al. Association of histological and clinical chorioamnionitis with perinatal and neonatal outcome. *J Matern Fetal Neonatal Med* 2021;34(05):794–802
- Higgins RD, Saade G, Polin RA, et al; Chorioamnionitis Workshop Participants. Evaluation and management of women and newborns with a maternal diagnosis of chorioamnionitis: summary of a workshop. *Obstet Gynecol* 2016;127(03):426–436
- Jung E, Romero R, Yeo L, et al. The fetal inflammatory response syndrome: the origins of a concept, pathophysiology, diagnosis, and obstetrical implications. *Semin Fetal Neonatal Med* 2020;25(04):101146
- Villamor-Martinez E, Cavallaro G, Raffaelli G, et al. Chorioamnionitis as a risk factor for retinopathy of prematurity: an updated systematic review and meta-analysis. *PLoS ONE* 2018;13(10):e0205838
- Welch V, Petticrew M, Petkovic J, et al; PRISMA-Equity Bellagio group. Extending the PRISMA statement to equity-focused systematic reviews (PRISMA-E 2012): explanation and elaboration. *J Clin Epidemiol* 2016;70:68–89

- 11 Modrzejewska M, Bosa-Gąsior W. Most up-to-date analysis of epidemiological data on the screening guidelines and incidence of retinopathy of prematurity in Europe—a literature review. *J Clin Med* 2023;12(11):3650
- 12 Kościółek M, Kisielewska W, Ćwiklik-Wierzbowska M, Wierzbowski P, Gilbert C. Systematic review of the guidelines for retinopathy of prematurity. *Eur J Ophthalmol* 2022;33(02):667–681
- 13 Santana DS, Silveira C, Costa ML, et al; WHO Multi-Country Survey on Maternal and Newborn Health Research Network. Perinatal outcomes in twin pregnancies complicated by maternal morbidity: evidence from the WHO Multicountry Survey on Maternal and Newborn Health. *BMC Pregnancy Childbirth* 2018;18(01):449
- 14 Trzcionkowska K, Groenendaal F, Andriessen P, et al. Risk factors for retinopathy of prematurity in the Netherlands: a comparison of two cohorts. *Neonatology* 2021;118(04):462–469
- 15 International Committee for the Classification of Retinopathy of Prematurity. The International Classification of Retinopathy of Prematurity revisited. *Arch Ophthalmol* 2005;123(07):991–999
- 16 Kim CJ, Romero R, Kusanovic JP, et al. The frequency, clinical significance, and pathological features of chronic chorioamnionitis: a lesion associated with spontaneous preterm birth. *Mod Pathol* 2010;23(07):1000–1011
- 17 Wells GA, Shea B, O'Connell D, Peterson J, Welch V, Losos M. The Newcastle-Ottawa Scale (NOS) for assessing the quality of non-randomized studies in meta-analyses. Accessed 17 November 2022 at: [http://www.ohri.ca/programs/clinical\\_epidemiology/oxford.htm](http://www.ohri.ca/programs/clinical_epidemiology/oxford.htm)
- 18 Viechtbauer W. Conducting meta-analyses in R with the metafor Package. *J Stat Soft* 2010;36(03):1–48. Accessed 17 November 2023 at: <https://www.jstatsoft.org/index.php/jss/article/view/v036i03>
- 19 Polam S, Koons A, Anwar M, Shen-Schwarz S, Hegyi T. Effect of chorioamnionitis on neurodevelopmental outcome in preterm infants. *Arch Pediatr Adolesc Med* 2005;159(11):1032–1035
- 20 Mehta R, Nanjundaswamy S, Shen-Schwarz S, Petrova A. Neonatal morbidity and placental pathology. *Indian J Pediatr* 2006;73(01):25–28
- 21 Mu SC, Lin CH, Chen YL, et al. Impact on neonatal outcome and anthropometric growth in very low birth weight infants with histological chorioamnionitis. *J Formos Med Assoc* 2008;107(04):304–310
- 22 Suppiej A, Franzoi M, Vedovato S, Marucco A, Chiarelli S, Zanardo V. Neurodevelopmental outcome in preterm histological chorioamnionitis. *Early Hum Dev* 2009;85(03):187–189
- 23 Soraisham AS, Trevenen C, Wood S, Singhal N, Sauve R. Histological chorioamnionitis and neurodevelopmental outcome in preterm infants. *J Perinatol* 2013;33(01):70–75
- 24 Lee Y, Kim HJ, Choi SJ, et al. Is there a stepwise increase in neonatal morbidities according to histological stage (or grade) of acute chorioamnionitis and funisitis?: effect of gestational age at delivery. *J Perinat Med* 2015;43(02):259–267
- 25 Lynch AM, Berning AA, Thevarajah TS, et al. The role of the maternal and fetal inflammatory response in retinopathy of prematurity. *Am J Reprod Immunol* 2018;80(03):e12986
- 26 Pietrasanta C, Pagni L, Merlo D, et al. Impact of different stages of intrauterine inflammation on outcome of preterm neonates: gestational age-dependent and -independent effect. *PLoS ONE* 2019;14(02):e0211484
- 27 Woo SJ, Park JY, Hong S, et al. Inflammatory and angiogenic mediators in amniotic fluid are associated with the development of retinopathy of prematurity in preterm infants. *Invest Ophthalmol Vis Sci* 2020;61(05):42
- 28 Park JY, Park CW, Moon KC, et al. Retinopathy of prematurity in infants without fetal growth restriction is decreased with the progression of acute histologic chorioamnionitis: new observation as a protective factor against retinopathy of prematurity. *Placenta* 2021;104:161–167
- 29 Ajayi SO, Morris J, Aleem S, et al. Association of clinical signs of chorioamnionitis with histological chorioamnionitis and neonatal outcomes. *J Matern Fetal Neonatal Med* 2022;35(26):10337–10347
- 30 Jang JH, Kim JG, Lee YH, Bae JG, Park JH. The association between amniotic fluid-derived inflammatory mediators and the risk of retinopathy of prematurity. *Medicine (Baltimore)* 2022;101(27):e29368
- 31 Bonafiglia E, Gusson E, Longo R, et al. Early and late onset sepsis and retinopathy of prematurity in a cohort of preterm infants. *Sci Rep* 2022;12(01):11675
- 32 Song JS, Woo SJ, Park KH, Kim H, Lee KN, Kim YM. Association of inflammatory and angiogenic biomarkers in maternal plasma with retinopathy of prematurity in preterm infants. *Eye (Lond)* 2023;37(09):1802–1809
- 33 Athikarisamy SE, Lam GC, Cooper MN, Strunk T. Retinopathy of prematurity and placental histopathology findings: a retrospective cohort study. *Front Pediatr* 2023;11:1099614
- 34 Kaur T, Sharma N, Jakati S, et al. Role of maternal, fetal and placental histopathology factors in the pathogenesis of retinopathy of prematurity. *bioRxiv* 2023
- 35 Strawbridge JC, Chu A, Dammann O, Hanson J, Janzen C, Tsui I. prenatal maternal characteristics associated with retinopathy of prematurity. *Retina* 2023;43(02):230–237
- 36 Lau J, Magee F, Qiu Z, Houbé J, Von Dadelszen P, Lee SK. Chorioamnionitis with a fetal inflammatory response is associated with higher neonatal mortality, morbidity, and resource use than chorioamnionitis displaying a maternal inflammatory response only. *Am J Obstet Gynecol* 2005;193(3 Pt 1):708–713
- 37 Sato M, Nishimaki S, Yokota S, et al. Severity of chorioamnionitis and neonatal outcome. *J Obstet Gynaecol Res* 2011;37(10):1313–1319
- 38 Seliga-Siwecka JP, Kornacka MK. Neonatal outcome of preterm infants born to mothers with abnormal genital tract colonisation and chorioamnionitis: a cohort study. *Early Hum Dev* 2013;89(05):271–275
- 39 Pappas A, Kendrick DE, Shankaran S, et al; Eunice Kennedy Shriver National Institute of Child Health and Human Development Neonatal Research Network. Chorioamnionitis and early childhood outcomes among extremely low-gestational-age neonates. *JAMA Pediatr* 2014;168(02):137–147
- 40 Kim SY, Choi CW, Jung E, et al. Neonatal morbidities associated with histologic chorioamnionitis defined based on the site and extent of inflammation in very low birth weight infants. *J Korean Med Sci* 2015;30(10):1476–1482
- 41 Çakir U, Yildiz D, Kahvecioğlu D, et al. Placenta, secret witness of infant morbidities: the relationship between placental histology and outcome of the premature infant. *Turk Patoloji Derg* 2019;35(01):28–35
- 42 Goldstein GP, Leonard SA, Kan P, Koo EB, Lee HC, Carmichael SL. Prenatal and postnatal inflammation-related risk factors for retinopathy of prematurity. *J Perinatol* 2019;39(07):964–973
- 43 Nagano N, Katayama D, Hara K, et al. Association of umbilical cord insulin-like growth factor 1 levels with severe retinopathy in extremely preterm infants. *Pediatr Neonatol* 2023;64(02):126–132
- 44 Ogunyemi D, Murillo M, Jackson U, Hunter N, Alperson B. The relationship between placental histopathology findings and perinatal outcome in preterm infants. *J Matern Fetal Neonatal Med* 2003;13(02):102–109
- 45 Alfiero Bordigato M, Piva D, Di Gangi IM, Giordano G, Chiandetti L, Filippone M. Asymmetric dimethylarginine in ELBW newborns exposed to chorioamnionitis. *Early Hum Dev* 2011;87(02):143–145
- 46 Woo SJ, Park KH, Jung HJ, et al. Effects of maternal and placental inflammation on retinopathy of prematurity. *Graefes Arch Clin Exp Ophthalmol* 2012;250(06):915–923

- 47 Perrone S, Toti P, Toti MS, et al. Perinatal outcome and placental histological characteristics: a single-center study. *J Matern Fetal Neonatal Med* 2012;25(suppl 1):110–113
- 48 Tsiartas P, Kacerovsky M, Musilova I, et al. The association between histological chorioamnionitis, funisitis and neonatal outcome in women with preterm prelabor rupture of membranes. *J Matern Fetal Neonatal Med* 2013;26(13):1332–1336
- 49 Woo SJ, Park KH, Lee SY, et al. The relationship between cord blood cytokine levels and perinatal factors and retinopathy of prematurity: a gestational age-matched case-control study. *Invest Ophthalmol Vis Sci* 2013;54(05):3434–3439
- 50 Hwang JH, Lee EH, Kim EA. Retinopathy of prematurity among very-low-birth-weight infants in Korea: incidence, treatment, and risk factors. *J Korean Med Sci* 2015;30(suppl 1):S88–S94
- 51 Alshaikh B, Salman O, Soliman N, Ells A, Yusuf K. Pre-eclampsia and the risk of retinopathy of prematurity in preterm infants with birth weight <1500 g and/or <31 weeks' gestation. *BMJ Open Ophthalmol* 2017;1(01):e000049
- 52 Lynch AM, Wagner BD, Hodges JK, et al. The relationship of the subtypes of preterm birth with retinopathy of prematurity. *Am J Obstet Gynecol* 2017;217(03):354.e1–354.e8
- 53 Kim CY, Jung E, Kim EN, et al. Chronic placental inflammation as a risk factor of severe retinopathy of prematurity. *J Pathol Transl Med* 2018;52(05):290–297
- 54 Ohyama M, Itani Y, Yamanaka M, et al. Re-evaluation of chorioamnionitis and funisitis with a special reference to subacute chorioamnionitis. *Hum Pathol* 2002;33(02):183–190
- 55 Henderson L, Russell L, Robertson CM, et al. Neonatal and neurodevelopmental outcomes of very low birth weight infants with histologic chorioamnionitis. *J Pediatr* 2011;158(03):397–402
- 56 Wirbelauer J, Thomas W, Speer CP. Response of leukocytes and nucleated red blood cells in very low-birth weight preterm infants after exposure to intrauterine inflammation. *J Matern Fetal Neonatal Med* 2011;24(02):348–353
- 57 Chen ML, Allred EN, Hecht JL, et al; ELGAN Study. Placenta microbiology and histology and the risk for severe retinopathy of prematurity. *Invest Ophthalmol Vis Sci* 2011;52(10):7052–7058
- 58 Nasef N, Shabaan AE, Schurr P, et al. Effect of clinical and histological chorioamnionitis on the outcome of preterm infants. *Am J Perinatol* 2013;30(01):59–68
- 59 Vesoulis ZA, Lust CE, Liao SM, Trivedi SB, Mathur AM. Early hyperoxia burden detected by cerebral near-infrared spectroscopy is superior to pulse oximetry for prediction of severe retinopathy of prematurity. *J Perinatol* 2016;36(11):966–971
- 60 Lust C, Vesoulis Z, Jackups R Jr, Liao S, Rao R, Mathur AM. Early red cell transfusion is associated with development of severe retinopathy of prematurity. *J Perinatol* 2019;39(03):393–400
- 61 Richter AE, Bos AF, Huiskamp EA, Kooi EMW. Postnatal cerebral hyperoxia is associated with an increased risk of severe retinopathy of prematurity. *Neonatology* 2019;116(04):356–362
- 62 Budal EB, Ebbing C, Kessler J, et al. Placental histology predicted adverse outcomes in extremely premature neonates in Norway-population-based study. *Acta Paediatr* 2022;111(03):546–553
- 63 Bae SP, Kim EK, Yun J, Yoon YM, Shin SH, Park SY. Retinopathy of prematurity requiring treatment is closely related to head growth during neonatal intensive care unit hospitalization in very low birth weight infants. *Neonatology* 2022;119(02):176–183
- 64 Lee J, Dammann O. Perinatal infection, inflammation, and retinopathy of prematurity. *Semin Fetal Neonatal Med* 2012;17(01):26–29
- 65 Dammann O, Leviton A. Maternal intrauterine infection, cytokines, and brain damage in the preterm newborn. *Pediatr Res* 1997;42(01):1–8
- 66 Stolp HB, Dziegielewska KM. Review: Role of developmental inflammation and blood-brain barrier dysfunction in neurodevelopmental and neurodegenerative diseases. *Neuropathol Appl Neurobiol* 2009;35(02):132–146
- 67 Silveira RC, Fortes Filho JB, Procianny RS. Assessment of the contribution of cytokine plasma levels to detect retinopathy of prematurity in very low birth weight infants. *Invest Ophthalmol Vis Sci* 2011;52(03):1297–1301
- 68 Sood BG, Madan A, Saha S, et al; NICHD Neonatal Research Network. Perinatal systemic inflammatory response syndrome and retinopathy of prematurity. *Pediatr Res* 2010;67(04):394–400
- 69 Smith LE. Pathogenesis of retinopathy of prematurity. *Growth Horm IGF Res* 2004;14(suppl A):S140–S144
- 70 Hellstrom A, Perruzzi C, Ju M, et al. Low IGF-I suppresses VEGF-survival signaling in retinal endothelial cells: direct correlation with clinical retinopathy of prematurity. *Proc Natl Acad Sci U S A* 2001;98(10):5804–5808
- 71 Dammann O, Brinkhaus MJ, Bartels DB, et al. Immaturity, perinatal inflammation, and retinopathy of prematurity: a multi-hit hypothesis. *Early Hum Dev* 2009;85(05):325–329
- 72 Lundgren P, Lundberg L, Hellgren G, et al. Aggressive posterior retinopathy of prematurity is associated with multiple infectious episodes and thrombocytopenia. *Neonatology* 2017;111(01):79–85
- 73 Wang X, Tang K, Chen L, Cheng S, Xu H. Association between sepsis and retinopathy of prematurity: a systematic review and meta-analysis. *BMJ Open* 2019;9(05):e025440
- 74 van Sorge AJ, Schalij-Delfos NE, Kerkhoff FT, et al. Reduction in screening for retinopathy of prematurity through risk factor adjusted inclusion criteria. *Br J Ophthalmol* 2013;97(09):1143–1147
- 75 Bahmani T, Karimi A, Rezaei N, Daliri S. Retinopathy prematurity: a systematic review and meta-analysis study based on neonatal and maternal risk factors. *J Matern Fetal Neonatal Med* 2022;35(25):8032–8050
- 76 Seong HS, Kang YD, Lee SE, et al. Lack of evidence for microorganisms in most women with clinical chorioamnionitis: a need to revisit the clinical and microbiologic criteria for one of the most important obstetrical complications. *Am J Obstet Gynecol* 2006;195(06):S73
- 77 Gibbs RS, Blanco JD, St Clair PJ, Castaneda YS. Quantitative bacteriology of amniotic fluid from women with clinical intra-amniotic infection at term. *J Infect Dis* 1982;145(01):1–8