



**Universiteit  
Leiden**  
The Netherlands

## **Characteristics and clinical outcomes of mucosal melanoma**

Boer, F.L.

### **Citation**

Boer, F. L. (2024, March 19). *Characteristics and clinical outcomes of mucosal melanoma*. Retrieved from <https://hdl.handle.net/1887/3725231>

Version: Publisher's Version

License: [Licence agreement concerning inclusion of doctoral thesis in the Institutional Repository of the University of Leiden](#)

Downloaded from: <https://hdl.handle.net/1887/3725231>

**Note:** To cite this publication please use the final published version (if applicable).



## General discussion and future perspectives



Mucosal melanoma (MM) is a rare melanoma subtype characterized by its unique tumour biology, aggressive course of disease and poor prognosis. [1] Whilst in CM significant progress in preventive and therapeutic strategies has been made, in MM progress has been slow and lags behind that of its cutaneous counterpart. [2-6] For unresectable stage III and stage IV CM, the introduction of immune- and targeted therapy in 2011, has revolutionized the therapeutic landscape. Both have resulted in improvement of overall survival (OS) for advanced CM. [6] Unfortunately, the prognosis of MM is still lagging behind of CM and has not improved over the past decades.

The worse prognosis of MM is partly ascribed to the low incidence of this disease, impeding large studies and clinical trials. Moreover, historically, treatment of localized MM is done by the doctor who is specialized in cancer at the primary tumor site. For instance, MM located at the female genital tract is treated by a gynaeco-oncologist whilst MM located at the head and neck is treated by an otolaryngologist. Consequently, for a long time, diagnostic approach, staging, treatment of local disease and most important research, did not cross the borders set by the doctor's field of interest. Fortunately, within national healthcare systems, there has been a significant improvement in collaboration leading to the concentration of care for rare diseases like MM. Within these hospitals, multidisciplinary teams work together to evaluate diagnostic and treatment strategies using the expertise of doctors across multiple disciplines. Still, to improve the care of MM, it is crucial to gain a deeper understanding of the biological behaviour and course of disease, in which international collaboration can be a powerful tool.

In this thesis, by collaborating with national and international hospitals, we analyzed clinical and histopathological characteristics and survival of a large cohort of vulvar melanomas (VM). Moreover, we reviewed the literature of VM resulting in a flow-chart In part 2 of this thesis, we assessed incidence of and analyzed trends of survival over time against the background of the new era of immune- and targeted therapy. Therefore, we used the well-functioning national cancer registry (NCR) and Dutch Melanoma Treatment Registry (DMTR), both characterized by their high coverage of patients diagnosed with any tumor or type of melanoma in the Netherlands. The DMTR includes clinical, pathological and treatment characteristics, making it a valuable database which can be used to evaluate the effect of the quickly accelerating landscape of systemic therapies in melanoma. The use of NCR data provided insights in incidence and survival over more than thirty years. This final discussion will summarize the key points of this thesis and will focus on the future by addressing new perspectives and possible new treatment options.

## Understanding the course of disease

In **Chapter 2** we observed that whilst in the Netherlands, incidence of CM has increased, the incidence of MM has remained stable with approximately 50 new cases every year. [6] Moreover, we found that whilst in CM there has been a shift to more patients with localized disease at presentation, in MM stage at presentation has not changed and patients often present with advanced disease. [6] In total, MM presents with distant metastasis in 15.1-23.6% of the cases whilst in CM this is the case in only 4% of the cases. [7, 8]

In CM, detection at lower stage of disease through preventive measures, as effective screening programs has been essential for improving survival rates. However, a screening program is often driven by the prevalence of the disease being screened for. Therefore rare diseases are not part of these programs. For less common cancers, creating awareness is the best preventive measure. Apart from MM located at the exterior mucosal lining of the vulva and the penis, the lack of visibility of MM makes it difficult to detect and monitor, and doctors delay and patients delay is not uncommon. As in most cancers, stage at diagnosis largely impacts survival. We found a median OS and 1-year OS of 2.4 years and 77.2% whilst in distant spread disease this is 0.6 years and 31.4% (**Chapter 2**). As in other types of cancer, metastatic disease is the leading cause of cancer-related mortality in MM and creating awareness for these cancer types in both patients and doctors may help to minimize delay in diagnosis and treatment and thus lower stage at diagnosis.

Yet, even localized MM harbour a poor prognosis and therefore, preventive strategies may not even be the way to go. We found that 5-year OS rates between stage I MM and stage I CM differed significantly (30.8% vs 71%-100%) (**Chapter 2**). [9, 10] This striking 40-70% survival gap is mainly due to the high recurrence rates and almost half of the patients developing regional or distant metastases. Understanding the course of disease and metastatic pattern may help to optimize the frequency and method of imaging in the follow-up, identifying spread of disease in an earlier phase.

The largest analysis of metastatic spread includes 706 patients with MM, of which 152 (21.5%) with nodal spread disease (stage III) and 163 (23.0%) with distant spread disease (stage IV). Of those who were diagnosed with, or developed, stage IV disease, disease most often spread to the lung, liver, distant lymph nodes or to both lung and liver, in respectively 21%, 19%, 9% and 7% of the patients. [8] An important note is that in the majority of the liver only or lung only metastasized cases, there were multiple metastasis (87.0% and 78.5%). Results of a smaller cohort were similar, though patients presented with disseminated metastatic disease in 19% of the cases. [7] Given the relatively low efficacy of systemic treatments for MM, local treatment of metastatic disease may represent a viable approach to delay the use of systemic treatments accompanied with high toxicity levels, and to improve OS.

Furthermore, gaining knowledge of the course of disease may allow early identification of patients who have a high risk of rapid disease progression and who may not benefit from (local) surgical treatment of the primary tumor. Though, surgeons aim for minimal resection margins, local excision often still consists of extensive surgery affecting quality of life.

In the literature, vulvar and vaginal melanomas are frequently grouped together and analysed as one entity (**Chapter 5**). However, studies that have specifically focused on vulvar and vaginal melanomas as separate entities have demonstrated a distinct course of disease. [11] Noticeable, is the worse prognosis of vaginal melanoma when compared to vulvar melanoma. In **Chapter 6**, we analysed 198 patients with vulvar melanoma and found a median OS of 33 months whilst the literature reports a median OS of 10-24 months for vaginal melanoma. [11, 12] The worse prognosis of vaginal MM may be explained by a delay in diagnosis, as the MM may be less visible, resulting in a higher stage at diagnosis. [13] Moreover, whilst the vagina exists of solely mucosal lining, the vulva exhibits both hairy skin (cutaneous lining) and glabrous skin (mucosal lining). Thus, some vulvar melanomas arise from cutaneous skin and therefore these can may also have more resemblance with CM than with MM. As CM is known for the better prognosis, this could explain better outcomes in vulvar melanomas as compared to vaginal melanomas. [14]

## Unraveling the tumour biology: towards novel treatment strategies in MM

The tremendous developments in systemic treatment, particularly immune- and targeted therapy, have improved the survival of advanced CM. [15, 16] This rising tide, however, has not lifted all the boats. In **Chapter 3**, we found that since 2015, immune- and targeted therapy more often were part of treatment in MM, but that survival of advanced disease did not improve during the same time period. Moreover immunotherapy had a lower objective response rate (ORR) as compared to CM (20.6% vs 37.8%) and median OS of patients treated with systemic therapy, was 6 months lower in MM when compared to CM (11.8 months vs 17.9 months). Clinical trials have demonstrated that combined anti-CTLA-4/anti-PD-1 treatment in CM has a higher ORR as compared to anti-CTLA-4 and anti-PD-1 monotherapy (58% vs 45% and 19%) [17] In **Chapter 4** we analysed 46 patients with MM who received combined ipilimumab/nivolumab and ORR was 39.2% (n=18/46) of which five responded completely. Though the efficacy seems to be higher than single agent immunotherapy, median OS is only 9.7 months and approximately 60% of the patients does not respond, thus leaving the majority without an effective treatment strategy.

It has long been recognized that MM is biologically different than CM. A lower tumor mutational burden (TMB) and distinct oncogenic mutations are reported. [18-20] In particular

MM harbour a lower rate of BRAF mutations as compared to CM, 5.9% and 55.9% respectively (**Chapter 3**). Consequently, the highly efficacious BRAF/MEK inhibitors (vemurafenib/cobimetinib dabrafenib/trametinib and encorafenib/binimetinib), ensuing durable responses, are of less use in MM. [19-21] MM however is characterized by a relatively higher rate of KIT mutations (13-23% vs 3% in CM). [19-21] A systematic review reported an ORR of 14% of in MM treated with (any) KIT-inhibitor, though durability of response was reported inconsistently making a meta-analysis not feasible. [22] Median time to progression in a study evaluating 25 melanoma, of which the majority MM, was 3.7 months and eventually all but one had progressive disease. [23] Thus, though (targetable) KIT mutations are seen in a subset of MM, the low efficacy of KIT inhibitors, underscore the urgency for different systemic agents or new combinations of existing agents. However, as seen in **Chapter 6**, genetic analysis is only performed in the minority of the cases, resulting in incomplete understanding of the genetic landscape.

It is widely accepted that, tumour infiltrating lymphocytes (TIL's), represent the local anti-tumour immune response in pathological assessed tumours. [24] In various types of cancer, including CM, the presence of CD8+ cytotoxic T-cells, CD4+ helper T-cells and memory T-cells, is associated with better survival and a better response to immune checkpoint inhibitors (ICI) whilst the presence of regulatory T-cells (T-reg's) around the tumour is associated with worse prognosis and a lower response to ICI. [25-29] Though based on small studies, MM seem to have a lower level of TIL's and a higher level of T-reg's, compared to CM. [27, 30-33] The immune microenvironment of MM in relation to survival and ICI response has not been studied, thus far reaching conclusions cannot be made. If it follows the pattern of CM, the lower number of TIL's, may explain the relative resistance to ICI in MM.

Exploring the immune microenvironment of MM can give valuable insights in the potential drivers of the lower response to ICI. These, then can provide an avenue by minimizing the number of patients treated with ICI without gaining survival advantage, though being at risk of ICI related toxicity. [34] Moreover, the presence of TIL's may be of future benefit when considering TIL therapy, which already has demonstrated to improve PFS and OS in patients with advanced CM. [35]

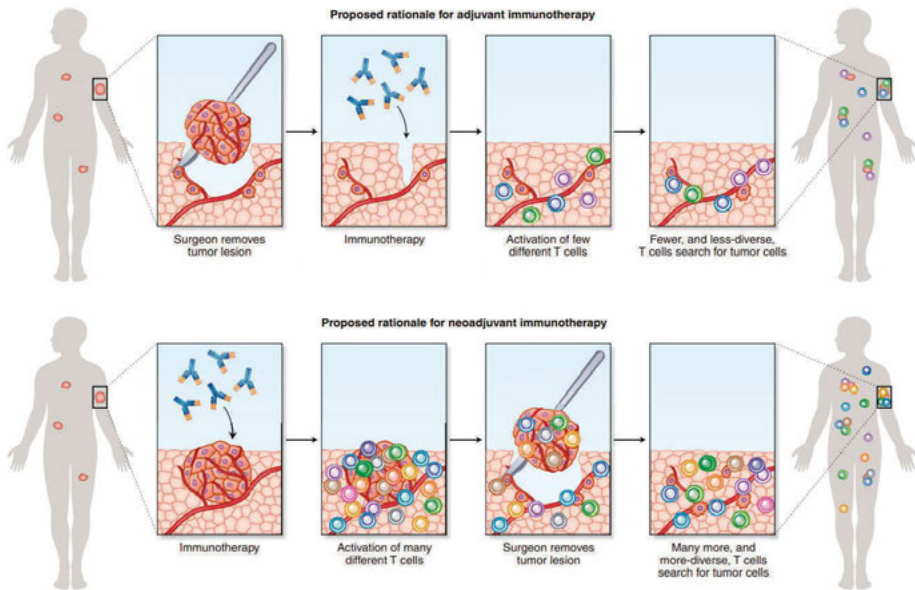
## (Neo)-adjuvant immunotherapy

The striking evidence regarding immunotherapy improving OS and progression-free survival (PFS) in metastatic CM is indisputable. Furthermore, in adjuvant setting, immunotherapy lowers the risk of recurrence in stage IIB, IIC and high-risk clinical stage III CM. Still, despite the use of adjuvant immunotherapy clinical stage III CM has suboptimal outcomes, can give

life-lasting side-effects and often recurs, sometimes even before the patient has started with adjuvant therapy [36]. Therefore, there is a high need for new (combinations of) therapeutic agents, better timing of therapy and improved treatment regimes.

Preclinical trials studying mice with breast cancer, demonstrated that neoadjuvant immunotherapy improved OS and can tackle occult distant metastasis when compared with the same immunotherapy in adjuvant setting. [37] The hypothesis for better outcomes of those who received ICI before surgery when compared with those who received it following surgery, is that the tumor load in situ can establish a higher immune response when the immune microenvironment of the tumor is still intact (Figure 1). [38, 39] This neoadjuvant approach is emerging and many clinical trials evaluating efficacy and safety of different (combinations of) ICI in CM, are ongoing.

**Figure 1.** Rationale for neoadjuvant immunotherapy



Adapted from "Learning from clinical trials of neoadjuvant checkpoint blockade" Versluis et al. *Nature Medicine*, 2020. Reprinted with permission of the publisher Springer Nature

The OpACIN (phase I) trial and OpACIN-Neo (phase II) trial, assessed the pathological response (PR), safety and dosing schedule of neoadjuvant immunotherapy in resectable stage III CM. [40, 41] In the OpACIN study, PR was seen in 78% (7/9) of the cases of which, at a median follow-up of 4 years, none relapsed. [40, 42] The OpACIN-Neo trial demonstrated a PR of 74% (64/86), of which at 2 years recurrence-free survival (RFS) was 97% for those with



PR and 36% for those with without PR, suggesting that PR can be predictive for RFS. [41, 42] In advanced CM (resectable stage III and stage IV), a phase II clinical trial demonstrated that neoadjuvant-adjuvant pembrolizumab compared with adjuvant pembrolizumab, provides a higher event-free survival (EFS) and that treatment related adverse events are similar. [43] In MM, two phase II clinical trials assessing neoadjuvant anti-PD-1 therapy with or without lenvatininb (a multi-targeted tyrosine kinase inhibitor) are currently open (NCT05545969 and NCT03313206), but results are awaiting. Up to today, only few studies assessing neoadjuvant therapy in MM are published. A retrospective assessment of 21 stage II/III resectable MM treated with toripalimab and axitinib by Cui et al found PR in 28.6% of the cases and median RFS of 56 weeks. [44] A second study assessed 36 stage II/III MM treated with neoadjuvant anti-PD-1, anti-CTLA-4 or combined anti-PD-1/anti-CTLA-4. PR was seen in 35% of the cases and median EFS, defined as time to progression, recurrence or death, was 40 weeks. [45] As in the adjuvant setting, the efficacy of neoadjuvant immunotherapy in MM is lower than in CM. [41]

Besides a stronger and broader T-cell response leading to longer PFS, neoadjuvant therapy can also reduce the size of bulky tumors. As surgery, with R0 resections improving RFS and OS, is the mainstay of treatment in MM, less extensive surgery has high priority. [46] In the study by Ho et al, 36 patients with resectable MM were treated with neoadjuvant immunotherapy, of which 3 patients (8%) had complete response and did not require surgery. However, in 6 cases (17%) the primary tumor progressed and was unresectable. This reveals the possible downside of neoadjuvant immunotherapy as delaying surgery may negatively impact the window of opportunity of resection of the primary tumour. However, a different perspective, is that the identification of non-responders who disseminate rapidly, is not a lost chance but a way to prevent those with an unfavorable prognosis, to undergo surgical treatment without survival benefit. [47] Though no studies are available assessing neoadjuvant immunotherapy in unresectable CM or MM the REDUCTOR trial studied BRAF/MEK inhibitors in unresectable regionally advanced CM. This resulted in shrinkage of the tumour leading to a resectable tumour in 18/21 cases of which 17 had an R0 resection. [48] If PR can become an established early endpoint, it may help to accelerate approval of neoadjuvant strategies in MM.

Lastly, an important benefit of neoadjuvant strategies is the opportunity to personalize treatment based on PR. In many types of cancer major pathologic response (MPR), defined as 10% or less residual viable tumour cells after neoadjuvant therapy, is used as outcome marker. Similarly in CM, the international neoadjuvant melanoma consortium conducted a pooled analysis of six neoadjuvant trials and demonstrated that in CM PR is associated with RFS and OS and is proposed as standard. [47] Thus, complete PR brings the opportunity to de-escalate (surgical) treatment, whilst poor response can encourage medical doctors to adjust or to add components to the treatment strategy. This individualized type of care

has been studied in the PRADO trial in which patients with clinical stage III nodal melanoma were treated with neoadjuvant immunotherapy. Nodal dissection with or without adjuvant therapy was performed in those with no or partial response, whilst in responders these were omitted, without affecting OS. [49]

## Future perspectives

Experimental therapies in MM, follow the footsteps of CM. Here, we will shine the light on more experimental therapies. One of those, which currently is investigated, are antiangiogenic agents as axitinib. Vascular endothelial growth factor (VEGF) inhibition can hamper the ability of VEGF to sustain tumour growth and enhance tumour survival and therefore may be limit progression of disease in the highly vascularized MM. [50, 51] After 3-year follow-up of a phase 1B study including 33 advanced MM treated with axitinib combined with toripalimab (a humanized immunoglobulin G<sub>4</sub> monoclonal antibody against PD-1) demonstrated a ORR of 48.7% and a median PFS of 7.5 and median OS of 20.7 months. [52, 53] Real-world data of MM treated with anti-VEGF combined with anti-PD-1 therapy (of which half was treatment naïve and half received this as first line treatment) demonstrated a lower ORR of 24.5% but disease control was seen in 72.7% and a ORR of 30.0% in treatment naïve patients. [54] These less convincing results in a real-world setting ask a phase III or randomized trial to evaluate the effect of anti-VEGF in combination with immunotherapy.

As already mentioned earlier, adoptive cell therapy (of which T-cell receptor therapy and tumour infiltrating lymphocytes therapy) is one of these empirical treatment strategies. In CM, this has shown promising results in terms of antitumor activity and survival, whilst in MM this topic needs more evidence. [55] Moreover, local interleukin-12 combined with ICI have recently been evaluated in phase I and II trials including metastatic CM, and are promising. IL-12 is a pivotal immune regulator and has major anti-tumor effects as it inhibits tumor growth by increasing infiltration of CD8-T cells and decreasing T-regs's, but is related with alarming toxicity when administered systemically. [56, 57] Local IL-12 in stage IV CM yielded an ORR of 35.7%, also affecting distant sites other than the location of administration, and an acceptable safety profile. [58] Moreover, even in non-immune infiltrated tumours (cold tumours) which are known to be ICI resistant, IL-12 combined with anti-PD-1 showed promising results. ORR was 41%, of which 42% of the responders were anti-PD-1 refractory and ORR was 30% in a cohort consisting of solely anti-PD-1-refractory advanced CM. [59] IL-12 in combination with anti-PD-1 therapy is worth evaluating in MM, as they generally are poor responders to ICI.

## Final conclusion

Over the past decade, rare cancers, including MM, have been studied at a higher pace. Still, cohorts are small and patients with MM are often excluded from clinical trials. Therefore only little evidence regarding novel therapeutic agents in MM is available. While small studies are providing some guidance, the development of effective strategies for advanced MM is progressing slowly. To improve outcomes in MM, there is a critical need for clinical trials specifically designed for this disease. Additionally, translational research can play a pivotal role in improving our knowledge of tumor biology and immune response in MM. To address the challenges ahead, there should be a focus on new combinations of existing therapies and shifting the timing and sequence of existing and novel therapeutic agents. Lastly, treating patients in the neoadjuvant setting, aiming to overcome occult metastasis, holds significant promise as a potential breakthrough.

## References

- Elder DE, Bastian BC, Cree IA, Massi D, Scolyer RA. The 2018 World Health Organization Classification of Cutaneous, Mucosal, and Uveal Melanoma: Detailed Analysis of 9 Distinct Subtypes Defined by Their Evolutionary Pathway. *Arch Pathol Lab Med.* **2020**;144(4):500-22.
- Michielin O, van Akkooi ACJ, Ascierto PA, Dummer R, Keilholz U. Cutaneous melanoma: ESMO Clinical Practice Guidelines for diagnosis, treatment and follow-up†. *Ann Oncol.* **2019**;30(12):1884-901.
- Garbe C, Amaral T, Peris K, Hauschild A, Arenberger P, Basset-Seguín N, Bastholt L, Bataille V, Del Marmol V, Dréno B, et al. European consensus-based interdisciplinary guideline for melanoma. Part 2: Treatment - Update 2022. *Eur J Cancer.* **2022**;170:256-84.
- Garbe C, Amaral T, Peris K, Hauschild A, Arenberger P, Basset-Seguín N, Bastholt L, Bataille V, Del Marmol V, Dréno B, et al. European consensus-based interdisciplinary guideline for melanoma. Part 1: Diagnostics: Update 2022. *Eur J Cancer.* **2022**;170:236-55.
- Arnold M, Singh D, Laversanne M, Vignat J, Vaccarella S, Meheus F, Cust AE, de Vries E, Whiteman DC, Bray F. Global Burden of Cutaneous Melanoma in 2020 and Projections to 2040. *JAMA Dermatol.* **2022**;158(5):495-503.
- Leeneman B, Schreuder K, Uyl-de Groot CA, van Akkooi ACJ, Haanen J, Wakkee M, Franken MG, Louwman MWJ. Stage-specific trends in incidence and survival of cutaneous melanoma in the Netherlands (2003-2018): A nationwide population-based study. *Eur J Cancer.* **2021**;154:111-9.
- Grözinger G, Mann S, Mehra T, Klumpp B, Grosse U, Nikolaou K, Garbe C, Clasen S. Metastatic patterns and metastatic sites in mucosal melanoma: a retrospective study. *Eur Radiol.* **2016**;26(6):1826-34.
- Lian B, Cui CL, Zhou L, Song X, Zhang XS, Wu D, Si L, Chi ZH, Sheng XN, Mao LL, et al. The natural history and patterns of metastases from mucosal melanoma: an analysis of 706 prospectively-followed patients. *Ann Oncol.* **2017**;28(4):868-73.
- Leeneman B, Franken MG, Coupé VMH, Hendriks MP, Kruit W, Plaisier PW, van Ruth S, Verstijnen J, Wouters M, Blommestein HM, et al. Stage-specific disease recurrence and survival in localized and regionally advanced cutaneous melanoma. *Eur J Surg Oncol.* **2019**;45(5):825-31.
- Boer FL, Ho VKY, Louwman MWJ, Schrader AMR, Zuur CL, Blank CU, van Poelgeest MIE, Kapiteijn EHW. Trends in Incidence and Survival of 1496 Patients with Mucosal Melanoma in The Netherlands (1990-2019). *Cancers (Basel).* **2023**;15(5).
- Sinasac SE, Petrella TM, Rouzbahman M, Sade S, Ghazarian D, Vicus D. Melanoma of the Vulva and Vagina: Surgical Management and Outcomes Based on a Clinicopathologic Review of 68 Cases. *Journal of Obstetrics and Gynaecology Canada.* **2019**;41(6):762-71.
- Janco JMT, Markovic SN, Weaver AL, Cliby WA. Vulvar and vaginal melanoma: Case series and review of current management options including neoadjuvant chemotherapy. *Gynecologic Oncology.* **2013**;129(3):533-7.
- Lorenz A, Kozłowski M, Lenkiewicz S, Kwiatkowski S, Cymbaluk-Płoska A. Cutaneous Melanoma versus Vulvovaginal Melanoma-Risk Factors, Pathogenesis and Comparison of Immunotherapy Efficacy. *Cancers (Basel).* **2022**;14(20).
- Heppt MV, Roesch A, Weide B, Gutzmer R, Meier F, Loquai C, Kähler KC, Gesierich A, Meissner M, von Bubnoff D, et al. Prognostic factors and treatment outcomes in 444 patients with mucosal melanoma. *European Journal of Cancer.* **2017**;81:36-44.
- Rigo R, Doherty J, Koczka K, Kong S, Ding PQ, Cheng T, Cheung WY, Monzon JG. Real World Outcomes in Patients with Advanced Melanoma Treated in Alberta, Canada: A Time-Era Based Analysis. *Curr Oncol.* **2021**;28(5):3978-86.
- van Zeijl MCT, Boer FL, van Poelgeest MIE, van den Eertwegh AJM, Wouters M, de Wreede LC, Aarts MJB, van den Berkmoortel F, de Groot JWB, Hospers GAP, et al. Survival outcomes of patients with advanced mucosal melanoma diagnosed from 2013 to 2017 in the Netherlands - A nationwide population-based study. *Eur J Cancer.* **2020**;137:127-35.
- Larkin J, Chiarion-Sileni V, Gonzalez R, Grob J-J, Rutkowski P, Lao CD, Cowey CL, Schadendorf D, Wagstaff J, Dummer R, et al. Five-Year Survival with Combined Nivolumab and Ipilimumab in Advanced Melanoma. *New England Journal of Medicine.* **2019**;381(16):1535-46.
- Furney SJ, Turajlic S, Stamp G, Nohadani M, Carlisle A, Thomas JM, Hayes A, Strauss D, Gore M, van den Oord J, et al. Genome sequencing of mucosal melanomas reveals that they are driven by distinct mechanisms from cutaneous melanoma. *J Pathol.* **2013**;230(3):261-9.
- Newell F, Johansson PA, Wilmott JS, Nones K, Lakis V, Pritchard AL, Lo SN, Rawson RV, Kazakoff SH, Colebatch AJ, et al. Comparative

- Genomics Provides Etiologic and Biological Insight into Melanoma Subtypes. *Cancer Discov.* **2022**;12(12):2856-79.
20. Newell F, Kong Y, Wilmott JS, Johansson PA, Ferguson PM, Cui C, Li Z, Kazakoff SH, Burke H, Dodds TJ, et al. Whole-genome landscape of mucosal melanoma reveals diverse drivers and therapeutic targets. *Nat Commun.* **2019**;10(1):3163.
  21. Indini A, Roila F, Grossi F, Massi D, Mandalà M. Molecular Profiling and Novel Therapeutic Strategies for Mucosal Melanoma: A Comprehensive Review. *International Journal of Molecular Sciences.* **2022**;23(1):147.
  22. Steeb T, Wessely A, Petzold A, Kohl C, Erdmann M, Berking C, Heppt MV. c-Kit inhibitors for unresectable or metastatic mucosal, acral or chronically sun-damaged melanoma: a systematic review and one-arm meta-analysis. *European Journal of Cancer.* **2021**;157:348-57.
  23. Hodi FS, Corless CL, Giobbie-Hurder A, Fletcher JA, Zhu M, Marino-Enriquez A, Friedlander P, Gonzalez R, Weber JS, Gajewski TF, et al. Imatinib for Melanomas Harboring Mutationally Activated or Amplified KIT Arising on Mucosal, Acral, and Chronically Sun-Damaged Skin. *Journal of Clinical Oncology.* **2013**;31(26):3182-90.
  24. Fridman WH, Pages F, Sautes-Fridman C, Galon J. The immune contexture in human tumours: impact on clinical outcome. *Nature reviews Cancer.* **2012**;12(4):298-306.
  25. Erdag G, Schaefer JT, Smolkin ME, Deacon DH, Shea SM, Dengel LT, Patterson JW, Slingluff CL. Immunotype and Immunohistologic Characteristics of Tumor-Infiltrating Immune Cells Are Associated with Clinical Outcome in Metastatic Melanoma. **2012**;72(5):1070-80.
  26. Sun Q, Sun H, Wu N, Cong L, Cong X. Prognostic Significance of Tumor-Infiltrating Lymphocyte Grade in Melanoma: A Meta-Analysis. *Dermatology.* **2020**;236(6):481-92.
  27. Gartrell RD, Marks DK, Hart TD, Li G, Davari DR, Wu A, Blake Z, Lu Y, Askin KN, Monod A, et al. Quantitative Analysis of Immune Infiltrates in Primary Melanoma. *Cancer Immunol Res.* **2018**;6(4):481-93.
  28. Fu Q, Chen N, Ge C, Li R, Li Z, Zeng B, Li C, Wang Y, Xue Y, Song X, et al. Prognostic value of tumor-infiltrating lymphocytes in melanoma: a systematic review and meta-analysis. *Oncoimmunology.* **2019**;8(7):e1593806.
  29. Reissfelder C, Stamova S, Gossmann C, Braun M, Bonertz A, Walliczek U, Grimm M, Rahbari NN, Koch M, Saadati M, et al. Tumor-specific cytotoxic T lymphocyte activity determines colorectal cancer patient prognosis. *The Journal of Clinical Investigation.* **2015**;125(2):739-51.
  30. Nakamura Y, Zhenjie Z, Oya K, Tanaka R, Ishitsuka Y, Okiyama N, Watanabe R, Fujisawa Y. Poor Lymphocyte Infiltration to Primary Tumors in Acral Lentiginous Melanoma and Mucosal Melanoma Compared to Cutaneous Melanoma. *Front Oncol.* **2020**;10:524700.
  31. Dodds TJ, Wilmott JS, Jackett LA, Lo SN, Long GV, Thompson JF, Scolyer RA. Primary anorectal melanoma: clinical, immunohistology and DNA analysis of 43 cases. *Pathology.* **2019**;51(1):39-45.
  32. Yin G, Guo W, Liu H, Huang Z, Chen X. Characteristics of tumor infiltrating lymphocytes in sinonasal mucosal melanoma and prognosis for patients. *Curr Probl Cancer.* **2022**;46(4):100878.
  33. D'Angelo SP, Larkin J, Sosman JA, Lebbe C, Brady B, Neyns B, Schmidt H, Hassel JC, Hodi FS, Lorigan P, et al. Efficacy and Safety of Nivolumab Alone or in Combination With Ipilimumab in Patients With Mucosal Melanoma: A Pooled Analysis. *J Clin Oncol.* **2017**;35(2):226-35.
  34. Maibach F, Sadozai H, Seyed Jafari SM, Hunger RE, Schenk M. Tumor-Infiltrating Lymphocytes and Their Prognostic Value in Cutaneous Melanoma. *Front Immunol.* **2020**;11:2105.
  35. Rohaan MW, Borch TH, van den Berg JH, Met Ö, Kessels R, Geukes Foppen MH, Stoltenborg Granhøj J, Nuijen B, Nijenhuis C, Jedema I, et al. Tumor-Infiltrating Lymphocyte Therapy or Ipilimumab in Advanced Melanoma. *N Engl J Med.* **2022**;387(23):2113-25.
  36. Bloemendaal M, van Willigen WW, Bol KF, Boers-Sonderen MJ, Bonenkamp JJ, Werner JEM, Aarntzen EHJG, Koornstra RHT, de Groot JWB, de Vries IJM, et al. Early Recurrence in Completely Resected IIIB and IIIC Melanoma Warrants Restaging Prior to Adjuvant Therapy. *Annals of Surgical Oncology.* **2019**;26(12):3945-52.
  37. Liu J, Blake SJ, Yong MC, Harjunpää H, Ngiew SF, Takeda K, Young A, O'Donnell JS, Allen S, Smyth MJ, et al. Improved Efficacy of Neoadjuvant Compared to Adjuvant Immunotherapy to Eradicate Metastatic Disease. *Cancer Discov.* **2016**;6(12):1382-99.
  38. Mittendorf EA, Burgers F, Haanen J, Cascone T. Neoadjuvant Immunotherapy: Leveraging the Immune System to Treat Early-Stage Disease. *American Society of Clinical Oncology Educational Book.* **2022**(42):189-203.
  39. Versluis JM, Long GV, Blank CU. Learning from clinical trials of neoadjuvant checkpoint blockade. *Nature Medicine.* **2020**;26(4):475-84.
  40. Blank CU, Rozeman EA, Fanchi LF, Sikorska K, van de Wiel B, Kvistborg P, Krijgsman O, van den Braber M, Philips D, Broeks A, et al. Neoadjuvant versus adjuvant ipilimumab plus nivolumab in macroscopic stage III melanoma. *Nat Med.*

- 2018;24(11):1655-61.
41. Rozeman EA, Menzies AM, van Akkooi ACJ, Adhikari C, Bierman C, van de Wiel BA, Scolyer RA, Krijgsman O, Sikorska K, Eriksson H, et al. Identification of the optimal combination dosing schedule of neoadjuvant ipilimumab plus nivolumab in macroscopic stage III melanoma (OpACIN-neo): a multicentre, phase 2, randomised, controlled trial. *Lancet Oncol.* **2019**;20(7):948-60.
  42. Rozeman EA, Hoefsmit EP, Reijers ILM, Saw RPM, Versluis JM, Krijgsman O, Dimitriadis P, Sikorska K, van de Wiel BA, Eriksson H, et al. Survival and biomarker analyses from the OpACIN-neo and OpACIN neoadjuvant immunotherapy trials in stage III melanoma. *Nat Med.* **2021**;27(2):256-63.
  43. Patel SP, Othus M, Chen Y, Wright GP, Jr., Yost KJ, Hynstrom JR, Hu-Lieskovan S, Lao CD, Fecher LA, Truong TG, et al. Neoadjuvant-Adjuvant or Adjuvant-Only Pembrolizumab in Advanced Melanoma. *N Engl J Med.* **2023**;388(9):813-23.
  44. Cui C, Wang X, Lian B, Si L, Chi Z, Sheng X, Kong Y, Mao L, Bai X, Tang B, et al. A phase 2 clinical trial of neoadjuvant anti-PD-1 ab (Toripalimab) plus axitinib in resectable mucosal melanoma. *Journal of Clinical Oncology.* **2021**;39(15\_suppl):9512-.
  45. Ho J, Mattei J, Tetzlaff M, Williams MD, Davies MA, Diab A, Oliva ICG, McQuade J, Patel SP, Tawbi H, et al. Neoadjuvant checkpoint inhibitor immunotherapy for resectable mucosal melanoma. *Front Oncol.* **2022**;12:1001150.
  46. Ottaviano M, Giunta EF, Marandino L, Tortora M, Attademo L, Bosso D, Cardalesi C, Fabbrocini A, Rosanova M, Silvestri A, et al. Anorectal and Genital Mucosal Melanoma: Diagnostic Challenges, Current Knowledge and Therapeutic Opportunities of Rare Melanomas. *Biomedicines.* **2022**;10(1).
  47. Menzies AM, Amaria RN, Rozeman EA, Huang AC, Tetzlaff MT, van de Wiel BA, Lo S, Tahrini AA, Burton EM, Pennington TE, et al. Pathological response and survival with neoadjuvant therapy in melanoma: a pooled analysis from the International Neoadjuvant Melanoma Consortium (INMC). *Nat Med.* **2021**;27(2):301-9.
  48. Blankenstein SA, Rohaan MW, Klop WMC, van der Hiel B, van de Wiel BA, Lahaye MJ, Adriaansz S, Sikorska K, van Tinteren H, Sari A, et al. Neoadjuvant Cytoreductive Treatment With BRAF/MEK Inhibition of Prior Unresectable Regionally Advanced Melanoma to Allow Complete Surgical Resection, REDUCTOR: A Prospective, Single-arm, Open-label Phase II Trial. *Ann Surg.* **2021**;274(2):383-9.
  49. Reijers ILM, Menzies AM, van Akkooi ACJ, Versluis JM, van den Heuvel NMJ, Saw RPM, Pennington TE, Kapiteijn E, van der Veldt AAM, Suijkerbuijk KPM, et al. Personalized response-directed surgery and adjuvant therapy after neoadjuvant ipilimumab and nivolumab in high-risk stage III melanoma: the PRADO trial. *Nat Med.* **2022**;28(6):1178-88.
  50. Simonetti O, Lucarini G, Rubini C, Lazzarini R, R DIP, Offidani A. Clinical and prognostic significance of survivin, AKT and VEGF in primary mucosal oral melanoma. *Anticancer Res.* **2015**;35(4):2113-20.
  51. Gorski DH, Leal AD, Goydos JS. Differential expression of vascular endothelial growth factor-A isoforms at different stages of melanoma progression. *J Am Coll Surg.* **2003**;197(3):408-18.
  52. Sheng X, Yan X, Chi Z, Si L, Cui C, Tang B, Li S, Mao L, Lian B, Wang X, et al. Axitinib in Combination With Toripalimab, a Humanized Immunoglobulin G(4) Monoclonal Antibody Against Programmed Cell Death-1, in Patients With Metastatic Mucosal Melanoma: An Open-Label Phase IB Trial. *J Clin Oncol.* **2019**;37(32):2987-99.
  53. Li S, Wu X, Yan X, Zhou L, Chi Z, Si L, Cui C, Tang B, Mao L, Lian B, et al. Toripalimab plus axitinib in patients with metastatic mucosal melanoma: 3-year survival update and biomarker analysis. *J Immunother Cancer.* **2022**;10(2).
  54. Tang B, Mo J, Yan X, Duan R, Chi Z, Cui C, Si L, Kong Y, Mao L, Li S, et al. Real-world efficacy and safety of axitinib in combination with anti-programmed cell death-1 antibody for advanced mucosal melanoma. *Eur J Cancer.* **2021**;156:83-92.
  55. Yarza R, Bover M, Herrera-Juarez M, Rey-Cardenas M, Paz-Ares L, Lopez-Martin JA, Haanen J. Efficacy of T-Cell Receptor-Based Adoptive Cell Therapy in Cutaneous Melanoma: A Meta-Analysis. *Oncologist.* **2023**;28(6):e406-e15.
  56. Hwang MP, Fecek RJ, Qin T, Storkus WJ, Wang Y. Single injection of IL-12 coacervate as an effective therapy against B16-F10 melanoma in mice. *J Control Release.* **2020**;318:270-8.
  57. Cirella A, Luri-Rey C, Di Trani CA, Teixeira A, Olivera I, Bolaños E, Castañón E, Palencia B, Brocco D, Fernández-Sendin M, et al. Novel strategies exploiting interleukin-12 in cancer immunotherapy. *Pharmacology & Therapeutics.* **2022**;239:108189.
  58. Algazi A, Bhatia S, Agarwala S, Molina M, Lewis K, Faries M, Fong L, Levine LP, Franco M, Oglesby A, et al. Intratumoral delivery of tavokinogene telseplasmid yields systemic immune responses in metastatic melanoma patients. *Ann Oncol.* **2020**;31(4):532-40.
  59. Algazi AP, Twitty CG, Tsai KK, Le M, Pierce R, Browning E, Hermiz R, Canton DA, Bannavong D, Oglesby A, et al. Phase II Trial of IL-12 Plasmid Transfection and PD-1 Blockade in

Immunologically Quiescent Melanoma. *Clin Cancer Res.* **2020**;26(12):2827-37.