



**Universiteit
Leiden**
The Netherlands

Characteristics and clinical outcomes of mucosal melanoma

Boer, F.L.

Citation

Boer, F. L. (2024, March 19). *Characteristics and clinical outcomes of mucosal melanoma*. Retrieved from <https://hdl.handle.net/1887/3725231>

Version: Publisher's Version

License: [Licence agreement concerning inclusion of doctoral thesis in the Institutional Repository of the University of Leiden](#)

Downloaded from: <https://hdl.handle.net/1887/3725231>

Note: To cite this publication please use the final published version (if applicable).





PART II

Vulvar melanoma

Vulvar malignant melanoma: pathogenesis, clinical behaviour and management: review of the literature

Florine L. Boer, Mieke L.G. ten Eikelder, Ellen H. Kapiteijn,
Carien L. Creutzberg, Khadra Galaal, Mariëtte I.E. van Poelgeest

Cancer treatment reviews, **2019** Feb; 73:91-103



Abstract

Vulvar malignant melanoma (VMM) is a rare disease, accounting for 5% of all vulvar malignancies and is characterized by low survival and high recurrence rates. It is considered as a distinct entity of mucosal melanoma. Prognostic factors are higher age, advanced Breslow thickness, and lymph node involvement whilst central localization and ulceration status are still under debate. Surgery is the cornerstone for the treatment of primary VMM, however, it can be mutilating due to the anatomical location of the disease. Elective lymph node dissection is not part of standard care. The value of sentinel lymph node biopsy in VMM is still being studied. Radiation therapy and chemotherapy as adjuvant treatment do not benefit survival. Immunotherapy in cutaneous melanoma has shown promising results but clinical studies in VMM are scarce. In metastatic VMM, checkpoint inhibitors and in case of BRAF or KIT mutated metastatic VMM targeted therapy have shown clinical efficacy. In this review, we present an overview of clinical aspects, clinicopathological characteristics and its prognostic value and the latest view on (adjuvant) therapy and follow-up.

Introduction

Vulvar malignant melanoma (VMM) is a rare type of cancer responsible for 5% of all vulvar malignancies. [1-6] The incidence in the United States is 0.136 cases per 100,000, with 1059 vulvar melanomas in a 30-year period. [4] Most women with VMM are postmenopausal and diagnosis is usually delayed due to the location of the disease and lack of early symptoms. [7] Recurrence rate is high and distant metastases are commonly seen, even in apparent early stages of VMM. [8, 9] The five-year survival rates of VMM range from 10-63%. [10, 11] In addition to the high mortality rates there is a substantial decrease in the quality of life. This is due to bothersome symptoms, bleeding, foul odour, decreased sexual functionality and surgery related morbidities. [12]

Although Breslow thickness does have predictive value no consensus exists on the most accurate staging system for VMM. [13] Treatment modalities for VMM have mostly been extrapolated from cutaneous melanoma. Surgery is the cornerstone for the treatment of primary VMM. Wide local excision (WLE) is recommended while there is no clear indication for groin node dissection. [14] The value of sentinel node biopsy is still a matter of debate. [15] Radiation therapy and chemotherapy both have shown to be poorly effective in prolonging survival. [16] Therefore, there is need for new treatment strategies. Immunotherapy and in presence of KIT or BRAF mutations targeted therapy have shown promising results in cutaneous melanomas and may also be of advantage in the treatment of VMM. [17]

In this review, we present an overview of the current literature on vulvar malignant melanomas including clinicopathological characteristics, predictors of outcome, and current and future therapeutic options.

Data sources

Data on VMM has been collected through the search engines PubMed, and Web of Science (date of last search May 8th, 2018). A combination of Medial Subject Headings (MeSH), Major terms (MeSH heading that is of major importance in an article) and free text words was established. We used the search comprising the terms vulvar melanoma, genital melanomas, vulvovaginal melanomas, mucosal melanomas, BRAF, KIT and NRAS. Furthermore, we included several articles using reference lists of articles found via electronical search. The Dutch, American and British oncological guidelines of both vulvar cancer and cutaneous melanomas have been consulted. For clinicopathological characteristics and survival rates, all studies including more than ten vulvar melanomas and published after 1990 have been sorted in tables. In total 30 articles analysing VMM cases have been included. The final search strategy has been included as appendix (Appendix 1).

Clinical features

VMM is mostly seen in Caucasian women, the mean age at diagnosis is 61.6 years (range 10-86). [4, 18-29] Though VMM is a disease mostly confined to the middle aged women, children as young as ten years have been diagnosed with VMM. [5, 19, 29] The mean age at diagnosis is similar to that of other cutaneous melanomas (63 years) and mucosal melanomas of the head, neck, anus and rectum (respectively 61 and 68 years). [30-32] Aetiology does not seem to be similar to cutaneous melanoma since the most important risk factor UV-light exposure, cannot be collaborated with the vulvar area, which is barely exposed to light. Therefore, although VMM can anatomically be located either on mucosal or cutaneous surface, the general opinion is to categorize VMM as a distinct entity of mucosal melanoma. [33, 34]

Most common presenting symptoms are pain, bleeding, pruritus and a vulvar lesion or lump. [29] Occasionally, VMM are asymptomatic, in a study including 98 genital melanomas, 85 were identified by the patient whilst 13 melanomas were asymptomatic and diagnosed through clinical examination. [16, 23] Figure 1 shows a clinical presentation of a patient with a VMM.

A delay of presentation is common, mostly due to an absence of early symptoms and low body awareness. [33] Moreover, amelanotic VMM can be mistaken for a benign or premalignant disease. [7, 35] , In a large cohort of 123 vulvar melanomas, 30% of all vulvar melanomas were reported to be macroscopically amelanotic. Slightly more melanomas are located on the labia majora than the labia minora. [36] Only 26.7% (range 10-62.5%) of the VMM are multifocal at presentation. [3, 23, 26, 28, 29]

Diagnosis

At first visit, detailed medical history including presenting complaints and family history should be taken. Clinically, vulvar melanomas are assessed using the same ABCDE rule as in cutaneous melanomas. [37] These letters stand for Asymmetry, Border irregularity, Colour, Diameter and Evolving (in size, shape or colour) of which the latter one is the most important in melanomas. [38] Also a blue-black colour, a raised lesion, a mole >6mm and a ragged, notched or fuzzy border should raise suspicion. [38] Physical examination of the vulvar lesion and groins should be performed. Of special importance is the exact location of the lesion in relation to adjacent structures such as the urethra, anus and clitoris since surgery is the primary treatment. [14] The impact on social, sexual and psychological health should not be underestimated and is very much recommended to be part of counselling and assessment. [38-40]

Pigmented lesions should be differentiated from benign vulvar and vulvar melanosis, however this is difficult by clinical assessment. [41, 42] For a final diagnosis histological confirmation should be done through a full-thickness biopsy reaching up to subcutaneous tissue. [28] To prevent difficulty in confirming diagnosis excisional biopsy (excision of entire lesion) is recommended. In case of the possible harm of near structures with excisional biopsy, incisional biopsy should be considered. [43, 44] Biopsies should be reviewed by a pathologist, and immunohistochemical staining with HMB-45 and S-100 protein and Melan-A and MART-1 antibodies can be used to confirm diagnosis and differentiate from other vulvar conditions. [10, 42] Because of the rare entity of the disease, VMM biopsies are recommended to be assessed by either experienced pathology teams specialized in vulvar or gynaecologic pathology or teams specialized in melanomas.

Clinical work-up for VMM is identical to cutaneous melanomas in which Computed Tomography (CT), Positron Emission Tomography (PET) or CT/PET scans of head, abdomen, and pelvis is advised for clinically suspected stage IIIB, IIIC or stage IV disease. [43] Due to the metastasizing nature of VMM, some advocate imaging as part of standard work-up for all cases. CT, MRI or ultrasound of the groin and pelvis for locoregional spread and PET/CT for distant spread is recommended. [45]

VMM staging

For VMM, micro staging systems of Breslow, Clark and Chung, evaluating pathological characteristics of the primary melanoma, and macro staging systems (AJCC, FIGO), evaluating both primary melanomas and spread of disease, are used. [45] Table 1 summarizes studies that assessed the survival outcomes using the different staging systems in VMM. [3, 7, 13, 16, 18, 20–22, 24–27, 46–51] Based on these studies, Clark and Breslow staging were found more predictive for survival and recurrence than FIGO staging (1988) (Table 1). This can be explained by the fact that survival of VMM predominantly depends on tumour depth and in lesser extent on the diameter of the tumour, which is used in FIGO staging. Clark micro staging, which measures depth of invasion to papillary dermis, reticular dermis, and subcutaneous fat, was found to be predictive for both recurrence-free survival and overall survival. The two studies which did not support the predictive value of Clark staging for survival also could not do so for Breslow thickness. [13,16]

Half of all studies addressing AJCC as possible staging system for VMM found a correlation with either survival or recurrence-free survival (Appendix 2, Table 1). [13, 21, 47, 51] Two studies favoured AJCC above Breslow, Clark and FIGO (1988) staging in predicting recurrence-free survival. [21, 47] In conclusion, many staging systems are used without accurate predictive value for survival.

Whereas no staging system exists for VMM, mucosal melanomas of vaginal and anorectal origin by the Ballantyne's staging as either local, regional, or distant. For head and neck mucosal melanomas an adapted Union for International Cancer Control staging system (2017) has been designed (Appendix 3). [31, 52] This system however cannot be applied to VMM due to a different anatomical location.

Table 1. Prognostic value of staging systems

Study	Number of patients (location/ of which vulvar)	FIGO staging 5YS per stage	AJCC staging 5YS per stage	Breslow staging 5YS per stage	Clark staging 5YS per stage
<i>Braggate et al. [27]</i>	50 (vu)	FIGO 1971: I 58%, II 55%, III 0%, IV 0% - FIGO only predictive I/II vs III/IV		Breslow is not predictive for 5YS	
<i>Tasseron et al. [46]</i>	30 (vu)			Breslow is not predictive for OS	
<i>Trimble et al. [20]</i>	80 (vu)			Breslow is predictive for OS (p=0.006)	
<i>Phillips et al. [47]</i>	71 (vu)		AJCC 1992: AJCC is related to RFI (p<0.0001)	Breslow is related to risk of recurrence (p=0.0003)	Clark level related to risk of recurrence (p=0.0003)
<i>Scheistroen et al. [48]</i>	75 (vu)	FIGO 1988: I 63%, II 44%, III 0%, IV 0% - FIGO only predictive I/II vs III/IV		Breslow is only predictive for survival in cases >5mm	
<i>Raber et al. [24]</i>	89 (vu)			Breslow is predictive for 5YS (p=0.0007)	Level I-III 64.6% Level IV-V 9%. Clark is predictive for 5YS
<i>De Matos et al. [25]</i>	43 (ge/30 vu)	FIGO 1988: I 50%, I/II 60% II 50%, III 63% - FIGO not predictive for survival			Level I 77%, II 70%, III 50%, IV 48%, V 24%
<i>Creasman et al. [49]</i>	569 (vu)			Breslow is predictive for local recurrence (p=0.018)	
<i>Raspagliesi et al. [26]</i>	40 (vu)			Breslow is predictive for overall survival RR 1.25 (p=0.0001)	Level < III 91%, level ≥III 27%
<i>Verschraegen et al. [21]</i>	51 (vu)		AJCC 1992: I 91%, ≥ IIA 31% RR 2.85 of OS (p=0.0001) AJCC predictive for survival	Breslow is not predictive for OS, whilst being predictive for recurrence.	Clark is not predictive for survival
<i>Maxley et al. [13]</i>	77 (vu)		AJCC 2002: Not significant but a trend between higher AJCC stage and recurrence. Advanced AJCC stage correlates with survival significantly (p=0.006)		

Table 1. (Continued.)

Study	Number of patients (location/ of which vulvar)	FIGO staging 5YS per stage	AJCC staging 5YS per stage	Breslow staging 5YS per stage	Clark staging 5YS per stage
<i>Taheung et al. [50]</i>	85 (ge/43 vu)			Breslow is predictive for MSS (p<0.01)	
<i>Heinzelmann et al. [7]</i>	33 (vu)			Breslow is related to RFS: HR=1.08 (p=0.049)	
<i>Seifried et al. [51]*</i>	85 (ge/62 vu)		AJCC 2009: 5Y MSS stage 0-II 0%, stage III 63.6% AJCC only predictive for 0-II vs III (p<0.0012)	Breslow is predictive for 5YS HR 1.16 (p=0.007)	
<i>Ditto et al. [16]</i>	98 (vuva/67 vu)		AJCC 2009: AJCC staging not related to survival	Breslow is not predictive for OS	Clark is not predictive for survival
<i>Nagarajan et al. [3]</i>	100 (vu)		AJCC 2009: AJCC is only predictive in VMM > 2mm thick	Breslow is predictive for OS [MA] (p=0.03)	
<i>Iacoponi et al. [22]</i>	42 (vu)		AJCC 2002: AJCC staging not related to survival. AJCC staging is related to distant recurrence/metastasis		
<i>Utager et al. [18]</i>	59 (ge/48 vu + 6 vuva)			Breslow is predictive for MSS HR 1.043 (p=0.001)	

Only studies published after 1990 and that reported a minimum of 10 patients were included. vu: vulvar melanomas, ge: female genital melanomas, vuva: vulvovaginal melanomas, 5YS: 5-year overall survival

*These outcomes have not been subdivided for different types of melanomas included in this study.

Predictors of outcome

Clinical Characteristics

Age at diagnosis is found to be an independent prognostic factor of 5-year -, disease-free -, and overall survival in most studies. [3, 4, 6, 19, 20, 22, 27, 36, 48, 53]

Melanomas located centrally on the vulva have been correlated with reduced short-term and long-term survival and with shorter recurrence-free interval. [3, 28, 48, 54] An hypothesis is that in central lesions priority was given to avoid urethral injury which may have been at the expense of the surgical margin. [55] Hypotheses for worse prognosis in centrally located vulvar squamous cell carcinoma (VSCC), which could also apply to VMM, is the rich lymphovascular supply of the clitoris. [56] In a study combining vulvar and genito-urinary melanomas the centrally localized lesions (bilateral, clitoral, urethral, vaginal, perineal and anal) were associated with a higher risk of nodal involvement in the groin than lateral lesions ($p=0.003$). Furthermore, nodal involvement was an independent factor for recurrence and survival. [47]

Evidently, multifocal spread and involvement of the urethra, vagina, perineum, or anus of the vulvar melanomas leads to a worse prognosis. [48]

Histological characteristics

Lymph node (LN) status in VMM as a predictor of survival has extensively been studied. Positive LN status is prognostic for distant recurrence, yet, local recurrence is not predicted by the involvement of nodes. [26] Table 2 summarizes the studies evaluating LN status as possible prognostic factor in VMM. Seven studies stated the 5-year survival rate in LN positive patients with an average of 23.4% (range 0-68%) (table 2). [20, 24-26, 46, 48, 51] 10- year survival rates are 43.8% in the LN negative cases and 11.5% in the LN positive cases (table 2). [20, 24, 25, 48]

Also the extent of LN involvement is shown to be prognostic for survival. [6, 19, 26, 50] With multivariate analysis both LN status ($p < 0.002$) as extent of LN involvement ($p < 0.0003$) were significantly associated with survival. Survival rates for VMM with 0, 1 or more than 2 positive lymph nodes were respectively 65%, 20% and 0%. The four cases with more than two positive nodes passed away within two years of follow up. [26]

Breslow defined tumour thickness as the distance from the top of the epidermal granular layer to the deepest point of invasion. Table 3 summarizes studies on Breslow thickness and other pathological characteristics (ulceration, mitotic rate, and histological type) in relation to clinical outcome.

In VMM the majority of the studies support increasing Breslow thickness as negative predictor of survival (Table 3). [3, 21, 24, 25, 27, 48, 50, 51, 53] Most studies propose a minimum cut-off value for high-risk melanomas of 1.5 mm tumour thickness for the prediction of survival (Table 3). [21, 24, 25, 46, 54] Few studies failed to correlate tumour thickness as prognostic factor. [16, 20, 26] Higher tumour depth of VMM is also associated with higher rates of nodal involvement and with higher rates of recurrence. [3, 7, 13, 16, 20, 21, 46, 47, 51]

Ulceration is defined by the AJCC staging system as the absence of an intact epidermis overlying a major portion of the primary melanoma based on microscopic examination of histological sections. [57] In most studies ulceration is a prognostic factor for 5-year survival (Table 2). [3, 16, 24, 25, 27, 46, 48, 51] An association between ulceration with higher tumour thickness and mitotic rates may explain why ulceration has not been identified as independent predictor of survival. [27, 46]

Studies on the prognostic relevance of mitotic rate in VMM show varying results. Two recent studies showed that the mitotic rate was independently associated with disease-specific and disease-free survival (Table 3). [3, 16] A higher risk of dying due to progression of VMM was found in those with a mitotic rate of $> 2 \text{ mm}^2$ compared to those with a mitotic rate of $< 2 \text{ mm}^2$ (HR 3.36, $p = 0.03$, multivariate analysis (Table 3)). [16] Vulvar melanomas can be classified based on their growth pattern as superficial spreading melanoma (SSM), nodular malignant melanoma (NMM) and acral lentiginous melanoma (ALM). To distinguish the different variants the histopathological identification of the radial and vertical growth phase is the most important. The majority of the VMM's are classified as SSM (47%, range 33–56% (Table 3)). [16, 21, 26, 27] Efforts to correlate histological type with survival generally have been unsuccessful due to scarce and inconsistent results (Table 3). [27, 48, 16, 21, 26, 27, 48]

In summary, LN status and Breslow thickness are the strongest predictors for survival in VMM. LN status is also prognostic for recurrence whilst for Breslow thickness more evidence is needed. The cut-off value of tumour thickness and the predictive value of the extent of nodal disease still remains unclear. Ulceration should be considered as risk factor for survival but validation in larger studies is needed.

Table 2. Prognostic value of lymph node status

Study	Number of patients (location/ of which vulvar)	Survival according to LN status of the groin	Significance	# of positive lymph nodes predictive?
<i>Bradgate et al. [27]</i>	50 (vu)	5YS LN total 35% LN- 55% 10YS LN total 22% LN- 35%	Not significant	
<i>Tasseron et al. [46]</i>	30 (vu)	5YS LN total 57% LN + 33%	Not significant	
<i>Piura et al. [118]</i>	18 (vu)	LN positivity is not related to worse survival	Not significant	
<i>Trimble et al. [20]</i>	80 (vu)	5YS LN- 70% LN+27% 10YS LN- 43% LN+ 20%	p<0.001	
<i>Phillips et al. [47]</i>	71 (vu)	LN positivity is related to worse survival	p<0.006	
<i>Scheistroen et al. [48]</i>	75 (vu)	5YS LN- 56% LN+ 0% [MA] 10YS LN- 44% LN+ 0%	p<0.016	
<i>Raber et al. [24]</i>	89 (vu)	5YS LN- 57% LN+ 9.2% 10YS LN- 45% LN+ 11%	p=0.0007	
<i>De Matos et al. [25]</i>	43 (ge/30 vu)	5YS LN- 60% LN+ 68% 10YS LN- 43% LN+ 15%	Not significant	
<i>Raspagliesi et al. [26]</i>	40 (vu)	5YS LN- 65.2% LN+ 26.8% [MA]	p<0.002	Yes, 5YS 0 nodes 65.2%, 1-3 nodes 37.5%, >3 nodes, 0% (p<0.0003)
<i>Sugiyama et al. [19]</i>	644 (vu)	5YMSS LN- 68.3% LN+ 24.0%	p<0.01	Yes, 5YSMSS 0 nodes 68.3%, 1 node 29%, >1 node 19.5% (p<0.01)
<i>Baiocchi et al. [11]</i>	11 (vu)	LN positivity is related to worse survival	p=not stated	Yes, extent of nodal involvement is inversely related with survival (p<0.01)
<i>Tcheung et al. [50]*</i>	85 (ge/43 vu)			
<i>Tran Janco et al. [17]</i>	50 (vuva/36 vu)	LN positivity is related to worse survival	p=0.02	
<i>Mert et al. [6]*</i>	769 (vuva/597 vu)	LN positivity is related to worse survival	p=0.0043	Yes, extent of nodal involvement is inversely related with survival
<i>Heinzelmann et al. [7]*</i>	33 (vu)	LN positivity is not related to worse survival [MA]	Not significant	
<i>Seifried et al. [51]</i>	85 (ge/62 vu)	5YS LN - 63.6% LN+ 0%	p<0.001	

Table 2. (Continued.)

Study	Number of patients (location/ of which vulvar)	Survival according to LN status of the groin	Significance	# of positive lymph nodes predictive?
<i>Ditto et al. [16]</i>	98 (vulva/67 vu)	HR for 5YOS LN+ vs LN- 1.76 [MA]	p=0.02	
<i>Sanchez et al. [4]*</i>	1586 (genitourinary/1059 vu)	5YMSS LN- 63% LN+ 24% 10YMSS LN- 49% LN+ 17%	p<0.001	
<i>Udager et al. [18]*</i>	59 (ge/48 Vu+ 6 vuva)	MSS was lower for LN+ vs LN- group	p=0.008	

Only studies published after 1990 and that reported a minimum of 10 patients were included. vu: vulvar melanomas, ge: female genital melanomas, vuva: vulvovaginal melanomas, LN: lymph node, LN total: survival for all patients included in their review, LN+: survival for all patients with positive LN status, LN-: survival for all patients with negative LN status MA: multivariate analysis, MSS: melanoma specific survival, DFS: disease free survival, OS: overall survival *These outcomes have not been subdivided for different types of melanomas included in this study.

Table 3. Prognostic value of histological parameters

Study	Number of patients (location/of which vulvar)	Breslow thickness		Risk of recurrence/RFS	Ulceration status		Mitotic rate		Histological type
		Survival	Survival		5YS/DFS ulcerated/non-ulcerated	5YS/DFS/association with survival	5YS/DFS/association with survival	Association with survival	
Bradgate et al. [27]	50 (vu)	5YS 0-4 mm	59% (p<0.05)	5YDFS 0-3 mm 80% (p= 0.27) 5YDFS 4-6 mm 63% 5YDFS ≥ 6mm 30%	5YS 27%/62% (p<0.05)	5YS 0-4 HPF 57% (p<0.05)	histological type of tumour is not related to survival		
		5YS 4.1-8.0 mm	38%		5YS >4 HPF 24%				
		5YS >8.0mm	10%						
Tasseron et al. [46]	30 (vu)	Cum. S. 0-3 mm	100% (p=0.99)	5YDFS ≥ 6mm 30%	DFS 40%/70% [MA] (p=0.004)	mitotic rate is not related to survival			
		Cum. S. 3-6 mm	60%						
		Cum. S. > 6mm	22%						
Trimble et al. [20]	80 (vu)	5YS <0.75 mm	48% (p<0.001)	Breslow thickness related to DFS [MA] (p =0.0003)		mitotic rate is related to survival [UA] (p<0.001) mitotic rate not related to survival [MA] (p=ns)			
		5YS 0.75-1.5 mm	79%						
		5YS 1.51-3.0 mm	56%						
		5YS >3.0 mm	44%						
Phillips et al. [47]	71 (vu)								
Scheistroen et al. [48]	75 (vu)	5YS <0.75 mm	80.0% (p= ns)		5YS 40.5%/62.7% (p<0.118) ulceration is related to DFS (p=0.027)		histological type of tumour is not related to survival		
		5YS 0.75-1.5 mm	88.9%						
		5YS 1.51-3.0mm	54.5%						
		5YS 3.0-5.0 mm	54.5%						
		5YS >5.0 mm	27.4%						
Raber et al. [24]	89 (vu)	Median survival ≤ 1.5 mm 112 months (p=0.0007) > 1.5 mm 25 months			5YS 14.3%/20.4% (p=0.082)				
De Matos et al. [25]	43 (ge/30 vu)	6YS ≤ 1.5 mm 100% (p= ns) 6YS > 1.5 mm 29%			5YS 75%/57% (p= ns)				
Ragnarsson et al. [53]	219 (vu)	thickness related to survival [MA] (p=0.009)			all stages: HR 2.17 for MSS [MA] (p=0.069) ulceration predictive only for clinical stage I VMM (p<0.001)				

Table 3. (Continued.)

Study	Number of patients (location/of which vulvar)	Breslow thickness		Breslow thickness		Ulceration status		Mitotic rate		Histological type	
		Survival	Risk of recurrence/RFS	5YS/DFS ulcerated/non-ulcerated	5YS/DFS ulcerated/non-ulcerated	5YS/DFS association with survival	Association with survival				
<i>Raspagliesi et al. [26]</i>	40 (vu)	thickness significant related to survival [UA] (p=ns) thickness not significant related to survival [MA] (p=0.07)		ulceration is not related to survival [MA] (p=0.1)		histological type of tumour is not related to survival					
<i>Veirschraegen et al. [21]</i>	51 (vu)	RR 1.25 for OS [UA] (p= 0.0001) 5YS ≤0.75mm 75% 5YS 0.75-1.5mm 57% 5YS >1.5 mm 11%	RR 1.19 for DFS [UA] (p=0.0004)		RR for OS = 13.71 SSM vs NMM (p=0.0006)						
<i>Tcheung et al. [50]*</i>	85 (ge/43 vu)	5YS <1.0 mm 60% (p<0.01) 5YS 1.1-2.0 mm 50% 5YS 2.1-4.0 mm 30% 5YS >4.0mm 10%		ulceration is not related to survival	mitotic rate is not related to survival						
<i>Heinzelmann et al. [7]</i>	33 (vu)		HR 1.08 for DFS [MA] (p=0.049)								
<i>Seiffried et al.* [51]</i>	85 (ge/62 vu)	HR for MSS=1.16 [UA] (p=0.007)	HR 1.19 for DFS [UA] (p=0.0011)	5YS 51.6%/ 81% (p=0.049)	HR 1.04 for MSS [UA] (p=0.013)						
<i>Ditto et al. [16]</i>	98 (vuva/67 vu)	thickness not related to 5YS (p=0.75) [UA]		ulceration is not related to survival [UA] (p= 0.28)	HR 1.24 for DFS [MA] (p<0.001)						
<i>Udager et al. [18] *</i>	59 (ge /48 vu+ 6 vuva)	HR 1.04 per mm for MSS [UA] (p=0.0001) Thickness related to OS [MA] (p=0.03)		ulceration related to OS [UA] (p=0.01) ulceration related to MSS [UA] (p<0.01) not significant for MSS and OS [MA]	mitotic rate of <2mm2 vs ≥2mm2 HR 3.36 for OS [MA] p<0.03 HR of 4.44 for DFS[MA] (p<0.001)						
<i>Nagarajan et al. [3]</i>	100 (vu)										

Treatment

Surgical treatment

For many years radical vulvectomy defined as “the removal of the entire vulva until the deep fascia of the thigh, the periosteum of the pubis and the inferior fascia of the urogenital diaphragm” was the standard treatment for VSCC and was adopted for VMM. [5,58] Extensive surgery however is associated with serious and long term morbidity, sexual dysfunction, and psychological burden. [59] Therefore, wide local excision (WLE), defined as the excision of the malignancy with wide tumour free surgical margins, has been proposed as alternative. WLE has shown similar survival rates compared to radical vulvectomy. [13, 19, 20, 23, 25] Studies addressing recurrence rates of those either treated with radical vulvectomy or WLE are ambivalent in their results. [22, 25] Since survival is not better in cases treated with radical vulvectomy; WLE is the preferred primary surgical treatment. [2, 16] Knowledge about the optimal surgical margins of the WLE for VMM is lacking. Though in head and neck melanomas some studies found clear margins to be related with better survival there is also conflicting data not finding a significant difference in survival for patients with either tumour negative or positive margins. [60–62] In the National Comprehensive Cancer Network guidelines for cutaneous melanoma smaller surgical resection margins (0.5 cm for in situ melanomas, 1 cm for lesions up to 2 mm thick and 2 cm margins for melanomas more than 2 mm thick) have been proposed finding no survival benefit favouring wider margins. [43] Irvin et al proposed identical margins for VMM and neither found margins wider than 2 cm to improve survival. [28]

Inguinal lymph node treatment

In VMM, only one prospective trial of 71 cases compared ELND with LN treatment when clinically manifested nodal disease, concluding no survival benefit for those treated with ELND. [47] In two retrospective studies consisting of 17 and 18 VMM's electively treated with lymph node dissection only 12% and 33% had nodal involvement, respectively. [15, 25]

Sentinel lymph node biopsy (SLNB) can help to obtain information on regional involvement whilst sparing ELND. Since in VMM positive pelvic nodes are rarely encountered in case of negative inguinal nodes, sentinel lymph node (SLN) status is thought to predict the status of the further nodes. [20, 25, 54, 63] However, evidence on this subject is scarce. Of the 59 documented VMM cases treated with a sentinel node procedure, 98% successfully identified the sentinel node. [11, 22, 29, 63–68]

De Hullu et al, found 2 out of 9 cases treated with a sentinel node procedure to recur in the groin whilst 0 of the 24 cases treated with ELND recurred ($p = 0.006$). The authors hypothesize that the SLN procedure and maybe the tumour thickness in these cases (both more than 4 mm thick) could explain these recurrences. [15] In no other studies SLNB

procedure has been related to a higher recurrence rate although in another cohort of 11 cases, two of the three (< 12 month) recurrences occurred in those treated with SLN [11]. In cutaneous melanomas of less than 1 mm thick SLNB is not indicated due to the rare occurrence of regional metastasis in these cases. De Hullu has extrapolated this to VMM and advised SLNB in VMM only to be considered in melanomas between the 1 and 4 mm. [15] This is derived from their own experience as also from the NCCN and EMSO guidelines for cutaneous melanoma. [43,69] In SLN positive cutaneous melanoma LN dissection does not affect overall survival but does improve disease-free survival and therefore should be discussed with the patient. [70, 71] For VMM conclusions on this subject are lacking.

Non-surgical treatment

Currently, non-surgical treatments aimed at prolonging disease-free or overall survival are not routinely used in VMM. Whilst checkpoint inhibitors and targeted therapies in BRAF and KIT mutated metastatic cutaneous melanomas have shown clinical benefit, data in mucosal melanomas is limited. Clinical studies of therapeutic vaccination or adoptive cell transfer in mucosal or vulvar melanomas have not been performed.

Radiotherapy

In general, radiotherapy (RT) in cutaneous and mucosal melanomas of any location has a limited response. [72] Adjuvant local RT for mucosal head and neck melanomas which have a high risk of recurrence and adjuvant RT for VMM have shown to improve local control without benefiting overall survival. [16, 22, 73, 74] Difficulty in appropriate resection margins is common in both head and neck and vulvar melanomas. Hence, in case of tumour positive or narrow margins, adjuvant RT may be justified. [75]

Neoadjuvant RT has been proposed in surgically irresectable head and neck melanomas. [76] The use of neoadjuvant radiotherapy alone in VMM has not yet been described. The anti-CTLA4 antibody ipilimumab with concomitant RT has been described in four female lower genital tract melanomas after which three underwent surgical treatment. Impressive results were obtained with 1 stable disease, 2 partial remissions and 1 complete remission. The combination of RT and immunotherapy as neoadjuvant treatment should only be given in trial setting. [77]

RT of the groin following LND has not been studied in VMM. In cutaneous melanomas, lacking effect on overall survival together with complication rates of 50% have withheld RT to become part of standard treatment. [73, 78] Regional RT can be considered in case of lymph node involvement when LND is contraindicated. [79] RT in these cases could be used to prevent locoregional recurrences or progression of disease with local complications [79,80]. Radiotherapy of the groin in VMM has not been investigated in the elective setting, but is sometimes used in case of macroscopic, unresectable disease.

Chemotherapy

Adjuvant chemotherapy does not show a survival benefit in VMM. [17, 22, 50] In mucosal melanomas one randomized trial compared high-dose IFN (HDI) with temozolomide + cisplatin in an adjuvant setting and concluded chemotherapy to be more effective in prolonging recurrence-free survival and overall survival than HDI. [81]

Neoadjuvant use of (bio) chemotherapy aiming at reduction of tumour bulk has been reported in one vulvar and two vaginal cases. In the vulvar case carboplatin and paclitaxel in combination with the anti-angiogenetic agent bevacizumab led to considerable reduction of the 5 cm large melanoma, making resection possible whilst omitting skin graft [17].

In advanced VMM the only study addressing adjuvant (bio)chemotherapy is a case series of 11 vulvar and vaginal melanomas. They used combinations of cisplatin, vinblastine, dacarbazine, temozolomide, tamoxifen, IL-2, and IFN- α as therapy for advanced vulvovaginal melanomas. Of all cases the median survival was 10 months and 36% had a partial response, which is similar to the normally less aggressive cutaneous melanoma. [82] They propose chemotherapy to be promising in advanced disease whilst keeping the many side effects in mind.

Immunotherapy and targeted therapy

Immunotherapy and targeted therapy have shown promising results in the treatment of cutaneous melanomas. Immunotherapy is divided in non-specific stimulation of the entire immune system with cytokines and in specific stimulation using either vaccines, adoptive cell therapy or checkpoint inhibitors. Targeted therapy in melanoma focuses on targeting melanoma cells with specific gene changes on the BRAF, KIT or NRAS gene.

Cytokines

High-dose IFN has been reported to prolong overall survival and disease-free survival in radically resected stage I-II cutaneous melanomas on expense of many serious side-effects. [83]

Interferon- α -2b (IFN α -2b) or interleukin-2 (IL-2) have been administered as adjuvant treatment in mucosal melanomas including a couple of VMM cases, not finding a survival benefit for those treated with either of both. [25, 32, 50, 84] Conclusions are hard to draw since the type of immunotherapy and the stage of cases in the treatment groups are either not specified or stated.

IFN- α or IL-2 in advanced VMM have not been studied. As IFN- α and IL-2 as adjuvant treatment in metastatic cutaneous melanomas are not as effective as immune- and targeted therapies, they have been replaced by the emerging checkpoint inhibitors and targeted agents. [85, 86]

Checkpoint inhibitors

In cutaneous melanomas, blocking programmed cell death protein 1 (PD-1) expression with nivolumab or pembrolizumab and blocking cytotoxic T-lymphocyte-associated protein 4 (CTLA-4) expression with ipilimumab has been FDA approved in unresected high-risk stage III and stage IV melanomas. Nivolumab and pembrolizumab are favoured over ipilimumab due to better recurrence-free survival rates and less treatment related toxicity. [87, 88] This is based on a randomized double-blind phase III trial of which 3.2% of the cohort were mucosal melanoma's. [89, 90] One study exclusively analysed vulvar and vaginal melanomas and found 50% of those treated with nivolumab to respond partially and 50% of those to have progression of disease. [91] Ipilimumab had worse results with 66% of the treated cases to have progression of disease, 16% to have stable disease and 16% to respond with regression of disease. Median progression-free survival and overall survival in VMM, respectively 3.0 months and 2.7 months was lower than that in cutaneous melanomas, respectively 11.7 months and 5.8 months. [92]

Targeted therapy

KIT, NRAS and BRAF mutations in oncogenic pathways are identified as inhibitable targets in cutaneous melanomas. In VMM still little is known, for which this subject is of great interest. [93]

In VMM only 3.9% harbours a mutation in the BRAF gene [18,94–106]. KIT mutations are found in 31.4% (range 18.2–40%) of the VMM's and most often are located at exon 11. [7, 18, 97–109] In as study combining 8 reports 9.8% (range 0–27.6%) of the VMM's were mutated in the NRAS gene. [18, 96–104, 106, 110] Table 4 summarizes all studies with analysing mutational status of the KIT, BRAF or NRAS gene. [7, 18, 94–110]

Three large melanoma case series including mucosal melanomas have been published showing response rates of 30%, 50% and 73,8% to KIT inhibition. [111–113] A cohort of 22 oral metastatic mucosal melanomas either treated with chemotherapy or imatinib showed better overall survival for the last mentioned. [114] KIT inhibition in VMM has not been studied. Up to today, no studies report on targeted therapy in NRAS or BRAF positive VMM's.

Table 4. Mutational status of VMM

Study	Number melanomas (location/ of which vulvar)	% BRAF mutation	% NRAS mutation	% KIT mutation
<i>Jiveskog et al. [110] *</i>	28 (non-exposed vs exposed to sun)		11% (3/28) exon 2 codon 61 (2) exon 1 codon 12	
<i>Edwards et al. [94] *</i>	13 (mucosal/8 vu)	0% (0/13)		271% (3/11) exon 11 L576P, exon 13 K642E(2), exon 17 N8221
<i>Cohen et al. [95]</i>	8 (vu)	0% (0/8)		35% (8/23) exon 11 W557R, exon 11 V559D, exon 11 V560D, exon 11 P573L, exon 11 L576P (2) exon 17, D820Y
<i>Wong et al. [96]</i>	7 (vuva/ 3 vu)	33.3% (1/3) exon15, N581I	0% (0/3)	
<i>Torres Cabala et al. [107]</i>	61 (mucosal/11 vu)			
<i>Omholt et al. [97]</i>	71(mucosal/23 vu)	8.6% (2/23) exon 15 V600E (2)	0% (0/23)	
<i>Canvajal et al. [98]</i>	13 (vuva)	0% (0/13)	8% (1/13) exon 2 Q61L, exon 1 G12D, exon 1 G13V	46% (6/13) exon 11 L576P (5), exon 11 Y553C, exon 18 V852I, exon 13 K642E
<i>Schoenewolf et al. [108] *</i>	16 (vuva)			45% (5/11) exon unknown
<i>Abu-Abed et al. [109]) *</i>	17 (vuva)			5.3% (1/19) exon 11 L576P
<i>Van Engen van Grunsven et al. [99]</i>	14 (vuva/1 vu)	0% (0/1)		0% (0/1)
<i>Tseng et al. [100]</i>	24 (vuva/11 vu)	0% (0/11)	27% (3/11) exon1, G13D, exon2, Q61K exon2, A59T	18% (2/11) exon 11 L576P17, exon 11 W557R and L576P
<i>Aulmann et al. [102] *</i>	65 (vuva/50 vu)	0% (0/39)	12% (5/42) G12A+ (2), G13D (2), G12V	18% (7/39) exon 11 W557R, exon 11 V559D, exon 11 V560D, Exon 11 R586I, exon 11 insertion Y578-H580dup (2), exon 17 D820V
<i>Heinzelmann et al. [7]</i>	50 (vuva/33 vu)			44% (12/27) exon unknown
<i>Rouzbahaman et al. [102]</i>	44 (vuva/13 vu)	7.6% (1/13) exon unknown	27.6% (3/13) exon unknown	27.6% (3/13) exon unknown

Table 4. (Continued.)

Study	Number melanomas (location/ of which vulvar)	% BRAF mutation	% NRAS mutation	% KIT mutation
Hou et al. [103] *	51 (vuva/37 vu)	27.3% (9/33) exon15 V600E (4), exon 15 T599V600E deletion	0% (0/19)	26.5% (9/34) exon 11 L576P (4), L576R(1), A736V, N822K, V654A, D816V
Dias-Santagata et al. [104]	95 (vu)	25%(10/40) exon 15 V600E(7), G469R, L597Q, A581S	9% (3/35) Q61R(2), G12V	44% (15/34) exon 11 L576P (8), D816V(2), A829P, Y646D(2), V560D
Cinotti et al. [105]	43 (mucosal/15 vu)	0% (0/15)		0% (0/15)
Udager et al. [18] *	59 (ge/48 vu+ 6 vuva)	0 % (0/59)	3.7% (1/59) exon 2	22% (6/59) exon 11 (3), exon 13, exon 18
Wylomanski et al. [106]	22 (vuva/15 vu)	33.3% (5/15) exon 15 V600E (5)	0/0% (0/15)	6.7% (1/15) exon 11 L576P

Vu: Vulvar melanomas, ge: genital melanomas, vuva: vulvovaginal melanomas *These outcomes have not been subdivided for different types of melanomas included in this study

Prognosis

Patients with VMM have a poor prognosis, reported 5-year survival rates range between 10 and 63%. [7, 48] Late stage at diagnosis and high recurrence rates contribute to low survival rates. [2, 7, 11, 13, 16] Pleunis et al compared a cohort of VMM with a cohort of cutaneous melanomas and found a 5-year survival in the VMM group of 35% compared to 85% in the cutaneous melanoma group. Yet, when matched to the VMM cases for age at diagnosis, Breslow thickness, nodal status, presence of distant metastases, tumour ulceration and time of diagnosis, 5-year survival difference between cutaneous melanoma and VMM was only 15% ($p < 0.002$). [115] This reflects that poor prognosis in VMM is partly explained by biological aggressiveness but also unfavourable characteristics at presentation may contribute to the poor prognosis. The 5-year survival rates have been investigated by stage. As there is no consensus on the appropriate staging system, data remains heterogeneous.

VMM recurrence rates vary between 42 and 70%. [21, 22, 28, 54] In a cohort of 51 VMM, 32 recurred of which most recur locoregional (53%), less recur at distant site (28%) or at both distant and locoregional sites (19%). [21] The average time to recurrence is only 1 year (range 1 month to 14 years). [28, 54, 116] This outcome could be biased due to short follow-up. This is questioned by a recent cohort which found a mean time to local recurrence of 5 years and 3 months which suggests that a substantial number of recurrences occur late (> 5 years). [22] Late recurrences may explain the difference between 5-year survival rates and 10-year survival rates for which 10-year survival rates may be more valuable than 5-year survival rate. [3, 22, 50]

Follow-up

Follow-up of any type of cancer, including melanomas, has the primary aim of detecting locoregional or distant recurrences in an early stage to improve the long-term survival. [117] Thus far, there are no guidelines on VMM follow up, and schedules are based on the clinical experience and custom practice rather than on evidence. To date, evaluation of these current follow-up regimes has not been undertaken. [14] For vulvar cancer the most often used follow-up scheme consists of appointments 6–8 weeks postoperative, every 3–4 months in the first two years post-diagnosis and twice a year in the 3rd and 4th year. [14] This has been adopted for vulvar melanoma. [14, 44] However, since recurrence rates are higher and late recurrences (> 5 years) are common a long-term follow-up plan is needed. [28, 30] The value of PET-CT in the follow-up of cutaneous melanoma is still unclear.

The first post-operative appointment aims to inspect the wounds and evaluate the occurrence of complications of surgical or adjuvant therapy. The leading thought is that lab

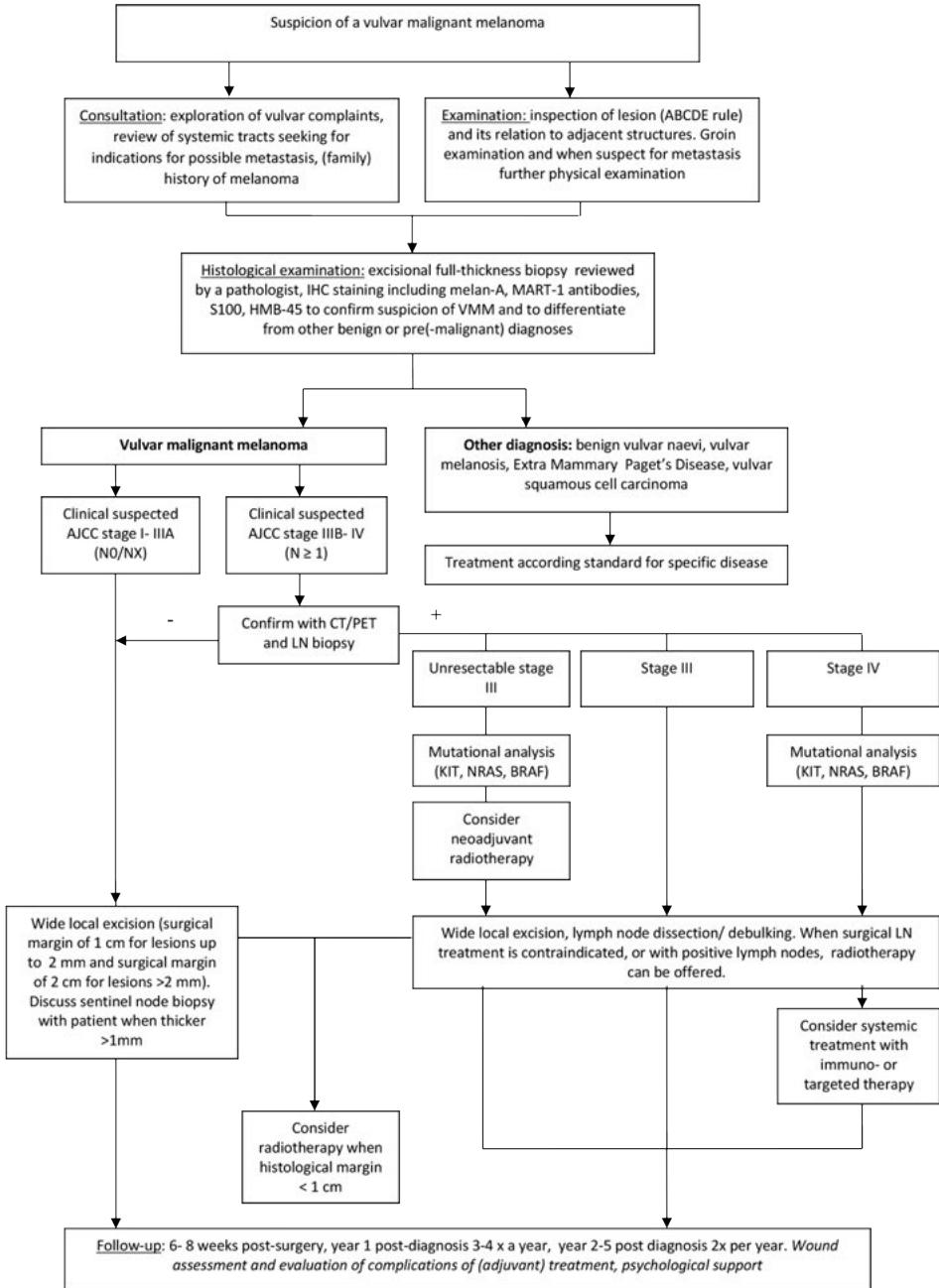
and imaging should only be done on indication when suspicion is raised for a recurrence or unidentified metastasis. Furthermore, during follow-up appointments there should be special attention for any need of psychological support as a substantial decrease in quality of life due to emotional, physical, and social functioning, sexuality, and body image in patients with any type of vulvar cancer. [39, 40]

Recommendations

- Higher age, Breslow thickness and lymph node involvement all are clear predictors of survival in VMM whilst for central localization and ulceration status this is less clear.
- For diagnosis of VMM histological evaluation through an excisional, and in case of possible damage to surrounding structures, incisional biopsy is recommended.
- We recommend imaging only in case of clinically suspected nodal involvement (AJCC stage III) with PET/CT of at least the chest, abdomen, and pelvic and inguinal regions. In case of a planned large surgery imaging can be considered since in case of distant metastasis, mutilating surgery should be reconsidered.
- When systemic treatment for stage IV disease or unresectable stage III disease is considered, mutational analysis of the KIT, BRAF and NRAS gene should be done.
- For locally confined disease treatment should consist of WLE with a surgical margin of 1 cm for lesions up to 2 mm thick and 2 cm for lesions of more than 2 mm thick.
- Neoadjuvant radiotherapy can be considered to reduce tumour bulk in case of large tumours or in case of proximity to vital structures like urethra of anus.
- For chemotherapy or immunotherapy as adjuvant or palliative treatment evidence is very scarce and treatment should only be considered in study setting and after thorough deliberation with patient and doctor.
- A sentinel lymph node biopsy can be discussed with the patient in case of a melanoma thicker than 1 mm. This should be performed by a specialized team using SLNB routinely for VSCC. In case of a negative sentinel node no further treatment is needed. The value of a lymph node dissection in case of a positive sentinel node in VMM is not known.
- In advanced melanoma with regional involvement, surgical treatment is identical to the treatment in early stage disease. Elective lymph node dissection in case of palpable nodal involvement has not shown a survival benefit but may, similar to cutaneous melanoma, prolong (distant) disease-free and melanoma-specific survival and for that reason can be managed. The advantages and disadvantages of lymph node dissection and adjuvant treatment should be weighed carefully in every individual case by both patient and doctor.
- Postoperative radiotherapy for better local control can be considered in case of histologically close of positive margins, or after lymph node dissection of positive nodes

- In recurrent or metastatic VMM treatment needs to be individualized. Local recurrences can be surgically removed in an attempt to prolong disease-free survival or local complaints. Systemic therapy can be considered to reduce complaints due to nodal or distant metastasis and to prolong survival. The checkpoint inhibitors nivolumab and pembrolizumab have shown positive results in studies including cutaneous melanomas and a small subset of mucosal melanomas. Moreover, targeted therapy, specifically imatinib in KIT-positive and BRAF-inhibitors in BRAF-positive mucosal melanomas, have shown improvement in survival. Adjuvant treatment in metastatic VMM should be considered in study design. Future studies should be aimed at molecular profiling for identification of novel treatment strategies and further development of immunotherapies in VMM.
- A proposed flowchart for the management of VMM is given in Fig. 2.

Figure 2. Flowchart management of vulvar malignant melanoma



References

1. Sugiyama VE, Chan JK, Kapp DS. Management of melanomas of the female genital tract. *Current opinion in oncology*. 2008;20(5):565-9.
2. Piura B. Management of primary melanoma of the female urogenital tract. *The Lancet Oncology*. 2008;9(10):973-81.
3. Nagarajan P, Curry JL, Ning J, Piao J, Torres-Cabala CA, Aung PP, et al. Tumor Thickness and Mitotic Rate Robustly Predict Melanoma-Specific Survival in Patients with Primary Vulvar Melanoma: A Retrospective Review of 100 Cases. *Clinical cancer research : an official journal of the American Association for Cancer Research*. 2017;23(8):2093-104.
4. Sanchez A, Rodriguez D, Allard CB, Bechis SK, Sullivan RJ, Boeke CE, et al. Primary genitourinary melanoma: Epidemiology and disease-specific survival in a large population-based cohort. *Urologic oncology*. 2016;34(4):166.e7-14.
5. Irvin WP, Jr., Bliss SA, Rice LW, Taylor PT, Jr., Andersen WA. Malignant melanoma of the vagina and locoregional control: radical surgery revisited. *Gynecologic oncology*. 1998;71(3):476-80.
6. Mert I, Semaan A, Winer I, Morris RT, Ali-Fehmi R. Vulvar/vaginal melanoma: an updated surveillance epidemiology and end results database review, comparison with cutaneous melanoma and significance of racial disparities. *International journal of gynecological cancer : official journal of the International Gynecological Cancer Society*. 2013;23(6):1118-25.
7. Heinzelmann-Schwarz VA, Nixdorf S, Valadan M, Diczbalis M, Olivier J, Otton G, et al. A clinicopathological review of 33 patients with vulvar melanoma identifies c-KIT as a prognostic marker. *International journal of molecular medicine*. 2014;33(4):784-94.
8. Chen L, Xiong Y, Wang H, Liang L, Shang H, Yan X. Malignant melanoma of the vagina: A case report and review of the literature. *Oncology letters*. 2014;8(4):1585-8.
9. Chokoeva AA, Tchernev G, Castelli E, Orlando E, Verma SB, Grebe M, et al. Vulvar cancer: a review for dermatologists. *Wiener medizinische Wochenschrift (1946)*. 2015;165(7-8):164-77.
10. Nobbenhuis MA, Lalondrelle S, Larkin J, Banerjee S. Management of melanomas of the gynaecological tract. *Current opinion in oncology*. 2014;26(5):508-13.
11. Baiocchi G, Duprat JP, Neves RI, Fukazawa EM, Landman G, Guimaraes GC, et al. Vulvar melanoma: report on eleven cases and review of the literature. *Sao Paulo medical journal = Revista paulista de medicina*. 2010;128(1):38-41.
12. Akhtar-Danesh N, Elit L, Lytwyn A. Trends in incidence and survival of women with invasive vulvar cancer in the United States and Canada: a population-based study. *Gynecologic oncology*. 2014;134(2):314-8.
13. Moxley KM, Fader AN, Rose PG, Case AS, Mutch DG, Berry E, et al. Malignant melanoma of the vulva: an extension of cutaneous melanoma? *Gynecologic oncology*. 2011;122(3):612-7.
14. BGCS. Vulval Carcinoma, Guidelines for the Diagnosis and Management of. 2014.
15. de Hullu JA, Hollema H, Hoekstra HJ, Piers DA, Mourits MJ, Aalders JG, et al. Vulvar melanoma: is there a role for sentinel lymph node biopsy? *Cancer*. 2002;94(2):486-91.
16. Ditto A, Bogani G, Martinelli F, Di Donato V, Lauffer J, Scasso S, et al. Surgical Management and Prognostic Factors of Vulvovaginal Melanoma. *Journal of lower genital tract disease*. 2016.
17. Janco JM, Markovic SN, Weaver AL, Cliby WA. Vulvar and vaginal melanoma: case series and review of current management options including neoadjuvant chemotherapy. *Gynecologic oncology*. 2013;129(3):533-7.
18. Udager AM, Frisch NK, Hong LJ, Stasenko M, Johnston CM, Liu JR, et al. Gynecologic melanomas: A clinicopathologic and molecular analysis. *Gynecologic oncology*. 2017;147(2):351-7.
19. Sugiyama VE, Chan JK, Shin JY, Berek JS, Osann K, Kapp DS. Vulvar melanoma: a multivariable analysis of 644 patients. *Obstetrics and gynecology*. 2007;110(2 Pt 1):296-301.
20. Trimble EL, Lewis JL, Jr., Williams LL, Curtin JP, Chapman D, Woodruff JM, et al. Management of vulvar melanoma. *Gynecologic oncology*. 1992;45(3):254-8.
21. Verschraegen CF, Benjapibal M, Supakarapongkul W, Levy LB, Ross M, Atkinson EN, et al. Vulvar melanoma at the M. D. Anderson Cancer Center: 25 years later. *International journal of gynecological cancer : official journal of the International Gynecological Cancer Society*. 2001;11(5):359-64.
22. Iacoponi S, Rubio P, Garcia E, Oehler MK, Diez J, Diaz-De la Noval B, et al. Prognostic Factors of Recurrence and Survival in Vulvar Melanoma: Subgroup Analysis of the VULvar CANcer Study. *International journal of gynecological cancer : official journal of the International Gynecological Cancer Society*. 2016;26(7):1307-12.
23. De Simone P, Silipo V, Buccini P, Mariani G, Marena S, Eibenschutz L, et al. Vulvar melanoma:

- a report of 10 cases and review of the literature. *Melanoma research*. 2008;18(2):127-33.
24. Raber G, Mempel V, Jackisch C, Hundeiker M, Heinecke A, Kurzl R, et al. Malignant melanoma of the vulva. Report of 89 patients. *Cancer*. 1996;78(11):2353-8.
 25. DeMatos P, Tyler D, Seigler HF. Mucosal melanoma of the female genitalia: a clinicopathologic study of fortythree cases at Duke University Medical Center. *Surgery*. 1998;124(1):38-48.
 26. Raspagliesi F, Ditto A, Paladini D, Fontanelli R, Stefanon B, Dipalma S, et al. Prognostic indicators in melanoma of the vulva. *Annals of surgical oncology*. 2000;7(10):738-42.
 27. Bradgate MG, Rollason TP, McConkey CC, Powell J. Malignant melanoma of the vulva: a clinicopathological study of 50 women. *British journal of obstetrics and gynaecology*. 1990;97(2):124-33.
 28. Irvin WP, Jr., Legallo RL, Stoler MH, Rice LW, Taylor PT, Jr., Andersen WA. Vulvar melanoma: a 2 retrospective analysis and literature review. *Gynecologic oncology*. 2001;83(3):457-65.
 29. Wechter ME, Gruber SB, Haefner HK, Lowe L, Schwartz JL, Reynolds KR, et al. Vulvar melanoma: a report of 20 cases and review of the literature. *Journal of the American Academy of Dermatology*. 2004;50(4):554-62.
 30. Mehra T, Grozinger G, Mann S, Guenova E, Moos R, Rocken M, et al. Primary localization and tumor thickness as prognostic factors of survival in patients with mucosal melanoma. *PLoS one*. 2014;9(11):e112535.
 31. Ascierto PA, Accorona R, Botti G, Farina D, Fossati P, Gatta G, et al. Mucosal melanoma of the head and neck. *Critical reviews in oncology/hematology*. 2017;112:136-52.
 32. Heppt MV, Roesch A, Weide B, Gutzmer R, Meier F, Loquai C, et al. Prognostic factors and treatment outcomes in 444 patients with mucosal melanoma. *European journal of cancer (Oxford, England : 1990)*. 2017;81:36-44.
 33. Mihajlovic M, Vljakovic S, Jovanovic P, Stefanovic V. Primary mucosal melanomas: a comprehensive review. *International journal of clinical and experimental pathology*. 2012;5(8):739-53.
 34. Dunton CJ, Berd D. Vulvar melanoma, biologically different from other cutaneous melanomas. *Lancet (London, England)*. 1999;354(9195):2013-4.
 35. An J, Li B, Wu L, Lu H, Li N. Primary malignant amelanotic melanoma of the female genital tract: report of two cases and review of literature. *Melanoma research*. 2009;19(4):267-70.
 36. Ragnarsson-Olding BK. Primary malignant melanoma of the vulva--an aggressive tumor for modeling the genesis of non-UV light-associated melanomas. *Acta oncologica (Stockholm, Sweden)*. 2004;43(5):421-35.
 37. Dummer R, Guggenheim M, Arnold AW, Braun R, von Moos R. Updated Swiss guidelines for the treatment and follow-up of cutaneous melanoma. *Swiss medical weekly*. 2011;141:w13320.
 38. Wechter ME, Reynolds RK, Haefner HK, Lowe L, Gruber SB, Schwartz JL, et al. Vulvar melanoma: review of diagnosis, staging, and therapy. *Journal of lower genital tract disease*. 2004;8(1):58-69.
 39. Janda M, Obermair A, Cella D, Crandon AJ, Trimmel M. Vulvar cancer patients' quality of life: a qualitative assessment. *International journal of gynecological cancer : official journal of the International Gynecological Cancer Society*. 2004;14(5):875-81.
 40. DiSaia PJ, Creasman WT, Rich WM. An alternate approach to early cancer of the vulva. *American journal of obstetrics and gynecology*. 1979;133(7):825-32.
 41. Murzaku EC, Penn LA, Hale CS, Pomeranz MK, Polsky D. Vulvar nevi, melanosis, and melanoma: an epidemiologic, clinical, and histopathologic review. *Journal of the American Academy of Dermatology*. 2014;71(6):1241-9.
 42. Schned L, Mount SL. Unusual neoplasms of the vulva. *Diagnostic Histopathology*. 16(11):517-25.
 43. NCCN guideline for patients. *Melanoma 2018*. Available from: www.nccn.org/patients/guidelines/melanoma/files
 44. Nederlandse Melanoom Werkgroep. Landelijke richtlijn melanoom: oncoline; 2016 [15-06-2018]. Available from: www.oncoline.nl/melanoom.
 45. Leitao MM, Jr., Cheng X, Hamilton AL, Siddiqui NA, Jurgentliemk-Schulz I, Mahner S, et al. Gynecologic Cancer InterGroup (GCIg) consensus review for vulvovaginal melanomas. *International journal of gynecological cancer : official journal of the International Gynecological Cancer Society*. 2014;24(9 Suppl 3):S117-22.
 46. Tasseron EW, van der Esch EP, Hart AA, Brutel de la Riviere G, Aartsen EJ. A clinicopathological study of 30 melanomas of the vulva. *Gynecologic oncology*. 1992;46(2):170-5.
 47. Phillips GL, Bundy BN, Okagaki T, Kucera PR, Stehman FB. Malignant melanoma of the vulva treated by radical hemivulvectomy. A prospective study of the Gynecologic Oncology Group. *Cancer*. 1994;73(10):2626-32.
 48. Scheistroen M, Trope C, Koern J, Pettersen EO, Abeler VM, Kristensen GB. Malignant melanoma of the vulva. Evaluation of prognostic factors with emphasis on DNA ploidy in 75 patients. *Cancer*. 1995;75(1):72-80.
 49. Creasman WT, Phillips JL, Menck HR. A survey of hospital management practices for vulvar

- melanoma. *Journal of the American College of Surgeons*. 1999;188(6):670-5.
50. Tcheung WJ, Selim MA, Herndon JE, 2nd, Abernethy AP, Nelson KC. Clinicopathologic study of 85 cases of melanoma of the female genitalia. *Journal of the American Academy of Dermatology*. 2012;67(4):598-605.
 51. Seifried S, Haydu LE, Quinn MJ, Scolyer RA, Stretch JR, Thompson JF. Melanoma of the vulva and vagina: principles of staging and their relevance to management based on a clinicopathologic analysis of 85 cases. *Annals of surgical oncology*. 2015;22(6):1959-66.
 52. Control UfIC. TNM classification of malignant tumours 2016 [01-06-2018]. Available from: www.hoofdhalskanker.info/wpavl/wp-content/uploads/TNM-Classification-of-Malignant-Tumours-8th-edition.
 53. Ragnarsson-Olding BK, Nilsson BR, Kanter-Lewensohn LR, Lagerlof B, Ringborg UK. Malignant melanoma of the vulva in a nationwide, 25-year study of 219 Swedish females: predictors of survival. *Cancer*. 1999;86(7):1285-93.
 54. Podratz KC, Gaffey TA, Symmonds RE, Johansen KL, O'Brien PC. Melanoma of the vulva: an update. *Gynecologic oncology*. 1983;16(2):153-68.
 55. Benda JA, Platz CE, Anderson B. Malignant melanoma of the vulva: a clinical-pathologic review of 16 cases. *International journal of gynecological pathology : official journal of the International Society of Gynecological Pathologists*. 1986;5(3):202-16.
 56. Hinten F, van den Einden LC, Cissen M, Int'Hout J, Massuger LF, de Hullu JA. Clitoral involvement of squamous cell carcinoma of the vulva: localization with the worst prognosis. *European journal of surgical oncology : the journal of the European Society of Surgical Oncology and the British Association of Surgical Oncology*. 2015;41(4):592-8.
 57. Balch CM, Buzaid AC, Soong SJ, Atkins MB, Cascinelli N, Coit DG, et al. Final version of the American Joint 3 Committee on Cancer staging system for cutaneous melanoma. *Journal of clinical oncology : official journal of the American Society of Clinical Oncology*. 2001;19(16):3635-48.
 58. Alkatout I, Schubert M, Garbrecht N, Weigel MT, Jonat W, Mundhenke C, et al. Vulvar cancer: epidemiology, clinical presentation, and management options. *International journal of women's health*. 2015;7:305-13.
 59. Vitale SG, Valenti G, Biondi A, Rossetti D, Frigerio L. Recent trends in surgical and reconstructive management of vulvar cancer: review of literature. *Updates in Surgery*. 2015;67(4):367-71.
 60. Lazarev S, Gupta V, Hu K, Harrison LB, Bakst R. Mucosal Melanoma of the Head and Neck: A Systematic Review of the Literature. *International Journal of Radiation Oncology • Biology • Physics*. 2014;90(5):1108-18.
 61. Lietin B, Montalban A, Louvrier C, Kemeny JL, Mom T, Gilain L. Sinonasal mucosal melanomas. *European annals of otorhinolaryngology, head and neck diseases*. 2010;127(2):70-6.
 62. Moreno MA, Roberts DB, Kupferman ME, DeMonte F, El-Naggar AK, Williams M, et al. Mucosal melanoma of the nose and paranasal sinuses, a contemporary experience from the M.D. Anderson Cancer Center. *Cancer*. 2010;116(9):2215-23.
 63. Trifiro G, Travaini LL, Sanvito F, Pacifici M, Mallia A, Ferrari ME, et al. Sentinel node detection by lymphoscintigraphy and sentinel lymph node biopsy in vulvar melanoma. *European journal of nuclear medicine and molecular imaging*. 2010;37(4):736-41.
 64. Abramova L, Parekh J, Irvin WP, Jr., Rice LW, Taylor PT, Jr., Anderson WA, et al. Sentinel node biopsy in vulvar and vaginal melanoma: presentation of six cases and a literature review. *Annals of surgical oncology*. 2002;9(9):840-6.
 65. Dhar KK, Das N, Brinkman DA, Beynon JL, Woolas RP. Utility of sentinel node biopsy in vulvar and vaginal melanoma: report of two cases and review of the literature. *International journal of gynecological cancer : official journal of the International Gynecological Cancer Society*. 2007;17(3):720-3.
 66. Vidal-Sicart S, Puig-Tintore LM, Lejarcegui JA, Paredes P, Ortega ML, Munoz A, et al. Validation and application of the sentinel lymph node concept in malignant vulvar tumours. *European journal of nuclear medicine and molecular imaging*. 2007;34(3):384-91.
 67. Levenback C, Burke TW, Gershenson DM, Morris M, Malpica A, Ross MI. Intraoperative lymphatic mapping for vulvar cancer. *Obstetrics and gynecology*. 1994;84(2):163-7.
 68. Rodier JF, Janser JC, Routiot T, David E, Ott G, Schneegans O, et al. Sentinel node biopsy in vulvar malignancies: a preliminary feasibility study. *Oncology reports*. 1999;6(6):1249-52.
 69. Dummer R, Hauschild A, Lindenblatt N, Pentheroudakis G, Keilholz U. Cutaneous melanoma: ESMO Clinical Practice Guidelines for diagnosis, treatment and follow-up. *Annals of oncology : official journal of the European Society for Medical Oncology*. 2015;26 Suppl 5:v126-32.
 70. Wong SL, Balch CM, Hurley P, Agarwala SS, Akhurst TJ, Cochran A, et al. Sentinel lymph node biopsy for melanoma: American Society of Clinical Oncology and Society of Surgical Oncology joint clinical practice guideline. *Journal of clinical*

- oncology : official journal of the American Society of Clinical Oncology. 2012;30(23):2912-8.
71. Morton DL, Thompson JF, Cochran AJ, Mozzillo N, Nieweg OE, Roses DF, et al. Final trial report of sentinelnode biopsy versus nodal observation in melanoma. *The New England journal of medicine*. 2014;370(7):599-609.
 72. Forschner A, Heinrich V, Pflugfelder A, Meier F, Garbe C. The role of radiotherapy in the overall treatment of melanoma. *Clinics in dermatology*. 2013;31(3):282-9.
 73. Ballo MT, Ang KK. Radiation therapy for malignant melanoma. *The Surgical clinics of North America*. 2003;83(2):323-42.
 74. Samstein Robert M, Carvajal Richard D, Postow Michael A, Callahan Margaret K, Shoushtari Alexander N, Patel Snehal G, et al. Localized sinonasal mucosal melanoma: Outcomes and associations with stage, radiotherapy, and positron emission tomography response. *Head & Neck*. 2016;38(9):1310-7.
 75. Vongtama R, Safa A, Gallardo D, Calcaterra T, Juillard G. Efficacy of radiation therapy in the local control of desmoplastic malignant melanoma. *Head Neck*. 2003;25(6):423-8.
 76. Testori A, Rutkowski P, Marsden J, Bastholt L, Chiarion-Sileni V, Hauschild A, et al. Surgery and radiotherapy in the treatment of cutaneous melanoma. *Annals of oncology : official journal of the European Society for Medical Oncology*. 2009;20 Suppl 6:vi22-9.
 77. Schiavone MB, Broach V, Shoushtari AN, Carvajal RD, Alektiar K, Kollmeier MA, et al. Combined immunotherapy and radiation for treatment of mucosal melanomas of the lower genital tract. *Gynecologic oncology reports*. 2016;16:42-6.
 78. Henderson MA, Burmeister BH, Ainslie J, Fisher R, Di Iulio J, Smithers BM, et al. Adjuvant lymph-node field radiotherapy versus observation only in patients with melanoma at high risk of further lymph-node field relapse after lymphadenectomy (ANZMTG 01.02/TROG 02.01): 6-year follow-up of a phase 3, randomised controlled trial. *The Lancet Oncology*. 2015;16(9):1049-60.
 79. Strojan P. Role of radiotherapy in melanoma management. *Radiology and Oncology*. 2010;44(1):1-12.
 80. Guadagnolo BA, Prieto V, Weber R, Ross MI, Zagars GK. The role of adjuvant radiotherapy in the local management of desmoplastic melanoma. *Cancer*. 2014;120(9):1361-8.
 81. Lian B, Si L, Cui C, Chi Z, Sheng X, Mao L, et al. Phase II randomized trial comparing high-dose IFN-alpha2b with temozolomide plus cisplatin as systemic adjuvant therapy for resected mucosal melanoma. *Clinical cancer research : an official journal of the American Association for Cancer Research*. 2013;19(16):4488-98.
 82. Harting MS, Kim KB. Biochemotherapy in patients with advanced vulvovaginal mucosal melanoma. *Melanoma research*. 2004;14(6):517-20. 4
 83. Mocellin S, Lens MB, Pasquali S, Pilati P, Chiarion Sileni V. Interferon alpha for the adjuvant treatment of cutaneous melanoma. *The Cochrane database of systematic reviews*. 2013(6):Cd008955.
 84. Xia L, Han D, Yang W, Li J, Chuang L, Wu X. Primary malignant melanoma of the vagina: a retrospective clinicopathologic study of 44 cases. *International journal of gynecological cancer : official journal of the International Gynecological Cancer Society*. 2014;24(1):149-55.
 85. Creagan ET, Ahmann DL, Frytak S, Long HJ, Chang MN, Itri LM. Phase II trials of recombinant leukocyte A interferon in disseminated malignant melanoma: results in 96 patients. *Cancer treatment reports*. 1986;70(5):619-24.
 86. Dummer R, Garbe C, Thompson JA, Eggermont AM, Yoo K, Maier T, et al. Randomized dose-escalation study evaluating peginterferon alfa-2a in patients with metastatic malignant melanoma. *Journal of clinical oncology : official journal of the American Society of Clinical Oncology*. 2006;24(7):1188-94.
 87. Wolchok JD, Chiarion-Sileni V, Gonzalez R, Rutkowski P, Grob JJ, Cowey CL, et al. Overall Survival with Combined Nivolumab and Ipilimumab in Advanced Melanoma. *The New England journal of medicine*. 2017;377(14):1345-56.
 88. Eggermont AM, Chiarion-Sileni V, Grob JJ, Dummer R, Wolchok JD, Schmidt H, et al. Prolonged Survival in Stage III Melanoma with Ipilimumab Adjuvant Therapy. *The New England journal of medicine*. 2016;375(19):1845-55.
 89. Robert C, Schachter J, Long GV, Arance A, Grob JJ, Mortier L, et al. Pembrolizumab versus Ipilimumab in Advanced Melanoma. *The New England journal of medicine*. 2015;372(26):2521-32.
 90. Weber J, Mandala M, Del Vecchio M, Gogas HJ, Arance AM, Cowey CL, et al. Adjuvant Nivolumab versus Ipilimumab in Resected Stage III or IV Melanoma. *The New England journal of medicine*. 2017;377(19):1824-35.
 91. Quereux G, Wylomanski S, Bouquin R, Saint-Jean M, Peuvrel L, Knol AC, et al. Are checkpoint inhibitors a valuable option for metastatic or unresectable vulvar and vaginal melanomas? *Journal of the European Academy of Dermatology and Venereology : JEADV*. 2018;32(1):e39-e40.
 92. Alexander M, Mellor JD, McArthur G, Kee D. Ipilimumab in pretreated patients with unresectable or metastatic cutaneous, uveal and mucosal melanoma. *The Medical journal of*

- Australia. 2014;20(1):49-53.
93. Liu LS, Colegio OR. Molecularly targeted therapies for melanoma. *International journal of dermatology*. 2013;52(5):523-30.
 94. Edwards RH, Ward MR, Wu H, Medina CA, Brose MS, Volpe P, et al. Absence of BRAF mutations in UVprotected mucosal melanomas. *Journal of medical genetics*. 2004;41(4):270-2.
 95. Cohen Y, Rosenbaum E, Begum S, Goldenberg D, Esche C, Lavie O, et al. Exon 15 BRAF mutations are uncommon in melanomas arising in nonsun-exposed sites. *Clinical cancer research : an official journal of the American Association for Cancer Research*. 2004;10(10):3444-7.
 96. Wong CW, Fan YS, Chan TL, Chan AS, Ho LC, Ma TK, et al. BRAF and NRAS mutations are uncommon in melanomas arising in diverse internal organs. *Journal of clinical pathology*. 2005;58(6):640-4.
 97. Omholt K, Grafstrom E, Kanter-Lewensohn L, Hansson J, Ragnarsson-Olding BK. KIT pathway alterations in mucosal melanomas of the vulva and other sites. *Clinical cancer research : an official journal of the American Association for Cancer Research*. 2011;17(12):3933-42.
 98. Carvajal RD, Antonescu CR, Wolchok JD, Chapman PB, Roman RA, Teitcher J, et al. KIT as a therapeutic target in metastatic melanoma. *Jama*. 2011;305(22):2327-34.
 99. van Engen-van Grunsven AC, Kusters-Vandeveldre HV, De Hullu J, van Duijn LM, Rijntjes J, Bovee JV, et al. NRAS mutations are more prevalent than KIT mutations in melanoma of the female urogenital tract—a study of 24 cases from the Netherlands. *Gynecologic oncology*. 2014;134(1):10-4.
 100. Tseng D, Kim J, Warrick A, Nelson D, Pukay M, Beadling C, et al. Oncogenic mutations in melanomas and benign melanocytic nevi of the female genital tract. *Journal of the American Academy of Dermatology*. 2014;71(2):229-36.
 101. Aulmann S, Sinn HP, Penzel R, Gilks CB, Schott S, Hassel JC, et al. Comparison of molecular abnormalities in vulvar and vaginal melanomas. *Modern pathology : an official journal of the United States and Canadian Academy of Pathology, Inc*. 2014;27(10):1386-93.
 102. Rouzbahman M, Kamel-Reid S, Al Habeeb A, Butler M, Dodge J, Laframboise S, et al. Malignant Melanoma of Vulva and Vagina: A Histomorphological Review and Mutation Analysis--A Single-Center Study. *Journal of lower genital tract disease*. 2015;19(4):350-3.
 103. Hou JY, Baptiste C, Hombalegowda RB, Tergas AI, Feldman R, Jones NL. Vulvar and vaginal melanoma: A unique subclass of mucosal melanoma based on a comprehensive molecular analysis of 51 cases compared with 2253 cases of nongynecologic melanoma. 2017;123(8):1333-44.
 104. Dias-Santagata D, Selim MA, Su Y, Peng Y, Vollmer R, Chlopik A, et al. KIT mutations and CD117 overexpression are markers of better progression-free survival in vulvar melanomas. *The British journal of dermatology*. 2017;177(5):1376-84.
 105. Cinotti E, Chevallier J, Labelle B, Cambazard F, Thomas L, Balme B, et al. Mucosal melanoma: clinical, histological and c-kit gene mutational profile of 86 French cases. *Journal of the European Academy of Dermatology and Venereology : JEADV*. 2017;31(11):1834-40.
 106. Wylomanski S, Denis MG, Theoleyre S, Bouquin R, Vallee A, Knol AC, et al. BRAF mutations might be more common than supposed in vulvar melanomas. *Experimental dermatology*. 2018;27(2):210-3.
 107. Torres-Cabala CA, Wang W-L, Trent J, Yang D, Chen S, Galbinca J, et al. Correlation between KIT expression and KIT mutation in melanoma: a study of 173 cases with emphasis on the acral-lentiginous/mucosal type. *Modern pathology : an official journal of the United States and Canadian Academy of Pathology, Inc*. 2009;22(11):1446-56. 5
 108. Schoenewolf NL, Bull C, Belloni B, Holzmann D, Tonolla S, Lang R, et al. Sinonasal, genital and acrolentiginous melanomas show distinct characteristics of KIT expression and mutations. *European Journal of Cancer*. 2012;48(12):1842-52.
 109. Abu-Abed S, Pennell N, Petrella T, Wright F, Seth A, Hanna W. KIT gene mutations and patterns of protein expression in mucosal and acral melanoma. *Journal of cutaneous medicine and surgery*. 2012;16(2):135-42.
 110. Jiveskog S, Ragnarsson-Olding B, Platz A, Ringborg U. N-ras mutations are common in melanomas from sun-exposed skin of humans but rare in mucosal membranes or unexposed skin. *The Journal of investigative dermatology*. 1998;111(5):757-61.
 111. Hodi FS, Corless CL, Giobbie-Hurder A, Fletcher JA, Zhu MJ, Marino-Enriquez A, et al. Imatinib for Melanomas Harboring Mutationally Activated or Amplified KIT Arising on Mucosal, Acral, and Chronically SunDamaged Skin. *J Clin Oncol*. 2013;31(26):3182+.
 112. Minor DR, Kashani-Sabet M, Garrido M, O'Day SJ, Hamid O, Bastian BC. Sunitinib therapy for melanoma patients with KIT mutations. *Clinical cancer research : an official journal of the American Association for Cancer Research*. 2012;18(5):1457-63.
 113. Guo J, Carvajal RD, Dummer R, Hauschild A, Daud A, Bastian BC, et al. Efficacy and safety of nilotinib in patients with KIT-mutated metastatic

- or inoperable melanoma: final results from the global, single-arm, phase II TEAM trial. *Annals of Oncology*. 2017;28(6):1380-7.
114. Ma X, Wu Y, Zhang T, Song H, Jv H, Guo W, et al. The clinical significance of c-Kit mutations in metastatic oral mucosal melanoma in China. *Oncotarget*. 2017;8(47):82661-73.
 115. Pleunis N, Schuurman MS, Van Rossum MM, Bulten J, Massuger LF, De Hullu JA, et al. Rare vulvar malignancies; incidence, treatment and survival in the Netherlands. *Gynecologic oncology*. 2016;142(3):440-5.
 116. Chung AF, Woodruff JM, Lewis JL, Jr. Malignant melanoma of the vulva: A report of 44 cases. *Obstetrics and gynecology*. 1975;45(6):638-46.
 117. Trotter SC, Sroa N, Winkelmann RR, Olencki T, Bechtel M. A Global Review of Melanoma Follow-up Guidelines. *The Journal of clinical and aesthetic dermatology*. 2013;6(9):18-26.
 118. Piura B, Egan M, Lopes A, Monaghan JM. Malignant melanoma of the vulva: a clinicopathologic study of 18 cases. *Journal of surgical oncology*. 1992;50(4):234-40

Appendix

Appendix 1- definitive search strategy Pubmed

See online: [https://www.cancertreatmentreviews.com/article/S0305-7372\(18\)30209-3/fulltext#supplementaryMaterial](https://www.cancertreatmentreviews.com/article/S0305-7372(18)30209-3/fulltext#supplementaryMaterial)

Appendix 2 - AJCC staging (2009) for cutaneous melanoma

See online: [https://www.cancertreatmentreviews.com/article/S0305-7372\(18\)30209-3/fulltext#supplementaryMaterial](https://www.cancertreatmentreviews.com/article/S0305-7372(18)30209-3/fulltext#supplementaryMaterial)

Appendix 3 - UICC TNM staging for head and neck mucosal melanomas (2017)

Primary tumour (T)	
T category	T criteria
T3	Tumors limited to the mucosa and immediately underlying soft tissue, regardless of thickness or greatest dimension; for example, polypoid nasal disease, pigmented or nonpigmented lesions of the oral cavity, pharynx, or larynx
T4	Moderately advanced or very advanced
T4a	Moderately advanced disease. Tumor involving deep soft tissue, cartilage, bone, or overlying skin
T4b	Very advanced disease. Tumor involving brain, dura, skull base, lower cranial nerves (IX, X, XI, XII), masticator space, carotid artery, prevertebral space, or mediastinal structures.
Regional lymph nodes (N)	
N category	N criteria
NX	Regional lymph nodes cannot be assessed
NO	No regional lymph node metastases
N1	Regional lymph node metastases present
Distant metastasis (M)	
M category	M criteria
M0	No distant metastasis
M1	Distant metastasis present

Figure 1. Clinical presentation of vulvar melanoma

