



**Universiteit  
Leiden**  
The Netherlands

## **A phase 2 trial combining afatinib with cetuximab in patients with EGFR exon 20 insertion-positive non-small cell lung cancer**

Veggel, B.A.M.H. van; Wekken, A.J. van der; Paats, M.S.; Hendriks, L.E.L.; Hashemi, S.M.S.; Daletzakis, A.; ... ; Langen, A.J. de

### **Citation**

Veggel, B. A. M. H. van, Wekken, A. J. van der, Paats, M. S., Hendriks, L. E. L., Hashemi, S. M. S., Daletzakis, A., ... Langen, A. J. de. (2023). A phase 2 trial combining afatinib with cetuximab in patients with EGFR exon 20 insertion-positive non-small cell lung cancer. *Cancer*, 5, 683-691. doi:10.1002/cncr.35090

Version: Publisher's Version


License: [Licensed under Article 25fa Copyright Act/Law \(Amendment Taverne\)](#)

Downloaded from: <https://hdl.handle.net/1887/3722141>

**Note:** To cite this publication please use the final published version (if applicable).

## ORIGINAL ARTICLE

# A phase 2 trial combining afatinib with cetuximab in patients with *EGFR* exon 20 insertion–positive non–small cell lung cancer

Bianca A. M. H. van Veggel MD<sup>1</sup>  | Anthonie J. van der Wekken MD, PhD<sup>2</sup> |  
 Marthe S. Paats MD, PhD<sup>3</sup> | Lizza E. L. Hendriks MD, PhD<sup>4</sup> |  
 Sayed M. S. Hashemi MD, PhD<sup>5</sup> | Antonios Daletzikis PhD<sup>6</sup> |  
 Daan van den Broek PhD<sup>7</sup> | Linda J. W. Bosch PhD<sup>8</sup> | Kim Monkhorst PhD<sup>8</sup> |  
 Egbert F. Smit MD, PhD<sup>1,9</sup> | Adrianus J. de Langen MD, PhD<sup>1</sup>

<sup>1</sup>Department of Thoracic Oncology, Netherlands Cancer Institute–Antoni van Leeuwenhoek Hospital, Amsterdam, the Netherlands

<sup>2</sup>Department of Pulmonary Diseases, University of Groningen and University Medical Center Groningen, Groningen, the Netherlands

<sup>3</sup>Department of Pulmonary Diseases, Erasmus University Medical Center Cancer Institute, Rotterdam, the Netherlands

<sup>4</sup>Department of Pulmonary Diseases, Maastricht University Medical Center, Maastricht, the Netherlands

<sup>5</sup>Department of Pulmonary Medicine, Amsterdam University Medical Centers, Vrije Universiteit Medical Center, and Cancer Center Amsterdam, Amsterdam, the Netherlands

<sup>6</sup>Department of Biometrics, Netherlands Cancer Institute–Antoni van Leeuwenhoek Hospital, Amsterdam, the Netherlands

<sup>7</sup>Department of Laboratory Medicine, Netherlands Cancer Institute–Antoni van Leeuwenhoek Hospital, Amsterdam, the Netherlands

<sup>8</sup>Department of Pathology, Netherlands Cancer Institute–Antoni van Leeuwenhoek Hospital, Amsterdam, the Netherlands

<sup>9</sup>Department of Pulmonary Diseases, Leiden University Medical Center, Leiden, the Netherlands

## Correspondence

Adrianus J. de Langen, Netherlands Cancer Institute–Antoni van Leeuwenhoek Hospital, Plesmanlaan 121, 1066 CX Amsterdam, the Netherlands.

Email: [j.d.langen@nki.nl](mailto:j.d.langen@nki.nl)

## Funding information

Boehringer Ingelheim; Merck BV, an affiliate of Merck KGaA

## Abstract

**Background:** Epidermal growth factor receptor (*EGFR*) exon 20 insertion (ex20ins) mutations are the third most common *EGFR* mutations in patients with non–small cell lung cancer (NSCLC) and are associated with primary resistance to *EGFR* tyrosine kinase inhibitors (TKIs). There is evidence of activity of combining *EGFR* TKIs with monoclonal antibodies. This study reports on the efficacy and safety of afatinib in combination with cetuximab.

**Methods:** In this single-arm phase 2 trial, patients with advanced NSCLC harboring an *EGFR* ex20ins mutation were treated with afatinib 40 mg once daily in combination with cetuximab 500 mg/m<sup>2</sup> every 2 weeks. The primary end point was disease control rate (DCR) at 18 weeks of treatment.

**Results:** Thirty-seven patients started treatment, with a median age of 65 years (range, 40–80 years), 78% female, and 95% White. The study achieved its primary end point with a DCR of 54% at 18 weeks, an overall response rate (ORR) of 43%, and a 32% confirmed ORR. Best responses were partial ( $n = 16$ ), stable ( $n = 16$ ), progressive disease ( $n = 2$ ), or not evaluable ( $n = 3$ ). Median progression-free survival was 5.5 months (95% CI, 3.7–8.3 months) and median overall survival was 16.8 months (95% CI, 10.7–25.8 months). The most common treatment-related

adverse events (TRAEs) were diarrhea (70%), rash (65%), dry skin (59%), paronychia (54%), and erythema (43%). Grade 3 TRAEs were reported in 54% of all patients.

**Conclusions:** Combination treatment with afatinib and cetuximab demonstrated antitumor activity with a DCR of 54% at 18 weeks and a 32% confirmed ORR. Toxicity was significant, although manageable, after dose reduction.

#### KEYWORDS

afatinib, cetuximab, EGFR exon 20 insertion, non-small cell lung cancer

## INTRODUCTION

Epidermal growth factor receptor (EGFR) exon 20 insertion (ex20ins) mutations comprise 4%–12% of EGFR-mutated non-small cell lung cancer (NSCLC) and approximately 2% of all NSCLC cases.<sup>1–4</sup> In contrast to the more common in-frame deletions in exon 19 and the L858R point mutation in exon 21, EGFR ex20ins mutations are generally resistant to EGFR tyrosine kinase inhibitors (TKIs), except for the EGFR A763\_Y764insFQEA variant.<sup>2,5–8</sup> Targeting EGFR ex20ins mutations is challenging because these mutations activate EGFR without diminishing adenosine triphosphate (ATP) affinity, which results in a small therapeutic window for EGFR TKIs.<sup>9</sup> Although there is progress in developing novel targeted therapies for these patients, currently platinum-based chemotherapy remains the first-line treatment of choice.<sup>10–12</sup>

EGFR ex20ins mutations are unresponsive to EGFR TKIs in general, including afatinib, a second-generation irreversible EGFR TKI, with overall response rates (ORRs) below 10%.<sup>8</sup> In addition, a pooled analysis of 70 patients treated with afatinib monotherapy demonstrated modest activity with an ORR of 24.3%.<sup>13</sup> There is some evidence of increased antitumor activity when adding cetuximab to an EGFR TKI. Cetuximab, an anti-EGFR monoclonal antibody (mAb), binds with high affinity to the extracellular domain of EGFR, partially blocks the ligand-binding domain, and sterically hinders EGFR dimer formation.<sup>14</sup> Cetuximab can also target EGFR by diminishing EGFR phosphorylation.<sup>15</sup> Consequently, in combination with an EGFR TKI, mAbs induce a more potent inhibitory effect in vitro, in vivo, and in xenografts than either therapy alone.<sup>16</sup> In 2018, we described tumor responses in three of four patients with EGFR ex20ins-positive NSCLC after afatinib and cetuximab combination treatment.<sup>17</sup> In conclusion, there is evidence of activity of combining EGFR TKIs with EGFR mAbs. However, the safety profile of this combination is of special interest because treatment with afatinib and cetuximab led to high rates of EGFR-related toxicity, especially dermatological side effects and diarrhea.<sup>18,19</sup>

We previously presented interim data of the first 17 patients with EGFR ex20ins-positive metastatic NSCLC who received afatinib in combination with cetuximab in our single-arm, phase 2 trial (AFACET). The antitumor activity of this combination was demonstrated by a disease control rate (DCR) at 18 weeks of 59%, an ORR of 47%, and a median progression-free survival (PFS) of 5.5 months.

Almost 60% of patients experienced grade  $\geq 3$  toxicity.<sup>20</sup> Here, we report the final results of this trial.

## MATERIALS AND METHODS

### Study design and patients

This single-arm, open-label, investigator-initiated phase 2 trial was conducted at five academic institutions in the Netherlands. Eligible patients had advanced NSCLC with an Eastern Cooperative Oncology Group performance status of  $\leq 2$  and had measurable disease according to Response Evaluation Criteria in Solid Tumors (RECIST), version 1.1.<sup>21</sup> EGFR mutation status was locally tested via an amplicon-based next-generation sequencing (NGS) hotspot panel that was validated for detection of EGFR ex20ins mutations. Previous systemic therapy was allowed but not mandatory. Key exclusion criteria were prior treatment with EGFR-targeting antibodies (prior treatment with EGFR TKIs was allowed) and symptomatic brain metastases. Untreated asymptomatic brain metastases were allowed.

The protocol was approved by an Institutional Review Board at each study center. All patients provided written informed consent before study procedures, and the study was done in accordance with the Declaration of Helsinki.<sup>22</sup> This study is registered with [ClinicalTrials.gov](https://clinicaltrials.gov) (NCT03727724).

### Treatment and study assessments

Patients received afatinib 40 mg orally once daily, in combination with cetuximab 500 mg/m<sup>2</sup> intravenously every 2 weeks, until disease progression or unacceptable toxicity. Patients who discontinued treatment for reasons other than disease progression continued with tumor assessments until disease progression. Supportive medication consisted of minocycline 100 mg once daily, loperamide as needed, and emollient skin creams two to four times per day. Two dose reductions were allowed: first, a dose reduction of afatinib to 30 mg in combination with 400 mg of cetuximab, followed by a second dose reduction of afatinib to 30 mg once daily and cetuximab 250 mg. If unacceptable toxicity recurred after two dose modifications, study

treatment was permanently discontinued. Tumor assessments according to RECIST, version 1.1 were locally performed by an independent thoracic radiologist via computed tomography (CT) scans. CT scans were performed at baseline and every 6 weeks thereafter until radiographic progression. Magnetic resonance imaging of the brain was performed at baseline and thereafter every 6 weeks only in cases where brain metastases were present at screening. Selected patients were permitted to continue treatment beyond disease progression in cases of ongoing clinical benefit.

## Outcomes

The primary objective was to determine the DCR at 18 weeks of afatinib and cetuximab treatment. Secondary end points included investigator-assessed ORR, duration of response (DoR), PFS, overall survival (OS), and safety. Adverse events were graded according to National Cancer Institute Common Terminology Criteria for Adverse Events, version 4.03.

## Statistical analysis

A Simon's two-stage optimal design was used for sample size determination. The null hypothesis was tested against a one-sided alternative, with  $\alpha$ : 0.10, power of 90. The trial aimed to show a DCR of  $\geq 40\%$  at 18 weeks after treatment initiation. Seventeen patients were planned for inclusion in the first stage. If at least four patients experienced disease control after 18 weeks of treatment, the trial would expand to a total sample size of 37 patients. The study treatment was accepted for further development if at least 11 of 37 patients experienced disease control at 18 weeks. Response rate was estimated using the uniform minimum variance unbiased estimator proposed by Jung,<sup>23</sup> with a 95% confidence interval (CI) obtained by the method of Koyama et al.<sup>24</sup> The *clinfun* package, version 1.1.0, in R programming was used for that calculation, specifically the *two-stage.inference* function.

Overall response and disease control were estimated, including their two-sided 95% CIs. DCR was defined as the percentage of patients who had achieved complete response, partial response, or stable disease at 18 weeks of treatment. To determine disease control at 18 weeks, we used the evaluation CT scan that was performed at 18 weeks of treatment or the first CT scan thereafter. Patients who were not evaluable at 18 weeks were considered to be treatment failures regarding the primary end point. Time-to-event end points (PFS, DoR, and OS) were analyzed via the Kaplan-Meier method. PFS was defined as the interval between the initiation of study treatment and the date of radiological progression or death from any cause, whichever occurred first. The data cutoff for the analyses was December 18, 2022. *p* values for subgroups were calculated via the log-rank test. The statistical software program R was used for all the analyses.

**TABLE 1** Baseline patient and tumor characteristics (N = 37).

Characteristics	Patients
Age, median (range), years	65 (40–80)
Female, No. (%)	29 (78)
Histology, No. (%)	
Adenocarcinoma	36 (97)
Squamous cell carcinoma	1 (3)
Smoking status, No. (%)	
Never	13 (35)
Former	22 (59)
Current	2 (5)
Ethnicity, No. (%)	
White	35 (95)
African descent	1 (3)
East/Southeast Asian	1 (3)
ECOG performance status, No. (%)	
0	11 (30)
1	23 (62)
2	3 (8)
Brain metastases at baseline, No. (%)	14 (38)
Local radiotherapy at baseline	2 (14)
Untreated asymptomatic brain metastases at baseline	12 (86)
Most common EGFR ex20ins mutations (>10%), No. (%)	
S768_D770dup	7 (19)
A767_V769dup	4 (11)
D770_N771insG	4 (11)
Prior treatment, No. (%)	
Platinum-based chemotherapy	10 (27)
Chemoimmunotherapy	6 (16)
Osimertinib	7 (19)
Prior lines of therapy, median (range), No. (%)	0 (0–5)
0	19 (51)
1	12 (32)
2	5 (14)
5	1 (3)

Abbreviations: ECOG, Eastern Cooperative Oncology Group; EGFR ex20ins, epidermal growth factor receptor exon 20 insertion.

## RESULTS

### Patients

Forty patients were screened between January 2019 and December 2021. Three patients did not meet all inclusion criteria and were

registered as screen failures. Thirty-seven patients were eligible and started study treatment. All patients had stage IV NSCLC harboring an *EGFR* ex20ins mutation based on NGS results of histological or cytological tumor samples. Baseline characteristics are shown in Table 1. The majority of patients (78%) were female, and 35% had never smoked. Among 14 patients (38%) with brain metastases at baseline, two were treated previously with local radiotherapy. The most common *EGFR* ex20ins mutation was S768\_D770dup (19%;  $n = 7$ ), followed by A767\_V769dup (11%;  $n = 4$ ) and D770\_N771insG (11%;  $n = 4$ ). No patients with the known sensitizing *EGFR* ex20ins variant A763\_Y764insFQEA were included in this cohort. Eighteen patients (49%) received previous treatment with chemotherapy, chemioimmunotherapy, and/or osimertinib. None of the patients received another (new-generation) *EGFR* TKI before enrollment in the study. The median number of previous lines of therapy was zero (range, 0–5).

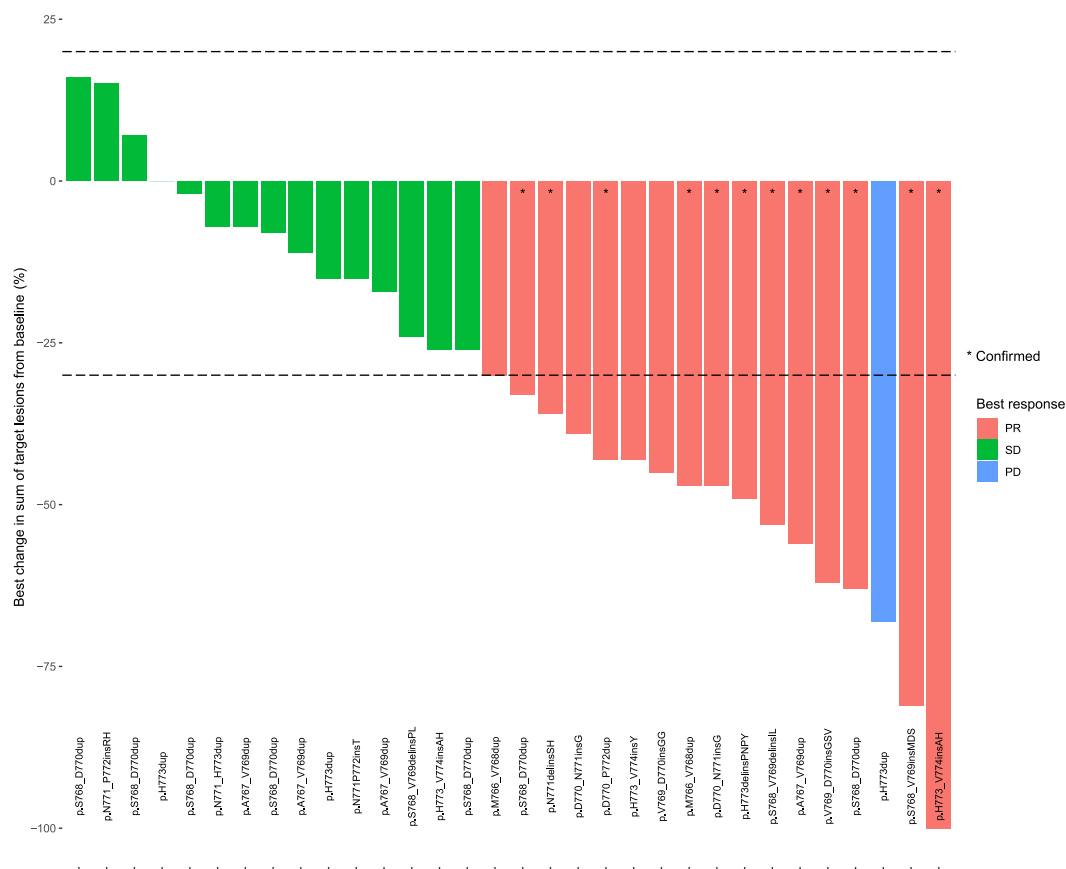
## Efficacy

The primary end point was met because disease control was achieved in 54% of patients (95% CI, 25%–63%;  $n = 20$ ) after 18 weeks of

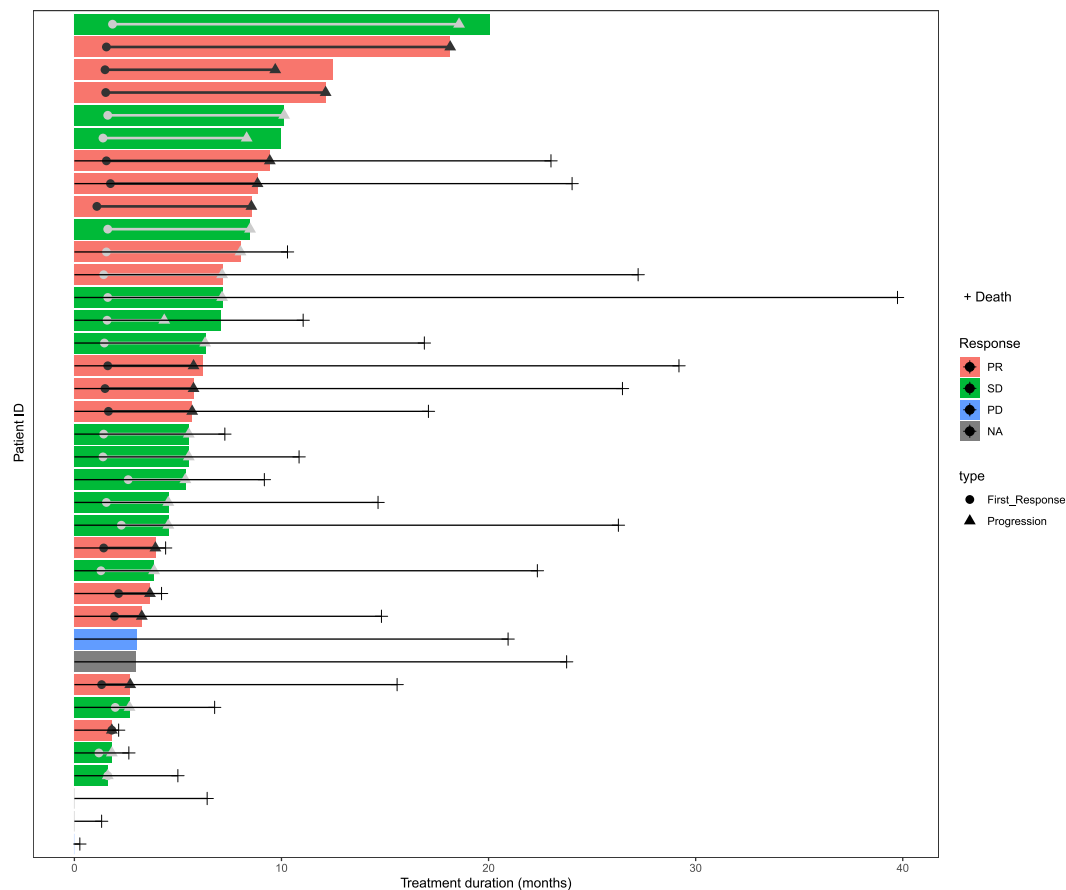
treatment. Best responses were partial ( $n = 16$ ), stable ( $n = 16$ ), or progressive disease (PD) ( $n = 2$ ) (Figure 1). Three patients were not evaluable for response because of a treatment-related adverse event (TRAE) or symptomatic deterioration before the first radiological assessment. The ORR was 43%. Among the 16 patients with a partial response, 12 were confirmed at subsequent imaging, which resulted in a confirmed ORR rate of 32% (95% CI, 20%–49%). Median DoR was 4.7 months (range, 0.3–16.6 months), median PFS was 5.5 months (95% CI, 3.7–8.3 months), and median OS was 16.8 months (95% CI, 10.7–25.8 months). At data cutoff (December 2022), all patients were off study treatment (Figure 2).

The primary reasons for discontinuation were PD (73%) or an adverse event(s) (22%). Two patients refused further treatment (5%).

In the subset of patients with brain metastases at baseline, the median PFS was similar to those without brain metastases ( $p = .87$ ). Three patients continued study treatment beyond cerebral disease progression for a median of 7 weeks (range, 6–14 weeks). One patient received whole-brain radiotherapy during study treatment. Seven weeks later, treatment was permanently discontinued because of further progression. Of the patients with brain metastases at baseline, all patients (except two patients who were not evaluable



**FIGURE 1** Tumor response to afatinib and cetuximab. Waterfall plot of the best percent change from baseline in the sum of target lesion diameters by locations of *EGFR* ex20ins mutations based on investigator assessment in patients with evaluable disease. The dashed lines at 20% and –30% indicate the thresholds for progressive disease and partial response, respectively, for RECIST response. Confirmed response rates are indicated with an asterisk. *EGFR* indicates epidermal growth factor receptor; ex20ins, exon 20 insertion; PD, progressive disease; PR, partial response; RECIST, Response Evaluation Criteria in Solid Tumors; SD, stable disease.



**FIGURE 2** Duration of treatment. Duration of afatinib and cetuximab treatment in all treated patients ( $N = 37$ ). Each bar represents one subject in the study. NA indicates nonapplicable; PD, progressive disease; PR, partial response; SD, stable disease.

for response) had cerebral progression as their first site of progression.

Although one partial response was observed in the subgroup of patients pretreated with osimertinib ( $n = 9$ ), patients pretreated with osimertinib did fare worse than those without in terms of PFS ( $p = .00055$ ; log-rank test).

When considering the treatment line, patients receiving study treatment as first-line treatment showed a statistically longer PFS compared to later lines ( $p = .0001$ ; log-rank test).

Responses were observed across the entire spectrum of *EGFR* ex20ins mutations (Table 2). There were no differences in ORR within the near-loop and far-loop regions of exon 20. Only two patients harbored an *EGFR* ex20ins mutation within the helical region, with an ORR of 100%.

## Safety

The most common TRAEs were diarrhea (70%), rash (65%), dry skin (59%), paronychia (54%), and erythema (43%). Grade 3 TRAEs were reported in 54% of patients. Grade 3 TRAEs of  $\geq 10\%$  included diarrhea ( $n = 5$ ; 14%), rash ( $n = 5$ ; 14%), and dry skin ( $n = 5$ ; 14%). All TRAEs of any grade reported in 10% or more of patients or grade 3

or higher TRAEs are listed in Table 3. No grade 4 treatment-related toxicity was observed. One patient died as a result of respiratory failure after the first infusion of study medication, probably related to disease progression and possibly treatment related. Two other patients died during study treatment as a result of non-treatment-related events, coronavirus disease 2019 infection and cardiac arrest. Twenty-five patients (68%) required a dose reduction, including five patients (14%) who had two dose reductions. The rate of treatment discontinuation due to TRAEs was 16% ( $n = 6$ ), including one grade 3 allergic reaction after the first infusion of cetuximab.

## DISCUSSION

In this phase 2 trial, combination treatment with afatinib and cetuximab was effective for patients with *EGFR* ex20ins-mutated NSCLC, which resulted in a DCR of 54% after 18 weeks and a confirmed ORR of 32%. The median PFS was 5.5 months. Twenty-eight patients (76%) experienced a decrease in tumor size.

Multiple other TKIs, specifically designed to target *EGFR* ex20ins, have recently been tested in clinical trials. This led to the Food and Drug Administration approval of mobocertinib for patients harboring an *EGFR* ex20ins mutation who progressed on or after prior

**TABLE 2** Mutation type and response to treatment.

Insertion region	Mutation type	Best response	Best change from baseline according to RECIST, %	PFS, months
Helical region, <i>n</i> = 2, ORR 100%	p.M766_V768dup	PR	−30	5.5
	p.M766_V768dup	PR	−47	3.2
Near-loop region, <i>n</i> = 28, ORR 39%	p.A767_V769dup	SD	−11	19.6
	p.A767_V769dup	SD	−17	5.5
	p.A767_V769dup	PR	−56	8.5
	p.A767_V769dup	SD	−7	6.2
	p.S768_V769insMDS	PR	−81	5.5
	p.S768_D770dup	PR	−63	6.9
	p.S768_D770dup	SD	−8	3.7
	p.S768_D770dup	SD	7	9.7
	p.S768_D770dup	SD	−2	1.6
	p.S768_D770dup	SD	16	1.4
	p.S768_D770dup	SD	−26	5.5
	p.S768_D770dup	PR	−33	9.7
	p.S768_V769delinsL	NE	NE	0
	p.S768_V769delinsL	PR	−53	8.8
	p.S768_V769delinsPL	SD	−24	8.3
	p.V769_D770insGSV	PR	−62	18.0
	p.V769_D770insGG	PR	−45	1.6
	p.D770_N771insG	PD	NE	0
	p.D770_N771insG	PR	−47	12.0
	p.D770_N771insG	SD	NE <sup>a</sup>	12.7
p.D770_N771insG	PR	−39	2.8	
p.D770_P772dup	NE	NE	3.0	
p.D770_P772dup	PR	−43	7.8	
p.N771delinsGY	NE	NE	1.0	
p.N771_P772insRH	SD	15	3.7	
p.N771_P772insT	SD	−15	3.9	
p.N771delinsSH	PR	−36	9.7	
p.N771_H773dup	SD	−7	2.1	
Far-loop region, <i>n</i> = 7, ORR 43%	p.H773dup	PD	−68	1.4
	p.H773dup	SD	0	6.9
	p.H773dup	SD	−15	4.1
	p.H773delinsPNPY	PR	−49	9.2
	p.H773_V774insY	PR	−43	2.1
	p.H773_V774insAH	SD	−26	4.6
p.H773_V774insAH	PR	−100	3.7	

Abbreviations: NE, not evaluable; ORR, overall response rate; PD, progressive disease; PFS, progression-free survival; PR, partial response; RECIST, Response Evaluation Criteria in Solid Tumors; SD, stable disease.

<sup>a</sup>There was no measurable lesion conforming to RECIST at baseline.

**TABLE 3** Summary of TRAEs of any grade reported in 10% or more of patients or grade 3 or higher.

TRAE $\geq$ 10%	Patients, No. (%)			
	Total	Grade 1	Grade 2	Grade $\geq$ 3
Diarrhea	26 (70)	19 (51)	2 (5)	5 (14)
Rash <sup>a</sup>	24 (65)	8 (22)	11 (30)	5 (14)
Dry skin	22 (59)	10 (27)	7 (19)	5 (14)
Paronychia	20 (54)	9 (24)	10 (27)	1 (3)
Erythema multiforme	16 (43)	8 (22)	6 (16)	2 (5)
Fatigue	14 (38)	9 (24)	5 (14)	0 (0)
Hypertrichosis	13 (35)	11 (30)	2 (5)	0 (0)
Nausea	13 (35)	6 (16)	6 (16)	1 (3)
Anorexia	9 (24)	5 (14)	4 (11)	0 (0)
Mucositis	9 (24)	2 (5)	6 (16)	1 (3)
Dysgeusia	8 (22)	7 (19)	1 (3)	0 (0)
Pruritus	7 (19)	4 (11)	2 (5)	1 (3)
Dry mouth	6 (16)	6 (16)	0 (0)	0 (0)
Chills	5 (14)	4 (11)	1 (3)	0 (0)
Dry eye	5 (14)	4 (11)	1 (3)	0 (0)
Infusion-related reaction	5 (14)	0 (0)	5 (14)	0 (0)
Headache	4 (11)	2 (5)	2 (5)	0 (0)

Abbreviation: TRAE, treatment-related adverse event.

<sup>a</sup>A rash is defined as rash papulopustular, rash maculopapular, dermatitis and rash acneiform are RECIST definitions.

platinum-based chemotherapy. The ORR was 28% with a median PFS of 7.3 months.<sup>25,26</sup> Pozitotinib, another *EGFR* ex20ins-directed TKI, demonstrated a 14.8% ORR.<sup>27</sup> In addition, amivantamab, a bispecific antibody against *EGFR* and c-mesenchymal-epithelial transition factor (cMET), was active in pretreated patients with an ORR of 40% and a median PFS of 8.3 months.<sup>28</sup> Although progress has been made in the treatment of previously considered untargetable *EGFR* ex20ins mutations, the effectiveness of these new agents is not on the same level as the treatment options for classical *EGFR* mutations, and toxicity remains a major concern.

*EGFR* ex20ins mutations lack the therapeutic advantage of increased affinity for TKIs versus ATP. Therefore, these mutations have a small therapeutic window for *EGFR* TKIs, which results in high rates of typical *EGFR*-related toxicity. In our study, grade 3 or higher TRAEs were reported in 54% of all patients, mostly diarrhea and skin toxicity. As a result, 68% of patients required a dose reduction and 16% discontinued treatment because of adverse events. With close monitoring, dose reductions, and timely referral to a dermatologist, skin-related toxicity was generally manageable. However, this also clearly shows that adding an anti-*EGFR* mAb to afatinib enhances on-target side effects associated with the inhibition of *EGFR*. Previous

studies with TKI-antibody combinations already showed an increase in TRAEs, which resulted in more than 50% grade  $\geq$ 3 toxicity.<sup>18,29</sup>

In addition, other TKIs such as pozitotinib and mobocertinib, specifically designed to target *EGFR* ex20ins mutations, could not preserve selectivity against wild-type *EGFR*. During pozitotinib treatment, 28% and 26% of patients had grade  $\geq$ 3 rash and diarrhea TRAEs, respectively.<sup>27</sup> Results from the expanded access program showed 66% grade  $\geq$ 3 TRAEs.<sup>30</sup> These high toxicity rates led to a new trial to evaluate a lower dose and twice-daily dosing. Mobocertinib resulted in 46% grade  $\geq$ 3 TRAEs.<sup>26</sup> The toxicity of these new agents seems comparable to our study. It is possible that a lower starting dose of afatinib of 30 mg daily will lead to fewer serious adverse events while maintaining effectiveness.<sup>31</sup>

Most of the clinical trials regarding new *EGFR* ex20ins-directed therapies excluded patients with active or untreated brain metastases. Therefore, the intracranial activity of these agents is largely unknown. Regarding intracranial activity in our study, the majority of patients with brain metastases at baseline were untreated ( $n = 12$ ). Of all patients with brain metastases at baseline, intracranial efficacy was insufficient irrespective of extracranial efficacy, suggesting the need for brain radiotherapy before starting treatment with afatinib plus cetuximab.

Our study has several limitations, including the lack of a control arm and an independent blinded radiological review. In addition, no previous line of treatment was required. Patients treated with afatinib and cetuximab as first-line treatment showed a statistically longer PFS compared to later lines. Therefore, comparison to other predominantly second-line studies involving new *EGFR* ex20ins-directed targeted treatment options is difficult.

In conclusion, combination treatment with afatinib and cetuximab demonstrated antitumor activity in patients with *EGFR* ex20ins-positive NSCLC, with a DCR of 54% at 18 weeks and a 32% confirmed ORR. *EGFR*-related toxicity was significant, although manageable, after dose reduction.

## AUTHOR CONTRIBUTIONS

**Bianca A. M. H. van Veggel:** Formal analysis, data curation, investigation, project administration, visualization, and writing—original draft. **Anthonie J. van der Wekken:** Investigation and writing—review and editing. **Marthe S. Paats:** Investigation and writing—review and editing. **Lizza E. L. Hendriks:** Investigation and writing—review and editing. **Sayed M. S. Hashemi:** Investigation and writing—review and editing. **Antonios Daletzakis:** Formal analysis, validation, visualization, and writing—review and editing. **Daan van den Broek:** Investigation and writing—review and editing. **Linda J. W. Bosch:** Visualization and writing—review and editing. **Kim Monkhorst:** Investigation and writing—review and editing. **Egbert F. Smit:** Conceptualization, methodology, funding acquisition, investigation, supervision, and writing—review and editing. **Adrianus J. de Langen:** Conceptualization, methodology, funding acquisition, investigation, supervision, and writing—review and editing.



## ACKNOWLEDGMENTS

This work was supported by Boehringer Ingelheim and Merck BV, Schiphol-Rijk, the Netherlands, an affiliate of Merck KGaA (CrossRef Funder ID Number 10.13039/100009945). Boehringer Ingelheim had no role in the design, analysis, or interpretation of the study results. Boehringer Ingelheim was given the opportunity to review the manuscript for medical and scientific accuracy as well as intellectual property considerations. Merck KGaA, Darmstadt, Germany, reviewed the manuscript for medical accuracy only before manuscript submission. The authors are fully responsible for the content of this manuscript, and the views and opinions described in the publication reflect solely those of the authors.

## CONFLICT OF INTEREST STATEMENT

Anthonie J. van der Wekken reports fees paid to his institution for his role as an invited speaker from MEDtalks and for his role as a member of the committee that revised the Dutch guidelines on non-small cell lung cancer (NSCLC) and unknown primary tumors, as a member of the Dutch University Federation, and as a member of the committee of Dure Geneesmiddelen from the Federation of Medical Specialists; to his institution for his advisory board membership from Amgen, AstraZeneca, Bayer, Boehringer Ingelheim, Janssen, Eli Lilly, Merck, Novartis, Pfizer, Roche, and Takeda; to his institution for his role as an invited speaker from AstraZeneca; institutional research grants from AstraZeneca, Boehringer Ingelheim, Roche, Takeda, and Pfizer; institutional funding as a local principal investigator (PI) from Amgen, AstraZeneca, Blueprint Medicines, Merck Serono, Novartis, Nuvalent, Roche, Takeda, and TP Therapeutics; and nonremunerated roles as a board member of the oncology section of Nederlandse Vereniging van Artsen voor Longziekten en Tuberculose, as a member of the advisory group of Longkanker Nederland, and as a member of the scientific advisory group of ROS1ders; all were unrelated to this manuscript. Marthe S. Paats reports honoraria for lectures, presentations, and advisory boards for AstraZeneca, Bayer, Eli Lilly, Janssen, Novartis, Pfizer, Roche, and Takeda, all paid to her institution; all were unrelated to this manuscript. Lizza E. L. Hendriks reports personal fees were paid for being an invited speaker for Benecke, MEDtalks, Medimix, and VJOnco; personal fees for participation in a mentorship program funded by AstraZeneca; personal fees for travel support from Roche; personal fees as a member of the committee that revised the Dutch guidelines on NSCLC, brain metastases, and leptomeningeal metastases; fees paid to her institution for an educational webinar from Janssen; fees paid to her institution for advisory board membership from Amgen, Bristol-Myers Squibb, Boehringer Ingelheim, Janssen, Eli Lilly, Merck, Merck Sharp & Dohme, Novartis, Pfizer, Roche, and Takeda; fees paid to her institution as an invited speaker from AstraZeneca, Bayer, high5oncology, Eli Lilly, and Merck Sharp & Dohme; fees paid to her institution for interview sessions from Roche; fees paid to her institution for a podcast appearance from Takeda; institutional research grants from AstraZeneca, Boehringer Ingelheim, Roche, Takeda, Merck, and Pfizer (Novartis under negotiation); institutional funding as a local PI from AbbVie, AstraZeneca, Blueprint Medicines, Gilead,

GlaxoSmithKline, Merck Serono, Merck Sharp & Dohme, Mirati, Novartis, Roche, and Takeda; nonremunerated roles as chair for metastatic NSCLC of the lung cancer group for the European Organisation for Research and Treatment of Cancer and as the secretary of the studies foundation for Nederlandse Vereniging van Artsen voor Longziekten en Tuberculose; all were unrelated to this manuscript. Sayed M. S. Hashemi reports research grants and fees for advisory board participation were received from AstraZeneca, Boehringer Ingelheim, Bristol-Myers Squibb, Eli Lilly, Janssen, GlaxoSmithKline, Merck Sharp & Dohme, Novartis, Roche, and Takeda; all were unrelated to this manuscript. Kim Monkhurst reports consulting fees from Amgen, Bayer, and Eli Lilly; all were unrelated to this manuscript. Egbert F. Smit reports financial compensation to the institution for advisory board attendance and speaker engagements from AstraZeneca, Bayer, Bristol-Myers Squibb, DSI, Eli Lilly, Merck Sharp & Dohme, Merck, Novartis, Pfizer, Takeda, Regeneron, Roche Genentech, Roche Diagnostics, Boehringer Ingelheim, and Sanofi and research support from AstraZeneca, Bristol-Myers Squibb, Merck, and Merck Sharp & Dohme; all were unrelated to this manuscript. Adrianus J. de Langen reports grants from Bristol-Myers Squibb, Merck Sharp & Dohme, Boehringer Ingelheim, and AstraZeneca and nonfinancial support from Merck Serono and Roche; all were unrelated to this manuscript. The other authors declare no conflicts of interest.

## DATA AVAILABILITY STATEMENT

The data that support the findings of this study are available on request from the corresponding author but are not publicly available because of privacy/ethical restrictions.

## ORCID

Bianca A. M. H. van Veggel  <https://orcid.org/0000-0002-3223-1255>

## REFERENCES

1. Beau-Faller M, Prim N, Ruppert AM, et al. Rare EGFR exon 18 and exon 20 mutations in non-small-cell lung cancer on 10 117 patients: a multicentre observational study by the French ERMETIC-IFCT network. *Ann Oncol.* 2014;25(1):126-131. doi:10.1093/annonc/mdt418
2. Fang W, Huang Y, Hong S, et al. EGFR exon 20 insertion mutations and response to osimertinib in non-small-cell lung cancer. *BMC Cancer.* 2019;19(1):595. doi:10.1186/s12885-019-5820-0
3. Kosaka T, Tanizaki J, Paranal RM, et al. Response heterogeneity of EGFR and HER2 exon 20 insertions to covalent EGFR and HER2 inhibitors. *Cancer Res.* 2017;77(10):2712-2721. doi:10.1158/0008-5472.can-16-3404
4. Riess JW, Gandara DR, Frampton GM, et al. Diverse EGFR exon 20 insertions and co-occurring molecular alterations identified by comprehensive genomic profiling of NSCLC. *J Thorac Oncol.* 2018; 13(10):1560-1568. doi:10.1016/j.jtho.2018.06.019
5. Naidoo J, Sima CS, Rodriguez K, et al. Epidermal growth factor receptor exon 20 insertions in advanced lung adenocarcinomas: clinical outcomes and response to erlotinib. *Cancer.* 2015;121(18): 3212-3220. doi:10.1002/cncr.29493
6. Robichaux JP, Elamin YY, Tan Z, et al. Mechanisms and clinical activity of an EGFR and HER2 exon 20-selective kinase inhibitor in non-small cell lung cancer. *Nat Med.* 2018;24(5):638-646. doi:10.1038/s41591-018-0007-9

7. van Veggel B, Madeira RSJFV, Hashemi SMS, et al. Osimertinib treatment for patients with EGFR exon 20 mutation positive non-small cell lung cancer. *Lung Cancer*. 2020;141:9-13. doi:10.1016/j.lungcan.2019.12.013
8. Yang JC, Sequist LV, Geater SL, et al. Clinical activity of afatinib in patients with advanced non-small-cell lung cancer harbouring uncommon EGFR mutations: a combined post-hoc analysis of LUX-Lung 2, LUX-Lung 3, and LUX-Lung 6. *Lancet Oncol*. 2015;16(7):830-838. doi:10.1016/s1470-2045(15)00026-1
9. Yasuda H, Park E, Yun CH, et al. Structural, biochemical, and clinical characterization of epidermal growth factor receptor (EGFR) exon 20 insertion mutations in lung cancer. *Sci Transl Med*. 2013;5(216):216ra177. doi:10.1126/scitranslmed.3007205
10. Choudhury NJ, Schoenfeld AJ, Flynn J, et al. Response to standard therapies and comprehensive genomic analysis for patients with lung adenocarcinoma with EGFR exon 20 insertions. *Clin Cancer Res*. 2021;27(10):2920-2927. doi:10.1158/1078-0432.ccr-20-4650
11. Shah MP, Aredo JV, Padda SK, et al. EGFR exon 20 insertion NSCLC and response to platinum-based chemotherapy. *Clin Lung Cancer*. 2022;23(2):e148-e153.
12. Hendriks LE, Kerr KM, Menis J, et al. Oncogene-addicted metastatic non-small-cell lung cancer: ESMO clinical practice guideline for diagnosis, treatment and follow-up. *Ann Oncol*. 2023;34(4):339-357. doi:10.1016/j.annonc.2022.12.009
13. Yang JC, Schuler M, Popat S, et al. Afatinib for the treatment of NSCLC harboring uncommon EGFR mutations: a database of 693 cases. *J Thorac Oncol*. 2020;15(5):803-815. doi:10.1016/j.jtho.2019.12.126
14. Li S, Schmitz KR, Jeffrey PD, Wiltzius JJ, Kussie P, Ferguson KM. Structural basis for inhibition of the epidermal growth factor receptor by cetuximab. *Cancer Cell*. 2005;7(4):301-311. doi:10.1016/j.ccr.2005.03.003
15. Brand TM, Iida M, Wheeler DL. Molecular mechanisms of resistance to the EGFR monoclonal antibody cetuximab. *Cancer Biol Ther*. 2011;11(9):777-792. doi:10.4161/cbt.11.9.15050
16. Hasegawa H, Yasuda H, Hamamoto J, et al. Efficacy of afatinib or osimertinib plus cetuximab combination therapy for non-small-cell lung cancer with EGFR exon 20 insertion mutations. *Lung Cancer*. 2019;127:146-152. doi:10.1016/j.lungcan.2018.11.039
17. van Veggel B, de Langen AJ, Hashemi SMS, et al. Afatinib and cetuximab in four patients with EGFR exon 20 insertion-positive advanced NSCLC. *J Thorac Oncol*. 2018;13(8):1222-1226. doi:10.1016/j.jtho.2018.04.012
18. Goldberg SB, Redman MW, Lilenbaum R, et al. Randomized trial of afatinib plus cetuximab versus afatinib alone for first-line treatment of EGFR-mutant non-small-cell lung cancer: final results from SWOG S1403. *J Clin Oncol*. 2020;38(34):4076-4085. doi:10.1200/jco.20.01149
19. Janjigian YY, Smit EF, Groen HJ, et al. Dual inhibition of EGFR with afatinib and cetuximab in kinase inhibitor-resistant EGFR-mutant lung cancer with and without T790M mutations. *Cancer Discov*. 2014;4(9):1036-1045. doi:10.1158/2159-8290.cd-14-0326
20. van Veggel B, van der Wekken AJ, Paats M, et al. Interim results of a phase II single arm trial combining afatinib with cetuximab in patients with EGFR exon 20 insertion positive NSCLC. *J Clin Oncol*. 2021;39(suppl 15):9112. doi:10.1200/jco.2021.39.15\_suppl.9112
21. Eisenhauer EA, Therasse P, Bogaerts J, et al. New response evaluation criteria in solid tumours: revised RECIST guideline (version 1.1). *Eur J Cancer*. 2009;45(2):228-247. doi:10.1016/j.ejca.2008.10.026
22. World Medical Association. World Medical Association Declaration of Helsinki: ethical principles for medical research involving human subjects. *JAMA*. 2013;310(20):2191-2194.
23. Jung SH, Kim KM. On the estimation of the binomial probability in multistage clinical trials. *Stat Med*. 2004;23(6):881-896. doi:10.1002/sim.1653
24. Koyama T, Chen H. Proper inference from Simon's two-stage designs. *Stat Med*. 2008;27(16):3145-3154. doi:10.1002/sim.3123
25. Duke ES, Stapleford L, Drezner N, et al. FDA approval summary: mobocertinib for metastatic non-small cell lung cancer with EGFR exon 20 insertion mutations. *Clin Cancer Res*. 2023;29(3):508-512. doi:10.1158/1078-0432.ccr-22-2072
26. Zhou C, Ramalingam SS, Kim TM, et al. Treatment outcomes and safety of mobocertinib in platinum-pretreated patients with EGFR exon 20 insertion-positive metastatic non-small cell lung cancer: a phase 1/2 open-label nonrandomized clinical trial. *JAMA Oncol*. 2021;7(12):e214761. doi:10.1001/jamaoncol.2021.4761
27. Le X, Goldman JW, Clarke JM, et al. Poziotinib shows activity and durability of responses in subgroups of previously treated EGFR exon 20 NSCLC patients. *J Clin Oncol*. 2020;38(suppl 15):9514. doi:10.1200/jco.2020.38.15\_suppl.9514
28. Park K, Haura EB, Leighl NB, et al. Amivantamab in EGFR exon 20 insertion-mutated non-small-cell lung cancer progressing on platinum chemotherapy: initial results from the CHRYSALIS phase I study. *J Clin Oncol*. 2021;39(30):3391-3402. doi:10.1200/jco.21.00662
29. Cortot AB, Madroszyk A, Giroux-Leprieur E, et al. First-line afatinib plus cetuximab for EGFR-mutant non-small cell lung cancer: results from the randomized phase II IFCT-1503 ACE-Lung study. *Clin Cancer Res*. 2021;27(15):4168-4176. doi:10.1158/1078-0432.ccr-20-4604
30. Prelaj A, Bottiglieri A, Proto C, et al. Poziotinib for EGFR and HER2 exon 20 insertion mutation in advanced NSCLC: results from the expanded access program. *Eur J Cancer*. 2021;149:235-248. doi:10.1016/j.ejca.2021.02.038
31. Yang CJ, Tsai MJ, Hung JY, et al. The clinical efficacy of afatinib 30 mg daily as starting dose may not be inferior to afatinib 40 mg daily in patients with stage IV lung adenocarcinoma harboring exon 19 or exon 21 mutations. *BMC Pharmacol Toxicol*. 2017;18(1):82. doi:10.1186/s40360-017-0190-1

**How to cite this article:** van Veggel BAMH, van der Wekken AJ, Paats MS, et al. A phase 2 trial combining afatinib with cetuximab in patients with EGFR exon 20 insertion-positive non-small cell lung cancer. *Cancer*. 2024;130(5):683-691. doi:10.1002/cncr.35090