



**Universiteit  
Leiden**  
The Netherlands

**Ambiguous melanocytic lesions: A retrospective cohort study of incidence and outcome of melanocytic tumor of uncertain malignant potential (MELTUMP) and superficial atypical melanocytic proliferation of uncertain significance (SAMPUS) in the Netherlands**

Vermarien-Wang, J.; Doeleman, T.; Doorn, R. van; Mooyaart, A.L.; Blokk, W.A.M.; Schrader, A.M.R.

**Citation**

Vermarien-Wang, J., Doeleman, T., Doorn, R. van, Mooyaart, A. L., Blokk, W. A. M., & Schrader, A. M. R. (2023). Ambiguous melanocytic lesions: A retrospective cohort study of incidence and outcome of melanocytic tumor of uncertain malignant potential (MELTUMP) and superficial atypical melanocytic proliferation of uncertain significance (SAMPUS) in the Netherlands. *Journal Of The American Academy Of Dermatology*, 88(3), 602-608. doi:10.1016/j.jaad.2022.11.019

Version: Publisher's Version  
License: [Creative Commons CC BY 4.0 license](https://creativecommons.org/licenses/by/4.0/)  
Downloaded from: <https://hdl.handle.net/1887/3720769>

**Note:** To cite this publication please use the final published version (if applicable).

---

# Ambiguous melanocytic lesions: A retrospective cohort study of incidence and outcome of melanocytic tumor of uncertain malignant potential (MELTUMP) and superficial atypical melanocytic proliferation of uncertain significance (SAMPUS) in the Netherlands



Jiahe Vermariën-Wang, MSc,<sup>a</sup> Thom Doeleman, MSc,<sup>a</sup> Remco van Doorn, MD, PhD,<sup>b</sup> Antien L. Mooyaart, MD, PhD,<sup>c</sup> Willeke A. M. Blokkx, MD, PhD,<sup>d</sup> and Anne M. R. Schrader, MD, PhD<sup>a</sup>

**Background:** Melanocytic tumor of uncertain malignant potential (MELTUMP) and superficial atypical melanocytic proliferation of uncertain significance (SAMPUS) are descriptive and provisional terms for melanocytic tumors with ambiguous histopathological features that are not easily classified as either benign or malignant.

**Objective:** To investigate the incidence and clinical outcome of MELTUMP and SAMPUS in the Netherlands.

**Methods:** In this retrospective cohort study, we reviewed all diagnoses of MELTUMP and SAMPUS from the Dutch Nationwide Pathology Databank from 1991 to October 1, 2021. Clinical outcome was studied for cases diagnosed until October 1, 2018.

**Results:** A total of 1685 MELTUMP and 1957 SAMPUS were identified with an annual incidence of 150 to 300 cases. Metastatic behavior was seen in 0.7% of all initially diagnosed MELTUMP. All SAMPUS remained free of metastases.

**Limitations:** Reassessment of pathology slides and confirmation of clonality between primary and metastatic lesions remained outside the scope of this study.

**Conclusion:** Despite the ‘uncertainty’ in the nomenclature, our results demonstrate a low malignant potential for MELTUMP and no malignant potential for SAMPUS. We emphasize the importance of consultation for ambiguous melanocytic lesions and to limit the MELTUMP/SAMPUS terminology to legitimately uncertain or unclassifiable cases. (J Am Acad Dermatol 2023;88:602-8.)

**Key words:** incidence; melanocytic lesions; MELTUMP; metastasis; outcome; SAMPUS; the Netherlands.

---

From the Department of Pathology, Leiden University Medical Center, Leiden, the Netherlands<sup>a</sup>; Department of Dermatology, Leiden University Medical Center, Leiden, the Netherlands<sup>b</sup>; Department of Pathology, Erasmus Medical Center Cancer Institute, Rotterdam, the Netherlands<sup>c</sup>; and Department of Pathology, Division of Laboratories, Pharmacy and Biomedical Genetics, University Medical Center Utrecht, Utrecht, the Netherlands.<sup>d</sup>

Drs Vermariën-Wang and Doeleman are joint first authors.

Funding sources: None.

IRB approval status: Not applicable. The authors conform to the updated “Code of Conduct for Health Research”, as stated by the Committee on Regulation of Health Research (COREON, 2022).

---

Patient consent: Not applicable.

Accepted for publication November 9, 2022.

Reprints not available from the authors.

Correspondence to: Thom Doeleman, MSc, Department of Pathology, Leiden University Medical Center Albinusdreef 2, 2333 ZA, Leiden, the Netherlands. E-mail: [t.doeleman@lumc.nl](mailto:t.doeleman@lumc.nl).

Published online November 18, 2022.

0190-9622

© 2022 by the American Academy of Dermatology, Inc. Published by Elsevier Inc. This is an open access article under the CC BY license (<http://creativecommons.org/licenses/by/4.0/>).

<https://doi.org/10.1016/j.jaad.2022.11.019>

## INTRODUCTION

To this day, histopathological examination remains the gold standard for diagnosis and classification of melanocytic lesions. Making the distinction between nevus and melanoma has far reaching consequences for patient management.<sup>1</sup> In most cases, by carefully considering several histomorphological characteristics, aided if necessary by immunohistochemical and molecular tests, the pathologist is able to make a clear-cut diagnosis.

Unfortunately, histopathology of melanocytic lesions is not always straightforward, as a significant subset of lesions show ambiguous features, not allowing definitive classification.<sup>2</sup> Even among experienced dermatopathologists, there is moderate interobserver ( $\kappa = 0.42$ ) and intraobserver agreement ( $\kappa = 0.57$ ) for melanocytic skin lesions, and particularly low accuracy of 25%-43% for diagnoses in the middle of the histopathologic spectrum between nevus and melanoma.<sup>3</sup> In order to address the difficult cases with ambiguous histology, provisional descriptive terms were introduced in 2004, including 'melanocytic tumor of uncertain malignant potential' (MELTUMP) and 'superficial atypical melanocytic proliferation of uncertain significance' (SAMPUS). The former indicates tumorigenic lesions with a (deeper) dermal component and the latter is reserved for thin, non-tumorigenic lesions that are confined to the epidermis and papillary dermis.<sup>4,5</sup> MELTUMP and SAMPUS do not reflect distinct entities and simply have in common a degree of cytoarchitectural atypia exceeding what is acceptable for nevi, yet insufficient to justify a melanoma diagnosis.<sup>5,6</sup> Not surprisingly, such a descriptive diagnosis poses problems for clinical management, potentially contributing to both under- and overtreatment. To avoid confusion to clinicians, it is emphasized that the acronyms should be written out in full and the differential diagnosis and applicable microstaging attributes should be supplied.<sup>4</sup>

Experts have proposed practical recommendations for the management of these ambiguous lesions. For

instance, seeking second opinion is strongly advised, preferably in a referral center.<sup>1,7</sup> The Dutch guidelines state that all resection margins should be free of

MELTUMP, preferably with excision margins ranging from 5 to 10 mm.<sup>7</sup> Nevertheless, due to their uncertain biological behavior, it remains a challenge to predict prognosis and define optimal treatment.

Currently, it is unknown how many lesions are described as MELTUMP or SAMPUS and how many of these lesions show local recurrence or metastatic behavior. Therefore, the primary aim of this study was to investigate the incidence and clinical course of MELTUMP and SAMPUS in the Netherlands. In addition, we aimed to assess how often these lesions received second opinion consultation following the current Dutch guidelines.

## CAPSULE SUMMARY

- It remains a challenge to predict prognosis and define optimal treatment for melanocytic tumor of uncertain malignant potential and superficial atypical melanocytic proliferation of uncertain significance.
- Metastatic behavior was only seen in 0.7% of melanocytic tumor of uncertain malignant potential whereas superficial atypical melanocytic proliferation of uncertain significance remained free of metastases. We emphasize the importance of consultation and to limit melanocytic tumor of uncertain malignant potential/superficial atypical melanocytic proliferation of uncertain significance terminology to cases with legitimate diagnostic uncertainty.

## METHODS

This observational retrospective cohort study used data provided by Pathologisch Anatomisch Landelijk Geautomatiseerd Archief (PALGA): the Dutch Nationwide Pathology Databank.<sup>8</sup> All pathology report excerpts until October 1, 2021 containing the descriptive terms MELTUMP or SAMPUS or their unabbreviated equivalents in the conclusion or the PALGA encoding of the report were requested, including excerpts regarding melanoma history and progression. A total of 9039 anonymized excerpts were assessed for inclusion by either JV or TD. All cases that were unclear in their conclusion or demonstrated local recurrence or metastatic behavior were discussed together by JV, TD, and AS until consensus was reached.

From the included cases, clinical parameters and evidence of consultation were collected which included consultation from a colleague in the same department, a regional melanoma panel, or an external expert pathologist. Cases were excluded when they received an unambiguous diagnosis (either benign, intermediate, or malignant) after consultation, including intermediate cases assigned to a specific World Health Organization (WHO)-defined evolutionary pathway.

*Abbreviations used:*

MELTUMP:	melanocytic tumor of uncertain malignant potential
SAMPUS:	superficial atypical melanocytic proliferation of uncertain significance
WHO:	World Health Organization

All MELTUMP and SAMPUS with a minimum follow-up period of 3 years were assessed for recurrence or metastasis. Full microscopy reports were obtained for progressive cases. The protocol for data collection and categorization can be found as Supplementary Table I, available via Mendeley at <https://data.mendeley.com/datasets/pcxm4wk57j/1>. Analyses were performed using IBM SPSS Statistics version 25 (IBM) and Microsoft Excel version 2108 (Microsoft). The authors conform to the updated “Code of Conduct for Health Research”, as stated by the Committee on Regulation of Health Research (COREON, 2022).

**RESULTS****Demographics and consultation frequency**

From the obtained pathology report excerpts, a total of 3997 primary cutaneous melanocytic lesions with a diagnosis or differential diagnosis of MELTUMP and SAMPUS were identified. For 355 of these lesions, the (differential) diagnosis of MELTUMP or SAMPUS was rejected after second opinion consultation and these cases were excluded from further analysis. The remaining 3642 lesions received a final diagnosis of MELTUMP ( $n = 1685$ ; 46.3%) or SAMPUS ( $n = 1957$ ; 53.7%). From these lesions, 927 (25.5%) had been sent to an expert pathologist for external consultation, 1006 (27.6%) received another form of consultation, eg, from a colleague in the same department or from a melanoma panel, and 1709 (46.9%) were diagnosed without recorded evidence of consultation.

The 3642 lesions diagnosed as MELTUMP or SAMPUS belonged to 3535 individual patients (Table I). Most patients ( $n = 3452$ ; 97.7%) had 1 lesion and a maximum of 5 lesions was present in 3 patients. The study population was predominantly female ( $n = 2173$ ; 59.7%) and most of the lesions occurred on the trunk ( $n = 1814$ ; 49.8%). There was a medical history of melanoma in 14.8% of MELTUMP ( $n = 250$ ) and in 23.0% of SAMPUS ( $n = 451$ ).

**Incidence**

The first cases of MELTUMP and SAMPUS in the Netherlands were diagnosed in 2006 and 2011,

respectively (Fig 1). After an upward trend, the incidence of MELTUMP stabilized at around 150 diagnoses per year from 2012 and onwards. The incidence of SAMPUS continued to increase until 2016, reaching a peak at around 300 diagnoses per year, after which it started to show a decreasing trend from 2019 and onwards.

**Recurrence and progression**

Disease course was studied for all cases with a minimum follow-up period of 3 years ( $n = 2692$ ). In total, 44 of 2692 lesions (1.6%), including 29 MELTUMP and 15 SAMPUS, showed evidence of local recurrence, local progression to melanoma, or metastatic behavior. Remarkably, in over half of these cases, the diagnosis of MELTUMP ( $n = 11$ ) and SAMPUS ( $n = 12$ ) was retrospectively made during reassessment of a previously diagnosed benign lesion after local recurrence or progression had already occurred. Also, 2 MELTUMP cases were excised and diagnosed after detection of lymph node or visceral metastasis. In order to determine the risk of progression for lesions with an initial diagnosis of SAMPUS or MELTUMP without already present clinically progressive behavior, these cases were excluded from further analysis.

In total, 19 of 2667 cases (0.7%) with an initial diagnosis of MELTUMP (16/1248; 1.3%) or SAMPUS (3/1419; 0.2%) demonstrated local recurrence, local progression to melanoma, or metastatic behavior (Table II). The median time to recurrence or progression was 33.0 (range, 4.7 to 97.7) months. In 14 of these cases (74%), the diagnosis was made after consultation. MELTUMP and SAMPUS with evidence of recurrence or progression were more often located in the head and neck region (42.1%) than cases without progression (6.3%). There was no obvious difference in age at diagnosis or gender between patients with and without recurrence or progression.

Local recurrence or local progression to melanoma was seen in 10 cases, including one MELTUMP with local progression to desmoplastic melanoma that, despite consultation at time of diagnosis, was later considered to be a ‘missed’ melanoma, as desmoplastic melanoma was found during reassessment of the primary lesion. Metastatic behavior was seen in 9 of 1248 (0.7%) MELTUMP, consisting of lymph node metastasis in 8 cases and distant metastasis in only 1 case. Satellitosis or in transit metastases were not detected. None of 1419 (0%) SAMPUS demonstrated any form of metastatic behavior.

In 16 of the 19 cases with recurrence or progression, resection margins were free of the lesion after

**Table I.** Demographics of melanocytic tumor of uncertain malignant potential and superficial atypical melanocytic proliferation of uncertain significance in the Netherlands until October 1, 2021

	MELTUMP	SAMPUS	Total
No. of lesions	1685	1957	3642
No. of patients	1656	1894	3535*
No. of patients with (%)			
1 lesion	1630 (98.4)	1847 (97.5)	3452 (97.7)*
2 lesions	23 (1.4)	38 (2.0)	69 (2.0)*
3 lesions	3 (0.2)	4 (0.2)	7 (0.2)*
4 lesions	0	3 (0.2)	4 (0.1)*
5 lesions	0	2 (0.1)	3 (0.1)*
Mean age at diagnosis, in y (SD)	47.2 (17.5)	51.9 (17.1)	49.7 (17.5)
Sex, n (%)			
Male	675 (40.1)	794 (40.6)	1469 (40.3)
Female	1010 (59.9)	1163 (59.4)	2173 (59.7)
Location, n (%)			
Head and neck	127 (7.5)	110 (5.6)	237 (6.5)
Trunk, including genitals	790 (46.9)	1024 (52.3)	1814 (49.8)
Upper extremities	311 (18.5)	353 (18.0)	664 (18.2)
Lower extremities	434 (25.8)	452 (23.1)	886 (24.3)
Unknown	23 (1.4)	18 (0.9)	41 (1.1)
Consultation frequency, n (%)	1049 (62.3)	884 (45.2)	1933 (53.1)

MELTUMP, Melanocytic tumor of uncertain malignant potential; SAMPUS, superficial atypical melanocytic proliferation of uncertain significance.

\*Includes patients with melanocytic tumor of uncertain malignant potential and/or superficial atypical melanocytic proliferation of uncertain significance.

primary excision ( $n = 5$ ) or re-excision ( $n = 11$ ). The remaining 3 cases had positive resection margins, even after a re-excision was performed in 2 of these cases, including the missed desmoplastic melanoma in which the resection margins were erroneously regarded as free of tumor.

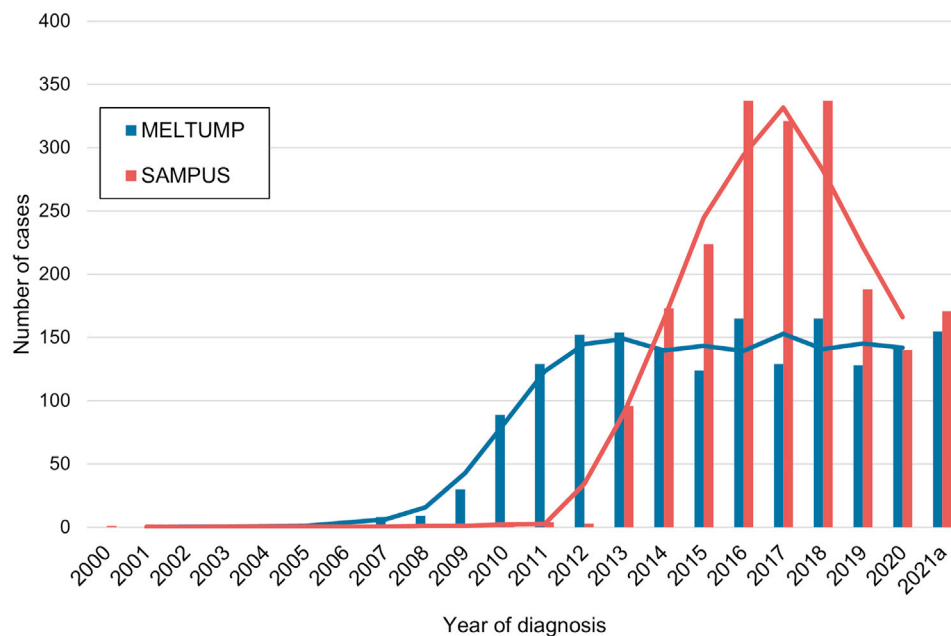
## DISCUSSION

In this study, we investigated the incidence and outcome of MELTUMP and SAMPUS in the Netherlands using data from PALGA: the Dutch Nationwide Pathology Databank from 1991 to October 1, 2021.

MELTUMP and SAMPUS terminology was introduced by Elder and Xu in 2004,<sup>5</sup> but these definitions have only been included in the WHO Classification of Tumours in the fourth edition of 2018.<sup>4</sup> Nonetheless, the terminology of MELTUMP and SAMPUS was used for the first time in the Netherlands in 2006 and 2011, respectively. Hereafter, the incidence of MELTUMP steadily increased, reaching a stable incidence of around 150 cases per year, while the incidence of SAMPUS demonstrated a peak in 2016 to 2018 of around 300 cases per year. The use of MELTUMP and SAMPUS terminology could be explained by the increased awareness and recognition of this nomenclature after being studied by Cerroni and colleagues<sup>2</sup> and

the International Melanoma Pathology Study Group,<sup>9</sup> as well as adoption of MELTUMP in the Dutch National Melanoma Guideline in 2012.<sup>10</sup> The decreasing trend in incidence for SAMPUS after 2018 might have resulted from the introduction of intermediate lesion/melanocytoma in the fourth edition of the WHO Classification of Skin Tumours,<sup>4</sup> although this is not reflected in the incidence of MELTUMP.

Importantly, the terminology of MELTUMP and SAMPUS is not used in a universal manner. For some, MELTUMP encompasses lesions from dysplastic nevi and atypical Spitz tumors to possible nevoid melanomas.<sup>5,11</sup> Others, as the 2018 WHO Classification proposes, define MELTUMP/SAMPUS simply as melanocytic proliferations that lack criteria to distinguish between benign and malignant.<sup>1,4</sup> This phenomenon of varying definitions is reflected in previous research that found poor interobserver agreement for MELTUMP.<sup>2</sup> Therefore, some authors have cautioned against the use of such descriptive provisional terms.<sup>12,13</sup> In line with the fourth edition of the WHO Classification of Skin Tumours,<sup>4</sup> more specific diagnoses of ambiguous lesions can be obtained in a percentage of cases with the help of molecular analysis, eg, as melanocytoma or intermediate lesion of a specific pathway, although uncertain and confusing results do occur. Nevertheless, we believe



**Fig 1.** Annual incidence of melanocytic tumor of uncertain malignant potential (MELTUMP) and superficial atypical melanocytic proliferation of uncertain significance (SAMPUS) in the Netherlands. The bars show the number of cases diagnosed per year. The first initial diagnoses of MELTUMP and SAMPUS were made in 2006 and 2011, respectively. Additionally, the diagnosis of MELTUMP or SAMPUS was made retrospectively in 23 cases during reassessment of a previously benign lesion because disease progression had occurred. This resulted in a first diagnosis of SAMPUS in 2000 and MELTUMP in 2003. The lines show the moving average per diagnosis with a 3-year window centered on the corresponding year. <sup>a</sup>Since data inclusion ended October 1, 2021, counts for 2021 were multiplied by  $1\frac{1}{3}$  to get an estimate of the total number of cases for 2021. MELTUMP, Melanocytic tumor of uncertain malignant potential; SAMPUS, superficial atypical melanocytic proliferation of uncertain significance.

that this molecular approach will continue to supplant use of MELTUMP and SAMPUS terminology in the future, as genetic subtyping becomes more widely used.

Although recommended in the WHO classification system, the MELTUMP and SAMPUS acronyms were not written out in full in 46 (31%) of a random sample of 150 cases from our dataset. In addition, a differential diagnosis was only provided in 27 (18%) of the 150 cases and, when applicable, microstaging attributes for melanoma were hardly ever supplied. In case provided, the differential diagnosis of MELTUMP predominantly consisted of melanoma and, less commonly, compound melanocytic nevus with reactive changes, melanoma in situ with compound melanocytic nevus, combined melanocytic nevus, and spitzoid tumor of uncertain malignant potential. For SAMPUS, the differential diagnosis variably included compound melanocytic nevus with or without reactive changes, recurrent melanocytic nevus, traumatized melanocytic nevus, pigmented spindle cell nevus of Reed, Spitz nevus

with reactive changes, nested melanoma, and spitzoid melanoma.

Despite the ambiguous morphology, in only 53.1% of cases described as MELTUMP or SAMPUS, the diagnosis was made after recorded evidence of consultation from either a departmental colleague, regional melanoma panel, or an expert consultant pathologist. This percentage is lower than we anticipated, as it is recommended by the Dutch guidelines to request a second assessment by a fellow pathologist for all MELTUMP, possibly followed by consultation with an external expert pathologist.<sup>7</sup> In this study, no clear difference was observed in consultation frequency before and after introduction of these guidelines in 2012 (data not shown). Possibly, our observed frequency of consultation represents an underestimation as consultations might not always be recorded in the conclusion text or PALGA coding lines of the pathology report. Nevertheless, we propose that in all ambiguous melanocytic lesions, an expert pathologist should be consulted.

**Table II.** Local recurrence and metastatic behavior of melanocytic tumor of uncertain malignant potential and superficial atypical melanocytic proliferation of uncertain in the Netherlands

	MELTUMP <i>n</i> = 1248	SAMPUS <i>n</i> = 1419	Total <i>n</i> = 2667
No evidence of recurrence or progression, <i>n</i> (%)	1232 (98.7%)	1416 (99.8%)	2648 (99.3%)
Local recurrence			
recurrence as MELTUMP/SAMPUS/melanoma in situ, <i>n</i>	3	3	6
recurrence with progression to melanoma, <i>n</i>	4*	0	4
Metastatic behavior			
satellite or in-transit metastasis, <i>n</i>	0	0	0
lymph node metastasis, <i>n</i>	8	0	8
distant metastasis, <i>n</i>	1	0	1
Median follow-up time in months (min-max)	87 (36-179)	61 (36-124)	69 (36-179)
Median time to recurrence or metastasis in months (min-max)	34 (5-98)	23 (6-39)	33 (5-98)

Only progressive cases with initial diagnosis of MELTUMP or SAMPUS and a minimum follow-up period of 3 years were included.

MELTUMP, Melanocytic tumor of uncertain malignant potential; SAMPUS, superficial atypical melanocytic proliferation of uncertain significance.

\*Includes one missed desmoplastic melanoma.

Since 2012, the Dutch guidelines state that all resection margins should be free of MELTUMP, preferably with excision margins ranging from 5 to 10 mm.<sup>10</sup> For SAMPUS, no official guidelines exist, but local practices are often similar to MELTUMP. In this clinical setting, the results from PALGA demonstrated local recurrence or progression in only 1.3% of MELTUMP and 0.2% of SAMPUS. Metastatic behavior was observed in only 0.7% of MELTUMP and in 0% of SAMPUS. The latter is consistent with the presumed lack of competence for metastasis of SAMPUS when the term was first proposed.<sup>5</sup> Remarkably, MELTUMP and SAMPUS with recurrence or progression were more often located in the head and neck region (42.1%) compared with cases without progression (6.3%). The percentage of metastasis for MELTUMP in our study is much lower than reported in a previous single center study from Denmark including 67 MELTUMP patients with a risk of nodal metastasis of 6% and a risk of distant metastasis of 1%.<sup>14</sup> A retrospective evaluation of MELTUMP treated in a single tertiary plastic surgery unit in the United Kingdom revealed nodal and distant metastases in 2 out of 42 patients (5%).<sup>15</sup> However, our risk of 0.7% for metastatic behavior in MELTUMP is equal to the risk for metastases reported for spitzoid tumor of uncertain malignant potential, that was determined in another nationwide study from the Netherlands using PALGA data.<sup>16</sup> Therefore, our results emphasize that ambiguous lesions ‘with uncertain malignant potential’ in fact have a low malignant potential.

Consistent with the European Society of Pathology (ESP)-European Organisation for Research and Treatment of Cancer (EORTC)-

European Rare Adult Cancer Network (EURACAN) guidelines,<sup>1</sup> we prefer the use of low-grade and high-grade intermediate lesion/melanocytoma instead of MELTUMP or SAMPUS for lesions with conflicting criteria to distinguish between nevus and melanoma. The terminology of MELTUMP/SAMPUS should be limited to cases with restrictions in the diagnostic process, such as tissue artifacts or failed molecular analysis, as these cases cannot be properly classified and have a true ‘uncertain malignant potential’ as well as for melanocytic lesions with legitimate diagnostic uncertainty. The pathologist should employ due diligence to keep the number of “uncertain” lesions at a minimum.

To our knowledge, this study is the first to report nationwide incidence, consultation frequency, and outcome of MELTUMP and SAMPUS, providing robust data on these ambiguous melanocytic lesions. However, it must be emphasized that our study reflects real-world usage of the MELTUMP and SAMPUS terminology and that the cases included were not centrally reviewed. Also, regarding outcome, we cannot rule out local recurrence or progression that is not documented within the PALGA database, eg, in case the metastases were not histologically confirmed or the histopathological assessment took place outside the Netherlands. Also, the minimal follow-up duration of 3 years (median 69 months) may not be sufficiently long for metastasis to develop. Additionally, for all MELTUMP cases with alleged metastases, the presence of clinically undetected melanoma as the origin of the metastases cannot be excluded. In order to obtain supporting evidence for true lymph node and distal metastasis of MELTUMP cases, ideally, clonal relationship analysis

should be performed. Reassessment of the pathology slides and confirmation of clonality between primary and metastatic lesions remained outside the scope of this study.

## CONCLUSIONS

In total, 3642 primary cutaneous melanocytic lesions have been diagnosed as MELTUMP or SAMPUS in the Netherlands until October 1, 2021. In a small majority (53.1%), the diagnosis was made after consultation. Despite the ‘uncertainty’ in the nomenclature, metastatic behavior was only observed in 0.7% of MELTUMP, reflecting a low malignant potential, and in 0% of SAMPUS, reflecting no malignant potential. We emphasize the importance of consultation for ambiguous melanocytic lesions and to limit the MELTUMP/SAMPUS terminology to legitimately uncertain or unclassifiable cases.

Doeleman had full access to all of the data in the study and takes responsibility for the integrity of the data and the accuracy of the data analysis.

## Conflicts of interest

None disclosed.

## REFERENCES

- de la Fouchardiere A, Blokx W, van Kempen LC, et al. ESP, EORTC, and EURACAN Expert Opinion: practical recommendations for the pathological diagnosis and clinical management of intermediate melanocytic tumors and rare related melanoma variants. *Virchows Arch*. 2021;479(1):3-11. <https://doi.org/10.1007/s00428-020-03005-1>
- Cerroni L, Barnhill R, Elder D, et al. Melanocytic tumors of uncertain malignant potential: results of a tutorial held at the XXIX Symposium of the International Society of Dermatopathology in Graz, October 2008. *Am J Surg Pathol*. 2010;34(3):314-326. <https://doi.org/10.1097/PAS.0b013e3181cf7fa0>
- Elmore JG, Barnhill RL, Elder DE, et al. Pathologists' diagnosis of invasive melanoma and melanocytic proliferations: observer accuracy and reproducibility study. *BMJ*. 2017;357:j2813. <https://doi.org/10.1136/bmj.j2813>
- Elder DE, Massi D, Scolyer RA, Willemze R. WHO classification of skin tumours. International Agency for Research on Cancer; 2018.
- Elder DE, Xu X. The approach to the patient with a difficult melanocytic lesion. *Pathology*. 2004;36(5):428-434. <https://doi.org/10.1080/00313020412331283905>
- Abraham RM, Karakousis G, Acs G, et al. Lymphatic invasion predicts aggressive behavior in melanocytic tumors of uncertain malignant potential (MELTUMP). *Am J Surg Pathol*. 2013;37(5):669-675. <https://doi.org/10.1097/PAS.0b013e318288ff47>
- Richtlijn Melanoom Federatie Medisch Specialisten. Nederlandse Melanoom Werkgroep, 2019. Accessed March 25, 2022. <https://richtlijndatabase.nl/richtlijn/melanoom/pathologie.html>
- Casparie M, Tiebosch AT, Burger G, et al. Pathology databanking and biobanking in The Netherlands, a central role for PALGA, the nationwide histopathology and cytopathology data network and archive. *Cell Oncol*. 2007;29(1):19-24. <https://doi.org/10.1155/2007/971816>
- Barnhill RL, Cerroni L, Cook M, et al. State of the art, nomenclature, and points of consensus and controversy concerning benign melanocytic lesions: outcome of an international workshop. *Adv Anat Pathol*. 2010;17(2):73-90. <https://doi.org/10.1097/PAP.0b013e3181cfe758>
- Landelijke Richtlijn Melanoom, Versie: 2.0. Nederlandse Melanoom Werkgroep, 2012. Accessed March 25, 2022. <https://www.huidziekten.nl/richtlijnen/richtlijn-melanoom-2012.pdf>
- Piscioli F, Pusioli T, Roncati L. Diagnostic disputes regarding atypical melanocytic lesions can be solved by using the term MELTUMP. *Turk Patoloji Derg*. 2016;32(1):63-64.
- Hookerman BJ. Dermatopathology: an abridged compendium of words. A discussion of them and opinions about them. Part 7 (M-O). *Dermatol Pract Concept*. 2015;5(1):1-9. <https://doi.org/10.5826/dpc.0501a01>
- Hurt MA. Diagnosis!(not prognosis, not potential, not risk). *Am J Dermatopathology*. 2009;31(8):763-765.
- Kaltoft B, Hainau B, Lock-Andersen J. Melanocytic tumour with unknown malignant potential—a Danish study of 67 patients. *Melanoma Res*. 2015;25(1):64-67. <https://doi.org/10.1097/CMR.000000000000130>
- Green RJ, Taghizadeh R, Lewis CJ, Lawrence C, Husain A, Ahmed O. Melanocytic tumours of uncertain malignant potential (MELTUMPs)—a diagnostic and management dilemma. *Eur J Plast Surg*. 2015;38(1):13-16.
- Ruijter CGH, Ouwerkerk W, Jaspars EH, et al. Incidence and outcome of Spitzoid tumour of unknown malignant potential (STUMP): an analysis of cases in the Netherlands from 1999 to 2014. *Br J Dermatol*. 2020;183(6):1121-1123. <https://doi.org/10.1111/bjd.19383>