



**Universiteit
Leiden**
The Netherlands

No NFATC2 fusion in simple bone cyst of the jaw

Ong, S.L.M.; Gomes, I.P.; Baelde, H.J.; Passador-Santos, F.; Andrade, B.A.B. de; Bruijn, I.H.B.D.; ... ; Bovee, J.V.M.G.

Citation

Ong, S. L. M., Gomes, I. P., Baelde, H. J., Passador-Santos, F., Andrade, B. A. B. de, Bruijn, I. H. B. D., ... Bovee, J. V. M. G. (2023). No NFATC2 fusion in simple bone cyst of the jaw. *Histopathology*, 83(2), 326-329. doi:10.1111/his.14905

Version: Publisher's Version








License: [Creative Commons CC BY 4.0 license](#)

Downloaded from: <https://hdl.handle.net/1887/3715545>

Note: To cite this publication please use the final published version (if applicable).

SHORT REPORT

No NFATC2 fusion in simple bone cyst of the jaw

Sheena L M Ong,¹  Isadora P Gomes,²  Hans J Baelde,¹  Fabricio Passador-Santos,³
Bruno A B de Andrade,⁴ Inge H Briaire-de Bruijn,¹  Israel L Cavalcante,⁴
Willem H Schreuder,⁵ Anne-Marie Cleton-Jansen,¹  Arjen H G Cleven,^{1,6} 
Karoly Szuhai,⁷  Carolina C Gomes² & Judith V M G Bovée¹ 

¹Department of Pathology, Leiden University Medical Center, Leiden, The Netherlands, ²Department of Pathology, Biological Science Institute (ICB), Universidade Federal de Minas Gerais (UFMG), Belo Horizonte, ³Oral Pathology, São Leopoldo Mandic Institute and Research Center, Campinas, ⁴Department of Oral Diagnosis and Pathology, School of Dentistry, Universidade Federal do Rio de Janeiro (UFRJ), Rio de Janeiro, Brazil, ⁵Department of Oral and Maxillofacial Surgery/Head and Neck Surgery, Amsterdam University Medical Center/Antoni Van Leeuwenhoek Hospital, Amsterdam, ⁶Department of Pathology, University Medical Center Groningen, Groningen and ⁷Department of Cell and Chemical Biology, Leiden University Medical Center, Leiden, The Netherlands

Date of submission 21 December 2022
Accepted for publication 2 March 2023

Ong S L M, Gomes I P, Baelde H J, Passador-Santos F, de Andrade B A B, Briaire-de Bruijn I H, Cavalcante I L, Schreuder W H, Cleton-Jansen A-M, Cleven A H G, Szuhai K, Gomes C C & Bovée J V M G
(2023) *Histopathology* 83, 326–329. <https://doi.org/10.1111/his.14905>

No NFATC2 fusion in simple bone cyst of the jaw

Aims: Simple Bone Cysts (SBCs) predominantly occur in long bones and 59% harbour *NFATC2* rearrangements. Jaw SBC is rare and was previously referred to as traumatic bone cyst. It can rarely occur in association with cemento-osseous dysplasia (COD). To determine whether jaw SBCs represent the same entity as SBC of the long bones, or if they have a different molecular signature, we collected 48 jaw SBC cases of 47 patients to assess *NFATC2* rearrangement.

Methods and results: Out of the 48 cases, 36 could be used for fluorescence in-situ hybridization (FISH), of which nine (two of which associated with COD) were

successful using an *NFATC2* split probe. The remaining cases failed to show adequate FISH signals. All nine cases lacked *NFATC2* rearrangement and five of these showed no detectable gene fusions using Archer FusionPlex.

Conclusion: In our study, *NFATC2* rearrangement is absent in solitary jaw SBC ($n = 7$) and COD-associated SBC ($n = 2$). Our findings suggest that SBC presenting in the jaw is molecularly different from SBC in long bones. Future molecular studies may confirm the absence of clonal molecular aberrations in SBC of the jaw which would support a non-neoplastic, reactive origin.

Keywords: bone tumour, cemento-osseous dysplasia, gene fusion, jaw, *NFATC2*, simple bone cyst

Simple Bone Cyst (SBC) is a benign fluid-containing unilocular cystic bone lesion lined by a fibrous membrane predominantly occurring in long bones, with

58% (20 of 34) harbouring *NFATC2* rearrangements.¹ Approximately 10% of SBCs arise in the jaw, which were previously referred to as a nonneoplastic traumatic bone cysts.² It can rarely occur in association with cemento-osseous dysplasia (COD). To date, one case of jaw SBC studied showed an absence of *NFATC2* rearrangement.³ With no other reports of genetic alterations in jaw SBC, we sought to

Address for correspondence: Judith V M G Bovée, Department of Pathology, LUMC, Postzone L1-Q, Postbus 9600, 2300 RC Leiden, The Netherlands. e-mail: j.v.m.g.bovee@lumc.nl
Carolina C Gomes and Judith V M G Bovée contributed equally.

determine whether jaw SBCs represent the same entity as SBC of the long bones with *NFATC2* rearrangement, or if they have a different molecular signature. Hence, we collected non- or EDTA decalcified formalin-fixed paraffin-embedded (FFPE) tissue of 48 jaw SBC cases (seven COD-associated) of 47 patients to assess this.

Of the 48 cases, 12 cases were excluded at revision since the cyst walls were no longer present or sections were of too low quality due to hard undecalcified bone material. The remaining 36 cases were processed for indirect fluorescence *in-situ* hybridisation (FISH) detection using a split-apart probe set: RP5-994O24 and RP5-1114A1 bracketing *NFATC2* on chromosome 20. In 27 of 36 cases, no interpretable FISH signals could be obtained due to strong autofluorescence caused by extracellular matrix ($n = 13$) or loss of cell integrity ($n = 14$). Decalcification is an essential process in the evaluation of bone samples, although acid-based methods severely hamper molecular analysis.⁴ Despite our selection of non- or EDTA decalcified tissue, only nine out of 36 cases were successfully analysed by FISH. Other factors such as abundant extracellular matrix, old samples, or preanalytical factors such as fixation and processing conditions may hamper FISH scoring.

The nine cases consisted of seven females and two males with a median age of 21 years (ranging from 12–51 years), seven located in the mandible, one in the maxilla, and unknown location for the other case. Two of nine were COD-associated. No history of trauma was recorded for any cases. Representative radiological imaging is shown in Figure 1A,B. Histologically, all cases showed typical features as seen in SBC of the long bones including fibrous septations with ‘cracking’ osteoid lined by a layer of flattened cells (Figure 1C). In five of nine cases, ‘cloud-like’ amorphous material typically found in SBC of the long bones was seen (Figure 1D). Occasionally, septations were more myxoid (Figure 1E). Cloud-like ‘osteoid’ was absent in COD-associated SBCs (Figure 1F–H).

All nine cases were negative for *NFATC2* rearrangement (Figure 1I). The total number of nuclei counted varied from 34 cells to 172. A positive event is considered when at least 20% of the total nuclei was translocated. We isolated RNA from these nine cases and five met the quality criteria for next-generation sequencing for gene fusion analysis. Fusion detection was performed using Ion S5 Torrent system (Thermo Fisher Scientific, Waltham, MA, USA) and Archer FusionPlex Sarcoma kit v2 (Archer, Boulder, CO, USA). In all five samples, no fusions were identified in any of the 63 genes covered by the Archer

FusionPlex sarcoma panel, which includes, amongst others, *EWSR1*, *FUS*, and *USP6*. Data are available upon request.

Combined with one jaw SBC case in our previous study,³ in total 10 cases are now successfully studied and lack *NFATC2* rearrangement, in contrast to long bones SBC, harbouring *NFATC2* rearrangement in 58%. These data suggest that, despite similar morphology, they are molecularly different and probably represent different entities as compared to *NFATC2* rearranged SBC of long bone.

Our findings are in line with aneurysmal bone cyst (ABC)-like changes that can be found juxtaposed to various benign bone neoplasms such as giant cell tumour of bone, osteoblastoma, or chondroblastoma.¹ While primary ABC is a benign cystic neoplasm of bone that frequently (~70%) contains *USP6* rearrangements,¹ these rearrangements were absent in what was previously referred to as secondary ABC.⁵ Now, this phenomenon is referred to as ABC-like changes, as they merely represent abundant cystic change,¹ despite the fact that they are morphologically identical to primary ABC.

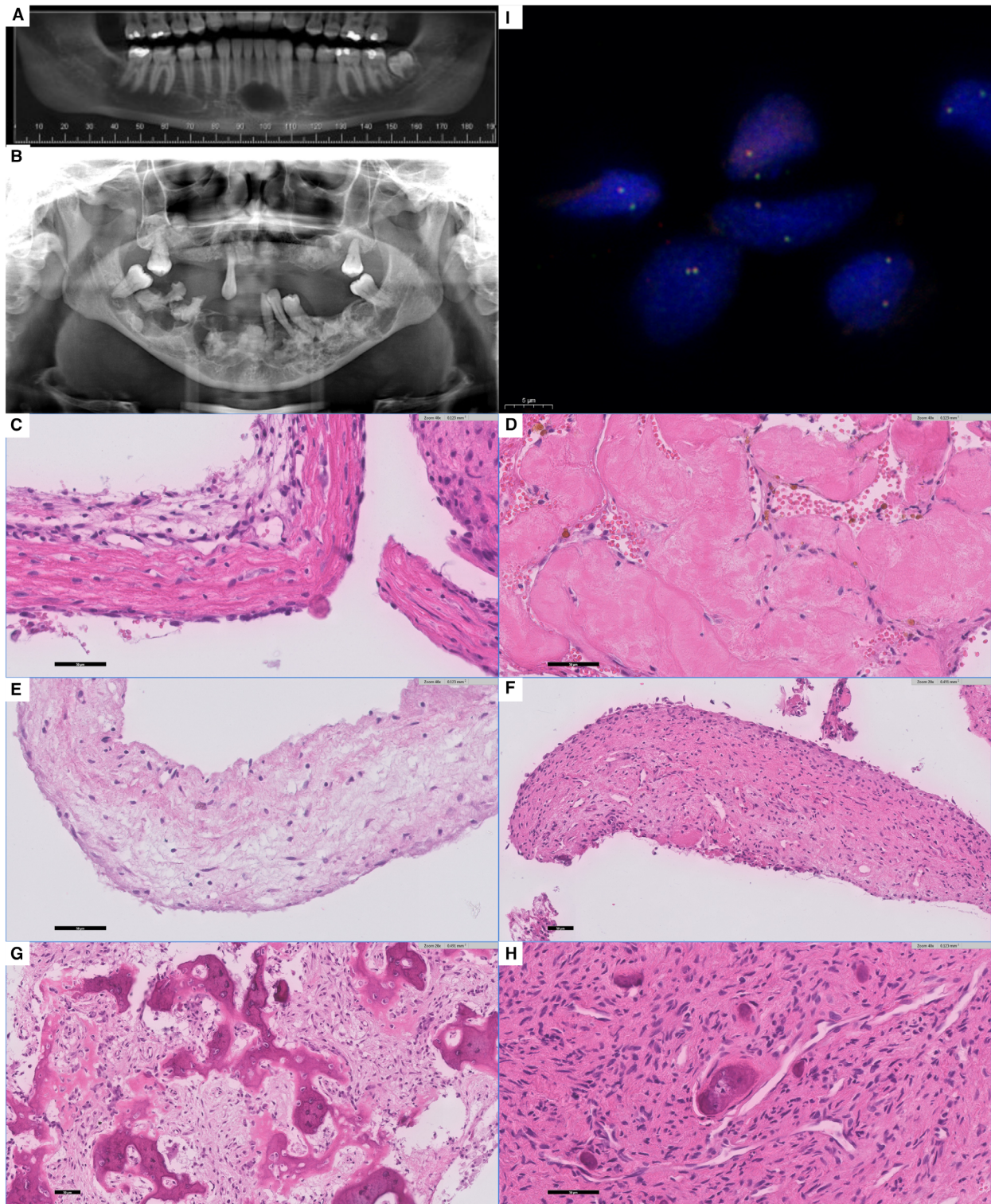
In conclusion, SBC of the jaw, either primary or COD-associated, is molecularly different from the majority of long bone SBC. How they relate to the subset of SBC without *NFATC2* rearrangement remains unclear. Future molecular studies on fresh frozen tissue may reveal whether recurrent molecular alterations other than *NFATC2* or the other gene fusions tested are present in jaw SBC, supporting a neoplastic origin, or that clonal molecular alterations are absent. The latter would support a reactive aetiology, potentially justifying referral to jaw SBC as traumatic bone cyst or secondary SBC-like or cystic change rather than SBC.

Acknowledgements

The authors thank the National Council of Scientific and Technological Development (CNPq)/Brazil and Coordination for the Improvement of Higher-Level Education Personnel (CAPES)/Brazil. C.C.G. is research fellow at CNPq. Additionally, we thank the São Leopoldo Mandic Institute (SLM) and Universidade Federal do Rio de Janeiro (UFRJ) for sharing the patient cases in this study.

Authors Contributions

J. V. M. G. B., K. S., A. H. G. C., and C. C. G. designed and supervised the study. S. L. M. O., H. J. B., and K. S. performed or analysed the FISH experiment. I. H. B. B.



generated paraffin sectioned slides. A. M. C. J. analysed anchored multiplex PCR. F. P. and B. A. B. A. provided the cases included in the study and were responsible

for the diagnosis. F. P., B. A. B. A., I. P. G., and I. L. C. provided patients clinical information. A. H. G. C., J. V. M. G. B., and W. H. S. provided pathological expertise

Figure 1. Radiological and histological spectrum of simple bone cyst (SBC) and cementous osseous dysplasia with associated SBC. **A:** Panoramic reconstruction of a cone-beam computed tomography demonstrating a representative image of a solitary jaw SBC. The hypodense central area is surrounded by a hyperdense and well-defined wall extending from the lower left to the lower right canine. **B:** Panoramic radiograph of a COD-associated SBC showing multiple radiolucent/radiopaque areas in the maxilla and mandible characteristic of COD. Additionally, radiolucent lesions presenting well-defined radiopaque borders are present in the right and left mandible. **C:** SBC with fibrous septa containing 'cracking' osteoid and reactive myxoid changes with influx of lymphocytes. The septations are lined by a layer of flattened cells; atypia and mitotic activity were absent. **D:** Loose connective tissue with abundant eosinophilic 'cloud-like' amorphous material in SBC. **E:** Example of SBC with myxoid septation without 'cracking' osteoid. **F:** SBC component in a case of COD showing cellular septa lined by flattened cells without any clear 'cracking' osteoid. **G,H:** COD morphology showing various proportions of woven bone arranged in trabeculae (G) or small bone islands (H) with osteoblastic rimming. In between, a moderately cellular and monomorphic fibroblastic stroma is seen. **I:** Representative image of SBC showing colocalisation indicating the absence of NFATC2 translocation via FISH.

and/or reviewed the patient cases. S. L. M. O. and J. V. M. G. B. wrote the draft. All authors contributed to and approved the final article.

Funding information

This work was financially supported by the Netherlands Organization for Scientific Research (ZON-MW VICI 170.055 to J.V.M.G.B.).

Conflict of interest

The authors have no conflicts of interest.

Data availability statement

The data that support the findings of this study are available on request from the corresponding author.

The data are not publicly available due to privacy or ethical restrictions.

References

1. *WHO classification of tumours of soft tissue and bone*. Vol. 3. 5th ed. Lyon, France: WHO Classification of Tumours Editorial Board, 2020.
2. *WHO classification of head and neck tumours*. Vol. 9. 5th ed. Lyon, France: International Agency for Research on Cancer, 2022.
3. Ong SLM, Lam SW, van den Akker BEWM *et al*. Expanding the Spectrum of EWSR1-NFATC2-rearranged benign tumors: a common genomic abnormality in vascular malformation/hemangioma and simple bone cyst. *Am. J. Surg. Pathol.* 2021; **45**: 1669–1681.
4. Schrijver WA, Van Der Groep P, Hoefnagel LD *et al*. Influence of decalcification procedures on immunohistochemistry and molecular pathology in breast cancer. *Mod. Pathol.* 2016; **29**: 1460–1470.
5. Oliveira AM, Perez-Atayde AR, Inwards CY *et al*. USP6 and CDH11 oncogenes identify the neoplastic cell in primary aneurysmal bone cysts and are absent in so-called secondary aneurysmal bone cysts. *Am. J. Pathol.* 2004; **165**: 1773–1780.