



Universiteit  
Leiden  
The Netherlands

## **Balloon atrial septostomy for transposition of the great arteries: safety and experience with the Z-5 balloon catheter**

Weeda, J.A.; Bokenkamp-Gramann, R.; Straver, B.B.; Rammeloo, L.; Hahurij, N.D.; Bertels, R.A.; ... ; Palen, R.L.F. van der

### **Citation**

Weeda, J. A., Bokenkamp-Gramann, R., Straver, B. B., Rammeloo, L., Hahurij, N. D., Bertels, R. A., ... Palen, R. L. F. van der. (2023). Balloon atrial septostomy for transposition of the great arteries: safety and experience with the Z-5 balloon catheter. *Catheterization & Cardiovascular Interventions*. doi:10.1002/ccd.30932



Version: Publisher's Version

License: [Creative Commons CC BY-NC-ND 4.0 license](#)

Downloaded from: <https://hdl.handle.net/1887/3714435>

**Note:** To cite this publication please use the final published version (if applicable).

# Balloon atrial septostomy for transposition of the great arteries: Safety and experience with the Z-5 balloon catheter

Jesse A. Weeda MD<sup>1,2,3</sup>  | Regina Bokenkamp-Gramann MD, PhD<sup>1,3</sup> |  
 Bart B. Straver MD, PhD<sup>3,4</sup> | Lukas Rammeloo MD<sup>3,4</sup> |  
 Nathan D. Hahurij MD, PhD<sup>1,3</sup> | Robin A. Bertels MD<sup>1,3</sup> |  
 Monique C. Haak MD, PhD<sup>3,5</sup> | Arjan B. te Pas MD, PhD<sup>2</sup> |  
 Mark G. Hazekamp MD, PhD<sup>3,6</sup> | Nico A. Blom MD, PhD<sup>1,3</sup> |  
 Roel L. F. van der Palen MD, PhD<sup>1,3</sup> 

<sup>1</sup>Department of Pediatrics, Division of Pediatric Cardiology, Willem-Alexander Children's Hospital, Leiden University Medical Center (LUMC), Leiden, The Netherlands

<sup>2</sup>Department of Pediatrics, Division of Neonatology, Willem-Alexander Children's Hospital, Leiden University Medical Center (LUMC), Leiden, The Netherlands

<sup>3</sup>Center for Congenital Heart Disease Amsterdam-Leiden (CAHAL), Departments of Pediatrics, Divisions of Pediatric Cardiology, Departments of Obstetrics and Fetal Medicine, Departments of Cardiothoracic Surgery, Amsterdam University Medical Center (Amsterdam UMC) and Leiden University Medical Center (LUMC), Amsterdam and Leiden, The Netherlands

<sup>4</sup>Department of Pediatrics, Division of Pediatric Cardiology, Emma Children's Hospital, Amsterdam University Medical Center (Amsterdam UMC), Amsterdam, The Netherlands

<sup>5</sup>Department of Obstetrics and Fetal Medicine, Leiden University Medical Center (LUMC), Leiden, The Netherlands

<sup>6</sup>Department of Cardiothoracic Surgery, Leiden University Medical Center (LUMC), Leiden, The Netherlands

## Correspondence

Jesse A. Weeda, MD, Department of Pediatrics, Division of Pediatric Cardiology, Willem-Alexander Children's Hospital, Leiden University Medical Center (LUMC), Leiden, The Netherlands.  
 Email: [j.a.weeda@lumc.nl](mailto:j.a.weeda@lumc.nl)

## Abstract

**Background:** Balloon atrial septostomy (BAS) is an emergent and essential cardiac intervention to enhance intercirculatory mixing at atrial level in deoxygenated patients diagnosed with transposition of the great arteries (TGA) and restrictive foramen ovale. The recent recall of several BAS catheters and the changes in the European legal framework for medical devices (MDR 2017/745), has led to an overall scarcity of BAS catheters and raised questions about the use, safety, and experience of the remaining NuMED Z-5 BAS catheter.

**Aims:** To evaluate and describe the practice and safety of the Z-5 BAS catheter, and to compare it to the performance of other BAS catheters.

**Methods:** A retrospective single-center cohort encompassing all BAS procedures performed with the Z-5 BAS catheter in TGA patients between 1999 and 2022.

**Results:** A total of 182 BAS procedures were performed in 179 TGA-newborns at Day 1 (IQR 0–5) days after birth, with median weight of 3.4 (IQR 1.2–5.7) kg. The need for BAS was urgent in 90% of patients. The percentage of BAS procedures performed at bedside increased over time from 9.8% (before 2010) to 67% (2017–2022). Major complication rate was 2.2%, consisting of cerebral infarction (1.6%) and hypovolemic shock (0.5%). The rate of minor complications was 9.3%, including temporary periprocedural AV-block (3.8%), femoral vein thrombosis (2.7%), transient intracardiac thrombus (0.5%), and atrial flutter (2.2%). BAS procedures performed at bedside and in the cardiac catheterization laboratory had similar complication rates.

**Conclusions:** BAS using the Z-5 BAS catheter is both feasible and safe at bedside and at the cardiac catheterization laboratory with minimal major complications.

This is an open access article under the terms of the [Creative Commons Attribution-NonCommercial-NoDerivs](https://creativecommons.org/licenses/by-nc-nd/4.0/) License, which permits use and distribution in any medium, provided the original work is properly cited, the use is non-commercial and no modifications or adaptations are made.

© 2023 The Authors. *Catheterization and Cardiovascular Interventions* published by Wiley Periodicals LLC.

**KEYWORDS**

congenital heart disease, transposition of the great arteries, cardiac catheterization, balloon atrial septostomy, septostomy catheter

## 1 | INTRODUCTION

Balloon atrial septostomy (BAS) is an emergent and essential cardiac interventional procedure to stabilize neonates with congenital heart diseases (CHD) with physiology of restrictive atrial communication, such as patients with transposition of the great arteries (TGA).<sup>1–3</sup> The enlargement of interatrial communication by BAS enhances atrial level mixing of oxygenated and deoxygenated blood from parallel pulmonary and systemic circulation and improves systemic hypoxia and acidosis.<sup>2</sup> BAS was first performed by Rashkind and Miller in 1966 and is currently still a lifesaving procedure for TGA neonates with severe oxygen desaturation after birth.<sup>4</sup> Since the first description, BAS technique has evolved drastically and many different septostomy catheters with different sizes of balloons have been developed, such as the Miller-Edwards catheter and Fogarty BAS catheter (Edwards Lifesciences Corporation), the Rashkind catheter (Medtronic), the NuMED Z-5 and the recently issued Z-6 BAS catheter (NuMED Inc.).<sup>1,5</sup> However, the recent recall and market withdrawal of Fogarty and Miller-Edwards catheters (2019) followed by Medtronic Rashkind BAS catheters (2020), due to safety issues, and changes in European legal framework for medical devices (MDR 2017/745), have led to an overall scarcity of BAS catheters.<sup>6–8</sup> Due to the critical shortage of BAS catheters worldwide, certain centers already have had to rely on static BAS catheters as an alternative to pull-through BAS for treatment of CHD.<sup>9</sup> In Europe, the only remaining septostomy catheter is the NuMED BAS catheter, of which the Z-5 is the long-standing “classic” BAS catheter, next to the Z-6 BAS catheter. The Z-6 BAS catheter is currently awaiting CE-marking and is scarcely available on demand in Europe.<sup>10</sup> Given that the Z-5 BAS catheter is presently the only long-standing and more-widely used available CE-marked BAS catheter, it is important to report on the utilization and safety of the Z-5 BAS catheter. For the past 24 years, the Center for Congenital Heart Disease Amsterdam-Leiden (CAHAL), a specialized tertiary referral center in the Netherlands, has exclusively used the Z-5 BAS catheter for BAS procedures in TGA patients. The main objective of this study was to evaluate and describe the practice and safety of the Z-5 BAS catheter, and to compare it to the performance of other BAS catheters.

## 2 | MATERIALS AND METHODS

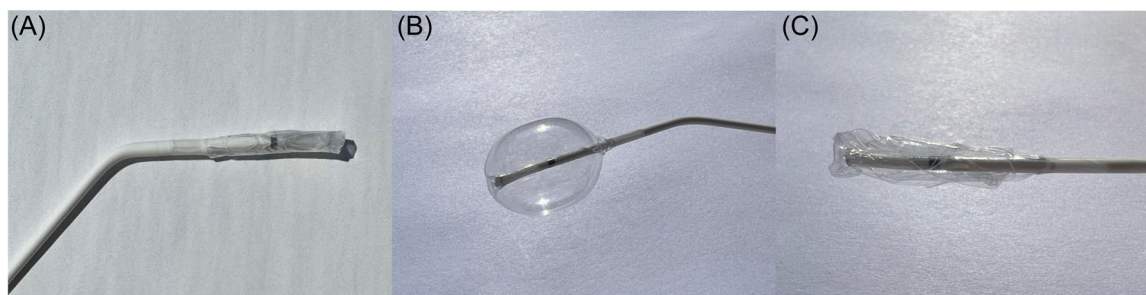
### 2.1 | Study population

This retrospective cohort study was conducted at the CAHAL, a tertiary referral center based in two academic hospitals in the

Netherlands (Leiden University Medical Center and Amsterdam University Medical Center). All TGA patients who underwent BAS at CAHAL between December 1998 and December 2022 were included. TGA subgroups based on anatomic differences included TGA with intact ventricular septum (TGA-IVS), TGA with ventricular septal defect (TGA-VSD), and double outlet right ventricle with subpulmonary VSD (i.e., Taussig-Bing anomaly). Variables such as demographic data, gender, gestational age, morphological diagnosis, birthweight, prenatal or postnatal detection of TGA and BAS data, including timing of procedure (urgent or elective), location of BAS procedure (bedside or at the cardiac catheterization laboratory), vascular access, type of BAS catheter, BAS efficacy (i.e., BAS reintervention rate) and BAS-related complications were obtained from medical records, echocardiographic and catheterization reports. BAS-related complications were classified as major or minor, comparable with the definitions as described by Vitiello et al.<sup>11</sup> Major complications included death, life-threatening hemodynamic compromise requiring immediate therapy (e.g., cardiac arrest), a significant unanticipated permanent anatomic or functional lesion resulting from the catheterization (e.g., cerebral infarct, cardiac perforation, permanent arterial or cardiac thrombosis, vessel tear, or aneurysm), or mechanical complications (e.g., balloon rupture or fragmentation). Minor complications were any events that were transient and resolved with or without specific treatment, including various transient arrhythmias, temporary atrioventricular (AV) block, and transient venous thrombosis.<sup>9</sup> Appropriate local scientific board approval was obtained and the need for written informed consent was waived by the institutional medical ethical board.

### 2.2 | Septostomy catheter

The Z-5 BAS catheter (NuMED, Inc.) is a dual lumen catheter of 50 cm in length with a noncompliant balloon made of polymeric nylon with a diameter of 13.5 to 0.5 mm, with a maximum capacity of 2 cc at the distal end. The inflated balloon is spherical in shape and features an end-hole to accommodate a 0.021-inch guidewire. The 2 cc balloon is inserted via a 6 Fr introducer sheath. Moreover, the Z-5 BAS catheter is also available with a 5 Fr introducer sheath, 0.014-inch guidewire and 1 cc capacity at the distal end. The Z-5 balloon (1 cc and 2 cc) contains a radiopaque imaging band in the center, which allows for precise positioning in the right atrium, and the catheter tip is angled at 35° to facilitate entry into the left atrium.<sup>10</sup> Out of the packaging, the wrapped and deflated balloon of the Z-5 BAS catheter extends beyond the tip of the catheter, resulting in a relatively more rigid and longer appearance (Figure 1); this has been modified in the new version of the Z-6 BAS catheter.<sup>9</sup>



**FIGURE 1** Displays the Z-5 in deflated state (A), inflated state (B), and again in deflated state after the procedure (C).

### 2.3 | Perinatal management and BAS procedure

The management policy for patients with TGA entails daytime delivery, to adequately facilitate BAS primarily at bedside with a second pediatric cardiologist, responsible for transthoracic echocardiographic guidance. The decision to perform the procedure is based on oxygen saturation levels and the size of interatrial communication, and secondary to the time to arterial switch operation (ASO). The performed procedures were indicated as urgent or elective. Urgent BAS was defined as need for BAS due to hypoxemia and inadequate systemic oxygen delivery in the setting of a restrictive interatrial communication; elective BAS was defined as BAS performed because of relatively small interatrial communication without severe hypoxemia to optimize systemic oxygen saturation while awaiting ASO. The technique for performing BAS is well-documented in literature.<sup>1</sup> In short, at our center, BAS is performed under general anesthesia and vascular access is obtained through the right femoral vein as first choice or through the umbilical vein by exception. An appropriately sized (5 Fr or 6 Fr) introducer sheath (Cordis Avantis) is inserted to allow the advancement of the BAS catheter. Since 2015, heparin (100 IU/kg) is administered following sheath placement, after which the Z-5 BAS catheter is introduced with a 0.021 or 0.014 floppy-tip guidewire. After crossing the foramen ovale (FO) and position control by fluoroscopy or echocardiography, the balloon is filled with a saline/contrast mixture (70:30%) or 100% saline if echocardiographic guidance. Once the inflated balloon is correctly positioned in the left atrium, the stopcock is closed, the guidewire is retracted, and the catheter is abruptly withdrawn into the body of the right atrium. Subsequently, the balloon is immediately deflated to allow vena cava inferior flow. If necessary, the procedure can be repeated, also with a larger volume balloon to achieve satisfactory communication. The efficacy of BAS is objectified through clinical evaluation (i.e., improvement of oxygen saturation) and echocardiographic assessment (2D and color Doppler) of the adequacy of the interatrial communication after the procedure. The sheath is withdrawn after the procedure and a pressure bandage is applied. In some patients, the sheath is replaced by a central venous catheter. Figure 2 shows the BAS procedure utilizing the Z-5 BAS catheter with echocardiographic guidance.

### 2.4 | Data management and analysis

Statistical analysis was performed using SPSS (version 29; SPSS Inc). Evaluation of normal distribution of continuous data was performed using the Shapiro–Wilk test.

Demographic and clinical data, and data regarding procedure and complications were presented as frequency with percentage for categorical variables and mean  $\pm$  SD or median with interquartile range [IQR] for continuous data.

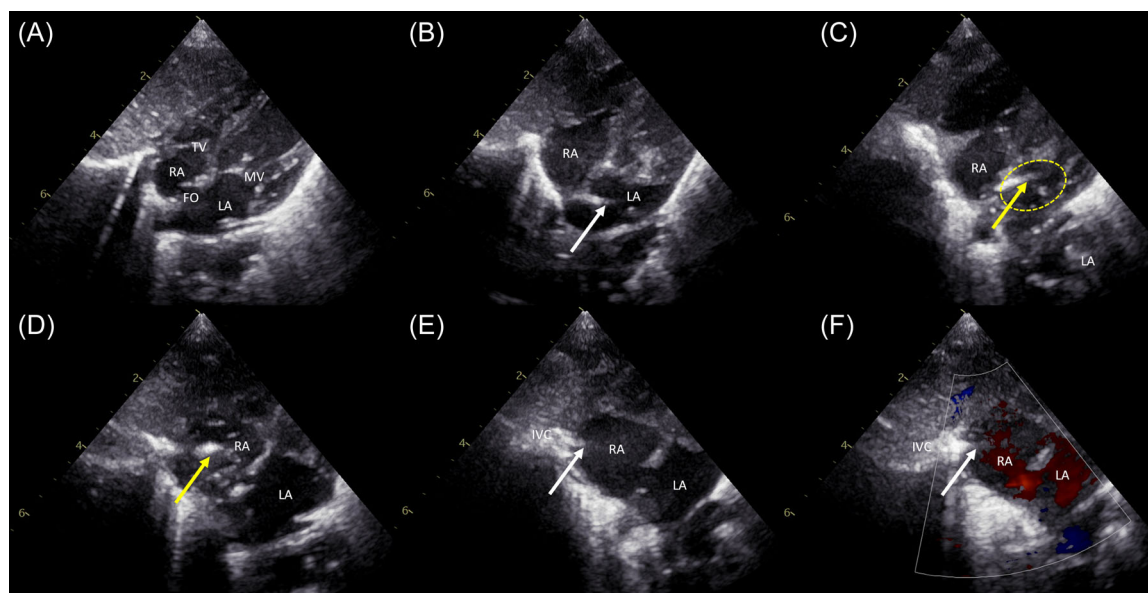
To test for differences between groups,  $\chi^2$  test for categorical variables, independent *t*-test for normally distributed continuous variables, and the Mann–Whitney *U* test for nonnormally distributed continuous variables, was performed. Moreover, a review of the existing literature was conducted to determine the safety and efficacy of the BAS procedures using various pull-through BAS catheters in CHD as well as in TGA patient alone (Supporting Information: Figure 1).

## 3 | RESULTS

### 3.1 | Baseline characteristics

Out of a total of 292 TGA patients, 179 infants (61%) underwent 182 BAS procedures to optimize interatrial mixing. Among the 179 patients, 70% were male and morphological subtypes were: TGA-IVS in 124 (69%), TGA-VSD in 44 (25%), and Taussig–Bing anomaly in 11 (6.1%) patients. The prenatal detection rate has improved over decades from 20% between 1998 and 2010 to 83% between 2011 and 2022. Median age at diagnosis of the prenatally undetected TGA patients was 1 [IQR 0–6] day(s). Eight neonates (4.5%) who underwent BAS were prematurely born (<37 weeks of gestation), six infants (3.3%) had birthweight  $\leq$ 2.5 kg and the lowest weight at which BAS was performed was 1150 g. Baseline characteristics are summarized in Table 1.

BAS was performed urgent in 90% and elective in 10% of patients. Pulmonary hypertension was present in 26 patients (15%) requiring mechanical ventilation, oxygen supplementation, and nitric oxide (all patients); 7 of them necessitated extracorporeal membrane oxygenation.



**FIGURE 2** Echocardiographic guided atrial septostomy. (A) Shows a restrictive foramen ovale (FO). The deflated Z-5 (2 cc) balloon atrial septostomy (BAS) catheter is advanced into the left atrium (LA) in (B), followed by inflation of the balloon (C). Subsequently, the inflated balloon is pulled through the restrictive FO into the right atrium (RA) where the inferior vena cava (IVC) enters the RA, followed by rapid deflation of the balloon (D, E). After balloon septostomy there is a nonrestrictive communication between the LA and RA (E) as is depicted by the laminar color Doppler flow in (F). White arrows indicate the deflated Z-5 BAS catheter; yellow arrow and yellow dotted line, the inflated Z-5 BAS catheter; MV, mitral valve; TV, tricuspid valve. [Color figure can be viewed at [wileyonlinelibrary.com](https://onlinelibrary.wiley.com/doi/10.1002/ajcd.30932)]

**TABLE 1** Baseline patient characteristics.

	N (%) or median (IQR) N = 179
Gender: Male	126 (70)
<i>Morphological diagnosis</i>	
TGA-IVS	124 (69)
TGA-VSD	44 (25)
TB	11 (6.1)
Prematurity (<37 weeks of gestation)	8 (4.5)
Prenatally diagnosed	92 (51)
Gestational age (weeks)	39 + 1
Birth weight (kg)	3.4 (1.2–5.7)
<i>Associated anomalies</i>	
LVOTO	5 (2.8)
Aortic arch abnormality	8 (4.5)
Aortic coarctation	7
Aortic arch interruption type B	1
Prostaglandin E2 administration	156 (87)

Abbreviations: IQR, interquartile range; IVS, intact ventricular septum; LVOTO, left ventricular outflow tract obstruction; TB, Taussig Bing anomaly; TGA, transposition of the great arteries; VSD, ventricular septal defect.

### 3.2 | BAS procedure

The Z-5 BAS catheter was exclusively used in all 182 procedures. In three patients, pull-through BAS procedure was preceded by static BAS (TYSHAK®) due to the presence of a thickened or heavily restricted interatrial septum, resistant to pull-through BAS. In total, three patients (1.7%) required reintervention BAS to achieve satisfactory interatrial communication. Baseline characteristics of BAS are presented in Table 2. Overall, 29% of BAS procedures were performed at bedside, with a marked increase of bedside BAS procedures over time, ranging from 9.8% (before 2010) up to 67% over the past 6 years (2017–2022) (Figure 3). In six patients (3.3%), bedside BAS procedure had to be converted to the cardiac catheterization laboratory for either the acquisition of vascular access in a hemodynamically unstable patient ( $n = 3$ ), challenges in passing through the FO with need of fluoroscopic guiding ( $n = 1$ ) or in the case of procedural complications ( $n = 2$ ). In most patients, venous access was obtained via femoral vein, facilitated by routine 2D and Doppler ultrasound delineation since 2013 or by exception through umbilical vein, accounting for 75% and 17% of cases respectively; in four patients (2.2%) surgical venesection was necessary for adequate vascular access. The 6 Fr introducer sheath (93%) was predominantly used for femoral venous vascular access. In infants with birthweight  $\leq 2.5$  kg ( $n = 6$ ), the 5 Fr introducer sheath was used in two and the 6 Fr introducer sheath in four patients.

**TABLE 2** BAS procedure characteristics.

BAS procedure (N = 182)	N (%), median (IQR)
Days postbirth	1 (0–5)
Reintervention, second BAS procedure	3 (1.7)
<i>Location BAS</i>	
Bedside	52 (29)
Catheterization laboratory	118 (65)
Bedside converted to catheterization laboratory	6 (3.3)
Unknown	6 (3.3)
<i>Access</i>	
Femoral vein	137 (75)
Umbilical vein	18 (9.9)
First via umbilical vein, converted to femoral vein	12 (6.6)
Surgical venesection	4 (2.2)
Unknown	11 (6.0)
<i>Sheath</i>	
5 French	7 (4.3)
6 French	142 (87)
7 French	1 (0.6)
Unknown	15 (9.1)
<i>Balloon type and volume</i>	
Z-5, 1 cc	10 (5.5)
Z-5, 2 cc	100 (55)
Z-5, 1 cc and 2 cc	52 (29)
Static dilatation (TYSHAK 5 or 6 × 20 mm), followed by Z5, 2cc	3 (1.6)
Unknown	17 (9.3)
<i>Indication</i>	
Elective	19 (10)
Urgent	163 (90)

Abbreviations: BAS, balloon atrial septostomy; FO, foramen ovale; IQR, interquartile range.

### 3.3 | Complications

There were four major complications (2.2%) out of 182 procedures (Table 3). Major complications consisted of a hypovolemic shock due to umbilical vein hemorrhage in one patient (prenatally unknown TGA, presented at Day 3 postbirth) and cerebral infarction in three patients. Among the patients with stroke, in one patient (2014) this complication was *highly likely* associated with BAS as there was a periprocedural iliac vein dissection following initial difficult venous access for which surgical venesection was required, accompanied by a deep vein thrombosis afterwards. In the other two patients (2006,

2014) with stroke, the cerebral infarction was *possibly* related to the BAS procedure. One of these patients was a prenatally unknown term neonate with TGA who presented to the emergency department in severe hemodynamically compromised state (severe cyanosis and acidosis) and underwent urgent BAS. This patient exhibited neurological symptoms post-BAS (difficulty wakening up completely after sedation tapering), with frontal lobe infarction and signs indicating posthypoxia on cranial ultrasound and MRI investigations. The other patient was unexpectedly born prematurely at a gestational age of 36 weeks and 4 days (birth weight 2710 g) requiring urgent BAS for low oxygen saturation and restrictive FO. In this case, surveillance cranial ultrasound 3 days post-BAS showed intraparenchymal echodensities and subsequent MRI revealed an infarction in the middle cerebral artery, despite the absence of evident neurological symptoms. From the TGA patients who did not undergo BAS in this series ( $n = 113$ ), one patient revealed a cerebral injury (0.9%) on routine cranial ultrasonography before corrective surgery.

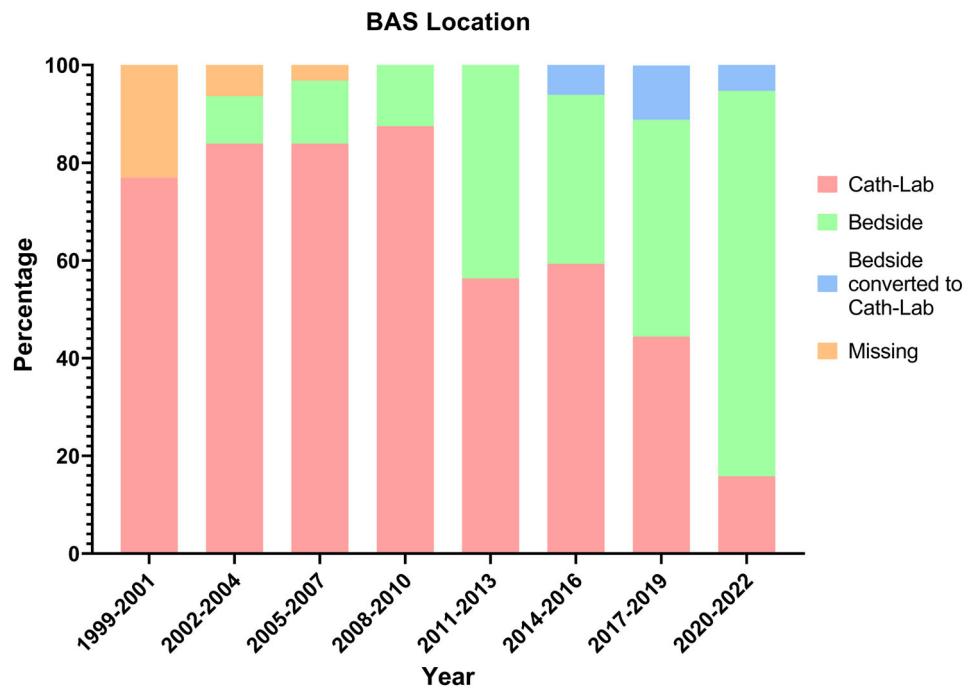
Minor complications were present in less than 10% of the procedures and consisted of a periprocedural transient intracardiac thrombus (0.5%), which completely resolved after thrombolytic therapy. Moreover, seven patients (3.8%) developed transient periprocedural AV-block, which was mostly brief; only one patient required temporary ventricular pacing. Furthermore, atrial flutter was seen in four patients (2.2%) and femoral vein thrombosis was observed in five patients (2.7%), of which two patients had a central venous line placed after the BAS procedure (Table 3). No balloon ruptures or balloon deflation failures have occurred.

There were no significant differences in gender, age at time of BAS, morphological diagnosis, birthweight, timing of BAS procedure (urgent vs. elective), vascular access (femoral vein vs. umbilical vein), and location of BAS procedure (bedside vs. at the cardiac catheterization laboratory) between the patients with complications (major and minor combined) and those without complications.

Except for the aforementioned preterm infant with cerebrovascular complication, there were no other complications among prematurely born patients or those with low birth weight ( $\leq 2.5$  kg).

### 3.4 | BAS studies reporting catheter-specific outcomes and complications in TGA patients

Supporting Information: Table 1 summarizes the existing literature on the effectiveness and complications of BAS with various pull-through septostomy catheters in TGA patients over the years. Retrospective ( $n = 15$ ) and prospective cohort studies ( $n = 2$ ) were included with sample sizes varying from 8 to 134 TGA patients and Miller-Edwards, Rashkind, Fogarty, and Z-5 BAS catheters. Septostomy procedures in larger cohorts of patients with different CHD, not exclusively but mainly TGA patients, are depicted in Supporting Information: Table 2. Registered complications were of mechanical (e.g., balloon rupture), traumatic (e.g., cardiac damage), embolic (e.g., cerebral event), and electrophysiological (e.g., transient rhythm disorders or AV-block) nature and were reported for all catheters. The Fogarty and



**FIGURE 3** Rashkind location. Changes in location of BAS procedures over time. BAS, balloon atrial septostomy. [Color figure can be viewed at [wileyonlinelibrary.com](http://wileyonlinelibrary.com)]

**TABLE 3** Complications BAS procedure.

	Cardiac cath-lab	Bedside	Total (n = 182)
<i>Major complications</i>			4
Cerebral infarction	1	-	1 (0.5)
Cerebral infarction and Iliac vein dissection	-	1	1 (0.5)
Cerebral infarction and subdural hemorrhage	1	-	1 (0.5)
Hypovolemic shock due to umbilical vein hemorrhage	-	1	1 (0.5)
<i>Minor complications</i>			17
<i>Periprocedural</i>			
Temporary AV-block	4	3	7 (3.8)
Self-limiting	4	2	
Transfemoral ventricular pacing	-	1	
Atrial flutter	4	-	4 (2.2)
Intracardiac thrombus	-	1	1 (0.5)
<i>Postprocedural</i>			
Femoral vein thrombosis	4	1	5 (2.8)

Note: Data are in N (%).

Miller-Edwards balloon catheters were related with an increased frequency of balloon ruptures, whereas the Z-5 and Rashkind catheters were not associated with this problem.<sup>5,12-14</sup>

## 4 | DISCUSSION

In this retrospective study, we present our clinical experience within a large cohort of unselected consecutive neonates with TGA undergoing BAS over the past 24 years. Our findings confirm the safety and efficacy of the Z-5 BAS catheter, which was introduced nearly three decades ago.<sup>15</sup> Irrespective of periprocedural setting (i.e., bedside or at the cardiac catheterization laboratory), major complications were infrequent, occurring in only 2.2% of procedures respectively. Minor complications occurred in less than 10% of procedures.

### 4.1 | Septostomy catheters

Over the years, different BAS catheters were available from various manufacturers, each with its own unique design and characteristics.<sup>16,17</sup> The composition of the balloon, its diameter and volume (including the maximum volumes of inflation), the size of the introducer sheath, and the ability of using a guidewire for advancement are some of these unique features. Previous research shows

that there are no substantial differences in outcomes and complications associated with the use of different septostomy catheters. However, there was a notable increased frequency of balloon ruptures utilizing the Fogarty and Miller-Edwards BAS catheters, thereby corroborating the reason for their recall.<sup>8,9</sup> Similarly, we did not observe mechanical complications attributed to the Z-5 BAS catheter in our cohort, such as balloon fragmentation, rupture, or detachment upon retrieval.<sup>18-20</sup>

#### 4.2 | Bedside versus cardiac catheterization laboratory

Bedside BAS has advantages of being less invasive, quicker, more cost-effective compared with the catheterization laboratory and avoids the risks of patient transfer and radiation exposure.<sup>21</sup> However, it may be technically challenging without fluoroscopic guidance, especially in more complex anatomical cases, such as patients with extremely floppy and highly mobile interatrial septum, and in those with juxtaposition of the atrial appendages. Previous studies using various types of BAS catheters comparing bedside and cardiac catheterization laboratory septostomy performances have shown mixed results. While some reported higher success rates and lower complication rates in the cardiac catheterization laboratory, others found no significant differences in outcomes.<sup>21,22</sup> The results from this study, with up to 70% of the BAS procedures performed bedside over the past 6 years, did not demonstrate a significant difference in complications between the two settings. We advocate that performing bedside BAS with the Z-5 septostomy catheter is as safe and effective as opposed to performing BAS in a catheterization laboratory, with the possible added benefit of cost savings.

#### 4.3 | Prematurity and low birth weight

Prematurity and low birth weight are associated with technical and physiological perioperative challenges as well as delayed time to ASO.<sup>23</sup> In the case of the Z-5 BAS catheter, it has been suggested that the angle of the catheter tip of 35° may be too small for the atrial anatomy in premature and low-weight children. However, we did not experience these difficulties in the clinical practice in the subset of low birthweight infants. Previous studies have highlighted substantial risks associated with cardiac catheterization in infants weighing  $\leq 2.5$  kg, resulting in higher morbidity (e.g., arrhythmias, vascular injuries, bleeding requiring blood transfusion) and mortality.<sup>24-26</sup> The overall complication rate among preterm and low birthweight infants in this cohort was low. Despite one major complication (i.e., cerebral infarction) in a preterm infant following BAS, none occurred in the group of low birthweight infants. For infants with a weight  $\leq 2.5$  kg, a 5 Fr introducer would have been the sheath of choice, but we only used a 5 Fr sheath with a 1 cc Z-5 BAS catheter in two of these neonates, while we were able to introduce a 6 Fr sheath with a 2 cc Z-5 BAS catheter in the remaining 4. This

did not result in increased vascular injury or thrombosis at the vascular access point.

#### 4.4 | Procedural complications and risk factors

Less than 10% of the patients had minor complications, and only 2.2% of the patients had major complications. The incidence of major complications, particularly cerebral infarction, following BAS has yielded conflicting results in literature. Mukherjee et al. reported in an analysis of 8681 neonates with TGA a twofold increase in the occurrence of stroke among neonates who underwent BAS compared with those who did not.<sup>27</sup> Consistent with these findings, a large registry study including 17,392 neonates with TGA reported an increased prevalence of stroke in BAS patients versus non-BAS patients (1.1% vs. 0.6%).<sup>28</sup> Moreover, McQuillen et al. presented MRI's in TGA children before corrective cardiac surgery and reported in 41% imaging characteristic of identified brain injuries consistent with embolism.<sup>29</sup> Conversely, Polito et al. did not find an increased risk of perioperative brain injury in their meta-analysis.<sup>30</sup> The disadvantage of the above-mentioned large national registry studies is the inclusion of the complete postoperative period until discharge and thus no temporal relationship could be established between BAS and stroke.<sup>27,28</sup> In our series, we specifically focused on preoperative brain injury identified clinically or on routine cranial ultrasonography before corrective cardiac surgery. Within our cohort, we also observed a higher prevalence of stroke in patients who underwent BAS compared with those who did not undergo BAS (1.7% vs. 0.9% respectively). However, due to the limitations of our study design and the lack of structural cranial ultrasonography before and immediately after BAS, we are unable to definitively establish a causal relationship between BAS and subsequent brain injury as well. Nevertheless, we speculate that the increased frequency of stroke observed in BAS patients may at least be partially attributable to BAS. However, it is important to note that BAS is performed in patients with higher risk of stroke, especially in urgent cases involving severe hypoxic and hemodynamically compromised patients with reduced cardiac output and oxygen supply. Consequently, brain injury then results from impaired cerebral perfusion and oxygenation and may not be directly linked to BAS. These aspects are illustrated from the individual cases.

Apart from brain-related complications, our series also observed one other major event. This patient experienced hemorrhagic shock, due to bleeding from the umbilical stump most likely caused by an inadequately secured umbilical tie.

Minor complications consisted of temporary AV-block, atrial flutter, and femoral vein thrombosis. The occurrence of temporary conduction disorders and atrial arrhythmias (i.e., AV-block and atrial flutter) was observed in 6% of all procedures, which is comparable to previous BAS reports.<sup>1,2</sup>

In this cohort, femoral venous thrombosis was observed in approximately 3% of procedures, which has previously been reported in 2%–6% of patients undergoing BAS using the Fogarty or Miller-Edwards BAS catheters.<sup>5,18,31</sup> Furthermore, the 6 Fr



sheath (93%) was predominantly used for femoral venous vascular access. Previous studies have established a significant correlation between larger sheath size and an increased risk of thromboembolic complications.<sup>32</sup> This needs to be seen in perspective as the Miller-Edwards, Rashkind, and Fogarty BAS catheters typically do require larger introducer sheath sizes, compared with the Numed BAS catheters. However, there is no study comparing the vascular complications between these BAS catheters in relation to patient size. It is worth noting that all patients treated in our center since 2015 have received heparin 100 IE/kg after vascular access, which is not standard practice in many centers.<sup>33</sup> This became standard practice after two cases with cerebral infarction after BAS procedure in 2014. Additionally, two of the five patients (40%) who developed femoral vein thrombosis had a central venous line placed after the BAS procedure, which may have been a contributing factor to the observed complication. Our findings may have underestimated the exact prevalence of femoral vein thrombosis, as routine ultrasound screening for femoral vein thrombosis after BAS is not performed, only when clinically indicated. Therefore, occult femoral vein thrombosis or ultimate occlusions might have been missed retrospectively. Other risk factors for complications or adverse outcomes of BAS in previous studies included technical challenge, longer procedural duration, critical clinical condition, variation among operator, and gender (male).<sup>34,35</sup>

## 5 | LIMITATIONS

This study is subject to the limitations inherent to a retrospective single-center design. Additionally, this study did not assess and include the overall impact on costs, the comparison between daytime delivery and deliveries outside of regular office hours, and the procedural time.

## 6 | CONCLUSION

Performing BAS in TGA patients with the Z-5 balloon septostomy catheter, both at patient's bedside and in the cardiac catheterization laboratory, is feasible and safe with minimal major complication rate, irrespective of procedural location or the vascular access used. Considering the present scarcity of septostomy catheters, attributed to certain devices being recalled and changes in the European legal framework for medical devices, the classic Z-5 BAS catheter serves as a viable alternative where concerns about its bedside use are unwarranted.

### ACKNOWLEDGMENTS

We thank Haylee K. Tower (*NuMED for Children*) for providing the images of the Z-5 balloon atrial septostomy catheter.

### CONFLICT OF INTEREST STATEMENT

The authors declare no conflict of interest.

### DATA AVAILABILITY STATEMENT

The data that support the findings of this study are available on request from the corresponding author. The data are not publicly available due to privacy or ethical restrictions.

### ORCID

Jesse A. Weeda  <http://orcid.org/0009-0007-4262-1808>

Roel L. F. van der Palen  <http://orcid.org/0000-0003-3640-603X>

### REFERENCES

- Boehm W, Emmel M, Sreeram N. Balloon atrial septostomy: history and technique. *Images Paediatr Cardiol*. 2006;8(1):8-14.
- Cinteza E, Carminati M. Balloon atrial septostomy—almost half a century after. *Maedica*. 2013;8(3):280-284.
- Szymanski MW, Moore SM, Kritzmire SM, Goyal A. Transposition of the great arteries. 2023 Jan 15. *StatPearls [Internet]*. StatPearls Publishing; 2023.
- Rashkind WJ. Creation of an atrial septal defect without thoracotomy. A palliative approach to complete transposition of the great arteries. *JAMA*. 1966;196(11):991-992.
- Matter M, Almarsafawy H, Hafez M, Attia G, Elkhier MMA. Balloon atrial septostomy: the oldest cardiac interventional procedure in Mansoura. *Egypt Heart J*. 2011;63(2):125-129.
- <https://www.fda.gov/medical-devices/medical-device-recalls/medtronic-recalls-rashkind-balloon-septostomy-catheters-quality-issues>
- FDA Miller recall. Class 1 device recall Miller balloon atrioseptostomy catheter. Accessed October 23, 2023. 2019. <https://www.accessdata.fda.gov/scripts/cdrh/cfdocs/cfRes/res.cfm?ID=171709>
- FDA Fogarty recall. Class 1 device recall Fogarty dilation atrioseptostomy catheter. Accessed October 23, 2023. 2019. <https://www.accessdata.fda.gov/scripts/cdrh/cfdocs/cfres/res.cfm?id=171707>
- Inuzuka R, Tachimori H, Kim SH, et al. Practice and safety of static balloon atrial septostomy based on a nationwide registry data. *Circ J*. 2022;86(12):1990-1997. doi:10.1253/circj.CJ-22-0185
- Naimi I. Balloon atrial septostomy: the balloon size doesn't matter?! *CJC Pediatr Congenit Heart Dis*. 2022;1(6):260-262.
- Vitiello R, McCrindle BW, Nykanen D, Freedom RM, Benson LN. Complications associated with pediatric cardiac catheterization. *J Am Coll Cardiol*. 1998;32(5):1433-1440. doi:10.1016/s0735-1097(98)00396-9
- Kumar N, Shaikh AS, Kumari V, Patel N. Echocardiography guided bed side balloon atrial septostomy in dextro transposed great arteries (dTGA) with intact ventricular septum (IVS): a resource limited country experience. *Pak J Med Sci*. 2018;34(6):1347-1352. doi:10.12669/pjms.346.15792
- Marchi CH, Godoy MF, Santos MA, Moscardini AC, Hassen Sobrinho S, Croti UA. Monitoração ecocardiográfica da atrioseptostomia com balão. *Arq Bras Cardiol*. 2005;84(3):245-250. doi:10.1590/s0066-782x2005000300010
- Jamjureeruk V, Sangtawesin C, Layangool T. Balloon atrial septostomy under two-dimensional echocardiographic control: a new outlook. *Pediatr Cardiol*. 1997;18(3):197-200. doi:10.1007/s002469900148
- Hijazi ZM, Geggel RL, Aronovitz MJ, Marx GR, Rhodes J, Fulton DR. A new low profile balloon atrial septostomy catheter: initial animal and clinical experience. *J Invasive Cardiol*. 1994;6(6):209-212.
- Boshoff DE, Gewillig MH. Creating an Interatrial communication. In: Butera G, Chessa M, Eicken A, Thomson JD, eds. *Atlas of Cardiac Catheterization for Congenital Heart Disease*. Springer; 2019: 209-223. doi:10.1007/978-3-319-72443-025
- Feltes TF, Bacha E, Beekman 3rd, RH, et al. Indications for cardiac catheterization and intervention in pediatric cardiac disease: a

- scientific statement from the American Heart Association. *Circulation*. 2011;123:2607-2652.
18. Al-Kassmy J, Navarro-Castellanos I, Barlatay FG, Miró J, Dahdah N. Balloon atrial Septostomy: does the balloon size matter? *CJC Pediatr Congenit Heart Dis*. 2022;1(6):253-259. doi:10.1016/j.cjpc.2022.10.006
  19. Akagi T, Tananari Y, Maeno YV, et al. Torn-off balloon tip of Z-5 atrial septostomy catheter. *Catheter Cardiovasc Interv*. 2001;52(4):500-503. doi:10.1002/ccd.1112
  20. Ellison RC, Plauth Jr, WH, Gazzaniga AB, Fyler DC. Inability to deflate catheter balloon: a complication of balloon atrial septostomy. *J Pediatr*. 1970;76(4):604-606. doi:10.1016/s0022-3476(70)80412-7
  21. Zellers TM, Dixon K, Moake L, Wright J, Ramaciotti C. Bedside balloon atrial septostomy is safe, efficacious, and cost-effective compared with septostomy performed in the cardiac catheterization laboratory. *Am J Cardiol*. 2002;89(5):613-615. doi:10.1016/s0002-9149(01)02309-8
  22. Savorgnan F, Zaban NB, Elhoff JJ, Ross MM, Breinholt JP. No difference found in safety or efficacy of balloon atrial septostomy performed at the bedside versus the catheterisation laboratory. *Cardiol Young*. 2018;28(12):1421-1425. doi:10.1017/S1047951118001439
  23. Hickey EJ, Nosikova Y, Zhang H, et al. Very low-birth-weight infants with congenital cardiac lesions: is there merit in delaying intervention to permit growth and maturation? *J Thorac Cardiovasc Surg*. 2012;143(1):126-136.e1. doi:10.1016/j.jtcvs.2011.09.008
  24. Simpson JM, Moore P, Teitel DF. Cardiac catheterization of low birth weight infants. *Am J Cardiol*. 2001;87(12):1372-1377. doi:10.1016/s0002-9149(01)01555-7
  25. Kobayashi D, Sallaam S, Aggarwal S, et al. Catheterization-based intervention in low birth weight infants less than 2.5 kg with acute and long-term outcome. *Catheter Cardiovasc Interv*. 2013;82(5):802-810. doi:10.1002/ccd.25009
  26. Al-Ata J. Balloon atrial septostomy in patient with dextrotransposition of the great arteries with insufficient mixing: 18 years' experience. *J King Abdulaziz Univ Mar Sci*. 2010;17(4):73-89. doi:10.4197/med.17-4.6
  27. Mukherjee D, Lindsay M, Zhang Y, et al. Analysis of 8681 neonates with transposition of the great arteries: outcomes with and without Rashkind balloon atrial septostomy. *Cardiol Young*. 2010;20(4):373-380. doi:10.1017/S1047951110000296
  28. Hamzah M, Othman HF, Peluso AM, Sasmour I, Aly H. Prevalence and outcomes of balloon atrial septostomy in neonates with transposition of great arteries. *Pediatr Crit Care Med*. 2020;21(4):324-331. doi:10.1097/PCC.0000000000002191
  29. McQuillen PS, Hamrick SEG, Perez MJ, et al. Balloon atrial septostomy is associated with preoperative stroke in neonates with transposition of the great arteries. *Circulation*. 2006;113(2):280-285. doi:10.1161/CIRCULATIONAHA.105.566752
  30. Polito A, Ricci Z, Fragasso T, Cogo PE. Balloon atrial septostomy and pre-operative brain injury in neonates with transposition of the great arteries: a systematic review and a meta-analysis. *Cardiol Young*. 2012;22(1):1-7. doi:10.1017/S1047951111001909
  31. Vimalasvaran S, Ayis S, Krasemann T. Balloon atrial septostomy performed "out-of-hours": effects on the outcome. *Cardiol Young*. 2013;23(1):61-67. doi:10.1017/S1047951112000364
  32. Saxena A, Gupta R, Kumar RK, Kothari SS, Wasir HS. Predictors of arterial thrombosis after diagnostic cardiac catheterization in infants and children randomized to two heparin dosages. *Cathet Cardiovasc Diagn*. 1997;41(4):400-403. doi:10.1002/(sici)1097-0304(199708)41:4<400::aid-ccd11>3.0.co;2-p
  33. Petit CJ, Rome JJ, Wernovsky G, et al. Preoperative brain injury in transposition of the great arteries is associated with oxygenation and time to surgery, not balloon atrial septostomy. *Circulation*. 2009;119(5):709-716. doi:10.1161/CIRCULATIONAHA.107.760819
  34. Agnoletti G, Bonnet C, Boudjemline Y, et al. Complications of paediatric interventional catheterisation: an analysis of risk factors. *Cardiol Young*. 2005;15(4):402-408. doi:10.1017/S1047951105000843
  35. Mehta R, Lee KJ, Chaturvedi R, Benson L. Complications of pediatric cardiac catheterization: a review in the current era. *Catheter Cardiovasc Interv*. 2008;72(2):278-285. doi:10.1002/ccd.21580

## SUPPORTING INFORMATION

Additional supporting information can be found online in the Supporting Information section at the end of this article.

**How to cite this article:** Weeda JA, Bokenkamp-Gramann R, Straver BB, et al. Balloon atrial septostomy for transposition of the great arteries: safety and experience with the Z-5 balloon catheter. *Catheter Cardiovasc Interv*. 2023;1-9. doi:10.1002/ccd.30932