



Universiteit
Leiden
The Netherlands

Association of interosseous tendon inflammation in the hand with different early arthritides in a 10-year magnetic resonance imaging study

Dijk, B.T. van; Reijnierse, M.; Helm-van Mil, A.H.M. van der


Citation

Dijk, B. T. van, Reijnierse, M., & Helm-van Mil, A. H. M. van der. (2023). Association of interosseous tendon inflammation in the hand with different early arthritides in a 10-year magnetic resonance imaging study. *Arthritis & Rheumatology*, 75(11), 1935-1946.
doi:10.1002/art.42626

Version: Publisher's Version
License: [Creative Commons CC BY-NC 4.0 license](#)
Downloaded from: <https://hdl.handle.net/1887/3714423>

Note: To cite this publication please use the final published version (if applicable).

Association of Interosseous Tendon Inflammation in the Hand With Different Early Arthritides in a 10-Year Magnetic Resonance Imaging Study

Bastiaan T. van Dijk,¹  Monique Reijniere,² and Annette H. M. van der Helm-van Mil³

Objective. Inflammation around the tendons of the hand interosseous muscles (interosseous tendon inflammation [ITI]) was recently identified on magnetic resonance imaging (MRI) in a set of patients with rheumatoid arthritis (RA) and arthralgia. We conducted a large MRI study to assess the prevalence of ITI at diagnosis of RA and of other arthritides, as well as its relationship with clinical signs.

Methods. A total of 1,205 patients presenting with various types of early arthritis between 2010 and 2020 underwent contrast-enhanced hand MRI as part of the prospective Leiden Early Arthritis Cohort. MRI was evaluated with blinding for clinical data, for ITI lateral of metacarpophalangeal (MCP) joints 2–5, and for synovitis/tenosynovitis/osteitis. We assessed ITI presence at baseline per diagnosis and its relationship with clinical characteristics (ie, presence of hand arthritis, increased acute phase reactants, and local joint swelling and tenderness). Logistic regression and generalized estimating equations were used with adjustment for age and established local inflammation features (synovitis/tenosynovitis/osteitis).

Results. A total of 36% of patients with early RA ($n = 532$) had ITI; this was similar in patients with anti-citrullinated protein antibody (ACPA)-negative RA (37%) and those with ACPA-positive RA (34%; $P = 0.53$). ITI occurred regularly in remitting seronegative symmetrical synovitis with pitting edema (60%) and connective tissue diseases (44%) and less frequently in undifferentiated arthritis (14%), psoriatic arthritis (14%), inflammatory osteoarthritis (8%), reactive arthritis (7%), crystal arthritis (7%), and peripheral spondylarthritis (4%). ITI occurred more often in diagnoses with frequent arthritis of the hands ($P < 0.001$) and increased acute-phase reactants ($P < 0.001$). Within RA, ITI occurred together with local MCP joint synovitis (odds ratio [OR] 2.4, 95% confidence interval [95% CI] 1.7–3.4), tenosynovitis (OR 2.4, 95% CI 1.8–3.3), and osteitis (OR 2.2, 95% CI 1.6–3.1) on MRI. Moreover, ITI presence was associated with local MCP joint tenderness (OR 1.6, 95% CI 1.2–2.1) and swelling (OR 1.8, 95% CI 1.3–2.6), independent of age and MRI-detected synovitis/tenosynovitis/osteitis.

Conclusion. ITI occurs regularly in RA and other arthritides with preferential involvement of hand joints and increased acute-phase reactants. At the MCP joint level, ITI associates independently with joint tenderness and swelling. Hence, ITI is a newly identified inflamed tissue mainly found in arthritides with particularly extensive and symptomatic inflammation.

INTRODUCTION

The clinical picture in various diseases with inflammatory arthritis is traditionally considered to result from inflammation of the intra-articular synovium (1). During the last decade, however, imaging and anatomical studies have shown that several tissues around the joint also have a synovial lining and can become inflamed, especially in rheumatoid arthritis (RA). The tenosynovial

sheaths around the tendons of the metacarpophalangeal (MCP), wrist and metatarsophalangeal (MTP) joints are such juxta-articular synovial tissues (2). Similarly, the intermetatarsal bursae located between the MTP joints possess a synovial lining (3). Inflammation of these juxta-articular tissues (ie, tenosynovitis and intermetatarsal bursitis) is found in the majority of patients with RA and independently explains typical clinical features such as joint tenderness and swelling (4–7). Moreover, tenosynovitis and

This work was supported by the European Research Council under the European Union's Horizon 2020 research and innovation program (Starting Grant, agreement 714312) and by the Dutch Arthritis Society.

¹Bastiaan T. van Dijk, MD: Rheumatology, Leiden University Medical Center (LUMC), Leiden, The Netherlands; ²Monique Reijniere, MD, PhD: Radiology, LUMC, Leiden, The Netherlands; ³Annette H. M. van der Helm-van Mil, MD, PhD: Rheumatology, LUMC, Leiden, The Netherlands and Rheumatology, Erasmus Medical Centre, Rotterdam, The Netherlands.

Author disclosures are available at <https://onlinelibrary.wiley.com/doi/10.1002/art.42626>.

Address correspondence via email to Bastiaan T. van Dijk, MD, at B.T.van_Dijk@lumc.nl.

Submitted for publication November 17, 2022; accepted in revised form June 6, 2023.

intermetatarsal bursitis contribute to functional impairments (8,9). This suggests that juxta-articular synovial inflammation is an increasingly recognized feature of RA that, in addition to intra-articular synovitis, aids to improve our understanding of the clinical presentation and pathophysiology of RA.

Interestingly, magnetic resonance imaging (MRI) studies have recently described inflammation around the tendons of the interosseous muscles in the hand (interosseous tendon inflammation [ITI]) in a set of patients with arthralgia or RA (10–12). The interosseous muscles have their origin on the metacarpal bones and transition into tendons that run adjacent to the radial and ulnar sides of the second through fifth MCP joints. Distally from

the MCP joint, they insert on the proximal phalanx and/or extensor aponeurosis, which is subject to anatomical variation. A schematic anatomical illustration of the interosseous muscles is presented in Figure 1A and B. The main actions of the interosseous muscles and tendons are finger abduction and adduction. Additionally, they provide stability to the fingers by supporting flexion at the MCP joints and extension at the proximal interphalangeal joints (13).

Inflammation around interosseous tendons was recently described in a set of patients with RA from Leeds, supporting the existence of ITI (10). In addition, ITI already occurs in the symptomatic at-risk stage preceding clinical arthritis/RA

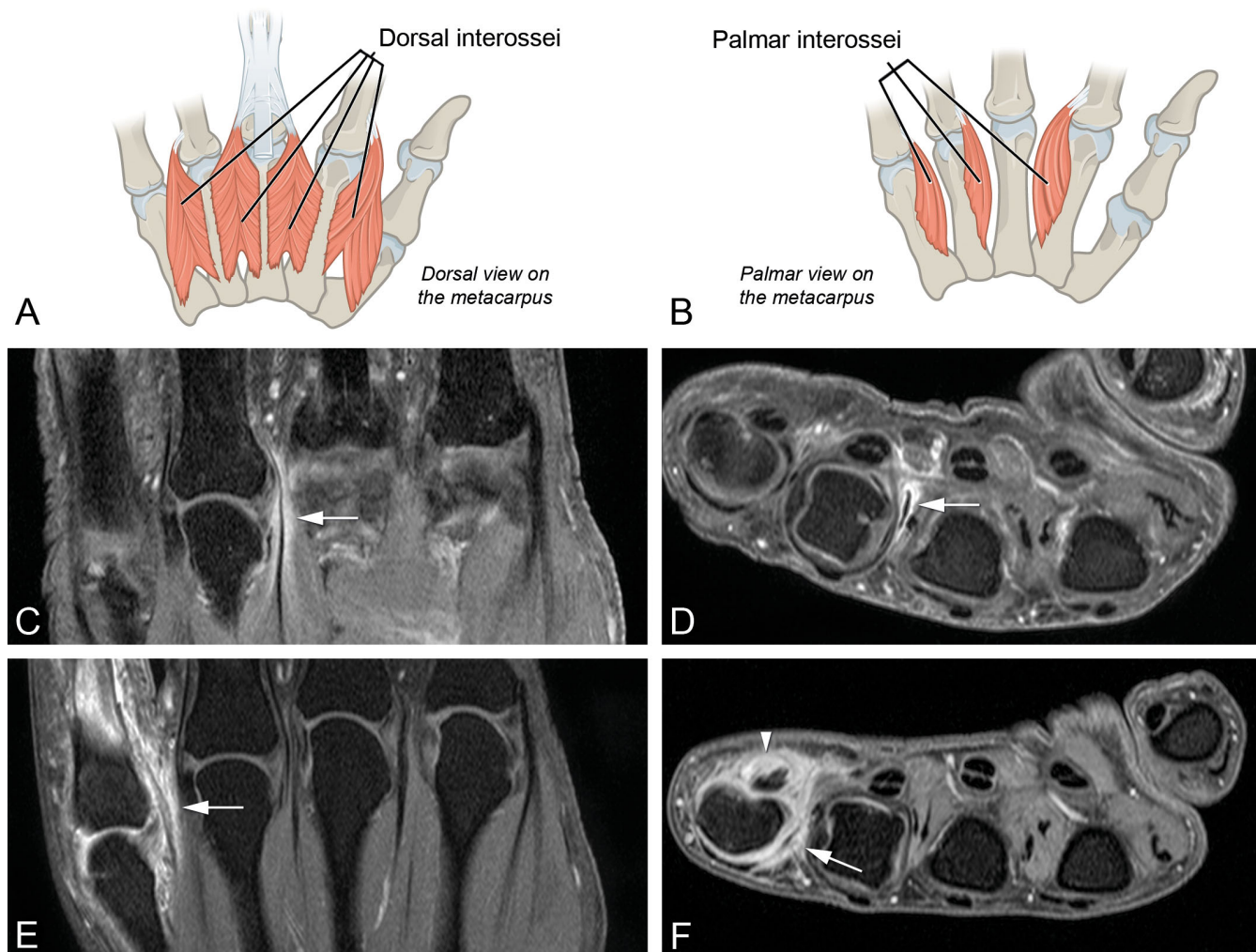


Figure 1. Schematic anatomical illustrations of the dorsal (A) and palmar interossei (B) and example magnetic resonance images of patients with rheumatoid arthritis with interosseous tendon inflammation (ITI) occurring at metacarpophalangeal 4 (MCP4) (C and D) without other inflammation features and at MCP5 (E and F), together with synovitis and flexor tenosynovitis, are shown. Shown are T1-weighted, fat-suppressed images after gadolinium administration at the level of the MCP joints. Coronal (C and D) and axial images (E and F) of the same patient are shown (C–F). The white arrows represent contrast enhancement around the interosseous tendon consistent with ITI. F, The white arrowhead represents contrast enhancement around the flexor tendon consistent with flexor tenosynovitis. The source image for A and B was derived from the digital book *Anatomy and Physiology*, which is published by OpenStax under a Creative Commons Attribution 4.0 International License, allowing reuse and adaptation under the condition of attribution (37). The source image was edited. Access for free at <https://openstax.org/books/anatomy-and-physiology/pages/1-introduction>.

development (11,12), further increasing the interest in this novel inflamed tissue. Besides these few observations, however, ITI remains an elusive phenomenon, making it difficult to determine its potential implications for clinical care and research in rheumatology. We aimed to improve this by elucidating which types of early arthritis and clinical features ITI associates with. In a large MRI study of ITI in patients with RA as well as other early arthritides from an entire health care region presenting over 10 years, we assessed the following unknown characteristics of ITI: 1) the prevalence in RA, 2) the frequency in other diagnoses with inflammatory arthritis, 3) the relation with established imaging features of local inflammation (synovitis, tenosynovitis, and osteitis), and 4) the relation with key clinical features of inflammatory arthritis, namely, joint tenderness and swelling and reduced hand functioning.

PATIENTS AND METHODS

Patients. The Leiden Early Arthritis Cohort (EAC) is a Dutch inception cohort based in the Leiden University Medical Center (LUMC) that has enrolled patients with clinically apparent arthritis of recent onset since 1993 and was extensively described previously (4,14). All patients presenting with clinically apparent inflammatory arthritis were eligible, except for those with long-standing arthritis (symptom duration ≥ 2 years) or evident gout, inflammatory osteoarthritis (OA), or posttraumatic arthritis. Throughout the study period, the LUMC has been the only rheumatology referral center in a health care region of approximately 400,000 inhabitants. Short waiting times and a weekly walk-in early arthritis recognition clinic provide optimal accessibility. This approach yields a relatively short symptom duration upon inclusion and ensures that patients with early arthritis preferentially visit the LUMC instead of hospitals in other regions. All in all, the EAC comprises a representative sample of almost the entire spectrum of early inflammatory arthritis.

Patients presenting from August 2010 to March 2020 received contrast-enhanced MRI of the hand (wrist and MCP joints 2–5) according to the study protocol. A total of 1,205 patients with early arthritis had MRI of sufficient quality available and were analyzed in the current study. In the same period, 477 patients were included in the cohort but excluded from the current study, mostly because of contraindications for undergoing MRI; a flowchart is presented in Supplementary Figure 1, available on the *Arthritis & Rheumatology* website at <http://onlinelibrary.wiley.com/doi/10.1002/art.42626>. Excluded patients had similar baseline characteristics as those who were included (Supplementary Table 1, <http://onlinelibrary.wiley.com/doi/10.1002/art.42626>).

Patient characteristics, disease activity parameters, and blood samples were collected at baseline shortly before the MRI scan. Tender and swollen joint counts (68 and 66 joints, respectively) were assessed upon physical examination, and

serum was analyzed for C-reactive protein (CRP), erythrocyte sedimentation rate (ESR), immunoglobulin (Ig) G anti-citrullinated protein antibodies (ACPAs), and IgM rheumatoid factor. In addition, patients filled out questionnaires including the Health Assessment Questionnaire Disability Index (HAQ-DI). Follow-up visits were scheduled after 4 months, 12 months, and yearly thereafter.

The study complied with the Declaration of Helsinki, and all participants provided written informed consent. The Leiden EAC protocol was approved by the LUMC's Medical Ethics Committee (B19.008).

Diagnoses. Diagnoses were retrieved from the medical files of the treating rheumatologist during the first year of follow-up. MR images and data were not considered when determining the diagnosis because these were not disclosed to patients and clinicians. RA was defined as clinical diagnosis plus fulfilment of the American Rheumatism Association 1987 and/or American College of Rheumatology/European League Against Rheumatism 2010 classification criteria (15,16). The other clinical diagnoses were based on the expertise of the treating rheumatologist. Undifferentiated arthritis (UA) was defined as not fulfilling the 1987 and 2010 classification criteria and not having an alternative diagnosis (17). Because of the low frequency of connective tissue diseases in our cohort, these conditions were analyzed as a single diagnostic group. The most frequent diagnoses in this group were undifferentiated connective tissue disease ($n = 5$), systemic lupus erythematosus (SLE; $n = 5$), systemic sclerosis (SSc; $n = 4$), Sjögren's syndrome ($n = 4$), mixed connective tissue disease (MCTD; $n = 4$), and different overlap connective tissue disease syndromes ($n = 8$; e.g., SSc with features of myositis).

MRI and ITI. Contrast-enhanced unilateral 1.5T MRI (ONI, GE) was made at baseline of the MCP joints 2–5 and wrist joints on the side with the most symptoms or the dominant side in case of symmetrical symptom severity. The scanning protocol is described in more detail in Supplementary Methods 1, available on the *Arthritis & Rheumatology* website at <http://onlinelibrary.wiley.com/doi/10.1002/art.42626>.

MRI was evaluated with blinding for clinical data. ITI was scored at the radial and ulnar sides of the second through fifth MCP joint, in line with the previously described approach (11). ITI was defined as contrast enhancement around the interosseous tendon, present in both the axial and coronal plane and two or more consecutive slices. According to the literature, we included the abductor digiti minimi tendon in our assessments because it functions as dorsal interosseus for the fifth digit (10,11,18). The presence/absence of ITI was recorded for each of the eight tendons by a single reader who is a medical doctor trained in reading extremity MRI and previously evaluated >800 MRIs for ITI in collaboration with a musculoskeletal radiologist with >20 years of experience (12). This method thus resulted in a number ranging

0 to 8, depicting the number of interosseous tendons with inflammation in the patient. Intrareader reliability was assessed by rescoring a set of 30 MRIs for ITI, which yielded an intraclass correlation coefficient (ICC) of 0.98.

Because of the relatively low frequency of inflammation around more than one interosseous tendon in a single patient, the number of locations with ITI was dichotomized for analyses. From here onward, in patient level analyses, ITI presence signifies the presence of ITI at one or more interosseous tendons. In MCP joint level analyses, ITI presence signifies the presence of inflammation around at least one of the two interosseous tendons adjacent to the MCP joint.

In addition, MRIs were evaluated for synovitis, tenosynovitis, and osteitis in line with the RA MRI scoring system (RAMRIS) by two independent trained readers, as reported previously (19–21). Scores of the individual locations in the hand were summed to obtain total scores for synovitis, tenosynovitis, and osteitis. Average scores of the two readers were used for analyses at patient level. Interreader ICCs were ≥ 0.94 for synovitis, ≥ 0.95 for tenosynovitis, and ≥ 0.83 for osteitis (Supplementary Table 2, <http://onlinelibrary.wiley.com/doi/10.1002/art.42626>). Details on the RAMRIS are described in Supplementary Methods 1, available on the *Arthritis & Rheumatology* website at <http://onlinelibrary.wiley.com/doi/10.1002/art.42626>. ITI and the RAMRIS features (synovitis, tenosynovitis, and osteitis) were scored by different readers without knowledge of the scores by other readers.

For analyses at the joint level, dichotomous absence/presence of MRI-detected synovitis, tenosynovitis, and osteitis was used, which was calculated using an adjustment for presence in the general population. To remove normal variation and thus study disease-related MRI inflammation, positivity for these features at the joint level was determined using measurements from the general population as a reference. MRI features were considered positive if scored by both readers and if present in $<5\%$ of age-matched, symptom-free controls at the same location, as described previously (22). These reference scores were developed using measurements in 193 symptom-free controls from the general population, who were scanned with the same MRI machine and protocol as in the current study and whose MRIs were also evaluated using the RAMRIS method (23). For ITI, the same method was used to adjust for presence in the general population. However, because of the near absence of ITI in the general population (prevalence approximately 1%), scores for ITI were the same with the reference as without the reference, as described previously (12). As such, any ITI lesion scored on MRI was considered “positive.”

ITI across diagnoses. The frequency of ITI presence was studied per diagnosis. We hypothesized that possible differences in ITI presence between diagnoses could be partly related to variations in the distribution and extent of inflammation pertaining to

the underlying disease. For example, involvement of the hands is typical for RA, whereas it is not for sarcoid arthritis. Although inflammatory OA often involves the hands, signs of systemic inflammation are rare in comparison to RA. Because of the location of ITI (in the hands) and the underlying pathological mechanism (inflammation), we expected to find more ITI in arthritic diseases that involve the hands and/or are associated with more extensive inflammation. To test this, the prevalence of ITI per diagnosis was plotted in relation to the frequency of hand arthritis (at least one swollen wrist, MCP, or proximal or distal interphalangeal joint) and/or presence of acute-phase reactants (increased CRP or ESR) within that diagnosis at baseline.

Taking into account that clinical heterogeneity does not just occur between diagnoses but also between patients with the same diagnosis, associations of ITI presence with clinical hand arthritis and increased acute-phase reactants were also studied within groups of patients with the same diagnosis.

The relation of ITI with other inflamed tissues as detected with imaging. Before ITI was first observed in patients with RA and individuals at risk of developing RA, three other forms of MRI-detected local inflammation in the hand have been described extensively in the literature as “established” RA features: synovitis, tenosynovitis, and osteitis (21). Especially tenosynovitis and synovitis are strongly associated with symptoms related to RA and other arthritic diseases (24–26). Therefore, to better understand the place of ITI in pathophysiology and symptomatology, we believe it is essential to first know its relationship with synovitis, tenosynovitis, and osteitis. These relations were assessed at MCP joint level. ITI was considered to be present at the MCP joint level if at least one of the two adjacent tendons had ITI on MRI.

The relation of ITI with clinical features. Next, to elucidate the possible contribution of ITI to clinical features, we investigated whether ITI presence associates with local joint tenderness and swelling at the level of the MCP joints (second through fifth) upon physical examination. In addition, we questioned whether presence of ITI may contribute to the patient-reported disease burden. For this, we studied reduced hand functioning measured by domains of the HAQ-DI specifically related to daily living activities that require the hands: “dressing/grooming,” “eating,” and “grip” (27,28). The eight questions on these domains were filled out by patients on a four-point scale of experienced difficulties, with “0” indicating no difficulties and “3” indicating full disability. In line with the total HAQ-DI score, the HAQ-DI score for reduced hand functioning was calculated as the average of the maximum scores in each domain and ranged 0–3 (29).

Because the extent of local inflammation, clinical involvement of MCP joints, and physical functioning may not be merely impacted by ITI but are known to differ between different arthritic diseases, analyses on associations of ITI with other inflamed

tissues with local MCP tenderness and swelling and with reduced physical functioning were done within groups of patients with the same diagnosis that had sufficient sample size: RA, UA, and psoriatic arthritis (PsA).

Analyses within patients with RA were repeated separately for those with ACPA-positive RA and those with ACPA-negative RA because these may be considered different entities based on differences in pathophysiology and outcomes (30,31).

Statistical analyses. The Cochran-Armitage test was used to assess whether diagnoses with higher frequencies of hand arthritis and acute-phase reactants were more likely to involve ITI (32,33). Associations between ITI and physical examination (joint tenderness and swelling) were assessed at joint level using generalized estimating equations (GEEs) wherein each patient contributed four MCP joints. Multivariable GEE models were used to adjust for simultaneous presence of the different MRI-detected inflamed tissues. The patient-level relation between ITI presence and reduced hand functioning was assessed using linear regression. An additional linear regression analysis assessed whether the presence of ITI at two or more locations was associated with reduced hand functioning. Synovitis, tenosynovitis, and osteitis were analyzed dichotomously (present/absent) in joint level analyses for tenderness/swelling and as semi-continuous scores in patient level analyses for reduced hand functioning measured with the HAQ.

IBM SPSS (version 25) was used. Two-sided P value less than 0.05 was considered statistically significant.

RESULTS

Patients. Baseline characteristics per diagnosis are presented in Table 1. The largest group consisted of patients with RA (44%; $n = 532$). Among them, 64% were female, and the mean \pm SD age was 59 ± 14 years.

Frequencies of ITI per diagnosis. A total of 36% of patients with RA (191 of 532) had at least one MRI-detected ITI. The prevalence was similar in patients ACPA-negative RA (37%) and those with ACPA-positive RA (34%; $P = 0.53$). The prevalence of ITI was also similar in patients with RA who fulfilled the 1987 criteria (39%) and those who fulfilled the 2010 criteria (36%; no P value was calculated because of the overlapping groups).

ITI also occurred regularly in remitting seronegative symmetrical synovitis with pitting edema (RS3PE; 60%) and connective tissue diseases (44%). ITI was less frequent in UA (14%), PsA (14%), inflammatory OA (8%), reactive arthritis (7%), crystal arthritis (7%), and peripheral spondylarthritis (4%). No ITI was found in patients with sarcoid arthritis. The number of tendons with ITI per diagnosis is depicted in Figure 2, showing that inflammation around at least two interosseous tendons was uncommon

(<5%) in most diagnoses but occurred regularly in ACPA-positive and ACPA-negative RA, RS3PE, and connective tissue diseases.

Next, the frequency of ITI per diagnosis was plotted against the observed frequency of clinical hand arthritis, showing that diagnoses that more often involve hand arthritis are generally associated with higher frequencies of ITI ($P < 0.001$; Figure 3A). ITI frequency per diagnosis was also associated with the presence of systemic inflammation, measured by acute-phase reactants ($P < 0.001$; Figure 3B). The relation of the combined presence of hand arthritis and acute phase reactants with the prevalence of ITI was particularly evident ($P < 0.001$; Figure 3C). Also, in groups of patients with the same diagnosis, clinical hand arthritis and increased acute-phase reactants were positively associated with the presence of ITI (Supplementary Table 4, <http://onlinelibrary.wiley.com/doi/10.1002/art.42626>). Thus, ITI occurs mostly in arthritis diagnoses characterized by preferential involvement of hand joints and with frequent systemic inflammation and in individual patients with these characteristics.

ITI in relation to other MRI-detected inflammation.

In patients with RA, ITI was more often present at MCP joints with synovitis, tenosynovitis, or osteitis on MRI (Table 2). Moreover, multivariable analyses showed that all three features were associated with ITI presence at the same MCP joint, independent of co-occurrence with each other (synovitis odds ratio [OR] 2.4, 95% confidence interval [95% CI] 1.7–3.4; tenosynovitis OR 2.4, 95% CI 1.8–3.3; and osteitis OR 2.2, 95% CI 1.6–3.1). The more different joint tissues were inflamed, the more likely it was that ITI was also present at the same joint ($P < 0.001$; Figure 4A). Hence, within RA, ITI occurred predominantly in joints with extensive local inflammation.

Similar findings were observed in patients with ACPA-positive RA and those with ACPA-negative RA (Supplementary Table 5, <http://onlinelibrary.wiley.com/doi/10.1002/art.42626>), those with UA, and those with PsA (Supplementary Figure 2 and Supplementary Tables 6 and 7, <http://onlinelibrary.wiley.com/doi/10.1002/art.42626>).

Example MR images of ITI, both solitary and together with local synovitis and tenosynovitis, are presented in Figure 1C–F.

Clinical signs. Within patients with RA, MCP joints with ITI were more often tender (OR 2.0, 95% CI 1.5–2.6) and swollen (OR 2.4, 95% CI 1.8–3.3). Multivariable analyses showed that the associations of ITI with MCP tenderness and swelling were independent of age and simultaneous presence of other MRI-detected inflamed tissues that may contribute to findings at joint examination (OR 1.6, 95% CI 1.2–2.1 for tenderness; and OR 1.8, 95% CI 1.3–2.6 for swelling). In addition, the number of inflamed joints in/around MCP joints was associated with the likelihood of an MCP joint being tender ($P < 0.001$; Figure 4B) and swollen ($P < 0.001$; Figure 4C).

Table 1. Baseline characteristics of early arthritis patients according to diagnosis*

Characteristic	Connective tissue diseases (n = 32)†									
	RA (n = 532)	RS3PE (n = 25)	UA (n = 311)	PsA (n = 87)	pSpA (n = 24)	Reactive arthritis (n = 30)	Sarcoidosis (n = 10)	Crystal arthritis (n = 44)	Inflammatory OA (n = 74)	
Age, y, mean ± SD	59 ± 14	74 ± 7	54 ± 15	49 ± 15	38 ± 14	47 ± 15	46 ± 13	60 ± 12	66 ± 11	
Female, n (%)	341 (64)	8 (32)	170 (55)	38 (44)	11 (46)	18 (60)	6 (60)	7 (16)	43 (58)	
Symptom duration, wk, median (IQR)	12 (6–29)	6 (3–10)	9 (4–23)	16 (7–47)	13 (5–42)	4 (2–7)	3 (3–4)	8 (3–15)	21 (4–32)	
TJC-68, median (IQR)	8 (4–13)	10 (3–20)	2 (1–4)	5 (2–8)	3 (2–5)	3 (1–7)	6 (5–7)	2 (1–6)	4 (2–9)	
SJC-66, median (IQR)	5 (2–10)	8 (5–17)	2 (1–3)	2 (1–5)	2 (1–4)	2 (1–4)	2 (2–6)	2 (1–4)	3 (1–4)	
Arthritis in ≥ 1 hand† joint, n (%)	482 (91)	25 (100)	221 (71)	66 (76)	11 (46)	15 (50)	3 (30)	30 (68)	67 (91)	
ESR, median (IQR)	28 (11–41)	45 (34–56)	11 (6–25)	17 (6–33)	33 (9–60)	21 (9–33)	30 (14–45)	16 (6–33)	9 (4–16)	
ACPA positive, n (%)	253 (48)	2 (8)	6 (2)	2 (2)	1 (1)	0 (0)	0 (0)	1 (2)	0 (0)	
RF positive, n (%)	293 (55)	3 (12)	15 (5)	13 (15)	2 (8)	3 (10)	1 (10)	9 (20)	13 (18)	

* ACPA = anti-citrullinated protein antibody; DIP = distal interphalangeal; ESR = erythrocyte sedimentation rate; IQR = interquartile range; MCP = metacarpophalangeal; MCTD = mixed connective tissue disease; OA = osteoarthritis; PIP = proximal interphalangeal; PsA = psoriatic arthritis; pSpA = peripheral spondylarthritis; RA = rheumatoid arthritis; RF = rheumatoid factor; RS3PE = remitting seronegative symmetrical synovitis with pitting edema; SJC = swollen joint count; SLE = systemic lupus erythematosus; TJC = tender joint count; UA = undifferentiated arthritis; UCTD = undifferentiated connective tissue disease.

† Wrist, MCP, PIP, or DIP joint.

‡ The connective tissue diseases UCTD, SLE, systemic sclerosis, Sjögren's syndrome, and MCTD were the most frequent diagnoses.

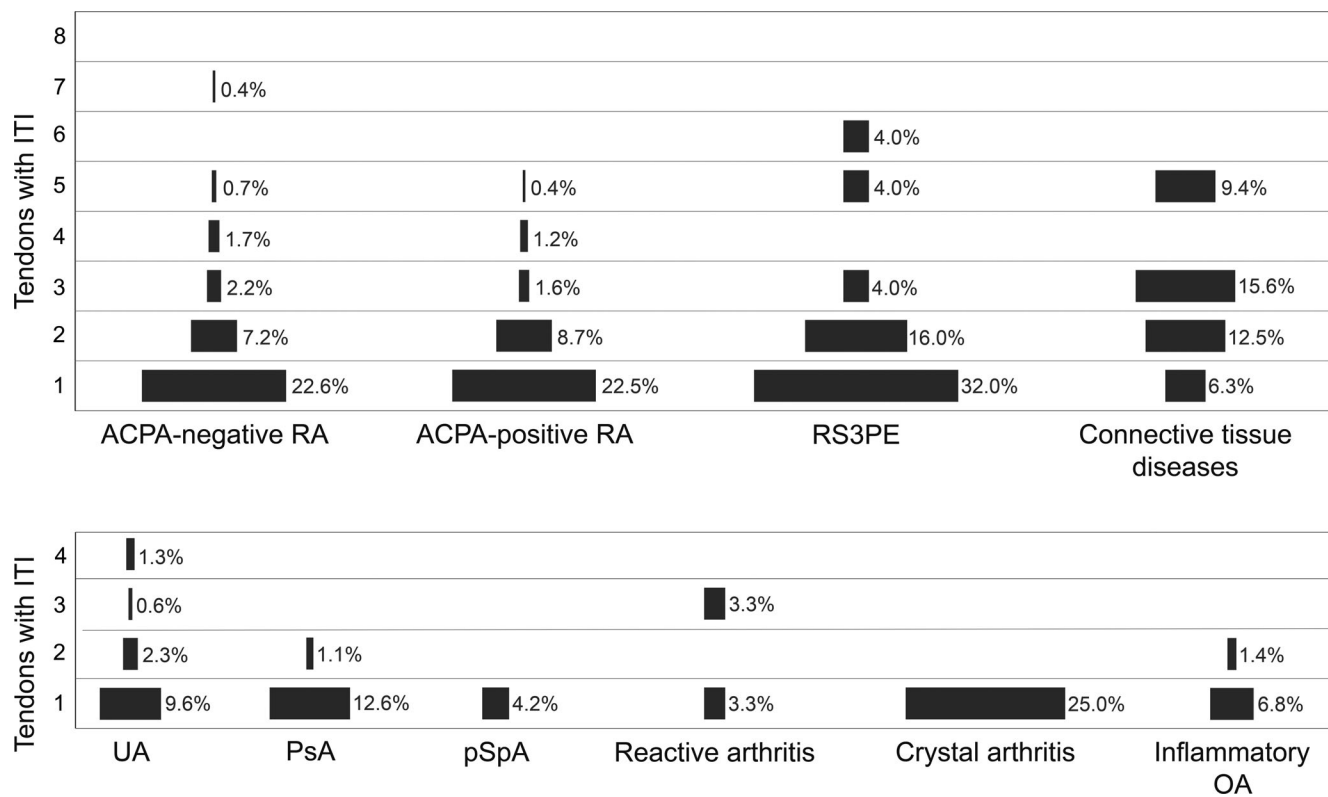


Figure 2. The number of tendons with interosseous tendon inflammation (ITI) per diagnosis. The width of the bars is proportionate to the percentage of patients within each diagnosis who had the depicted number of locations with ITI on magnetic resonance imaging. Patients without ITI (no tendons with ITI) are not depicted; therefore, the percentages do not add up to 100%. The connective tissue diseases undifferentiated connective tissue disease, systemic lupus erythematosus, systemic sclerosis, Sjögren's syndrome, and mixed connective tissue disease were the most frequent diagnoses. ACPA = anti-citrullinated protein antibody; OA = osteoarthritis; PsA = psoriatic arthritis; pSpA = peripheral spondylarthritis; RA = rheumatoid arthritis; RS3PE = remitting seronegative symmetrical synovitis with pitting edema; UA = undifferentiated arthritis.

Finally, patients with RA with ITI had reduced hand functioning compared with those without ITI (0.18 points higher mean hand functioning score; 95% CI 0.05–0.30). In multivariable analyses, this association was not statistically independent of synovitis and tenosynovitis ($\beta = 0.05$, 95% CI -0.08 to 0.18), suggesting a limited contribution of ITI to reduced hand functioning. In contrast, the tenosynovitis score was independently associated with worse hand functioning ($\beta = 0.02$, 95% CI -0.00 to 0.04 per point of the tenosynovitis score, $P = 0.019$; Supplementary Table 8A, <http://onlinelibrary.wiley.com/doi/10.1002/art.42626>). Additional analyses explored whether having ITI at multiple locations (at least two interosseous tendons) was independently associated with worse hand functioning; this was not the case ($\beta = 0.04$, 95% CI -0.15 to 0.22 ; Supplementary Table 8B, <http://onlinelibrary.wiley.com/doi/10.1002/art.42626>).

Associations with joint tenderness and swelling and hand functioning were similar in patients with ACPA-positive RA and those with ACPA-negative RA (Supplementary Table 9, <http://onlinelibrary.wiley.com/doi/10.1002/art.42626>) and in patients with UA and patients with PsA (Supplementary Figure 2 and

Supplementary Tables 10 and 11, <http://onlinelibrary.wiley.com/doi/10.1002/art.42626>).

DISCUSSION

Although inflammation of the intra-articular synovium is generally considered the most eminent feature of RA, modern imaging research has expanded this classical view on RA by showing that juxta-articular inflammation is also prevalent (4,5). Recently, ITI was described in the hands of patients with RA or who were at risk for RA (11,12). By examining a large sample of subsequently presenting patients with early arthritis who underwent MRI, the current study estimated the prevalence of ITI in RA at diagnosis at 36% (34% in patients who were ACPA positive and 37% in those who were ACPA negative). In addition, we showed for the first time that ITI is not confined to RA but is even more prevalent in other arthritides and occurs especially in patients with arthritis of the hand joints as well as increased acute-phase reactants (eg, RS3PE and connective tissue diseases such as SLE and MCTD). Furthermore, although ITI often occurs together with

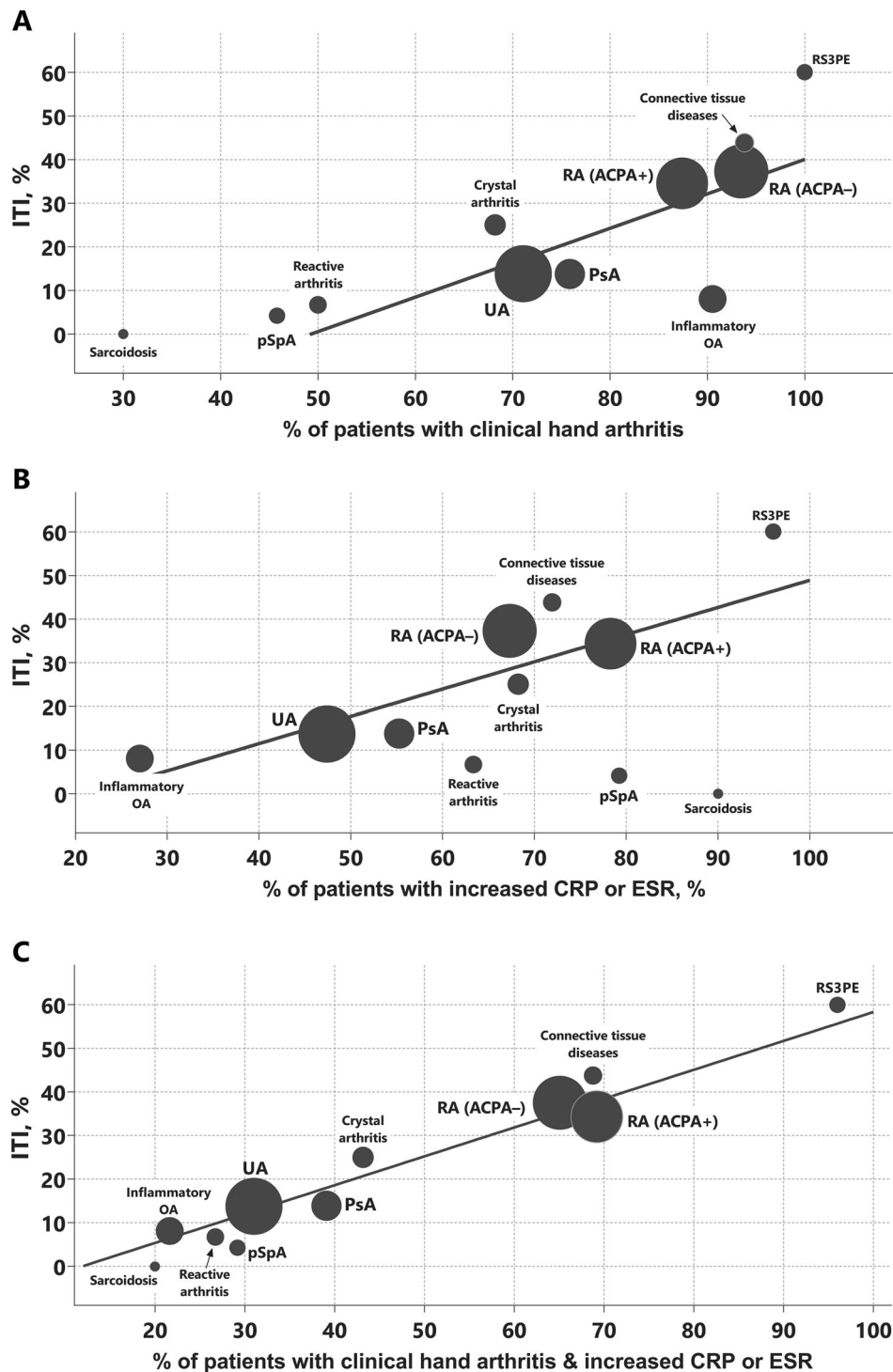


Figure 3. The frequency of interosseous tendon inflammation (ITI) presence per diagnosis according to the following: the frequency of clinical hand arthritis (A) the frequency of increased C-reactive protein (CRP) or erythrocyte sedimentation rate (ESR) (B) and the frequency of combined clinical hand arthritis and increased CRP or ESR (C). The ITI presence was, on average, more likely in diagnoses with higher frequencies of clinical hand arthritis, increased CRP or ESR, or both clinical hand arthritis and increased CRP or ESR (all $P < 0.001$ by Cochran–Armitage test). To illustrate these associations, the best fit linear trend lines are shown. The surface area of the dots is proportionate to group size. Frequencies per diagnosis are presented numerically in Supplementary Table 3, available on the *Arthritis & Rheumatology* website at <http://onlinelibrary.wiley.com/doi/10.1002/art.42626>. The connective tissue diseases undifferentiated connective tissue disease, systemic lupus erythematosus, systemic sclerosis, Sjögren’s syndrome, and mixed connective tissue disease were the most frequent diagnoses. ACPA– = negative for anti-citrullinated autoantibodies; ACPA+ = positive for anti-citrullinated autoantibodies; OA = osteoarthritis; PsA = psoriatic arthritis; pSpA = peripheral spondylarthritis; RA = rheumatoid arthritis; RS3PE = remitting seronegative symmetrical synovitis with pitting edema; UA = undifferentiated arthritis.

Table 2. ITI in patients with RA particularly occurs together with other locally inflamed tissues at the same MCP joint and associates independently with local tenderness and swelling*

	Univariable OR (95% CI)	Multivariable OR (95% CI)†
ITI presence		
Synovitis	3.5 (2.6–4.8)‡	2.4 (1.7–3.4)‡
Tenosynovitis	3.1 (2.3–4.1)‡	2.4 (1.8–3.3)‡
Osteitis	3.4 (2.5–4.8)‡	2.2 (1.6–3.1)‡
MCP tenderness		
ITI	2.0 (1.5–2.6)‡	1.6 (1.2–2.1)‡
Synovitis	1.5 (1.1–2.0)‡	1.1 (0.8–1.4)
Tenosynovitis	2.2 (1.7–2.7)‡	1.9 (1.5–2.4)‡
Osteitis	2.6 (1.8–3.6)‡	2.0 (1.5–2.9)‡
MCP swelling		
ITI	2.4 (1.8–3.3)‡	1.8 (1.3–2.6)‡
Synovitis	2.6 (1.9–3.7)‡	1.9 (1.4–2.6)‡
Tenosynovitis	2.6 (2.0–3.4)‡	2.3 (1.8–3.0)‡

* Analyses were conducted at the joint level (metacarpophalangeal [MCP] joints) using generalized estimating equations (GEEs) with logit link. The odds ratio (OR) represents the increase in the odds of the concerned outcome (interosseous tendon inflammation [ITI] presence and MCP tenderness or swelling) when a particular magnetic resonance imaging (MRI) feature is present. The multivariable model for MCP tenderness in addition had age and binary presence of ITI, synovitis, tenosynovitis, and osteitis at the MCP joint as separate independent variables. The multivariable model for MCP swelling had age and binary presence of ITI, synovitis, and tenosynovitis at the MCP joint as separate independent variables. 95% CI = 95% confidence interval; RA = rheumatoid arthritis.

† The multivariable model for ITI presence had binary presence of synovitis, tenosynovitis, and osteitis at the MCP joint as separate independent variables.

‡ Associations were statistically significant at the 0.05 level.

other inflamed tissues at the joint level (synovitis, tenosynovitis, and osteitis), we showed that ITI associates independently with joint tenderness and swelling after adjustment for concomitant synovitis, tenosynovitis, and osteitis. This relation was not confined to RA but was also present in other diagnoses.

The current study is the first to study ITI in a large group of patients with RA and in any patients at all with other arthritic diseases. ITI was thus far only described in RA and persons at risk for developing RA and reported to be virtually absent in symptom-free persons from the general population (10–12). This evoked the question whether ITI is specific for early RA. Our findings answer that question by demonstrating that the specificity for RA is limited: ITI occurred in other arthritides as well, especially those involving high frequencies of hand arthritis and acute-phase reactants.

Although a previous study including individuals who were ACPA positive and patients with RA showed that ITI was more common at tender than nontender MCP joints, the potential role of other inflamed tissues both related to ITI and to tenderness was not taken into account (11). In our study, this was addressed by performing multivariable analyses. In addition, the current study evaluated additional clinical signs, namely, joint swelling and reduced hand functioning. These analyses revealed that ITI

was associated with local MCP tenderness and swelling independent of synovitis, tenosynovitis, and osteitis, but not with reduced hand functioning.

Literature on the tissue surrounding the interosseous tendons is scarce, and it is unknown whether or not these tendons are surrounded by tenosynovial tissue. ITI was first described as tenosynovitis (10), which would imply the presence of tenosynovial tissue. Contrastingly, it has also been described as peritendinitis or fasciitis, which would imply the presence of nonsynovial connective tissue (11,34,35). Of note, the latter study performed hematoxylin–eosin (HE) staining of the tissue and did not report a tenosynovial sheath around the interosseous tendons (11). The notion that ITI probably constitutes nonsynovial inflammation may fit with the current findings showing ITI presence in other diagnoses than RA, also in those in which tenosynovitis is less common. On the other hand, the interosseous tendons are very small, and especially in the normal situation without synovial hyperplasia, tenosynovial cells may be missed on standard HE staining.

Taken together, our findings imply that ITI is indeed a newly identified local inflammatory feature that is prevalent in RA, but it also occurs throughout the rest of the spectrum of early arthritis. The relation with clinical signs underlines that ITI is a novel indicator of particularly high local inflammatory activity, going beyond the known imaging features underlying clinical arthritis. Although the tissue around the interosseous tendons has yet to be studied more closely, the current study is a step forward in understanding the tissue level origins of early inflammatory arthritis and associated clinical features because it expands the knowledge on the variety of tissues involved.

There were some limitations to this study. First, sample sizes for the relatively rare arthritides were small. Nevertheless, this is in line with the prevalence of these diseases, and the current study is the first to even assess ITI in other arthritides than RA. Second, the current large cross-sectional study was specifically designed to elucidate the occurrence of ITI and its relationship with clinical signs at presentation with many different arthritides. It was therefore beyond its scope to assess the prognostic significance of ITI. Third, influences of mechanical factors such as physical work, hobbies, or sports were not studied because such detailed data were not available. Although mechanical stressors have been suggested to be possibly causally related to inflammatory arthritis and to local inflammatory responses at and around tendons, the influence on the interosseous tendons specifically is unknown (36). ITI was, however, previously shown to be nearly absent in the general population (ie, a sample with a wide variety of ages and socioeconomic statuses), which suggests a limited influence of extraneous factors such as mechanical factors and aging. Lastly, ITI was scored in line with the approach described by Mankia et al to facilitate comparability with previous work (11). Because of the novelty of ITI, a limitation is that no validated scoring method is available. In addition, a consensus-based

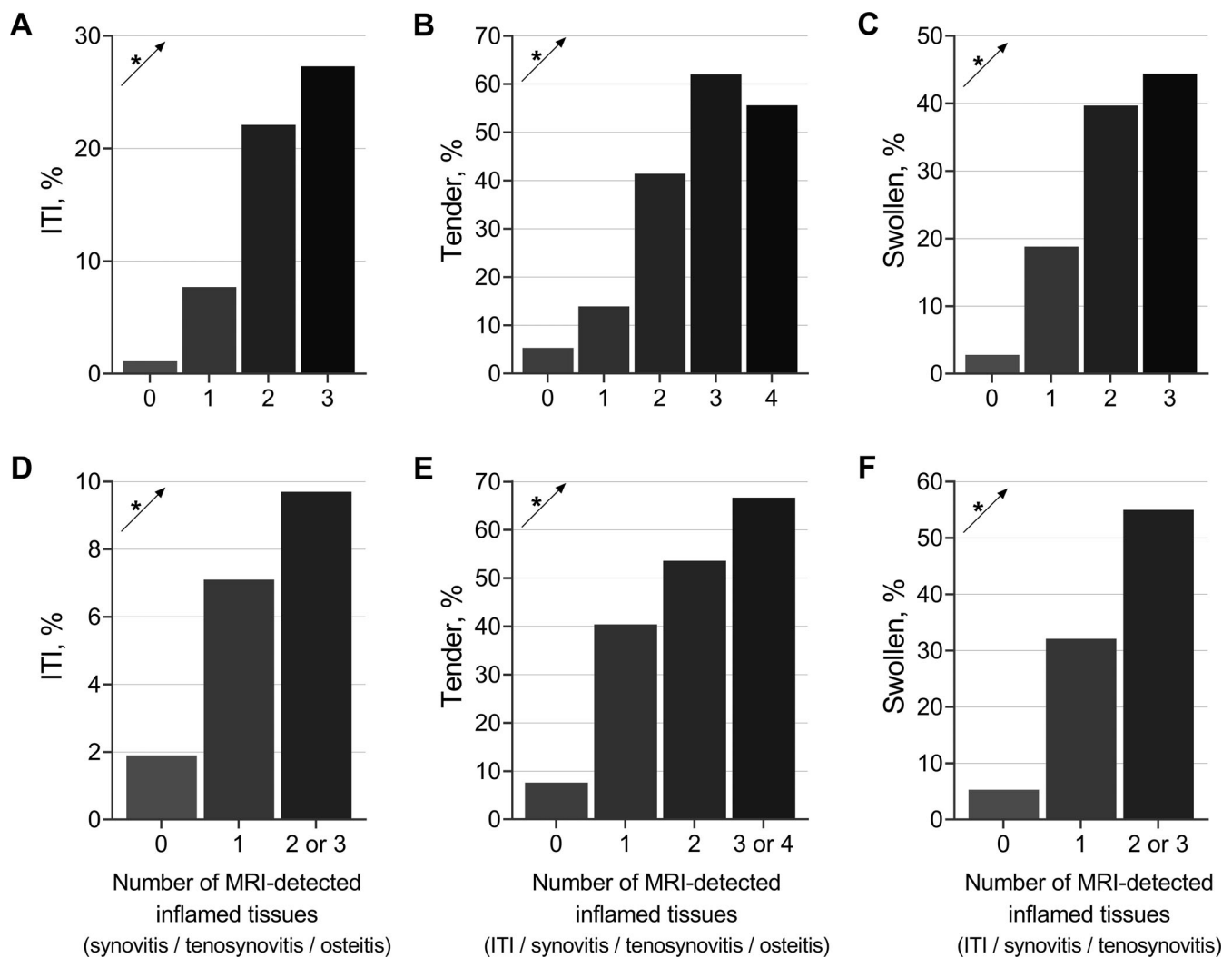


Figure 4. The frequency of interosseous tendon inflammation (ITI) presence (A&D), local tenderness (B&E), and swelling (C&F) according to the number of magnetic resonance imaging (MRI)-detected inflamed tissues at the metacarpophalangeal (MCP) joint in patients with rheumatoid arthritis, without (A-C) and with (D-F) merging of the upper 2 numbers of inflamed tissues. Linear trends that were statistically significant were represented by an asterisk (all $P < 0.001$); analyses were done at the joint level (MCP joints) using generalized estimating equations.

reference atlas of MR images positive and negative for ITI is lacking, and interreader reliability remains to be formally assessed. On the other hand, intrareader reliability was reassuring (ICC 0.98) (12). Hypothetically, the RAMRIS could, in the future, be expanded with a score for ITI, like it was previously expanded with the score for tenosynovitis in 2017 (21).

Several aspects of ITI remain to be explored by future studies. Given that ITI seems to be present at joint locations with more extensive local inflammation and in patients with more systemic inflammation, it would be interesting to study whether patients and/or joints with ITI have a more severe course of the disease. Longitudinal studies would be required to assess associations with important outcomes such as structural damage and remission. If such associations are present, this would pave the way for ITI as a prognostic marker. In addition, the exact composition of the tissue

surrounding the interosseous tendons remains unknown. Advanced comparative histological studies on the different inflamed tissues related to clinical arthritis, such as immunohistochemistry for markers of synovial tissue, are therefore indicated.

In conclusion, this 10-year study across the spectrum of early inflammatory arthritis identified ITI in approximately one-third of patients with ACPA-negative early RA and those with ACPA-positive early RA, as well as in other inflammatory arthritides. ITI occurs in MCP joints with more severe local inflammation and contributes to the likelihood of an MCP joint being tender and swollen. Because ITI mostly occurs in patients with hand arthritis and increased acute-phase reactants, its presence could be an indicator of particularly high inflammatory activity. Longitudinal studies are needed to evaluate the potential prognostic value of ITI.

ACKNOWLEDGMENTS

W. Nieuwenhuis, E. Newsum, D. Boeters, A. Boer, N. Sidhu, and F. Wouters are acknowledged for RA MRI scoring system scoring of MRI scans. G. Kracht is acknowledged for his assistance with preparing Figure 1C–F.

AUTHOR CONTRIBUTIONS

All authors were involved in drafting the article or revising it critically for important intellectual content, and all authors approved the final version to be published. Bastiaan van Dijk had full access to all of the data in the study and takes responsibility for the integrity of the data and the accuracy of the data analysis.

Study conception and design. van Dijk, Reijnierse, van der Helm-van Mil.

Acquisition of data. van Dijk, Reijnierse, van der Helm-van Mil.

Analysis and interpretation of data. van Dijk, Reijnierse, van der Helm-van Mil.

REFERENCES

1. Van de Sande MG, Baeten DL. Immunopathology of synovitis: from histology to molecular pathways. *Rheumatology* 2015;55(4):599–606.
2. Dakkak YJ, van Dijk BT, Jansen FP, et al. Evidence for the presence of synovial sheaths surrounding the extensor tendons at the metacarpophalangeal joints: a microscopy study. *Arthritis Res Ther* 2022;24(1):154.
3. Theumann NH, Pfirrmann CW, Chung CB, et al. Intermetatarsal spaces: analysis with MR bursography, anatomic correlation, and histopathology in cadavers. *Radiology* 2001;221(2):478–84.
4. Matthijssen XME, Wouters F, Sidhu N, et al. Tenosynovitis has a high sensitivity for early ACPA-positive and ACPA-negative RA: a large cross-sectional MRI study. *Ann Rheum Dis* 2021;80(8):974–80.
5. Dakkak YJ, Niemantsverdriet E, van der Helm-van Mil AHM, et al. Increased frequency of intermetatarsal and submetatarsal bursitis in early rheumatoid arthritis: a large case-controlled MRI study. *Arthritis Res Ther* 2020;22(1):277.
6. Dakkak YJ, Boer AC, Boeters DM, et al. The relation between physical joint examination and MRI-depicted inflammation of metatarsophalangeal joints in early arthritis. *Arthritis Res Ther* 2020;22(1):67.
7. Van Dijk BT, Dakkak YJ, Matthijssen XME, et al. Intermetatarsal bursitis, a novel feature of juxta-articular inflammation in early rheumatoid arthritis that is related to clinical signs: results of a longitudinal MRI study. *Arthritis Care Res (Hoboken)* 2022;74(10):1713–22.
8. Rogier C, Hayer S, van der Helm-van Mil A. Not only synovitis but also tenosynovitis needs to be considered: why it is time to update textbook images of rheumatoid arthritis. *Ann Rheum Dis* 2020;79(4):546–7.
9. Bowen CJ, Culliford D, Dewbury K, et al. The clinical importance of ultrasound detectable forefoot bursae in rheumatoid arthritis. *Rheumatology* 2009;49(1):191–2.
10. Rowbotham EL, Freeston JE, Emery P, et al. The prevalence of tenosynovitis of the interosseous tendons of the hand in patients with rheumatoid arthritis. *Eur Radiol* 2016;26(2):444–50.
11. Mankia K, Agostino MA, Rowbotham E, et al. MRI inflammation of the hand interosseous tendons occurs in anti-CCP-positive at-risk individuals and may precede the development of clinical synovitis. *Ann Rheum Dis* 2019;78(6):781–6.
12. Van Dijk BT, van Steenbergen HW, Reijnierse M, et al. Interosseous tendon inflammation in the hands: a novel feature of developing rheumatoid arthritis? Results from a large MRI study in clinically suspect arthralgia. *Arthritis Rheumatol* 2022;74(suppl 9).
13. Liss FE. The interosseous muscles: the foundation of hand function. *Hand Clin* 2012;28(1):9–12.
14. De Rooy DP, van der Linden MP, Knevel R, Huizinga TW, et al. Predicting arthritis outcomes—what can be learned from the Leiden Early Arthritis Clinic? *Rheumatology (Oxford)* 2011;50(1):93–100.
15. Arnett FC, Edworthy SM, Bloch DA, et al. The American Rheumatism Association 1987 revised criteria for the classification of rheumatoid arthritis. *Arthritis Rheum* 1988;31(3):315–24.
16. Aletaha D, Neogi T, Silman AJ, et al. 2010 Rheumatoid arthritis classification criteria: an American College of Rheumatology/European League Against Rheumatism collaborative initiative. *Arthritis Rheum* 2010;62(9):2569–81.
17. Den Hollander NK, Verstappen M, Sidhu N, et al. Hand and foot MRI in contemporary undifferentiated arthritis: in which patients is MRI valuable to detect rheumatoid arthritis early? A large prospective study. *Rheumatology* 2022;61(10):3963–73.
18. Pasquella JA, Levine P. Anatomy and function of the hypothenar muscles. *Hand Clin* 2012;28(1):19–25.
19. Matthijssen XM, Wouters F, Boeters DM, et al. A search to the target tissue in which RA-specific inflammation starts: a detailed MRI study to improve identification of RA-specific features in the phase of clinically suspect arthralgia. *Arthritis Res Ther* 2019;21(1):249.
20. Haavardsholm EA, Østergaard M, Ejbjerg BJ, et al. Introduction of a novel magnetic resonance imaging tenosynovitis score for rheumatoid arthritis: reliability in a multireader longitudinal study. *Ann Rheum Dis* 2007;66(9):1216–20.
21. Østergaard M, Peterfy CG, Bird P, et al. The OMERACT Rheumatoid Arthritis Magnetic Resonance Imaging (MRI) scoring system: updated recommendations by the OMERACT MRI in arthritis working group. *J Rheumatol* 2017;44(11):1706–12.
22. Boer AC, Burgers LE, Mangnus L, et al. Using a reference when defining an abnormal MRI reduces false-positive MRI results—a longitudinal study in two cohorts at risk for rheumatoid arthritis. *Rheumatology (Oxford)* 2017;56(10):1700–6.
23. Mangnus L, van Steenbergen HW, Reijnierse M, et al. Magnetic resonance imaging-detected features of inflammation and erosions in symptom-free persons from the general population. *Arthritis Rheumatol* 2016;68(11):2593–602.
24. Van Dijk BT, Dakkak YJ, Krijbolder DK, et al. Which inflamed tissues explain a positive metatarsophalangeal squeeze test? A large imaging study to clarify a common diagnostic procedure. *Rheumatology (Oxford)* 2022;61(10):4107–12.
25. Burgers LE, Ten Brinck RM, van der Helm-van Mil AH. Is joint pain in patients with arthralgia suspicious for progression to rheumatoid arthritis explained by subclinical inflammation? A cross-sectional MRI study. *Rheumatology (Oxford)* 2019;58(1):86–93.
26. Wouters F, van der Giesen FJ, Matthijssen XM, et al. Difficulties making a fist in clinically suspect arthralgia: an easy applicable phenomenon predictive for RA that is related to flexor tenosynovitis. *Ann Rheum Dis* 2019;78(10):1438–9.
27. Bruce B, Fries JF. The Stanford Health Assessment Questionnaire: dimensions and practical applications. *Health Qual Life Outcomes* 2003;1:20.
28. Fries JF, Spitz P, Kraines RG, et al. Measurement of patient outcome in arthritis. *Arthritis Rheum* 1980;23(2):137–45.
29. Khidir S, van Dijk B, van Mulligen E, et al. Functional disabilities in hands precede those in feet in patients progressing from clinically suspect arthralgia to rheumatoid arthritis: a longitudinal observational study. *Ann Rheum Dis* 2022;81(suppl 1):1213.
30. Daha NA, Toes RE. Rheumatoid arthritis: are ACPA-positive and ACPA-negative RA the same disease? *Nat Rev Rheumatol* 2011;7(4):202–3.
31. Matthijssen XM, Niemantsverdriet E, Huizinga TW, et al. Enhanced treatment strategies and distinct disease outcomes among

- autoantibody-positive and -negative rheumatoid arthritis patients over 25 years: a longitudinal cohort study in the Netherlands. *PLoS Med* 2020;17(9):e1003296.
32. Armitage P. Tests for linear trends in proportions and frequencies. *Biometrics* 1955;11(3):375–86.
 33. Cochran WG. Some methods for strengthening the common χ^2 tests. *Biometrics* 1954;10(4):417–51.
 34. Deng Z, Liu H, Lu W. Interosseous tendon inflammation of rheumatoid arthritis: what's the real meaning? *Ann Rheum Dis* 2020;79(7):e83.
 35. Mankia K, Agostino MA, Murillo-González J, et al. Response to: 'Interosseous tendon inflammation of rheumatoid arthritis: what's the real meaning?' by Deng et al. *Ann Rheum Dis* 2020;79(7):e84.
 36. Gracey E, Burssens A, Cambré I, et al. Tendon and ligament mechanical loading in the pathogenesis of inflammatory arthritis. *Nat Rev Rheumatol* 2020;16(4):193–207.
 37. Betts JG, Young KA, Wise JA, et al. *Anatomy and Physiology*. 1st ed. OpenStax; 2013.