



Universiteit
Leiden
The Netherlands

Molecular imaging of pancreatic and rectal cancer: on a path towards optimized detection and response prediction

Vuijk, F.A.

Citation

Vuijk, F. A. (2024, January 10). *Molecular imaging of pancreatic and rectal cancer: on a path towards optimized detection and response prediction*. Retrieved from <https://hdl.handle.net/1887/3677368>

Version: Publisher's Version


License: [Licence agreement concerning inclusion of doctoral thesis in the Institutional Repository of the University of Leiden](#)

Downloaded from: <https://hdl.handle.net/1887/3677368>

Note: To cite this publication please use the final published version (if applicable).

SECTION I

Pancreatic cancer



Molecular targeted positron emission tomography
imaging and radionuclide therapy of pancreatic
ductal adenocarcinoma

T.T. Poels, F.A. Vuijk, L.F. de Geus-Oei, A.L. Vahrmeijer, D.E. Oprea-Lager and
R.J. Swijnenburg.

Cancers (Basel) 2021

2

ABSTRACT

Pancreatic ductal adenocarcinoma (PDAC) has an inauspicious prognosis, mainly due to difficulty in early detection of the disease by current imaging modalities. Upcoming development of tumour specific tracers provide an alternative solution for more accurate diagnostic imaging techniques for staging and therapy response monitoring. The future goal to strive for, in a patient with PDAC, should definitely be first to receive a diagnostic dose of an antibody labelled with a radionuclide and to subsequently receive a therapeutic dose of the same labelled antibody with curative intent. In the first part of this paper we summarize the available evidence on tumour-targeted diagnostic tracers for molecular positron emission tomography (PET) imaging that have been tested in humans, together with their clinical indications. Tracers such as radiolabelled prostate-specific membrane antigen (PSMA), in particular ^{18}F -labelled PSMA, already validated and successfully implemented in clinical practice for prostate cancer, also seem promising for PDAC.

In the second part we discuss the theranostic applications of these tumour specific tracers. Although targeted radionuclide therapy is still in its infancy, lessons can already be learned from early publications focusing on dose fractioning and adding a radiosensitizer, such as gemcitabine.

INTRODUCTION

Pancreatic ductal adenocarcinoma (PDAC) is the most frequent type of all pancreatic cancers and has an inauspicious prognosis, with a five-year survival rate of less than 5%^{1,2}. This extremely low survival rate is mainly due to difficulty in early detection of the disease extent by current imaging modalities. Staging, and hence rational use of treatment, are highly dependent on information yielded from conventional imaging modalities (i.e., computed tomography (CT), magnetic resonance imaging (MRI) or endoscopic ultrasound (EUS)³. However, almost 50% of surgery is performed without patient benefit (i.e., due to benign diagnoses, undetected metastases, or rapid recurrence <6 months), indicating that these imaging modalities are lacking diagnostic precision and therapy response evaluation accuracy.

During surgery for PDAC, 10% of the patients already present with metastases at laparoscopy and approximately half of the patients undergoing a resection will have microscopically positive resection margins (R1), of whom 25% will develop disease recurrence within six months after surgery. Furthermore, the imaging in patients with borderline resectable or locally advanced PDAC who started chemotherapy is unreliable due to difficulty in distinguishing between fibrosis and stroma in PDAC⁴. Also, ^{18}F -fluorodeoxyglucose (^{18}F -FDG) PET-CT, the most commonly used tracer in oncology, has a variable and debatable role in the routine pancreatic work up, mainly due to the large number of false positive findings by also identifying pancreatitis, potentially resulting in futile resections of the pancreas. ^{18}F -FDG PET-CT is therefore only reserved on indication for the individual patient⁴.

Upcoming development of tumour specific tracers provide an alternative solution for more accurate diagnostic techniques, staging and therapy response monitoring. Targeted radionuclides such as radiolabelled peptides, which bind to the receptors overexpressed by cancer cells and radiolabelled antibodies to tumour-specific antigens can provide a more specific diagnosis⁵⁻⁷. Additionally, this development offers new possibilities to maximally capitalize the theranostic applicability, i.e. the possibility to use the tracer both for imaging purposes as well as a targeting binder for radionuclide therapy.

In the first part of this review we summarize the available evidence on tumour-targeted imaging tracers for molecular PET-CT imaging that have been tested in humans, together with their clinical indications, and in the second part we discuss the theranostic applications of these tumour specific tracers.

For this narrative review our search strategy for both the diagnostic and therapeutic section consisted of a general search of diagnostic and therapeutic tracers in pancreatic

cancer, followed by a search of specific tracers and finally reviewing the papers for leads to other – not yet included- tracers.

PART I: TUMOUR TARGETED TRACERS FOR THE DETECTION OF PANCREATIC CANCER

Early detection is important for the treatment of PDAC. It is believed there are two main precursors for PDAC; namely pancreatic intraepithelial neoplasia (PanIN) and intraductal papillary mucinous neoplasm (IPMN). Three grades can be distinguished in PanIN. PanIN-1 and PanIN-2 are commonly found in patients over the age of 40 or in chronic pancreatitis. PanIN-3 is more exclusively found in the pancreas with PDAC and is the stage prior to invasion⁸⁻¹⁰. IPMNs develop in the cells lining the pancreatic ducts and contribute to mucin production, cystic dilatation of the pancreatic ducts and intraductal papillary growth. IPMNs are at risk of developing into malignancy in 20% over a period of 10 years^{8,11-12}.

PanIN's are challenging to diagnose, as all types are under the resolution of conventional imaging, due to their limited size. EUS may help in detecting identifiable parenchymal changes such as acinar cell loss, proliferation of small ductular structures and fibrosis. These combination of changes, labelled as lobulocentric atrophy (LCA), however, are not specific for PanIN^{8,13}.

In diagnosing PDAC, an important challenge is to distinguish PDAC from pancreatitis, as both entities have abundant stroma. Also, neoadjuvant treatment such as FOLFIRINOX make it difficult to discriminate between viable tumour and chemoradiation-induced tumour necrosis and fibrosis¹⁴⁻¹⁶. Tumour-targeted molecular imaging could provide essential knowledge in these situations, by adding metabolic molecular imaging information to the anatomical changes.

¹⁸F-Fluorodeoxyglucose - ¹⁸F-FDG

PET imaging for the diagnosis of PDAC uses ¹⁸F-FDG, a radiolabelled glucose¹⁷. ¹⁸F-FDG PET imaging relies on the property that a normal pancreas tissue has low glucose usage compared to PDAC. In PDAC a KRAS mutation induces over-expression of hexokinase-2 and glucose cell membrane transporter, GLUT-1²⁰. ¹⁸F-FDG is accumulated by PDAC where it is phosphorylated and consequently goes into metabolic arrest¹⁷⁻¹⁸. (Figure 1.1, Table 1).

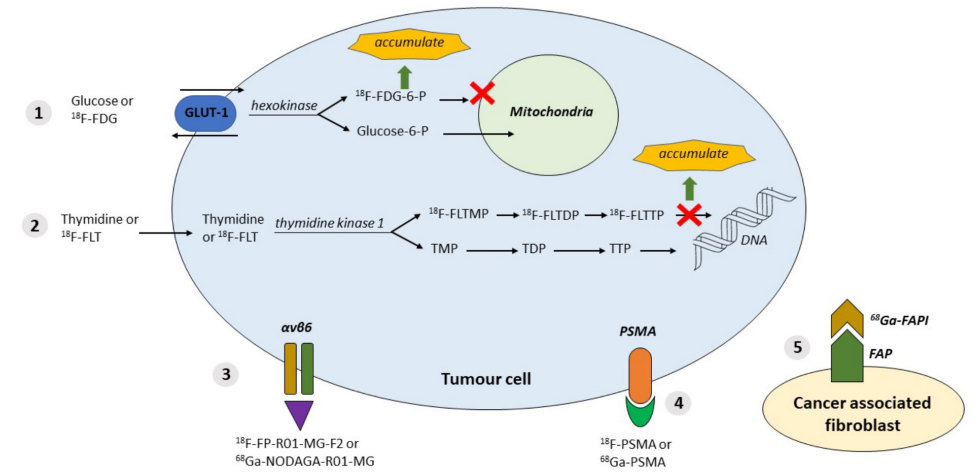


FIGURE 1. Available tracers and their properties

- ¹⁸F-FDG:** Tumour cells have the property of using glucose: GLUT-1 and hexokinase are upregulated in tumours. ¹⁸F labelled FDG accumulation
- ¹⁸F-FLT:** Cell proliferation in tumour cells: Thymidine kinase is upregulated. ¹⁸F labelled (FLT) → FLTTP accumulation
- $\alpha\text{v}\beta\text{6}$** overexpressed in tumour cells: targeted by labelled peptides: ¹⁸F-FP-R01-MG-F2 or ⁶⁸Ga-NODAGA-R01-MG
- PSMA** expressed in tumour cells: targeted by inhibitor molecules labelled with ¹⁸F or ⁶⁸Ga
- Expression of **FAP** (fibroblast activation protein) by CAF (cancer associated fibroblasts) targeted by FAPI (FAP inhibitor) labelled with ⁶⁸Ga or ¹⁸F

Abbreviations: $\alpha\text{v}\beta\text{6}$ = integrin $\alpha\text{v}\beta\text{6}$; DNA = Deoxyribonucleic acid; FAP= fibroblast activation protein; ¹⁸F = ¹⁸Fluorodeoxyglucose labelled; ¹⁸F-FDG = ¹⁸F-fluorodeoxyglucose; ¹⁸F-FDG-6-P = ¹⁸F-FDG-6-phosphate; ¹⁸F-FLT = ¹⁸F-fluorothymidine; ¹⁸F-FLTDP = ¹⁸F-FLT diphosphate; ¹⁸F-FLTMP = ¹⁸F-FLT monophosphate; ¹⁸F-FLTTP = ¹⁸F-FLT triphosphate; ¹⁸F-FP-R01-MG-F2 = ¹⁸F labelled integrin tracer; ¹⁸F-PSMA = ¹⁸F labelled PSMA; ⁶⁸Ga = ⁶⁸Gallium labelled; ⁶⁸Ga-FAPI = ⁶⁸Ga labelled fibroblast activation protein inhibitor; ⁶⁸Ga-NODAGA-R01-MG = ⁶⁸Ga labelled integrin tracer; ⁶⁸Ga-PSMA = ⁶⁸Ga labelled PSMA; Glucose-6-P = Glucose-6-Phosphate; GLUT-1 = glucose transporter type 1; PSMA= prostate-specific membrane antigen; TDP = thymidine diphosphate; TMP = thymidine monophosphate; TTP = thymidine triphosphate.

The average sensitivity and specificity for detecting PDAC by ¹⁸F-FDG is reported to be superior to CT, with sensitivity 94% and specificity 90% for ¹⁸F-FDG, compared to 82% and 75% respectively for CT^{14,19-20}.

A major limitation of PET imaging with ¹⁸F-FDG, is that glucose uptake can also be seen in inflammation, leading to similar appearance of pancreatitis and PDAC^{14,21}. However, when the diagnosis of PDAC is correct, the degree of ¹⁸F-FDG uptake can predict tumour aggressiveness and survival²²⁻²³.

In clinical practice differentiation between pancreatitis and PDAC is possible by performing a dual-phase PET scan. This method consists of performing a PET scan at two different time intervals after the injection of the tracer. Pancreatic masses on PET images in pancreatitis have lower standardized uptake values (SUV), which further decrease in the delayed phase. However, there can be overlap in SUV values between inflammation and PDAC. Furthermore, dual-phase ^{18}F -FDG PET imaging is very time consuming and therefore often not feasible in the daily practice^{17,24}.

The specificity of PET imaging for diagnosis of PDAC could be improved by using more disease-specific imaging agents compared to ^{18}F -FDG. Several other radiotracers have been used for the evaluation of PDAC^{17,25-26}. These include radiotracers such as ^{18}F -Fluorothymidine (^{18}F -FLT), ^{68}Ga labelled fibroblast activation protein inhibitor (^{68}Ga -FAP), ^{68}Ga labelled 1,4,7,10-tetraazacyclododecane-1,4,7,10-tetraacetic acid-FAPI-04 (^{68}Ga -DOTA-FAPI-04), ^{18}F Fluorodeoxyglucose labelled PSMA (^{18}F -PSMA), ^{68}Ga labelled PSMA (^{68}Ga -PSMA) and Integrin $\alpha\text{v}\beta\text{6}$ tracers. These tracers are amply discussed in the following part.

^{18}F -Fluorothymidine - ^{18}F -FLT

^{18}F -fluorothymidine is a marker of cell proliferation due to tracer accumulation in proliferating cells. Thymidine kinase activity is upregulated during proliferation, subsequently phosphorylating ^{18}F -FLT which gets trapped intracellularly. (Figure 1.2, Table 1)

^{18}F -FLT PET imaging has shown good correlation with histological Ki-67 expression, a marker of cell proliferation^{17,27}. Furthermore ^{18}F -FLT PET imaging is potentially superior to ^{18}F -FDG PET as ^{18}F -FLT uptake is not affected by inflammation or hyperglycaemia¹⁷.

Fibroblast Activation Protein Inhibitor - FAPI

In PDAC more than 90% of the tumour volume consists of cancer-associated fibroblasts (CAF). CAFs are associated with promotion of tumour growth, tissue invasion, metastasis developing and therapy resistance²⁸⁻³¹. CAFs express Fibroblast Activation Protein (FAP) on the cell surface, a type II membrane-bound glycoprotein³²⁻³³. FAP can be detected by performing a PET-CT with ^{68}Ga -labelled FAP-Inhibitors. (Figure 1.5, Table 1)

Röhrich et al. showed in a small study including 19 PDAC patients (7 primary and 12 progressive/recurrent) that ^{68}Ga -FAP PET-CT led to restaging in half of patients with PDAC and also in most patients with recurrent disease, compared to standard of care imaging. Differentiation from pancreatitis was challenging, but significantly improved with imaging at multiple time points after injection of ^{68}Ga -FAP²⁸.

Chen et al. compared the use of ^{68}Ga -DOTA-FAPI-04 to ^{18}F -FDG PET for the diagnosis of primary disease and metastatic lesions for various types of cancer. Four patients with pancreatic cancer were included. In one patient the pancreatic cancer was not visualised due to uptake throughout the pancreas caused by tumour-induced pancreatitis [34]. Identical findings of uptake of ^{68}Ga -DOTA-FAPI-04 in patients with Ig-G4 related disease have been reported by others³⁴⁻³⁸.

The study of Chen et al. did show a significantly lower uptake of ^{68}Ga -DOTA-FAPI-04 than ^{18}F -FDG, thus facilitating an improved detection of possible liver metastases³⁴.

TABLE 1. Available tracers and their properties for the diagnosis of primary disease.

Tracer	Properties	Localization	Main advantage	Main disadvantage
^{18}F -FDG	Marker of glucose consumption	Intracellular	High-glucose-use of malignant cells	High-glucose-using cells in inflammation
^{18}F -FLT	Marker of cell proliferation	Intracellular	Cell proliferation in malignancies	
^{68}Ga -FAP; ^{68}Ga -DOTA-FAPI-04;	Expression of FAP by CAF targeted by FAPI labelled with ^{68}Ga	Cell membrane of cancer associated fibroblast	After multiple time points, PDAC and pancreatitis show a trend for differential uptake kinetics.	Can be false positive in pancreatitis
^{18}F -FP-R01-MG-F2; ^{68}Ga -NODAGA-R01-MG; ^{68}Ga -Trivehexin	Labelled peptides targeting $\alpha\text{v}\beta\text{6}$ overexpressed in tumour cells	Cell membrane	Distinguishment between PDAC and pancreatitis. Also uptake in lymph node metastases	
Radiolabelled PSMA (i.e. ^{18}F -PSMA; ^{68}Ga -PSMA)	Inhibitor molecules labelled with ^{18}F or ^{68}Ga targeting PSMA expressed in tumour cells	Cell membrane	Very high diagnostic accuracy between PDAC and pancreatitis	

Abbreviations: $\alpha\text{v}\beta\text{6}$ = integrin $\alpha\text{v}\beta\text{6}$; CAF = cancer associated fibroblast; FAP = fibroblast activation protein; FAPI= FAP inhibitor; ^{18}F = ^{18}F Fluorodeoxyglucose labelled; ^{18}F -FDG = ^{18}F -fluorodeoxyglucose; ^{18}F -FLT = ^{18}F -fluorothymidine; ^{18}F -FP-R01-MG-F2 = ^{18}F labelled integrin tracer; ^{18}F -PSMA = ^{18}F labelled PSMA; ^{68}Ga = ^{68}Ga Gallium labelled; ^{68}Ga -DOTA-FAPI-04= ^{68}Ga labelled (macrocyclic chelator) 1,4,7,10-tetraazacyclododecane-1,4,7,10-tetraacetic acid-FAPI-04; ^{68}Ga -FAP = ^{68}Ga labelled fibroblast activation protein inhibitor; ^{68}Ga -NODAGA-R01-MG = ^{68}Ga labelled integrin tracer; ^{68}Ga -Trivehexin = ^{68}Ga labelled Trivehexin; ^{68}Ga -PSMA= ^{68}Ga labelled PSMA; PSMA= prostate-specific membrane antigen.

Integrin $\alpha\text{v}\beta\text{6}$

Integrins are proteins that facilitate adhesion of cells to extracellular matrix (ECM) of polypeptides. Integrins play a crucial role in the signalling pathway for the regulation of cell differentiation, migration, proliferation and apoptosis³⁹⁻⁴⁰. In many cancers the expression of specific integrins can become dysregulated, such as $\alpha\text{v}\beta\text{3}$ and $\alpha\text{v}\beta\text{6}$. Overexpression of $\alpha\text{v}\beta\text{3}$ results in over-promotion of the angiogenesis pathway^{39, 41}.

Integrin $\alpha\beta6$ promotes PDAC by modulating proliferation, survival, migration and invasion of both the cancer cells and its microenvironment⁴². Studies have shown higher expressions of $\alpha\beta6$ in PDAC compared to other type of cancers^{39,43-44}, also differentiation of PDAC from pancreatitis was possible⁴⁵. Additionally tumour positive lymph nodes also showed elevated levels of $\alpha\beta6$ ⁴⁵. As $\alpha\beta6$ seems to be an important integrin for the detection of PDAC and the distinguishment from pancreatitis, numerous research groups have been developing PET tracers⁴⁶⁻⁴⁸. Kimura et al. used ¹⁸F-FPR01-MG-F2 to target $\alpha\beta6$. (Figure 1.3, Table 1). The study group demonstrated that the targeting peptide was able to penetrate the pancreatic tumour rapidly and also showed an improved uptake compared to ¹⁸F-FDG, reflecting the difference in the peptide's target, namely glucose metabolism versus expression of ECM protein. In addition it was observed that uptake only occurred in the viable part of the tumour compared to parts of significant necrosis³⁹. A recent small study from Quigley et al. showed the first promising result for ⁶⁸Ga-labeled trimerized $\alpha\beta6$ -integrin selective nonapeptide (⁶⁸Ga-Trivehexin) enabled PET-CT imaging. One patient, out of a total of four, was included with PDAC, showing a high tracer uptake in the pancreatic tumour including multiple liver metastases⁴⁹.

Prostate-Specific Membrane Antigen targeted PET-CT imaging

Currently different types of radiolabelled-PSMA tracers exist (i.e. ¹⁸F-PSMA, ⁶⁸Ga-PSMA) with different biodistribution, as largely described in literature⁵⁰. Prostate-specific membrane antigen (PSMA) is a type II transmembrane glycoprotein highly expressed on the surface of prostate cancer cells. The expression of PSMA in tumour-associated (neo) vasculature of prostate cancer, breast cancer and primary gliomas have been reported, and has also proven to be high in PDAC⁵¹⁻⁵³. Immunohistochemical experiments from our group showed high expression of PSMA in 4 out of 5 patients with PDAC de novo, as well as in 32 out of 33 PDAC patients after neoadjuvant treatment (mean tumour H-score of 99 (maximum 300)). These experiments also showed no expression on adjacent normal and pancreatitis tissue (H-score 0), thus yielding high tumour contrast with the background and an improved tumour detection⁵⁴. Radiolabelled PSMA targeted PET-CT has proven highly successful for primary staging and restaging of prostate cancer patients and is currently being implemented worldwide⁵⁵⁻⁵⁶. PSMA expression can be imaged by labelling small inhibitor molecules, with PET radionuclides, i.e., ¹⁸F or ⁶⁸Ga⁵⁷. (Figure 1.4, Table 1)

¹⁸F labelled Prostate-Specific Membrane Antigen - ¹⁸F –PSMA

¹⁸F-radiolabelled PSMA PET has been recently technically validated and successfully implemented in clinical practice for prostate cancer^{54-55,58}. With one of the more commonly used variants the ¹⁸F-DCFpYL, a second generation ¹⁸F-fluorinated PSMA-ligand, has advantages over ⁶⁸Ga-labelled PSMA tracers. It provides namely a higher spatial resolution, along with a longer half-life, which may result in a more accurate

staging due to the detection of small local tumour deposits⁵⁹.

⁶⁸Ga labelled Prostate-specific Membrane Antigen - ⁶⁸Ga-PSMA

Krishnaraju et al. showed improved diagnostic accuracy with ⁶⁸Ga-PSMA compared to ¹⁸F-FDG in a study among 40 patients with pancreatic lesions - positive predictive value 90.5% vs. 65.4%, for ⁶⁸Ga-PSMA compared to ¹⁸F-FDG; accuracy 92.5% vs. 72.5%, respectively⁵⁷.

PART II: TARGETED RADIONUCLIDE THERAPY OF PANCREATIC DUCTAL ADENOCARCINOMA

Locally advanced and metastatic pancreatic cancer has a poor prognosis. Current standard of care treatment such as gemcitabine or FOLFIRINOX provides minimal survival benefit. Targeted radionuclide therapy may provide improved survival in addition to less systemic toxicity seen with current chemotherapy⁶⁰. In patients with cancer, the ultimate goal is first to identify the receptor expression (by using a diagnostic scan with a diagnostic tracer) and then, in case of an adequate expression of the receptor, to use the tracer, radiolabelled with alpha or beta-particles, for therapeutic purposes, with curative or sometimes palliative intent⁶¹.

In addition to therapy with radiolabelled antibodies, there is a possibility to add gemcitabine, serving as a radiosensitizer, which is generally well tolerated in combination with external radiotherapy⁶²⁻⁶⁶.

In this second part we discuss the theranostic applications of tumour specific tracers. To our knowledge, there have only been 2 different types of antibodies that have been reported on in humans as targeted radionuclide therapy of PDAC; ¹³¹I-KAb201 antibody and ⁹⁰Y-clivayuzumab tetraxetan antibody (⁹⁰Y-labelled hPAM4). Furthermore there is only one single study registered at popular databases that is currently recruiting patients and focusing on the theranostic pair of ⁶⁸Ga-DOTA-5G /¹⁷⁷Lu-DOTA-ABM-5G⁶⁷.

¹³¹I labelled KAb201 antibody - ¹³¹I-KAb201

Carcinoembryonic antigen (CEA) is expressed in most patients with pancreatic cancer and therefore serves as an interesting target for antibodies. One potential antibody is KAb201, an anti-CEA antibody labelled with ¹³¹Iodine⁶⁸.

Sultana et al. performed a randomised Phase I/II trial assessing the safety and efficacy of ¹³¹I-KAb201 in patients with inoperable PDAC. Patients were randomized to receive ¹³¹I-KAb201 via either the intra-arterial (gastroduodenal artery) or intravenous (standard

intravenous line) delivery route. The hypothesis of including an intra-arterial delivery route is expected higher concentration of the radiolabelled drug at the target site and thus increased effectiveness with reduced toxicity⁶⁸. In total nineteen patients were randomised (9 in the intravenous arm, 10 in the intra-arterial arm), of whom 1 patient was excluded from the intra-arterial arm as there was no uptake on the pre-therapy scan. The overall response rate was 6% (1 out of 18 patients). Dose limiting toxicity was only reached in the intra-arterial route (at 50 mCi). Both anti-chimeric antibodies (HACA) and anti-sheep antibodies (HASA) developed in the entire study population, thus limiting the possibility of repeat dosing as this could lead to either hypersensitivity reactions or to complexing with circulating antibodies, creating a challenge to maintain effective therapeutic levels⁶⁸⁻⁶⁹. Median overall survival was 5.2 months (95% CI = 3.3-9.0 months), with no significant difference between either delivery arm (log rank test $p = 0.79$)⁷⁰. Survival and efficacy data are comparable with a single agent therapy of gemcitabine⁷¹⁻⁷³. Future improvement can be found in the ability to predict the occurrence and type (I or II) of antibody response, thus aiding the possibility of repeat dosing. Also humanisation of the antibody may reduce the immunogenicity⁶⁸.

⁹⁰Y labelled clivazutumab tetraxetan antibody - ⁹⁰Y-hPAM4

Preclinical studies in nude mice have shown that ⁹⁰Y-labelled PAM4 decelerates tumour growth^{70,74}. PAM4 is a monoclonal antibody which binds to a mucin produced primarily in PDAC⁷⁵⁻⁷⁸. Gulec et al. performed a phase I single-dose escalation trial among 21 patients with PDAC (4 stage III- locally advanced; 17 stage IV- metastatic) with the primary aim to determine dose-limiting toxicity and the maximum tolerated dose. Patients first received ¹¹¹In-hPAM4 for diagnostic imaging and finally ⁹⁰Y-hPAM4 for therapy⁷⁹. Drug-related toxicities among the study group were grade 3/4 neutropenia and thrombocytopenia, which both increased with ⁹⁰Y dose. Fourteen patients progressed rapidly, however 7 patients remained progression-free for 2-6 months, with 3 patients showing partial response with tumour shrinkage. The combination with gemcitabine showed further improvements⁷⁹.

Fractionated dosing of ⁹⁰Y-hPAM4 (for increased total radiation dose) in combination with gemcitabine acting as a radiosensitizer (for increased potency of the radiation) could be a promising treatment regimen^{38,79}. Ocean et al. showed in a phase 1 trial among 38 untreated patients with pancreatic cancer (5 stage III- locally advanced, 33 stage IV- metastatic) that fractionated dosing of ⁹⁰Y-hPAM4 in combination with gemcitabine in repeated cycles (number of cycles varied among the patients) allowed for double the radioimmunotherapy dose⁸⁰.

Drug-related toxicities among the study group were grade 3/4 thrombocytopenia and neutropenia in 28 patients. Sixteen patients showed stabilization and 6 patients a

partial response. Median overall survival was 7.7 months for all patients, with improved survival up to 11.8 months with repeated cycles⁸⁰. An important terminated and unpublished study is the PANCRIT-1 trial. This was an international, multi-center, double-blind, randomized phase III trial of ⁹⁰Y-labelled hPAM4 in combination with gemcitabine versus placebo in combination with gemcitabine in patients with metastatic PDAC who had progressed despite receiving at least two prior therapies for metastatic disease. After enrolment of 334 patients, an interim analysis on overall survival was performed, showing that the treatment arm did not demonstrate a sufficient improvement in overall survival⁸¹. One major flaw of the study seems to be the lack of pre-treatment evaluation of receptor expression, thus not applying the theranostic concept.

⁶⁸Ga-DOTA-5G /¹⁷⁷Lu-DOTA-ABM-5G theranostic pair

(⁶⁸Gallium labelled- DOTA – 5G / ¹⁷⁷labelled Lutetium – DOTA–ABM-5G; DOTA=1,4,7,10-tetraazacyclododecane-1,4,7,10-tetraacetic acid)

The only study listed on a clinical study database (ClinicalTrials.gov) is from Sutcliffe et al. from the University of California. This is a phase I study evaluating the safety and efficacy of the theranostic pair of ⁶⁸Ga-DOTA-5G /¹⁷⁷Lu-DOTA-ABM-5G in patients with locally advanced or metastatic PDAC. Patients first receive a diagnostic ⁶⁸Ga-DOTA-5G PET scan, subsequently only the patients that show uptake receive ¹⁷⁷Lu-DOTA-ABM-5G as therapy.

The primary objective is to identify the dose limiting toxicity and the recommend phase 2 dose. The objective is to enrol 30 participants with an expected completion in 2023⁶⁷.

In summary, results from the study with ¹³¹I-KAb201 demonstrated the importance of further investigation into the type of antibody response and the ability to predict this adverse event for the possibility of repeat dosing. Future research will learn if humanisation of the antibody is able to reduce immunogenicity. Also, the route of delivery (intra-arterial versus intravenous) did not show any difference in survival benefit or reduction in toxicity. Studies using ⁹⁰Y-labelled hPAM4 proved that dose fractioning could be successful in increasing the total radiation dose without an increasing adverse events. In addition the combination with gemcitabine acting as a radiosensitizer can increase the potency of the radiation. Future research, including randomized controlled trials, will need to confirm these results.

We are looking forward to the first results from the ⁶⁸Ga-DOTA-5G /¹⁷⁷Lu-DOTA-ABM-5G theranostic pair, as evaluation of quantifiable antibody localization at the site of disease before administering a therapeutic dose seems to be the best tailored made medicine.

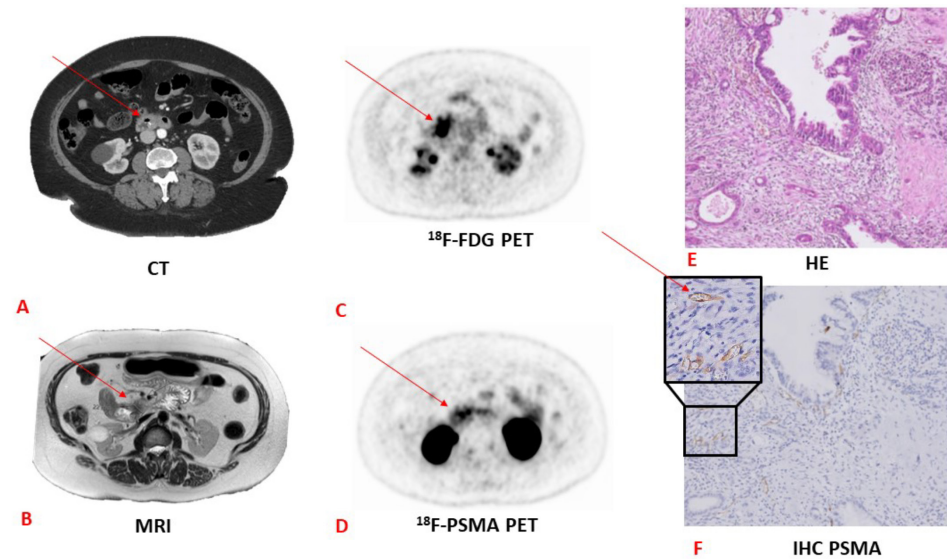


FIGURE 2. CT vs MRI vs ^{18}F -FDG vs ^{18}F -PSMA PET and corresponding pathology and HE and immunohistochemistry coupes in a patient with pancreatic adenocarcinoma

A: CT image with arrow pointing towards pancreatic lesion; B: MRI image with arrow pointing towards pancreatic lesion; C: ^{18}F -FDG PET image with arrow pointing towards pancreatic lesion; D: ^{18}F -PSMA PET image with arrow pointing towards pancreatic lesion. Note the more specific PSMA uptake compared to the ^{18}F -FDG PET scan; E: Hematoxylin and Eosin staining (HE) image. Adenocarcinoma is not visible on this staining; F: immunohistochemistry staining of PSMA. The arrow points towards stained PSMA. CT, computed tomography; MRI, magnetic resonance imaging; PET, positron emitting tomography; HE, hematoxylin eosin; IHC, immunohistochemistry.

(The "HE image" has previously been published by our study group⁸² and is licensed under a Creative Commons Attribution 4.0 International - <http://creativecommons.org/licenses/by/4.0>)

SUMMARY AND CHALLENGES FOR THE FUTURE

Impressive efforts have been made in improving tumour specific tracers for the detection of PDAC. In patients with PDAC, the ultimate goal is to firstly identify the radiolabelled peptide expression and then, in case of an adequate expression of the peptide, to use the tracer, radiolabelled with alpha or beta-particles, for therapeutic purposes, with curative or sometimes palliative intent. ^{18}F -FDG is a well-known radiotracer that already is being used in PDAC. An important limitation, however, is that increased glucose metabolism is not specific for malignant processes only, but can be also found in inflammatory and infectious disease sites. The specificity of PET imaging for the diagnosis of PDAC could be improved by a more disease specific imaging agent.

In general there are currently three types of tracers. Tracers that accumulate in the proliferating cell, such as ^{18}F -FLT. The second type of tracers target highly expressed integrin receptors or PSMA on the surface of cells in PDAC. In this group ^{18}F -PSMA is a

promising tracer (Figure 2) that already has been validated and successfully implemented in clinical practice for prostate cancer. The last type of tracer targets fibroblast activation protein (FAP inhibitor), which is expressed by CAF (cancer associated fibroblast).

Targeted radionuclide therapy is still in its infancy. The effectiveness of targeted radionuclide therapy has been limited by poor delivery to tumours. There have only been 2 different types of antibodies that have been reported on in humans as targeted radionuclide therapy of pancreatic ductal adenocarcinoma; ^{131}I -KAb201 antibody and ^{90}Y -clivayuzumab tetraxetan antibody (^{90}Y -labelled hPAM4). Besides selecting the correct radionuclide antibody, important contributing factors for successful therapy is dose fractioning and the addition of a radiosensitizer, such as gemcitabine.

These novel diagnostic and therapeutic approaches, in population often characterized by poor outcome and decreased quality of life, has the potential to add a new chapter to a patient's life.

REFERENCES

1. Vincent A, Herman J, Schulick R, Hruban RH, Goggins M. Pancreatic cancer. *Lancet*. 2011 Aug 13;378(9791):607-20.
2. Latenstein AEJ, van der Geest LGM, Bonsing BA, Groot Koerkamp B, Haj Mohammad N, de Hingh IHJT, et al.; Dutch Pancreatic Cancer Group. Nationwide trends in incidence, treatment and survival of pancreatic ductal adenocarcinoma. *Eur J Cancer*. 2020 Jan;125:83-93.
3. Gerritsen A, Molenaar IQ, Bollen TL, Nio CY, Dijkgraaf MG, van Santvoort HC, et al. Preoperative characteristics of patients with presumed pancreatic cancer but ultimately benign disease: a multicenter series of 344 pancreatoduodenectomies. *Ann Surg Oncol*. 2014 Nov;21(12):3999-4006.
4. van Veldhuisen E, van den Oord C, Brada LJ, Walma MS, Vogel JA, Wilmink JW, et al. Locally Advanced Pancreatic Cancer: Work-Up, Staging, and Local Intervention Strategies. *Cancers (Basel)*. 2019 Jul 12;11(7):976.
5. Orlando LA, Kulasingam SL, Matchar DB. Meta-analysis: the detection of pancreatic malignancy with positron emission tomography. *Aliment Pharmacol Ther*. 2004 Nov 15;20(10):1063-70.
6. Montemagno C, Cassim S, De Leiris N, Durivault J, Faraggi M, Pagès G. Pancreatic Ductal Adenocarcinoma: The Dawn of the Era of Nuclear Medicine? *Int J Mol Sci*. 2021 Jun 15;22(12):6413.
7. Ren H, Zhang H, Wang X, Liu J, Yuan Z, Hao J. Prostate-specific membrane antigen as a marker of pancreatic cancer cells. *Med Oncol*. 2014 Mar;31(3):857.
8. Petrone MC, Arcidiacono PG. New strategies for the early detection of pancreatic cancer. *Expert Rev Gastroenterol Hepatol*. 2016;10(2):157-9.
9. Canto MI, Goggins M, Hruban RH, Petersen GM, Giardiello FM, Yeo C, et al. Screening for early pancreatic neoplasia in high-risk individuals: a prospective controlled study. *Clin Gastroenterol Hepatol*. 2006 Jun;4(6):766-81; quiz 665.
10. Maire F, Couvelard A, Palazzo L, Aubert A, Vullierme MP, Rebours V, et al. Pancreatic intraepithelial neoplasia in patients with intraductal papillary mucinous neoplasms: the interest of endoscopic ultrasonography. *Pancreas*. 2013 Nov;42(8):1262-6.
11. Del Chiaro M, Verbeke C, Salvia R, Klöppel G, Werner J, McKay C, et al. European Study Group on Cystic Tumours of the Pancreas. European experts consensus statement on cystic tumours of the pancreas. *Dig Liver Dis*. 2013 Sep;45(9):703-11.
12. Tanaka M, Fernández-del Castillo C, Adsay V, Chari S, Falconi M, Jang JY, et al; International Association of Pancreatology. International consensus guidelines 2012 for the management of IPMN and MCN of the pancreas. *Pancreatology*. 2012 May-Jun;12(3):183-97.
13. Del Chiaro M, Segersvärd R, Lohr M, Verbeke C. Early detection and prevention of pancreatic cancer: is it really possible today? *World J Gastroenterol*. 2014 Sep 14;20(34):12118-31.
14. Tummers WS, Willmann JK, Bonsing BA, Vahrmeijer AL, Gambhir SS, Swijnenburg RJ. Advances in Diagnostic and Intraoperative Molecular Imaging of Pancreatic Cancer. *Pancreas*. 2018 Jul;47(6):675-689.
15. Conroy T, Desseigne F, Ychou M, Bouché O, Guimbaud R, Bécauarn Y, et al. FOLFIRINOX versus gemcitabine for metastatic pancreatic cancer. *N Engl J Med*. 2011 May 12;364(19):1817-25.
16. Ferrone CR, Marchegiani G, Hong TS, Ryan DP, Deshpande V, McDonnell EI, et al. Radiological and surgical implications of neoadjuvant treatment with FOLFIRINOX for locally advanced and borderline resectable pancreatic cancer. *Ann Surg*. 2015 Jan;261(1):12-7.
17. Panda A, Garg I, Johnson GB, Truty MJ, Halfdanarson TR, Goenka AH. Molecular radionuclide imaging of pancreatic neoplasms. *Lancet Gastroenterol Hepatol*. 2019 Jul;4(7):559-570.
18. Samuel N, Hudson TJ. The molecular and cellular heterogeneity of pancreatic ductal adenocarcinoma. *Nat Rev Gastroenterol Hepatol*. 2011 Dec 20;9(2):77-87.
19. Gambhir SS, Czernin J, Schwimmer J, Silverman DH, Coleman RE, Phelps ME. A tabulated summary of the FDG PET literature. *J Nucl Med*. 2001 May;42(5 Suppl):1S-93S.
20. Ghaneh P, Hanson R, Titman A, Lancaster G, Plumpton C, Lloyd-Williams H, et al. PET-PANC: multicentre prospective diagnostic accuracy and health economic analysis study of the impact of combined modality 18fluorine-2-fluoro-2-deoxy-d-glucose positron emission tomography with computed tomography scanning in the diagnosis and management of pancreatic cancer. *Health Technol Assess*. 2018 Feb;22(7):1-114.
21. Yokoyama Y, Nagino M, Hiromatsu T, Yuasa N, Oda K, Arai T, et al. Intense PET signal in the degenerative necrosis superimposed on chronic pancreatitis. *Pancreas*. 2005 Aug;31(2):192-4.
22. Epelbaum R, Frenkel A, Haddad R, Sikorski N, Strauss LG, Israel O, Dimitrakopoulou-Strauss A. Tumour aggressiveness and patient outcome in cancer of the pancreas assessed by dynamic 18F-FDG PET/CT. *J Nucl Med*. 2013 Jan;54(1):12-8.
23. Lee JW, Kang CM, Choi HJ, Lee WJ, Song SY, Lee JH, Lee JD. Prognostic Value of Metabolic Tumour Volume and Total Lesion Glycolysis on Preoperative 18F-FDG PET/CT in Patients with Pancreatic Cancer. *J Nucl Med*. 2014 Jun;55(6):898-904.
24. Kato K, Nihashi T, Ikeda M, Abe S, Iwano S, Itoh S, Shimamoto K, Naganawa S. Limited efficacy of (18)F-FDG PET/CT for differentiation between metastasis-free pancreatic cancer and mass-forming pancreatitis. *Clin Nucl Med*. 2013 Jun;38(6):417-21.
25. Sahani DV, Bonaffini PA, Catalano OA, Guimaraes AR, Blake MA. State-of-the-art PET/CT of the pancreas: current role and emerging indications. *Radiographics*. 2012 Jul-Aug;32(4):1133-58; discussion 1158-60.
26. Chang J, Schomer D, Dragovich T. Anatomical, Physiological, and Molecular Imaging for Pancreatic Cancer: Current Clinical Use and Future Implications. *Biomed Res Int*. 2015;2015:269641.
27. Chalkidou A, Landau DB, Odell EW, Cornelius VR, O'Doherty MJ, Marsden PK. Correlation between Ki-67 immunohistochemistry and 18F-fluorothymidine uptake in patients with cancer: A systematic review and meta-analysis. *Eur J Cancer*. 2012 Dec;48(18):3499-513.
28. Röhrich M, Naumann P, Giesel FL, Choyke PL, Staudinger F, Wefers A, et al. Impact of 68Ga-FAPI PET/CT Imaging on the Therapeutic Management of Primary and Recurrent Pancreatic Ductal Adenocarcinomas. *J Nucl Med*. 2021 Jun 1;62(6):779-786.
29. von Ahrens D, Bhagat TD, Nagrath D, Maitra A, Verma A. The role of stromal cancer-associated fibroblasts in pancreatic cancer. *J Hematol Oncol*. 2017 Mar 28;10(1):76.
30. Sun Q, Zhang B, Hu Q, Qin Y, Xu W, Liu W, Yu X, Xu J. The impact of cancer-associated fibroblasts on major hallmarks of pancreatic cancer. *Theranostics*. 2018 Oct 6;8(18):5072-5087.
31. Kalluri R. The biology and function of fibroblasts in cancer. *Nat Rev Cancer*. 2016 Aug 23;16(9):582-98.
32. Sahai E, Astsaturou I, Cukierman E, DeNardo DG, Egeblad M, Evans RM, et al. A framework for advancing

- our understanding of cancer-associated fibroblasts. *Nat Rev Cancer*. 2020 Mar;20(3):174-186.
33. McCarthy JB, El-Ashry D, Turley EA. Hyaluronan, Cancer-Associated Fibroblasts and the Tumor Microenvironment in Malignant Progression. *Front Cell Dev Biol*. 2018 May 8;6:48.
 34. Chen H, Pang Y, Wu J, Zhao L, Hao B, Wu J, et al. Comparison of [⁶⁸Ga]Ga-DOTA-FAPI-04 and [¹⁸F] FDG PET/CT for the diagnosis of primary and metastatic lesions in patients with various types of cancer. *Eur J Nucl Med Mol Imaging*. 2020 Jul;47(8):1820-1832.
 35. Luo Y, Pan Q, Zhang W, Li F. Intense FAPI Uptake in Inflammation May Mask the Tumor Activity of Pancreatic Cancer in 68Ga-FAPI PET/CT. *Clin Nucl Med*. 2020 Apr;45(4):310-311.
 36. Luo Y, Pan Q, Zhang W. IgG4-related disease revealed by ⁶⁸Ga-FAPI and ¹⁸F-FDG PET/CT. *Eur J Nucl Med Mol Imaging*. 2019 Nov;46(12):2625-2626.
 37. Pan Q, Luo Y, Zhang W. Recurrent Immunoglobulin G4-Related Disease Shown on 18F-FDG and 68Ga-FAPI PET/CT. *Clin Nucl Med*. 2020 Apr;45(4):312-313.
 38. Ocean AJ, Guarino MJ, Pennington KL, O'Neil BH, Rocha Lima CS, Bekaii-Saab TS, et al. Therapeutic effects of fractionated radioimmuno- notherapy (RAIT) with clivatuzumab tetraxetan combined with low- dose gemcitabine (Gem) in advanced pancreatic cancer (APC). *J Clin Oncol* 2010;28:75.
 39. Kimura RH, Wang L, Shen B, Huo L, Tummers W, Filipp FV, et al. Evaluation of integrin $\alpha\beta_6$ cystine knot PET tracers to detect cancer and idiopathic pulmonary fibrosis. *Nat Commun*. 2019 Oct 14;10(1):4673.
 40. Hynes RO. Integrins: bidirectional, allosteric signaling machines. *Cell*. 2002 Sep 20;110(6):673-87.
 41. Desgrosellier JS, Cheresh DA. Integrins in cancer: biological implications and therapeutic opportunities. *Nat Rev Cancer*. 2010 Jan;10(1):9-22.
 42. Reader CS, Vallath S, Steele CW, Haider S, Brentnall A, Desai A, et al. The integrin $\alpha\beta_6$ drives pancreatic cancer through diverse mechanisms and represents an effective target for therapy. *J Pathol*. 2019 Nov;249(3):332-342.
 43. Bandyopadhyay A, Raghavan S. Defining the role of integrin $\alpha\beta_6$ in cancer. *Curr Drug Targets*. 2009 Jul;10(7):645-52.
 44. Sipos B, Hahn D, Carceller A, Piulats J, Hedderich J, Kalthoff H, et al. Immunohistochemical screening for β_6 -integrin subunit expression in adenocarcinomas using a novel monoclonal antibody reveals strong up-regulation in pancreatic ductal adenocarcinomas in vivo and in vitro. *Histopathology*. 2004 Sep;45(3):226-36.
 45. Vachiranubhap B, Kim YH, Balci NC, Semelka RC. Magnetic resonance imaging of adenocarcinoma of the pancreas. *Top Magn Reson Imaging*. 2009 Feb;20(1):3-9.
 46. Hausner SH, DiCara D, Marik J, Marshall JF, Sutcliffe JL. Use of a peptide derived from foot-and-mouth disease virus for the noninvasive imaging of human cancer: generation and evaluation of 4-[¹⁸F] fluorobenzoyl A20FMDV2 for in vivo imaging of integrin $\alpha\beta_6$ expression with positron emission tomography. *Cancer Res*. 2007 Aug 15;67(16):7833-40.
 47. Kimura RH, Teed R, Hackel BJ, Pysz MA, Chuang CZ, Sathirachinda A, et al. Pharmacokinetically stabilized cystine knot peptides that bind $\alpha\beta_6$ integrin with single-digit nanomolar affinities for detection of pancreatic cancer. *Clin Cancer Res*. 2012 Feb 1;18(3):839-49.
 48. Altmann A, Sauter M, Roesch S, Mier W, Warta R, Debus J, et al. Identification of a Novel ITG $\alpha\beta_6$ -Binding Peptide Using Protein Separation and Phage Display. *Clin Cancer Res*. 2017 Aug 1;23(15):4170-4180.
 49. Quigley NG, Steiger K, Hoberück S, Czech N, Zierke MA, Kossatz S, et al. PET/CT imaging of head-and-neck and pancreatic cancer in humans by targeting the "Cancer Integrin" $\alpha\beta_6$ with Ga-68-Trivehexin. *Eur J Nucl Med Mol Imaging*. 2021 Sep 24:1–12.
 50. Ceci F, Oprea-Lager DE, Emmett L, Adam JA, Bomanji J, Czernin J, et al. E-PSMA: the EANM standardized reporting guidelines v1.0 for PSMA-PET. *Eur J Nucl Med Mol Imaging*. 2021 May;48(5):1626-1638.
 51. Stock K, Steinestel K, Wiesch R, Mikesch JH, Hansmeier A, Trautmann M, Bet al. Neovascular Prostate-Specific Membrane Antigen Expression Is Associated with Improved Overall Survival under Palliative Chemotherapy in Patients with Pancreatic Ductal Adenocarcinoma. *Biomed Res Int*. 2017;2017:2847303.
 52. Ren H, Zhang H, Wang X, Liu J, Yuan Z, Hao J. Prostate-specific membrane antigen as a marker of pancreatic cancer cells. *Med Oncol*. 2014 Mar;31(3):857.
 53. Sahbai S, Rieping P, Pfannenbergs C, la Fougère C, Reimold M. Pancreatic Ductal Adenocarcinoma With High Radiotracer Uptake in 68Ga-Prostate-Specific Membrane Antigen PET/CT. *Clin Nucl Med*. 2017 Sep;42(9):717-718.
 54. Vuijk FA, de Muynck LDAN, Franken LC, Busch OR, Wilmink JW, Besselink MG, et al. Molecular targets for diagnostic and intraoperative imaging of pancreatic ductal adenocarcinoma after neoadjuvant FOLFIRINOX treatment. *Sci Rep*. 2020 Oct 1;10(1):16211.
 55. Mottet N, van den Bergh RCN, Briers E, Van den Broeck T, Cumberbatch MG, De Santis M, et al. EAU-EANM-ESTRO-ESUR-SIOG Guidelines on Prostate Cancer-2020 Update. Part 1: Screening, Diagnosis, and Local Treatment with Curative Intent. *Eur Urol*. 2021 Feb;79(2):243-262.
 56. Jansen BHE, Cysouw MCF, Vis AN, van Moorselaar RJA, Voortman J, Bodar YJL, et al. Repeatability of Quantitative ¹⁸F-DCFPyL PET/CT Measurements in Metastatic Prostate Cancer. *J Nucl Med*. 2020 Sep;61(9):1320-1325.
 57. Krishnaraju VS, Kumar R, Mittal BR, Sharma V, Singh H, Nada R, et al. Differentiating benign and malignant pancreatic masses: Ga-68 PSMA PET/CT as a new diagnostic avenue. *Eur Radiol*. 2021 Apr;31(4):2199-2208.
 58. Jansen BHE, Yaqub M, Voortman J, Cysouw MCF, Windhorst AD, Schuit RC, et al. Simplified Methods for Quantification of ¹⁸F-DCFPyL Uptake in Patients with Prostate Cancer. *J Nucl Med*. 2019 Dec;60(12):1730-1735.
 59. Rowe SP, Gorin MA, Allaf ME, Pienta KJ, Tran PT, Pomper MG, et al. PET imaging of prostate-specific membrane antigen in prostate cancer: current state of the art and future challenges. *Prostate Cancer Prostatic Dis*. 2016 Sep;19(3):223-30.
 60. Aigner KR, Gailhofer S, Kopp S. Regional versus systemic chemotherapy for advanced pancreatic cancer: a randomized study. *Hepatogastroenterology*. 1998 Jul-Aug;45(22):1125-9.
 61. Shah M, Da Silva R, Gravekamp C, Libutti SK, Abraham T, Dadachova E. Targeted radionuclide therapies for pancreatic cancer. *Cancer Gene Ther*. 2015 Aug;22(8):375-9.
 62. Maitra A, Hruban RH. Pancreatic cancer. *Annu Rev Pathol*. 2008;3:157-88.
 63. Moore MJ, Goldstein D, Hamm J, Figer A, Hecht JR, Gallinger S, et al; National Cancer Institute of Canada Clinical Trials Group. Erlotinib plus gemcitabine compared with gemcitabine alone in patients with advanced pancreatic cancer: a phase III trial of the National Cancer Institute of Canada Clinical Trials Group. *J Clin Oncol*. 2007 May 20;25(15):1960-6.

64. Kulke MH, Blaszkowsky LS, Ryan DP, Clark JW, Meyerhardt JA, Zhu AX, et al. Capecitabine plus erlotinib in gemcitabine-refractory advanced pancreatic cancer. *J Clin Oncol*. 2007 Oct 20;25(30):4787-92.
65. Morgan MA, Parsels LA, Maybaum J, Lawrence TS. Improving gemcitabine-mediated radiosensitization using molecularly targeted therapy: a review. *Clin Cancer Res*. 2008 Nov 1;14(21):6744-50.
66. Pauwels B, Korst AE, Lardon F, Vermorken JB. Combined modality therapy of gemcitabine and radiation. *Oncologist*. 2005 Jan;10(1):34-51.
67. <https://clinicaltrials.gov/ct2/show/NCT04665947>
68. Sultana A, Shore S, Raraty MG, Vinjamuri S, Evans JE, Smith CT, et al. Randomised Phase I/II trial assessing the safety and efficacy of radiolabelled anti-carcinoembryonic antigen I(131) KAb201 antibodies given intra-arterially or intravenously in patients with unresectable pancreatic adenocarcinoma. *BMC Cancer*. 2009 Feb 25;9:66.
69. Adams GP, Weiner LM. Monoclonal antibody therapy of cancer. *Nat Biotechnol*. 2005 Sep;23(9):1147-57.
70. Cardillo TM, Ying Z, Gold DV. Therapeutic advantage of (90)yttrium- versus (131)iodine-labeled PAM4 antibody in experimental pancreatic cancer. *Clin Cancer Res*. 2001 Oct;7(10):3186-92.
71. Berlin JD, Catalano P, Thomas JP, Kugler JW, Haller DG, Benson AB 3rd. Phase III study of gemcitabine in combination with fluorouracil versus gemcitabine alone in patients with advanced pancreatic carcinoma: Eastern Cooperative Oncology Group Trial E2297. *J Clin Oncol*. 2002 Aug 1;20(15):3270-5.
72. Colucci G, Giuliani F, Gebbia V, Biglietto M, Rabitti P, Uomo G, et al. Gemcitabine alone or with cisplatin for the treatment of patients with locally advanced and/or metastatic pancreatic carcinoma: a prospective, randomized phase III study of the Gruppo Oncologia dell'Italia Meridionale. *Cancer*. 2002 Feb 15;94(4):902-10.
73. Burris HA 3rd, Moore MJ, Andersen J, Green MR, Rothenberg ML, Modiano MR, et al. Improvements in survival and clinical benefit with gemcitabine as first-line therapy for patients with advanced pancreas cancer: a randomized trial. *J Clin Oncol*. 1997 Jun;15(6):2403-13.
74. Gold DV, Cardillo T, Vardi Y, Blumenthal R. Radioimmunotherapy of experimental pancreatic cancer with 131I-labeled monoclonal antibody PAM4. *Int J Cancer*. 1997 May 16;71(4):660-7.
75. Gold DV, Karanjawala Z, Modrak DE, Goldenberg DM, Hruban RH. PAM4-reactive MUC1 is a biomarker for early pancreatic adenocarcinoma. *Clin Cancer Res*. 2007 Dec 15;13(24):7380-7.
76. Gold DV, Lew K, Maliniak R, Hernandez M, Cardillo T. Characterization of monoclonal antibody PAM4 reactive with a pancreatic cancer mucin. *Int J Cancer*. 1994 Apr 15;57(2):204-10.
77. Gold DV, Modrak DE, Ying Z, Cardillo TM, Sharkey RM, Goldenberg DM. New MUC1 serum immunoassay differentiates pancreatic cancer from pancreatitis. *J Clin Oncol*. 2006 Jan 10;24(2):252-8.
78. Gold DV, Goggins M, Modrak DE, Newsome G, Liu M, Shi C, Hruban RH, Goldenberg DM. Detection of early-stage pancreatic adenocarcinoma. *Cancer Epidemiol Biomarkers Prev*. 2010 Nov;19(11):2786-94.
79. Gulec SA, Cohen SJ, Pennington KL, Zuckier LS, Hauke RJ, Horne H, et al. Treatment of advanced pancreatic carcinoma with 90Y-Clivatuzumab Tetraxetan: a phase I single-dose escalation trial. *Clin Cancer Res*. 2011 Jun 15;17(12):4091-100.
80. Ocean AJ, Pennington KL, Guarino MJ, Sheikh A, Bekaii-Saab T, Serafini AN, et al. Fractionated radioimmunotherapy with (90)Y-clivatuzumab tetraxetan and low-dose gemcitabine is active in advanced pancreatic cancer: A phase 1 trial. *Cancer*. 2012 Nov 15;118(22):5497-506.
81. <https://clinicaltrials.gov/ct2/show/NCT01956812>
82. Vuijk FA, de Muynck LDAN, Franken LC, Busch OR, Wilmink JW, Besselink MG, et al. Molecular targets for diagnostic and intraoperative imaging of pancreatic ductal adenocarcinoma after neoadjuvant FOLFIRINOX treatment. *Sci Rep*. 2020 Oct 1;10(1):16211.