



Universiteit  
Leiden  
The Netherlands

## Imaging the prenatal brain in congenital heart defects

Everwijn, S.M.P.

### Citation

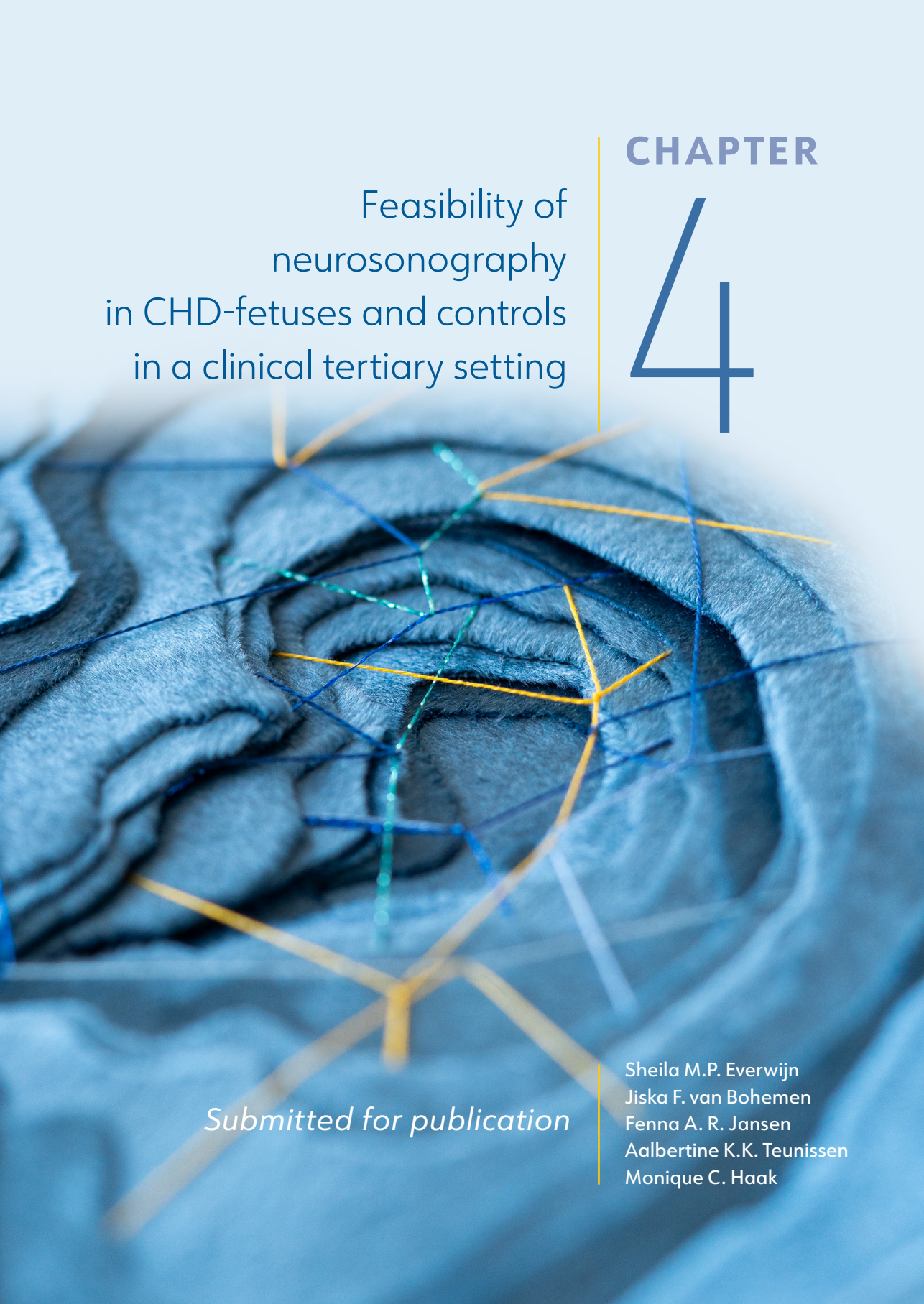
Everwijn, S. M. P. (2023, December 13). *Imaging the prenatal brain in congenital heart defects*. Retrieved from <https://hdl.handle.net/1887/3672336>

Version: Publisher's Version

License: [Licence agreement concerning inclusion of doctoral thesis in the Institutional Repository of the University of Leiden](#)

Downloaded from: <https://hdl.handle.net/1887/3672336>

**Note:** To cite this publication please use the final published version (if applicable).



Feasibility of  
neurosonography  
in CHD-fetuses and controls  
in a clinical tertiary setting

CHAPTER

4

*Submitted for publication*

Sheila M.P. Everwijn  
Jiska F. van Bohemen  
Fenna A. R. Jansen  
Aalbertine K.K. Teunissen  
Monique C. Haak

# ABSTRACT

**INTRODUCTION:** Ultrasonographic examination is the first-tier test to detect abnormal development of central nervous system (CNS). In optimal conditions, neurosonography can detect all important hallmarks of neurological development. It is, however, not known how the performance of this modality is in a routine setting. We aim to evaluate the feasibility of neurosonography in a time-limited routine setting.

**METHODS:** We have performed basic neurosonography examination according to the guideline 'how to perform a basic screening examination of the CNS', published by the international society of ultrasound in obstetrics and gynecology. We have included a group of pregnant women carrying a fetus with an isolated congenital heart defect (CHD), and a control group of fetuses without structural anomalies. Examinations were scored off-line by researchers blinded for group allocation.

**RESULTS:** A total of 574 neurosonographic examinations were performed in 151 fetuses, 90 in the CHD-group and 61 in the control group. In all these examinations, 9 brain structures were scored in 3 different planes. A successful neurosonogram could be performed in 79% (234/294) of cases in a real clinical setting (CHD cases) and in 90% (253/280) of control pregnancies. Higher maternal BMI (>30), maternal age, fetal cephalic position, fetal gender and placental position did not significantly influence neurosonography scores.

**CONCLUSION:** In real clinical setting, basic neurosonography can successfully be performed in the majority of cases. This was not significantly influenced by maternal or fetal factors. When an abnormality is suspected in a screening setting, longer time slots for diagnostic neurosonography have to be planned, which allows for a complete examination.

## INTRODUCTION

Abnormalities in the fetal central nervous system (CNS) have a prevalence of 1-2/1000 live births. The value of prenatal detection of these defects is important for expecting parents, as malformations of the CNS can have a great effect on the quality of life of a child. It may guide the decision to have an invasive genetic diagnostic procedure or, in severe cases, to terminate the pregnancy within the legal constraints of the law. Dedicated neurosonography, performed by a team of well-trained ultrasonographers with a uniform protocol, has the ability to correctly diagnose 84% of the CNS-anomalies without the use of magnetic resonance imaging (MRI)<sup>1</sup>. Additional pathology or a different diagnosis was found with MRI in only 1.3% of the cases. The diagnostic accuracy of CNS abnormalities improves when the examiner works in a center with a high volume of referrals, within an experienced multi-disciplinary team<sup>2,3</sup>. CNS abnormalities are known to be more prevalent in fetuses and neonates with congenital heart defects (CHD), even in the absence of genetic syndromes. To explore the prevalence of CNS abnormalities in isolated CHD, we have performed neurosonography routinely to detect CNS anomalies in a group of fetuses with a broad range of CHDs and a group of controls.

The aim of this study was to evaluate the performance of two-dimensional ultrasound in a tertiary setting. We used a limited time frame, to reflect daily clinical care. We hypothesize that complete visibility of all possible structures with neurosonography, might not be entirely achievable in a daily clinical setting.

## Methods

All fetal neurosonography scans were performed prior to a fetal echocardiography scan, as part of a neurological surveillance program, in the Leiden University Medical Center, a tertiary care center for prenatal diagnosis. The examinations were performed by experienced fetal ultrasonographers (SE/FJ/AT), according to the HAND (Heart And NeuroDevelopment)-study protocol every four weeks from 20 weeks onwards. We have performed the examinations according to the ISUOG guidelines for the performance of 'basic screening' and 'fetal neurosonogram'<sup>4</sup>. All examinations were performed with a RAB 6-D three-dimensional transducer on Voluson E8 and E10 systems (General Electric, Milwaukee, WI, USA). A group of prenatally detected CHD cases and a group of healthy control volunteers were recruited after giving informed consent. The study protocol was approved by the local ethics committee (P13.07). All cranial planes, including axial (trans-ventricular, trans-thalamic, trans-cerebellar planes), coronal (trans-caudate plane) and sagittal (mid- and para sagittal planes) were attempted. We developed a neurosonography score which was



the composite score of the visibility of nine brain structures in three different planes, resulting in a total score of 0 in case no plane was visible to nine if all structures could be retrieved. In the axial plane, cavum septum pellucidum (CSP), lateral ventricle (LV), third ventricle (3V), fourth ventricle (4V), cerebellum (CB) and Cisterna Magna (CM) were scored. In the coronal plane the frontal horns (FH), and in the sagittal plane the corpus callosum (CC) and the thalamo-occipital depth (TOD) were scored. A sufficient neurosonography score was defined as  $\geq 7$  points ( $>77.8\%$ ), an insufficient score as  $< 7$  ( $<77.8\%$ ). Additional vaginal ultrasound was added, after maternal informed consent, if abdominal planes were insufficient, but were not standard. To reflect daily clinical practice in a population in which normal findings were expected, time slots of 20 minutes were scheduled to perform all necessary planes of the ISUOG guideline for basic screening neurosonogram. Fetal echocardiography (in fetuses with (suspected) CHD) and fetal biometry were performed apart from this time slot. In the CHD-group, cases with extracardiac structural malformations or genetic syndromes were not included. If a genetic syndrome was diagnosed in the first year of life, the data were excluded from analysis. Both groups had a neonatal cerebral follow-up scan. Maternal characteristics such as BMI, maternal age, parity and diabetes were recorded. Furthermore, gestational age (GA), placental position and fetal position were recorded for each scanning session.

All fetal neurosonography examinations were stored as images and clips and were analysed offline by two researchers (SE/JvB) that were blinded for group allocation, GA and clinical outcome.

In the stored images and clips the aforementioned nine structures of brain anatomy were identified for visibility: The brain structure was scored as visible if the anatomy was clearly visible, without shadowing and in full width and length. In case of blurred vision of vague borders of the structure, the anatomic structure was scored as not visible. To avoid intra-observer variation, a set of 30 examinations were scored and compared between the two examiners. These 30 training sets were not a part of the studied data, in this initial training period, differences were agreed upon by consensus. The intra-observer variation was calculated after the training period and the method was found to have excellent intraobserver variation with an ICC of 0.97 (95% CI, 0.95-0.98).

Analysis in categorical variables were performed with Chi-square testing, and continuous variables were analysed with independent T-testing. All statistical analyses were performed using IBM SPSS statistics version 24.0.0.0 (IBM, Armonk, NY, USA). Statistical significance was set at  $p \leq 0.05$ . The results are presented as the visible percentage of structures of total number of scored structures.

## Results

A total of 574 neurosonographic examinations were performed in 151 fetuses, 90 in the CHD-group and 61 in the control group. Baseline characteristics did not differ, except for maternal age which was slightly higher in the control group (30.2 vs 32.1 years,  $p = 0.01$ , Table 1).

The mean neurosonography score was  $81.3\% \pm 11.7$  in the CHD group and  $85.2\% \pm 9.0$  in the control group. Mean neurosonography score was lower for primigravidae was  $78.8\% \pm 13.5$  and for non-primigravidae  $83.1\% \pm 9.9$ ,  $p = 0.01$  in the CHD-group. This difference was not observed in the control group. Patients with maternal diabetes ( $n=2$ ), had significantly reduced neurosonography scores in the CHD-group. Mean neurosonography score for patients with maternal diabetes was  $66.7\% \pm 16.7$  and for patients without maternal diabetes  $81.9\% \pm 11.7$ ,  $p = 0.002$ . There were no patients in the control group with maternal diabetes, as they were included based on normal uncomplicated pregnancy. Maternal BMI negatively influenced neurosonography scores in CHD-cases, however, the difference was not statistically significant. Maternal age, fetal cephalic position, fetal gender and placental position did not statistically influence neurosonography scores in both CHD-cases and control groups (see Table 2).

In table 3 and 4, the evaluated brain structures are shown according to the GA in which the scan took place. In the axial plane, for both CHD-cases and controls, more than 80% of the structures are visible. The CSP, LV and CB were visible in almost all examinations ( $>94\%$ ) in both groups. In the coronal plane, the FH was visible in  $>80\%$  cases in both groups. The structures that are only be visible in the sagittal plane were visualised in the minority of cases; the CC 14-40% and TOD  $>46\%$  in both groups.

Examinations in which 85-100% of the studied brain structures could be visualised, were performed between 22 - 34 weeks gestation, defining this as the optimal GA-window for fetal neurosonography.

## Discussion

This study presents a large group of ultrasound examinations of the fetal brain, that were systematically scored for visibility of well-known brain structures. We have found that fetal brain structures were best visualized between 22 and 34 weeks. The standard neurosonogram can successfully be performed within a time limit of 20 minutes, in 79% (234/294) of cases in a real clinical setting (CHD cases) and in 90% (253/280) of control pregnancies. We did not find that maternal BMI, fetal cephalic position and placental position significantly influenced the visibility of brain structures.

This study used the ISUOG practice guideline: sonographic examination of the fetal central nervous system part 1, which describes the basic planes to perform a fetal neurosonographic examination. As these fetuses were not expected to have structural brain abnormalities, we aimed to perform and complete a basic screening neurosonographic exam. A previous study by Hormazabal analysed the feasibility of neurosonography in the second and third trimester by scoring the visibility of different brain structures<sup>5</sup>. They found higher scores (around 95%) in the performance to visualize the different brain structures. The examinations were, however, performed in a research setting without time-restriction. Presumably, in a clinical setting with time restriction, as was presented in our study, scores higher than 90% are not achievable due to clinical demands. Another study that has analysed the feasibility of an ISUOG screening protocol, described the learning curve of experienced and non-experienced sonographers in performing a first-trimester fetal anatomy screening<sup>6</sup>. Although these authors conclude that complete scans were feasible in the majority of cases as was found in our study, both experienced and non-experienced sonographers were not able to reach maximum scores for each examination. We conclude, based on the results of Sripilaipong and our results that success rates of around 90% reflect the performance of a screening neurosonogram in routine practice. If a CNS-abnormality is expected through a screening ultrasound, a broader time slot should be planned, to allow the sonographer time to produce all the necessary planes to accurately diagnose the CNS abnormality.

Although this is not the primary aim of our study, the differences between the control group and the CHD group were noteworthy. Mean neurosonography scores were lower in the CHD-groups as compared to control group. We suspect that the attitude of the sonographer towards maternal anxiety in the situation of an already diagnosed CHD could have played a role, as well as time pressure of the scheduled subsequent scan, since the neurosonography exam was planned prior to the echocardiography,

This study also provides a unique insight in the performance of fetal neurosonographic screening relating to maternal or fetal factors. Of the patient related factors, maternal BMI (although not significant) and the number of previous pregnancies, negatively influenced the neurosonography score, this finding is in line with the prenatal detection of cardiac defects<sup>7-9</sup>. It is noteworthy that the mentioned factors did not seem to influence the visibility of CNS structures, as we all know from clinical practice that BMI influences image quality. A possible explanation could be that with modern ultrasound equipment that was used in this study, the image quality is stable despite scanning women with higher BMI's.

A limitation of this study, is the sparse use of transvaginal ultrasound. In the minority of cephalic presenting cases, transvaginal ultrasound was added, although it is well known that transvaginal ultrasound has a significant diagnostic value in combination with abdominal US<sup>10</sup>. A reason for this reserved attitude towards invasive examination at that time was the absence of suspicion of a CNS abnormality combined with sufficient visualization of the CNS anatomy by abdominal US.

In conclusion, neurosonography in a tertiary center for the purpose of neurosonography surveillance is able to detect more than 80% of CNS structures in the axial and coronal planes in second and third trimester examinations. Structures in the sagittal planes are more difficult to detect. Furthermore, maternal habitus, fetal position and placenta position did not significantly influence the visibility of brain structures.



## Tables

**Table 1** Baseline characteristics (n=574 ultrasounds)

TGA cases	CHD- cases	Controls	p-value
	n = 294 ultrasounds	n = 280 ultrasounds	
	90 fetuses	61 fetuses	
Maternal age in years (Mean(SD))	30.2 (4.6)	32.1 (4.6)	0.01
Maternal Diabetes	2	0	0.24
BMI	23.6 (3.9)	24 (4.6)	0.60
Primigravidae (%)	36 (40)	20 (33)	0.49
Male gender	52 fetuses	28 fetuses	0.18
Fetal position	Cephalic: 223 Breech: 52 Transverse: 18	Cephalic: 213 Breech: 56 Transverse: 11	0.63
Placenta position	Anterior: 142 Posterior: 129 Lateral: 12 Fundus: 11	Anterior: 115 Posterior: 133 Lateral: 9 Fundus: 23	0.28
HHS n(%)	6 (6.7)		
TGA n(%)	14 (15.6)		
Ao Hypoplasia and/or aortic stenosis n(%)	17 (18.9)		
TA/PA n (%)	6 (6.7)		
Fallot of Fallot-like n(%)	14 (15.6)		
AVSD n(%)	3 (3.3)		
Other Major CHD n(%)	17 (18.9)		
Other minor CHD n(%)	9 (10)		

\* p-values of <0.05 are considered statistically significant

**Table 2** Influence of confounding variables on neurosonography scores

	Percentage of visible structures % $\pm$ SD (n)		p-value
	Normal-low BMI (<30)	High BMI	
CHD-cases	82.2 $\pm$ 14.4 (190)	77.0 $\pm$ 15.5 (28)	<i>P</i> = 0.06
Controls	85.7 $\pm$ 12.2 (177)	81.0 $\pm$ 8.9 (17)	<i>P</i> = 0.1
	Primigravidae	Non-primigravidae	
CHD-cases	78.8 $\pm$ 16.7 (115)	83.1 $\pm$ 12.2 (179)	<i>P</i> = <0.01*
Controls	86.8 $\pm$ 8.9 (88)	84.5 $\pm$ 12.2 (192)	<i>P</i> = 0.1
	Cephalic position	Non-cephalic position	
CHD-cases	82.3 $\pm$ 14.4 (224)	81.1 $\pm$ 1.3 (70)	<i>P</i> = 0.5
Controls	84.9 $\pm$ 11.1 (213)	86.4 $\pm$ 12.2 (67)	<i>P</i> = 0.4
	Anterior placenta	Non-anterior placenta	
CHD-cases	80.7 $\pm$ 14.4 (129)	82.0 $\pm$ 14.4 (165)	<i>P</i> = 0.5
Controls	84.8 $\pm$ 11.1 (133)	85.7 $\pm$ 12.2 (147)	<i>P</i> = 0.5

N= number of analysed examinations,

\* p-values of <0.05 are considered statistically significant

**Table 3** Evaluable brain structures in neurosonography of the CHD-group (n=294 ultrasounds)

Gestational age	n	AXIAL						CORONAL			SAGITTAL		
		CSP n (%)	LV n (%)	3V n (%)	4V n (%)	CB n (%)	CM n (%)	FH n (%)	CC n (%)	TOD n (%)			
19+0 – 21+6	37	36 (97.3)	37 (100)	25 (67.6)	22 (59.2)	37 (100)	37 (100)	33 (89.2)	11 (29.7)	18 (48.6)			
22+0 – 25+6	54	54 (100)	54 (100)	46 (85.2)	47 (87)	54 (100)	53 (98.1)	53 (98.1)	22 (40.7)	43 (79.6)			
26+0 – 29+6	65	64 (98.5)	65 (100)	56 (86.2)	57 (87.7)	65 (100)	63 (96.9)	64 (98.5)	12 (18.5)	46 (70.8)			
30+0 – 33+6	74	72 (98.6)	73 (100)	71 (97.3)	59 (80.8)	72 (98.6)	66 (90.4)	68 (93.2)	13 (17.8)	54 (74)			
34+0 – 37+6	64	60 (93.8)	60 (93.8)	62 (96.9)	46 (71.9)	63 (98.4)	43 (67.2)	52 (81.3)	9 (14.1)	30 (46.9)			

**Table 4** Evaluable brain structures in neurosonography of the control-group (n=280 ultrasounds)

Gestational age	n	AXIAL						CORONAL			SAGITTAL		
		CSP n (%)	LV n (%)	3V n (%)	4V n (%)	CB n (%)	CM n (%)	FH n (%)	CC n (%)	TOD n (%)			
19+0 – 21+6	38	38 (100)	38 (100)	27 (71.1)	30 (78.9)	38 (100)	38 (100)	38 (100)	13 (34.2)	28 (73.7)			
22+0 – 25+6	64	64 (100)	64 (100)	60 (93.8)	60 (93.8)	63 (98.4)	61 (95.3)	63 (98.4)	21 (32.8)	53 (82.8)			
26+0 – 29+6	63	61 (96.8)	62 (98.4)	60 (95.2)	59 (93.7)	63 (100)	61 (96.8)	62 (98.4)	13 (20.6)	56 (88.9)			
30+0 – 33+6	58	57 (98.3)	58 (100)	56 (96.6)	57 (98.3)	58 (100)	50 (86.2)	57 (98.3)	10 (17.2)	50 (86.2)			
34+0 – 37+6	57	54 (94.7)	55 (96.5)	54 (94.7)	51 (89.5)	56 (98.2)	28 (49.1)	53 (93)	8 (14)	42 (73.7)			

**Table 5** Total neurosonography-score in the control group: sum score of the 'visible' brain structures, of the **CHD-group** (n=294 ultrasounds)

Gestational age	n	Insufficient score (0-77.8%) n (%)	Sufficient score (77.8-100%) n (%)
19+0 – 21+6	37	11 (29.7)	26 (70.3)
22+0 – 25+6	54	6 (11.1)	48 (88.9)
26+0 – 29+6	65	9 (13.8)	56 (86.2)
30+0 – 33+6	74	11 (14.9)	63 (85.1)
34+0 – 37+6	64	23 (35.9)	41 (64.1)

**Table 6** Total neurosonography-score in the control group: sum score of the 'visible' brain structures, of the **control-group** (n=280 ultrasounds)

Gestational age	n	Insufficient score (0-77.8%) n (%)	Sufficient score (77.8-100%) n (%)
22+0 – 25+6	64	3 (4.7)	61 (95.3)
26+0 – 29+6	63	3 (4.7)	60 (95.2)
30+0 – 33+6	58	0 (0)	58 (100)
34+0 – 37+6	57	14 (24.6)	43 (75.4)



## References

- 1 Paladini D, Quarantelli M, Sglavo G, Pastore G, Cavallaro A, D'Armiento MR, Salvatore M, Nappi C. **Accuracy of neurosonography and MRI in clinical management of fetuses referred with central nervous system abnormalities.** *Ultrasound Obstet Gynecol.* 2014;44(2):188-96.
- 2 Iruretagoyena JI, Shah D, Malinger G. **Dedicated fetal neurosonographic evaluation improves patient care and maternal fetal medicine fellow training.** *The journal of maternal-fetal & neonatal medicine : the official journal of the European Association of Perinatal Medicine, the Federation of Asia and Oceania Perinatal Societies, the International Society of Perinatal Obstet.* 2016;29(3):482-6.
- 3 Paladini D, Malinger G, Pilu G, Timor-Trisch I, Volpe P. **The MERIDIAN trial: caution is needed** *Lancet.* 2017;389(10084):2103.
- 4 International Society of Ultrasound in O, Gynecology Education C. **Sonographic examination of the fetal central nervous system: guidelines for performing the 'basic examination' and the 'fetal neurosonogram'.** *Ultrasound Obstet Gynecol.* 2007;29(1):109-16.
- 5 Hormazabal L, Correa F, Escribano D, Quiroz G, Saint-Jean C, Espinel A, Diaz L, Zambrano B, Galindo A, Vinals F. **Feasibility and agreement of including anterior-posterior complexes and landmarks of the proximal hemisphere into basic examination of the fetal brain: A prospective study.** *Prenat Diagn.* 2020;40(5):596-604.
- 6 Sripilaipong S, Panburana P, Wattanayingcharoenchai R, Tangshewinsirikul C. **Feasibility and learning curve of performing first trimester fetal anatomy screening among operators with varying experience using the protocol of the International Society of Ultrasound in Obstetrics and Gynecology (ISUOG).** *The journal of maternal-fetal & neonatal medicine : the official journal of the European Association of Perinatal Medicine, the Federation of Asia and Oceania Perinatal Societies, the International Society of Perinatal Obstet.* 2022;35(25):8691-7.
- 7 Wong SF, Chan FY, Cincotta RB, Lee-Tannock A, Ward C. **Factors influencing the prenatal detection of structural congenital heart diseases.** *Ultrasound Obstet Gynecol.* 2003;21(1):19-25.
- 8 Pinto NM, Keenan HT, Minich LL, Puchalski MD, Heywood M, Botto LD. **Barriers to prenatal detection of congenital heart disease: a population-based study.** *Ultrasound Obstet Gynecol.* 2012;40(4):418-25.
- 9 Vavolizza RD, Dar P, Suskin B, Moore RM, Stern KWD. **Clinical yield of fetal echocardiography for suboptimal cardiac visualization on obstetric ultrasound.** *Congenit Heart Dis.* 2018;13(3):407-12.
- 10 Birnbaum R, Barzilay R, Brusilov M, Acharya P, Malinger G, Krajdén Haratz K. **Early second-trimester three-dimensional transvaginal neurosonography of fetal midbrain and hindbrain: normative data and technical aspects.** *Ultrasound Obstet Gynecol.* 2022;59(3):317-24.