



Universiteit
Leiden

The Netherlands

Taking a closer look: non-invasive tools for in-depth characterisation of vulvar diseases

Pagan, L.

Citation

Pagan, L. (2023, December 12). *Taking a closer look: non-invasive tools for in-depth characterisation of vulvar diseases*. Retrieved from <https://hdl.handle.net/1887/3666289>

Version: Publisher's Version

License: [Licence agreement concerning inclusion of doctoral thesis in the Institutional Repository of the University of Leiden](#)

Downloaded from: <https://hdl.handle.net/1887/3666289>

Note: To cite this publication please use the final published version (if applicable).

Summary and Discussion



The scope of this thesis was to identify objective, non-invasive biomarkers for vulvar premalignant disease. The aetiology of vulvar diseases, including LS, vulvar HSIL, dVIN and vSCC is poorly understood. Clinically, these diseases can be challenging to monitor and therapeutic management options are limited. The envisaged application of improving non-invasive biomarkers is therefore threefold: 1) enhanced recognition of the underlying cause 2) augmenting clinical detection and 3) contributing to the investigation of potential new drug targets for vulvar premalignant diseases. Early phase clinical trials should include assessments that can show pharmacodynamic effects ideally leading to proof-of-mechanism and/or proof-of-concept.¹ For the vulvar diseases, the outcome measures currently utilized to evaluate efficacy are non-sensitive, non-objective and inadequate, mostly relying on non-standardized clinician-based scoring alone.² The drivers of pathogenesis or disease progression are not fully understood. Disease mechanisms need to be clarified and biomarkers need to be discovered that can indicate changes in disease states. Then, novel drug compounds can be developed specifically targeting a disease process and tested appropriately.

It is imperative to apply a structured methodology for the recognition of applicable and valid biomarkers per disease entity. This was incorporated in this thesis using a model across a variety of domains.³ This thesis has extensively focused on two of the domains from this approach. In the first section, novel imaging techniques for disease characterisation were described for feasibility and applicability in vulvar diseases and HPV-related cutaneous disease. In the second part, the vulvar microbiome composition is explored in relation to health and disease. The other domains of the comprehensive model were also addressed as auxiliary biomarkers during the studies described in this thesis, including clinical assessments, patient reporting, histological references, immunohistochemistry and HPV-typing.

This final chapter provides a summary and discussion of the results presented in this thesis. This chapter addresses the potential steps to expand and integrate this knowledge for future studies to improved understanding of vulvar diseases. In addition, this chapter is a call for other research groups to optimise biomarkers for vulvar diseases.

SECTION I: CHARACTERISING VULVAR AND HPV-DRIVEN DISEASE WITH NOVEL IMAGING TECHNIQUES

As a health care provider with a vulvar clinic, it can be challenging to keep up with the rapidly changing technological field of medical imaging. Every new

technique brings financial investments and time-consuming efforts for acquisition, training and maintenance. Choosing which imaging applications are relevant for integration into patient care requires translational collaboration by researchers, clinicians and industry. In skin research and the dermatological practice, traditional digital cameras are gradually being replaced by more advanced technologies. These may, in addition to lesion capture, include incorporated algorithms for disease recognition, lesion size determination or blood flow measurements.^{4,5} These enhanced systems include, but are not limited to, stereophotogrammetric 3D photography, dermatoscopy, optical coherence tomography (OCT) and reflectance confocal microscopy (RCM). None of these techniques are routinely applied in the vulvar clinic, and even their application in vulvar research is sparse and without consensus on scoring systems to describe observations. Technical application and clinical exploration of these highlighted imaging techniques have been described in this thesis.

Performing clinical trials requires accurate measurement tools and it is imperative that reduction of lesion count and size is carefully monitored during the trials to obtain an accurate reflection of efficacy parameters. Especially for vulvar HSIL, which is often irregularly shaped, lesion size is challenging to determine. In **chapter 2**, stereophotogrammetric 3D photography was validated as a method for the determination of lesion size of vulvar HSIL, anogenital and cutaneous warts. 3D photography was considered precise and accurate during technical validation with good to excellent agreement between operators and raters. Clinical validation was achieved by comparing 3D photography to caliper measurements, which was used as the clinical golden standard for lesion size determination. Agreement between methods was good to excellent for the determination of lesion diameter of all three lesion types. However, the height of cutaneous warts could not accurately be determined. 3D photography is also applicable for the determination of surface area and volume of lesions. To conclude, stereophotogrammetric 3D imaging was found to be an accurate and reliable method for the clinical visualization and quantification of HPV-induced skin lesions. This technique can consequently be applied to explore the efficacy of novel therapeutics, especially in the early clinical phase.⁶

Next, an extensive prospective observational clinical feasibility trial was performed to characterize novel, non-invasive methods for the recognition of vulvar HSIL and LS and to compare these outcomes to histology. The aim was to describe the practical applicability of these new techniques, also considering physician-oriented handling and patient tolerability. In

addition, characteristics and features of vulvar HSIL and LS were compared to healthy vulvar skin. In total, 25 women were included in this study, of which 10 healthy controls, 5 patients with vulvar HSIL and 10 patients with lichen sclerosus. The results of the studied non-invasive imaging modalities, dermatoscopy, D-OCT and RCM, were described in **chapter 3** and **chapter 4**, respectively.

Dermatoscopic characteristics were identified in vulvar HSIL and LS that may differentiate these conditions from healthy vulvar skin, but none of these features were specific for a particular disease in our study population. This technique could be applied to aid identification of vulvar lesions, or recognition of the most suspicious part of a lesion to guide biopsy or excision. Assembly of reference images of all diseases found on vulvar tissue and identification of a distinct set of features for each disease entity is required, however, before this technique can routinely be applied in the vulvar clinic. Recently, several research groups have described collections of dermatoscopic references for genital disease, but vulvar specialists are yet to adopt the technique in practice.⁷⁻⁹ The study performed in this thesis only serves as a pilot with a focus on precursors of vSCC, but expansion of the study population in numbers and diversity is essential for training and reference. Changes over time, including (side-)effects of topical treatment, scarring from surgery and disease progression, ought to be recognized and documented. For instance, discrepant observations have been described for the dermatoscopic vessel structure in LS, prompting discussion in literature on the distinct dermatoscopic presentation based on disease activity or state.¹⁰ Dermatoscopic and histological references have generally described a reduction, or *desertification*, in vessel concentration and intensity in LS.⁹ In contrast, presence of thick, arborizing vessels against a white or pink background was a feature almost exclusively observed in a subset of the LS population studied in this thesis. Our vascular finding reflects the gap in our knowledge about the diverse presentation of LS and underlines the importance of creating a reference catalogue. These limitations notwithstanding, dermatoscopy is a technique that could easily be incorporated into the vulvar clinic. Dermatoscopy already is a fundamental part of the modern dermatology practice, therefore acquisition of the technology and training of specialized personnel in the vulvar clinic should be straightforward. Yet, further validation and operator training specifically for the vulvar field will be imperative for successful integration of this technique.

D-OCT uses laser-light to generate images of sub-surface structures of a biological tissue, such as the retina or the skin. The scattering pattern translates into a graphical representation of the imaged tissue and displays dynamic features of the skin. Integrated algorithms can determine epidermal thickness, skin roughness and blood flow. Morphologically, major histological structures up to 1-2 mm depth can be recognized in a non-invasive manner using D-OCT, although the resolution of the technology is insufficient for the identification of individual cellular changes. Epidermal thickness of normal, non-genital skin can be determined using algorithms, although our study found that these automatic measurements are unsuitable for the irregular and hirsute vulvar skin.¹¹ Manual measurements did identify a thinner epidermis in LS patients (both of lesional and seemingly non-lesional skin) compared to healthy volunteers. On histology, LS presents with thinning of the epidermis, and vulvar HSIL with acanthosis. Practically, there is no clinical application for using epidermal thickness as a proxy for the diagnostics of vulvar diseases. Additionally, manual measurements would be too time-consuming to be considered applicable for the clinical setting. Hence, epidermal thickness determination using D-OCT is considered suitable for research rather than clinical practice. Blood flow, as ascertained by D-OCT, was increased in the lesional vulvar skin of LS patients, which reflects the newly identified arborizing vasculature on dermatoscopy. Furthermore, seemingly non-lesional vulvar skin of vulvar HSIL displayed a higher blood flow than healthy controls or lesional vulvar HSIL skin. However, the irregular, warty shape of vulvar HSIL and the modest sample size in this study should be considered in the interpretation of these findings. The data from blood flow and epidermal thickness measurements in this study also reflect that vulvar skin adjacent to visible diseased skin should not automatically be regarded as healthy vulvar skin, as changes compared to healthy controls were found. Bordering, seemingly non-lesional skin may have undergone changes due to previous treatments or changes in the immune and vascular microenvironment due to the adjacent disease process. Within-patient controls are thus intrinsically invalid, and the inclusion of a healthy, ideally age-matched, control population, is essential in similar investigations and follow-up studies.

RCM is an imaging technique can generate real time, non-invasive, transversal images of the skin at a cellular resolution to a depth of 250 µm. RCM provides horizontal images of the scanned surface, starting at the epidermis through to the dermis, in contrast to the familiar transversal slides in

histology. While D-OCT and dermatoscopy are incorporated clinical tools in ophthalmology and dermatology, respectively, the application of RCM is mostly applied in research settings. Most dermatological studies using RCM have focused on the investigation of pigmented lesions to aid identification of melanoma.¹²⁻¹⁴ RCM imaging of the vulvar area had only been described in a handful of case reports. No studies had previously focused on practical steps of obtaining and analysing vulvar RCM images, nor the patient acceptability of this technique. Our study provided a practical application framework and identified several cellular features identified in a non-invasive manner that are known from histological literature on LS and vulvar HSIL. Dermal sclerosis and hyalinized vessels on RCM, as observed in LS, may in time prove pathognomonic for the disease, as both features were almost exclusively identified in LS in a clear pattern. However, a follow-up study including the whole spectrum of vulvar diseases and all stages of LS should confirm or repudiate this hypothesis. Downsides of RCM that could hinder integration into the clinic is the time-consuming nature of the procedure, extensive operator training and the steep expenses of acquisition and maintenance of the equipment. Individual cells can be recognised and discriminated, but nuclear changes cannot be discerned using RCM. Neither does this imaging technique replace routine diagnostic staining procedures, e.g. for P16 or P53. Especially for vulvar HSIL, nuclear clumping, mitotic figure patterns and strong P16 positivity are pathological hallmarks of disease.¹⁵ It is therefore unlikely that biopsies for histological confirmation of premalignant diagnosis will be replaced by introducing RCM imaging. In the future, if RCM is adopted as tool by vulvar specialists, it could potentially be utilised to guide differential diagnosis and recognise the most suspicious lesion area for biopsy.

Due to the paucity of patients with vulvar HSIL and taboo surrounding genital disease, recruitment of these patient groups into clinical trials is often challenging. More common HPV-driven diseases such as plantar and cutaneous warts are caused by different phylotypes. These disease entities can supply a pool of potential patients in which HPV-targeting therapies can be studied, while remembering that grouping of these diseases may overlook pertinent clinical dissimilarities. In addition, novel imaging tools described in the first chapters of this thesis can also be applied in broader dermatology research. In **chapter 5**, 3D photography and D-OCT were applied as a research tool to monitor efficacy during a first-on-human, double-blind, randomized, placebo-controlled clinical trial. In this study, a novel synthetic peptide with

anti-neoplastic activity, CY-002 with anti-neoplastic activity, was tested in 63 patients with cutaneous warts with low-risk HPV types. The primary objective of this study was to assess safety and tolerability of topical CY-002 on the skin. Exploratory analysis of potential clinical effect on the cutaneous warts was performed by wart count, imaging (3D photography and D-OCT), viral HPV load measurements, biopsy analysis and morphological assessment.¹⁶ In this study, we found that CY-002 was safe and tolerable for daily topical use under occlusion for up to 4 weeks. No statistically significant effects were observed comparing efficacy outcomes of CY-002 to placebo, possibly due to relatively high placebo responses. Preclinically, CY-002 had selectively targeted tumour cell lines whilst sparing normal cells. The discrepancy of the cell membrane charge is thought to be the key to the working mechanism of CY-002. Issues with permeation of the callous wart structure could explain the lack of observed effects. Studying topical therapies is always limited by uncertainty whether the medication has reached its intended intradermal target. Intralesional therapy or abrasion of the lesions can circumvent these issues but are considered painful by patients.

Considerations and future applications

Making a clinical diagnosis and following up treatment effect can be subjective and challenging, especially for diseases such as vulvar HSIL and dVIN. It is fundamental to make early and accurate diagnoses to reduce associated morbidity and guide fitting treatment. Going forward, the clinical field should consider incorporating the technological advancements to aid their clinical decision making. However, medical imaging is a rapidly developing field; today's studies are virtually outdated tomorrow. In the few years since the setup of the studies described in this section, technical advancements now allow for even higher resolution and improved orientation of the visualised tissue.¹⁷ Choosing the correct appliances for clinical application requires prior validation and integration in clinical studies (*Table 1*). Visualisation of the superficial layer of the vulva can currently be achieved by using the naked eye, conventional photography, colposcopy, or, as recommended in this thesis, dermatoscopy. Colposcopy and dermatoscopy observations should be compared for accuracy and practicality in a future clinical study, as both techniques rely on magnification of the cutaneous surface.¹⁸ Dermatoscopy is currently considered the most applicable the evaluation of vulvar disease out the techniques studied in this thesis, despite the need for robust

scoring systems and a collection of reference images. Adopting dermatology would be especially feasible for in the vulvar clinics affiliated with dermatological practices, which will probably have the systems readily available. This is not the case for D-OCT, stereophotogrammetry or RCM systems, which are more cumbersome for image capture and subsequent analysis and interpretation. RCM probably is the most promising novel technique to follow in the upcoming years, because of the non-invasive nature combined with real-time cellular-resolution image capture down to the dermis. Further improvements of the image resolution and building of a reference log of all vulvar diseases may in the future lead to application of this non-invasive technique in the outpatient clinic or operation rooms.

Two highlighted technical advancements that are expected to have a substantial impact in the future are line field confocal optical coherence tomography (LC-OCT) and artificial intelligence (AI). LC-OCT is a new imaging system that combines the cross-sectional view and blood flow measurements of OCT with the cellular resolution of RCM.¹⁹ LC-OCT has improved resolution at depth and the system allows for further automated analyses, including cell type count and recognition, using automated analysis software. Recent pilot studies in dermatology have used LC-OCT for the characterisation of melanocytic lesions and basal and squamous cell carcinoma.²⁰⁻²³ This new technique has not previously been used on the vulvar area, but may have the potential to overcome several of the limitations identified for D-OCT and RCM imaging. Technological advancements has also made way for development and integration of deep-learning-based algorithms for image analysis in the medical field.²⁴ Dermatology is especially suitable for incorporation of AI-aided pattern recognition to support clinical diagnosis. This also applies to the pathological examination of biopsy tissue.²⁵ The expectation is that AI will be incorporated into dermatological image analysis to improve objective and accurate scoring and diagnosis in the near future.²⁶

SECTION II: THE VULVAR MICROBIOME

Investigations pertaining to the microbiome composition, the collective of all microbial taxa and their genes within a community, are subject to significant attention of researchers and industry alike.²⁷⁻²⁹ The crosstalk observed between the human body and 'our second genome' can explain a great deal of diversity in our population.³⁰ The microbiome constitutes essential components of the digestive system and has direct effects on drug metabolism

and interactions. In addition, the immune system is shaped by our co-existing micro-organisms, forming a barrier against pathogens and directly influencing immune reactions.³¹ Perturbations of the microbiome have been described in a wide variety of disciplines, including gastroenterology, gynaecology, neurology and psychiatry, endeavouring to describe a causative role in diseases ranging from bacterial vaginosis to depression.^{32,33} Many of these findings have proven robust over the years, but the research field should keep in mind that the microbiome is highly complex and the direction of causality of observed correlations should always be critically appraised. Upon the discovery of certain dysbiosis patterns in disease states, industry has responded with a panacea of pro- and pre-biotics with insistent claims loosely based on scientific consensus.³⁴⁻³⁶ These formulations often contain a single modified strain or species. However, the microbiome composition as a balanced, holistic system seems forgotten. These potential shortfalls in the microbiome field are considerations that should be appraised critically, especially during the development of pharmaceutical products. In this thesis, we have attempted to remain prudent in the elucidation of the microbiome composition of the vulvar niche. Although the vaginal microbiome has been a focal subject in gynaecological microbiome research, little to no attention has been given to the vulva. This untapped field may clarify aetiological factors for LS or provide clues that can explain malignant disease progression of other vulvar premalignancies.

Firstly, the normal vulvar microbiome composition and the diversity within what is considered 'healthy' should be defined. Therefore, we performed a systematic review of the available literature in **chapter 6**. In this review, 10 studies were identified that describe the microbiome composition of 261 women. Most studies were performed in healthy, Caucasian or Asian women aged 18-55 years. Only two studies reported on the vulvar microbiome composition of premenarchal girls, one of which included 5 girls with LS. The main findings showed that the bacterial composition of the vulva contains a mix of commensals often associated with vaginal, intestinal and cutaneous niches, with a distinctly higher diversity on the vulva than the vagina. This supports the function of the vulva as transitional epithelium from the vaginal mucosa to the genital skin. Overall, the available data on the vulvar microbiome composition contains an underrepresentation of age categories, diverse ethnic groups and patients with vulvar disease. Discoveries in microbiome research are highly dependent on the applied sequencing and analysis

techniques. Therefore, we recommended metagenomic sequencing as preferred method for future studies to the vulvar microbiome composition. This technique can determine the complete genomic makeup in a sample, also supplying functional information of the gene pool in addition to identification of the present species.

The findings of the review also showed an absence of comprehensive, prospective studies in premalignant and malignant patient groups. The microbiome composition of vulvar HSIL and LS was compared to healthy volunteers in **chapter 7**. This study was performed as part of the multi-modal pilot study described in the first section of this thesis. Metagenomic sequencing was performed on vulvar, vaginal and anal swabs of 10 patients with LS, 5 patients with vulvar HSIL and 10 healthy controls. No significant differences were observed in diversity and richness between healthy and diseased vulvar skin. The labia minora of LS patients was mainly populated by bacteria of the *Lactobacillus*, *Prevotella* and *Gardnerella* genera. In vulvar HSIL, *Prevotella* and *Alphapapillomavirus* were the most described taxa. Healthy vulvar skin mainly comprised of *Prevotella* and *Lactobacillus*. Compared to the healthy vulvar skin, the vulvar microbiome composition of both LS and vulvar HSIL patients was characterized by significantly higher proportions of *Papillomaviridae*. In contrast, *Bacteroidia* and *Actinobacteria* were less abundant in respectively LS and vulvar HSIL compared to healthy vulvar skin. While bacteria and viruses were most abundant, fungal and archaeal taxa were scarcely observed. Trans-epidermal water loss, a biomarker for the barrier function of the skin, was increased in affected skin compared to healthy vulvar skin. This could be due to a disruption in barrier function from disease processes or locational differences in vulvar skin composition (mucosal vs. hirsute). Alternatively in LS, increased skin permeability may enable HPV infection of affected vulvar skin. This study was the first to describe the vulvar microbiome composition in LS and vulvar HSIL using sequencing-based methods on the vulva compared to healthy controls. It should be noted that this study remains a cross-sectional pilot with low numbers of participants, with a predominantly Caucasian population. Therefore, the observations from this study require validation in an expanded and more diverse group, also including women with dVIN and vSCC to capture the complete disease range from healthy vulvar skin to cancer. This study provides new clues to the aetiology of LS and a steppingstone for expansion of knowledge on potential drivers of vulvar premalignant disease.

Considerations and future applications

The current findings of the vulvar microbiome composition reflect its transitional anatomical location, with identified commensals associated with vaginal, cutaneous and intestinal milieus. Extra layers of complexity can be expected from demographics including age and ethnicity, in addition to biological processes as menstruation and lifestyle factors such as hygiene practices, sexual activities and contraceptive use. Although the vulvar microbiome research field is of modest size, one recently published study was appraised the microbiome composition in adult women with LS, identifying a reduction of *Lactobacillus* genera and a higher proportion of *Prevotella spp.* in patients.³⁸ In addition, two new studies have recently been initiated focusing on the vulvar microbiome composition in adult women with LS (NCT05671263, NCT05147129).^{39,40} Urology research in male LS may also be informative for translation understanding the interactions of the microbiome and vulvar disease, although the hypothesised aetiology of LS in males is centred around chronic irritation due to micro-incontinence.^{41,42} For vulvar HSIL, no recent or ongoing microbiome studies were identified. Still, the described relationships between the microbiome and cervical dysplasia poses potential for guiding hypotheses in the vulvar field. Interactions between the microbiome and existing and novel treatments can be appraised after the microbiome signature of vulvar diseases has been clarified further. Remarkably, there is no understanding of the effect of topical corticosteroids on the microbiome composition of the skin, although this is the golden standard for treatment of a multitude of dermatological diseases. The description of the microbiome composition in vulvar diseases is still in its infancy. The vulvar location is still a minute niche within microbiome research. Extensive efforts are yet needed to fully understand the exact relationships between the microbiome and vulvar health and disease (*Table 2*).

Perspectives

DEVELOPMENT PIPELINES AND FUTURE THERAPEUTIC OPTIONS FOR VULVAR (PRE)MALIGNANT DISEASE

A joint feature of the diseases described in this thesis is the paucity of disease-specific, patient-friendly and effective therapeutic options. However, the development pipeline of novel treatments for vSCC and its precursors appears depleted compared to other, more prevalent, (pre)malignant diseases. This

situation can partially be attributed to the persisting social taboo on vulvar disease and numerous other factors common to ‘orphan’ diseases. These include difficulty of recruiting patients for research, lack of industry incentive to develop therapies for small markets, shortfalls of clinical detection techniques and, as a consequence, the absence of effective screening approaches.⁵⁴ Both for vulvar HSIL and LS, there is gap in our knowledge on the cause of disease origins and drivers of malignant development. Unlike for LS, we have recognised the causative agent of vulvar HSIL: persistent high-risk HPV infections. Yet, exactly which factors contribute to disease progression from vulvar HSIL to HPV-positive VSCC, and of LS into dVIN and HPV-negative VSCC remains largely unknown.⁵⁵ The survival rate for VSCC has been stagnant over the past decades, with some recent reports are even suggesting a decrease in survival numbers and rise in VSCC incidence rates, possibly stemming from increased incidence of precursor lesions.^{54,56-58}

Lichen sclerosus

Ongoing clinical trials to LS are sparse, with a few noteworthy observational studies on histological biomarkers (NCT03561428) and the microbiome composition (NCT05671263, NCT05147129).^{39,40,59} The majority of current interventional trials investigate the application of several types of ablative lasers on LS (e.g. NCT05010421).⁶⁰ However, laser treatment for LS is currently advised against by international guidelines due to low-quality evidence and lack of long-term follow up.^{61,62} In 2022, a clinical trial was initiated with topical ruxolitinib (brand name Opzelura) in vulvar LS patients (NCT0593445).⁶³ Ruxolitinib is a small molecule Janus kinase (JAK) type 1-2 inhibitor that has been on the market as oral immune modulator for the past two decades. It was approved in topical formulation by the FDA for the treatment of vitiligo in 2022.^{64,65} The inhibition of the JAK/STAT signalling pathway leads to prevention of cytotoxic T-cell recruitment through reducing IFN- γ and downstream chemokine ligand 9 and 10 (CXCL9/CXCL10) signalling. In vitiligo, cytotoxic T-cell mediated inflammatory damage to melanocytes is an established cause of the condition.^{66,67} For LS, however, the aetiology of disease remains unknown. Inhibition of the JAK/STAT pathway may well reduce cytotoxic T-cell driven inflammation in diseased LS skin, but a mechanistic rationale to target this mechanism specifically in LS seems lacking from a pharmacological standpoint.

A major shortfall in several recent and ongoing clinical trials to LS is the requirement of ‘histologically proven LS’ as an inclusion criterium.⁶⁸ In a recently published study with primarily non-invasive outcome measures, 63% (65/102) of potential patients were excluded based to a lack of diagnosis confirmation by pathology.⁶⁹ We emphasize that LS is primarily a clinical diagnosis. According to national and international clinical guidelines, LS is a diagnosis made on clinical examination and patient history. Clinical invasive biopsy procedures must be limited to one of the following three conditions: 1) diagnostic uncertainty, 2) suspicion for malignancy or 3) unsatisfactory treatment results.⁷⁰ LS can present heterogenic on histology, prompting uncertainties from a pathological point of view.^{71,72} Disease duration, disease activity, cutaneous thinning from corticosteroid use, scarring and previous surgical interventions can influence the histological presentation. The clinical diagnosis must take precedent in case of ambiguous findings from pathology.⁷³ Obtaining histological ‘proof’ of a LS diagnosis should be considered a disservice to the patient, in the absence of the aforementioned conditions on the contrary. If clinical studies primarily focus on non-invasive assessments for clinical follow up, it is misguided to adopt ‘histologically proven LS’ as inclusion criterium. Primarily, the study results will only apply for a subset of LS phenotypes. Secondly, these study protocols should be flagged by medical ethical committees, as the LS patients are exposed to unnecessary invasive procedures. On a more practical note, otherwise eligible patients are excluded from study participation, impacting financial resources and logistical study timelines. Thus, collecting biopsies in a LS population should be limited to clinical studies with objectives that require tissue analysis, including histology, immunohistochemistry and gene expression analyses.

Vulvar HSIL

The efficacy evaluation of existing and experimental treatments for vulvar HSIL and dVIN mainly depends on non-standardized clinician-based scoring and rarely (\pm 1/3 of studies) on patient-reported symptoms.² Objective and sensitive efficacy core outcome measures are required, but identifying and selecting reliable and reproducible biomarkers for vulvar (pre)malignant diseases remains challenging. Different vulvar disease subtypes can have varying therapeutic responses. For instance, subcategories of VSCC can be stratified by immunohistochemical P16 and P53 mutant or wildtype

signatures.⁷⁴ These molecular vsCC subtypes have distinct overall survival, relative survival and recurrence-free period rates. Additionally, the response rates to immunotherapy (e.g. therapeutic HPV vaccination) in vulvar HSIL are correlated to specific pre-existent inflammatory microenvironments.⁷⁵ These findings exemplify that there are distinctive potential biological targets for treatment of vulvar (pre)malignant disease, which require specific efficacy evaluations. These findings underline the importance of venturing beyond clinician and patient-reporting alone in the appraisal of vulvar disease, potentially including imaging, molecular, biophysical and sequencing techniques, as discussed in this thesis.

Imiquimod was approved for the treatment of external genital warts in 1997 by the FDA and has since been recognized as effective first-line topical treatment option for vulvar HSIL.^{76,77} Therapeutic HPV-vaccination has been identified as effective treatment for vulvar and vaginal HSIL, with approximately 50% efficacy.^{78,79} This clinical response to HPV-vaccination relates to the strength of vaccine-induced HPV-16-specific T-cell immunity.⁸⁰ International preventive HPV-vaccination strategies are showing decreases in cervical dysplasia rates and other HPV-related disease incidence, which is also promising for the future of HPV-dependent SCC and its precursors.^{81,82} In the meantime, few novel therapeutic options are being investigated specifically targeting vulvar HSIL. A proportion originates from re-purposing of antiviral or immunomodulatory drugs (NCT03792516).⁸³⁻⁸⁵ Alternatively, experimental treatments for cervical dysplasia are occasionally also tested for efficacy in vulvar HSIL, conjecturing that the shared HPV-mediated aetiology could also yield comparable treatment responses.^{86,87} This could lead to co-developed breakthroughs for the treatment of vulvar HSIL, as was the case with the HPV vaccine. However, this grouping of diseases may erroneously dismiss some clinically relevant differences (i.e. clinical presentation, embryonic nature of affected tissue, natural disease history, management and follow up) between cervical and vulvar dysplasia. These discrepancies between disease types should be considered in the appraisal of these traversing treatment strategies.⁸⁸

CALL FOR MULTI-MODAL BIOMARKERS FOR INTEGRATION INTO FUTURE STUDIES TO VULVAR DISEASES

Novel therapeutic options should be developed based on expanded proficiency of biological and pharmacological processes. In depth understanding

of the processes that drive disease can be obtained using the multi-modal approach for dermatological disease characterisation introduced in the introduction of this thesis. Once more, these core domains are:

- 1 Clinician
- 2 Patient-reporting
- 3 Biophysical assessments
- 4 Analysis of invasive procedures such as biopsies, including histology and gene expression analyses
- 5 Microbiome research
- 6 Imaging

The latter two areas have extensively been discussed in this thesis. The remaining domains have also evolved regarding vulvar premalignant disease.

Clinician-based scoring is generally considered an objective outcome measurement for the appraisal of treatment effects. However, the definition of clinical response is heterogeneously applied. For LS, several clinical scoring systems have been suggested, but are not widely adopted in clinical practice.^{89,90} These may report excellent intra- and inter-rater performance, but are not applicable or validated for the follow up of treatment effects. Classification of lesional dimensions according to the ‘response evaluation criteria in solid tumours’ (RECIST) guidelines into response categories can be used to follow disease regression or progression in vulvar HSIL.^{91,92} This does require improvements in reliable lesion size measurement and accurate photo-documentation. The current clinical scoring algorithms alone are therefore not the optimal measurement tool to reliably evaluate the response to novel treatments. Current evidence for the treatment of the LS or vulvar HSIL is particularly lacking implementation of the traditionally considered ‘subjective’ patient-oriented outcome measures, including their symptoms, behaviours and experiences.^{2,93} Arguably, the patient perspective should be an integral part of both clinical trials and clinical practice, considering the substantial morbidity associated with these vulvar diseases. Fortunately, an increasing amount of research and therapeutic efforts are focusing on the impact of LS on the quality of life, including sexual aspects (NCT03419377).^{68,94-96} For vulvar HSIL, few quality of life instruments have been developed and validated specifically for this population, usually relying on adaptations of questionnaires developed for other diseases.^{97,98} This patient-oriented domain is therefore a fundamental part of the multi-modal model proposed in this thesis that requires further expansion in future

research. Biophysical measurements have rarely been evaluated on the vulvar area, nor for the evaluation of therapeutic effect. The makeup of the healthy vulvar skin barrier function has previously been determined using the ceramide content in the epidermis after tape-stripping or determining the trans-epidermal water loss.^{45,99} The state of the skin barrier function can relate to the permeability of topically applied drugs, influencing dermal pharmacokinetics. Similarly, the solubility of pharmaceutical compounds can depend on local pH. Neither of these biophysical properties have been described for LS or vulvar HSIL. Whereas this thesis has focused on non-invasive biomarkers for vulvar diseases, many lessons are yet to be learned from analyses of biopsy tissue. Improvements in the histological recognition dVIN are acutely needed to make robust diagnoses.¹⁰⁰⁻¹⁰² The pathological presentation LS is heterogeneous.^{71,72} Several immunohistochemical biomarkers have been recognized to offset specific disease subtypes, but accurate disease recognition remains challenging.¹⁰³ Gene expression analyses may uncover leads to understand vulvar disease aetiology or drivers of malignant progression.^{104,105} Considerable collaborative efforts are needed across research groups and clinical institutions to obtain sufficient patient material and supporting clinical data to detect meaningful results.

Each domain from this comprehensive approach has become a distinct specialty, with required proficiency in methodology, interpretation, analytics, and clinical integration. The integrated analysis of multi-omics will be the major challenge in the years to come (*Figure 1*).¹⁰⁶ Sequencing-based domains (e.g. microbiome composition analyses, genetic sequencing, transcriptomics and protein identification) yield highly complex data. Combining these datasets could delineate meaningful biological signatures of disease processes. However, that process will demand considerable computational power and comprehension of each separate method.¹⁰⁷ For the vulvar disease, these developments will hopefully lead to improved clinical outcomes through accelerated disease recognition and identification of new, disease-specific therapeutic targets.

Table 1 Current advantages and disadvantages for each imaging system studied in this thesis for practical application in vulvar disease monitoring.

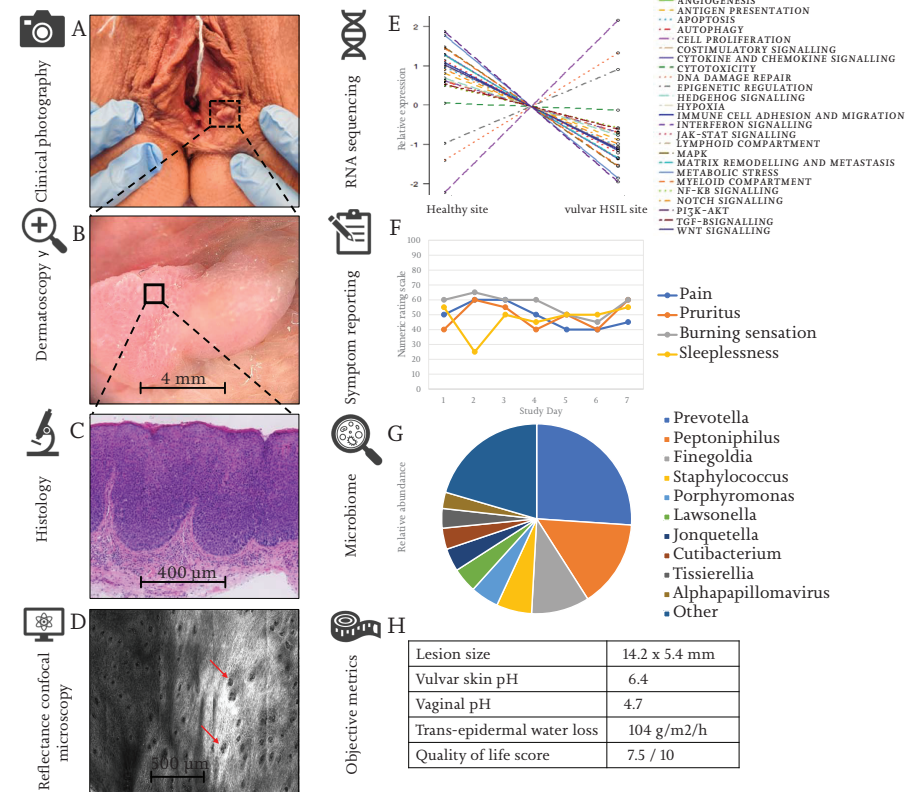
	3D	Dermatoscopy	D-OCT	RCM
Easy to use	Yes	Yes	No	No
Easy to analyse	No	Yes	No	No
Acquisition costs	Moderate	High*	High	High
Training of staff	Low	Moderate*	High	High
Resolution	Good	Good	Moderate	Excellent
Sub-surface visualisation	No	No	Yes	Yes
Patient burden**	Low	Low	Mild	Moderate
Correlation golden standard?	Yes	Yes	No	Yes
Clinical validation	No	No	No	No
Ready for clinical use?	No	No	No	No
Clinical integration?	No	Yes*	No	No

3D dynamic optical coherence tomography (D-OCT), reflectance confocal microscopy (RCM). / *A dermatoscopy system is often already present in dermatology clinic, thus acquisition and training costs may be reduced in practice. / ** All techniques are non-invasive procedures, but the amount time of having to remain still for the duration of image acquisition of the vulvar area (30 seconds for D-OCT, 5-15 minutes for RCM) can be considered a burden to some patients.

Table 2 Overview of all studies performed to the vulvar microbiome composition to date, illustrating factors and disease states that have previously been studied, but more importantly which numerous conditions that remains unknown, in addition to currently ongoing clinical trials.

	Health	Disease
Previously studied (small studies)	<p>Specific vulvar locations</p> <ul style="list-style-type: none"> • Labia majora^{43-46, this thesis} • Labia minora^{43,46-50, this thesis} • Vestibulum^{51,52} <p>Cycle-related factors</p> <ul style="list-style-type: none"> • Menarche⁴⁹ • Menstruation⁴⁸ <p>Obesity⁴⁶</p>	<p>Lichen sclerosus</p> <ul style="list-style-type: none"> • Pre-pubertal girls⁵⁰ • Post-menopausal³⁸ • Adult women^{this thesis} <p>Vulvar HSIL^{this thesis}</p> <p>Provoked vestibulodynia⁵²</p> <p>Vulvar vestibulitis syndrome⁵¹</p>
Not previously investigated (Incomplete overview)	<p>Demographic factors</p> <ul style="list-style-type: none"> • Age (including menopause) • Ethnicity <p>Lifestyle factors</p> <ul style="list-style-type: none"> • Washing and bathing • Shaving habits • Toilet hygiene practices • Sexual practices • Underwear choice • Topical products • Contraceptives <p>Within-subject location control</p> <p>Balance between niches</p> <ul style="list-style-type: none"> • Vagina • Skin • Gut 	<p>Vulvar cancer</p> <ul style="list-style-type: none"> • VSCC • Melanoma • Merkel cell <p>Hidradenitis suppurativa</p> <p>Vulvar ulcerative disease</p> <p>Sexual transmitted disease</p> <ul style="list-style-type: none"> • Condyloma acuminata • Syphilis • Herpes <p>Medication use</p> <ul style="list-style-type: none"> • Topical imiquimod • Topical corticosteroids • Oral or topical antibiotics
Prospective studies	None	<p>Lichen sclerosus^{39,40}</p> <p>Lichen planus⁵²</p> <p>Vulvar Paget's disease⁵³</p>

Figure 1 An example of integration of exploratory biomarkers. An example in one individual with vulvar HSIL.



HSIL = high-grade squamous intraepithelial lesions. RNA = Ribonucleic acid

REFERENCES

- 1 Cohen AF, Burggraaf J, Van Gerven JMA, Moerland M, Groeneveld GJ. The use of biomarkers in human pharmacology (Phase I) studies. *Annu Rev Pharmacol Toxicol.* 2015;55:55-74. doi:10.1146/ANNUREV-PHARMTOX-011613-135918
- 2 Jamieson A, Tse SS, Proctor L, Sadownik LA. A Scoping Review of Treatment Outcome Measures for Vulvar Intraepithelial Neoplasia. *J Low Genit Tract Dis.* 2022;26(4):328-338. doi:10.1097/LGT.0000000000000698
- 3 Rissmann R, Moerland M, van Doorn MBA. Blueprint for mechanistic, data-rich early phase clinical pharmacology studies in dermatology. *Br J Clin Pharmacol.* Published online 2020. doi:10.1111/bcp.14293
- 4 Shahriari N, Grant-Kels JM, Rabinovitz H, Oliviero M, Scope A. Reflectance confocal microscopy: Principles, basic terminology, clinical indications, limitations, and practical considerations. *J Am Acad Dermatol.* 2021;84(1):1-14. doi:10.1016/J.JAAD.2020.05.153
- 5 Wan B, Ganier C, Du-Harpur X, et al. Applications and future directions for optical coherence tomography in dermatology. *Br J Dermatol.* 2021;184(6):1014-1022. doi:10.1111/BJD.19553
- 6 Rijsbergen M, Niemeyer-van der Kolk T, Hogendoorn G, et al. A randomized controlled proof-of-concept trial of digoxin and furosemide in adults with cutaneous warts. *Br J Dermatol.* 2019;180(5):1058-1068. doi:10.1111/bjd.17583
- 7 Borghi A, Virgili A, Corazza M. Dermoscopy of Inflammatory Genital Diseases: Practical Insights. *Dermatol Clin.* 2018;36(4):451-461. doi:10.1016/J.DET.2018.05.013
- 8 Maatouk I, Apalla Z, Errichetti E, Lallas A. Dermoscopy for urologists: an update on patterns of tumors, inflammatory and infectious diseases of the genitalia, and tips for differential diagnosis. *Int J Dermatol.* 2021;60(10):1211-1218. doi:10.1111/IJD.15333
- 9 Lacarrubba F, Borghi A, Verzi AE, Corazza M, Stinco G, Micali G. Dermoscopy of genital diseases: a review. *J Eur Acad Dermatol Venereol.* 2020;34(10):2198-2207. doi:10.1111/jdv.16723
- 10 Larre Borges A, Tiodorovic-Zivkovic D, Lallas A, et al. Clinical, dermoscopic and histopathologic features of genital and extragenital lichen sclerosis. *J Eur Acad Dermatol Venereol.* 2013;27(11):1433-1439. doi:10.1111/j.1468-3083.2012.04595.x
- 11 Katkar RA, Tadinada SA, Amaechi BT, Fried D. Optical Coherence Tomography. *Dent Clin North Am.* 2018;62(3):421-434. doi:10.1016/J.CDEN.2018.03.004
- 12 Braga JCT, Macedo MP, Pinto C, et al. Learning reflectance confocal microscopy of melanocytic skin lesions through histopathologic transversal sections. *PLoS One.* 2013;8(12). doi:10.1371/journal.pone.0081205
- 13 Dinnes J, Deeks JJ, Saleh D, et al. Reflectance confocal microscopy for diagnosing cutaneous melanoma in adults. *Cochrane database Syst Rev.* 2018;12(12):CD013190. doi:10.1002/14651858.CD013190
- 14 Lan J, Wen J, Cao S, et al. The diagnostic accuracy of dermoscopy and reflectance confocal microscopy for amelanotic/hypomelanotic melanoma: a systematic review and meta-analysis. *Br J Dermatol.* 2020;183(2):210-219. doi:10.1111/bjd.18722
- 15 Hoang LN, Park KJ, Soslow RA, Murali R. Squamous precursor lesions of the vulva: current classification and diagnostic challenges. *Pathology.* 2016;48(4):291-302. doi:10.1016/j.pathol.2016.02.015
- 16 Hogendoorn GK, Bruggink SC, de Koning MNC, et al. Morphological characteristics and human papillomavirus genotype predict the treatment response in cutaneous warts. *Br J Dermatol.* 2018;178(1):253-260. doi:10.1111/bjd.15758
- 17 Hibler BP, Qi Q, Rossi AM. Current state of imaging in dermatology. *Semin Cutan Med Surg.* 2016;35(1):2-8. doi:10.12788/sjder.2016.001
- 18 Gagné HM. Colposcopy of the vagina and vulva. *Obstet Gynecol Clin North Am.* 2008;35(4):659-669; x. doi:10.1016/j.jogc.2008.10.002
- 19 Chauvel-Picard J, Bérout V, Tognetti L, et al. Line-field confocal optical coherence tomography as a tool for three-dimensional in vivo quantification of healthy epidermis: A pilot study. *J Biophotonics.* 2022;15(2):e202100236. doi:10.1002/jbio.202100236
- 20 Cinotti E, Bertello M, Cartocci A, et al. Comparison of reflectance confocal microscopy and line-field optical coherence tomography for the identification of keratinocyte skin tumours. *Ski Res Technol Off J Int Soc Bioeng Ski [and] Int Soc Digit Imaging Ski [and] Int Soc Ski Imaging.* Published online November 2022. doi:10.1111/srt.13215
- 21 Verzi AE, Micali G, Lacarrubba F. Line-Field Confocal Optical Coherence Tomography May Enhance Monitoring of Superficial Basal Cell Carcinoma Treated with Imiquimod 5% Cream: A Pilot Study. *Cancers (Basel).* 2021;13(19). doi:10.3390/cancers13194913
- 22 Schuh S, Ruini C, Perwein MKE, et al. Line-Field Confocal Optical Coherence Tomography: A New Tool for the Differentiation between Nevi and Melanomas? *Cancers (Basel).* 2022;14(5). doi:10.3390/cancers14051404
- 23 Perez-Anker J, Puig S, Alos L, et al. Morphological evaluation of melanocytic lesions with three-dimensional line-field confocal optical coherence tomography: correlation with histopathology and reflectance confocal microscopy. A pilot study. *Clin Exp Dermatol.* 2022;47(12):2222-2233. doi:10.1111/ced.15383
- 24 Li Z, Koban KC, Schenck TL, Giunta RE, Li Q, Sun Y. Artificial Intelligence in Dermatology Image Analysis: Current Developments and Future Trends. *J Clin Med.* 2022;11(22). doi:10.3390/jcm11226826
- 25 Jartarkar SR, Cockerell CJ, Patil A, et al. Artificial intelligence in Dermatopathology. *J Cosmet Dermatol.* Published online December 2022. doi:10.1111/jocd.15565
- 26 Ring C, Cox N, Lee JB. Dermatoscopy. *Clin Dermatol.* 2021;39(4):635-642. doi:10.1016/J.CLINDERMATOL.2021.03.009
- 27 Byrd AL, Belkaid Y, Segre JA. The human skin microbiome. *Nat Rev Microbiol.* 2018;16(3):143-155. doi:10.1038/nrmicro.2017.157
- 28 Marcon AR, Turvey S, Caulfield T. 'Gut health' and the microbiome in the popular press: a content analysis. *BMJ Open.* 2021;11(7):e052446. doi:10.1136/bmjopen-2021-052446
- 29 KBV Research. *Global Printed Electronics Market Size, Share & Industry Trends Analysis Report By Material, By Technology, By Device, By Regional Outlook and Forecast, 2022 - 2028.*; 2022. Accessed January 22, 2023. <https://www.globenewswire.com/en/news-release/2022/11/02/2546254/28124/en/Global-Human-Microbiome-Market-Report-2022-Rising-Focus-on-the-Development-of-Therapeutics-Driving-Growth.html>
- 30 Grice EA, Segre JA. The human microbiome: our second genome. *Annu Rev Genomics Hum Genet.* 2012;13:151-170. doi:10.1146/ANNUREV-GENOM-090711-163814
- 31 Picardo SL, Coburn B, Hansen AR. The microbiome and cancer for clinicians. *Crit Rev Oncol Hematol.* 2019;141:1-12. doi:10.1016/j.critrevonc.2019.06.004
- 32 Valles-Colomer M, Falony G, Darzi Y, et al. The neuroactive potential of the human gut microbiota in quality of life and depression. *Nat Microbiol.* 2019;4(4):623-632. doi:10.1038/s41564-018-0337-x
- 33 Zwitterink RD, van den Munkhof EHA, Leverstein-van Hall MA, et al. The vaginal microbiota in the course of bacterial vaginosis treatment. *Eur J Clin Microbiol Infect Dis.* 2021;40(3):651-656. doi:10.1007/s10096-020-04049-6
- 34 Yoshikata R, Yamaguchi M, Mase Y, Tatsuyuki A, Myint KZY, Ohta H. Evaluation of the efficacy of Lactobacillus-containing feminine hygiene products on vaginal microbiome and genitourinary symptoms in pre- and postmenopausal women: A pilot randomized controlled trial. *PLoS One.* 2022;17(12):e0270242. doi:10.1371/journal.pone.0270242
- 35 Falagas ME, Betsi GI, Athanasiou S. Probiotics for the treatment of women with bacterial vaginosis. *Clin Microbiol Infect Off Publ Eur Soc Clin Microbiol Infect Dis.* 2007;13(7):657-664. doi:10.1111/j.1469-0691.2007.01688.x
- 36 Armstrong E, Hemmerling A, Miller S, et al. Sustained effect of LACTIN-V (Lactobacillus crispatus CTV-05) on genital immunology following standard bacterial vaginosis treatment: results from a randomised, placebo-controlled trial. *The Lancet Microbe.* 2022;3(6):e435-e442. doi:10.1016/S2666-5247(22)00043-X
- 37 Management of symptomatic vulvovaginal atrophy: 2013 position statement of The North American Menopause Society. *Menopause.* 2013;20(9):884-888. doi:10.1097/GME.0b013e3182a122c210.1097/GME.0b013e3182a122c2
- 38 Liu X, Zhuo Y, Zhou Y, Hu J, Wen H, Xiao C. Analysis of the Vulvar Skin Microbiota in Asymptomatic Women and Patients With Vulvar Lichen Sclerosus Based on 16S rRNA Sequencing. *Front Cell Dev Biol.* 2022;10:842031. doi:10.3389/fcell.2022.842031
- 39 Characterizing the Microbiome in Postmenopausal Women With Vulvar Lichen Sclerosus - Full Text View - ClinicalTrials.gov. Accessed January 11, 2023. <https://clinicaltrials.gov/ct2/show/NCT05147129?cond=lichen+sclerosus&draw=2&rank=10>
- 40 Genital Lichen Sclerosus - Epidemiology, Comorbidities and the Role of Vulvar and Penile Microbiome - Full Text View - ClinicalTrials.gov. Accessed January 14, 2023. <https://clinicaltrials.gov/ct2/show/NCT05671263?cond=lichen+sclerosus&draw=2&rank=2>
- 41 Watchorn RE, van den Munkhof EHAA, Quint KD, et al. Balanopreputial sac and urine microbiota in patients with male genital lichen sclerosis. *Int J Dermatol.* 2020;60(2):201-207. doi:10.1111/ijd.15252
- 42 Cohen AJ, Gaither TW, Srirangapatnam S, et al. Symchronous genitourinary lichen sclerosis signals a distinct urinary microbiome profile in men with urethral stricture disease. *World J Urol.* 2020;39(2). doi:10.1007/s00345-020-03198-9
- 43 Brown CJ, Wong M, Davis CC, Kanti A, Zhou X, Forney LJ. Preliminary characterization of the normal microbiota of the human vulva using cultivation-independent methods. *J Med Microbiol.* 2007;55(PART 2):271-276. doi:10.1099/jmm.0.46607-0
- 44 Bruning E, Chen Y, McCue KA, Rubino JR, Wilkinson JE, Brown ADG. A 28 Day Clinical Assessment of a Lactic Acid-containing Antimicrobial Intimate Gel Wash Formulation on Skin Tolerance and Impact on the Vulvar Microbiome. *Antibiot (Basel, Switzerland).* 2020;9(2). doi:10.3390/antibiotics9020055
- 45 Miyamoto T, Akiba S, Sato N, et al. Study of the vulvar skin in healthy Japanese women: components of the stratum corneum and
- 46 Vongsa R, Hoffman D, Shepard K, Koenig D. Comparative study of vulva and abdominal skin microbiota of healthy females with high and average BMI. *BMC Microbiol.* 2019;19(1):16. doi:10.1186/s12866-019-1391-0
- 47 Costello EK, Lauber CL, Hamady M, Fierer N, Gordon JI, Knight R. Bacterial community variation in human body habitats across space and time. *Science (80-).* 2009;326(5960):1694-1697. doi:10.1126/science.1177486
- 48 Shiraishi T, Fukuda K, Morotomi N, et al. Influence of menstruation on the microbiota of healthy women's labia minora as analyzed using a 16S rRNA gene-based clone library method. *Jpn J Infect Dis.* 2011;64(1):76-80.
- 49 Hickey RJ, Zhou X, Settles ML, et al. Vaginal microbiota of adolescent girls prior to the onset of menarche resemble those of reproductive-age women. *MBio.* 2015;6(2). doi:10.1128/mBio.00097-15
- 50 Chattopadhyay S, Arnold JD, Malayil L, et al. Potential role of the skin and gut microbiota in premenarchal vulvar lichen sclerosis: A pilot case-control study. *PLoS One.* 2021;16(1):e0245243. doi:10.1371/journal.pone.0245243
- 51 Jayaram A, Witkin SS, Zhou X, et al. The bacterial microbiome in paired vaginal and vestibular samples from women with vulvar vestibulitis syndrome. *Pathog Dis.* 2014;72(3):161-166. doi:10.1111/2049-632X.12197
- 52 Murina F, Caimi C, Di Piero F, Di Francesco S, Cetin I. Features of the Vaginal and Vestibular Microbioma in Patients With Vestibulodynia: A Case-Control Study. *Journal of Lower Genital Tract Disease.* 24(3), 290-294. *J Low Genit Tract Dis.* 2020;24(3):290-294. doi:10.1097/LGT.0000000000000523
- 53 Gynecologic Extramammary Paget's Disease - Full Text View - ClinicalTrials.gov. Accessed January 18, 2023. <https://clinicaltrials.gov/ct2/show/NCT03564483?term=microbiome&cond=vulva&draw=2&rank=3>
- 54 Bodelon C, Madeleine MM, Voigt LF, Weiss NS. Is the incidence of invasive vulvar cancer increasing in the United States? *Cancer Causes Control.* 2009;20(9):1779-1782. doi:10.1007/s10552-009-9418-8
- 55 Pinto AP, Miron A, Yassin Y, et al. Differentiated vulvar intraepithelial neoplasia contains Tps3 mutations and is genetically linked to vulvar squamous cell carcinoma. *Mod Pathol an Off J United States Am Acad Pathol Inc.* 2010;23(3):404-412. doi:10.1038/modpathol.2009.179
- 56 Thuijs NB, van Beurden M, Bruggink AH, Steenbergen RDMM, Berkhof J, Bleeker MCGG. Vulvar intraepithelial neoplasia: Incidence and long-term risk of vulvar squamous cell carcinoma. *Int J cancer.* 2021;148(1):90-98. doi:10.1002/ijc.33198
- 57 Akhtar-Danesh N, Elit L, Lytwyn A. Trends in incidence and survival of women with invasive vulvar cancer in the United States and Canada: A population-based study. *Gynecol Oncol.* 2014;134(2):314-318. doi:https://doi.org/10.1016/j.ygyno.2014.05.014
- 58 Olawaiye AB, Cuello MA, Rogers LJ. Cancer of the vulva: 2021 update. *Int J Gynecol Obstet.* 2021;155(S1):7-18. doi:10.1002/IJGO.13881
- 59 Biomarkers of Lichen Sclerosus - Full Text View - ClinicalTrials.gov. Accessed January 3, 2023. <https://clinicaltrials.gov/ct2/show/NCT03561428?cond=Lichen+Sclerosus&draw=2&rank=1>
- 60 Laser vs Clobetasol for Lichen Sclerosus - Full Text View - ClinicalTrials.gov. Accessed January 14, 2023. <https://clinicaltrials.gov/ct2/show/NCT05010421>
- 61 Krapf JM, Mitchell L, Holton MA, Goldstein AT. Vulvar lichen sclerosis: Current perspectives. *Int J Womens*

- Health. 2020;12:11-20. doi:10.2147/IJWH.S191200
- 62 Preti M, Vieira-Baptista P, Digesu GA, et al. The clinical role of LASER for vulvar and vaginal treatments in gynecology and female urology: An ICS/ISSVD best practice consensus document. *Neurol Urodyn*. 2019;38(3):1009-1023. doi:https://doi.org/10.1002/nuu.23931
- 63 A Study to Evaluate the Efficacy and Safety of Ruxolitinib Cream in Participants With Lichen Sclerosus - Full Text View - ClinicalTrials.gov. Accessed January 3, 2023. <https://clinicaltrials.gov/ct2/show/NCT05593445?cond=Lichen+Sclerosus&draw=2&rank=4>
- 64 FDA approves topical treatment addressing repigmentation in vitiligo in patients aged 12 and older | FDA. Accessed January 10, 2023. <https://www.fda.gov/drugs/news-events-human-drugs/fda-approves-topical-treatment-addressing-repigmentation-vitiligo-patients-aged-12-and-older>
- 65 Hwang JR, Driscoll MS. Review of Ruxolitinib for Treatment of Non-Segmental Vitiligo. *Ann Pharmacother*. Published online December 2022;10600280221143748. doi:10.1177/10600280221143748
- 66 Marchioro HZ, Silva de Castro CC, Fava VM, Sakiyama PH, Dellatorre G, Miot HA. Update on the pathogenesis of vitiligo. *An Bras Dermatol*. 2022;97(4):478-490. doi:10.1016/j.abd.2021.09.008
- 67 Chapman S, Gold LS, Lim HW. Janus kinase inhibitors in dermatology: Part II. A comprehensive review. *J Am Acad Dermatol*. 2022;86(2):414-422. doi:10.1016/j.jaad.2021.06.873
- 68 Wijaya M, Lee G, Fischer G. Why do some patients with vulval lichen sclerosus on long-term topical corticosteroid treatment experience ongoing poor quality of life? *Australas J Dermatol*. 2022;63(4):463-472. doi:https://doi.org/10.1111/ajd.13926
- 69 Günthert AR, Limacher A, Beltraminelli H, et al. Efficacy of topical progesterone versus topical clobetasol propionate in patients with vulvar lichen sclerosus - A double-blind randomized phase II pilot study. *Eur J Obstet Gynecol Reprod Biol*. 2022;272:88-95. doi:10.1016/j.ejogrb.2022.03.020
- 70 Lewis FM, Tatnall FM, Velangi SS, et al. British Association of Dermatologists guidelines for the management of lichen sclerosus, 2018. *Br J Dermatol*. 2018;178(4):839-853. doi:10.1111/bjd.16241
- 71 Scurry J, Whitehead J, Healey M. Histology of lichen sclerosus varies according to site and proximity to carcinoma. *Am J Dermatopathol*. 2001;23(5):413-418. doi:10.1097/00000372-200110000-00005
- 72 Regauer S, Liegl B, Reich O. Early vulvar lichen sclerosus: A histopathological challenge. *Histopathology*. 2005;47(4):340-347. doi:10.1111/j.1365-2559.2005.02209.x
- 73 Nederlandse Vereniging voor Dermatologie en Venerologie. Lichen Sclerosus Richtlijn 2021. Published online 2021:99.
- 74 Kortekaas KE, Santeogoets SJ, Tas L, et al. Primary vulvar squamous cell carcinomas with high T cell infiltration and active immune signaling are potential candidates for neoadjuvant PD-1/PD-L1 immunotherapy. *J Immunother cancer*. 2021;9(10). doi:10.1136/JITC-2021-003671
- 75 Abdulrahman Z, De Miranda N, Van Esch EMG, et al. Pre-existing inflammatory immune microenvironment predicts the clinical response of vulvar high-grade squamous intraepithelial lesions to therapeutic HPV16 vaccination. 2020;8(1):e000563. doi:10.1136/JITC-2020-000563
- 76 van Seters M, van Beurden M, ten Kate FJW, et al. Treatment of vulvar intraepithelial neoplasia with topical imiquimod. *N Engl J Med*. 2008;358(14):1465-1473. doi:10.1056/NEJMoa072685
- 77 Trutnovsky G, Reich O, Joura EA, et al. Topical imiquimod versus surgery for vulvar intraepithelial neoplasia: a multicentre, randomised, phase 3, non-inferiority trial. *Lancet*. 2022;399(10337):1790-1798. doi:10.1016/S0140-6736(22)00469-X
- 78 Kenter GG, Welters MJP, Valentijn ARPM, et al. Vaccination against HPV-16 oncoproteins for vulvar intraepithelial neoplasia. *N Engl J Med*. 2009;361(19):1838-1847. doi:10.1056/NEJMoa0810097
- 79 Welters MJP, Kenter GG, de Vos van Steenwijk PJ, et al. Success or failure of vaccination for HPV16-positive vulvar lesions correlates with kinetics and phenotype of induced T-cell responses. *Proc Natl Acad Sci U S A*. 2010;107(26):11895-11899. doi:10.1073/pnas.1006500107
- 80 van Poelgeest MIE, Welters MJP, Vermeij R, et al. Vaccination against Oncoproteins of HPV16 for Noninvasive Vulvar/Vaginal Lesions: Lesion Clearance Is Related to the Strength of the T-Cell Response. *Clin Cancer Res an Off J Am Assoc Cancer Res*. 2016;22(10):2342-2350. doi:10.1158/1078-0432.CCR-15-2594
- 81 Huh WK, Joura EA, Giuliano AR, et al. Final efficacy, immunogenicity, and safety analyses of a nine-valent human papillomavirus vaccine in women aged 16-26 years: a randomised, double-blind trial. *Lancet (London, England)*. 2017;390(10108):2143-2159. doi:10.1016/S0140-6736(17)31821-4
- 82 Kamolratanakul S, Pitisuttithum P. Human Papillomavirus Vaccine Efficacy and Effectiveness against Cancer. *Vaccines*. 2021;9(12). doi:10.3390/vaccines9121413
- 83 Artesunate Ointment for the Treatment of High Grade Vulvar Intraepithelial Neoplasia (HSIL VIN2/3) - Full Text View - ClinicalTrials.gov. Accessed January 12, 2023. <https://clinicaltrials.gov/ct2/show/NCT03792516?cond=vulvar+HSIL&draw=2&rank=5>
- 84 Stier EA, Goldstone SE, Einstein MH, et al. Safety and efficacy of topical cidofovir to treat high-grade perianal and vulvar intraepithelial neoplasia in HIV-positive men and women. *AIDS*. 2013;27(4):545-551. doi:10.1097/QAD.0b013e32835a9b16
- 85 Rijsbergen M, Rijneveld R, Todd M, et al. Results of phase 2 trials exploring the safety and efficacy of omiganan in patients with human papillomavirus-induced genital lesions. *Br J Clin Pharmacol*. 2020;86(11):2133-2143. doi:10.1111/BCP.14181
- 86 Trimble CL, Morrow MP, Kraynyak KA, et al. Safety, efficacy, and immunogenicity of VGX-3100, a therapeutic synthetic DNA vaccine targeting human papillomavirus 16 and 18 E6 and E7 proteins for cervical intraepithelial neoplasia 2/3: a randomised, double-blind, placebo-controlled phase 2b trial. *Lancet (London, England)*. 2015;386(10008):2078-2088. doi:10.1016/S0140-6736(15)00239-1
- 87 Evaluation of VGX-3100 and Electroporation Alone or in Combination With Imiquimod for the Treatment of HPV-16 and/or HPV-18 Related Vulvar HSIL (Also Referred as: VIN 2 or VIN 3) - Full Text View - ClinicalTrials.gov. Accessed January 13, 2023. <https://clinicaltrials.gov/ct2/show/NCT03180684?cond=vulvar+HSIL&draw=2&rank=2>
- 88 Maclean AB, Jones RW. Differences Between Squamous Intraepithelial Lesions of the Vulva and the Cervix. *J Low Genit Tract Dis*. 2020;24(3):330-331. doi:10.1097/LGT.0000000000000545
- 89 Boero V, Liverani CA, Brambilla M, et al. The 'CIV Classification,' a New Proposal for the Architectural Grading of Vulvar Lichen Sclerosus. *J Low Genit Tract Dis*. 2021;25(4):291-295. doi:10.1097/LGT.0000000000000627
- 90 Günthert AR, Duclos K, Jahns BG, et al. Clinical Scoring System for Vulvar Lichen Sclerosus. *J Sex Med*. 2012;9(9):2342-2350. doi:10.1111/j.1743-6109.2012.02814.x
- 91 Eisenhauer EA, Therasse P, Bogaerts J, et al. New response evaluation criteria in solid tumours: revised RECIST guideline (version 1.1). *Eur J Cancer*. 2009;45(2):228-247. doi:10.1016/j.ejca.2008.10.026
- 92 Rijsbergen M, Rijneveld R, Todd M, et al. Results of phase 2 trials exploring the safety and efficacy of omiganan in patients with human papillomavirus-induced genital lesions. *Br J Clin Pharmacol*. 2020;86(11):2133-2143. doi:10.1111/BCP.14181
- 93 Pergialiotis V, Bellos I, Biliou E-C, Varnava P, Mitsopoulou D, Doumouchtsis SK. An arm-based network meta-analysis on treatments for vulvar lichen sclerosus and a call for development of core outcome sets. *Am J Obstet Gynecol*. 2020;222(6):542-550.e6. doi:10.1016/j.ajog.2019.10.095
- 94 Pope R, Lee MH, Myers A, et al. Lichen Sclerosus and Sexual Dysfunction: A Systematic Review and Meta-Analysis. *J Sex Med*. 2022;19(11):1616-1624. doi:10.1016/J.JSXM.2022.07.011
- 95 Vittrup G, Westmark S, Riis J, et al. The Impact of Psychosexual Counseling in Women With Lichen Sclerosus: A Randomized Controlled Trial. *J Low Genit Tract Dis*. 2022;26(3):258-264. doi:10.1097/LGT.0000000000000669
- 96 Lichen Sclerosus - the Influence on Quality of Life - Full Text View - ClinicalTrials.gov. Accessed January 14, 2023. <https://clinicaltrials.gov/ct2/show/NCT03419377>
- 97 Cedejas BR, Smith-McCune KK, Khan MJ. Does treatment for cervical and vulvar dysplasia impact women's sexual health? *Am J Obstet Gynecol*. 2015;212(3):291-297.
- 98 Likes WM, Stegbauer C, Hathaway D, Brown C, Tillmanns T. Use of the female sexual function index in women with vulvar intraepithelial neoplasia. *J Sex Marital Ther*. 2006;32(3):255-266. doi:10.1080/00926230600575348
- 99 Elsner P, Wilhelm D, Maibach HI. Mechanical properties of human forearm and vulvar skin. *Br J Dermatol*. 1990;122(5):607-614. doi:10.1111/j.1365-2133.1990.tb07282.x
- 100 Morrel B, Ewing-Graham PC, van der Avoort IAM, Pasmans SGMA, Damman J. Structured analysis of histopathological characteristics of vulvar lichen sclerosus in a juvenile population. *Hum Pathol*. 2020;106:23-31. doi:10.1016/j.humpath.2020.09.003
- 101 Hoang LN, Park KJ, Soslow RA, Murali R. Squamous precursor lesions of the vulva: current classification and diagnostic challenges. *Pathology*. 2016;48(4):291-302. doi:10.1016/j.pathol.2016.02.015
- 102 Thuijs NB, Schonck WAM, Klaver LLJ, et al. Biomarker Expression in Multifocal Vulvar High-Grade Squamous Intraepithelial Lesions. *Cancers (Basel)*. 2021;13(2). doi:10.3390/CANCERS13225646
- 103 Nooij LS, Dreef EJ, Smit VTHBM, Van Poelgeest MIE, Bosse T. Stathmin is a highly sensitive and specific biomarker for vulvar high-grade squamous intraepithelial lesions. *J Clin Pathol*. 2016;69(12):1070-1075. doi:10.1136/jclinpath-2016-203676
- 104 Yang M, Sun K, Chang J. Screening differential circular RNAs expression profiles in Vulvar Lichen Sclerosus. *Biomed Eng Online*. 2022;21(1):51. doi:10.1186/s12938-022-01013-7
- 105 Oyama N, Hasegawa M. Lichen Sclerosus: A Current Landscape of Autoimmune and Genetic Interplay. *Diagnostics (Basel, Switzerland)*. 2022;12(12):3070. doi:10.3390/DIAGNOSTICS12123070
- 106 Subramanian I, Verma S, Kumar S, Jere A, Anamika K. Multi-omics Data Integration, Interpretation, and Its Application. *Bioinform Biol Insights*. 2020;14:1177932219899051. doi:10.1177/1177932219899051
- 107 McDermott JE, Wang J, Mitchell H, et al. Challenges in Biomarker Discovery: Combining Expert Insights with Statistical Analysis of Complex Omics Data. *Expert Opin Med Diagn*. 2013;7(1):37-51. doi:10.1517/17530059.2012.718329