



Universiteit  
Leiden

The Netherlands

## Taking a closer look: non-invasive tools for in-depth characterisation of vulvar diseases

Pagan, L.

### Citation

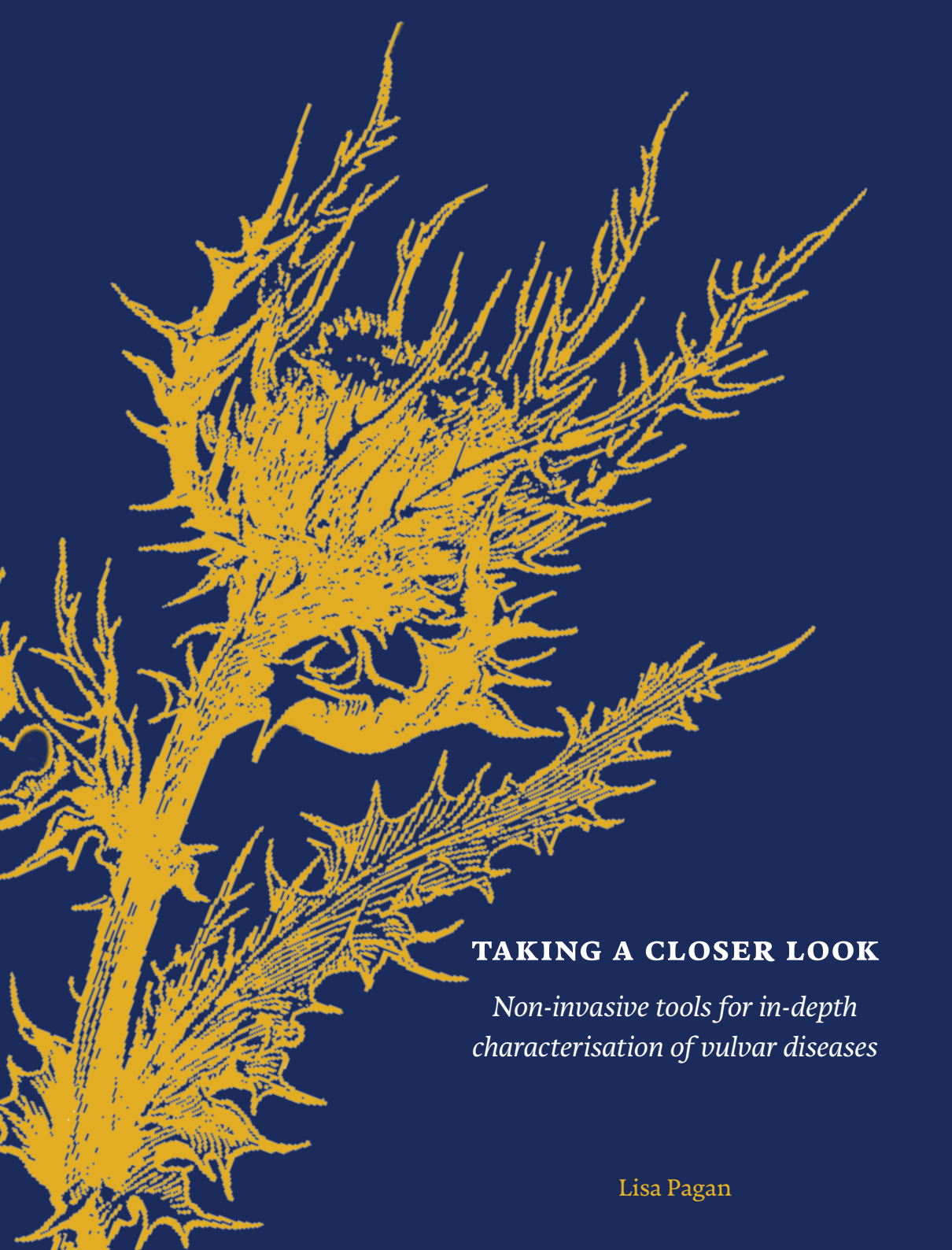
Pagan, L. (2023, December 12). *Taking a closer look: non-invasive tools for in-depth characterisation of vulvar diseases*. Retrieved from <https://hdl.handle.net/1887/3666289>

Version: Publisher's Version

License: [Licence agreement concerning inclusion of doctoral thesis in the Institutional Repository of the University of Leiden](#)

Downloaded from: <https://hdl.handle.net/1887/3666289>

**Note:** To cite this publication please use the final published version (if applicable).



## **TAKING A CLOSER LOOK**

*Non-invasive tools for in-depth  
characterisation of vulvar diseases*

Lisa Pagan

TAKING A CLOSER LOOK

NON-INVASIVE TOOLS FOR IN-DEPTH CHARACTERISATION OF VULVAR DISEASES

# TAKING A CLOSER LOOK

---

## *NON-INVASIVE TOOLS FOR IN-DEPTH CHARACTERISATION OF VULVAR DISEASES*

Proefschrift

ter verkrijging van  
de graad van doctor aan de Universiteit Leiden,  
op gezag van rector magnificus prof.dr.ir. H. Bijl,  
volgens besluit van het college voor promoties  
te verdedigen op dinsdag 12 december 2023

klokke 16:15 uur

door

Lisa Pagan

geboren te Amsterdam

in 1992

© Lisa Pagan, 2023

Design: Caroline de Lint, Den Haag (caro@delint.nl)

Illustrations: illustration page 129 by F.A. van Meurs

Publication of this thesis was financially supported by the foundation Centre  
for Human Drug Research in Leiden, the Netherlands

### **Promotores**

Prof. dr. J. Burggraaf

Prof. dr. R. Rissmann

### **Co-promotor**

Dr. M.I.E. van Poelgeest

### **Leden promotiecommissie**

Prof. dr. J.M.M. van Lith

Prof. dr. E.J. Kuijper

Prof. dr. K. Mosterd (MUMC+)

Dr. M.C.G. Bleeker (AMC)

**CHAPTER 1** Introduction — 7

**SECTION I CHARACTERISING VULVAR AND HPV-DRIVEN DISEASE WITH NOVEL IMAGING TECHNIQUES**

**CHAPTER 2** Stereophotogrammetric 3D photography is an accurate and precise planimetric method for the clinical visualization and quantification of HPV-induced skin lesions — 31

**CHAPTER 3** Dermatoscopy and dynamic optical coherence tomography in vulvar HSIL and lichen sclerosus: a prospective feasibility study — 47

**CHAPTER 4** Reflectance confocal microscopy as a non-invasive imaging tool in vulvar high grade squamous intraepithelial lesions and lichen sclerosus: a descriptive morphological study in patients and healthy volunteers — 65

**CHAPTER 5** Results of a randomized, placebo-controlled, first-in-human trial of topical CY-002 in patients with cutaneous warts — 83

**SECTION II THE VULVAR MICROBIOME**

**CHAPTER 6** The human vulvar microbiome: a systematic review — 109

**CHAPTER 7** The vulvar microbiome in lichen sclerosus and high-grade intraepithelial lesions — 135

**CHAPTER 8** Summary and Discussion — 169

Samenvatting in het Nederlands — 193

Curriculum Vitae — 205

List of Publications — 207

---

*Put on your red shoes  
and dance the blues*

## CHAPTER 1

---

# Introduction



The vulva is the name of the external female genital organs delineated by the mons pubis, groin and anus. Individual components of the vulva include the mons pubis, labia majora, labia minora, clitoris, urethral meatus, vaginal vestibulum, vaginal introitus, Bartholin's and Skene's glands and perineum (Figure 1).<sup>1</sup> The vulva is a unique anatomical site, functioning as a transition zone from the mucosa of the vagina to cutaneous tissue. Histologically, the vulva is a transitional epithelium. The mons pubis, groin and labia majora display a hirsute, keratinised epithelium, whilst a non-adnexal, nonkeratinized mucosal epithelium with sebaceous glands can be found on the labia minora.<sup>2</sup> Vulvar skin requires resilience against urine, faecal matter and vaginal fluor in addition to pressure and friction from physical activities. Simultaneously, it has an essential role to play in sexual stimulation, intercourse and satisfaction. The vulva also endures the stress of childbirth. Considering the various purposes of the vulva, diseases affecting the vulvar area are often experienced as a serious burden.<sup>3-5</sup> Vulvar disease can consequently affect every aspect of daily life, such as urination, defecation, mobility, sexuality, and clothing choice, resulting in considerable physical and psychological morbidity.<sup>6</sup> Shame, social stigma, and taboo associate strongly with genital diseases, resulting in severe underreporting, lack of clinical recognition, delays in proper treatment, deficient etiological knowledge and paucity in development of novel treatments.<sup>6,7</sup> The spectrum of vulvar diseases encompasses benign and malignant conditions. The subsequent sections will expound upon a selection of vulvar pathologies in greater detail.

### PRECURSOR LESIONS OF VSCC: VULVAR HSIL AND DIFFERENTIATED VIN

Vulvar squamous cell carcinoma (VSCC) can arise from two etiologically distinct precursor diseases. The first, vulvar high-grade squamous intraepithelial lesions (HSIL), is caused by human-papillomavirus (HPV) and causes ±20% of VSCC. The remaining ±80% of VSCC cases is preceded by differentiated vulvar intraepithelial neoplasia (dVIN), which develops independently from HPV (Figure 2).<sup>8</sup> Individual HPV types are categorised as low-risk and high-risk HPV types, depending on their oncogenic potential. The Lower Anogenital Squamous Terminology (LAST) guidelines were introduced in 2012 to uniformly name HPV-related lesions of the genital tract, distinguishing low-grade squamous intraepithelial lesions (LSIL) from high-grade squamous intraepithelial lesions (HSIL).<sup>9</sup> Vulvar lesions caused by low-risk HPV-types (formerly VIN I)

are allocated to the LSIL category.<sup>9</sup> Lesions caused by high-risk HPV types are classified as vulvar HSIL (formerly VIN II and III). Lastly, dVIN was recognised separately in the terminology as a distinct, HPV-independent precursor lesion for VSCC. Clinical features of VSCC and its precursors are further explained upon in the forthcoming sections.

### Vulvar HSIL

Vulvar HSIL is caused by high-risk HPV types, most common HPV types 16, 18 and 33.<sup>8</sup> The median age of onset is in a patient's 3rd and 4th decade.<sup>10</sup> Immune suppression and smoking are highly associated with the development and recurrence of vulvar HSIL.<sup>11-13</sup> The majority of affected individuals have symptoms including pruritus, dyspareunia, dysuria, pain and vulvar skin pigmentation.<sup>13</sup> Vulvar HSIL has a malignant potential of 3% with adequate therapy, but this may increase up to 9% when left untreated.<sup>14,15</sup> Only up to 1.5% of vulvar HSIL lesions are reported to regress spontaneously.<sup>15</sup> It is of importance to add cervical dysplasia screening during the treatment of vulvar HSIL patients, as these dysplastic conditions can coincide. Non-surgical treatment options for vulvar HSIL are immune-modulating topical therapies such as the Toll-like receptor 7 and 8 agonist imiquimod.<sup>16,17</sup> Reported efficacy of imiquimod are between 51–58% with 11–16% reported recurrence rates. Common side effects include erythema, irritation, ulceration and pain at application site.<sup>18,19</sup> Surgically, the vulvar HSIL lesions can be excised or ablated using a CO2 laser. Both procedures are characterized by painful post-operative recovery and high recurrence rates of up to 51%.<sup>16</sup> Studies to the efficacy of therapeutic HPV-vaccination for existing and prevention of recurrent vulvar HSIL are ongoing, with recent publications suggesting potential for patient subgroups or combinations with conventional treatment modalities.<sup>20-22</sup>

Future vulvar HSIL incidence will likely decline because of ongoing preventive HPV-vaccination strategies. Many nation-wide vaccination programmes have been rolled out over the past two decades to prevent cervical dysplasia caused by HPV.<sup>23</sup> Clear evidence for the effectiveness and justification of these programmes can now be deducted from declining incidence rates of cervical dysplasia and cancer incidence in countries that introduced vaccination in the late 2000's.<sup>24</sup> No significant effects have been observed for vulvar cancer or vulvar HSIL to date, which has been attributed to low disease incidence. Preventive actions notwithstanding, novel treatment options are still

urgently required to offset the numerous treatment side effects, high recurrence rates and remaining malignant potential of vulvar HSIL.

### **Lichen sclerosus (LS)**

Patients with LS suffer from a chronic inflammatory condition that can affect non-mucosal skin with a preference for the genital area. Genital LS reportedly has a peak incidence in postmenopausal women but can also occur in men and women of all ages, including prepubertal girls. The exact aetiology of LS remains unknown.<sup>10,25</sup> However, an association between the incidence of autoimmune disorders and LS and a positive family history has been found, suggesting a role of immunity and genetics in the aetiological pathway.<sup>26-28</sup> The classic clinical presentation of vulvar LS is a pruritic, hypopigmented 'figure of eight' area of atrophic vulvar skin, bilaterally and symmetrically reaching outward from the clitoris to encompass the labia minora, dipping inward at the perineum and reaching around the anus to form a number eight shape. The hypopigmented skin may display fissures, erosive areas, and, in advanced stages, agglutination of labia minora, concealment of the clitoris and narrowing of the vaginal introitus. vSCC can arise in affected LS tissue in small percentage patients, necessitating regular follow-up.<sup>29,30</sup> Pruritic symptoms can be alleviated by treatment with life-long, ultra-potent topical corticosteroids on the affected vulvar skin.<sup>31-33</sup> There are indications that disease progression and malignant transformation can be partially prevented by corticosteroid treatment, but prognosis is dependent on prompt and accurate diagnosis, correct treatment and patient compliance.<sup>34</sup> Substantial morbidity of physical, sexual and psychological nature persists despite available therapy.<sup>35-37</sup> This austere prospect will not change without advancement of adequate aetiological understanding and innovative LS treatment modalities with disease-specific targets.

### **Differentiated VIN**

HPV-independent vSCC and its precursor, dVIN, have been associated with mutations in tumour-suppressor oncogene TP53.<sup>38,39</sup> dVIN is frequently found with a background of LS in postmenopausal women, although dVIN lesions can also develop independently.<sup>40</sup> Recognition of dVIN lesions is challenging, often requiring a specialised clinician and pathologist to come to an accurate diagnosis. Patients with dVIN have a reported absolute risk of 33-86% to develop primary vSCC and 32-64% for recurrent vSCC. Cancer

progression usually occurs within 2 years after dVIN diagnosis.<sup>41,42</sup> This rapid and high malignant potential necessitates swift treatment with radical excision and follow-up surveillance. Recurrence risks and vSCC risk are probably dependent on residual dVIN in the resection margins.<sup>43</sup> The first line of treatment for dVIN is surgical excision, although an onerous balance remains between complete (pre)malignancy removal and needless resection of essential vulvar tissue. The management of these patients is challenging because of the difficult lesion recognition, which demonstrates the need for advanced imaging methods to differentiate healthy from diseased vulvar tissue.

### **VULVAR SQUAMOUS CELL CARCINOMA (vSCC)**

Vulvar cancer represents about 4% of all gynaecological cancers, occurring in 2.6 per 100,000 women per year with average 5-year overall survival rates of 71%.<sup>44-46</sup> The predominant histological subtype, in 85-90% of cases, is vSCC.<sup>47,48</sup> vSCC risk increases with age with a peak incidence at 70 years, in line with the age-bound incidence of dysplastic precursor lesions.<sup>44</sup> Regional metastases in the groin occur in approximately 25-30% of cases, while distant metastases are rare (5%).<sup>49</sup> Surgery is the cornerstone of treatment for vSCC. Surgical treatment for vSCC is associated with damage to essential structures such as the distant urethra, clitoris or anus with significant morbidity.<sup>4,50</sup> Despite radical surgical margins during surgery, local recurrence rates up to 40% have been reported, prompting necessity for re-excision and severely reducing survival chances.<sup>51-54</sup>

### **BENIGN HUMAN PAPILLOMA VIRUS (HPV) MEDIATED DISEASE: CONDYLOMATA ACUMINATA AND CUTANEOUS WARTS**

HPV is a double-stranded virus that can cause subclinical or latent infections sequestered away from the immune system in the epithelium of cutaneous or mucosal tissue. Over 180 HPV types have been described and classified in phylogenetic groups. The Gamma, Mu and Nu phylotypes mostly cause benign cutaneous lesions, while HPV types from the Alpha genus preferably infect mucosal tissues.<sup>55</sup> The oncogenic potential of HPV types determines their classification as either high-risk or low-risk. Whereas the high-risk variants are the notorious drivers of cervical cancer, low-risk types can cause common skin lesions such as cutaneous warts and condylomata acuminata. HPV type 6 and 11 can cause benign anogenital warty lesions in both men and

women called condylomata acuminata, more commonly known as anogenital warts (AGW). Condylomata are highly contagious, with a reported 65% of individuals whose sexual partner also develop anogenital warts. Patients may experience psychological discomfort from the cosmetically disfiguring nature of the lesions and concerns about infecting sexual partners.<sup>56</sup> Cutaneous warts, also known as verrucae, are common skin lesions a reported prevalence of 3.6–22% in schoolchildren and 0.84–13% in adults.<sup>57–61</sup> HPV type 1, 2, 7, 27 and 57 the drive cutaneous wart formation.<sup>62,63</sup> Although these lesions do not have malignant potential, patients can report physical or psychological discomfort, including pain or embarrassment.<sup>64</sup>

Untreated or unsuccessfully treated warts, both of cutaneous and anogenital nature, pose a pool of infection on an individual as well as a community level.<sup>65,66</sup> Current treatment options focus on destruction of the epithelium rather than specifically targeting the HPV-infected keratinocyte.<sup>67–70</sup> The reported efficacy rate of treatments for AGW is 45–83% with recurrence rates of 19–77%, with side effects that may include pain, burning sensation and blistering. Clearance rates of cutaneous warts is 24–40%.<sup>71,72</sup> Re-emergence of the lesions is thought to be due to failure to remove the reservoir of HPV present in surrounding (anogenital) tissue.<sup>73</sup> The drawbacks of the current wart treatments encourage the development of novel treatment modalities with higher specificity, improved efficacy and reduced side effects. Many studies to new therapies are limited by shortfalls in objective assessments to measure effect. Accurate biomarkers to quantify disease therefore need to be embedded into these clinical trials.

## **Biomarkers for comprehensive disease monitoring and therapeutic target recognition**

Biomarkers are quantifiable measurements of a biological process that can contribute to diagnosis, prognosis and therapy of diseases.<sup>74</sup> A biomarker can reflect the normal or pathological process or the pharmaceutical response to a therapeutic intervention.<sup>75</sup> A classic example of a biomarker in gynaecologic oncology is the immunohistochemical P16 staining as a surrogate marker for high-risk HPV infection in biopsy tissue of cervical lesions.<sup>76</sup> In drug development, biomarkers are increasingly being applied to predict clinical benefit or efficacy of a new compound and to substitute for a clinical endpoint in case of chronic and long-term diseases. Objective and sensitive clinical endpoints

need to be recognised and tested for validity prior to application in clinical trials. Validation of biomarkers in a structured manner is based on five pillars: repeatability, tolerability, discriminatory capacity between diseased and healthy characteristics, treatment effect and correlations to traditional endpoints.<sup>77</sup> By incorporating precise and accurate biomarkers in early-phase clinical studies, compounds with limited efficacy can be abandoned in favour of more promising ones, saving precious economical resources and reducing the amount of patients exposed to ineffective treatments.<sup>78,79</sup> Additionally, with the growing understanding of the complexity of diseases, biomarkers will play an increasing role in personalised therapy choices. Especially in vulvar diseases such as vSCL, vulvar HSIL, dVIN and LS, there is a lack of accurate, precise and non-invasive biomarkers to guide diagnostics, clinical follow-up and treatment effects.

Recognition of novel biomarkers can be approached in a structured manner encompassing multiple domains (*Figure 3*).<sup>80</sup> A multitude of domains ranging from histological findings to patient reported outcomes may generate potential candidates to be used as biomarkers in future applications. Incorporating new, tailored biomarkers in clinical trials in turn depends on the pharmacokinetic and pharmacodynamic considerations of potential drug candidates. Clinician-based scoring of vulvar disease can be complemented by symptom reporting by patients and e.g. by wearables measuring scratching as a surrogate biomarker for pruritus.<sup>81</sup> In addition, non-invasive techniques such as biophysical assessments (e.g. pH, trans-epidermal water loss) can be applied to acquire an insight on the biological process at the surface of the vulvar skin. Imaging techniques have advanced significantly over the past decades with increasing resolution and quantifiable measurements in different skin layers. Histology and immunohistochemistry can provide insight in mechanistic processes on a cellular level, which can be complemented by molecular sequencing techniques to uncover genomic properties and gene expression profiles. When considering application of topical medication, pharmacokinetic properties of the compound through the skin to the intended target is of utmost importance, as the skin's primary function is to provide a barrier to external factors. Finally, there is increasing evidence that the microbiome composition plays an essential role in health and disease, and its interaction should be further understood. All these domains together can provide a holistic, phenotypic reflection of a disease entity that can be applied to improve disease recognition and

understanding and to guide therapeutic target development. This thesis will extensively focus on two domains from this comprehensive approach:

- 1 non-invasive **imaging** for disease recognition and follow-up
- 2 the vulvar **microbiome** composition.

These primary categories of interest are accompanied by components from the other areas highlighted in the flower-shaped model.

### ADVANCED IMAGING TECHNIQUES FOR DISEASE RECOGNITION AND FOLLOW-UP

The dermatology practice routinely applies imaging in for improved visualisation of cutaneous lesions and as a follow-up reference.<sup>82</sup> Imaging techniques have advanced significantly over the past decades, with increased resolution, improved follow-up possibilities and expanded quantifiable measurements in various skin layers.<sup>83</sup> These developments reduce the need for relatively subjective clinical scoring systems. Consecutive, non-invasive measurements can be obtained whilst providing objective data over time, as opposed to limitations posed for invasive methods such as biopsies. Clinical imaging of vulvar diseases in the daily gynaecological practice is currently performed as photo-documentation for follow-up, generally using a conventional photo camera system, despite the challenges in the recognition of vulvar disease such as vulvar HSIL and dVIN. In this thesis, several potential imaging systems are applied in a clinical trial setting to assess their potential application for the vulvar clinic. These include dermatoscopy, optical coherence tomography (OCT) and reflectance confocal microscopy (RCM) and stereophotogrammetric three-dimensional (3D) photography (*Figure 4*).

Dermatoscopy has been integrative part of the dermatology practice for many years. The diagnostic accuracy of the clinical evaluation potentially malignant lesions transformation has greatly improved since the widespread utilization of dermatoscopy systems.<sup>84-86</sup> These dermatoscopy systems can range from simple, hand-held magnification glasses to vast, high-resolution cameras linked to analysis programmes including lesion location options and follow-up functionalities. Dynamic OCT (D-OCT) is most renowned for being the clinical standard in the ophthalmology clinic for the diagnostics of retinal diseases through visualization and quantification of the retinal microcirculation.<sup>87,88</sup> D-OCT uses light reflectance to generate a real-time black and white image perpendicular showing the imaged skin and its components up to a depth up to 2.0 mm. The analysis of these visualised skin layers can be used to determine epidermal thickness, cutaneous blood flow and skin roughness.

This technique has been applied in dermatology research for the assessment of skin thickness and cutaneous microcirculation, but more sparingly on the vulvar area.<sup>89-94</sup> RCM applies a low powered laser (830 nm) to generate a non-invasive and real-time visualization of the skin (up to a depth of 150 µm) with cellular resolution.<sup>95</sup> The technique has proven useful as adjunct tool for the recognition and diagnosis of malignancies of the skin and may reduce the need for biopsies.<sup>96,97</sup> Finally, stereophotogrammetric 3D photography is a hand-held camera system that is already utilized in the field of plastic surgery in order to add objective measuring techniques to the clinical practice.<sup>98,99</sup> Stereophotogrammetry obtains two or more images from different angles which can subsequently be reconstructed into a 3D image. The technique has previously been used in the assessment of scars, but not for the study of vulvar diseases.<sup>100,101</sup>

### THE MICROBIOME AND ITS ROLE IN GYNAECOLOGICAL HEALTH AND DISEASE

The microbiome, the aggregate of bacteria, viruses and fungi in a niche, plays a key role in human health.<sup>102</sup> Alterations in the microbiome composition have been associated with several conditions, including inflammatory disease, skin conditions and cancer.<sup>103,104</sup> Dysbiosis of the whole microbiome composition in an anatomical niche is believed to drive DNA damage, inflammatory responses and aberrant signalling pathways summing to tumorigenesis and cancer progression.<sup>105</sup> Therefore, the maintenance of an optimal microbiota composition could prove crucial in cancer prevention.

Large-scale studies to the cervical and vaginal bacteriome composition have described relationships between microbiome changes and pre-term birth, bacterial vaginosis and cervical dysplasia. Of these, the vaginal microbiome has most extensively been studied (*Figure 5*). The vaginal bacteriome of healthy women is characterized by inter-individual heterogeneity and temporal variability, which can partially attributed to demographic characteristics and lifestyle.<sup>106,107</sup> *Lactobacillus* is a genus of Gram-positive anaerobic bacteria that are often identified in the female genital tract, which preserve an acidic vaginal milieu. Patterns of the vaginal microbiome composition have been clustered into numbered community state types (CST).<sup>108,109</sup> The vaginal CST I is dominated by *L. crispatus*, CST II by *L. gasseri*, CST III by *L. iners* and CST V by *L. jensenii*. The non-*Lactobacillus*-dominated CST IV constitutes a diverse pattern with strictly anaerobic bacteria, such as *Atopobium vaginiae*, *Gardnerella vaginalis* and *Megasphaera elsdenii*.<sup>109</sup> These bacteria have

also been associated with bacterial vaginosis.<sup>110,111</sup> The complete microbiome encompasses more than just the bacteriome, although most of the research has focused on this dominant component. Current knowledge on the mycobio-  
biome, the fungal fraction, is primarily derived from culture-based studies. In gynaecology, candidiasis is a well-known opportunistic fungal infection of the vaginal tract that can cause pruritic symptoms and purulent discharge. The causative fungus, *C. albicans*, colonises up to 20% of women asymptotically, rendering it a commensal with pathogenic properties.<sup>112</sup> The viral fraction of the vaginal microbiome composition is even less extensively studied, except for the role of HPV on dysplasia and cancer.

Gynaecological oncology covers malignancies of all female reproductive organs, including the cervix, vagina, uterus, ovaries, fallopian tubes and vulva. The cervicovaginal microbiome in relation to cancer has been studied extensively.<sup>113</sup> A high-diversity cervicovaginal microbiome composition and disappearance of *Lactobacillus* dominance associates with advancing stages of HPV-driven cervical dysplasia.<sup>114-116</sup> In addition, increased prevalence of vaginal *Snaethia* spp. has been described in patients with hrHPV infections, cervical intraepithelial neoplasia and invasive cervical carcinoma.<sup>117-120</sup> These findings endorse a potential causal link between vaginal dysbiosis and cervical cancer, influencing cancer development in all phases from acquisition and persistence of HPV to formation and progression of cervical dysplasia.<sup>116</sup> Vaginal dysbiosis may also drive ovarian or endometrial cancer through immunogenic disruption.<sup>121</sup> In endometrial cancer, presence of *Atopobium vaginae* and *Porphyromonas* species and significantly elevated levels of *Proteobacteria* and *Firmicutes* phylum bacteria have been reported. *Chlamydia trachomatis*, *Lactobacillus* and *Mycobacterium* have been suggested to potentially influence ovarian cancer development.<sup>122</sup>

Although patterns of microbiome disruptions have been studied for other gynaecological cancers, no studies have been conducted that investigate the vulvar microbiome in relation to vulvar cancer or its precursors. Apart from a handful of culture-based studies conducted in the previous century, there seems little interest into understanding the healthy vulvar microbiome composition.<sup>123-125</sup> Insights in the healthy microbiome composition is the basis to correlate alterations to disease states. Our knowledge of the intestinal and vaginal microbiome indicates a pivotal role of the microbiome in the pathway to malignancy. The lack of interest in translation of this expertise from other anatomical locations to the vulvar research field is remarkable, especially

considering the prominent role of a microorganism, HPV, in the development of vulvar HSIL and VSCC. Additionally, we have no clear understanding of LS aetiology, nor conclusive evidence explaining disease progression to dysplasia and VSCC. In conclusion, the vulvar microbiome composition is an untapped field of research with myriad possibilities to expand vulvar disease understanding. Awareness of the role of the microbiome of the vulva may unlock opportunities to improve disease recognition and development of therapeutic options.

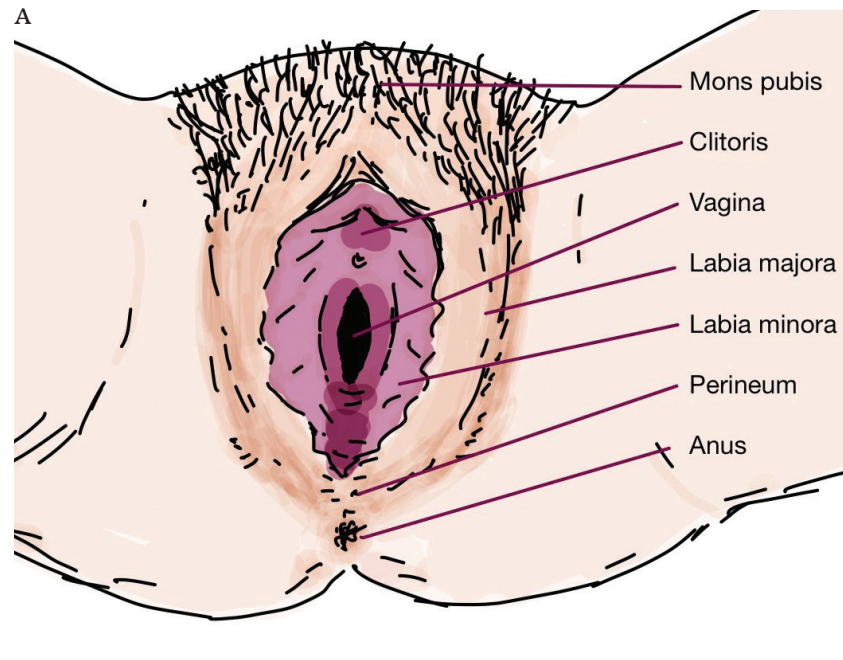
## Aims and outline of this thesis

The aim of this thesis was to study novel tools and biomarkers for improved detection of vulvar premalignant disease and aid the investigation of potential new drug targets for the indication of vulvar and HPV-driven diseases.

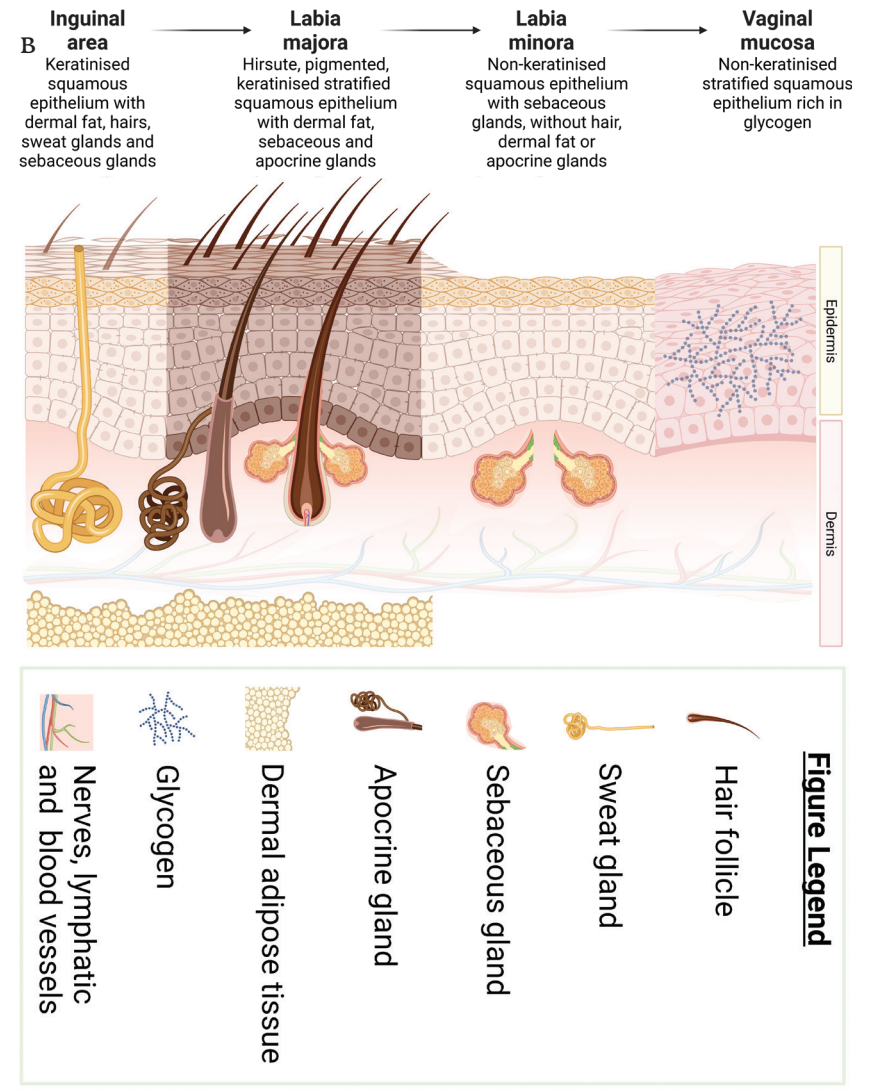
*Section I* of this thesis focuses on the recognition and validation of imaging-based biomarkers for HPV-driven diseases of the skin and external genitalia. In *chapter 2*, stereophotogrammetric photography was studied for the use in cutaneous warts, vulvar HSIL and AGW as reliable photo-documentation and lesion size calculation. *Chapter 3* presents a pilot study for the application of dermatoscopy and optical coherence tomography (OCT) for the visualisation and characterisation of vulvar HSIL and LS. In *chapter 4*, reflectance confocal microscopy (RCM), which allows for detailed dermal imaging at cellular resolution, was applied in the same patient population. In *chapter 5*, a first-in-its-class small molecule was tested in a Phase I trial for safety and exploratory efficacy for the treatment of cutaneous warts, using stereophotogrammetric 3D photography and OCT as exploratory biomarkers.

*Section II* investigates sequencing-based biomarkers for vulvar disease, facilitating insight into the aetiology of vulvar diseases and identifying potential new therapeutic targets. The currently available literature on the vulvar microbiome composition was investigated in *chapter 6*. The findings from this review of literature are further expanded in an observational study characterising the vulvar microbiome composition of healthy volunteers, vulvar HSIL patients and LS patients, which is described in *chapter 7*. Lastly, *chapter 8* summarises the findings of this thesis with a call to the research field to improve the biomarkers for vulvar HSIL and LS. In addition, a perspective on recent developments in the field of premalignant vulvar disease is provided, with recommendations for future applications of the biomarkers studied in this thesis.

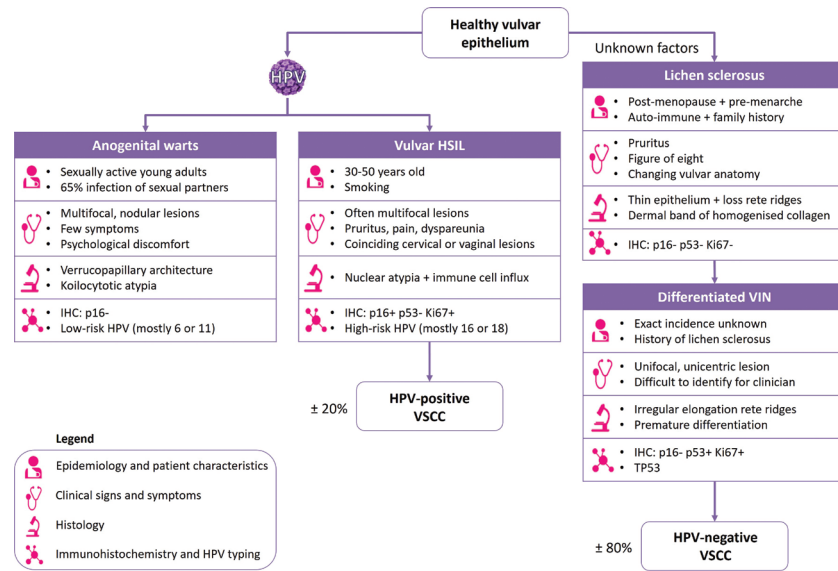
**Figure 1 Schematic overview of vulvar anatomy.** A) overall anatomy and B) histological features, signifying the transitional skin types from the inguinal area, the labia majora, labia minora to the vaginal mucosa. Figures made using Apple GoodNotes 5 and Biorender.



(continuation Figure 1)

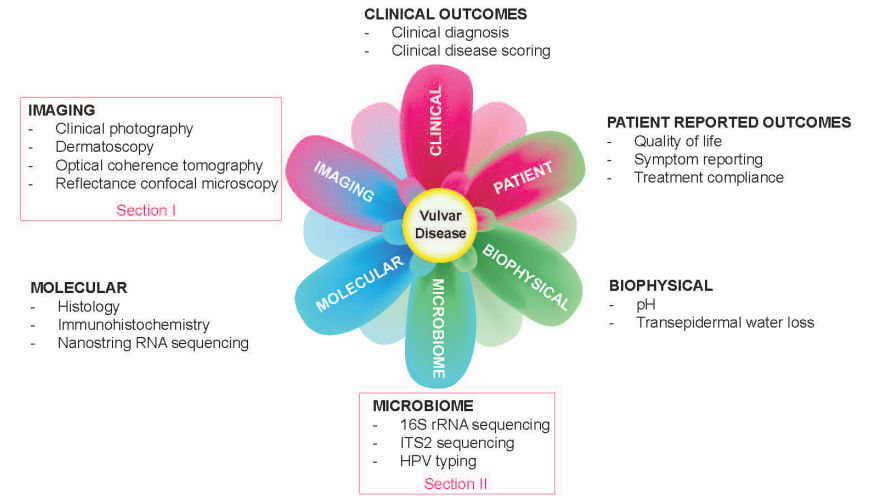


**Figure 2** Human papillomavirus (HPV)-independent and HPV-dependent pathways leading to distinct subtypes of vulvar lesions and vulvar squamous cell carcinoma (VSCC).



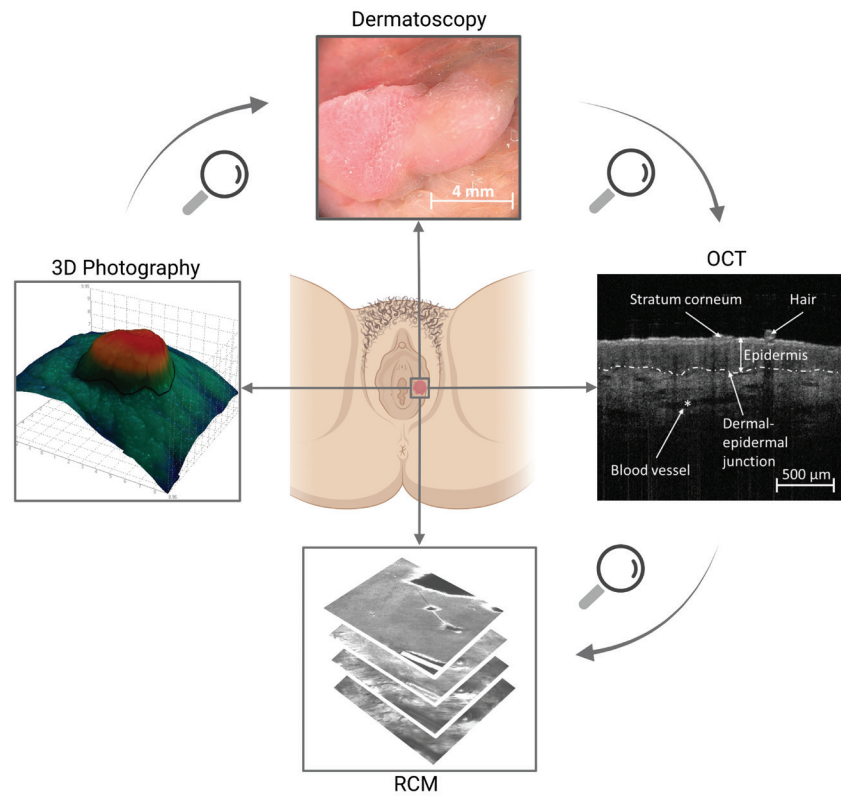
HSIL = high-grade squamous intraepithelial lesions, VIN = vulvar intraepithelial neoplasia, IHC = immunohistochemistry, HPV = Human-papillomavirus, TP53 = Tumour protein P53.

**Figure 3** Multi-modal approach to characterising (vulvar) diseases.



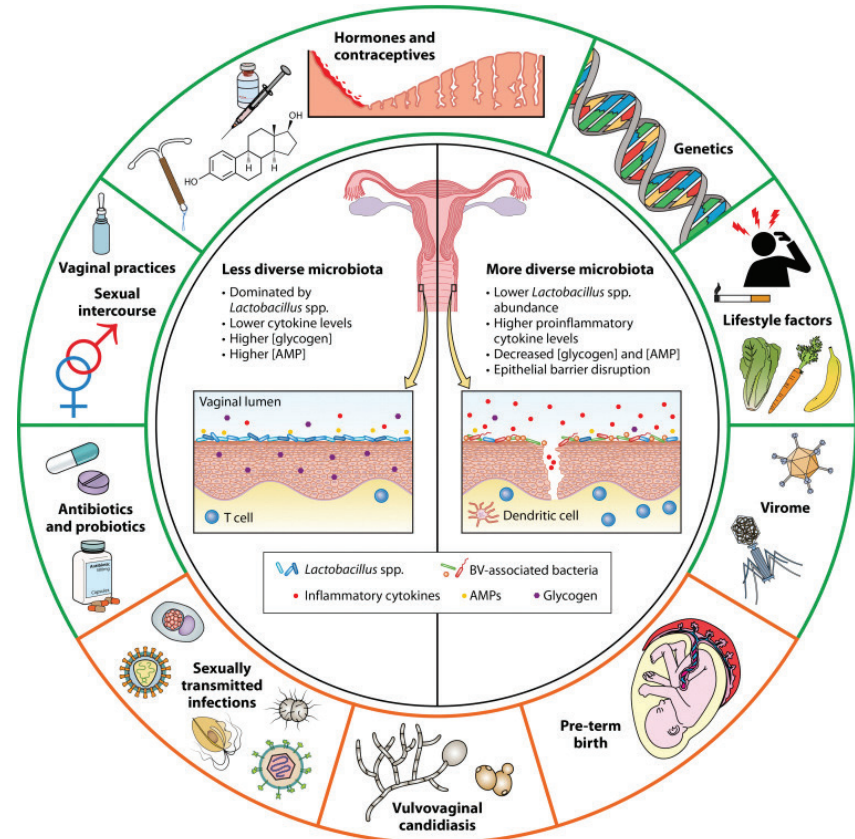
RNA = Ribonucleic acid, ITS2 = Internal transcribed spacer region, 2 HPV = Human-papillomavirus

**Figure 4 Imaging techniques.** Examples of novel imaging techniques applied in this thesis, showing in clockwise fashion in ascending order of magnification and resolution – stereophotogrammetric three-dimensional (3D) photography, dermatoscopy, optical coherence tomography (OCT) and reflectance confocal microscopy (RCM). Figure made using BioRender.



**Figure 5 The vaginal microbiome composition and correlations to disease.**

External and internal factors that have been shown to influence the vaginal microbiome composition and its consequences on a functional and clinical level. Reproduced with permission from Dabee *et al*, 2021.<sup>113</sup>



REFERENCES

1 Nguyen J, Duong H. Anatomy, Abdomen and Pelvis, Female External Genitalia. *StatPearls*. Published online October 16, 2019. Accessed January 28, 2022. <http://europepmc.org/books/NBK547703>

2 Day T, Holland SM, Scurry J. Normal Vulvar Histology: Variation by Site. *J Low Genit Tract Dis*. 2016;20(1):64-69. doi:10.1097/LGT.0000000000000162

3 Mullen MM, Merfeld EC, Palisoul ML, et al. Wound Complication Rates After Vulvar Excisions for Premalignant Lesions. *Obstet Gynecol*. 2019;133(4):658-665. doi:10.1097/AOG.0000000000003185

4 Grimm D, Eulenburg C, Brummer O, et al. Sexual activity and function after surgical treatment in patients with (pre)invasive vulvar lesions. *Support Care Cancer*. 2016;24(1):419-428. doi:10.1007/s00520-015-2812-8

5 Bell SG, Kobernik EK, Haefner HK, Welch KC. Association Between Vulvar Squamous Intraepithelial Lesions and Psychiatric Illness. *J Low Genit Tract Dis*. 2021;25(1):53-56. doi:10.1097/LGT.0000000000000580

6 Lockhart J, Gray N, Cruickshank M. The development and evaluation of a questionnaire to assess the impact of vulval intraepithelial neoplasia: a questionnaire study. *BJOG-An Int J Obstet Gynaecol*. 2013;120(9):1133-1143. doi:10.1111/1471-0528.12229

7 Ansink A. Vulvar squamous cell carcinoma. *Semin Dermatol*. 1996;15(1):51-59. doi:10.1016/s1085-5629(96)80019-8

8 de Sanjosé S, Alemany L, Ordi J, et al. Worldwide human papillomavirus genotype attribution in over 2000 cases of intraepithelial and invasive lesions of the vulva. *Eur J Cancer*. 2013;49(16):3450-3461. doi:https://doi.org/10.1016/j.ejca.2013.06.033

9 Bornstein J, Bogliatto F, Haefner HK, et al. The 2015 International Society for the Study of Vulvovaginal Disease (ISSVD) Terminology of Vulvar Squamous Intraepithelial Lesions. *J Low Genit Tract Dis*. 2016;20(1):11-14. doi:10.1097/LGT.0000000000000169

10 Thuijs NB, van Beurden M, Bruggink AH, Steenbergen RDMM, Berkhof J, Bleeker MCGG. Vulvar intraepithelial neoplasia: Incidence and long-term risk of vulvar squamous cell carcinoma. *Int J cancer*. 2021;148(1):90-98. doi:10.1002/ijc.33198

11 Khan AM, Freeman-Wang T, Pisal N, Singer A. Smoking and multicentric vulvar intraepithelial neoplasia. *J Obstet Gynaecol*. 2009;29(2):123-125. doi:10.1080/01443610802668938

12 Satmary W, Holschneider CH, Brunette LL, Natarajan S. Vulvar intraepithelial neoplasia: Risk factors for recurrence. *Gynecol Oncol*. 2018;148(1):126-131. doi:10.1016/j.ygyno.2017.10.029

13 van Esch EM, Dam MC, Osse ME, et al. Clinical Characteristics Associated With Development of Recurrence and Progression in Usual-Type Vulvar Intraepithelial Neoplasia. *Int J Gynecol Cancer*. 2013;23(8). doi:10.1097/IGC.0b013e3182a57fd6

14 van Seters M, van Beurden M, de Craen AJM. Is the assumed natural history of vulvar intraepithelial neoplasia III based on enough evidence? A systematic review of 3322 published patients. *Gynecol Oncol*. 2005;97(2):645-651. doi:10.1016/j.ygyno.2005.02.012

15 Jones RW, Rowan DM, Stewart AW. Vulvar intraepithelial neoplasia: aspects of the natural history and outcome in 405 women. *Obstet Gynecol*. 2005;106(6):1319-1326. doi:10.1097/01.AOG.0000187301.76283.7f

16 Lawrie TA, Nordin A, Chakraborti M, Bryant A, Kaushik S, Pepas L. Medical and surgical interventions for the treatment of usual-type vulvar intraepithelial neoplasia. *Cochrane database Syst Rev*. 2016;2016(1). doi:10.1002/14651858.CD011837.PUB2

17 Pepas L, Kaushik S, Bryant A, Nordin A, Dickinson HO. Medical interventions for high grade vulvar intraepithelial neoplasia. *Cochrane database Syst Rev*. 2011;2011(4):CD007924. doi:10.1002/14651858.CD007924.PUB2

18 Mahto M, Nathan M, O'Mahony C. More than a decade on: review of the use of imiquimod in lower anogenital intraepithelial neoplasia. *Int J STD AIDS*. 2010;21(1):8-16. doi:10.1258/ijsa.2009.009309

19 van Seters M, van Beurden M, ten Kate FJW, et al. Treatment of vulvar intraepithelial neoplasia with topical imiquimod. *N Engl J Med*. 2008;358(14):1465-1473. doi:10.1056/NEJMoa072685

20 Ghelardi A, Marrai R, Bogani G, et al. Surgical Treatment of Vulvar HSIL: Adjuvant HPV Vaccine Reduces Recurrent Disease. *Vaccines*. 2021;9(2):1-12. doi:10.3390/VACCINES9020083

21 Abdulrahman Z, De Miranda N, Van Esch EMG, et al. Pre-existing inflammatory immune microenvironment predicts the clinical response of vulvar high-grade squamous intraepithelial lesions to therapeutic HPV16 vaccination. 2020;8(1):e000563. doi:10.1136/JITC-2020-000563

22 Stankiewicz Karita HC, Hauge K, Magaret A, et al. Effect of Human Papillomavirus Vaccine to Interrupt Recurrence of Vulvar and Anal Neoplasia (VIVA): A Trial Protocol. *JAMA Netw open*. 2019;2(4):e190819. doi:10.1001/jamanetworkopen.2019.0819

23 Dorji T, Nopsopon T, Tamang ST, Pongpirul K. Human papillomavirus vaccination uptake in low-and middle-income countries: a meta-analysis. *EclinicalMedicine*. 2021;34:100836. doi:10.1016/j.eclinm.2021.100836/ATTACHMENT/83D3842F-04E6-48DB-A60C-0C0385AE78FE/MMC2.PDF

24 Wang W, Kothari S, Baay M, et al. Real-world impact and effectiveness assessment of the quadrivalent HPV vaccine: a systematic review of study designs and data sources. *Expert Rev Vaccines*. Published online December 13, 2021;1-14. doi:10.1080/14760584.2022.2008243/SUPPL\_FILE/IERV\_A\_2008243\_SM359.ZIP

25 Van De Nieuwenhof HP, Van Kempen LCLT, De Hullu JA, et al. The etiologic role of HPV in vulvar squamous cell carcinoma fine tuned. *Cancer Epidemiol Biomarkers Prev*. 2009;18(7):2061-2067. doi:10.1158/1055-9965.EPI-09-0209

26 Powell J, Wojnarowska F, Winsey S, Marren P, Welsh K. Lichen sclerosus premenarche: Autoimmunity and immunogenetics. *Br J Dermatol*. 2000;142(3):481-484. doi:10.1046/j.1365-2133.2000.03360.x

27 Tran DA, Tan X, Macri CJ, Goldstein AT, Fu SW. Lichen sclerosus: An autoimmunopathogenic and genomic enigma with emerging genetic and immune targets. *Int J Biol Sci*. 2019;15(7):1429-1439. doi:10.7150/ijbs.34613

28 Harrington CI, Dunsmore IR. An investigation into the incidence of auto-immune disorders in patients with lichen sclerosus and atrophicus. *Br J Dermatol*. 1981;104(5):563-566. doi:10.1111/j.1365-2133.1981.tb08172.x

29 Carlson JA, Ambros R, Malfetano J, et al. Vulvar lichen sclerosus and squamous cell carcinoma: a cohort, case control, and investigational study with historical perspective; implications for chronic inflammation and sclerosis in the development of neoplasia. *Hum Pathol*. 1998;29(9):932-948. doi:10.1016/s0046-8177(98)90198-8

30 Bleeker MCG, Visser PJ, Overbeek LIH, van Beurden M, Berkhof J. Lichen Sclerosus: Incidence and Risk of Vulvar Squamous Cell Carcinoma. *Cancer Epidemiol Biomarkers*

31 Goldstein AT, Creasey A, Pfau R, Phillips D, Burrows LJ. A double-blind, randomized controlled trial of clobetasol versus pimecrolimus in patients with vulvar lichen sclerosus. *J Am Acad Dermatol*. 2011;64(6):e99-104. doi:10.1016/j.jaad.2010.06.011

32 Krampf JM, Mitchell L, Holton MA, Goldstein AT. Vulvar lichen sclerosus: Current perspectives. *Int J Womens Health*. 2020;12:11-20. doi:10.2147/IJWH.S191200

33 Cooper SM, Gao XH, Powell JJ, Wojnarowska F. Does treatment of vulvar lichen sclerosus influence its prognosis? *Arch Dermatol*. 2004;140(6):702-706. doi:10.1001/archderm.140.6.702

34 Lee A, Bradford J, Fischer G. Long-term Management of Adult Vulvar Lichen Sclerosus: A Prospective Cohort Study of 507 Women. *JAMA dermatology*. 2015;151(10):1061-1067. doi:10.1001/jamadermatol.2015.0643

35 Pérez-López FR, Vieira-Baptista P. Lichen sclerosus in women: a review. *Climacteric*. 2017;20(4):339-347. doi:10.1080/13697137.2017.1343295

36 Ranum A, Pearson DR. The impact of genital lichen sclerosus and lichen planus on quality of life: A review. *Int J women's dermatology*. 2022;8(3):e042. doi:10.1097/JW9.0000000000000042

37 Sivalingam Id V, Tamber Id K. Understanding the impact of life with vulvar lichen sclerosus. *Br J Dermatol*. Published online September 2, 2022. doi:10.1111/BJD.21846

38 Hoang LN, Park KJ, Soslow RA, Murali R. Squamous precursor lesions of the vulva: current classification and diagnostic challenges. *Pathology*. 2016;48(4):291-302. doi:10.1016/j.pathol.2016.02.015

39 Pinto AP, Miron A, Yassin Y, et al. Differentiated vulvar intraepithelial neoplasia contains Tps3 mutations and is genetically linked to vulvar squamous cell carcinoma. *Mod Pathol an Off J United States Can Acad Pathol Inc*. 2010;23(3):404-412. doi:10.1038/modpathol.2009.179

40 Hart WR. Vulvar intraepithelial neoplasia: historical aspects and current status. *Int J Gynecol Pathol*. 2001;20(1):16-30. doi:10.1097/00004347-200101000-00003

41 Voss FO, Thuijs NB, Vermeulen RFM, Wilthagen EA, van Beurden M, Bleeker MCG. The vulvar cancer risk in differentiated vulvar intraepithelial neoplasia: A systematic review. *Cancers (Basel)*. 2021;13(24). doi:10.3390/CANCERS13246170/S1

42 McAlpine JN, Kim SY, Akbari A, et al. HPV-independent Differentiated Vulvar Intraepithelial Neoplasia (dVIN) is Associated With an Aggressive Clinical Course. *Int J Gynecol Pathol Off J Int Soc Gynecol Pathol*. 2017;36(6):507-516. doi:10.1097/PGP.0000000000000375

43 Te Grootenhuus NC, Pouwer AW, de Bock GH, et al. Margin status revisited in vulvar squamous cell carcinoma. *Gynecol Oncol*. 2019;154(2):266-275. doi:10.1016/j.ygyno.2019.05.010

44 Hacker NF, Eiffel PJ, van der Velden J. Cancer of the vulva. *Int J Gynecol Obstet*. 2012;119:S90-S96. doi:https://doi.org/10.1016/S0020-7292(12)60021-6

45 Olawaye AB, Cuello MA, Rogers LJ. Cancer of the vulva: 2021 update. *Int J Gynecol Obstet*. 2021;155(S1):7-18. doi:10.1002/IJGO.13881

46 Vulvar Cancer — Cancer Stat Facts. Accessed January 31, 2022. <https://seer.cancer.gov/staffacts/html/vulva.html>

47 Nguyen AH, Tahseen AI, Vaudreuil AM, Caponetti GC, Huertter CJ. Clinical features and treatment of vulvar

Merkel cell carcinoma: a systematic review. *Gynecol Oncol Res Pract*. 2017;4(1):2. doi:10.1186/s40661-017-0037-x

48 Sznurkowski JJ. Vulvar cancer: initial management and systematic review of literature on currently applied treatment approaches. *Eur J Cancer Care (Engl)*. 2016;25(4):638-646. doi:https://doi.org/10.1111/ecc.12455

49 Prieske K, Haeringer N, Grimm D, et al. Patterns of distant metastases in vulvar cancer. *Gynecol Oncol*. 2016;142(3):427-434. doi:https://doi.org/10.1016/j.ygyno.2016.07.009

50 Aerts L, Enzlin P, Vergote I, Verhaeghe J, Poppe W, Amant F. Sexual, psychological, and relational functioning in women after surgical treatment for vulvar malignancy: a literature review. *J Sex Med*. 2012;9(2):361-371. doi:10.1111/J.1743-6109.2011.02520.X

51 Te Grootenhuus NC, Van Der Zee AGJ, Van Doorn HC, et al. Sentinel nodes in vulvar cancer: Long-term follow-up of the GROningen International Study on Sentinel nodes in Vulvar cancer (GROINSS-V) i. *Gynecol Oncol*. 2016;140(1):8-14. doi:10.1016/j.ygyno.2015.09.077

52 Te Grootenhuus NC, Pouwer AFW, de Bock GH, et al. Prognostic factors for local recurrence of squamous cell carcinoma of the vulva: A systematic review. *Gynecol Oncol*. 2018;148(3):622-631. doi:10.1016/j.ygyno.2017.11.006

53 Yap JKW, O'Neill D, Nagenthiran S, Dawson CW, Luesley DM. Current insights into the aetiology, pathobiology, and management of local disease recurrence in squamous cell carcinoma of the vulva. *BJOG*. 2017;124(6):946-954. doi:10.1111/1471-0528.14560

54 Nooij LS, Brand FAMM, Gaarenstroom KN, Creutzberg CL, de Hullu JA, van Poelgeest MIEE. Risk factors and treatment for recurrent vulvar squamous cell carcinoma. *Crit Rev Oncol Hematol*. 2016;106:1-13. doi:10.1016/j.critrevonc.2016.07.007

55 De Villiers EM, Fauquet C, Broker TR, Bernard HU, Zur Hausen H. Classification of papillomaviruses. *Virology*. 2004;324(1):17-27. doi:10.1016/j.virol.2004.03.033

56 Maw RD, Reitano M, Roy M, et al. An international survey of patients with genital warts: perceptions regarding treatment and impact on lifestyle. *Int J STD AIDS*. 1998;9(10):571-578. doi:10.1258/0956462981921143

57 Williams HC, Pottier A, Strachan D. The descriptive epidemiology of warts in British schoolchildren. *Br J Dermatol*. 1993;128(5):504-511. doi:10.1111/j.1365-2133.1993.tb00226.x

58 van Haalen FM, Bruggink SC, Gussekloo J, Assendelft WJJ, Eekhof JAH. Warts in primary schoolchildren: prevalence and relation with environmental factors. *Br J Dermatol*. 2009;161(1):148-152. doi:10.1111/j.1365-2133.2009.09160.x

59 Kilkenny M, Merlin K, Young R, Marks R. The prevalence of common skin conditions in Australian school students: 1. Common, plane and plantar viral warts. *Br J Dermatol*. 1998;138(5):840-845. doi:10.1046/j.1365-2133.1998.02222.x

60 Johnson MT, Roberts J. Skin conditions and related need for medical care among persons 1-74 years. United States, 1971-1974. *Vital Health Stat 11*. 1978;(212):i-v, 1-72.

61 Beliaeva TL. [The population incidence of warts]. *Vestn Dermatol Venerol*. 1990;(2):55-58.

62 Bruggink SC, de Koning MNC, Gussekloo J, et al. Cutaneous wart-associated HPV types: prevalence and relation with patient characteristics. *J Clin Virol Off Publ Pan Am Soc Clin Virol*. 2012;55(3):250-255. doi:10.1016/j.jcv.2012.07.014

63 Hagiwara K, Uezato H, Arakaki H, et al. A genotype distribution of human papillomaviruses detected by

- polymerase chain reaction and direct sequencing analysis in a large sample of common warts in Japan. *J Med Virol*. 2005;77(1):107-112. doi:10.1002/jmv.20421
- 64 Ciconte A, Campbell J, Tabrizi S, Garland S, Marks R. Warts are not merely blemishes on the skin: A study on the morbidity associated with having viral cutaneous warts. *Australas J Dermatol*. 2003;44(3):169-173. doi:10.1046/j.1440-0960.2003.00672.x
- 65 Bruggink SC, Eekhof JAH, Egberts PF, van Blijswijk SCE, Assendelft WJJ, Gusssekloo J. Warts transmitted in families and schools: a prospective cohort. *Pediatrics*. 2013;131(5):928-934. doi:10.1542/peds.2012-2946
- 66 Massing AM, Epstein WL. Natural history of warts. A two-year study. *Arch Dermatol*. 1963;87:306-310. doi:10.1001/archderm.1963.01590150022004
- 67 Bruggink SC, Waagmeester SC, Gusssekloo J, Assendelft WJJ, Eekhof JAH. Current choices in the treatment of cutaneous warts: a survey among Dutch GP. *Fam Pract*. 2010;27(5):549-553. doi:10.1093/fampra/cmq047
- 68 Pezeshkpoor F, Banihashemi M, Yazdanpanah MJ, Yousefzadeh H, Sharghi M, Hoseinzadeh H. Comparative study of topical 80% trichloroacetic acid with 35% trichloroacetic acid in the treatment of the common wart. *J Drugs Dermatol*. 2012;11(11):e66-9.
- 69 Kwok CS, Gibbs S, Bennett C, Holland R, Abbott R. Topical treatments for cutaneous warts. *Cochrane database Syst Rev*. 2012;(9):CD001781. doi:10.1002/14651858.CD001781.pub3
- 70 Coleman N, Birley HDL, Renton AM, et al. Immunological events in regressing genital warts. *Am J Clin Pathol*. 1994;102(6):768-774. doi:10.1093/AJCP/102.6.768
- 71 Bourke JF, Berth-Jones J, Hutchinson PE. Cryotherapy of common viral warts at intervals of 1, 2 and 3 weeks. *Br J Dermatol*. 1995;132(3):433-436. doi:10.1111/j.1365-2133.1995.tb08678.x
- 72 Finley C, Korowynk C, Kolber MR. What works best for nongenital warts? *Can Fam Physician*. 2016;62(12):997.
- 73 Stanley MA. Genital human papillomavirus infections: current and prospective therapies. *J Gen Virol*. 2012;93(Pt 4):681-691. doi:10.1099/vir.0.039677-0
- 74 Cohen AF, Burggraaf J, Van Gerven JMA, Moerland M, Groeneveld GJ. The use of biomarkers in human pharmacology (Phase I) studies. *Annu Rev Pharmacol Toxicol*. 2015;55:55-74. doi:10.1146/ANNUREV-PHARMTOX-011613-135918
- 75 Atkinson AJ, Colburn WA, DeGruttola VG, et al. Biomarkers and surrogate endpoints: Preferred definitions and conceptual framework. *Clin Pharmacol Ther*. 2001;69(3):89-95. doi:10.1067/mcp.2001.113989
- 76 Hovenaars BM, Van Der Avoort IAM, De Wilde PCM, et al. A panel of p16INK4A, MIB1 and p53 proteins can distinguish between the 2 pathways leading to vulvar squamous cell carcinoma. *Int J Cancer*. 2008;123(12):2767-2773. doi:10.1002/ijc.23857
- 77 Kruizinga MD, Stuurman FE, Exadaktylos V, et al. Development of Novel, Value-Based, Digital Endpoints for Clinical Trials: A Structured Approach Toward Fit-for-Purpose Validation. *Pharmacol Rev*. 2020;72(4):899-909. doi:10.1124/PR.120.000028
- 78 Rijdsbergen M. Early phase clinical drug development for HPV-induced disorders: novel tools and treatments | Scholarly Publications. Published online 2020. Accessed May 16, 2022. [https://scholarlypublications.universiteitleiden.nl/handle/1887/854448?solr\\_nav%5Bid%5D=9d950c5a19db59e53bb3&so\\_lr\\_nav%5Bpage%5D=0&solr\\_nav%5Boffset%5D=0](https://scholarlypublications.universiteitleiden.nl/handle/1887/854448?solr_nav%5Bid%5D=9d950c5a19db59e53bb3&so_lr_nav%5Bpage%5D=0&solr_nav%5Boffset%5D=0)
- 79 de Visser SJ. A question based approach to drug development [PhD thesis]. *Leiden Univ*. Published online 2003. Accessed May 16, 2022. [https://scholarlypublications.universiteitleiden.nl/handle/1887/28222?solr\\_nav%5Bid%5D=32fe002df2a89e252d0e&so\\_lr\\_nav%5Bpage%5D=0&solr\\_nav%5Boffset%5D=4](https://scholarlypublications.universiteitleiden.nl/handle/1887/28222?solr_nav%5Bid%5D=32fe002df2a89e252d0e&so_lr_nav%5Bpage%5D=0&solr_nav%5Boffset%5D=4)
- 80 Rissmann R, Moerland M, van Doorn MBA. Blueprint for mechanistic, data-rich early phase clinical pharmacology studies in dermatology. *Br J Clin Pharmacol*. Published online 2020. doi:10.1111/bcp.14293
- 81 Kruizenga M. Trial@home for children | Scholarly Publications. Published online 2022. Accessed May 16, 2022. [https://scholarlypublications.universiteitleiden.nl/handle/1887/3274248?solr\\_nav%5Bid%5D=47b9222fb9449647f091b&so\\_lr\\_nav%5Bpage%5D=0&solr\\_nav%5Boffset%5D=0](https://scholarlypublications.universiteitleiden.nl/handle/1887/3274248?solr_nav%5Bid%5D=47b9222fb9449647f091b&so_lr_nav%5Bpage%5D=0&solr_nav%5Boffset%5D=0)
- 82 Kaliyadan F, Manoj J, Venkitakrishnan S, Dharmaratnam AD. Basic digital photography in dermatology. *Indian J Dermatol Venereol Leprol*. 2008;74(5):532-536. doi:10.4103/0378-6323.44334
- 83 Hibler BP, Qi Q, Rossi AM. Current state of imaging in dermatology. *Semin Cutan Med Surg*. 2016;35(1):2-8. doi:10.12788/j.sder.2016.001
- 84 Guida S, Alma A, Shaniko K, et al. Non-Melanoma Skin Cancer Clearance after Medical Treatment Detected with Noninvasive Skin Imaging: A Systematic Review and Meta-Analysis. *Cancers (Basel)*. 2022;14(12). doi:10.3390/cancers14122836
- 85 Dinnes J, Deeks JJ, Chuchu N, et al. Dermoscopy, with and without visual inspection, for diagnosing melanoma in adults. *Cochrane database Syst Rev*. 2018;12(12):CD011902. doi:10.1002/14651858.CD011902.pub2
- 86 Bakos RM, Blumetti TP, Roldán-Marín R, Salerni G. Non-invasive Imaging Tools in the Diagnosis and Treatment of Skin Cancers. *Am J Clin Dermatol*. 2018;19(Suppl 1):3-14. doi:10.1007/s40257-018-0367-4
- 87 Fujimoto J, Swanson E. The Development, Commercialization, and Impact of Optical Coherence Tomography. *Invest Ophthalmol Vis Sci*. 2016;57(9):OCT1-OCT13. doi:10.1167/iovs.16-19963
- 88 Marschall S, Sander B, Mogensen M, Jørgensen TM, Andersen PE. Optical coherence tomography-current technology and applications in clinical and biomedical research. *Anal Bioanal Chem*. 2011;400(9):2699-2720. doi:10.1007/s00216-011-5008-1
- 89 Mogensen M, Morsy HA, Thrane L, Jemec GBE. Morphology and epidermal thickness of normal skin imaged by optical coherence tomography. *Dermatology*. 2008;217(1):14-20. doi:10.1159/000118508
- 90 Themstrup L, Welzel J, Ciardo S, et al. Validation of Dynamic optical coherence tomography for non-invasive, in vivo microcirculation imaging of the skin. *Microvasc Res*. 2016;107:97-105. doi:10.1016/j.mvr.2016.05.004
- 91 Glinos GD, Verne SH, Aldahan AS, et al. Optical coherence tomography for assessment of epithelialization in a human ex vivo wound model. *Wound Repair Regen Off Publ Wound Heal Soc [and] Eur Tissue Repair Soc*. 2017;25(6):1017-1026. doi:10.1111/wrr.12600
- 92 Sirotkina MA, Potapov AL, Vagapova NN, et al. Multimodal optical coherence tomography: Imaging of blood and lymphatic vessels of the vulva. *Sovrem Tehnol v Med*. 2019;11(4):26-31. doi:10.17691/STM2019.11.4.03
- 93 Wessels R, Bruin DM de, Faber DJ, et al. Optical coherence tomography in vulvar intraepithelial neoplasia. <https://doi.org/10.1117/1JBO171116022> 2012;17(11):116022. doi:10.1117/1.JBO.17.11.116022
- 94 Kirillin M, Motovilova T, Shakhova N. Optical coherence tomography in gynecology: a narrative review. *J Biomed Opt*. 2017;22(12):1. doi:10.1117/1.JBO.22.12.121709
- 95 Hofmann-Wellenhof R, Pellacani G, Malvehy J, Soyer HP. *Reflectance Confocal Microscopy for Skin Diseases*. Springer Berlin Heidelberg; 2012. doi:10.1007/978-3-642-21997-9
- 96 Dinnes J, Deeks JJ, Saleh D, et al. Reflectance confocal microscopy for diagnosing cutaneous melanoma in adults. *Cochrane database Syst Rev*. 2018;12(12):CD013190. doi:10.1002/14651858.CD013190
- 97 Braga JCT, Macedo MP, Pinto C, et al. Learning reflectance confocal microscopy of melanocytic skin lesions through histopathologic transversal sections. *PLoS One*. 2013;8(12). doi:10.1371/journal.pone.0081205
- 98 Hoeffelin H, Jacquemin D, Defaweux V, Nizet JL. A methodological evaluation of volumetric measurement techniques including three-dimensional imaging in breast surgery. *Biomed Res Int*. 2014;2014. doi:10.1155/2014/573249
- 99 Catherwood T, McCaughan E, Greer E, Spence RAJ, McIntosh SA, Winder RJ. Validation of a passive stereophotogrammetry system for imaging of the breast: A geometric analysis. *Med Eng Phys*. 2011;33(8):900-905. doi:10.1016/j.MEDENGGPHY.2011.02.005
- 100 Stekelenburg CM, Van Der Wal MBA, Knol DL, De Vet HCW, Van Zuijlen PPM. Three-dimensional digital stereophotogrammetry: A reliable and valid technique for measuring scar surface area. *Plast Reconstr Surg*. 2013;132(1):204-211. doi:10.1097/PRS.0b013e318290f675
- 101 Stekelenburg CM, Jaspers MEH, Niessen FB, et al. In a clinimetric analysis, 3D stereophotogrammetry was found to be reliable and valid for measuring scar volume in clinical research. *J Clin Epidemiol*. 2015;68(7):782-787. doi:10.1016/j.JCLINEPI.2015.02.014
- 102 Byrd AL, Belkaid Y, Segre JA. The human skin microbiome. *Nat Rev Microbiol*. 2018;16(3):143-155. doi:10.1038/nrmicro.2017.157
- 103 Niemeier-van der Kolk T, van der Wall HEC, Balmforth C, Van Doorn MBA, Rissmann R. A systematic literature review of the human skin microbiome as biomarker for dermatological drug development. *Br J Clin Pharmacol*. 2018;84(10):2178-2193. doi:10.1111/bcp.13662
- 104 Rajagopala S V, Vashee S, Oldfield LM, et al. The Human Microbiome and Cancer. *Cancer Prev Res (Phila)*. 2017;10(4):226-234. doi:10.1158/1940-6207.CAPR-16-0249
- 105 Bhatt AP, Redinbo MR, Bultman SJ. The role of the microbiome in cancer development and therapy. *CA Cancer J Clin*. 2017;67(4):326-344. doi:10.3322/CAAC.21398
- 106 Song SD, Acharya KD, Zhu JE, et al. Daily Vaginal Microbiota Fluctuations Associated with Natural Hormonal Cycle, Contraceptives, Diet, and Exercise. *mSphere*. 2020;5(4). doi:10.1128/mSphere.00593-20
- 107 Gupta S, Kakkur V, Bhushan I. Crosstalk between Vaginal Microbiome and Female Health: A review. *Microb Pathog*. 2019;136:103696. doi:10.1016/j.micpath.2019.103696
- 108 Ravel J, Gajer P, Abdo Z, et al. Vaginal microbiome of reproductive-age women. *Proc Natl Acad Sci U S A*. 2011;108(Suppl(Suppl 1):4680-4687. doi:10.1073/pnas.100261107
- 109 Gajer P, Brotman RM, Bai G, et al. Temporal dynamics of the human vaginal microbiota. *Sci Transl Med*. 2012;4(132):132ra52-132ra52. doi:10.1126/scitranslmed.3003605
- 110 Mendling W, Palmeira-de-Oliveira A, Biber S, Prasauskas V. An update on the role of Atopobium vaginae in bacterial vaginosis: what to consider when choosing a treatment? A mini review. *Arch Gynecol Obstet*. 2019;300(1):1. doi:10.1007/s00404-019-05142-8
- 111 Pépin J, Deslandes S, Giroux G, et al. The complex vaginal flora of West African women with bacterial vaginosis. *PLoS One*. 2011;6(9). doi:10.1371/journal.pone.0025082
- 112 Bradford LL, Ravel J. The vaginal microbiome: A contemporary perspective on fungi in women's health and diseases. *Virulence*. 2017;8(3):342-351. doi:10.1080/21505594.2016.1237332
- 113 Dabee S, Passmore J-AS, Heffron R, Jaspas HB. The Complex Link between the Female Genital Microbiota, Genital Infections, and Inflammation. *Infect Immun*. 2021;89(5). doi:10.1128/IAI.00487-20
- 114 Norenhag J, Du J, Olovsson M, Verstraeten H, Engstrand L, Brusselaers N. The vaginal microbiota, human papillomavirus and cervical dysplasia: a systematic review and network meta-analysis. *BJOG An Int J Obstet Gynaecol*. 2020;127(2):171-180. doi:10.1111/1471-0528.15854
- 115 Curty G, de Carvalho PS, Soares MA. The Role of the Cervicovaginal Microbiome on the Genes and as a Biomarker of Premalignant Cervical Intraepithelial Neoplasia and Invasive Cervical Cancer. *Int J Mol Sci*. 2020;21(1). doi:10.3390/IJMS21010222
- 116 Brusselaers N, Shrestha S, van de Wijgert J, Verstraeten H. Vaginal dysbiosis and the risk of human papillomavirus and cervical cancer: systematic review and meta-analysis. *Am J Obstet Gynecol*. 2019;221(1):9-18. e8. doi:10.1016/j.ajog.2018.12.011
- 117 Mitra A, MacIntyre DA, Lee YS, et al. Cervical intraepithelial neoplasia disease progression is associated with increased vaginal microbiome diversity. *Sci Rep*. 2015;5(September):1-11. doi:10.1038/srep16865
- 118 Lee JE, Lee S, Lee H, et al. Association of the Vaginal Microbiota with Human Papillomavirus Infection in a Korean Twin Cohort. *PLoS One*. 2013;8(5). doi:10.1371/journal.pone.0063514
- 119 Audirac-Chalifour A, Torres-Poveda K, Bahena-Román M, et al. Cervical microbiome and cytokine profile at various stages of cervical cancer: A pilot study. *PLoS One*. 2016;11(4). doi:10.1371/journal.pone.0153274
- 120 Łaniewski P, Cui H, Roe DJ, et al. Features of the cervicovaginal microenvironment drive cancer biomarker signatures in patients across cervical carcinogenesis. *Sci Rep*. 2019;9(1):1-14. doi:10.1038/s41598-019-43849-5
- 121 Champer M, Wong AM, Champer J, et al. The role of the vaginal microbiome in gynaecological cancer. *BJOG*. 2018;125(3):309-315. doi:10.1111/1471-0528.14631
- 122 Wahid M, Dar SA, Jawed A, et al. Microbes in gynecologic cancers: Causes or consequences and therapeutic potential. *Semin Cancer Biol*. Published online July 22, 2021. doi:10.1016/j.semcancer.2021.07.013
- 123 ALY R, BRITZ MB, MAIBACH HI. Quantitative microbiology of human vulva. *Br J Dermatol*. 1979;101(4):445-448. doi:10.1111/j.1365-2133.1979.tb00024.x
- 124 Elsnér P, Maibach HI. Microbiology of specialized skin: The vulva. *Semin Dermatol*. 1990;9(4):300-304. Accessed March 21, 2021. <https://pubmed.ncbi.nlm.nih.gov/22855574/>
- 125 Brown CJ, Wong M, Davis CC, Kanti A, Zhou X, Forney LJ. Preliminary characterization of the normal microbiota of the human vulva using cultivation-independent methods. *J Med Microbiol*. 2007;56(PART 2):271-276. doi:10.1099/jmm.0.46607-0

## SECTION I

---

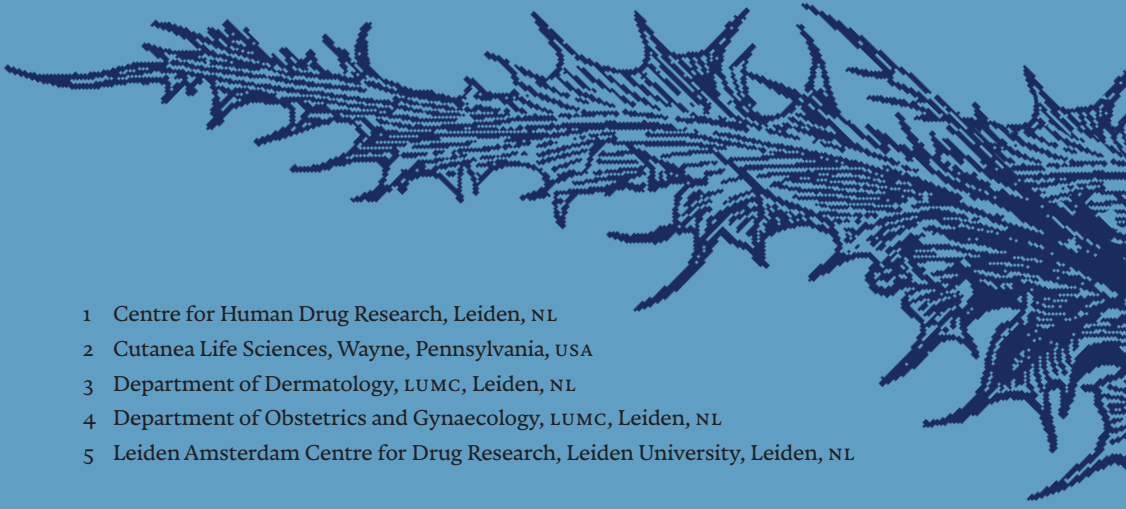
# CHARACTERISING VULVAR AND HPV-DRIVEN DISEASE WITH NOVEL IMAGING TECHNIQUES

## Stereophotogrammetric 3D photography is an accurate and precise planimetric method for the clinical visualization and quantification of HPV-induced skin lesions

*Published in Journal of the European Academy of Dermatology and Venereology, 2019. Doi: 10.1111/jdv.15474*

Melanie Rijsbergen,<sup>1</sup> Lisa Pagan,<sup>1</sup> Tessa Niemeyer-van der Kolk,<sup>1</sup> Rianne Rijneveld,<sup>1</sup> Geretta Hogendoorn,<sup>1</sup> Celeste Lemoine,<sup>1</sup> Yuri Meija Miranda,<sup>1</sup> Gary Feiss<sup>2</sup>, Jan Nico Bouwes Bavink,<sup>3</sup> Jacobus Burggraaf,<sup>1,5</sup> Mariëtte I.E. van Poelgeest<sup>1,4</sup> and Robert Rissmann.<sup>1,5</sup>

---

- 
- 1 Centre for Human Drug Research, Leiden, NL
  - 2 Cutanea Life Sciences, Wayne, Pennsylvania, USA
  - 3 Department of Dermatology, LUMC, Leiden, NL
  - 4 Department of Obstetrics and Gynaecology, LUMC, Leiden, NL
  - 5 Leiden Amsterdam Centre for Drug Research, Leiden University, Leiden, NL

## Abstract

**BACKGROUND** Quantification of HPV-induced skin lesions is essential for the clinical assessment of the course of disease and the response to treatment. However, clinical assessments that measure dimensions of lesions using a caliper, do not provide complete insight into 3D lesions and its inter-rater variability is often poor.

**OBJECTIVE** The aim of this study was to validate a stereophotogrammetric 3D camera system for the quantification of HPV-induced lesions.

**METHODS** The camera system was validated for accuracy, precision and inter-operator and inter-rater variability. Subsequently, 3D photographs were quantified and compared to caliper measurements for clinical validation by Bland-Altman modelling, based on data from 80 patients with cutaneous warts (CW), 24 with anogenital warts (AGW) patients and 12 with high-grade squamous intraepithelial lesions of the vulva (vulvar HSIL) with a total lesion count of 220 CW, 74 AGW and 31 vulvar HSIL.

**RESULTS** Technical validation showed excellent accuracy (coefficients of variation (CV)  $\leq 0.68\%$ ) and reproducibility (CVs  $\leq 2\%$ ), a good to excellent agreement between operators (CVs  $\leq 8.7\%$ ) and a good to excellent agreement between different raters for all three lesion types (ICCs  $\geq 0.86$ ). When comparing 3D with caliper measurements, excellent biases were found for diameter of AGW (long diameter 5%), good biases for diameter of AGW (short diameter 10%) and height of CW (8%) and acceptable biases were found for the diameter of CW (11%) and vulvar HSIL (short diameter 14%, long diameter 16%). An unfavorable difference between these methods (bias 25%) was found for the assessment of height of AGWs.

**CONCLUSION** Stereophotogrammetric 3D imaging is an accurate and reliable method for the clinical visualization and quantification of HPV-induced skin lesions.

## Introduction

The human papilloma virus (HPV) is responsible for a spectrum of dermatological and gynaecological lesions. Low-risk HPV types are associated with cutaneous warts (CW) and anogenital warts (AGW), whilst high-risk types can cause (pre-)malignant lesions of the tissues of the anogenital tract, including high-grade squamous intraepithelial lesions of the vulva (vulvar HSIL, formerly referred to as usual-type vulvar intraepithelial neoplasia, uVIN).<sup>1-4</sup> Standard treatment for HPV-induced lesions includes surgical excision or ablative therapy; however, these can be mutilating and cause physical, psychological and (psycho-)sexual problems.<sup>5,6</sup> Overall, current treatment options for HPV are associated with poor response, high recurrence rates and treatment limiting side effects.<sup>7,8</sup> Therefore, new treatment options for HPV-related lesions are under investigation. The response to new dermatological therapies is often measured by calipers using traditional linear size assessments. These techniques fail to deliver complete insight into lesion dimensions as they can only assess the diameter and, if applicable, height of a lesion, and do not determine surface area or volumetric parameters.<sup>9,10</sup> Three-dimensional (3D) imaging might offer a solution to these limitations. These techniques are already widely used in the field of plastic surgery and anthropometry to add objective measuring techniques to clinical practice.<sup>11-13</sup> Advantages of 3D imaging include the possibility of offline 3D visualization for dimensional quantification and photo documentation over time. A validated 3D imaging system would enable the accurate and highly sensitive characterization of detailed skin lesions, and would allow for an adequate evaluation of new therapies for HPV-induced lesions.

Stereophotogrammetry is a technique that obtains two or more images from different angles, which can subsequently be reconstructed into a 3D image and has been validated for use in scars, basal cell carcinoma, wounds and wrinkles.<sup>14-20</sup> Currently, this method remains unvalidated for the analysis of HPV-related skin lesions. Before it can be used in the clinical practice, 3D imaging using stereophotogrammetry requires technical verification for the analysis of HPV-related lesions. Therefore, the aim of this study was to validate stereophotogrammetric 3D photography for the clinical assessment of CW, AGW and vulvar HSIL.

## Materials and methods

### DEVICE & ANALYSIS TOOLS

The LifeViz® Micro (Quantificare, Sophia Antipolis, France) is a compact stereophotogrammetric 3D imaging system. The package includes hardware consisting of a 15.1 megapixels, single lens reflex camera (Canon, Tokyo, Japan) with a polar flash system and a dual beam pointer used to standardize photographing distance at 20 cm. All photographs were taken according to a pre-defined standard operating procedure (see *Supplemental Figure 1*) in identical environmental conditions and standardized positioning of the patient depending on lesion type (see *Supplemental Figure 2* and *3*). All photographs were made in the same room with closed blinds and room lights on. The camera distance was set to 'micro' to standardize the system-lesion distance to 20 cm by means of an integrated dual beam pointer. Before taking the photographs the circumstances were verified using a checklist (*Supplementary Figure 4*). Photographs were always free hand images and the camera system was perpendicularly pointed at the lesion of interest. Baseline photographs were used as reference for follow-up photography. Subsequently, the photograph was taken as soon as the dual beam pointers merged onto the lesion of interest. Image management, 3D image reconstruction, and 3D analysis were performed using DermaPix® software (Quantificare, Cedex, France), which is an image management software package providing a database system and quantification features. The photographs were uploaded in the software system processed as described in *Supplementary Figure 1*. The 3D analysis module was opened to generate a heat map (indicating height levels). As result 'difference' could be selected in the menu and the contour was loaded to verify the correct cement of the manual contour. The lesion dimensions were provided after loading of the contour.

### TECHNICAL VALIDATION

For the technical validation of the 3D camera system, a twelve inch ruler (Schaedler Quinzel Inc., Parsippany NJ, USA) and a wart-like object manufactured out of lightweight air-drying modeling clay (Hema, the Netherlands) were used.

Accuracy of the stereophotogrammetric 3D imaging system (i.e. '3D camera system') was determined regarding absolute linear measurement by 3D

photography of the twelve inch ruler and regarding multiple dimensions measurement using the wart-like object. Repeated (N=40) 3D images were taken of the wart-like phantom object under identical conditions to determine the precision of repeated measurements. The inter-operator reliability of the 3D camera system was determined to validate the use by ten different photographers. All obtained 3D images were processed and quantified by one trained assessor.

### PATIENT CHARACTERISTICS

For the clinical validation, i.e. inter rater variability and clinical application, of the 3D camera system, HPV-induced skin lesions were photographed during three phase 2 clinical trials. These were randomized, double-blind, placebo-controlled studies to evaluate the efficacy and safety of a topically applied novel drug on lesions caused by HPV (*Supplementary Table 1*). All lesions were measured by a caliper by a trained physician and trained operators subsequently obtained 3D photographs during all study visits.

### CLINICAL VALIDATION

The images of the CW were processed and quantified by four individual and independent raters. Also four individuals scored the AGW lesions. Finally, 3D images of vulvar HSIL were independently quantified by two raters. The concordance between different assessors of the 3D images in the imaging software (i.e. inter-rater variability) was determined by comparing the quantification results of all clinical 3D images of skin lesions taken at the baseline study visit.

In addition, the HPV-induced lesions in the three trials were assessed by caliper measurements and 3D photography during all visits. The 3D measurements were compared to manual measurements acquired with a digital Vernier caliper (0-150 mm, Aerospace). The caliper measurements of CW and AGW were performed by trained physicians and the vulvar HSIL measurements were performed by a trained physician and a gynaecologist. The 3D photographs were taken by trained clinical staff. For the CW and AGW, the analysis of the 3D photographs was performed after all patients completed all visits by one clinical rater. The analysis of the 3D photographs of vulvar HSIL was performed after all patients completed all visits by two raters (the trained physician and gynaecologist who also performed the caliper measurements) who independently rated all images and had a consensus meeting afterwards.

The raters who quantified the 3D photographs of the AGW and vulvar HSIL also performed the clinical caliper measurements. The quantification process was performed after all patients completed all visits. The analysis of the 3D data was performed individually and blinded to the assessment of the other operators.

The Declaration of Helsinki was the guiding principle for trial execution and all subjects gave informed consent before any procedure. The study was approved by the Dutch Medical Ethics Committee ('Stichting Beoordeling Ethiek Biomedisch Onderzoek', Assen, the Netherlands).

The clinical results on the efficacy and safety of the novel drugs investigated in the phase 2 trials will be published elsewhere.

### STATISTICAL ANALYSIS

For the technical validation, the accuracy, precision and inter-operator reliability of the camera system were expressed by the mean ( $\mu$ ) and standard deviation (SD) per measured domain of all images, which were used to determine the coefficient of variation (CV) in percentage. We pre-specified a CV  $\leq 5\%$  as excellent, a CV 6-10% as good and a CV 11-20% as acceptable. The intra-class correlation coefficient (ICC) was established to quantify the variability of the 3D image processing and quantification. The ICC was determined in a two-way mixed model, with investigators as fixed and the subjects as random variable.<sup>21</sup> ICC values of 0.7-0.8, 0.8-0.9 and  $\geq 0.9$  were considered as of acceptable, good and excellent agreement, respectively.<sup>22,23</sup>

Clinical validation was approached by visualizing the data in Bland-Altman plots per parameter (where applicable; long diameter, short diameter and height) to represent the agreement between caliper and 3D measurements.<sup>24,25</sup> These plots calculate the mean difference between the two measurements (bias, in mm) and the limits of agreement (LOA). We used a linear mixed model specified to calculate the bias and limits of agreement based on the repeated measurements as described previously.<sup>26</sup> Based on the size of the lesions, we predefined the biases of  $\leq 5\%$ , 6-10% and 11-20% as percentages of the mean baseline caliper measurement as excellent, good and acceptable, respectively. These specifications were derived from analytical methods for clinical trials and practice.<sup>27,28</sup> The comparative analysis between caliper and 3D measurements was not performed until all 3D data was quantified to avoid subjectivity in the manual contours.

## Results

### TECHNICAL VALIDATION

The technical validation revealed a high accuracy with CVs ranging from 0 to 0.68% for 3D measurements of units of absolute ruler length (*Figure 1*). The precision of a phantom object analyzed in diameter, height, volume and surface area resulted in CVs of 0.69%, 2.0%, 1.5% and 1.1%, respectively.

The inter-operator variability resulted in CVs of 1.9% for longest diameter, 8.7% for height, 2.8% for volume and 2.7% for surface area, indicating that analysis of 3D images taken by different trained persons yields similar results. For the inter-rater variability, 220 images of different CW, 72 images of different AGW and 31 different images of vulvar HSIL were quantified by the raters (see *Table 1*). The ICCs of the inter-rater variability for CW were 0.97, 0.90 and 0.88 for diameter, height and volume respectively. The inter-rater variability was similar for common and plantar warts (data not shown). In AGW we found an ICC of 0.91 for long diameter, 0.86 for short diameter, 0.90 for height and 0.98 for volume. For vulvar HSIL we found an ICC of 0.97 for long diameter, 0.94 for short diameter and 0.96 for surface. These data indicate that analysis of the 3D images by different raters yielded comparable results.

### CLINICAL VALIDATION

Two-hundred-twenty (220) CW of 80 patients were included, of which 114 common and 106 plantar warts. In total, 1110 measurements of CW were performed, all of which (100%) were eligible for diameter, height and volume analysis. Subject characteristics are summarized in *Table 1*. An example of the three lesion types and the 3D reconstruction are shown in *Fig 2*.

Forest plots of the outcomes of Bland-Altman analysis in CW, AGW and vulvar HSIL are shown in *Figure 3*. In CW we found a bias of 0.7mm (11%) with LOA of -1.2mm and 2.6mm for diameter. The bias for height was -0.04mm (8%) with LOA of -0.5mm and 0.4mm (*Figure 3A*). Outcomes for common and plantar warts separately showed no differences (data not shown).

Seventy-two (72) individual AGW of a total of 24 patients were included. In total, 341 measurements were performed, all of which (100%) were eligible for diameter analysis and 270 (79.2%) were eligible for height and volume measurements. The 71 photographs (20.8%) unsuitable for height and volume measurements showed abundant presence of hairs or shadows, which

impeded the construction of a 3D image. The results of the Bland-Altman analysis are shown in a forest plot (Figure 3B). For the measurement of long diameter, we found a bias of 0.2mm (5%) with LOA between -1.5mm and 1.9mm. For short diameter we found a bias of 0.3mm (10%) and LOA ranging from -0.08mm and 0.7mm. Height bias was calculated as -0.3mm (25%) with LOA -0.7mm and 0.2mm.

Thirty-one (31) vulvar HSIL lesions of 12 patients were included and a total of 170 measurements were collected. All were eligible for diameter analysis (100%) and 164 (96.5%) were eligible for surface measurements. Photos were deemed unsuitable for further analysis when the imaging software was unable to compute a correct 3D image because of shadows and hairs disturbing the image. The bias values for long and short diameter were 2.3mm (14%) and 1.8mm (16%), with LOA ranging from -8.9mm and 13.4mm, and -7.1mm and 10.8mm, respectively (Figure 3C).

## Discussion

This validation study is the first to demonstrate that stereophotogrammetric 3D imaging is an accurate and precise method for the characterisation of HPV-related lesions and is applicable for the assessment of these lesions in a clinical setting.

The technical validation revealed an excellent accuracy with CVs < 0.68%, an excellent reproducibility with CVs ≤ 2% and a good to excellent agreement with CVs ≤ 8.7% for the inter-operator variability. This indicates that 3D imaging is an exact and highly reproducible method. Three-dimensional photography of HPV-related lesions is also reliable for individual raters to assess the obtained photographs, established by good to excellent ICC values (0.86–0.98). These results indicate that a single photograph taken in standardized conditions by a trained operator is sufficient for reliable quantification of the lesions.

The clinical validation of diameter and height measurements yielded an acceptable (11%) and good (8%) bias between caliper and 3D imaging for CW. For AGW, we found an excellent (5%) and a good (10%) bias for the long and short diameter, respectively, but an unacceptable bias (25%) for the height of the AGW. For vulvar HSIL the calculated biases for comparison of the methods caliper and 3D measurements were acceptable for both the long (14%) and short (16%) diameter. However, we did not investigate the errors induced by variation of environmental factors such as lighting, distance, variation of

the plane/positioning in an artificial manner but focused on the standardized procedure to readily use it for monitoring HPV-induced lesions in clinical practice or after intervention in a clinical trial setting. Of note, calibration of the device was not necessary as both the high accuracy (Figure 1) and the finding of a good inter-day precision could be confirmed by the manufacturer. The latter was determined by repeatedly (N=27) analysing the geometric parameters over a period of 3 months which showed CVs ranging from 0.65% for diameter to 3.72% for volume (see Supplemental Table 2).

Our technical and clinical validation results correspond to findings in earlier studies utilizing stereophotogrammetry as a method for the qualification of dermatological lesions. Robertson and colleagues found an ICC of 0.98 for volume quantification of hemangiomas in children using the same stereophotogrammetric system as utilized in this study.<sup>29</sup> Moreover, a previous study evaluating pressure ulcer wounds also found excellent inter-operator variability between operators (ICC=0.99).<sup>16</sup> The evaluation of scars with stereophotogrammetry demonstrated excellent reliability and validity of the technique, although there was only moderate agreement between 3D quantification results and the gold standard (weighing of simulated clay scars).<sup>14</sup> Other studies using stereophotogrammetry for breast dimension assessments reported moderate to good agreement with manual measurements due to difficulties in exact determination of the borders.<sup>11,12</sup>

This study was limited by the absence of a comparison between the caliper and 3D measurements for volume and surface area. Indirectly, volume can only be calculated by a formula for an ellipse using the caliper measurements which often inaccurately reflects the shape of most warts. However, reliably including the third dimension of lesions and thus parameters like lesion volume and height of CW and AGW for detecting drug effects would be advantageous and indisputable for clinicians and drug developers. A similar limitation applies for area calculation of vulvar HSIL. There is no formula that encompasses the dimensions of HSIL and on the uneven genital tissue surface estimation techniques such as planimetry by tracing cannot be performed.<sup>15</sup> For these reasons, other type of research must be performed to investigate the reliability of stereophotogrammetrically acquired volume and surface estimations like the artificial system used by Skvara et al.<sup>18</sup>

A limitation of the imaging software was that the contour around the lesions had to be drawn manually by the investigator. A system automatically determining the borders of the lesion would be of great added value but the

current auto-contour function of the software did not pass the face validity criteria, i.e. already simple assignments would lead to obvious incorrect contour representation (data not shown). However, drawing the manual outline and the subsequent automatically calculated size led to reproducible results, indicated by a low inter-rater variability (*Table 1*).

Limitations of stereophotogrammetry of genital HPV-related lesions concern the plane surface in the vicinity of the lesion of interest, which is a pre-requisite for the analysis tool during 3D reconstruction. Achieving a plane surface is complicated in case of periungual warts, AGW on the labia, frenulum or in the perianal area, or by areas disrupted by the presence of hairs projecting over the lesion of interest. The difficulty of accurately picturing curved body parts is a feature of 3D imaging systems that has been noted previously.<sup>13-15</sup> These confounders might have resulted in unreliable measurement of height, surface and volume in this study. It is imperative that these data are correctly obtained by the 3D system, as caliper measurements only yield rough estimates of these parameters. For instance, we had to omit 20.8% of the volume and height quantification results of the AGW study due to suboptimal image reconstructions. Therefore, we advise potential users of stereophotogrammetry to pay extra attention to the removal of obscuring hairs during photography. We discarded images with irregularities in 3D reconstructions and erroneous measurements caused by hairs from the data that was analyzed for this study.

Recent studies suggested that following immunotherapy, lesions can firstly increase in size before regression, a phenomenon known as pseudo-progression. This is caused by influx of immune cells and measured according to the iRECIST, a guideline for response criteria for use in immunotherapeutic trials.<sup>30,31</sup> Future research should take into account the applicability of 3D photography as a potential biomarker for response to immune therapy in combination with histologic immune infiltration assessments.

Overall, the added value of 3D imaging over caliper measurements is the enhanced accuracy of the measurement. Additional potential applications of 3D imaging of vulvar HSIL would be collegial or post-hoc consultation, clinical follow-up and training purposes to increase disease awareness among clinicians. Furthermore, stereophotogrammetric photo documentation and offline visualization of the lesions offers an accurate and precise manner to follow the lesions during clinical trials. While the focus of our investigation was on the clinical application of 3D photography for geometric parameters of

HPV-induced lesions one might speculate of its potential value for the objective measurement of lesions with distinct features such as textural changes of the skin in atopic dermatitis or other inflammatory skin conditions.

In conclusion, this study shows that stereophotogrammetry is an adequate tool for accurate and precise evaluation of HPV-induced skin lesions. Furthermore, it is applicable as a method for accurate and reproducible photo documentation of lesions. Being a portable, hand-held system, the validated system offers flexibility and practical advantages over other 3D imaging systems.<sup>13-15</sup> These results need validation in larger cohorts and regarding other skin conditions. In addition, future studies should aim at the examination of 3D photography as a possible biomarker for lesion size assessment and treatment response.

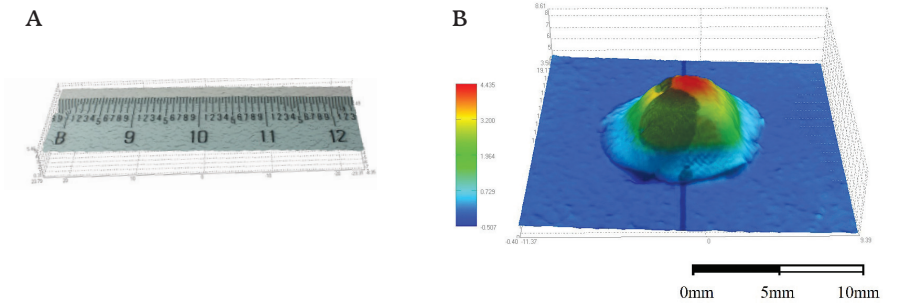
**Table 1** The inter-rater variability of 3D photography in HPV-induced skin lesions.

	Cutaneous warts (CW)			Anogenital warts (AGW)			Vulvar HSIL			Surface
	Dia- meter	Height	Volume	Long diameter	Short diameter	Height	Volume	Long diameter	Short diameter	
ICC	0.97	0.90	0.88	0.91	0.86	0.90	0.98	0.97	0.94	0.96
95% CI	0.96, 0.98	0.88, 0.92	0.85, 0.91	0.87, 0.94	0.80, 0.91	0.85, 0.94	0.96, 0.99	0.93, 0.99	0.88, 0.97	0.91, 0.98

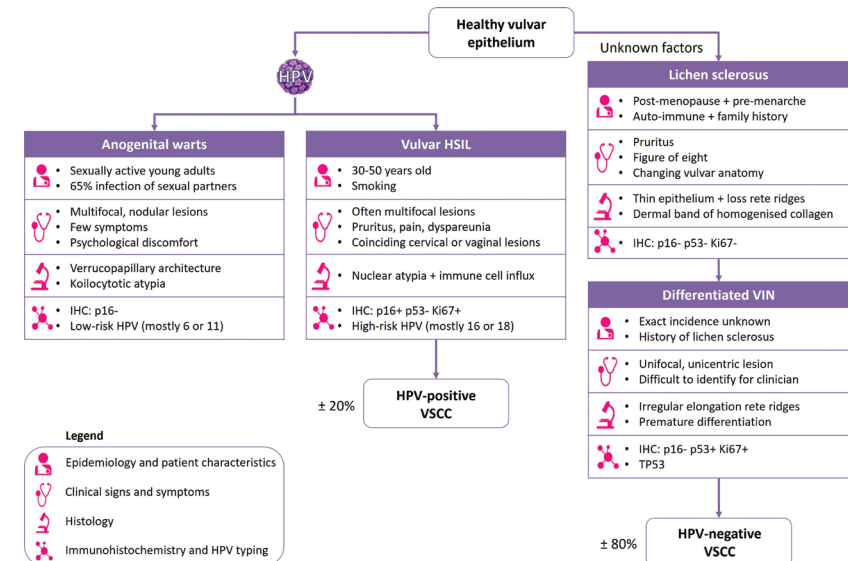
ICC=intra-class correlation coefficient; CI=confidence interval; ICC values of >0.9 were considered as excellent and >0.8 as good

**Figure 1** 3D reconstruction of the twelve inch ruler (A) and wart-like object (B).

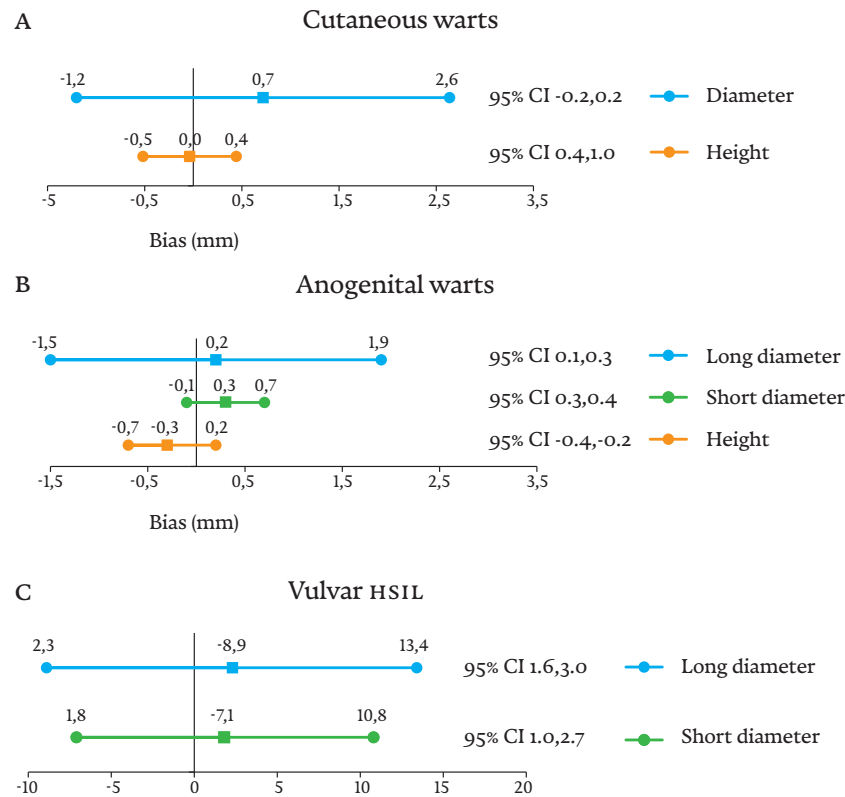
Three-D reconstruction of the twelve inch ruler by the image reconstruction software (A), and the wart-like object in a 3D reconstruction with a heat-map showing the height of the object which is used for the 3D analysis (B).



**Figure 2** Three-dimensional reconstruction by stereophotogrammetry. A representative lesion for all three HPV-induced lesions (cutaneous warts, anogenital warts and vulvar HSIL) with on the left the 2D photograph, in the middle the 3D reconstruction and on the right the heat map showing height differences and the manual contour around the lesion.



**Figure 3** Forest plot of the bias and Limit of Agreement (LOA) from the Bland-Altman analysis for common and plantar warts, anogenital warts and vulvar HSIL. Forest plots of the outcomes of the Bland-Altman analysis in CW, AGW and vulvar HSIL.



CI= confidence interval, bias is indicated by a square, corresponding LoA are indicated by dots.  
 CW = cutaneous warts, AGW = anogenital warts, HSIL = High-grade squamous intraepithelial lesions

**SUPPLEMENTS CHAPTER 2**

Supplemental data can be accessed online at:  
<https://www.ncbi.nlm.nih.gov/pmc/articles/PMC6767777/>

- Supplementary Figure 1 Flow diagram of the 3D photography procedure
- Supplementary Figure 2 Positioning of patients with cutaneous warts
- Supplementary Figure 3 Positioning vulvar HSIL patients and patients with anogenital warts
- Supplementary Figure 4 Checklist 3D photography with LifeViz Micro Camera
- Supplementary Table 1 Patient characteristics of the three clinical trials at baseline
- Supplementary Table 2 Inter-day precision (repeatability) geometrical parameters of a standard, phantom object over the period of 3 months (N = 27).



REFERENCES

- 1 Bruggink SC, de Koning MN, Gussekloo J, et al. Cutaneous wart-associated HPV types: prevalence and relation with patient characteristics. *Journal of clinical virology: the official publication of the Pan American Society for Clinical Virology* 2012;55(3):250-5.
- 2 de Koning MN, Khoe LV, Eekhof JA, et al. Lesional HPV types of cutaneous warts can be reliably identified by surface swabs. *Journal of clinical virology: the official publication of the Pan American Society for Clinical Virology* 2011;52(2):84-7.
- 3 Rock B, Shah KV, Farmer ER. A morphologic, pathologic, and virologic study of anogenital warts in men. *Archives of Dermatology* 1992;128(4):495-500.
- 4 Faber MT, Sand FL, Albieri V, et al. Prevalence and type distribution of human papillomavirus in squamous cell carcinoma and intraepithelial neoplasia of the vulva. *International journal of cancer* 2017;141(6):1161-69.
- 5 Hillemanns P, Wang X, Staehle S, et al. Evaluation of different treatment modalities for vulvar intraepithelial neoplasia (VIN): CO(2) laser vaporization, photodynamic therapy, excision and vulvectomy. *Gynecol Oncol* 2006;100(2):271-5.
- 6 Likes WM, Stegbauer C, Tillmanns T, et al. Correlates of sexual function following vulvar excision. *Gynecol Oncol* 2007;105(3):600-3.
- 7 Stanley MA. Genital human papillomavirus infections: current and prospective therapies. *J Gen Virol* 2012;93(Pt 4):681-91.
- 8 Hanna E, Abadi R, Abbas O. Imiquimod in dermatology: an overview. *Int J Dermatology* 2016;55(8):831-44.
- 9 Committee Opinion No.675: Management of Vulvar Intraepithelial Neoplasia. *Obstetrics and gynecology* 2016;128(4):e178-82.
- 10 van de Nieuwenhof HP, van der Avoort IA, de Hullu JA. Review of squamous premalignant vulvar lesions. *Crit Rev Oncol Hematol* 2008;68(2):131-56.
- 11 Hoeffelin H, Jacquemin D, Defaweux V, et al. A methodological evaluation of volumetric measurement techniques including three-dimensional imaging in breast surgery. *Biomed Res Int* 2014;2014:573249.
- 12 Catherwood T, McCaughan E, Greer E, et al. Validation of a passive stereophotogrammetry system for imaging of the breast: a geometric analysis. *Med Eng Phys* 2011;33(8):900-5.
- 13 Heike CL, Upton K, Stuhaut E, et al. 3D digital stereophotogrammetry: a practical guide to facial image acquisition. *Head & Face Medicine* 2010;6:18-18.
- 14 Stekelenburg CM, Jaspers ME, Niessen FB, et al. In a clinimetric analysis, 3D stereophotogrammetry was found to be reliable and valid for measuring scar volume in clinical research. *Journal of clinical epidemiology* 2015;68(7):782-7.
- 15 Stekelenburg CM, van der Wal MB, Knol DL, et al. Three-dimensional digital stereophotogrammetry: a reliable and valid technique for measuring scar surface area. *Plastic and reconstructive surgery* 2013;132(1):204-11.
- 16 Davis AJ, Nishimura J, Seton J, et al. Repeatability and clinical utility in stereophotogrammetric measurements of wounds. *J Wound Care* 2013;22(2):90-2, 94-7.
- 17 Xu Y, Sun J, Carter RR, et al. Personalized prediction of chronic wound healing: an exponential mixed effects model using stereophotogrammetric measurement. *J Tissue Viability* 2014;23(2):48-59.
- 18 Skvara H, Burnett P, Jones J, et al. Quantification of skin lesions with a 3D stereovision camera system: validation and clinical applications. *Skin Res Technol* 2013;19(1):e182-90.
- 19 Skvara H, Kalthoff F, Meingassner JG, et al. Topical treatment of Basal cell carcinomas in nevroid Basal cell carcinoma syndrome with a smoothed inhibitor. *J Invest Dermatol* 2011;131(8):1735-44.
- 20 Lumenta DB, Selig H, Kitzinger HB, et al. Objective quantification of wrinkles: three-dimensional analysis of surface irregularity. *Plast Reconstr Surg* 2012;129(4):735e-7e.
- 21 Haber M, Gao J, Barnhart HX. Evaluation of Agreement between Measurement Methods from Data with Matched Repeated Measurements via the Coefficient of Individual Agreement. *Journal of data science: JDS* 2010;8(3):457-69.
- 22 Koo TK, Li MY. A Guideline of Selecting and Reporting Intraclass Correlation Coefficients for Reliability Research. *Journal of Chiropractic Medicine* 2016;15(2):155-63.
- 23 Shrout PE, Fleiss JL. Intraclass correlations: uses in assessing rater reliability. *Psychological bulletin* 1979;86(2):420-8.
- 24 Bland JM, Altman DG. Measuring agreement in method comparison studies. *Statistical methods in medical research* 1999;8(2):135-60.
- 25 Bland JM, Altman DG. Statistical methods for assessing agreement between two methods of clinical measurement. *Lancet (London, England)* 1986;1(8476):307-10.
- 26 Carstensen B, Simpson J, Gurrin LC. Statistical models for assessing agreement in method comparison studies with replicate measurements. *Int J Biostat* 2008;4(1):Article 16.
- 27 Klonoff DC. The need for clinical accuracy guidelines for blood glucose monitors. *Journal of diabetes science and technology* 2012;6(1):1-4.
- 28 Little TA. Establishing Acceptance Criteria for Analytical Methods. *ADVANTAR Communications Inc 131 w 1st street, Duluth, MN 55802 USA; 2016.*
- 29 Robertson SA, Kimble RM, Storey KJ, et al. 3D photography is a reliable method of measuring infantile haemangioma volume over time. *Journal of Pediatric Surgery* 2016;51(9):1552-56.
- 30 Seymour L, Bogaerts J, Perrone A, et al. iRECIST: guidelines for response criteria for use in trials testing immunotherapeutics. *Lancet Oncol* 2017;18(3):e143-e52.
- 31 Hodi FS, Hwu WJ, Kefford R, et al. Evaluation of Immune-Related Response Criteria and RECIST v1.1 in Patients With Advanced Melanoma Treated With Pembrolizumab. *J Clin Oncol* 2016;34(13):1510-7.

CHAPTER 3

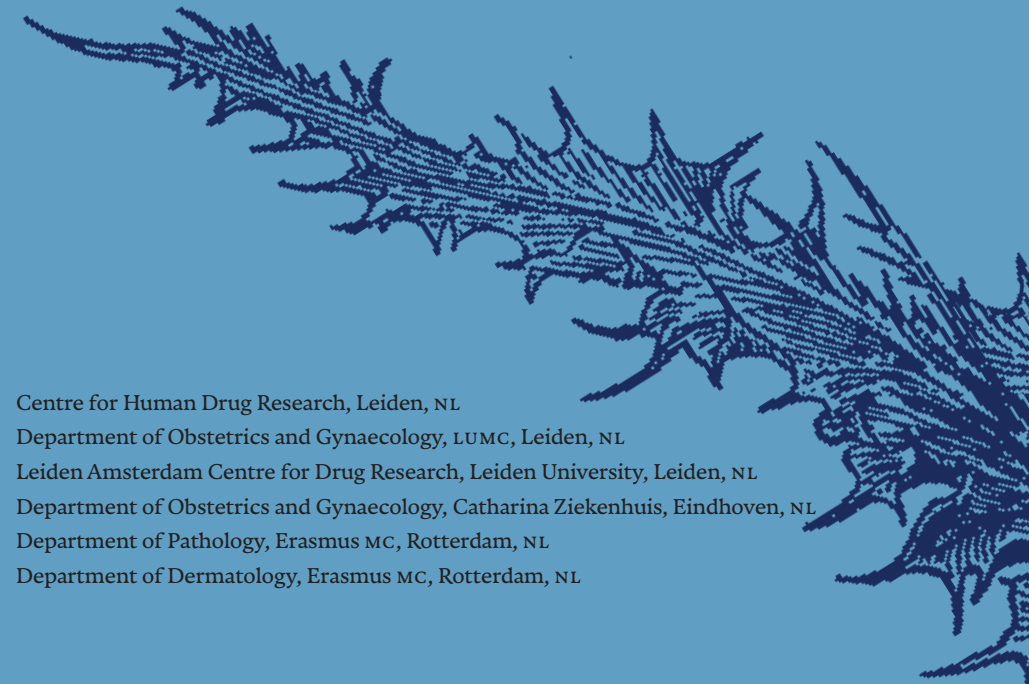# Dermatoscopy and optical coherence tomography in vulvar HSIL and lichen sclerosus: a prospective observational trial

*Published in Journal of Lower Genital Tract Disease, 2023, Doi: 10.1097/LGT.0000000000000731*

Lisa Pagan,<sup>1,2\*</sup> Bertine W. Huisman,<sup>1,2\*</sup> Rosanne G.C. Naafs,<sup>1</sup> Wouter ten Voorde,<sup>1</sup> Prof. Robert Rissmann,<sup>1,2,3</sup> Jurgen M.J. Piek,<sup>4</sup> Jeffrey Damman,<sup>5</sup> Maria J. Juachon,<sup>1</sup> Michelle Osse,<sup>1</sup> Tessa Niemeyer-van der Kolk,<sup>1</sup> Colette L.M. van Hees<sup>1</sup> and Mariëtte I.E. van Poelgeest<sup>1,2</sup>

*\* These authors share first authorship*

- 1 Centre for Human Drug Research, Leiden, NL
- 2 Department of Obstetrics and Gynaecology, LUMC, Leiden, NL
- 3 Leiden Amsterdam Centre for Drug Research, Leiden University, Leiden, NL
- 4 Department of Obstetrics and Gynaecology, Catharina Ziekenhuis, Eindhoven, NL
- 5 Department of Pathology, Erasmus MC, Rotterdam, NL
- 6 Department of Dermatology, Erasmus MC, Rotterdam, NL



## Abstract

**OBJECTIVE** To examine potential discriminatory characteristics of dermatoscopy and dynamic optical coherence tomography (D-OCT) on vulvar high-grade squamous intraepithelial lesions (VHSIL) and lichen sclerosus (LS) compared to healthy vulvar skin.

**METHODS** A prospective observational clinical trial was performed in 10 healthy volunteers, 5 VHSIL and 10 LS patients. Non-invasive imaging measurements using dermatoscopy and D-OCT were obtained at several time-points, including lesional and non-lesional vulvar skin. Morphologic features of VHSIL and LS were compared to healthy controls. Epidermal thickness and blood flow were determined using D-OCT. Patients reported tolerability of each study procedure, including reference vulvar biopsies. The main outcome measures were Feasibility and tolerability of imaging modalities, dermatoscopy and OCT characteristics, OCT epidermal thickness and D-OCT dermal blood flow.

**RESULTS** The application of dermatoscopy and D-OCT is feasible and tolerable. In VHSIL, dermatoscopic warty structures were present. In LS, sclerotic areas and arborizing vessels were observed. Structural OCT in the vulvar area aligned with histology for hyperkeratosis and dermal-epidermal junction visualisation. Currently, the OCT algorithm is unable to calculate the epidermal thickness of the uneven vulvar area. D-OCT showed statistically significant increased blood flow in LS patients (mean  $\pm$ SD 0.053  $\pm$ 0.029) to healthy controls (0.040  $\pm$ 0.012,  $p=0.0024$ ).

**CONCLUSIONS** The application of dermatoscopy and D-OCT is feasible and tolerable in VHSIL and LS patients. Using dermatoscopy and D-OCT, we describe potential characteristics to aid differentiation of diseased from healthy vulvar skin, which could complement clinical assessments.

## Introduction

Inadequate clinical recognition and delayed or inadequate treatment of vulvar high-grade intraepithelial lesions (VHSIL) and lichen sclerosus (LS) can have considerable physical, sexual and psychological impact.<sup>1</sup> The diagnostic process and disease follow-up of these vulvar diseases should be improved by objective and non-invasive, disease-specific biomarkers.<sup>2</sup> A prerequisite in biomarker validation is its ability to discriminate healthy from diseased tissue.<sup>3</sup>

Examples of potential novel techniques are dermatoscopy and dynamic optical coherence tomography (D-OCT). Dermatoscopy is routinely applied by dermatologists as adjunctive tool to ameliorate subsurface structure visualization and pattern identification to aid diagnosis of melanoma, basal cell carcinoma and other cutaneous disorders.<sup>4</sup> Its application on the vulvar area is currently limited to research purposes of vulvar pigmented lesions.<sup>5-7</sup> D-OCT is a non-invasive imaging technique that provides real-time cross-sectional images of biological structures. It has been incorporated in the daily ophthalmology practice for diagnosis of retinal diseases.<sup>8</sup> D-OCT has been applied as a research tool in dermatology for characterisation of non-melanoma skin cancer.<sup>9,10</sup> In gynaecology, a few studies in cervical, vulvar and ovarian tissue suggest potential for D-OCT to differentiate between healthy and (pre)malignant tissue of epithelial origin.<sup>11-14</sup>

The study objective was to examine and describe potential discriminatory characteristics of dermatoscopy and D-OCT on premalignant vulvar skin compared to healthy vulvar skin. Therefore, we examined dermatoscopy and D-OCT on VHSIL and LS patients and healthy controls.

## Methods

A prospective, healthy volunteer-matched, single-centre trial conducted at the Centre for Human Drug Research, Leiden, The Netherlands, was performed from February 2021 to October 2021. The Declaration of Helsinki was the guiding principle for trial execution. The study was approved by an independent medical-ethics committee 'Medisch-Ethische Toetsingscommissie Leiden Den Haag Delft' and registered in 'Nederlands Trial Register' (NL73964.058.20) and 'EudraCT' (2020-002201-2). All subjects provided written informed consent before participation. These imaging results are part

of a multi-modal pilot study investigating research methods to identify biomarkers that could improve vulvar disease identification and therapeutic response monitoring (*Figure S1*).<sup>15</sup>

## STUDY DESIGN AND SUBJECTS

In total, 25 women, aged 25-95 with a body mass index (BMI) <30 kg/m<sup>2</sup> were included: 5 VHSIL patients (≥1 sharply margined histologically confirmed VHSIL lesion ≥15mm), 10 LS patients (clinical and/or histological diagnosis confirmation) and 10 healthy controls (confirmed absence of vulvar disease). Main exclusion criteria were significant other diseases, pregnancy, other vulvar conditions, immunocompromised state, sexually transmitted disease, AIDS or hepatitis. For standardization, wash-out for topically applied products on the vulvar area was ≥14 days.<sup>16</sup>

All subjects visited the clinical research department on Day 0 (oh = baseline, 3h and 6h), Day 1 and Day 7 (*Figure S2*). LS patients also visited the clinic on Day 21 and 35, as follow-up for a 4-week standard of care treatment with corticosteroid ointment clobetasol 0.05% (Dermovate, GlaxoSmithKline, Brentford, United Kingdom) starting at Day 8. At each visit, clinical assessments and non-invasive imaging measurements were performed. Biopsies were obtained at Day 0 for all subjects and on Day 35 for LS patients.

## ANOGENITAL EXAMINATION

Examination of the anogenital region and study procedures were performed in a gynaecological chair. All patients were assessed by trained physicians (BH and LP) and discussed with an oncological gynaecologist specialized in vulvar disease (MVP) at baseline. Although LS has a heterogeneous clinical presentation, we opted out of further stratification due to low patient numbers and the exploratory scope of our study. All procedures were performed on selected target areas, including a lesional and non-lesional site for all patients.

## IMAGING

### *Dermatoscopy on the vulvar area*

Macroscopic dermatoscopic images of the vulvar surface were obtained using a FotoFinder Medicam 1000 with the Bodystudio ATBM (FotoFinder Systems GmbH, Bad Birnbach, Germany) for photo analysis and documentation (*Figure S3*). Microscopic images were obtained with a D-Scope IV dermatoscopy lens with polarized light and analysed using FotoFinder universe. Dermatoscopy includes a follow-up photo documentation function.

## Microscopic characteristics

Individual dermatoscopic characteristic or a set of characteristics were exploratorily assessed for discriminatory potential for vulvar diseases. An expert dermatologist fully blinded for patient type (CH) scored characteristics in decoded microscopic images. The characteristics included: colour of the skin (red, pink, yellow, grey, brown, white or other); vessel density or concentration (increased, normal, decreased or invisible) and vessel concentration (dotted, hairpin, linear, linear serpentine, thin/thick arborizing, thick root-like, other or not visible). The presence or absence of scales, ecchymoses, purpura, yellow-white structureless areas, white circles, peppering, comedo-like openings, ulceration and warty structures were reported, as previously described in literature of dermatoscopy characteristics of genital lesions.<sup>17,18</sup> In total, 85 photos were scored (15 VHSIL, 40 LS and 30 healthy volunteers) obtained at Day 0, 7 and 35.

## D-OCT

Skin morphology analysis up to a depth of 1 mm was performed by D-OCT using the Vivosight Dx (Michelson Diagnostics Ltd., United Kingdom) (*Figure S4*). Scans with artefacts due to movement were excluded from analysis and directly retaken. Data were stored and analysed using VivoSight and VivoTools version 4.15. Qualitative assessments were performed by three trained OCT operators (BH, LP and WV).

## EPIDERMAL THICKNESS

Epidermal thickness was determined using algorithms incorporated in the software. Manual epidermal thickness analyses were performed with ImageJ (version Java 1.8.0\_172, Bethesda, Maryland, USA). Using a self-generated macro, three consecutive vertical lines were drawn for the epidermal layer per scan. The mean, SD, minimum and maximum epidermal thickness were determined per set of 120 consecutive scans per patient. Baseline and post-treatment (LS) scans were analysed manually for epidermal thickness due to the exploratory and time-consuming nature of manual calculations.

## BLOOD FLOW

D-OCT blood flow was determined using the algorithms incorporated in the software. The quantification of the blood flow was based on the average speckle signal returning at the detector at dermal depth from 0.10 to 0.35 mm to reduce contortions from artefacts.<sup>19</sup>

### **Histological analysis**

Vulvar tissue samples were obtained using a 4mm punch biopsy acquired by trained physicians (BH, LP and MVP) at the end of Day 0. The skin was anesthetised using subcutaneous lidocaine prior to the procedure. The obtained biopsies were stained for hematoxylin and eosin (H&E) by the Erasmus Medical Centre (EMC, Rotterdam, The Netherlands) following clinical protocols. Slides were scored by a dermatopathologist (JD). Dysplasia was assessed by the epidermal levels of atypia and scored as warty and/or basaloid types. LS was diagnosed by histological characteristics.<sup>20,21</sup> Inno-LiPa HPV Genotyping Extra (Eurofins NMDL-LCPL, Rijswijk, The Netherlands) was used for HPV typing.<sup>22</sup>

### **Patient reported outcomes**

The 'burdensome questionnaire' comprised of 100 mm lines which the patient completed for each study procedure, ranging 0 mm 'no burden at all' to 100 mm 'the most burdensome procedure possible'. The e-diary (Promasys® EPRO platform) with a reminder and photograph function (with corresponding timestamps) monitored at-home drug compliance.

### **Statistical analysis**

Dermatoscopic observations were summarized and shown descriptively. Differences of D-OCT between patient groups were tested using Mann-Whitney U Test on baseline averages of two groups (VHSIL, LS or healthy). A paired, two-tailed t-test was performed comparing mean D-OCT values pre- to post-treatment. Differences for the burdensome questionnaire were analysed using a paired student's t-test comparing dermatoscopy and D-OCT to the biopsy procedure. The analyses were computed in SAS 9.4 and GraphPad version 9.3.1.

## **Results**

In total, 25 women (5 patients with VHSIL and 10 patients with LS and 10 healthy controls) were enrolled and finished the study (Table S1). Fitzpatrick skin-type ranged from I-III. Menopausal status was equally distributed among groups.

## **DERMATOSCOPY**

Vulvar skin of a representative subject of each cohort (VHSIL, LS and healthy controls) captured by dermatoscopy is presented in a macroscopic overview and a microscopic image (Figure S5)

### **Microscopic characteristics**

Examples of dermatoscopic characteristics are shown in Figure 1 and the frequency of observations per group are summarized in Figure 2. The most prominent characteristic of VHSIL were warty structures (4/5), which could be accompanied by some scales and peppering. The colour of VHSIL skin was highly variable. Women with Fitzpatrick skin-type >III were could not be recruited, so colour findings may vary based on the analysed population. Vessels were present with dotted or linear vessel. LS typically showed white structureless areas (8/10) and/or increased vessel concentration (8/10), with arborizing and/or thick root-like vessel morphology. The vulvar skin of healthy controls was mostly yellow (8/10), with normal vessel pattern of dotted or linear vessels, sometimes accompanied by white circles (4/10). Occasionally white structureless areas or peppering was observed (3/10). No changes were observed in LS skin after 4-week clobetasol treatment (data not shown).

## **D-OCT**

### **Morphological characteristics**

VHSIL is histologically characterized by hyperkeratosis and parakeratosis, acanthosis with club-shaped rete ridges, cytonuclear atypia, disorientation of individual epithelial cells and an intact basement membrane.<sup>23</sup> Hyperkeratosis could be identified in the structural OCT image of a VHSIL lesion as hyperreflective stratum corneum. OCT shows the broadening of the epidermis in the club-shaped pattern associated with acanthotic VHSIL with an intact dermal-epidermal junction, as observed in histology (Figure 3A). LS is histologically characterized by hyperkeratosis, epidermal thinning with loss of the rete ridge pattern and dermal changes, including sclerosis.<sup>20,21</sup> These changes can also be identified with OCT, especially the disorganized extracellular matrix reflecting dermal changes (Figure 3B). Nuclear and cellular changes cannot be visualized using OCT. We observed that resolution

was occasionally lost under a hyperkeratotic and hyperreflective stratum corneum or sclerotic area. These OCT findings are pronounced in VHSIL and LS compared to healthy vulvar skin. Histologically, healthy vulvar skin has a normal epidermal thickness in the absence of characteristics observed in diseased vulvar skin. These features could also be visualized in OCT recordings (Figure 3C).

### Epidermal thickness

In total 77.5% (VHSIL), 56.9% (LS) and 91.2% (healthy control) of the measurements using the incorporated algorithm failed, as an impossible epidermal thickness of 0  $\mu\text{m}$  was reported. Therefore, manual epidermal thickness measurements were performed (Figure 4A+B). No significant differences in epidermal thickness were identified comparing lesional or non-lesional VHSIL to healthy controls. The epidermis (mean $\pm$ SD) of pre-clobetasol lesional LS (0.13 $\pm$ 0.10  $\mu\text{m}$ ) was significantly thinner compared to healthy controls (0.19 $\pm$ 0.06  $\mu\text{m}$ ),  $p=0.0312$ . No differences were observed between pre- and post-clobetasol-treated LS (0.127 $\pm$ 0.10  $\mu\text{m}$  vs 0.118 $\pm$ 0.034,  $p=0.643$ ).

### Blood flow

At baseline, higher blood flow (mean $\pm$ SD) was observed in non-lesional VHSIL (0.063  $\pm$ 0.040) compared to lesional VHSIL (0.044 $\pm$ 0.025),  $p=0.0255$  (Figure 4C). No differences were detected between lesional VHSIL and healthy controls (0.040 $\pm$ 0.017,  $p=0.347$ ). Blood flow in non-lesional VHSIL skin differed significantly from healthy controls (0.063 $\pm$ 0.040,  $p=0.0001$ ). Blood flow was significantly higher in pre-treatment lesional LS (0.053 $\pm$ 0.029) compared to non-lesional LS (0.034 $\pm$ 0.019,  $p<0.0001$ ) and healthy controls (0.040 $\pm$ 0.012,  $p=0.0024$ ) (Figure 4D). Non-lesional LS did not differ significantly compared to healthy controls ( $p=0.077$ ). No differences were observed between pre- and post-clobetasol-treated LS (0.057 $\pm$ 0.042) ( $p=0.532$ ). Blood flow measurements fluctuated over time (Day 0, 2, 8, 22 and 36), depending on sample location (lesional vs non-lesional) (Figure S6).

## HISTOLOGICAL ANALYSIS

All clinical diagnoses of non-lesional and lesional skin of VHSIL, non-lesional LS and healthy controls were confirmed in biopsy (Table S2). The biopsies of lesional LS were classified as LS in 3/10 cases. The remaining were classified as normal vulvar skin with inflammatory reactive changes, although clinical

LS diagnosis had been confirmed by a specialized gynaecologist (MVP) prior to enrolment. Positivity for HPV type 16 was identified in 4/5 lesional VHSIL biopsies. One lesional LS biopsy tested positive for HPV type 53, while no HPV was found in non-lesional or healthy control biopsies.

### Patient-friendliness and treatment compliance

All imaging methods applied in this study were considered mildly burdensome and therefore patient friendly. Vulvar biopsy was considered substantially more burdensome than all non-invasive imaging procedures, with mean scores  $>20$  mm (Figure S7). Treatment compliance was 99%.

## Discussion

This exploratory study shows that application of dermatoscopy and D-OCT is feasible and tolerable in VHSIL and LS patients. The most prominent finding with dermatoscopy was presence of sclerotic areas and arborizing vessels in LS and warty structures for VHSIL. Structural OCT images could be aligned for both diseases with histology. A novel finding in this study was the increased blood flow measured by the algorithm of the D-OCT in vulvar LS compared to healthy tissue. Epidermal thickness determination by OCT should be considered for research purposes only at this stage.

The main strength is the prospective trial design in vulvar patients and healthy controls including within-subject lesional and non-lesional control. Including only within-patient 'healthy' control sites can be invalid, as the vulvar tissue may be affected by scarring, immune cell infiltration or treatment effects. The study was carried out in a clinical research facility that allowed for standardized image and measurement acquisition (i.e. light conditions and operators) in a structured manner, allowing for side-by-side comparisons of techniques. The dermatoscopic follow-up functionality allowed for exact traceability of location throughout the study (Figure S3) and the biopsy location aligned with the obtained non-invasive measurements.

Performing a data-rich pilot trial in vulvar disease has inherently resulted in a modest sample size. Unfortunately, not all intended VHSIL and no vulvar squamous cell carcinoma (VSCC) patients could be recruited, mainly due to the short and emotionally intense period between diagnosis and timely scheduled treatment. This pilot trial had intended to include VSCC patients to portray the complete pathway from healthy vulvar skin to VSCC.

This statement could be expanded to all patients visiting the vulvar consultation office with a variety of vulvar diseases, including differentiated vulvar intraepithelial neoplasia (DVIN), as the possible discriminative nature of promising characteristics should be validated in a practical sample. In addition, to contribute a diverse and representative study population, the field should aim to include women with all Fitzpatrick skin-types, as dermatoses can be phenotypically distinct on darker skin types than those included in this patient sample. Finally, 7/10 histological assessments of LS were incongruent with the clinical diagnosis. This discrepancy is not considered a limitation, as LS is primarily a clinical diagnosis, but highlights the heterogeneity of this vulvar disease. LS can present heterogeneously in the clinic (with atrophy, fibrosis or inflammation). This clinical, morphological, and histological variability could influence the findings of our study and should be considered in further interpretations.

Dermatoscopy is an integrative part of the dermatologists' evaluation of potentially malignant cutaneous lesions.<sup>4</sup> However, the evaluation of vulvar disease using sophisticated imaging devices is uncommon in daily vulvar clinic or gynaecological practice. An expanding catalogue of reports describe dermatoscopy for vulvar lesions, but a well-established and structured approach of image acquisition and reporting remains lacking.<sup>5,6,24,25</sup> Observations in intraepithelial neoplasia have been summarized in a recent review, although the overview does not include stratification for sex or disease subtypes (i.e. vHSIL or HPV-independent DVIN).<sup>26</sup> The currently recognized characteristics include red to white structureless areas in addition to presence of dotted, glomerular and linear vessels. Grey-brownish dots have been described in pigmented intraepithelial neoplasia lesions. Our dermatoscopy results in vHSIL concur with literature, although the modest patient population restricts further comparisons. Features identified in vHSIL could also be found in LS or healthy controls, rendering none of the identified characteristics disease specific. The only distinctive feature in our study were warty structures in vHSIL, but this adds little clinical value as this is clear upon visual inspection. Plus, many vulvar diagnoses may present as warty structures, such as condylomata acuminata or papillomatosis.<sup>12</sup>

On D-OCT, we found an increased blood flow in non-lesional vHSIL compared to healthy vulvar skin. This observation may be due to a more extensively inflamed vulvar area, besides the clinically observable vHSIL lesion(s). This implies that non-lesional, apparently healthy, vulvar skin of

vHSIL patients should not be considered a valid healthy control, i.e. within-patient controls can cause potential confounding. The same notion applies for non-lesional LS skin, which can appear without clinical signs of LS but in fact may comprise of pre-clinical diseased vulvar skin. Our conclusions may have been influenced by the small cohort and potential artefacts from warty lesional structures on the blood flow measurements. Histologically, acanthosis is a well-known feature vHSIL.<sup>23</sup> Structural OCT analysis non-invasively found a thicker epidermis for lesional vHSIL than healthy vulvar skin, as reported once previously.<sup>12</sup> However, the OCT software algorithm is inadequate for epidermal thickness measurements, most likely due to anatomically irregular vulvar structures. Unfortunately, manual measurements are too time-consuming. Improvement of the software algorithm for vulvar skin would be required to make this OCT parameter applicable for practical implementation.

Several reports have described dermatoscopic features of LS.<sup>17,25,27,28</sup> A recent review summarized dermatoscopic features of LS, which reportedly appears with structureless areas, red globules in a white background with a decrease, or *desertification*, of vessels.<sup>26</sup> Our observations are in line with these results, with the notable exception with regard to vascular changes in a number of cases. We found more pronounced vasculature primarily consisting of thick and thin arborizing vessels in approximately 40% of LS cases. Generally, these patients presented clinically with a loss of vulvar architecture. Literature is yet undecided whether dermatoscopic vascular patterns could correlate to disease duration.<sup>18,27</sup>

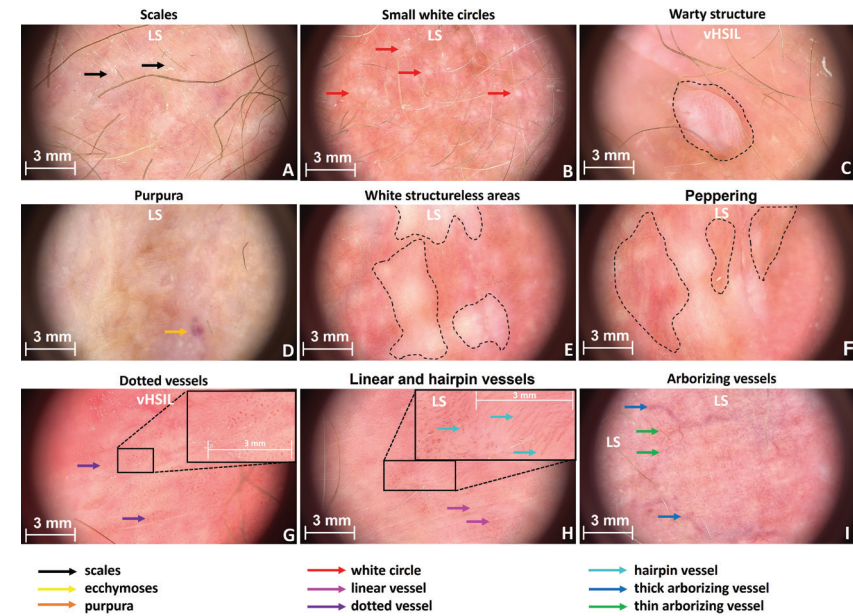
These newly described dermatoscopic thick and thin arborizing vessels concur with established histological features of hyalinized, stiff vessels in the dermis of LS.<sup>20,21</sup> These stiff vessels translated into the observed increase in blood flow in lesional LS vulvar skin, as measured by D-OCT. We hypothesize that this could be the result of sclerosis and damage to the connective tissue in LS, affecting the microvasculature of the dermis.<sup>29</sup> The observed increase in dermal blood flow in genital LS has not previously been objectified by D-OCT, but are in agreement with previous descriptions using Laser Doppler and in three patients with extragenital LS.<sup>30,31</sup> Histologically, the vulvar epidermis in LS is thinner compared to healthy vulvar skin.<sup>21</sup> We confirm epidermal thinning in LS numerically and morphologically using non-invasive structural OCT measurements.

## Conclusion

This study describes a structured, prospective approach to identify sophisticated imaging methods for vHSIL and LS. Using dermatoscopy and D-OCT, we described potential characteristics to aid differentiation of diseased from healthy vulvar skin. Dermatoscopy is a promising tool that may facilitate clinical recognition and follow-up of vHSIL and LS after expansion of patient groups and clinical validation. Vulvar biopsies can be obtained on a limited basis, whilst non-invasive techniques can be used repeatedly, minimizing patient burden. The step to clinical integration of D-OCT is considered inappropriate at this stage due to the suboptimal algorithms and remaining questions on the applicability in clinical practice. Imaging techniques should always be preceded by visual examination to establish a clinical differential diagnosis. Our findings require confirmation in larger, more diverse cohorts including suspicious lesions of the vulva over time before implementation in the vulvar clinic.

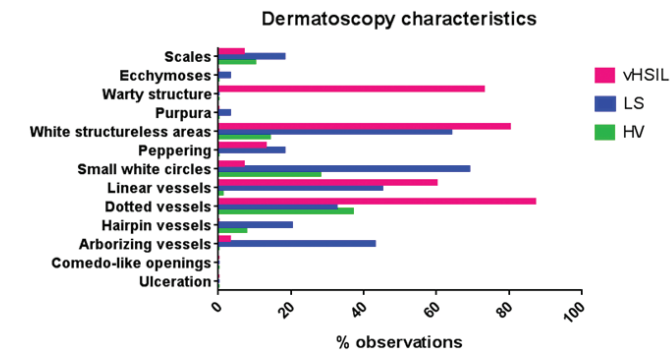
**Figure 1** Representative images showing examples of scored characteristics.

A) Scales (LS) B) Small white circles (LS) C) Warty structure (vHSIL) D) Purpura (LS) E) White structureless areas (LS) F) Peppering (LS) G) Dotted vessels (vHSIL) H) Linear and hairpin vessels (LS) I) Thick and thin arborizing vessels (LS).



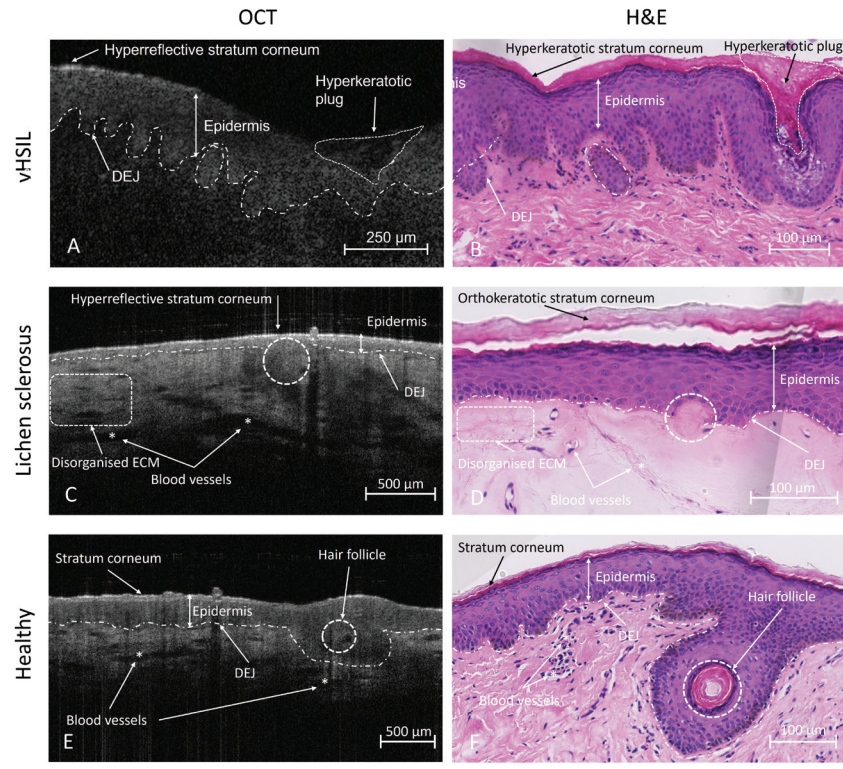
vHSIL=vulvar high-grade squamous intraepithelial lesion, LS=lichen sclerosus

**Figure 2** Percentage of observed characteristics per patient group. 85 photos were scored (15 vHSIL, 40 LS and 30 HV) from the scoring of microscopic dermatoscopy images by a blinded dermatologist (CH).



vHSIL=vulvar high-grade squamous intraepithelial lesion, LS=lichen sclerosus, HV=healthy volunteers

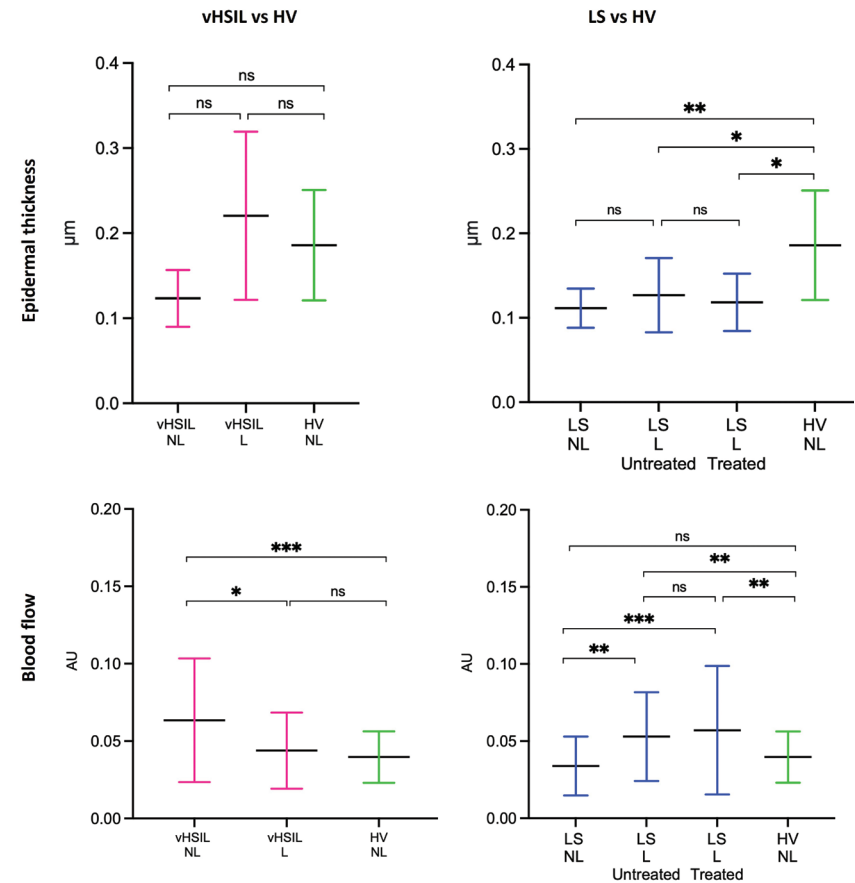
**Figure 3** Structural OCT recordings compared to aligned histological assessments of A+B) vHSIL, C+D) lichen sclerosus and E+F) healthy volunteers. Asterisks (\*) indicate blood vessels.



OCT=optical coherence tomography, H&E=hematoxylin and eosin, vHSIL=vulvar high-grade squamous intraepithelial lesion; DEJ=dermal-epidermal junction; ECM=extracellular matrix

**Figure 4** D-OCT epidermal thickness measurements (manually determined using ImageJ) and blood flow measurements (determined by incorporated algorithm).

Measurements were assessed at baseline (D1H0) and, for LS only, post-treatment (D35). The mean and standard deviations are displayed for each group. A) Epidermal thickness in  $\mu\text{m}$  (y-axis) is plotted against measurements clustered per patient group (x-axis). B) The average blood flow measured between a skin depth of 0.10-0.35  $\mu\text{m}$  at non-biopsy sites of vHSIL and LS subjects compared to healthy controls. The mean and standard deviations are displayed for each group, as well as individual data points. Blood flow in AU (y-axis) plotted against measurements clustered per patient group (x-axis).



ns= $p > 0.05$ , \*= $p \leq 0.05$ , \*\*= $p \leq 0.01$ , \*\*\*= $p \leq 0.001$ , \*\*\*\*= $p \leq 0.0001$ . vHSIL=vulvar high-grade squamous intraepithelial lesion, LS=lichen sclerosus, HV=healthy volunteers. L=lesional and NL=non-lesional skin.

## SUPPLEMENTS CHAPTER 3

Supplemental data can be accessed online at:

[https://journals.lww.com/jlgted/Fulltext/9900/Dermatoscopy\\_and\\_Optical\\_Coherence\\_Tomography\\_in.48.aspx](https://journals.lww.com/jlgted/Fulltext/9900/Dermatoscopy_and_Optical_Coherence_Tomography_in.48.aspx)

Supplementary Table 1	Baseline Characteristics
Supplementary Table 2	Histology overview
Supplementary Figure 1	Vulva flower multimodal study
Supplementary Figure 2	Clinical study design
Supplementary Figure 3	Dermatoscopy
Supplementary Figure 4	OCT
Supplementary Figure 5	Example dermatoscopy per disease entity
Supplementary Figure 6	Blood flow over time
Supplementary Figure 7	Patient burden scores



## REFERENCES

1. Lockhart J, Gray N, Cruickshank M. The development and evaluation of a questionnaire to assess the impact of vulval intraepithelial neoplasia: a questionnaire study. *BJOG-An Int J Obstet Gynaecol*. 2013;120(9):1133-1143. doi:10.1111/1471-0528.12229
2. Jamieson A, Tse SS, Proctor L, Sadownik LA. A Scoping Review of Treatment Outcome Measures for Vulvar Intraepithelial Neoplasia. *J Low Genit Tract Dis*. 2022;26(4):328-338. doi:10.1097/LGT.0000000000000698
3. Kruizinga MD, Stuurman FE, Exadaktylos V, et al. Development of Novel, Value-Based, Digital Endpoints for Clinical Trials: A Structured Approach Toward Fit-for-Purpose Validation. *Pharmacol Rev*. 2020;72(4):899-909. doi:10.1124/PR.120.000028
4. Ring C, Cox N, Lee JB. Dermatoscopy. *Clin Dermatol*. 2021;39(4):635-642. doi:10.1016/J.Clndermatol.2021.03.009
5. Ronger-Savle S, Julien V, Duru G, Raudrant D, Dalle S, Thomas L. Features of pigmented vulval lesions on dermatoscopy. *Br J Dermatol*. 2011;164(1):54-61. doi:10.1111/J.1365-2133.2010.10043.X
6. Ferrari A, Zalaudek I, Argenziano G, et al. Dermatoscopy of pigmented lesions of the vulva: a retrospective morphological study. *Dermatology*. 2011;222(2):157-166. doi:10.1159/000323409
7. Cengiz FP, Emiroglu N, Hofmann Wellenhof R. Dermoscopic and clinical features of pigmented skin lesions of the genital area. *An Bras Dermatol*. 2015;90(2):178-183. doi:10.1590/ABD1806-4841.20153294
8. Fujimoto J, Swanson E. The Development, Commercialization, and Impact of Optical Coherence Tomography. *Invest Ophthalmol Vis Sci*. 2016;57(9):OCT1-OCT13. doi:10.1167/iovs.16-19963
9. Marschall S, Sander B, Mogensen M, Jørgensen TM, Andersen PE. Optical coherence tomography-current technology and applications in clinical and biomedical research. *Anal Bioanal Chem*. 2011;400(9):2699-2720. doi:10.1007/S00216-011-5008-1
10. Wan B, Ganier C, Du-Harpur X, et al. Applications and future directions for optical coherence tomography in dermatology. *Br J Dermatol*. 2021;184(6):1014-1022. doi:10.1111/BJD.19553
11. Escobar PF, Belinson JL, White A, et al. Diagnostic efficacy of optical coherence tomography in the management of preinvasive and invasive cancer of uterine cervix and vulva. *Int J Gynecol Cancer*. 2004;14(3):470-474. doi:10.1136/IJGC-00009577-200405000-00008
12. Wessels R, Bruin DM de, Faber DJ, et al. Optical coherence tomography in vulvar intraepithelial neoplasia. <https://doi.org/10.1117/1JBO.17.11.116022>. 2012;17(11):116022. doi:10.1117/1JBO.17.11.116022
13. Xu L, Ma Q, Lin S, et al. Study on the application and imaging characteristics of optical coherence tomography in vulva lesions. *Sci Rep*. 2022;12(1):3659. doi:10.1038/S41598-022-07634-1
14. Kirillin M, Motovilova T, Shakhova N. Optical coherence tomography in gynecology: a narrative review. *J Biomed Opt*. 2017;22(12):1. doi:10.1117/1.JBO.22.12.121709
15. Rissmann R, Moerland M, van Doorn MBA. Blueprint for mechanistic, data-rich early phase clinical pharmacology studies in dermatology. *Br J Clin Pharmacol*. Published online 2020. doi:10.1111/bcp.14293
16. Hehir M, Vivier A DU, Eilon L, Danie MJ, Shenoy EVB. Investigation of the pharmacokinetics of clobetasol propionate and clobetasone butyrate after a single application of ointment. *Clin Exp Dermatol*. 1983;8(2):143-151. doi:10.1111/j.1365-2230.1983.tb01758.x
17. Borghi A, Corazza M, Minghetti S, Bianchini E, Virgili A. Dermoscopic Features of Vulvar Lichen Sclerosus in the Setting of a Prospective Cohort of Patients: New Observations. *Dermatology*. 2016;232(1):71-77. doi:10.1159/000439198
18. Borghi A, Virgili A, Corazza M. Dermoscopy of Inflammatory Genital Diseases: Practical Insights. *Dermatol Clin*. 2018;36(4):451-461. doi:10.1016/J.DET.2018.05.013
19. Themstrup L, Welzel J, Ciardo S, et al. Validation of Dynamic optical coherence tomography for non-invasive, in vivo microcirculation imaging of the skin. *Microvasc Res*. 2016;107:97-105. doi:10.1016/j.mvr.2016.05.004
20. Morrel B, Ewing-Graham PC, van der Avoort IAM, Pasmans SGMA, Damman J. Structured analysis of histopathological characteristics of vulvar lichen sclerosus in a juvenile population. *Hum Pathol*. 2020;106:23-31. doi:10.1016/j.humphath.2020.09.003
21. Regauer S, Liegl B, Reich O. Early vulvar lichen sclerosus: a histopathological challenge. *Histopathology*. 2005;47(4):340-347. doi:10.1111/J.1365-2559.2005.02209.X
22. Xu L, Padalko E, Östbränka A, Poljak M, Arbyn M. Clinical Evaluation of inno-lipa HPV genotyping extra II assay using the valgent Framework. *Int J Mol Sci*. 2018;19(9). doi:10.3390/IJMS19092704
23. Hoang LN, Park KJ, Soslow RA, Murali R. Squamous precursor lesions of the vulva: current classification and diagnostic challenges. *Pathology*. 2016;48(4):291-302. doi:10.1016/j.pathol.2016.02.015
24. Oakley A. Dermatoscopic features of vulval lesions in 97 women. *Australas J Dermatol*. 2016;57(1):48-53. doi:10.1111/ajd.12298
25. Corazza M, Borghi A, Minghetti S, Ferron P, Virgili A. Dermoscopy of isolated syringoma of the vulva. *J Am Acad Dermatol*. 2017;76(2):S37-S39. doi:10.1016/J.JAAD.2016.06.009
26. Lacarrubba F, Borghi A, Verzi AE, Corazza M, Stinco G, Micali G. Dermoscopy of genital diseases: a review. *J Eur Acad Dermatol Venereol*. 2020;34(10):2198-2207. doi:10.1111/jdv.16723
27. Larre Borges A, Todorovic-Zivkovic D, Lallas A, et al. Clinical, dermoscopic and histopathologic features of genital and extragenital lichen sclerosus. *J Eur Acad Dermatol Venereol*. 2013;27(11):1433-1439. doi:10.1111/j.1468-3083.2012.04595.x
28. Shim W-H, Jwa S-W, Song M, et al. Diagnostic usefulness of dermatoscopy in differentiating lichen sclerosus et atrophicus from morphea. *J Am Acad Dermatol*. 2012;66(4):690-691. doi:10.1016/j.jaad.2011.06.042
29. Sirotkina MA, Potapov AL, Vagapov NN, et al. Multimodal optical coherence tomography: Imaging of blood and lymphatic vessels of the vulva. *Sovrem Tehnol v Med*. 2019;11(4):26-31. doi:10.17691/STM2019.11.4.03
30. Saravanamuthu J, Seifalian AM, Reid WM, Maclean AB. A new technique to map vulva microcirculation using laser Doppler perfusion imager. *Int J Gynecol Cancer*. 2003;13(6):812-818. doi:10.1111/J.1525-1438.2003.13047.X
31. Ring HC, Mogensen M, Hussain AA, et al. Imaging of collagen deposition disorders using optical coherence tomography. *J Eur Acad Dermatol Venereol*. 2015;29(5):890-898. doi:10.1111/jdv.12708

# Reflectance confocal microscopy as a non-invasive imaging tool in vulvar high grade squamous intraepithelial lesions and lichen sclerosus: a descriptive morphological study in patients and healthy volunteers

*Published in Experimental Dermatology, 2023. Doi: 10.1111/exd.14888*

Bertine W. Huisman,<sup>1,2</sup> Lisa Pagan,<sup>1,2</sup> Martina Ulrich,<sup>3</sup> Robert Rissmanni,<sup>2,4</sup> Jeffrey Damman,<sup>5</sup> Jurgen M.J. Piek,<sup>6</sup> Tessa Niemeyer-van der Kolk<sup>1</sup> and Mariëtte I.E. van Poelgeest<sup>1,2</sup>

---

1 Centre for Human Drug Research, Leiden, NL

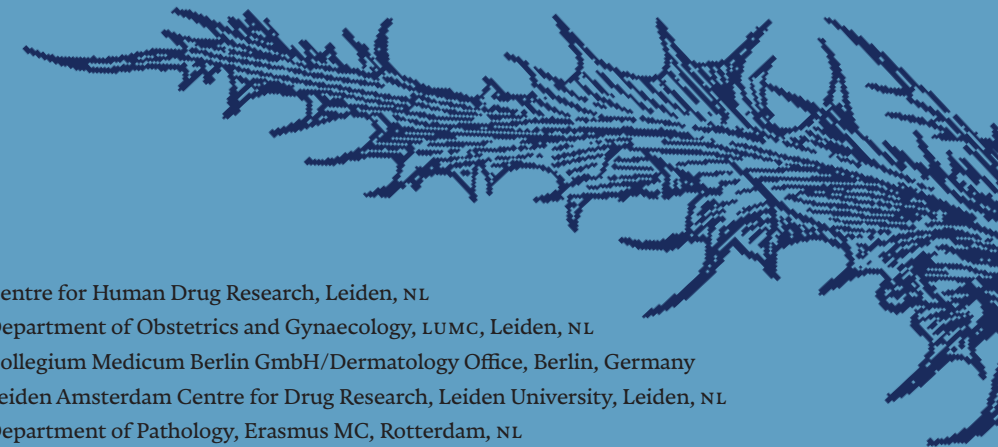2 Department of Obstetrics and Gynaecology, LUMC, Leiden, NL

3 Collegium Medicum Berlin GmbH/Dermatology Office, Berlin, Germany

4 Leiden Amsterdam Centre for Drug Research, Leiden University, Leiden, NL

5 Department of Pathology, Erasmus MC, Rotterdam, NL

6 Department of Obstetrics and Gynaecology, Catharina Ziekenhuis, Eindhoven,



## Abstract

**BACKGROUND** Incorrect and delayed diagnosis of vulvar high-grade squamous intraepithelial neoplasia (vHSIL) and lichen sclerosus (LS) increases malignant progression risks and negatively impacts prognosis and quality of life. There is a need for novel techniques to improve diagnosis and monitoring. Reflectance confocal microscopy is a non-invasive imaging tool that can visualize skin structures at cellular resolution. However, reflectance confocal microscopy has not extensively been described on vulvar HSIL or LS.

**OBJECTIVES** The primary objective was to explore feasibility and patient acceptability of RCM imaging on premalignant vulvar skin. The secondary aim was to identify RCM-characteristics that are discriminative for vHSIL and LS.

**METHODS** This was a prospective, cross-sectional, observational clinical trial in patients with vHSIL and LS compared to healthy volunteers. RCM recordings and vulvar tissue samples were obtained.

**RESULTS** Five (5) patients with vHSIL, 10 patients with LS and 10 healthy volunteers were enrolled. In total, 100 recordings of vulvar skin were obtained, including lesional and non-lesional sites. The reflectance confocal microscopy technique was considered acceptable for application by patients and healthy controls. Healthy skin was characterized by a homogenous, normal honeycomb patterned epidermis and a clear epidermal-dermal junctions. Vulvar HSIL and LS lesions often displayed an atypical honeycomb pattern of the epidermis and lymphocytic influx with presence of melanophages. Distinct features specifically observed in LS included the presence of hyalinised vessels and sclerotic areas in the dermis.

**CONCLUSIONS** Reflectance confocal microscopy is a non-invasive imaging technique that is feasible and clinically acceptable to apply on vulvar skin, both in patients with premalignant lesions and healthy controls. Recognition and validation of disease-specific characteristics could make reflectance confocal microscopy a clinical tool to non-invasively aid identification of vulvar premalignancies. However, studies to validate disease-specific characteristics in a wider range of vulvar diseases including vulvar squamous cell carcinoma are indicated.

## Introduction

Incorrect or delayed diagnosis of vulvar high-grade squamous intraepithelial neoplasia (vHSIL) and lichen sclerosus (LS) has detrimental consequences as both diseases can predispose to vulvar squamous cell carcinoma (vSCC). Malignant progression risks are estimated to be up to 5% and 10%.<sup>1-3</sup>

vHSIL is caused by high-risk oncogenic human papillomavirus (HPV) infection and symptoms include genital pruritus or pain. Peak prevalence is in women aged 20-35 years.<sup>3,4</sup>

Genital LS has a peak incidence in woman aged 45-60 years, but also occurs in prepubertal children and adult males.<sup>5</sup>

LS is characterized by vulvar pruritus. Clinically, the vulvar skin becomes thinner, less flexible, and hypopigmented or erosive areas appear in a classic 'figure of eight' shape. LS is a chronic disease with mutilating effects due to disappearance of the labia minora and clitoris and vaginal narrowing. Current standard-of-care treatment for LS is topical application of ultra-potent corticosteroids, which can reduce vSCC incidence if applied with high compliance.<sup>6</sup>

The malignant pathway from LS to vSCC usually progresses via a precursor lesion known as differentiated vulvar intraepithelial neoplasia (dVIN). The malignant transformation risk is very high (33-86%) with cancer progression usually occurring within 2 years after dVIN diagnosis.<sup>3,7</sup>

For these reasons, life-long surveillance and therapy is indicated for LS patients.

Major issues in the management of vulvar premalignant disease include frequent misdiagnosis, delays in receiving the correct diagnosis and the recognition of disease margins for biopsy or therapy. This delay is mainly caused by a lack of awareness among patients and healthcare professionals, in addition to the social stigma and taboo that patients experience causing a delay in time from symptom occurrence to presenting to a physician.<sup>8,9,10</sup> Even among specialised dermatologists and gynaecologists, vulvar premalignancies such as vulvar HSIL and dVIN are sometimes challenging to recognise. A pathological examination of invasively obtained biopsy material is needed for a conclusive diagnosis of vulvar HSIL and dVIN.<sup>11,12</sup> For LS, the mean time between onset of pruritic symptoms and identification is reported to be approximately 5 years. It is assumed that the onset of disease occurs even earlier.<sup>13</sup> These diagnostic challenges illustrate the need for enhanced tools

to improve timely recognition of vulvar diseases and prompt identification of malignant progression. One of our hypothesised tools is the application of non-invasive, real-time techniques such as reflectance confocal microscopy (RCM). RCM is an *in vivo* confocal imaging tool that uses a low powered laser (830nm) to provide non-invasive and real-time visualization of the epidermis and superficial collagen layers at a cellular level up to a depth of 150  $\mu\text{m}$ .<sup>14</sup> This results in optical transversal sectioning of unstained epithelium and stroma. This technique has been applied for early and accurate diagnosis of skin tumors including melanoma or basal cell carcinoma (BCC) and reportedly may reduce unnecessary biopsies of benign lesions.<sup>15,16</sup> Despite these technological and clinical advancements in the improvement of diagnostic accuracy, RCM imaging of vulvar area has only been described in few pilot studies.<sup>17-20</sup>

These studies lacked thorough descriptions of methodology and specifics of clinical application of RCM on the delicate vulvar area. Only one small study has previously described vHSIL using RCM imaging and none to date have described vulvar LS.<sup>21</sup> The primary objective of this clinical trial was to explore the technical feasibility and patient acceptability of RCM imaging on the vulva. The secondary aim was to describe morphological RCM characteristics that are discriminative for vHSIL and LS in comparison to non-lesional control sites as well as healthy females.

## Methods

This RCM analysis was part of a single-centre observational clinical trial performed at the Centre for Human Drug Research in Leiden, The Netherlands, from February 2021 to October 2021. The trial incorporated a multi-modal range of techniques to identify and validate new clinical biomarkers for vHSIL and LS.<sup>22,23</sup> The study protocol was approved by the local ethics review board (Medisch-Ethische Toetsingscommissie Leiden Den Haag Delft) with reference number P.20.075. The trial was registered with the 'Netherlands Trial Register' (NL73964.058.20) and EudraCT (2020-002201-2). Subjects gave written informed consent prior to any study activities.

### TRIAL DESIGN AND STUDY POPULATION

In total, 25 women (Fitzpatrick skin type I-III), aged 25-72 with a body mass index (BMI)  $<30 \text{ kg/m}^2$  were included. Ten healthy controls, five patients with vHSIL ( $\geq 1$  sharply marginated histologically confirmed vHSIL lesion  $\geq$

15mm) and ten patients with LS (clinical diagnosis) were enrolled. The wash-out for topically applied products on the vulvar area was  $\geq 14$  days. RCM images were obtained of visually lesional and (apparently) non-lesional sites of the vulva at every trial visit. Vulvar tissue was obtained using a 4mm skin punch biopsy as histological reference. All patients and healthy volunteers completed a questionnaire assessing the patient acceptability of the RCM procedure compared to vulvar biopsies (range 0-100). The differences between procedures were analysed using a paired student's t-test for all subjects as one group in GraphPad version 9.3.1.

### PREPARATION AND OBTAINING OF RCM IMAGES

RCM images were obtained using the VivaScope confocal laser scan system, with the VivaCam<sup>®</sup> (VivaScope GmbH, Munich, Germany) for dermatoscopic images and the fixed VivaScope 1500 imaging module (Gen4) or the hand-held VivaScope 3000 add-on imaging module for microscopical images (*Supplementary Figure 1A+B*). The patients were seated in the gynaecological chair to obtain the RCM images (*Supplementary Figure 1C*). Generally, one operator is required to obtain an RCM image, but in this study most images were obtained by two operators (LP and BH) assisting each other.

A small drop of imaging oil (Crystal Plus Food Grade Mineral Oil FG-40Z, Vivascope) was placed between the skin and the plastic imaging frame. Areas of interest included the labia majora, labia minora, interlabial fold, perineum and peri-anal sites. Hairs were occasionally clipped to enhance image quality. Generally, the adhesive of the plastic tissue cap was applied to the vulvar skin to keep the cap in place during the imaging procedure (*Supplementary Figure 2D+E*). In case of disrupted, sensitive vulvar skin, the protective cover paper on the adhesive area was partly removed and/or the tissue cap was held in place by one operator while the other operator executed the imaging steps. A dermatoscopic image was obtained for reference and orientation using the VivaCam. Subsequently, water soluble and hypoallergenic ultrasound gel (Aquasonic, Parker) was placed within the tissue cap and the Vivascope 1500 scanner was placed in the cap. The imaging scanner moved within the tissue cap as they were navigated across the vulvar skin via the computer-driven instructions of the operator based on the macroscopic image. This resulted in cellular-resolution images of the epithelium of the skin and supporting stroma using the VivoScan software (Vivosight, Caliber I.D., Inc., Rochester, NY, USA). Images were obtained with functions 1) VivoBlock: single image of 0.5

x 0.5mm at a pre-selected depth; 2) VivoStacks: vertical series of images at the same horizontal position and 3) VivoCube: series/stack of RCM images/blocks digitally rendering a mosaic up to 3x3mm. In case of difficult to reach vulvar areas, the hand-held VivaScope 3000 system was used without dermatoscopy alignment to obtain RCM footage. Complete image acquisition took 5-15 minutes, depending on the size and number of the images.

### SCORING OF RCM CHARACTERISTICS

The obtained RCM images were analysed by two raters (LP and BH) after completion of the clinical trial. All images were randomized and blinded (LP) before scoring by random assignment of a letter combination to the images sorted for subject type. Analysis was performed per location according to a pre-determined set of characteristics in mutual agreement with MU and the raters (Table 1, Figure 1), based on knowledge from histology and RCM.<sup>14,24-26</sup>

Training of the raters on recognition of RCM characteristics was performed by an expert in the field (MU) prior to full study analysis. Observations were summarized and shown descriptively.

### MORPHOLOGIC ANALYSIS OF VULVAR REFERENCE TISSUE

Lesional and non-lesional vulvar tissue samples were obtained using a 4 mm punch biopsy acquired by trained physicians (LP, BH or MVP). Biopsies were formalin fixed and paraffin embedded (FFPE) and cut in 4 µm sections and stained for H&E. Pathological examination was performed by a dermatopathologist (JD).

## Results

### POPULATION CHARACTERISTICS

In total, 25 women, of which 5 patients with vHSIL and 10 patients with LS and 10 HV were enrolled in the study. Baseline characteristics were comparable between patients and healthy controls, with mean ages of 46.6, 50.3 and 46.5 years, respectively (Supplementary Table 1). Pre- and postmenopausal status was equally distributed within groups. All patients (vHSIL and LS) had previously undergone therapy for their vulvar disease. Histologically, all vHSIL and healthy tissue was confirmed corresponding to the clinical diagnosis. LS diagnosis was based on the clinical assessment, as stipulated

by current protocols and guidelines. Three out of ten LS biopsies were morphologically confirmed as LS. The remaining being classified as normal skin with inflammatory reactive changes (e.g. acanthosis, lymphohistiocytic inflammation).

### PATIENT ACCEPTABILITY OF RCM IMAGING

No adverse reactions were observed from the imaging oil or the adhesive from the plastic tissue cap on the vulvar area. Removal of the adhesive from the tissue cap was considered slightly uncomfortable for a short time without being painful and left no long-term irritation or pain. This was also the case for subjects with erosive lesions or image sites in sensitive areas like the labia minora or peri-anally. The non-invasive RCM procedure was considered significantly less burdensome compared to the invasive biopsy procedure ( $p=0.0259$ ) (Supplementary Figure 2).

### RCM FINDINGS: MORPHOLOGICAL CHARACTERISTICS

In total, 100 RCM images were obtained at different study days and scored by two raters. Intentionally, a recording of each study day was analysed, however some images were of poor quality and were therefore excluded. The final analysis image set included 29 of vulvar tissue of healthy control subjects (N=10 HV), 12 recordings of lesional vHSIL (N=5 patients), 2 of non-lesional skin of vHSIL patients, 42 of lesional LS vulvar skin (N=10 patients) and 15 of non-lesional skin of LS patients (N=10) mostly of the groin region as LS often involved the whole vulvar area). A representative example of all characteristics is shown in Figure 1. For each population (healthy control, vHSIL, LS) a representative case with disease-distinguishing characteristics is shown to allow for side-by-side comparison of corresponding histological, dermatoscopic and RCM images (Figs. 3-5).

Features characterizing healthy skin were an intact dermal-epidermal junction (100%) and a normal, honeycomb patterned epidermis, generally in the absence of inflammatory cells, unusual vessel structure and epidermal or dermal changes. Some of the scored characteristics were occasionally observed, such mild lymphocytic infiltrate in the dermis (Figure 2).

Common characteristics identified in vHSIL were an atypical honeycomb pattern (75%) and presence of melanophages (62.5%). Lymphocyte infiltration was mildly to profoundly present in 71%, mostly in the dermis but also with epidermal lymphocytic exocytosis in 37.5% of cases. No dermal sclerosis

was identified. Vascular changes were minimal (*Figure 2*). Only two recordings were obtained on non-lesional vulvar skin of vHSIL, of which one was of insufficient quality to assess, whilst the other was classified as healthy vulvar skin without notable characteristics or morphological changes.

Ectactic (63%) or hyalinised sclerotic vessels (68%) and dermal sclerosis (71%) were among often observed characteristics in LS. In addition, mild to profound lymphocyte infiltrate (79%) was found in the dermis. An atypical honeycomb pattern was observed in 56% of the LS epidermis analysed. In 88% of cases, the dermal-epidermal junction was considered intact (*Figure 2*). Non-lesional LS tissue was characterized by the absence of honeycomb atypia or immune cell influx. In a minority of cases (7%), dermal sclerosis and hyalinised vessels were observed (*Supp Figure 3*).

## Discussion

This is the first study to systematically assess and extensively describe the application of RCM imaging on the vulvar area. We have shown that RCM is technically feasible on the vulva of patients with premalignant disease with minimal patient discomfort. In addition, we were able to identify and compare RCM features of healthy vulvar skin to vHSIL and LS. RCM features observed in vHSIL included an atypical honeycomb pattern of the epidermis and strong dermal lymphocytic influx including melanophages. Lymphocytic exocytosis into the epidermis may also be present. These features were also observed in LS, with the distinct presence of sclerotic, collagenous areas and pronounced, hyalinised vessels in the dermis of LS vulvar skin. In line with previous findings, our control group included healthy vulvar skin that showed a normal honeycomb pattern of the epidermis and a distinct dermal-epidermal junction (DEJ).<sup>18,21</sup>

This study adds to the sparse available data of the application of RCM in vHSIL, LS and healthy vulvar skin. Fouques *et al.* were the first and only to report on RCM features of 10 patients with lesions suspicious for vHSIL.<sup>21</sup> They described features of vHSIL including an atypical honeycomb pattern, parakeratosis and keratinocyte atypia. This concurs with our findings, although lymphocytic influx, a common (71%) feature in our analysis, was not described. In addition, we did not include parakeratosis or keratinocyte atypia in our analysis. In three LS lesions, Fouques *et al.* reported a normal honeycomb epidermal pattern and a 'frosted glass aspect' (dermal sclerosis) of the dermis. We confirmed these findings in a more substantial population,

but also identify honeycomb pattern disruption in 56% of cases. Dermal sclerosis was considered one of the prominent features of LS in our findings. Melanocyte influx in 3/6 cases of hyperpigmented LS were reported by Theillac *et al.*, concurring with our finding of 48% melanocyte presence in LS.<sup>27</sup> Vascular changes, which were identified in 63-68% of our LS cases, have not previously been described. The remaining literature on the application of RCM on the vulva is limited by case studies which primarily focus on pigmented lesions.<sup>17-19,28-30</sup>

The main strength of this study is the inclusion of healthy controls as reference for scoring the characteristics of vHSIL and LS skin. Within-patient control potentially confounds 'healthy' findings as the tissue can be compromised by scarring, immune cell infiltration or treatment effects. As previous studies lacked a detailed description of the application of RCM on (diseased) vulvar tissue, we here showed our practical considerations and a setup to facilitate follow-up studies by other research groups. Also, although the hand-held RCM tool is useful for difficult to reach vulvar areas, this study shows that larger scanning areas using the 1500 scanning head is feasible and renders high-quality images with direct dermatoscopic reference. Patient acceptability assessment scoring as incorporated in this study is essential to encourage further development and clinical integration of the technique.

Limitations of this study include the modest sample size which means that our assessments require replication in a larger and more diverse patient population (including vSCC and dVIN) to appraise validity of our findings, repeatability, and clinical application. We were unable to recruit patients with dVIN or vSCC, which would have enabled comparison of RCM features between pre-malignant vulvar tissue and invasive vSCC. Another limitation concerns that the data was assessed by only two raters. In total, 100 images were obtained from 25 subjects, thus no corrections for repeated within-subject observations were performed in this descriptive analysis. Additionally, this study stratified described RCM features by disease, and not by anatomical location, although the vulva is a diverse anatomical structure from the hirsute labia majora to the mucosal vaginal vestibulum.

Lichen sclerosis is diagnosed based on clinical features. This could raise valid concerns for the clinical applicability of RCM for this benign disease. In our opinion, the potential gain of the use of RCM lies in earlier and improved non-invasive recognition of lesions suspicious for dVIN or vSCC during the life-long follow-up of LS patients. In addition, RCM has been shown to enable safe reduction of biopsy frequency in basal cell carcinoma.<sup>31</sup> On the vulva,

this potential benefit could be even more vital in sparing essential vulvar structures such as the clitoris and urethra. This could also apply for the recognition and follow-up of vHSIL, dVIN and vSCC, which are diagnoses that currently require histological confirmation. In addition, RCM might help to identify the most aberrant part of the vulvar lesion for choosing the most suspicious biopsy location. Before incorporation into the dermatological or gynaecological practice, a more expansive, prospective and long-term study of vulvar features of RCM should be conducted, including all suspicious lesions in the outpatient clinic, including vHSIL, LS, dVIN and vSCC. Hence, the RCM features in lesions ranging from healthy vulvar skin to invasive cancer could be collected and validated to create a scoring and reference system for clinicians. Interstitial lymphocyte infiltration, follicular plugging and basal membrane thickening are typical histological features of LS that were not included in the pre-set of characteristics scored in this analysis, but could be considered for follow-up studies.<sup>26</sup> To facilitate image interpretation, we suggest standardizing the image acquisition protocol, stipulating the depth interval between images and the areas of special interest.

In conclusion, RCM imaging on the delicate vulvar area is feasible and well tolerated by patients, also in premalignant vulvar diseases. Presence of morphological RCM characteristics observed in the RCM images of this study have the potential to distinguish vHSIL and lichen sclerosus from healthy vulvar skin. However, a discriminative set of RCM features that could facilitate vulvar disease diagnosis was could not consistently be identified. This would require expansion of patient groups and inclusion of additional vulvar disease entities. This technique could lead to improved diagnostics of premalignant lesions and potentially guide or reduce biopsy frequency, though clinical validation in larger patient groups with long-term follow-up is crucial before implementation. Future studies should also focus on elucidation of RCM characteristics of dVIN and vSCC to improve recognition of the complete dysplastic pathway from healthy vulvar skin to invasive malignant disease.

The overall observation by the operators was that the presence of RCM features corresponding with lesional vulvar skin could generally differentiate diseased from healthy vulvar skin. However, these findings currently could not reliably discriminate vHSIL from LS (Figure 2). Immune cell influx and atypical honeycomb patterns of the epidermis were observed at comparable rates in vHSIL and LS. Dermal sclerosis and sclerotic vessels was distinctively identified in LS.

**Table 1** Overview of selected morphological RCM characteristics based on literature.

Characteristic	Example	Scoring	Associated Diseases	Description	
Epidermis	Normal honeycomb	1A	Absent/ Present	HV	A normal stratum granulosum and spinosum of the epidermis display a normal honeycomb pattern, made by the arrangement of the keratinocytes with demarcated outlines that make up a regular grid shaped like a honeycomb. <sup>14</sup>
	Atypical honeycomb pattern	1B	Absent/ Present	vHSIL, LS, actinic keratosis, invasive squamous cell carcinoma, melanoma	Disarranged epithelial cells of different sizes, varying brightness of the lines without clear regular structure, as opposed to a normal honeycomb pattern. <sup>14</sup>
	Hyperkeratosis	1C	Absent/ Present	LS, keratosing diseases (actinic keratosis, seborrheic keratosis), squamous cell carcinoma, warts, psoriasis	An increase of thickness stratum corneum, visible as reflectile amorphous material in RCM. Hyperkeratosis is commonly described in histological assessments of lichen sclerosus and vHSIL. <sup>14,24,25</sup>
DEJ/Dermis	Normal DEJ	1D	Absent/ Present	HV	Basal cells are highly reflective and display a uniform size and shape. In the DEJ, the basal cells are arranged in a typical ringed appearance of dark round to oval shapes corresponding with the basal cell covering of the finger-like dermal papillae, a feature in RCM also called 'edged papillae'. <sup>14</sup>
	Disrupted DEJ	1E	Absent/ Present	vHSIL, LS	Disappearance of the dermal papillae structure and thickening or degeneration of the basal layer has been described in lichen sclerosus. <sup>24</sup>
	Dermal sclerosis	1F	Absent/ Present	Lichen sclerosus, lupus erythematosus	Thick and increased number of dermal fibers. Dermal sclerosis is a key feature of lichen sclerosus, also described in histological assessments. <sup>14,25</sup>
Immune infiltrate	Lymphocytic exocytosis	1G	Absent/ Present	vHSIL, LS	Single or aggregates of round-to-polygonal, mildly refractive cells at the level of the stratum spinosum interspersed between keratinocytes. <sup>14</sup> Lymphocytes in the epithelium have been described in histological assessments of vulvar disease, indicating immune responses. <sup>25,26</sup>
	Lymphocyte infiltrate	1H	Absent/ Mild/ Moderate/ Profound	vHSIL, LS, lupus erythematosus	Immune infiltrate in general, described in histological literature of both vHSIL (REF) and LS. This infiltrate can be observed in the dermis and can consist of different type of immune cells. <sup>25,26</sup>
	Melanophages	1I	Absent/ Present	Chronic inflammatory diseases, e.g. vHSIL, LS	Polygonal, bright structures larger than inflammatory cells and sometimes dendritic in the dermis. These cells are rich in melanin and are typically solitary distributed around papillary dermal capillaries. <sup>14</sup> Also described in histological assessments of lichen sclerosus. <sup>25,26</sup>

(Continuation Table 1)

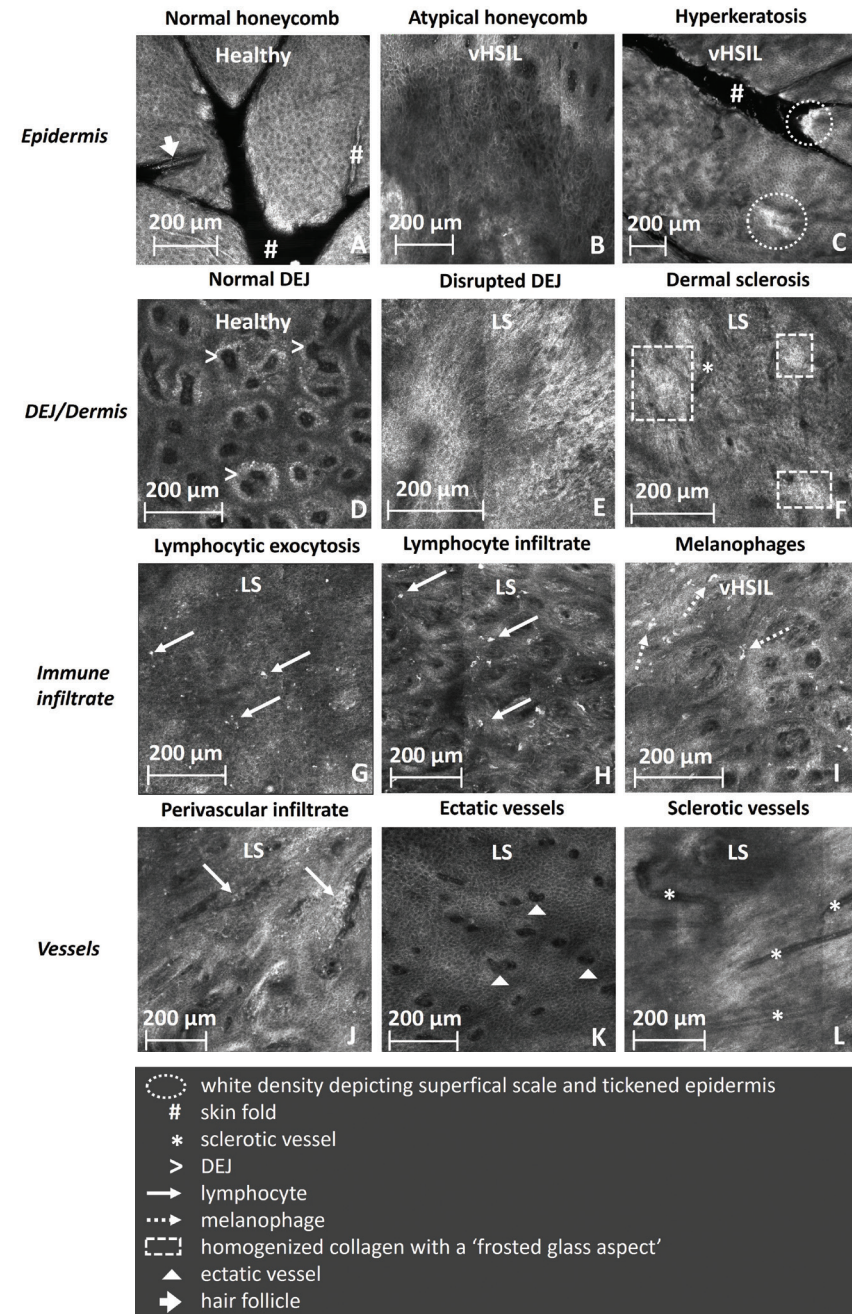
Characteristic	Example	Scoring	Associated Diseases	Description
Vessels	Perivascular infiltrate	Absent/ Mild/ Moderate/ Profound	LS	Round-to-polygonal, mildly refractive cells around the dermal vessels. A perivascular distribution of atypical lymphocytes and inflammatory cells within dermal papillae may lead to a loss of the typical ringed appearance of dermal papillae at the DEJ. <sup>14</sup> Resulting from inflammatory process, often found in histological assessment of lichen sclerosis. <sup>25,26</sup>
	Ectatic vessels / capillaries in dermal papillae	Absent/ Present	LS	Canalicular vessels with bright cells characteristic of dilated, telangiectatic vessels. <sup>14</sup> Changes in vasculature due to sclerotic dermis and inflammatory process, also described in histology of lichen sclerosis. <sup>25,26</sup>
	Hyalinised or sclerotic vessels	Absent/ Mild/ Moderate/ Profound	LS	Commonly described in histological assessment of lichen sclerosis. <sup>25,26</sup>

HV=healthy volunteer, vHSIL=vulvar high grade squamous intraepithelial lesion, LS=lichen sclerosis, DEJ=dermal-epidermal junction. volunteer. RCM = reflectance confocal microscopy

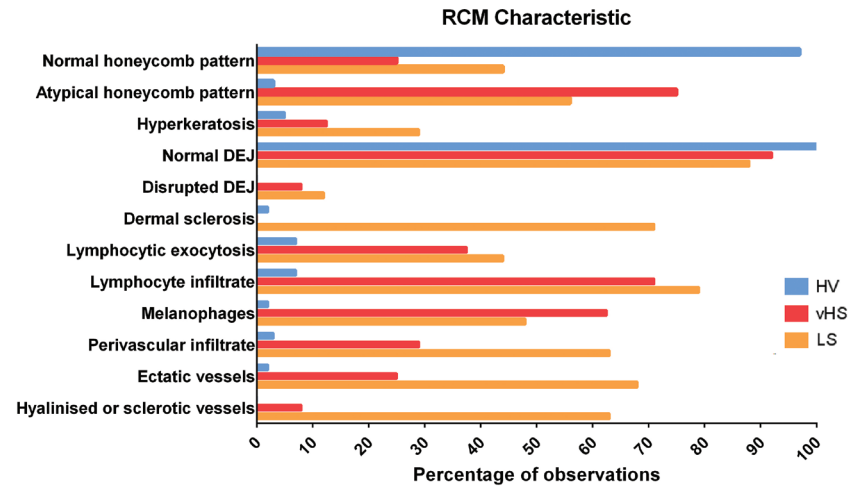
**Figure 1 Representative images showing examples of scored characteristics.**

A) Normal honeycomb pattern of the epidermis of labia majora (Healthy)- depth 60 µm; B) Atypical honeycomb pattern of the epidermis of the perineum (vHSIL)- depth 85 µm; C) Hyperkeratosis in the epidermis of the perineum (vHSIL)- depth 27 µm; D) Normal pattern of the dermal-epidermal junction (DEJ) of the labia majora (Healthy)- depth 73 µm; E) Absent or disturbed dermal papillae located in the labia majora (note the lack of papillar pattern and direct transition from epidermal cells (bottom left) to sclerotic dermis) (LS)- depth 195 µm; F) Dermal sclerosis (or homogenized collagen) in the dermis of the labia minora (LS)- depth 83 µm; G) Lymphocytic exocytosis in the epidermis of the perineum (LS)- depth 61 µm; H) Profound lymphocytic infiltrate in the dermis of the labia minora (LS)- depth 76 µm; I) Presence of melanophages in the epidermis of the interlabial fold, paraclitoral (vHSIL)- depth 91 µm. J) Perivascular infiltrate in the dermis of the labia majora (LS)- depth 178 µm; K) Ectatic vessels in the dermal papillae of the interlabial fold, paraclitoral (LS)- depth 78 µm; L) Sclerotic vessels in the dermis of the inner side of the labia minora (LS)- depth 106 µm. Scale bars in all images represent 200 µm.

(Figure on opposite page)



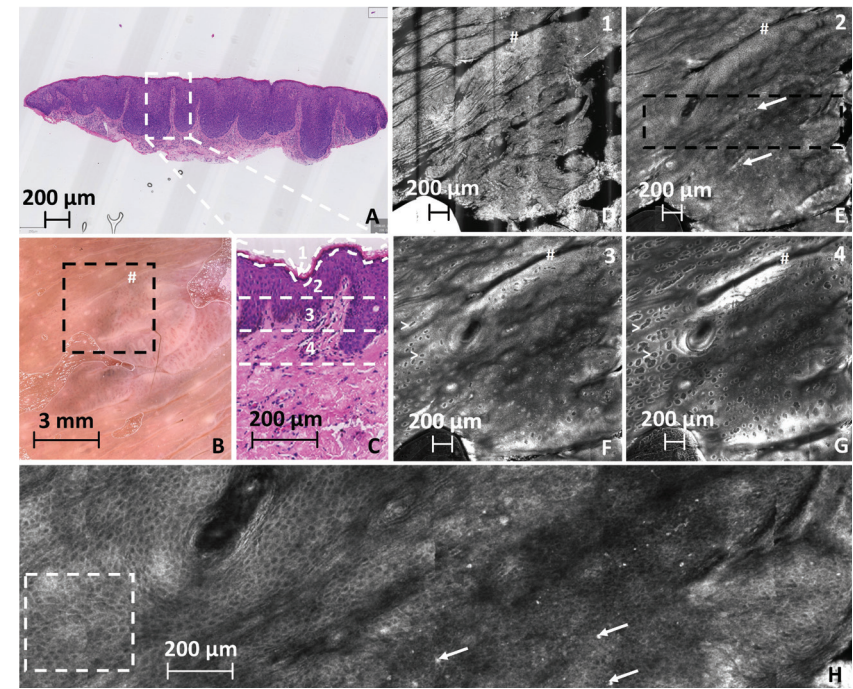
**Figure 2** Percentage observed characteristics in RCM images, in HV, vHSIL and LS. The average percentage of observations of both two raters were shown.



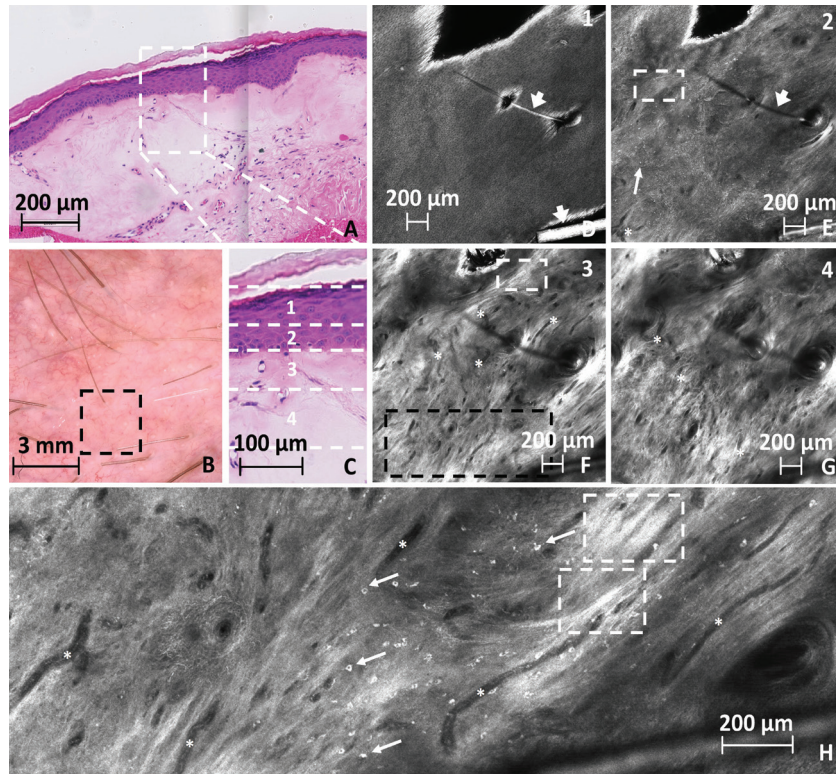
HV=healthy volunteer, n=58 observations, vHSIL=vulvar HSIL, n=24 observations, LS=Lichen sclerosis, n=84 observations. DEJ=Dermal Epidermal Junction.

**Figure 3** Images of representative lesional skin of vHSIL in the peri-anal area.

A) H&E staining of a 4 mm punch biopsy of lesional warty-type vHSIL on the perineum. Scale bar represents 200  $\mu$ m. B) Macroscopic dermatoscopic image of a vHSIL lesion in the peri-anal area of another patient (more representative corresponding RCM images). The black insert represents the location of the RCM close-ups represented in image C-G. Scale bar represents 3 mm. C) Insert of a H&E staining as annotated in A. Dashed areas 1,2,3 and 4 represent skin layers stratum corneum, stratum granulosum, stratum spinosum and epidermal-dermal junction (EDJ) respectively, matching to the layers shown in RCM images D-G. Scale bar represents 200  $\mu$ m. D) RCM image of the stratum corneum with skin folds (# signs) (depth 0  $\mu$ m). E) RCM image of the epidermis showing an atypical honeycomb pattern and lymphocyte influx with melanophages (white arrows) (depth 41  $\mu$ m). F) RCM image showing the epidermal-dermal junction (> sign) (depth 81  $\mu$ m). G) RCM image showing the dermis and the dermal papillae with the epidermal-dermal junction (> sign) (depth 121  $\mu$ m). H) RCM image showing a magnification of the indicated area (black dashed box) in RCM image E displaying an atypical honeycomb pattern (white dashed box) and lymphocytic influx (bright white cells) including melanophages (white arrows). The scale bars in the RCM images (D-H) represent 200  $\mu$ m.




**Figure 4** Images of representative vulvar skin of a LS patient - labia majora inner side. A) H&E staining of 4 mm punch biopsy of lesional LS skin on the inner side of the labia majora. Scale bar represents 200  $\mu$ m. B) Macroscopic dermatoscopic image of corresponding lesional biopsy (LB) location with black insert of the close-up of the RCM images in D-G. Scale bar 3 mm. C) Insert of H&E staining represented in A. Dashed areas 1,2,3 and 4 represent skin layers stratum corneum, stratum granulosum, stratum spinosum and epidermal-dermal junction (EDJ) respectively, correlating to the layers shown 1-4 in the RCM images D-G. Scale bar represents 100  $\mu$ m. D) RCM image at the stratum corneum with a visible hair (arrowhead) (depth 29  $\mu$ m). E) RCM image of the transition from the epidermis to the dermis showing an atypical honeycomb pattern in the epidermal structure, loss of dermal papillae, melanophage influx (white arrows), sclerotic vessels (asterixes) and sclerotic dermal areas (white dashed box) (depth 78  $\mu$ m). F) RCM image showing the dermis with pronounced sclerosis (white dashed box) and hyalinised, sclerotic vessels (asterixes) (depth 126  $\mu$ m). G) RCM image showing the deep dermis with distinct sclerosis (white dashed box) and hyalinised vessels (asterixes) (depth 175  $\mu$ m). H) RCM image showing a magnification of the indicated area (black dashed box) in RCM image F displaying moderate to profound lymphocytic (bright white cells) and melanocytic infiltration (white arrows), sclerotic areas (white dashed box) and stiff, hyalinised vessels (asterixes). The scale bars in the RCM images (D-H) represent 200  $\mu$ m.



#### SUPPLEMENTS CHAPTER 4

Supplemental data can be accessed online at:

- Supplementary Figure 1* In vivo VivaScope 1500/3000 system
- Supplementary Figure 2* Mean (SD) patient rating of patient acceptability
- Supplementary Figure 3* Images of representative healthy vulvar skin on the labia majora
- Supplementary Figure 4* Percentage observed characteristics in RCM images, in non-lesional LS
- Supplementary Table 1* Baseline characteristics



## REFERENCES

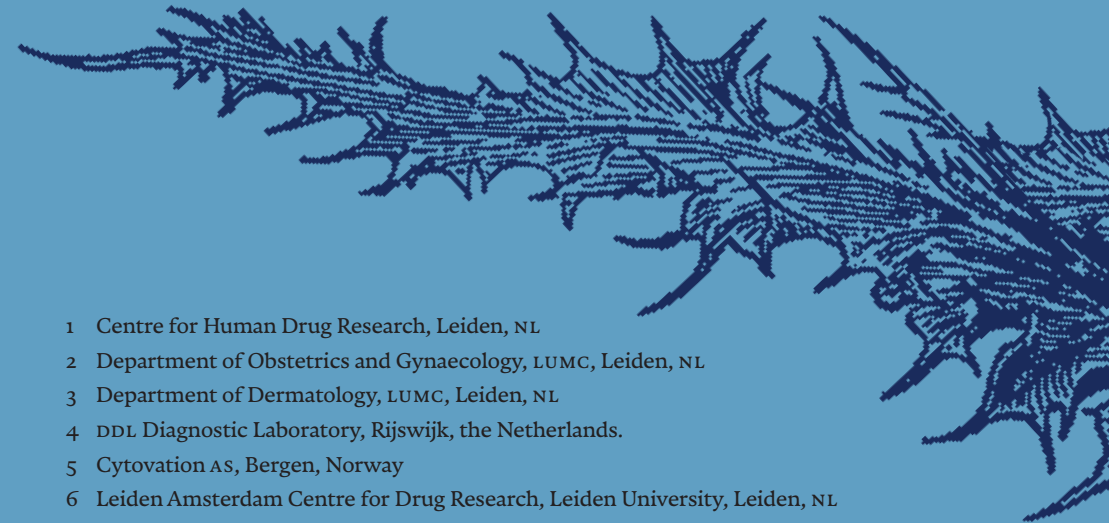- 1 Hacker NF, Eifel PJ, van der Velden J. Cancer of the vulva. *Int J Gynecol Obstet.* 2012;119:S90-S96. doi:https://doi.org/10.1016/S0020-7292(12)60021-6
- 2 Thuijs NB, van Beurden M, Bruggink AH, Steenbergen RDMM, Berkhof J, Bleeker MCGG. Vulvar intraepithelial neoplasia: Incidence and long-term risk of vulvar squamous cell carcinoma. *Int J cancer.* 2021;148(1):90-98. doi:10.1002/ijc.33198
- 3 Voss FO, Thuijs NB, Vermeulen RFM, Wilthagen EA, van Beurden M, Bleeker MCG. The vulvar cancer risk in differentiated vulvar intraepithelial neoplasia: A systematic review. *Cancers (Basel).* 2021;13(24). doi:10.3390/CANCERS13246170/S1
- 4 de Sanjosé S, Alemany L, Ordi J, et al. Worldwide human papillomavirus genotype attribution in over 2000 cases of intraepithelial and invasive lesions of the vulva. *Eur J Cancer.* 2013;49(16):3450-3461. doi:https://doi.org/10.1016/j.ejca.2013.06.033
- 5 Tran DA, Tan X, Macri CJ, Goldstein AT, Fu SW. Lichen Sclerosus: An autoimmunopathogenic and genomic enigma with emerging genetic and immune targets. *Int J Biol Sci.* 2019;15(7):1429-1439. doi:10.7150/IJBS.34613
- 6 Chin S, Scurry J, Bradford J, Lee G, Fischer G. Association of Topical Corticosteroids With Reduced Vulvar Squamous Cell Carcinoma Recurrence in Patients With Vulvar Lichen Sclerosus. *JAMA Dermatology.* 2020;156(7):813-814. doi:10.1001/jamadermatol.2020.1074
- 7 McAlpine JN, Kim SY, Akbari A, et al. HPV-independent Differentiated Vulvar Intraepithelial Neoplasia (dVIN) is Associated With an Aggressive Clinical Course. *Int J Gynecol Pathol Off J Int Soc Gynecol Pathol.* 2017;36(6):507-516. doi:10.1097/PGP.0000000000000375
- 8 Bentham GL, Manley K, Halawa S, Biddle L. Conversations between women with vulval lichen sclerosus: a thematic analysis of online forums. *BMC Womens Health.* 2021;21(1). doi:10.1186/s12905-021-01223-6
- 9 PA N. Vulvar Lichen Sclerosus et Atrophicus. *J Midlife Health.* 2017;8(2):55-62. doi:10.4103/JMH.JMH\_13\_17
- 10 Ansink A. Vulvar squamous cell carcinoma. *Semin Dermatol.* 1996;15(1):51-59. doi:10.1016/s1085-5629(96)80019-8
- 11 Abhisek K, Khunger N. Complications of skin biopsy. *J Cutan Aesthet Surg.* 2015;8(4):239-241. doi:10.4103/0974-2077.172206
- 12 Allbritton JI. Vulvar Neoplasms, Benign and Malignant. *Obstet Gynecol Clin North Am.* 2017;44(3):339-352. doi:10.1016/j.ogc.2017.04.002
- 13 Christmann-Schmid C, Hediger M, Gröger S, Krebs J, Günthert AR. Vulvar lichen sclerosus in women is associated with lower urinary tract symptoms. *Int Urogynecology J* 2017 292. 2017;29(2):217-221. doi:10.1007/S00192-017-3358-8
- 14 Hofmann-Wellenhof R, Pellacani G, Malvey J, Soyer HP. *Reflectance Confocal Microscopy for Skin Diseases.* Springer Berlin Heidelberg; 2012. doi:10.1007/978-3-642-21997-9
- 15 Farnetani F, Scope A, Braun RP, et al. Skin cancer diagnosis with Reflectance confocal microscopy: Reproducibility of feature recognition and accuracy of diagnosis. *JAMA Dermatology.* 2015;151(10):1075-1080. doi:10.1001/jamadermatol.2015.0810
- 16 Braga JCT, Macedo MP, Pinto C, et al. Learning reflectance confocal microscopy of melanocytic skin lesions through histopathologic transversal sections. *PLoS One.* 2013;8(12). doi:10.1371/journal.pone.0081205
- 17 Feng L, Lin Y, Wang L, et al. Imaging of Vulva Syringoma With Reflectance Confocal Microscopy. *Front Med.* 2021;8. doi:10.3389/fmed.2021.649438
- 18 Cinotti E, Perrot JL, Labeille B, Adegbi H, Cambazard F. Reflectance confocal microscopy for the diagnosis of vulvar melanoma and melanosis: Preliminary results. *Dermatologic Surg.* 2012;38(12):1962-1967. doi:10.1111/dsu.12009
- 19 Ozkur E, Falay T, Turgut Erdemir AV, Gürel MS, Leblebici C. Vestibular papillomatosis: An important differential diagnosis of vulvar papillomas. *Dermatol Online J.* 2016;22(3). doi:10.5070/d3223030368
- 20 Cinotti E, Tonini G, Perrot JL, Habougit C, Luisi S, Rubegni P. Dermoscopic and reflectance confocal microscopy features of two cases of vulvar basal cell carcinoma. *Dermatol Pract Concept.* 2018;8(1):68-71. doi:10.5826/dpc.0801a17
- 21 Fouques C, Dorez M, Le Duff F, et al. Reflectance confocal microscopy of vulvar epithelial neoplasia: a pilot study. *Br J Dermatol.* 2017;177(5):e196-e199. doi:10.1111/bjd.15573
- 22 Rissmann R, Moerland M, van Doorn MBA. Blueprint for mechanistic, data-rich early phase clinical pharmacology studies in dermatology. *Br J Clin Pharmacol.* Published online 2020. doi:10.1111/bcp.14293
- 23 Rijsbergen M, Pagan L, Niemeier-van der Kolk T, et al. Stereophotogrammetric three-dimensional photography is an accurate and precise planimetric method for the clinical visualization and quantification of human papilloma virus-induced skin lesions. *J Eur Acad Dermatol Venereol.* Published online 2019. doi:10.1111/jdv.15474
- 24 Dasgupta S, Ewing-Graham PC, Swagemakers SMA, et al. Precursor lesions of vulvar squamous cell carcinoma - histology and biomarkers: A systematic review. *Crit Rev Oncol Hematol.* 2020;147:102866. doi:10.1016/j.critrevonc.2020.102866
- 25 Morrel B, Ewing-Graham PC, van der Avoort IAM, Pasmans SGMA, Damman J. Structured analysis of histopathological characteristics of vulvar lichen sclerosus in a juvenile population. *Hum Pathol.* 2020;106:23-31. doi:10.1016/j.humpath.2020.09.003
- 26 Regauer S, Liegl B, Reich O. Early vulvar lichen sclerosus: a histopathological challenge. *Histopathology.* 2005;47(4):340-347. doi:10.1111/j.1365-2559.2005.02209.x
- 27 Theillac C, Cinotti E, Malvey J, et al. Evaluation of large clinically atypical vulvar pigmentation with rcm: atypical melanosis or early melanoma? *J Eur Acad Dermatol Venereol.* 2019;33(1):84-92. doi:10.1111/jdv.15141
- 28 Cinotti E, Tonini G, Perrot JL, Habougit C, Luisi S, Rubegni P. Dermoscopic and reflectance confocal microscopy features of two cases of vulvar basal cell carcinoma. *Dermatol Pract Concept.* 2018;8(1):68-71. doi:10.5826/DPC.0801A17
- 29 Aydin AM, Chahoud J, Adashek JJ, et al. Understanding genomics and the immune environment of penile cancer to improve therapy. *Nat Rev Urol.* 2020;17(10):555-570. doi:10.1038/s41585-020-0359-z
- 30 Leclercq A, Cinotti E, Labeille B, et al. [The role of reflectance confocal microscopy in the diagnosis of secondary syphilis of the vulva and anus: A first case report]. *Ann Dermatol Venereol.* 2016;143(11):687-690. doi:10.1016/j.annder.2016.07.010
- 31 Kadouch DJ, Leeflang MM, Elshot YS, et al. Diagnostic accuracy of confocal microscopy imaging vs. punch biopsy for diagnosis and subtyping basal cell carcinoma. *J Eur Acad Dermatol Venereol.* 2017;31(10):1641-1648. doi:10.1111/jdv.14253

## CHAPTER 5

# Results of a randomized, placebo-controlled, first-in-human trial of topical CY-002 in patients with cutaneous warts

Adapted from *Journal of the European Academy of Dermatology and Venereology*, 2022. Doi: 10.1111/jdv.18291

Lisa Pagan<sup>1,2</sup>, Christina Yfanti<sup>1</sup>, Rianne Rijnveld<sup>1</sup>, Marina Todd<sup>1</sup>, Peter Jongste<sup>1</sup>, Joep J. Feijen<sup>1</sup>, Erica S. Klaassen<sup>1</sup>, Jan Nico Bouwes Bavinck<sup>3</sup>, Linda Struijk<sup>4</sup>, Maurits N.C. de Koning<sup>4</sup>, Lars Prestegarden<sup>5</sup>, Tessa Niemeier-van der Kolk<sup>1</sup>, Mariëtte I.E. van Poelgeest<sup>1,2</sup> and Robert Rissmann<sup>1,6,7</sup>



- 1 Centre for Human Drug Research, Leiden, NL
- 2 Department of Obstetrics and Gynaecology, LUMC, Leiden, NL
- 3 Department of Dermatology, LUMC, Leiden, NL
- 4 DDL Diagnostic Laboratory, Rijswijk, the Netherlands.
- 5 Cytovation AS, Bergen, Norway
- 6 Leiden Amsterdam Centre for Drug Research, Leiden University, Leiden, NL
- 7 Leiden Skin Institute, Leiden, NL

## Abstract

**BACKGROUND** The first-in-class peptide CY-002 was developed to target neoplastic and HPV-infected cells. Topical CY-002 was investigated on patients with cutaneous warts.

**OBJECTIVES** The primary objective was assessment of safety and tolerability of CY-002 in adults with cutaneous warts. Exploration of efficacy was the secondary objective.

**METHODS** CY-002 was investigated in a single-centre, randomized, double-blind, placebo-controlled, first-in-human, Phase-I trial including a safety run-in. Sixty-three adult patients with  $\geq 1$  cutaneous warts (on the hands) received CY-002 (1%) or placebo 1:1. Treatment was topically administered under occlusion for 28 consecutive days. Safety and multi-modal efficacy assessments were performed weekly and at 3-month follow-up.

**RESULTS** Baseline characteristics were similar except for a higher fraction of treatment-naïve patients among placebo compared to CY-002-treated patients (67.9% versus 33.3%,  $p=0.009$ ). CY-002 was well tolerated with no differences in adverse events or treatment discontinuations. Exploratory efficacy measures (wart size, clearance, morphology and HPV load) did not differ statistically significant between groups. After CY-002, 2 patients (7.7%) achieved full clearance and 4 patients (15.4%) had clearance of  $\geq 1$  warts, compared to respectively 1 (3.8%) and 3 placebo patients (11.5%). Partial clearance was 44% in the CY-002-treated group versus 29% in placebo.

**CONCLUSION** CY-002 is safe and well tolerated for topical daily use up to 4 weeks. While explorative efficacy outcomes showed no statistically significant outcomes, a trend favouring CY-002 across multiple parameters warrants further studies. The design of this trial allows exploration of efficacy parameters without compromising on primary assessment of novel compound safety and tolerability.

## Introduction

Cutaneous warts, or verrucae, are common skin lesions that affect most people at some point in their lifetime. Reported prevalence is 3.6–22% in schoolchildren and 0.84–13% in adults.<sup>1–5</sup> Cutaneous warts are caused by the human papillomavirus (HPV).<sup>6</sup> Some HPV types (e.g. type 16 and 18) have malignant potential in the genitourinary or oropharyngeal tract, whereas others give rise to benign skin lesions. HPV type 1, 2, 7, 27 and 57 most commonly cause cutaneous warts in the general population.<sup>7,8</sup> People with cutaneous warts may report physical or psychological discomfort, including pain or embarrassment.<sup>9</sup> Cutaneous warts can lead to social stigmatisation and lower quality of life.<sup>10,11</sup>

Untreated or unsuccessfully treated warts pose a pool of infection on an individual as well as a community level.<sup>12,13</sup> Current treatment options for cutaneous warts focus on general destruction of the epithelium rather than specifically targeting the HPV-infected keratinocyte.<sup>14–16</sup> The efficacy rate of these treatments varies between 24–40%, with frequently reported side effects including pain, burning sensation and blistering.<sup>17,18</sup> Development of a wart treatment sparing healthy tissue would be of considerable added value. Currently there are no treatments effectively eliminating the HPV infection.<sup>19</sup> Therefore, there is a need for novel treatments that treat cutaneous warts with higher specificity, improved efficacy and reduced side effects.

CY-002 is a synthetic, tumour-targeted membranolytic peptide that aims at an HPV-oriented, immune-targeted cutaneous wart therapy. CY-002 was previously shown to selectively induce cell death in multiple tumour cell lines whilst sparing normal cells *in vitro*.<sup>20</sup> Here, we report the results of a Phase I, first-in-human trial of CY-002 in otherwise healthy subjects with cutaneous warts.

The primary objective of this first-in-human proof-of-concept clinical study was to assess the safety and tolerability of topically applied CY-002 in adults with cutaneous warts. The secondary objective was to explore efficacy of CY-002 on reduction of wart number, size and HPV load after four weeks of daily topical application. Thirdly, new measurement approaches towards a multi-modal follow-up in wart trials were considered.

## Methods

### STUDY DESIGN

The study was designed as a randomized, placebo-controlled, double-blind, single-centre Phase I, first-in-human trial with a safety run-in. Safety and efficacy of CY-002 was evaluated after 4 weeks of treatment at home, preceded by a separate clinical safety run-in. Patients, study personnel and investigators were blinded throughout study conduct. The study was conducted at the Centre for Human Drug Research, Leiden, The Netherlands from February 2019 to December 2019. The Declaration of Helsinki was the guiding principle for trial execution and the study was approved by the independent medical ethics committee 'Medisch Ethische Toetsingscommissie van de Stichting Beoordeling Ethiek Biomedisch Onderzoek' prior to any procedure. All patients provided written informed consent before enrolment.

### STUDY POPULATION

Patients were considered eligible if they were healthy,  $\geq 18$  years old and had  $\geq 1$  cutaneous warts on the hand with a diameter  $\geq 3$  mm. Patients were excluded if they had used wart-removing products within 30–60 days prior to enrolment, depending on the treatment. Effective contraception was required. Warts which were  $> 6$  years old or had been treated with  $> 5$  different treatments were excluded.

### STUDY OUTLINE

The safety in-clinic phase was performed in 8 patients. CY-002 or placebo (randomised 1:1) was administered on 5x5 cm healthy skin on the back and on cutaneous warts during 7 consecutive days. Following no safety concerns during the initial phase, 55 ambulatory patients visited the clinical research unit once weekly (baseline, week 1, 2, 3 and 4) during at-home topical treatment of 28 days (*Supplementary Figure 1*). The patients applied one droplet (15–30mg) of CY-002 1% or placebo cream once daily followed by overnight occlusion using Tegaderm™ film (3M healthcare, Maplewood, MN, USA) on max. 3 warts. Patients returned for follow-up after 6 weeks (week 10) and after 12 weeks for end of study (EOS, week 16). Treatment compliance was monitored using a mobile e-diary application.<sup>21</sup> A pre-defined minimum of 21/28 planned applications was considered acceptable to include a patient for efficacy analysis.<sup>22</sup> Patients who failed to apply the study drug were replaced.

### SAFETY MEASUREMENTS

The safety assessments comprised of evaluation of adverse events (AE), application site inspection for local tolerability, physical examination, ECG, vital signs (including systolic and diastolic blood pressure, pulse rate and temperature) and clinical laboratory testing. Systematic exposure to CY-002 was assessed in plasma on Day 28 and analysed by Ardena Bioanalytical Laboratory (Assen, The Netherlands) after study completion.

### EFFICACY MEASUREMENTS

Efficacy measurements were obtained at baseline and at every following visit to the clinic (*Supplementary Figure 1*).

#### *Wart size and clearance*

Dimensions of the target warts (long diameter, short diameter, height and volume) were measured using a digital vernier caliper (0–75 mm) (HBM Machines B.V., Moordrecht, the Netherlands). The wart volume was calculated (volume =  $\pi * (\text{diameter}/2)^2 * \text{height}$ ). Wart clearance was determined by medical study personnel recording total wart count at each visit. Complete clearance was defined as the diameter of the lesion being zero.

#### *HPV typing and quantification*

Swab samples were collected by rubbing the surface of the target wart five consecutive times with a sterile, pre-wetted cotton-tipped applicator (Puritan Medical Products, Guilford, Maine, USA), subsequently placed in 1 mL of saline solution and stored at -40 degrees Celsius. HPV type was determined with bead-based XMAP suspension array technology simultaneously identifying 23 wart-associated HPV types from the alpha- (HPV2, 3, 7, 10, 27, 28, 29, 40, 43, 57, 77, 91 and 94), gamma- (4, 65, 95, 48, 50, 60 and 88), mu- (HPV1 and 63) and nu-genus (HPV41) (DDL Diagnostic Laboratory BV, Rijswijk, The Netherlands).<sup>23–25</sup> HPV viral load of HPV types HPV1, HPV2, HPV-4, HPV27 and HPV57 was determined by quantitative PCR in all baseline and follow-up samples if the baseline sample was positive for the respective HPV type.

#### *Morphology*

Clinical photography was obtained using conventional 2D and the LifeViz 3D camera.<sup>26</sup> At each study visit, the treated warts were assessed for morphological properties according to the dichotomous nine-point CWARTS

method.<sup>27,28</sup> A 3 mm punch biopsy of the target wart was obtained at the end of study and assessed according to conventional pathological standards at DDL after haematoxylin and eosin (H&E) staining. Quantitative skin morphology analysis was determined by optical coherence tomography (D-OCT VivoSight, Michelson Diagnostics, UK).

### **Multimodal responder/non-responder analysis**

The obtained data from 2D photography in addition to novel techniques (3D photography, OCT imaging and HPV-load analysis) was combined for in-depth study of potential effects. One partial responder after treatment with CY-002 and one non-responder from the placebo group were compared.

## **STATISTICS**

### **Sample size justification**

A group size of 25 patients was considered common for early exploration of safety, tolerability and efficacy of novel topical formulations with a safety run-in group size of 4. This sample size power of 0.8 to detect a difference in means of 24.3 mm<sup>3</sup>, assuming that the common standard deviation was 30, using a two-group t-test with a 0.05 two-sided significance level.

### **Randomization**

The patients were randomized 1:1. In the ambulatory part, randomization was performed in blocks of 10. The randomization code was generated in SAS 9.4 by an independent statistician and patient numbers were allocated by chronological enrolment. Patients, study personnel and investigators were blinded. The randomization code was made available for data analysis after study closure and database lock.

### **Statistical analysis**

All safety and statistical programming was conducted with SAS 9.4. Each efficacy parameter was analysed using a mixed model analysis of covariance (ANCOVA) with treatment, time, and treatment by time as fixed factors and patient as random factor and the (average) baseline measurement as covariate. The Kenward-Roger approximation was used to estimate denominator degrees of freedom and model parameters were estimated using the restricted maximum likelihood method.

## **Results**

### **PATIENTS**

Following an acceptable safety profile in the first 8 patients (safety run-in), 55 patients (50 patients and 5 reserves) started treatment in the ambulatory part of the study (Intention to Treat population, ITT). Throughout the study, 52 patients completed treatment (per protocol population, PP) and 49 completed follow-up (*Figure 1* and *Supplementary Figure 2*). Baseline and disease characteristics were comparable for the two treatment groups (*Table 1*). The placebo patients were more treatment-naïve compared to CY-002 patients (67.9% versus 33.3%,  $p=0.009$ ). Baseline wart morphology according to the CWARTS scoring was similar across groups (*Supplementary Table 1*).<sup>27</sup> Home treatment compliance ranged from 25–28 topical applications with a mean of 27 applications per subject (96.4%). Three patients were replaced due to non-compliance failing study drug application for the pre-defined minimum 21 of 28 planned doses. There was no statistically significant difference in treatment adherence between groups.

### **SAFETY AND TOLERABILITY**

Adverse events (AE) were similar between the treatment and placebo groups (*Supplementary Table 2*). No treatment emergent severe AES or clinically significant changes in vital signs, clinical laboratory results, or ECG occurred in any patients throughout the study. Two patients reported mild application site tolerability issues, with one patient reporting a mild burning sensation lasting 10 seconds after study drug application. All pharmacokinetic samples showed no levels above the lowest level of quantification (LLOQ), concluding that there was no systemic exposure of CY-002.

### **WART CLEARANCE AND SIZE**

*Table 2* shows that after treatment with CY-002, 2 patients (7.7%) achieved full clearance and 4 (15.4%) patients had clearance of a minimum of one of the treated warts. In the placebo group, clearance was observed in 1 patient (3.8%) and 3 patients (11.5%), respectively. Three out of 4 responders in the CY-002 group had unsuccessfully used salicylic acid for wart treatment in their medical history. All placebo responders had treatment-naïve warts. Partial clearance ( $\geq 50\%$  volume reduction) was observed in 21 treated warts (41%) in the CY-002 group compared to 13 treated warts (25%) following placebo

( $p=0.0962$ ) at end of treatment (EOT, week 4). At the end of study (week 16), the partial clearance was 43% (22 warts) in CY-002 group versus 29% (15 warts) in placebo ( $p=0.0940$ ). There were no statistically significant differences in the clearance rates between groups. Diameter, height and volume of the treated lesions were determined at each visit (Figure 2). There were no statistically significant differences in wart dimensions comparing CY-002 and placebo over time. Both the lesions treated with CY-002 and placebo showed reduction in lesion volume within the first week of treatment persisting until the end of study, although the difference between treatment groups was not statistically significant ( $p=0.0896$ ).

### HPV TYPE AND LOAD

The predominant HPV types found >50% of patients were HPV type 27 and 57 (Table 1). HPV viral load decreased within the first week after treatment initiation in both the CY-002 and placebo group (Figure 3), with high variability found between samples (range  $4.1477-3.10^9$  copies/mL). For CY-002, the HPV viral load remained reduced at the end of treatment (-73.4%) and up until the end of study (-80.2%). After placebo, a decrease in HPV viral load was observed in the first week, but the results varied during the remainder of the study period (+6.2 at end of treatment, -78.4% at end of study). There were no significant differences between the groups or over time, probably due to high variability observed between samples.

### MULTI-MODAL RESPONDER/NON-RESPONDER EVALUATION

Conventional 2D photography, 3D reconstructions and cross-sectional OCT images showed changes in wart characteristics and morphology over time for the CY-002 partial responder (Figure 4A), but not for the placebo non-responder (Figure 4B). HPV load reduced considerably following the first week of CY-002 treatment (Figure 4C), although a spike occurred at follow-up. Morphologically, the responding wart showed extensive roughness and epithelial hyperintensity at baseline in the OCT cross-sectional slides. This signifies a thick epithelium with considerable callous, which can also be seen in the 2D images. The level of roughness and hyperintensity were not present at end of treatment and end of study, although it was observed at follow-up, concurring with HPV-load finding and the 2D images. No distinct morphological changes over time were observed in the placebo subject. HPV load changes in the placebo subject were also less pronounced with no clear pattern.

## Discussion

This first-in-human study shows for the first time that topical CY-002 is safe and well tolerated after 4-week treatment. In this study, no statistically significant effect on reduction of wart number, size or HPV load was discerned between treatment and placebo. This poses considerations on mode of action, placebo formulation, drug delivery, and adequate dosing regimen as well as statistical power of the study. Yet, as shown in Figure 2 and Figure 3, the lesions treated with CY-002 showed a potential trend in volume and HPV-load reduction at end of treatment, during follow-up and at end of study. To further substantiate these results, increasing and aligning patient groups with different drug delivery strategies should be considered. Of note, the clearance of  $\geq 1$  warts in the placebo group was pronounced (11.5%). Other recent cutaneous warts trial investigating topicals presented 0–11.6% clearance in placebo groups.<sup>25,29</sup> In addition, one recent study with occlusion of a topical reported complete clearance in 1 subject (3.4%) and partial clearance in 1 subject (3.4%) within the placebo group.<sup>30</sup> In this study, the placebo group included more treatment-naïve patients compared to the CY-002 group (imbalance of 67.9% versus 33.3%). It should be emphasized that warts exposed to prior, unsuccessful therapy may be more resistant to other treatments.<sup>31</sup> All placebo patients showing response in this trial were treatment-naïve. In contrast, 75% of responders receiving CY-002 had a previous history of salicylic acid use. Although this small group size does not allow formal comparisons, this observation could partially explain the relatively high placebo response in this study compared to CY-002. This first-in-human study was primarily aimed at assessing the safety and tolerability of CY-002 and was not powered for efficacy.

Early-phase dermatology trials are increasingly introduced to novel techniques for effect exploration guiding drug development.<sup>32</sup> This study presents a combined phenotypical lesion follow-up of a responder and non-responder (Figure 4). The addition of 3D photography, HPV load and OCT imaging to conventional wart count allows for detailed observation, suggesting minor changes in HPV load and wart morphology although no effect was observed at group level. Additionally, a trend in partial response was discernible after 16 weeks at the end of study (CY-002 43%, placebo 29%,  $p=0.0940$ ). Although full lesion clearance is the clinically relevant outcome for wart trials,<sup>19</sup> these positive exploratory observations may substantiate further develop-

ment of CY-002 for the indication of cutaneous warts at different dose levels. The rationale for investigating CY-002 as possible treatment for cutaneous warts comes from its cytolytic activity in malignant neoplasia and its intended mechanism of action directly targeting the HPV-infected cell and subsequently mounting an immune response against HPV.<sup>20</sup> Several potential topical and intralesional compounds targeting immune activation are under investigation, especially for recalcitrant warts and immunocompromised patients.<sup>33,34</sup> Topically, the TLR-7 agonist imiquimod has shown complete wart clearance of 27–89% in immunocompetent and 33–50% in immunocompromised patients in a recent literature review.<sup>35</sup> Intralesional injections of bleomycin have shown 70–95% response rates of treated warts.<sup>36</sup> Administration pain and local blistering limits intralesional application as first-line treatment, prompting development of topical bleomycin spray following several wart abrasion strategies to optimize drug delivery.<sup>37,38</sup> Intralesional *C. albicans* antigen therapy has shown additional efficacy against distant, untreated lesions<sup>39</sup>, as have intralesional Bacillus Calmette-Guérin (BCG) vaccine derivatives.<sup>40</sup> Recent trials including an intralesional saline control report wart clearance of 0–40%, showing the marked effect of vehicle or manipulation potentially confounding therapeutic observations.<sup>40–46</sup>

The main strength of this study is its two-tiered design of a first-in-human trial to a novel topical compound in which safety was investigated without compromising on exploring efficacy parameters. Most first-in-human, Phase I trials are carried out clinically for safety surveillance. Here, safety and tolerability could be closely monitored by starting with a run-in population of 8 patients during the in-clinic part with focusing on potential systemic exposure.<sup>47</sup> The subsequent ambulatory phase with weekly follow-up allowed for evaluation of safety with exploration of efficacy. Wart treatment trials have essential challenges and limitations, which add to the low level of evidence for most wart therapy modalities.<sup>19,48</sup> Therefore, this study focused on recognizing and removing potential confounders from its design. Within-subject placebo-control studies ('left-right studies') are flawed as a response of distant warts may occur.<sup>19,49,50</sup> Indeed, recent topical wart trials have reported treatment effects on distant, untreated warts, citing immune activation as a possible explanation.<sup>25,51</sup> A biopsy was only obtained after 16 weeks at the end of this study, as potential effects may also apply to concomitant therapy or interventions on distant lesions.<sup>23,52</sup>

The putative limitation of this study is the lack of confirmation that CY-002 reaches HPV-infected keratinocytes and induces cell death *in vivo*. There was no systemic exposure of CY-002, which is beneficial considering potential systemic effects. However, this may imply lack of dermal penetration. Any interventions to enhance drug delivery may act as a confounder on treatment efficacy, illustrated by the marked placebo effect of intralesional saline injections. Overnight occlusion was included in this study to increase the likelihood of transdermal penetration despite potential confounding. Transdermal drug delivery always poses a key question in dermatology trials.<sup>53,54</sup> This is even more challenging with calloused cutaneous warts. Even salicylic acid, the golden standard in topical treatment, requires erosive intervention.<sup>19</sup> Other experimental wart treatment modalities are often accompanied by drug-delivery enhancing, abrasive methods such as microneedling, tape stripping or lesion shaving, especially in plantar warts.<sup>55–57</sup>

In conclusion, topical CY-002 is considered safe and tolerable when used daily up to 28 consecutive days with no systemic exposure. There was no significant reduction of wart size, number or HPV load comparing active treatment to placebo, although a higher partial response was observed in the warts treated with CY-002. A noteworthy observation in this study is an unprecedented placebo response, which may be the result of overnight occlusion. The design of this data-rich trial with a first-in-its-class topical treatment with a clinical safety run-in followed by ambulatory application allows for in-depth exploration of efficacy parameters without compromising on primary assessment of novel topical compound safety and tolerability.

**Table 1 Baseline characteristics.**

Characteristic	Safety run-in		Ambulatory trial	
	CY-002 (n=4)	Placebo (n=4)	CY-002 (n=27)	Placebo (n=28)
Age (years), mean (SD)	31.0 (9.4)	23.0 (4.7)	28.1 (11.4)	25.1 (9.9)
SEX, N (%)				
Male	3 (75.0)	2 (50.0)	14 (51.9)	12 (42.9)
Female	1 (25.0)	2 (50.0)	13 (48.1)	16 (57.1)
FITZPATRICK SKIN TYPE, N (%)				
I	1 (25.0)	1 (25.0)	2 (7.4)	3 (10.7)
II	3 (75.0)	2 (50.0)	13 (48.1)	12 (42.9)
III	0 (0)	1 (25.0)	7 (25.9)	8 (28.6)
IV	0 (0)	0 (0)	4 (14.8)	3 (10.7)
V	0 (0)	0 (0)	0 (0)	2 (7.1)
VI	0 (0)	0 (0)	1 (3.7)	0 (0)
Height (cm), mean (SD)	174.0 (10.0)	177.9 (16.9)	177.6 (9.5)	174.1 (8.0)
Weight (kg), mean (SD)	69.9 (7.2)	71.5 (11.0)	72.8 (10.0)	72.0 (10.6)
BMI (kg/m <sup>2</sup> ), mean (SD)	23.2 (1.5)	22.8 (4.4)	23.1 (3.0)	23.8 (3.3)
WART CHARACTERISTICS				
Wart age (years), mean (SD)	1.88 (2.77)	5 (4.69)	2.32 (1.54)	1.92 (1.26)
Total warts per patient (n), mean (SD)	2 (2)	1 (0)	3.56 (3.26)	3.04 (2.3)
Treated warts per patient (n), mean (SD)	1.5 (1)	1 (0)	1.93 (0.96)	2 (0.9)
Long diameter of treated warts (mm), mean (SD)	6.12 (2.5)	4.95 (1.5)	4.61 (1.83)	4.31 (1.7)
Short diameter of treated warts (mm), mean (SD)	4.45 (1.38)	3.95 (1.48)	3.73 (1.36)	3.49 (1.25)
Height of treated warts (mm), mean (SD)	1.32 (0.59)	1.28 (0.34)	0.84 (0.53)	0.83 (0.6)
HPV TYPE OF TARGET WART, N (%)				
HPV2/zvar	0 (0)	2 (50)	3 (11.1)	5 (17.8)
HPV4	0 (0)	0 (0)	2 (7.4)	4 (14.3)
HPV27	1 (25.0)	0 (0)	8 (29.6)	8 (28.6)
HPV57	3 (75.0)	1 (25.0)	8 (29.6)	6 (21.4)
HPV65*	0 (0)	0 (0)	1 (3.7)	1 (3.6)
Other**	0 (0)	0 (0)	2 (7.4)	2 (7.1)
Missing	0 (0)	1 (25.0)	2 (7.4)	2 (7.1)

(continuation Table 1)

PREVIOUS WART TREATMENT, N (%)				
Cryotherapy, n (%)	1 (25.0)	2 (50.0)	11 (40.7)	7 (25.0)
Salicylic acid	2 (50.0)	2 (50.0)	10 (37.0)	4 (14.3)
Mono/bi/trichloroacetic acid	1 (25.0)	0 (0)	0 (0)	0 (0)
Surgical excision	1 (25.0)	0 (0)	0 (0)	1 (3.6)
Other ***	0 (0)	1 (25.0)	0 (0)	0 (0)
No previous wart treatment	2 (50.0)	1 (25.0)	9 (33.3)	19 (67.9)

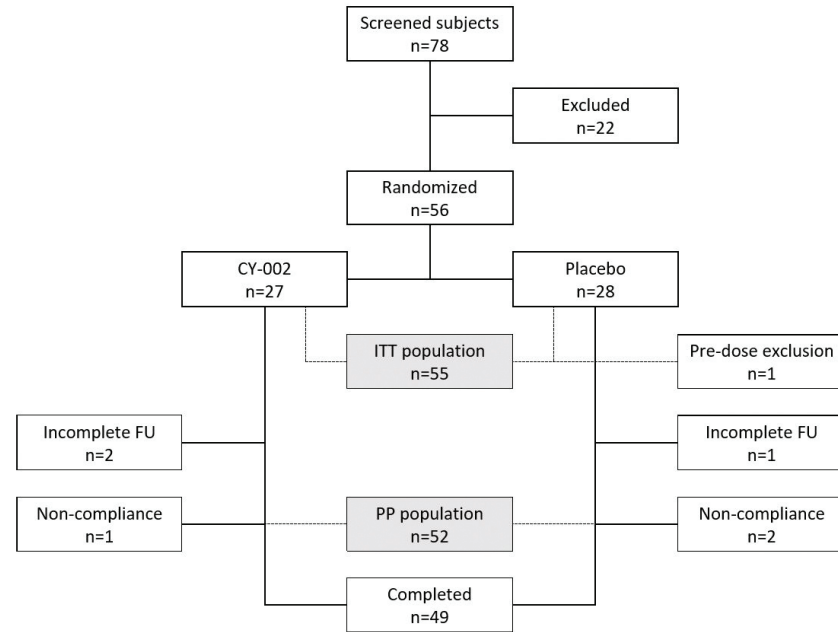
HPV = Human papillomavirus. \* HPV65 was found as a co-infection with HPV4 in 2 patients from the placebo group. \*\* Other HPV types which were reported once included HPV3, HPV10, HPV88 and HPV95. \*\*\* Homeopathic topical formulation. Display of the intention to treat (ITT) population.

**Table 2 Cutaneous wart clearance.**

	CY-002 N=26 Treated warts = 51	Placebo N=26 Treated warts = 51	p-value
Subjects with clearance of all treated warts at EOS, N (%)	2 (7.7)	1 (3.8)	0.6092
Subjects with clearance of at least 1 wart at EOS, N (%)	4 (15.4)	3 (11.5)	0.7019
Treated warts completely cleared at EOT (Day 28), N (%)	0 (0)	1 (2)	1.0000
Treated warts completely cleared at EOS (Day 112), N (%)	6 (12)	4 (8)	0.5162
Treated warts with partial clearance at EOT (Day 28), N (%)	21 (41)	13 (25)	0.0962
Treated warts with partial clearance at EOS (Day 112), N (%)	22 (43)	15 (29)	0.0940

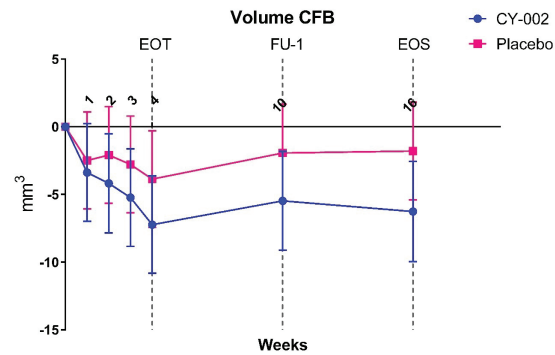
\*Partial clearance was defined as >50% reduction in wart volume. Analysis performed on the per protocol (PP) population. EOT = End of Treatment, EOS = End of Study.

**Figure 1 Study flow chart.**



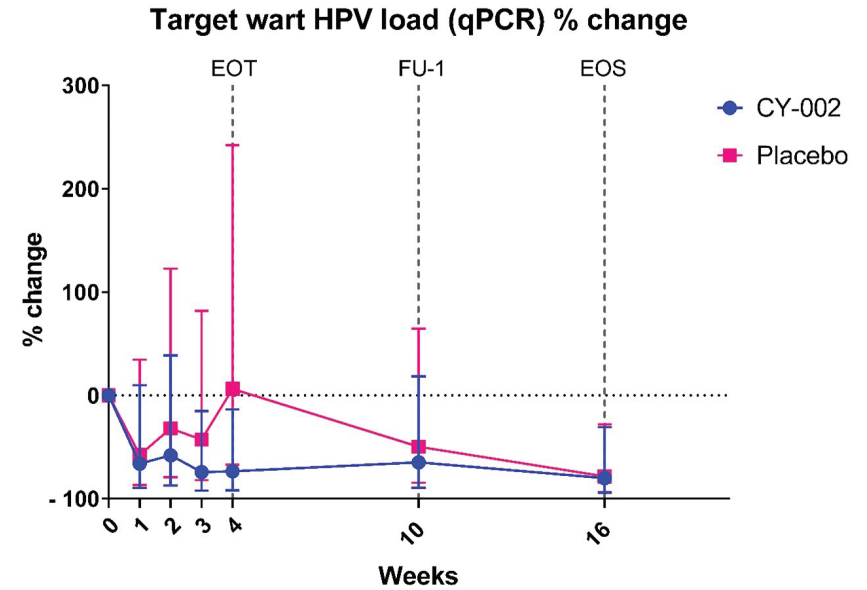
ITT = intention-to-treat population. PP = per-protocol population. FU = follow-up.

**Figure 2 Volume change of cutaneous warts over time.** In blue, active treatment with CY-002 is shown. In pink, placebo is shown.



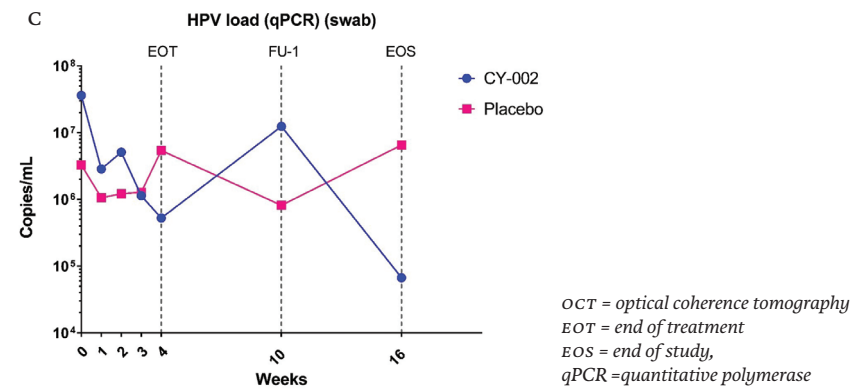
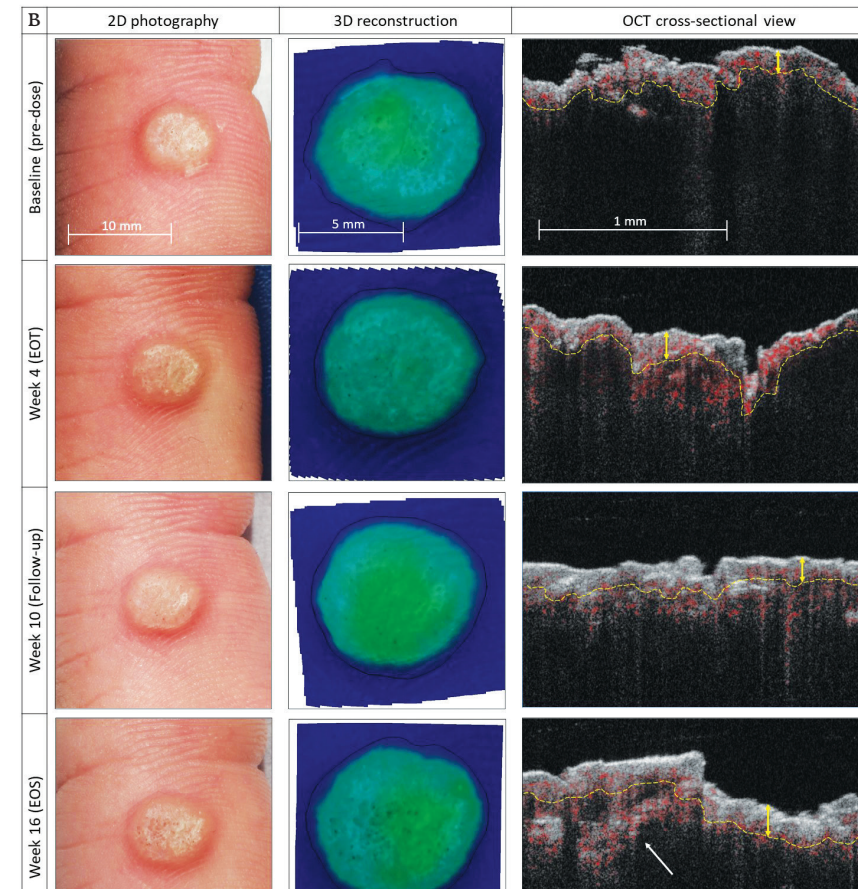
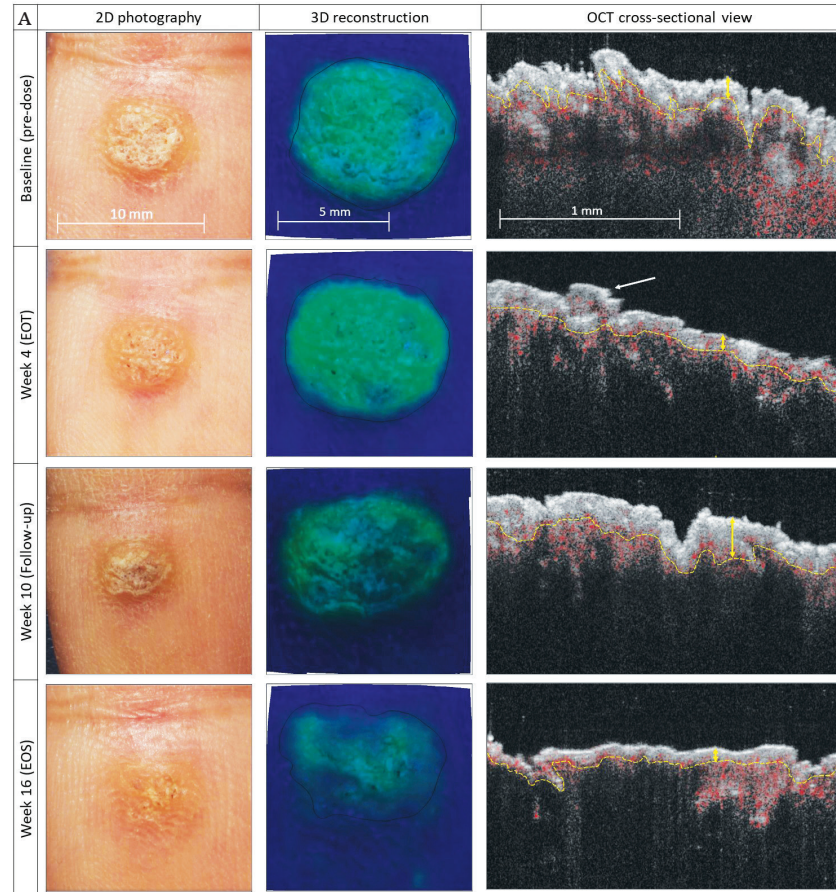
CFB = change from baseline. EOT = end-of-treatment. FU-1 = follow-up visit 1. EOS = end-of-study.

**Figure 3 HPV load of target wart, percentage change over time.** In blue, active treatment with CY-002 is shown. In pink, placebo is shown.



HPV = human papillomavirus. EOT = end-of-treatment. FU-1 = follow-up visit 1. EOS = end-of-study, qPCR: quantitative polymerase chain reaction

**Figure 4 Multimodal analysis of responders and non-responders using imaging and sequencing techniques.** Imaging techniques shown include conventional photography, stereophotogrammetric three-dimensional photography and optical coherence tomography analysis. A) Individual randomised to active treatment with CY-002. B) Individual randomised to Placebo. C) HPV load as determined by qPCR.



**Supplementary Table 1** Wart morphology of target wart at baseline according to CWARTS during the ambulatory trial.

CWARTS characteristic of TW		CY-002 (n=27)	Placebo (n=28)
Arrangement	Confluent	2 (7.4%)	1 (3.6%)
	Solitary	25 (92.6%)	27 (96.4%)
Level	Elevated	22 (81.4%)	23 (85.2%)
	Skin level	5 (18.5%)	5 (17.9%)
Aspect	Rough/lobed	19 (70.3%)	19 (67.9%)
	Smooth/not lobed	8 (29.6%)	9 (32.1%)
Border	Sharp	23 (85.2%)	23 (82.1%)
	Unsharp	4 (14.8%)	5 (17.9%)
Colour	Skin colour	8 (29.6%)	8 (28.6%)
	Lighter than skin	5 (18.5%)	4 (14.3%)
	White	8 (29.6%)	11 (39.3%)
	Red	5 (18.5%)	3 (10.7%)
	Dark	1 (3.7%)	2 (7.1%)
White skin flakes	Present	16 (59.3%)	21 (75.0%)
	Absent	11 (40.7%)	7 (25.0%)
Capillary thrombosis	Present	13 (48.1%)	13 (46.4%)
	Absent	14 (51.9%)	15 (53.6%)
Border erythema	Present	10 (37.0%)	8 (28.6%)
	Absent	17 (63.0%)	20 (71.4%)
Callus	Present	12 (44.4%)	13 (46.4%)
	Absent	15 (55.6%)	15 (53.6%)

CWARTS = cutaneous WARTS, TW = target wart

**Supplementary Table 2** Treatment Emergent Adverse Events – Analysis of the Intention to Treat (ITT) population.

	Safety run-in		At-home trial	
	CY-002 (N=4)	Placebo (n=4)	CY-002 (N=27)	Placebo (n=28)
Total reported adverse events (% subjects)	12 (100%)	8 (75%)	11 (33.3%)	12 (39.3)
Gastrointestinal symptoms	3 (50%)	1 (25%)	1 (3.7%)	0
Application site pain	0	0	1 (3.7%)	0
Skin abrasion*	1 (25%)	1 (25%)	1 (3.7%)	0
Dermatitis**	1 (25%)	0	0	0
Pruritus***	2 (50%)	1 (25%)	0	0
Cystitis	0	0	0	1 (3.6%)
Skin infection****	0	0	0	2 (7.1%)
Upper respiratory tract infection	1 (25%)	1 (25%)	4 (14.8%)	5 (17.8%)
Respiratory tract infection	0	0	0	1 (3.6%)
Influenza like illness	0	0	1 (3.7%)	2 (7.1%)
Headache	3 (75%)	3 (75%)	1 (3.7%)	0
Increased transaminases	1 (25%)	0	0	0
Musculoskeletal pain	0	1 (25%)	1 (3.7%)	1 (3.6%)
Wrist fracture	0	0	1 (3.7%)	0

\* Caused by occlusive tape. One patient in Part 2 discontinued treatment on wart #3 / \*\* Caused by ECG lead adhesive / \*\*\* Reported on target area on the back where study drug was applied / \*\*\*\* One subject reported an infection on his foot, 1 patient reported impetigo on the axilla.

**Supplementary Figure 1 Study design of run-in trial.**

	Baseline ↓							EOT ↓	EOS ↓	
Day	0	1	2	3	4	5	6	7	14	28
In clinic	X	X	X	X	X	X	X	X		
Outpatient visit									X	X
Treatment application lesions	X	X	X	X	X	X	X	X		
Treatment application healthy skin	X	X	X	X	X	X	X	X		
Safety assessments	X	X	X	X	X	X	X	X	X	X
Efficacy assessments	X	X		X		X		X	X	X
Biopsy										X

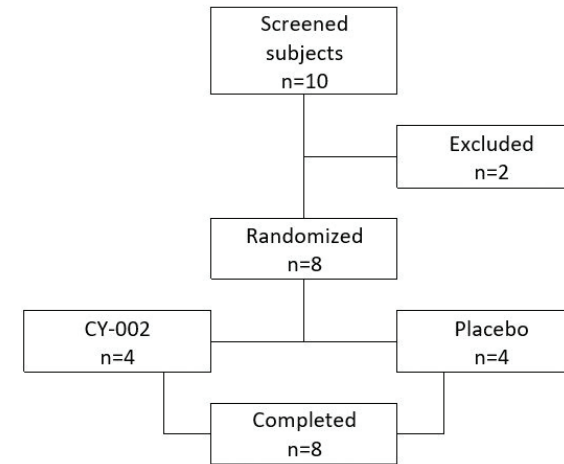
*EOT = end of treatment, EOS = end of study*

**Supplementary Figure 2 Study design of ambulatory trial.**

	Baseline ↓				EOT ↓	EOS ↓	
Day	0	7	14	21	28	70	112
Week	0	1	2	3	4	10	16
Outpatient visit	X	X	X	X	X	X	X
Safety assessments	X	X	X	X	X	X	X
Efficacy measurements	X	X	X	X	X	X	X
Biopsy							X

*EOT = end of treatment, EOS = end of study*

**Supplementary Figure 3 Flow-Chart of the run-in trial.**



REFERENCES

1 Williams HC, Pottier A, Strachan D. The descriptive epidemiology of warts in British schoolchildren. *Br J Dermatol.* 1993;128(5):504-511. doi:10.1111/j.1365-2133.1993.tb00226.x

2 van Haalen FM, Bruggink SC, Gusssekloo J, Assendelft WJJ, Eekhof JAH. Warts in primary schoolchildren: prevalence and relation with environmental factors. *Br J Dermatol.* 2009;161(1):148-152. doi:10.1111/j.1365-2133.2009.09160.x

3 Kilkenny M, Merlin K, Young R, Marks R. The prevalence of common skin conditions in Australian school students: 1. Common, plane and plantar viral warts. *Br J Dermatol.* 1998;138(5):840-845. doi:10.1046/j.1365-2133.1998.02222.x

4 Johnson MT, Roberts J. Skin conditions and united need for medical care among persons 1-74 years. *United States, 1971-1974.* *Vital Health Stat 11.* 1978;(212):i-v, 1-72.

5 Beliaeva TL. [The population incidence of warts]. *Vestn Dermatol Venerol.* 1990;(2):55-58.

6 Bzhalava D, Mühr LSA, Lagheden C, et al. Deep sequencing extends the diversity of human papillomaviruses in human skin. *Sci Rep.* 2014;4:5807. doi:10.1038/srep05807

7 Bruggink SC, de Koning MNC, Gusssekloo J, et al. Cutaneous wart-associated HPV types: prevalence and relation with patient characteristics. *J Clin Virol Off Publ Pan Am Soc Clin Virol.* 2012;55(3):250-255. doi:10.1016/j.jcv.2012.07.014

8 Hagiwara K, Uezato H, Arakaki H, et al. A genotype distribution of human papillomaviruses detected by polymerase chain reaction and direct sequencing analysis in a large sample of common warts in Japan. *J Med Virol.* 2005;77(1):107-112. doi:10.1002/jmv.20421

9 Cicone A, Campbell J, Tabrizi S, Garland S, Marks R. Warts are not merely blemishes on the skin: A study on the morbidity associated with having viral cutaneous warts. *Australas J Dermatol.* 2003;44(3):169-173. doi:10.1046/j.1440-0960.2003.00672.x

10 Zachariae C, Sand C, Hansen J, et al. Warts in a Cohort of Danish Kidney Transplanted Patients: Impact on Quality of Life. *Acta Derm Venereol.* 2012;92(6):615-618. doi:10.2340/00015555-1377

11 Akdoğan N, Yıldırım SK, Kültür E, Evans SE. The effect of warts on quality of life in Turkish pediatric patients. *Turk J Pediatr.* 2020;62(6):1028. doi:10.24953/turkjped.2020.06.015

12 Bruggink SC, Eekhof JAH, Egberts PF, van Blijswijk SCE, Assendelft WJJ, Gusssekloo J. Warts transmitted in families and schools: a prospective cohort. *Pediatrics.* 2013;131(5):928-934. doi:10.1542/peds.2012-2946

13 Massing AM, Epstein WL. Natural history of warts. A two-year study. *Arch Dermatol.* 1963;87:306-310. doi:10.1001/archderm.1963.01590150022004

14 Bruggink SC, Waagmeester SC, Gusssekloo J, Assendelft WJJ, Eekhof JAH. Current choices in the treatment of cutaneous warts: a survey among Dutch GP. *Fam Pract.* 2010;27(5):549-553. doi:10.1093/fampira/cm047

15 Pezeshkpoor F, Banihashemi M, Yazdanpanah MJ, Yousefzadeh H, Sharghi M, Hoesinzadeh H. Comparative study of topical 80% trichloroacetic acid with 35% trichloroacetic acid in the treatment of the common wart. *J Drugs Dermatol.* 2012;11(11):e66-9.

16 Kwok CS, Gibbs S, Bennett C, Holland R, Abbott R. Topical treatments for cutaneous warts. *Cochrane database Syst Rev.* 2012;(9):CD001781. doi:10.1002/14651858.CD001781.pub3

17 Bourke JF, Berth-Jones J, Hutchinson PE. Cryotherapy of common viral warts at intervals of 1, 2 and 3 weeks. *Br J Dermatol.* 1995;132(3):433-436. doi:10.1111/j.1365-2133.1995.tb08678.x

18 Finley C, Korownyk C, Kolber MR. What works best for nongenital warts? *Can Fam Physician.* 2016;62(12):997.

19 Sterling JC, Gibbs S, Haque Hussain SS, Mohd Mustapa MF, Handfield-Jones SE. British Association of Dermatologists' guidelines for the management of cutaneous warts 2014. *Br J Dermatol.* 2014;171(4):696-712. doi:10.1111/bjd.13310

20 Szczepanski C, Tenstad O, Baumann A, et al. Identification of a novel lytic peptide for the treatment of solid tumours. *Genes Cancer.* 2014;5(5-6):186-200. doi:10.18632/genesandcancer.18

21 Rijsbergen M, Niemeyer-van der Kolk T, Rijneveld R, et al. Mobile e-diary application facilitates the monitoring of patient-reported outcomes and a high treatment adherence for clinical trials in dermatology. *J Eur Acad Dermatol Venerol.* 2020;34(3):633-639. doi:10.1111/jdv.15872

22 De Geest S, Sabaté E. Adherence to long-term therapies: Evidence for action. *Eur J Cardiovasc Nurs.* 2003;2(4):323. doi:10.1016/S1474-5151(03)00091-4

23 de Koning MNC, Khoe L V, Eekhof JAH, et al. Lesional HPV types of cutaneous warts can be reliably identified by surface swabs. *J Clin Virol Off Publ Pan Am Soc Clin Virol.* 2011;52(2):84-87. doi:10.1016/j.jcv.2011.06.016

24 de Koning MNC, ter Schegget J, Eekhof JAH, et al. Evaluation of a novel broad-spectrum PCR-multiplex genotyping assay for identification of cutaneous wart-associated human papillomavirus types. *J Clin Microbiol.* 2010;48(5):1706-1711. doi:10.1128/JCM.02122-09

25 Rijsbergen M, Niemeyer-van der Kolk T, Hogendoorn G, et al. A randomized controlled proof-of-concept trial of digoxin and furosemide in adults with cutaneous warts. *Br J Dermatol.* 2019;180(5):1058-1068. doi:10.1111/bjd.17583

26 Rijsbergen M, Pagan L, Niemeyer-van der Kolk T, et al. Stereophotogrammetric three-dimensional photography is an accurate and precise planimetric method for the clinical visualization and quantification of human papilloma virus-induced skin lesions. *J Eur Acad Dermatol Venerol.* Published online 2019. doi:10.1111/jdv.15474

27 Hogendoorn GK, Bruggink SC, Hermans KE, et al. Developing and validating the Cutaneous WARTS (CWARTS) diagnostic tool: a novel clinical assessment and classification system for cutaneous warts. *Br J Dermatol.* 2018;178(2):527-534. doi:10.1111/bjd.15999

28 Hogendoorn GK, Bruggink SC, de Koning MNC, et al. Morphological characteristics and human papillomavirus genotype predict the treatment response in cutaneous warts. *Br J Dermatol.* 2018;178(1):253-260. doi:10.1111/bjd.15758

29 Smith S, Trying S, Grande K, Schlessinger J, Gold M, Shanier S. Hydrogen Peroxide Topical Solution, 45% for Common Warts: Phase 2 Efficacy and Safety Trial Results. *J Drugs Dermatol.* 2020;19(10):969-976. doi:10.36849/JDD.2020.5054

30 Mahran AM, Twisy HO, Elghazally SA, Badran AY. Evaluation of different concentrations of hydrogen peroxide solution (3% and 6%) as a potential new therapeutic option of nongenital warts: A randomized controlled triple-blinded clinical trial. *J Cosmet Dermatol.* 2020;19(2):416-422. doi:10.1111/jocd.13021

31 Leerunyakul K, Thammarucha S, Suchonwanit P, Rutnain S. A comprehensive review of treatment options for recalcitrant nongenital cutaneous warts. <https://doi.org/10.1080/09546634.2020.1737635>. Published online 2020. doi:10.1080/09546634.2020.1737635

32 Rissmann R, Moerland M, van Doorn MBA. Blueprint for mechanistic, data-rich early phase clinical pharmacology studies in dermatology. *Br J Clin Pharmacol.* Published online 2020. doi:10.1111/bcp.14293

33 Thappa DM, Chiramel MJ. Evolving role of immunotherapy in the treatment of refractory warts. *Indian Dermatol Online J.* 2016;7(5):364. doi:10.4103/2229-5178.190487

34 García-Oreja S, Álvaro-Afonso FJ, García-Álvarez Y, García-Morales E, Sanz-Corbalán I, Lázaro Martínez JL. Topical treatment for plantar warts: A systematic review. *Dermatol Ther.* 2021;34(1). doi:10.1111/dth.14621

35 Ahn CS, Huang WW. Imiquimod in the Treatment of Cutaneous Warts: An Evidence-Based Review. *Am J Clin Dermatol.* 2014;15(5):387-399. doi:10.1007/s40257-014-0093-5

36 Soni P, Khandelwal K, Aara N, Ghiya BC, Mehta RD, Bumb RA. Efficacy of Intralesional Bleomycin in Palmo-plantar and Periungual Warts. *J Cutan Aesthet Surg.* 2011;4(3):188. doi:10.4103/0974-2077.91250

37 Al-Naggar MR, Al-Adl AS, Rabie AR, Abdelkhalik MR, Elsaie ML. Intralesional bleomycin injection vs microneedling-assisted topical bleomycin spraying in treatment of plantar warts. Published online 2018. doi:10.1111/jocd.12537

38 Kaul S, Kaur I, Jakhar D, Edigin E, Caldito EG. The diverse methods of bleomycin delivery in cutaneous warts: A literature review. *Dermatol Ther.* 2021;34(1). doi:10.1111/dth.14401

39 Hodeib AAE, Al-Sharkawy BG, Hegab DS, Talaat RAZ. A comparative study of intralesional injection of Candida albicans antigen, bleomycin and 5-fluorouracil for treatment of plane warts. *J Dermatolog Treat.* Published online November 12, 2019;1-6. doi:10.1080/09546634.2019.1688236

40 Ebrahim HM, Asaad AM, El desoky F, Morsi HM. Bacillus Calmette-Guerin polysaccharide nucleic acid vs Bacillus Calmette-Guerin vaccine in the treatment of warts: A comparative, double-blind, controlled study. *Dermatol Ther.* 2021;34(1). doi:10.1111/dth.14549

41 Awal G, Kaur S. Therapeutic Outcome of Intralesional Immunotherapy in Cutaneous Warts Using the Mumps, Measles, and Rubella Vaccine: A Randomized, Placebo-controlled Trial. *J Clin Aesthet Dermatol.* 2018;11(5):15. Accessed August 3, 2021. /pmc/articles/PMC5955628/

42 Ibrahim AM, Elkot RA, Khashaba SA. Successful Treatment of Multiple Common Warts With Intralesional Ozone. *Dermatologic Surg.* 2020;46(7):928-933. doi:10.1097/DSS.0000000000002174

43 El Sayed MH, Sayed FS, Afify AA. Intralesional zinc sulfate 2% vs intralesional vitamin D in plantar warts: A clinicodermoscopic study. *Dermatol Ther.* 2020;33(3). doi:10.1111/dth.13308

44 Nofal A, Yehia E, Khater E, Bessar H. Alternating intralesional purified protein derivative and Candida antigen versus either agent alone in the treatment of multiple common warts. *J Am Acad Dermatol.* 2020;83(1):208-210. doi:10.1016/j.jaad.2020.01.054

45 Kareem IMA, Ibrahim IM, Mohammed SFF, Ahmed AA. Effectiveness of intralesional vitamin D 3 injection in the treatment of common warts: Single-blinded placebo-controlled study. *Dermatol Ther.* 2019;32(3). doi:10.1111/dth.12882

46 Abdo HM, Elrewny EM, Elkholy MS, Ibrahim SM. Efficacy of intralesional methotrexate in the treatment of plantar warts. *Dermatol Ther.* 2020;33(2). doi:10.1111/dth.13228

47 van der Kolk T, Dillingh MR, Rijneveld R, et al. Topical ionic contra-viral therapy comprised of digoxin and furosemide as a potential novel treatment approach for common warts. *J Eur Acad Dermatol Venerol.* 2017;31(12):2088-2090. doi:10.1111/jdv.14527

48 Oren-Shabtai M, Snast I, Noyman Y, et al. Topical and systemic retinoids for the treatment of cutaneous viral warts: A systematic review and meta-analysis. *Dermatol Ther.* 2021;34(1). doi:10.1111/DTH.14637

49 Adalatkhah H, Khalilollahi H, Amini N, Sadeghi-Bazargani H. Compared therapeutic efficacy between intralesional bleomycin and cryotherapy for common warts: A randomized clinical trial. *Dermatol Online J.* 2007;13(3). doi:10.5070/D362GoG3MJ

50 Bohlooli S, Mohebbipour A, Mohammadi S, Kouhnavard M, Pashapoor S. Comparative study of fig tree efficacy in the treatment of common warts (*Verruca vulgaris*) vs. cryotherapy. *Int J Dermatol.* 2007;46(5):524-526. doi:10.1111/j.1365-4632.2007.03159.x

51 Shaheen MA, Salem SAM, Fouad DA, El-Fatah AAA. Intralesional tuberculin (PPD) versus measles, mumps, rubella (MMR) vaccine in treatment of multiple warts: A comparative clinical and immunological study. *Dermatol Ther.* 2015;28(4):194-200. doi:10.1111/dth.12230

52 Nofal A, Nofal E, Yosef A, Nofal H. Treatment of recalcitrant warts with intralesional measles, mumps, and rubella vaccine: A promising approach. *Int J Dermatol.* 2015;54(6):667-671. doi:10.1111/ijd.12480

53 Hadgraft J, Lane ME. Skin permeation: The years of enlightenment. *Int J Pharm.* 2005;305(1-2):12-12. doi:10.1016/J.IJPHARM.2005.07.014

54 Trommer H, Neubert RHH. Overcoming the Stratum Corneum: The Modulation of Skin Penetration. *Skin Pharmacol Physiol.* 2006;19(2):106-121. doi:10.1159/000091978

55 Huang K, Xie Y, Li M, et al. A Comparative Study: Superficial Shaving Combined With Photodynamic Therapy Versus Cryotherapy in the Treatment of Recalcitrant Plantar Warts. *Lasers Surg Med.* 2020;52(8):747-752. doi:10.1002/lsm.23212

56 Sumi E, Nomura T, Asada R, et al. Safety and Plasma Concentrations of a Cyclin-dependent Kinase 9 (CDK9) Inhibitor, FIT039, Administered by a Single Adhesive Skin Patch Applied on Normal Skin and Cutaneous Warts. *Clin Drug Investig.* 2019;39(1):55. doi:10.1007/S40261-018-0712-7

57 Hashmi F, Fairhurst C, Cockayne S, et al. The EVerT2 (Effective Verruca Treatments 2) trial: a randomized controlled trial of needling vs. nonsurgical debridement for the treatment of plantar verrucae. *Br J Dermatol.* 2017;177(5):1285-1292. doi:10.1111/bjd.15751

## SECTION II

---

# THE VULVAR MICROBIOME

## The human vulvar microbiome: a systematic review

Published in *Microorganisms*, 2021. Doi: 10.3390/microorganisms9122568

Lisa Pagan<sup>1,2,\*</sup>, Roos A. M. Ederveen<sup>3,4,\*</sup>, Bertine W. Huisman<sup>1,2</sup>,  
Jan W. Schoones<sup>5</sup>, Romy D. Zwittink<sup>6</sup>, Frank H. J. Schuren<sup>7,8</sup>,  
Robert Rissmann<sup>1,8,9</sup>, Jurgen M. J. Piek<sup>4</sup> and Mariëtte I. E. van Poelgeest<sup>1,2</sup>

*\*Both authors contributed equally.*

---

- 
- 1 Centre for Human Drug Research, Leiden, NL
  - 2 Department of Gynaecology and Obstetrics LUMC, Leiden, NL
  - 3 Maastricht University Medical Centre, Maastricht, NL
  - 4 Department of Obstetrics and Gynaecology, Catharina Ziekenhuis, Eindhoven, NL
  - 5 Directorate of Research Policy, LUMC, Leiden NL
  - 6 Center for Microbiome Analyses and Therapeutics, LUMC, Leiden, NL
  - 7 Netherlands Organisation for Applied Scientific Research, TNO, Zeist, NL
  - 8 Leiden Skin Institute, Leiden, NL
  - 9 Leiden Amsterdam Center for Drug Research, Leiden University, Leiden, NL

## Abstract

The link between cancer and the microbiome is a fast-moving field in research. There is little knowledge on the microbiome in ((pre)malignant) conditions of the vulvar skin. This systematic review aims to provide an overview of the literature regarding the microbiome composition of the healthy vulvar skin and in (pre)malignant vulvar disease. This study was performed according to the PRISMA guidelines. A comprehensive, electronic search strategy was used to identify original research articles (updated September 2021). The inclusion criteria were articles using culture-independent methods for microbiome profiling of the vulvar region. Ten articles were included. The bacterial composition of the vulva consists of several genera including *Lactobacillus*, *Corynebacterium*, *Staphylococcus* and *Prevotella*, suggesting that the vulvar microbiome composition shows similarities with the corresponding vaginal milieu. However, the vulvar microbiome generally displayed higher diversity with commensals of cutaneous and faecal origin. This is the first systematic review that investigates the relationship between microbiome and vulvar (pre)malignant disease. There are limited data and the level of evidence is low with limitations in study size, population diversity and methodology. Nevertheless, the vulvar microbiome represents a promising field for exploring potential links for disease aetiology and targets for therapy.

## Introduction

The human skin is a complex barrier organ and consists of a symbiosis between host tissue and a large aggregate of microorganisms including bacteria, viruses, and fungi, known as microbiota. The microbiome is the composition of all microbial taxa and their genes within a community.<sup>1</sup> The human microbiome plays a key role in health and has been linked to several disease conditions, including inflammatory diseases, skin conditions and cancer.<sup>2-4</sup> Following recent publications in solid cancer types and their pre-cursors, the link between the development of cancer and the microbiome is a fast-moving field in the area of cancer research.<sup>5-7</sup> Several micro-organisms are well-known for their oncogenic potential, such as human papillomavirus (HPV) in cervical carcinoma and *Helicobacter pylori* in gastric cancer, prompting effective and targeted vaccine and treatment rollout.<sup>8,9</sup> Recent studies suggest that the microbiome could influence carcinogenesis through dysregulation of inflammation, immunity and metabolism.<sup>10</sup> Furthermore, the microbiome may influence cancer therapy delivery and response.<sup>11,12</sup> A useful avenue would be to investigate the associations between cancer and the microbiome in a range of (pre)malignant diseases. Knowledge of the healthy microbiome composition is of paramount importance before any oncogenic associations can be identified.

The incidence rate of vulvar squamous cell carcinoma (VSCC) is 1 to 2 per 100,000 and increases with age.<sup>13</sup> Currently, a HPV-dependent and an HPV-independent pathway in developing VSCC have been identified.<sup>14-16</sup> HPV-related premalignant vulvar lesions are commonly caused by HPV16 or HPV18 and referred to as high-grade squamous intraepithelial lesions (HSIL).<sup>15</sup> Chronic inflammatory conditions, such as lichen sclerosus (LS) and lichen planus, may predispose VSCC and its precursor, differentiated vulvar intraepithelial neoplasia (dVIN). However, the mechanisms for malignant progression remain largely unknown.<sup>16,17</sup> There is a considerable amount of taboo associated with vulvar disease, adding to underreporting, lack of clinical recognition and treatment.<sup>18</sup> Considerable physical, sexual and psychological morbidity is caused by vulvar (pre)malignant diseases.<sup>19-21</sup>

Elucidation of the healthy cervicovaginal microbiota composition and its changes that may correlate to gynaecological and obstetric disease is ongoing. Several studies have investigated the role of vaginal microbiome changes

to the development of cervical dysplasia and cervical cancer.<sup>22-24</sup> A number of studies have documented the vulvar microbiome composition.<sup>25</sup> However, these are of limited scope. No comprehensive overview of the current knowledge of the vulvar microbiome is available. Although the causal pathway between HPV and HSIL is well understood, no other associations between the microbiome and emergence of vulvar disease have been described. The objective of this systematic review of the literature is to identify and summarize studies investigating the composition and changes of the vulvar microbiome in health and disease. In addition, suggestions for the design of future research will be provided. Improving the knowledge on the vulvar microbiome may contribute to new perspectives in the management of (pre) malignant vulvar disease.

## Methods

This systematic review adheres to the relevant criteria from the PRISMA statement (Preferred Reporting Items for Systematic Reviews and Meta-Analyses).<sup>26</sup> The methods used, including identification, screening, eligibility and inclusion, were agreed by the authors and the protocol was registered with PROSPERO (reference number CRD42020181148).<sup>27,28</sup> The scope of this review was altered to focus on the vulvar microbiome composition rather than the complete gynaecological field.

### SEARCH STRATEGY

Relevant scientific papers were identified by a systematic online cross-database search performed in April 2020 (last update 29 September 2021), using PubMed, Embase, Emcare, Web of Science, Cochrane Library and Academic Search Premier. Search strategies for all databases were adapted from the PubMed strategy and developed with assistance of an experienced librarian of the Walaeus Library of the Leiden University Medical Center (JS). The search strategy consisted of the medical subject headings and text words related to the following anatomical sites: vulva, vagina, anus and cervix in (a) the following disease entities: high-grade squamous intraepithelial lesions (HSIL), low-grade squamous intraepithelial lesions (LSIL), carcinoma, lichen sclerosus, lichen planus and differentiated VIN (dVIN) and (b) healthy individuals. See *Supplementary File 1* for the complete search strategies for each database. The search was restricted to English language and human studies.

In addition, hand searching of the reference lists of relevant reviews and included studies was undertaken to identify additional relevant references.

### INCLUSION CRITERIA

Original articles examining the vulvar microbiome through culture-independent methods in tissue or swabs in patients with vulvar/cervical HSIL, LSIL (including genital warts), vulvar and anal squamous cell carcinoma, lichen sclerosus, lichen planus, dVIN and healthy women were included. As the majority of the human microbiome is uncultivable and potentially misleading results may arise from cultivation studies, the study was restricted to research articles in which culture-independent techniques using molecular methods with DNA were applied for microbiota profiling DNA.<sup>29-32</sup>

### EXCLUSION CRITERIA

Culture-based studies, animal studies, (systematic) reviews, conference abstracts, articles written in languages other than English and case reports were excluded. Additionally, studies that did not include a culture-independent microbiome analysis of the vulvar region were excluded.

### STUDY SELECTION

Titles and abstracts of studies retrieved were screened independently using the Rayyan online tool by two review authors (LP and RE) to identify studies that met the inclusion criteria outlined above.<sup>33</sup> The full text of these potentially eligible studies was retrieved and independently assessed for eligibility by two review authors (LP and RE). Disagreement over the eligibility of specific studies between the two review authors was resolved through discussion with a third review author (MVP).

### DATA EXTRACTION

Data were extracted from the included studies for assessment of study quality and evidence synthesis. Predefined extracted information included: study setting (including country); study population; participant demographics and baseline characteristics; target organ; target disease; in- and exclusion criteria; study methodology (including sample collection method and type of microbiome analysis) and microbiome outcomes (including community types and main findings). Synthesis of the summarizing figure was based on the reported relative abundance of the bacterial composition, when applicable.

## ASSESSMENT OF RISK OF BIAS AND LEVEL OF EVIDENCE

Two review authors (LS and RE) independently assessed the risk of bias and the level of evidence according to the Critical Appraisal Checklist characteristics as recommended by the Joanna Briggs Institute.<sup>34</sup> The level of evidence was assessed as recommended by Grading of Recommendations, Assessment, Development and Evaluation (GRADE) guidelines.<sup>35</sup> Disagreements in the risk of bias and level of evidence assessment were resolved by discussion between the review authors with involvement of a third review author (MVP).

## Results

### NUMBER OF RETRIEVED PAPERS

A total of 1347 articles were obtained from the initial database search. After removal of 748 duplicates, 599 records were screened for title and abstract, from which 486 were excluded (Figure 1). From this search, 113 articles were assessed for eligibility based on the full text, of which nine were selected to be included in the qualitative synthesis of this review. In addition, one study was identified through snowballing and included in the re-view. The excluded full text articles were mostly excluded because these focused on a different area (i.e., vagina without vulvar data) or used a different, inappropriate technique for microbiome assessment (culture-dependent techniques or cytokine assays). One recent study by Park et al. combined sampling of the vestibulum and vagina and was therefore excluded from the synthesis of results.<sup>36</sup>

From the ten studies that were included in this review, nine studies employed 16S rRNA gene amplicon sequencing for analysis of the vulvar microbiome. The remaining study, by Miyamoto et al., employed QPCR analysis using five genus or species-specific bacterial primers.<sup>37</sup> One study, by Bruning et al., also analysed the fungal fraction of the microbiota through ITS amplicon sequencing.<sup>38</sup> In total, vulvar microbiome analysis has been performed on 261 women (total data set). No studies used shotgun meta-genomics or other culture-independent techniques that could identify the microbial composition of the vulva. All included studies are summarized in Table 1.

### THE HEALTHY VULVAR MICROBIOME

Seven out of ten studies investigated the vulvar microbiota in healthy women or factors that can influence the healthy microbiota composition.

Brown et al. aimed to characterize the vulvar microbiome of four healthy Caucasian women aged 28–44 years by 16S rRNA gene amplicon sequencing analysis from single vaginal, labia majora and labia minora samples.<sup>39</sup> In three out of four women, the most abundant phylotypes on the labia minora and labia majora were *Lactobacillus crispatus* or *L. iners*, whilst the fourth participant's labia minora and majora were dominated almost equally by *L. iners* (resp. 32.0 and 28.3%), *Atopobium vaginae* (resp. 26.8 and 17.5%) and *Megasphaera elsdenii* (resp. 30.1 and 12.5%), species that are known colonizers of the vagina. The authors concluded that the dominant phylotypes from the vulva were also dominant members of communities in the corresponding vaginal samples, which were published in a separate paper.<sup>40</sup> Furthermore, communities found on the labia majora were generally more diverse than those found on the labia minora, with two to fourteen times more phylotypes detected on the former location. *Staphylococcus epidermidis* and *Corynebacterium* are phylotypes of cutaneous origin that were found on the labia majora but not, excluding one case, on the labia minora. Emerging from the intestinal tract, *Enterococcus faecalis* was found in a higher proportion on the labia majora than on the labia minora.

Bruning et al. performed 16S rRNA gene and ITS amplicon sequencing on 34 and 16 labia majora samples, respectively, in a clinical trial to a microbiome-friendly vulvar wash in a Caucasian population aged 18–55 years. In follow-up samples throughout the study, it was found that the wash had no effect on the bacterial and fungal microbiota composition. The predominant bacterial genera found at baseline (relative abundance) included *Corynebacterium* (27–47%), *Lactobacillus* (12–18%), *Staphylococcus* (4–10%), *Prevotella* (4–12%), *Propionibacterium* (1–13%) and *Finnegoldia* (3–5%). Several genera belonging to *Actinobacteria* were present in low relative abundance (<1%). The predominant fungi were *Cryptococcus* (20–50%), *Malassezia* (0.3–21%), *Saccharomyces* (20%), *Cladosporium* (1–12%) and *Rhodotorula* (2%). The vulvar pH was found to be significantly influenced by relative abundance of *Lactobacillus*. The authors hypothesize that the colonization of the identified organisms could correlate to the heterogeneous vulvar skin structure and function, such as *Staphylococcus* and *Corynebacterium* on moist areas, *Propionibacterium* and *Malassezia* on sebaceous skin and other *Actinobacteria* spp. on dry areas.

The only study included in this review to employ species-specific primers for QPCR, by Miyamoto et al., found a significantly ( $p < 0.001$ ) higher total bacterial load on the labia and groin compared to the mons pubis or the inner

thigh in a cross-sectional sample of 40 healthy Japanese women aged 20–40 years.<sup>37</sup> *Lactobacillus* spp. and *Staphylococcus epidermidis* were identified as the dominant species at all sites. *Lactobacillus* spp. were found in a statistically ( $p < 0.001$ ) higher abundance on the labia and groin compared to the mons pubis and the inner thigh. *Staphylococcus aureus* was found in 60% of women, while the abundance was significantly ( $p < 0.001$ ) higher on the labia and groin compared to the other two regions. *Prevotella* spp., a collection of species commonly found in the gastrointestinal tract, were only detected on the labia and groin samples, although prevalent in 95% of participants. *Propionibacterium acnes* was identified on the labia of all subjects, and in 98% of samples of the mons pubis and inner thigh.

Costello *et al.* performed a longitudinal study in nine healthy adults in the United States of America (USA, ethnicity undisclosed), including three women aged 30–35, on the bacterial community of up to 27 body sites with samples of the labia minora on two consecutive days.<sup>41</sup> The authors concluded that observed variation between samples was mostly explained by the different body sites sampled, followed by differences between individuals and by changes over time. The microbial community on the labia minora clustered separately from the rest of the samples identified in this study, mostly because of dominance of *Lactobacillus* (48.6%), probably arising from the vagina. Additionally, presence of *Prevotella* (16%) and *Finegoldia* (8.9%) on the labia minora were described. The remaining various other species (26.4%) were present in low abundance or not present in all subjects in the study.

### THE ASSOCIATION OF THE MENSTRUAL CYCLE AND OBESITY AND THE VULVAR MICROBIOME

One study, by Shiraishi *et al.*, evaluated the effect of menstruation on the vulvar microbiota in ten healthy Japanese women aged 31–43 years.<sup>42</sup> No bacterial species were found to be consistently increased or decreased in abundance before or during menstruation when sampled once one week before menstruation and once on the second day of menstruation. Seven out of ten women presented with a microbiota of the labia minora that predominantly consisted of by *L. crispatus* or *L. iners* and remained so during menstruation. In five of these women, this remained so during menstruation, while the dominant species switched during menstruation in two subjects, *L. iners* to *L. crispatus* and vice versa. The vaginal microbiome was also determined in three out of ten participants. They concluded that the vaginal samples displayed highly similar species as found on the vulva.

Hickey *et al.* performed a prospective study to investigate the effect of menarche on the composition of the vulvar and vaginal microbiome in 32 healthy 10–13 year-old girls with different ethnicities.<sup>43</sup> Quarter-yearly swabs were collected up to three years. During the study, 67.7% (21 out of 32) of the participants reached menarche. They concluded that the vulvar and vaginal microbiota composition of pre- and perimenarchal girls had a high *Lactobacillus* abundance. There was a moderately high degree of concordance between the vulva and the vagina, although the vulva tended to have a greater variety of bacterial taxa. Specifically, *Segniliparus*, *Murdochiella* and *Fusobacterium* showed a stronger association with the vulva in relative abundance levels compared to the vagina.

One cross-sectional study by Vongsa *et al.* focused on the differences in vulvar microbiota composition in 20 obese women (body mass index  $> 30$ ) compared to 20 lean women (body mass index 18–25) aged 18–35 years (ethnicity undisclosed).<sup>44</sup> Kruskal–Wallis tests were used to calculate differences in relative abundance of bacterial genera. The authors concluded that women with a high BMI have a distinct vulvar microbial pattern compared to average-weight women ( $p = 0.005$ ). *Lactobacillus* spp. were more prevalent on the vulva of lean women than of obese women ( $p = 0.00$ ), whereas *Corynebacterium* spp. ( $p = 0.04$ ) and *Anaerococcus* spp. ( $p = 0.01$ ) were more prevalent on the vulva of obese women. They also found that the community populations of the labia majora clustered distinctly from the labia minora in obese women ( $p = 0.001$ ). The diversity did not differ between the labia minora and the labia majora. *Finegoldia* and *Lactobacillus* were more prevalent on the labia minora (resp.  $p = 0.02$  and  $p = 0.05$ ). Conversely, *Corynebacterium* was more prevalent on the labia majora compared to the labia minora ( $p = 0.00$ ), as was *Staphylococcus* ( $p = 0.00$ ).

### THE MICROBIOME IN VULVOVAGINAL DISEASE

Two studies investigated the role of the microbiome in vulvar vestibulitis or provoked vestibulodynia, comparing patients to controls.<sup>45,46</sup> The first, by Jayaram *et al.*, found no significant differences in the vulvar or vaginal bacterial microbiota composition between 15 cases (mean age 30.8) and 20 healthy women (mean age 32.6).<sup>46</sup> Additionally, corresponding vestibular and vaginal samples were grossly similar in composition, with no significant differences in prevalence and dominance of species. The dominant genera in vestibular samples of patients with vestibulodynia were *Lactobacillus* (76.7%), *Streptococcus* (10%), *Gardnerella* (6.7%), *Anaerococcus* (3.3%) and *Enterococcus* (3.3%). The

dominant genera in vestibular samples of healthy controls were *Lactobacillus* (80%) and *Gardnerella* (20%). On species level, *L. crispatus* and *L. iners* were most often dominant in the vulvar and vaginal samples of both patients and controls. *L. coleohominis* was prevalent on the vestibular samples of patients (10%) and controls (13.3%), but not identified in their vaginal samples. *L. gasseri* was identified in vestibular (36.7%) and vaginal (26.7%) samples of patients with vestibulodynia, but not in healthy controls.

Murina *et al.* observed no significant differences in bacterial composition in vaginal and vestibular samples in 20 women with provoked vestibulodynia (PVD) compared to 18 healthy controls, both groups comprising of Caucasian women aged 23–48 years.<sup>45</sup> *L. gasseri* was identified as the dominant vulvar species in the PVD group, but not as the dominant species in healthy women, whilst correlating with pain and dyspareunia intensity ( $p < 0.001$ ). The most prevalent genera in the women with PVD were *Lactobacillus* (80.9%), *Gardnerella* (9.5%) and *Atopobium* (9.5%). In the control group, the most dominant genera were *Lactobacillus* (64.7%), *Gardnerella* (11.7%) and *Bifidobacterium* (5.8%). The vestibular samples displayed no statistically different bacterial composition compared to vaginal samples.

Finally, one recent study by Chattopadhyay *et al.* tried to elucidate the vulvar and gut microbiome of five premenarchal girls with lichen sclerosus (LS) and five girls with non-specific vulvovaginitis as compared to three healthy girls in a case-control study.<sup>47</sup> The mean age of the population was 6 years and the population was of mixed ethnicity. They found that in vulvar samples, 26 bacterial genera or species were significantly different ( $p < 0.05$ ) between LS, non-specific vulvovaginitis and healthy controls. Specifically, girls with LS and non-specific vulvovaginitis presented with a lower relative abundance of *Streptococcus anginosus*, but a higher abundance of *Peptostreptococcus anaerobius* and *Prevotella melaninogenica* compared to controls. In fecal samples, 21 bacterial genera or species were identified as significantly different ( $p < 0.005$ ) between LS, non-specific vulvovaginitis and healthy controls. Girls with LS showed a higher abundance of *Dialister* spp., *Clostridiales*, *Paraprevotella* spp. and *E. coli* compared to healthy controls, while *Phascolarctobacterium* spp. was present in a lower abundance. This study identified an overlap of 34 genera or species present in both the faecal and vulvar milieu, suggesting exchange between the microbial niches.

## Discussion

To our knowledge, this is the first study that comprehensively assessed the vulvar microbiome in health and (pre)malignant vulvar disease. One of the main findings of this study is that there is very limited knowledge on the vulvar microbiome. The bacterial genera and species that have been described on the healthy vulva are several taxa of *Lactobacillus*, *Corynebacterium*, *Staphylococcus* and *Prevotella*, suggesting possible emergence from vaginal, cutaneous and intestinal origin. The results of this review suggest that the vulva may constitute a separate microbial niche with different signatures found on various anatomical sites within the vulva, e.g., labia minora, labia majora and mons pubis. However, only ten studies in a total of 261 women have been conducted in heterogenous study designs and populations, therefore this picture is far from complete.

*Lactobacillus* are well-known lactic-acid-producing colonizers of the female genital tract, maintaining an acidic vaginal milieu. It has been suggested that *Lactobacillus* dominance plays a protective role against cervical dysplasia, although the true nature of this association is not fully elucidated.<sup>48,49</sup> In this review, dominance of *L. crispatus* and *L. iners* was observed on the vulva in most healthy women. *L. gasseri* dominance was noted only in a proportion of patients with vestibulodynia, but not in the healthy control groups, although this correlation was not considered statistically significant in either studies.<sup>45,46</sup> *Corynebacterium* species are commonly found cutaneous bacteria.<sup>50</sup> *Corynebacterium* presence has been described on the vulva in several studies, although in most cases not as the dominant species or in specific correlation to vulvar disease. *Corynebacterium* has been described as an occasional colonizer of the vaginal tract, specifically when *Lactobacillus* abundance is low.<sup>51</sup> *Staphylococcus aureus*, from the phylum *Firmicutes*, is found predominantly on the skin and in the upper respiratory tract. In this review, *S. aureus* prevalence on the vulva ranged from 0 to 63%.<sup>37,39</sup> From literature, *S. aureus* colonization of the vagina is 9.2%,<sup>52</sup> with similar varying rates (6,8 to 67%) have been observed on the external female genitalia.<sup>25,53</sup> *Prevotella*, often found in the gut, has been associated with periodontal disease.<sup>54</sup> Vaginal *Prevotella* presence has been associated with bacterial vaginosis, but also with a healthy vaginal environment.<sup>55</sup> Notably on the vulva, *Prevotella* was reported in 95% of labia and groin samples by Miyamoto *et al.*, whilst only 1 in 10 labia minora samples from Shiraishi *et al.* showed presence of *Prevotella*.<sup>37,42</sup>

Visualisation of the vulvar microbiota is provided in *Figure 2*, comparing the vulvar microbiome composition with those of vaginal, intestinal and cutaneous (inguinal fold) body sites.<sup>50,56</sup> Only four out of ten studies could be incorporated in the depiction due to heterogeneous reporting and lack of raw data availability. Although data are scarce and study populations are heterogeneous, we hypothesize that the vulva could constitute an inward-facing gradual transition zone from predominantly cutaneous commensals towards components of the vaginal microbiome with intestinal influences. Microorganisms thrive on body sites that supply the optimal growth conditions, including pH, nutrients, oxygenation and moisturization.<sup>57</sup> The heterogeneous vulvar skin composes an occluded, humid environment with friction and areas with and without keratinization, challenging the interpretation of the observations.<sup>58,59</sup> Higher bacterial loads are found on occluded areas of the skin (inguinal fold, axilla, postauricular), which was also observed on the vulva by Miyamoto *et al.*<sup>37</sup> High relative abundance of *Corynebacteria* has been described in moist and sebaceous areas such as the inguinal fold,<sup>50</sup> which may correlate with the observation of their distinct presence on the labia majora. There are several potentially confounding factors in this representation of the vulvar microbiota. Firstly, sequencing techniques measure DNA, meaning that no distinction can be made between live and dead bacteria. Additionally, these techniques sensitively pick up overflow or contamination from vaginal or intestinal sites, which are more densely populated than skin sites. This can swiftly cause an overrepresentation of these contaminating bacteria on vulvar sites. Finally, the data for the current visualization of the vulvar microbiome constitution has been deduced from small, heterogeneous study populations sampled in varying study designs, thus the picture is in its infancy and these current associations may prove to be incidental and need larger confirmatory studies to become generalizable.

One of the focus points of this review was to identify existing correlations of the vulvar microbiome and (pre)malignant vulvar disease. Only one study reported on premenarchal LS in girls. Chattopadhyay *et al.* correlate the identified higher abundance of *Dialister* spp. and lower abundance of *Roseburia faecis* in the gut of LS patients to findings in other inflammatory diseases such as ankylosing spondyloarthritis and Crohn's disease. The authors also argue that their LS patients display a more dysbiotic vulvar microbiome, with a possible excess of *Prevotella* spp., *Porphyromonas* spp. and *Parvimonas* spp., correlating it to observations of these taxa in chronic periodontitis. The

observed higher abundance of *Peptostreptococcus* spp., *Prevotella* spp. in girls with LS has previously been described in psoriatic lesions.<sup>60</sup> Likewise, higher abundance of *Porphyromonas* spp. and *Parvimonas* spp. have also been found in hidradenitis suppurativa,<sup>61</sup> which was also observed in girls with LS. However, this pilot study was only performed in five LS cases and three controls in a paediatric population. This leaves many questions about the interplay between the vulvar microbiome and LS, including adult women with LS or other vulvar (pre)malignancies.

Previous research in microbiome perturbations in cervicovaginal or male genital (pre)malignant disease may generate hypotheses for vulvar disease. A recent meta-analysis by Norenhag *et al.* found that an increasing stage of HPV-driven cervical dysplasia was associated with a higher prevalence of a non-*Lactobacillus* dominated vaginal microbiome.<sup>22</sup> In addition, several studies have reported an increased prevalence of *Sneathia* spp. in the vaginal microbiome of patients with hrHPV infections, cervical intraepithelial neoplasia and invasive cervical carcinoma.<sup>23,62-64</sup> Likewise, *Mycoplasma* spp. is reportedly often found to co-infect with hrHPV.<sup>65</sup> Of note, many of these reports were cross-sectional studies describing results of one or two stages of cervical dysplasia, with few longitudinal trials that allow for validation of this relationship. In Nigerian men with anal cancer, Nowak *et al.* found that *Sneathia* spp. was associated with HPV16 prevalence among men who have sex with men with HIV or at risk for HIV.<sup>66</sup> In penile cancer, Onywera *et al.* have described a higher a greater relative abundance of *Prevotella*, *Peptinophilus* and *Dialister* and lower relative abundance of *Corynebacterium* in hrHPV-infected men.<sup>67</sup> Cohen *et al.* found that the urine bacteriome of male LS patients with showed enrichment of *Bacillales*, *Bacteroidales* and *Pasteurellales*.<sup>68</sup> Increased incidence of Epstein-Barr virus (EBV) in LS biopsy tissue has been described in both female (26.5%) and male (37–38.3%) LS patients.<sup>69-71</sup> A recent meta-analysis found a positive correlation between EBV and oral lichen planus (odds ratio 4.41).<sup>72</sup> EBV is a known cause for Burkitt lymphoma, nasopharyngeal carcinoma and diffuse large B-cell lymphoma and other lymphoma subtypes.<sup>73-75</sup> These findings may provide a lead for the currently unknown aetiology of LS. However, no studies in this review have investigated the vulvar virome nor the microbiome composition of adult LS patients.

Several limitations of the current literature can be identified. Firstly, the sample size of all studies is low, with a minimum of three and a maximum of 45 participants per study, which does not allow for robust results within

a highly variable field of research. Furthermore, all studies of the adult vulvar microbiome were only performed in Caucasian or Japanese participants, while two studies omit disclosure of ethnicity data.<sup>41,44</sup> The only two studies that do include a diverse population (e.g., Black, Hispanic, Native American) were carried out in young girls.<sup>43,47</sup> As the vaginal bacteriota is known to differ across ethnic groups<sup>76-80</sup> and this review suggests parallels between vaginal and vulvar samples, it is imperative to include more diverse populations in future studies. Another limitation is the lack of elaboration and elucidation of other potentially confounding factors. For instance, the current literature only includes women aged 6–55 years. The only study to LS was conducted in young girls and there is no literature on the microbiome composition in the adult group at risk for vulvar (pre)malignant conditions. In some of the included publications, e.g., by Murina *et al.*, Vongsa *et al.* and Chattopadhyay *et al.*,<sup>44,45,47</sup> highly significant findings were found in extremely small study populations without corrections for multiple testing or described considerations to avoid bias. Results from these studies should therefore be carefully interpreted and the potential risk for type I errors ought to be noted for future research.

Lifestyle choices should also be considered, such as vulvovaginal hygiene, vaginal douching or drying practices or type and frequency of sexual intercourse. Patient characteristics that may alter the microbiome are insufficiently considered in the current literature. These aspects include, but are not limited to, ethnicity, age, weight, hormonal state and systemic (immunosuppressive) disease. Antibiotic use is the only factor listed as an exclusion criterium in all but one study, with other restrictions applied haphazardly when comparing the included studies (*Supplementary Table 1*). Furthermore, there is a lack of longitudinal studies, with only four studies that sample the vulvar microbiome at more than one time point.<sup>38,41-43</sup> Research has shown that the composition of the healthy vaginal microbiome can easily be disrupted but appears to be stable over a longer period of time.<sup>51,81</sup> Sampling at a single time point is only a snapshot representation and disregards dynamics of the microbial ecosystem in the pathway of disease onset and progression. Co-occurrence of certain microbial dysbiosis and disease states at a single time point cannot unveil the direction of association.

There is little information on the presence and function of viruses, parasites and fungi on the vulva. Nine out of ten studies analysed the bacteriome

through 16S rRNA gene amplicon sequencing. The choice of a certain 16S rRNA region (i.e., hypervariable region V1-V3 or V3-V4) can lead to heterogeneity in quantification of certain species and influence classification level. It is currently recognized that V1-V3 of the 16S rRNA gene correlates most with shotgun metagenomics for cutaneous and vaginal analysis and is preferred over targeting of V3-V4.<sup>82,83</sup> Two studies included in this review used primers for the V3-V4 region,<sup>42,47</sup> and in two studies the targeted region could not be traced.<sup>39,44</sup> Only one study included fungal analysis<sup>38</sup> and no studies included shotgun metagenomics sequencing. Furthermore, there was a large discrepancy in sampling methods (dry or wet swab, scrub) between studies, which can greatly affect the outcomes of microbiota profiling.<sup>84</sup> Every minor variation picked up at sampling is subsequently amplified by molecular microbiome assay techniques. In low biomass samples, such as those of the vulva, negative control samples should also be added to the analysis. Only one out of ten studies in this review reported the use of negative or blank control samples.<sup>47</sup> The limitations of the analysis techniques for the identification of the microbiome and sampling methods employed in the current studies contribute to the low level of evidence and difficulties in comparison of the presented results.

We recommend longitudinal, case-control study designs for future vulvar microbiome research in a range of (pre)malignant vulvar diseases and in healthy controls. Ideally, shotgun metagenomics methods should be chosen over solely 16S rRNA gene amplicon sequencing to allow for a more complete picture of the microbiome and its functional potential. We urge including samples from several anatomical locations within the vulva, in addition to vaginal, intestinal or cutaneous samples to allow for intra-individual comparison of results. As the current knowledge of the vulvar microbiome is centralized around data from premenopausal Caucasian women, it is advised to attempt to recruit a more diverse population in future studies. If possible, lifestyle factors that could disrupt microbiome results (e.g., sexual activities, topical medication or emollient use, washing, hair removal practices) prior to microbiome sampling should be standardized or recorded. Hormonal or menstrual cycle status may also influence results status. Many questions remain on the composition of the healthy vulvar microbiome and the role of the microbiome in the origin and progression of vulvar disease.

## Conclusions

This systematic review investigates the role of the microbiome in vulvar health and disease for the first time. We conclude that there is very limited knowledge on the microbiome of the vulva. There are indications that microbiota composition of the vulva shows many similarities with the corresponding vaginal milieu, although the vulvar microbiome generally showed a higher diversity with commensals of cutaneous and faecal origin, potentially giving the vulva a unique signature that ought to be further elucidated in further studies.

No studies have been performed to the microbiome of (pre)malignant vulvar disease. Future studies unravelling the vulvar microbiome in much greater phylogenetic detail and with frequent longitudinal information are highly needed for better understanding of disease and to identify potential novel biomarkers for diagnosis and disease monitoring.

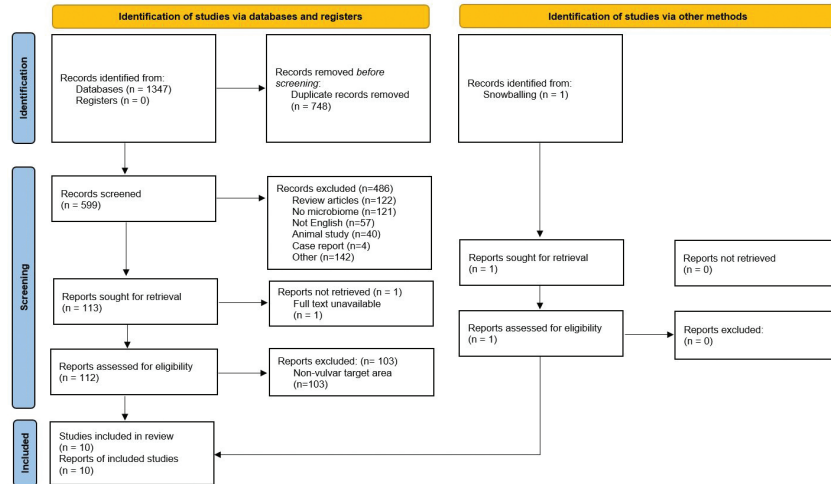
**Table 1** Summary table of the studies included in the review.

Author, year	Focus	Study subjects	Subject Age	Ethnicity + country	Sample locations	Sample type	Microbial analysis	Key findings	Limitations	Risk of bias	Level of evidence
Brown et al, 2007	Healthy	4 HV	28-44 years	Caucasian, USA	Labia minora, labia majora, vagina	Scrape samples	16S rRNA amplification of unspecified region	Bacteriome vulva=vagina. Dominant vulvar species: 3/4 <i>L. crispatus</i> or <i>L. iners</i> , 1/4 <i>L. iners</i> , <i>Atopobium vaginae</i> and <i>Megasphaera elsdenii</i> .	Small sample size. No longitudinal sampling. No specification of sequencing region.	Low	Very low
Bruming et al, 2020	Healthy	36 HV	18-55 years	Caucasian, USA	Labia majora	Modified liquid cup scrub method	16S rRNA amplification of the V1-V3 region and fungal ITS sequencing	Bacterial relative abundance at baseline: 27-47% <i>Corynebacterium</i> , 12-18% <i>Lactobacillus</i> , 4-10% <i>Staphylococcus</i> , 3-12% <i>Prevotella</i> , 1-13% <i>Propionibacterium</i> and 3-5% <i>Finegoldia</i> . Fungal relative abundance at baseline: 20-50% <i>Cryptococcus</i> , 0.3-21% <i>Malassezia</i> , 1-12% <i>Cladosporium</i> and 2% <i>Rhodotulura</i> .	Focus reporting on effects investigational product, not microbiome. 34/36 bacterial, 16/36 fungal samples showed amplification for analysis.	Low	Low
Miyamoto et al, 2013	Healthy	40 HV	20-40 years	Japanese, Japan	Labia majora, groin, mons pubis, inner thigh	Saline wetted sterile swabs	qPCR for specific genera ( <i>S. epidermidis</i> , <i>S. aureus</i> , <i>P. acnes</i> , <i>Lactobacilli</i> spp., <i>Prevotella</i> spp.)	Labia + groin vs. mons pubis/inner thigh: ↑ <i>Lactobacilli</i> and <i>S. aureus</i> . <i>Prevotella</i> spp. on labia + groin only.	No extensive sequencing data due to employed procedure. No longitudinal sampling.	Low	Very low

Author, year	Focus	Study subjects	Subject Age	Ethnicity + country	Sample locations	Sample type	Microbial analysis	Key findings	Limitations	Risk of bias	Level of evidence
Costello et al., 2009	Healthy	3 HV	30-35 years	Unknown, USA	Labia minora	NaCl + Tween wetted sterile swabs	16s rRNA amplification of the V2 region	Predominant taxa: Lactobacillus (48.6%), Prevotella (16%) and Finegoldia (8.9%)	Small sample size. Focus not on vulvar microbiome, but on other body sites.	Low	Very low
Shiraishi et al., 2010	Menstruation	10 HV	31-43 years	Japanese, Japan	Labia minora, vagina (3/10)	Scrape samples	16s rRNA amplification of the V3-V4 region	No species consistently changed abundance before or during menstruation. 7/10 showed predominance of <i>L. crispatus</i> or <i>L. iners</i> .	Small sample size. Only 3/10 vaginal cross-reference samples. No longitudinal sampling.	Low	Very low
Hickey et al., 2015	Menarche	32 HV	10-12.9 years	Mixed Black, Caucasian, Native American, Hispanic. USA	Labia minora, vagina	Dry, sterile flocced swabs	16s rRNA amplification of the V1-V3 region	Bacteriome vulva ≈ vagina (mean more similarities before menarche. Greater variety bacterial taxa on vulva compared to the vagina. Abundance lactic acid producing bacteria increases with puberty on vulva and vagina)	Focus on vaginal microbiome. No report comparing the pre- and post-menarchal vulvar microbiome	Low	Low
Vongsa et al., 2019	Obesity	20 obese (BMI >30) 20 HV (BMI 18-25)	18-35 years	Unknown, USA	Labia majora, labia minora	Swab	16s rRNA amplification of unspecified region	Obese vs. HV: ↑Corynebacterium spp. and Anaerococcus spp., ↓Lactobacillus spp. Labia majora more diverse than labia minora.	No longitudinal sampling. No ethnicity data disclosure. No specification of sequencing region.	Low	Low

Author, year	Focus	Study subjects	Subject Age	Ethnicity + country	Sample locations	Sample type	Microbial analysis	Key findings	Limitations	Risk of bias	Level of evidence
Jayaram et al., 2014	Vulvar vestibulitis syndrome (VVS)	20 VVS 15 HV (BMI 32.6 (HV) years)	Mean 30.8 (VVS) and 32.6 (HV) years	Caucasian, USA	Vestibulum, vagina	Swab	16s rRNA amplification of the V1-V3 region	No differences vulvar or vaginal bacteriome composition cases vs. controls. Bacteriome vestibulum ≈ vagina. Most prevalent vvs: Lactobacillus, Gardnerella, Atopobium. Most prevalent HV: Lactobacillus, Streptococcus and Gardnerella	No longitudinal sampling.	Low	Low
Murina et al., 2020	Provoked vestibulodynia (PVD)	20 PVD 18 HV	23-48 years	Caucasian, Italian	Vestibulum, vagina	Swab	16s rRNA amplification of the V3 region	<i>L. gasseri</i> only dominant in PVD. Most prevalent genera PVD: Lactobacillus, Gardnerella and Atopobium. Most prevalent genera HV: Lactobacillus, Gardnerella and Bifidobacterium.	No longitudinal sampling.	Low	Low
Chattopadhyay et al., 2021	Pre-menarchal lichen sclerosis	5 LS 5 NSVV 3 HV	Mean 6 years	Mixed Caucasian, Black and Hispanic, USA	Labial fold, perineum, feces	Dry flocced swabs	16s rRNA amplification of the V3-V4 region	LS vs. HV: vulvar bacteriome ↑ Porphyromonas spp., Parvimonas spp., Peptoniphilus spp., Prevotella spp, Dialister spp and ↓ Peptostreptococcus spp. Corynebacterium spp. Faecal bacteriome LS: ↑Dialister spp.	Small sample size. No longitudinal sampling. Only premenarchal girls. No species level determination due to employed procedure.	Low	Very low

**Figure 1** PRISMA Flow chart of the study.



**Figure 2** Graphical representation of the vulvar microbiome composition. The microbiome composition of the vulva appears to potentially be distinct from the microbiome composition of the adjacent anatomical sites (vagina, gut or skin). It should be noted that this figure was based on only four studies that reported the relative abundance on phylum or genus level. The remaining four studies did not have a report on the relative abundance nor raw data available in the public domain that could allow for generation of relative abundance data. The outer circle represents the reported phyla per study per anatomical location upon the vulva. If applicable, the inner circle represents the genera reported in the same study. The data on the microbiome composition of the vagina, gut and skin (inguinal fold) was adapted from Grice and Segre, 2011 and 2012.

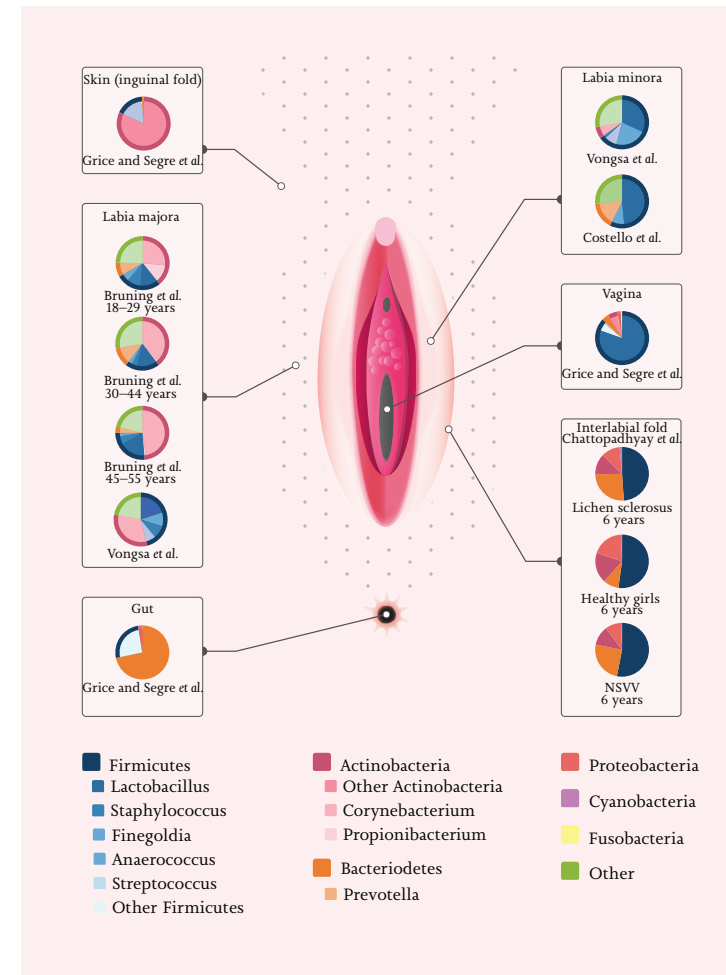


Illustration: F.A. van Meurs

---

**SUPPLEMENTS CHAPTER 6**

---

Supplemental data can be accessed online at:

<https://www.mdpi.com/article/10.3390/microorganisms9122568/s1>

Supplemental Table S1 Summary of lifestyle rules.

Supplementary File S1 Search strategy

---

**REFERENCES**

- 1 Byrd AL, Belkaid Y, Segre JA. The human skin microbiome. *Nat Rev Microbiol*. 2018;16(3):143-155. doi:10.1038/nrmicro.2017.157
- 2 Feng Q, Liang S, Jia H, et al. Gut microbiome development along the colorectal adenoma-carcinoma sequence. *Nat Commun*. 2015;6:6528. doi:10.1038/ncomms7528
- 3 Niemeyer - van der Kolk T, van der Wall HEC, Balmforth C, Van Doorn MBA, Rissmann R. A systematic literature review of the human skin microbiome as biomarker for dermatological drug development. *Br J Clin Pharmacol*. 2018;84(10):2178-2193. doi:10.1111/bcp.13662
- 4 Hale VL, Chen J, Johnson S, et al. Shifts in the Fecal Microbiota Associated with Adenomatous Polyps. *Cancer Epidemiol Biomarkers Prev a Publ Am Assoc Cancer Res cosponsored by Am Soc Prev Oncol*. 2017;26(1):85-94. doi:10.1158/1055-9965.EPI-16-0337
- 5 Rajagopala S V., Vashee S, Oldfield LM, et al. The Human Microbiome and Cancer. *Cancer Prev Res (Phila)*. 2017;10(4):226-234. doi:10.1158/1940-6207.CAPR-16-0249
- 6 Chen J, Douglass J, Prasath V, et al. The microbiome and breast cancer: a review. *Breast Cancer Res Treat*. 2019;178(3):493-496. doi:10.1007/s10549-019-05407-5
- 7 Schmidt BL, Kuczynski J, Bhattacharya A, et al. Changes in Abundance of Oral Microbiota Associated with Oral Cancer. *PLoS One*. 2014;9(6):e98741. <https://doi.org/10.1371/journal.pone.0098741>
- 8 Parsonnet J, Friedman GD, Vandersteen DP, et al. *Helicobacter pylori* Infection and the Risk of Gastric Carcinoma. *N Engl J Med*. 1991;325(16):1127-1131. doi:10.1056/NEJM199110173251603
- 9 Cubie HA. Diseases associated with human papillomavirus infection. *Virology*. 2013;445(1-2):21-34. doi:10.1016/j.virol.2013.06.007
- 10 Matson V, Chervin CS, Gajewski TF. Cancer and the Microbiome—Influence of the Commensal Microbiota on Cancer, Immune Responses, and Immunotherapy. *Gastroenterology*. 2021;160(2):600-613. doi:10.1053/j.gastro.2020.11.041
- 11 Helmkink BA, Khan MAW, Hermann A, Gopalakrishnan V, Wargo JA. The microbiome, cancer, and cancer therapy. *Nat Med*. 2019;25(3):377-388. doi:10.1038/s41591-019-0377-7
- 12 Schwartz DJ, Rebeck ON, Dantas G. Complex interactions between the microbiome and cancer immune therapy. *Crit Rev Clin Lab Sci*. 2019;56(8):567-585. doi:10.1080/10408363.2019.1660303
- 13 Hacker NF, Eifel PJ, van der Velden J. Cancer of the vulva. *Int J Gynecol Obstet*. 2012;119:S90-S96. doi:[https://doi.org/10.1016/S0020-7292\(12\)60021-6](https://doi.org/10.1016/S0020-7292(12)60021-6)
- 14 Nitecki R, Feltmate CM. Human papillomavirus and nonhuman papillomavirus pathways to vulvar squamous cell carcinoma: A review. *Curr Probl Cancer*. 2018;42(5):476-485. doi:10.1016/j.cupr.2018.06.008
- 15 de Sanjosé S, Alemany L, Ordi J, et al. Worldwide human papillomavirus genotype attribution in over 2000 cases of intraepithelial and invasive lesions of the vulva. *Eur J Cancer*. 2013;49(16):3450-3461. doi:<https://doi.org/10.1016/j.ejca.2013.06.033>
- 16 Van De Nieuwenhof HP, Van Kempen LCLT, De Hullu JA, et al. The etiologic role of HPV in vulvar squamous cell carcinoma fine tuned. *Cancer Epidemiol Biomarkers Prev*. 2009;18(7):2061-2067. doi:10.1158/1055-9965.EPI-09-0209
- 17 Thuijs NB, van Beurden M, Bruggink AH, Steenbergen RDMM, Berkhof J, Bleeker MCGG. Vulvar intraepithelial neoplasia: Incidence and long-term risk of vulvar squamous cell carcinoma. *Int J Cancer*. 2021;148(1):90-98. doi:10.1002/ijc.33198
- 18 Lockhart J, Gray NM, Cruickshank ME. The development and evaluation of a questionnaire to assess the impact of vulvar intraepithelial neoplasia: a questionnaire study. *BJOG*. 2013;120(9):1133-1142. doi:10.1111/1471-0528.12229
- 19 Mullen MM, Merfeld EC, Palisoul ML, et al. Wound Complication Rates After Vulvar Excisions for Premalignant Lesions. *Obstet Gynecol*. 2019;133(4):658-665. doi:10.1097/AOG.0000000000003185
- 20 Grimm D, Eulenburg C, Brummer O, et al. Sexual activity and function after surgical treatment in patients with (pre)invasive vulvar lesions. *Support Care Cancer*. 2016;24(1):419-428. doi:10.1007/s00520-015-2812-8
- 21 Pérez-López FR, Vieira-Baptista P. Lichen sclerosus in women: a review. *Climacteric*. 2017;20(4):339-347. doi:10.1080/13697137.2017.1343295
- 22 Norenhag J, Du J, Olovsson M, Verstraelen H, Engstrand L, Brusselsaers N. The vaginal microbiota, human papillomavirus and cervical dysplasia: a systematic review and network meta-analysis. *BJOG An Int J Obstet Gynaecol*. 2020;127(2):171-180. doi:10.1111/1471-0528.15854
- 23 Laniewski P, Cui H, Roe DJ, et al. Features of the cervicovaginal microenvironment drive cancer biomarker signatures in patients across cervical carcinogenesis. *Sci Rep*. 2019;9(1):1-14. doi:10.1038/s41598-019-43849-5
- 24 Lin D, Kouzy R, Jaoude JA, et al. Microbiome factors in HPV-driven carcinogenesis and cancers. *PLoS Pathog*. 2020;16(6). doi:10.1371/journal.ppat.1008524
- 25 Aly R, Britz MB, Maibach HI. Quantitative microbiology of human vulva. *Br J Dermatol*. 1979;101(4):445-448. doi:10.1111/j.1365-2133.1979.tb00024.x
- 26 Moher D, Liberati A, Tetzlaff J, Altman DG. Preferred reporting items for systematic reviews and meta-analyses: the PRISMA statement. *PLoS Med*. 2009;6(7):e1000097. doi:10.1371/journal.pmed.1000097
- 27 Booth A, Clarke M, Dooley G, et al. The nuts and bolts of Prospero: an international prospective register of systematic reviews. *Syst Rev*. 2012;1:2. doi:10.1186/2046-4053-1-2
- 28 Moher D, Booth A, Stewart L. How to reduce unnecessary duplication: use Prospero. *BJOG*. 2014;121(7):784-786. doi:10.1111/1471-0528.12657
- 29 Browne HP, Forster SC, Anonye BO, et al. Culturing of 'unculturable' human microbiota reveals novel taxa and extensive sporulation. *Nature*. 2016;533(7604):543-546. doi:10.1038/nature17645
- 30 Fettweis JM, Serrano MG, Girerd PH, Jefferson KK, Buck GA. A new era of the vaginal microbiome: Advances using next-generation sequencing. In: *Chemistry and Biodiversity*. Vol 9. Chem Biodivers; 2012:965-976. doi:10.1002/cbdv.201100359
- 31 Walker AW, Duncan SH, Louis P, Flint HJ. Phylogeny, culturing, and metagenomics of the human gut microbiota. *Trends Microbiol*. 2014;22(5):267-274. doi:10.1016/j.tim.2014.03.001
- 32 Peterson J, Garges S, Giovanni M, et al. The NIH Human Microbiome Project. *Genome Res*. 2009;19(12):2317-2323. doi:10.1101/gr.096651.109
- 33 Ouzzani M, Hammady H, Fedorowicz Z, Elmagarmid A. Rayyan-a web and mobile app for systematic reviews. *Syst Rev*. 2016;5(1):210. doi:10.1186/s13643-016-0384-4
- 34 Porritt K, Gomersall J, Lockwood C. JBI's Systematic Reviews: Study selection and critical appraisal. *Am J Nurs*. 2014;114(6):47-52. doi:10.1097/01.NAJ.0000450430.97383.64

- 35 Guyatt GH, Oxman AD, Vist GE, et al. GRADE: an emerging consensus on rating quality of evidence and strength of recommendations. *BMJ*. 2008;336(7650):924-926. doi:10.1136/bmj.39489.470347.AD
- 36 Park SY, Lee ES, Lee SR, Kim SH, Chae HD. Vaginal Microbiome Is Associated With Vulvodynia, Vulvar Pain Syndrome: A Case-Control Study. *Sex Med*. 2021;9(2). doi:10.1016/j.esxm.2020.100314
- 37 Miyamoto T, Akiba S, Sato N, et al. Study of the vulvar skin in healthy Japanese women: components of the stratum corneum and microbes. *Int J Dermatol*. 2013;52(12):1500-1505. doi:10.1111/j.1365-4632.2012.05582.x
- 38 Bruning E, Chen Y, McCue KA, Rubino JR, Wilkinson JE, Brown ADG. A 28 Day Clinical Assessment of a Lactic Acid-containing Antimicrobial Intimate Gel Wash Formulation on Skin Tolerance and Impact on the Vulvar Microbiome. *Antibiot (Basel, Switzerland)*. 2020;9(2). doi:10.3390/antibiotics9020055
- 39 Brown CJ, Wong M, Davis CC, Kanti A, Zhou X, Forney LJ. Preliminary characterization of the normal microbiota of the human vulva using cultivation-independent methods. *J Med Microbiol*. 2007;56(PART 2):271-276. doi:10.1099/jmm.0.46607-0
- 40 Zhou X, Bent SJ, Schneider MG, Davis CC, Islam MR, Forney LJ. Characterization of vaginal microbial communities in adult healthy women using cultivation-independent methods. *Microbiology*. 2004;150(Pt 8):2565-2573. doi:10.1099/mic.0.26905-0
- 41 Costello EK, Lauber CL, Hamady M, Fierer N, Gordon JJ, Knight R. Bacterial community variation in human body habitats across space and time. *Science (80- )*. 2009;326(5960):1694-1697. doi:10.1126/science.1177486
- 42 Shiraiishi T, Fukuda K, Morotomi N, et al. Influence of menstruation on the microbiota of healthy women's labia minora as analyzed using a 16S rRNA gene-based clone library method. *Jpn J Infect Dis*. 2011;64(1):76-80.
- 43 Hickey RJ, Zhou X, Settles ML, et al. Vaginal microbiota of adolescent girls prior to the onset of menarche resemble those of reproductive-age women. *MBio*. 2015;6(2). doi:10.1128/mBio.00097-15
- 44 Vongsra R, Hoffman D, Shepard K, Koenig D. Comparative study of vulva and abdominal skin microbiota of healthy females with high and average BMI. *BMC Microbiol*. 2019;19(1):16. doi:10.1186/s12866-019-1391-0
- 45 Murina F, Caimi C, Di Pierro F, Di Francesco S, Cetin I. Features of the VagMurina, F., Caimi, C., Di Pierro, F., Di Francesco, S., & Cetin, I. (2020). Features of the Vaginal and Vestibular Microbioma in Patients With Vestibulodynia: A Case-Control Study. *Journal of Lower Genital Tract Disease*, 24(3), 290-294. *J Low Genit Tract Dis*. 2020;24(3):290-294. doi:10.1097/LGT.0000000000000523
- 46 Jayaram A, Witkin SS, Zhou X, et al. The bacterial microbiome in paired vaginal and vestibular samples from women with vulvar vestibulitis syndrome. *Pathog Dis*. 2014;72(3):161-166. doi:10.1111/2049-632X.12197
- 47 Chattopadhyay S, Arnold JD, Malayil L, et al. Potential role of the skin and gut microbiota in premenarchal vulvar lichen sclerosis: A pilot case-control study. *PLoS One*. 2021;16(1):e0245243. doi:10.1371/journal.pone.0245243
- 48 Yang X, Da M, Zhang W, Qi Q, Zhang C, Han S. Role of Lactobacillus in cervical cancer. *Cancer Manag Res*. 2018;10:1219-1229. doi:10.2147/CMAR.S165228
- 49 Wang H, Ma Y, Li R, Chen X, Wan L, Zhao W. Associations of cervicovaginal lactobacilli with high-risk human papillomavirus infection, cervical intraepithelial neoplasia, and cancer: A systematic review and meta-analysis. *J Infect Dis*. 2019;220(8):1243-1254. doi:10.1093/infdis/jiz325
- 50 Grice EA, Segre JA. The skin microbiome. *Nat Rev Microbiol*. 2011;9(4):244-253. doi:10.1038/nrmicro2537
- 51 Gajer P, Brotman RM, Bai G, et al. Temporal dynamics of the human vaginal microbiota. *Sci Transl Med*. 2012;4(132):132ra52-132ra52. doi:10.1126/scitranslmed.3003605
- 52 Guinan M, Dan BB, Guidotti RJ, et al. *Vaginal Colonization with Staphylococcus Aureus in Healthy Vaginal Colonization with Staphylococcus Aureus in Healthy Women: A Review of Four Studies Women: A Review of Four Studies Repository Citation Repository Citation*. Accessed April 16, 2021. [https://digitalscholarship.unlv.edu/community\\_health\\_sciences\\_fac\\_articles/11ThisresponseorcommentisavailableatDigitalScholarship@UNLV:https://digitalscholarship.unlv.edu/community\\_health\\_sciences\\_fac\\_articles/11](https://digitalscholarship.unlv.edu/community_health_sciences_fac_articles/11ThisresponseorcommentisavailableatDigitalScholarship@UNLV:https://digitalscholarship.unlv.edu/community_health_sciences_fac_articles/11)
- 53 Linnemann CC, Stanek JL, Hornstein S, et al. The epidemiology of genital colonization with *Staphylococcus aureus*. *Ann Intern Med*. 1982;96(6 Pt 2):940-944. doi:10.7326/0003-4819-96-6-940
- 54 Yamashita Y, Takeshita T. The oral microbiome and human health. *J Oral Sci*. 2017;59(2):201-206. doi:10.2334/josnusd.16-0856
- 55 Randis TM, Ratner AJ. Gardnerella and Prevotella: Co-conspirators in the Pathogenesis of Bacterial Vaginosis. *J Infect Dis*. 2019;220(7):1085-1088. doi:10.1093/infdis/jiy705
- 56 Grice EA, Segre JA. The human microbiome: Our second genome. *Annu Rev Genomics Hum Genet*. 2012;13:151-170. doi:10.1146/annurev-genom-090711-163814
- 57 Oh J, Byrd AL, Deming C, et al. Biogeography and individuality shape function in the human skin metagenome. *Nature*. 2014;514(7520):59-64. doi:10.1038/nature13786
- 58 Farage MA, Miller KW, Elsner P, Maibach HI. Intrinsic and extrinsic factors in skin ageing: A review. *Int J Cosmet Sci*. 2008;30(2):87-95. doi:10.1111/j.1468-2494.2007.00415.x
- 59 Chen Y, Bruning E, Rubino J, Eder SE. Role of female intimate hygiene in vulvovaginal health: Global hygiene practices and product usage. *Women's Heal*. 2017;13(3):58-67. doi:10.1177/1745505717731011
- 60 Langan EA, Künstner A, Miodovnik M, et al. Combined culture and metagenomic analyses reveal significant shifts in the composition of the cutaneous microbiome in psoriasis. *Br J Dermatol*. 2019;181(6):1254-1264. doi:10.1111/bjd.17989
- 61 Ring HC, Thorsen J, Saunte DM, et al. The follicular skin microbiome in patients with hidradenitis suppurativa and healthy controls. *JAMA Dermatology*. 2017;153(9):897-905. doi:10.1001/jamadermatol.2017.0904
- 62 Wiik J, Sengpiel V, Kyrgiou M, et al. Cervical microbiota in women with cervical intra-epithelial neoplasia, prior to and after local excisional treatment, a Norwegian cohort study. *BMC Womens Health*. 2019;19(1):1-9. doi:10.1186/s12905-019-0727-0
- 63 Lee JE, Lee S, Lee H, et al. Association of the Vaginal Microbiota with Human Papillomavirus Infection in a Korean Twin Cohort. *PLoS One*. 2013;8(5). doi:10.1371/journal.pone.0063514
- 64 Audirac-Chalifour A, Torres-Poveda K, Bahena-Román M, et al. Cervical microbiome and cytokine profile at various stages of cervical cancer: A pilot study. *PLoS One*. 2016;11(4). doi:10.1371/journal.pone.0153274
- 65 Adebamowo SN, Ma B, Zella D, Famooto A, Ravel J, Adebamowo C. Mycoplasma hominis and mycoplasma genitalium in the vaginal microbiota and persistent high-risk human papillomavirus infection. *Front Public Heal*. 2017;5(June):1-10. doi:10.3389/fpubh.2017.00140
- 66 Nowak RG, Bentzen SM, Ravel J, et al. Anal Microbial Patterns and Oncogenic Human Papillomavirus in a Pilot Study of Nigerian Men Who Have Sex with Men at Risk for or Living with HIV. *AIDS Res Hum Retroviruses*. 2019;35(3):267-275. doi:10.1089/aid.2018.0158
- 67 Onywera H, Williamson AL, Ponomarenko J, Meiring TL. The Penile Microbiota in Uncircumcised and Circumcised Men: Relationships With HIV and Human Papillomavirus Infections and Cervicovaginal Microbiota. *Front Med*. 2020;7. doi:10.3389/fmed.2020.00383
- 68 Cohen AJ, Gaither TW, Srirangapatnam S, et al. Synchronous genitourinary lichen sclerosis signals a distinct urinary microbiome profile in men with urethral stricture disease. *World J Urol*. 2020;39(2). doi:10.1007/s00345-020-03198-9
- 69 Levy A, Browne B, Fredrick A, et al. Insights into the Pathophysiology of Urethral Stricture Disease due to Lichen Sclerosis: Comparison of Pathological Markers in Lichen Sclerosis Induced Strictures vs Nonlichen Sclerosis Induced Strictures. *J Urol*. 2019;201(6):1158-1162. doi:10.1097/JU.000000000000155
- 70 Aidé S, Lattario FR, Almeida G, Do Val IC, Da Costa Carvalho M. Epstein-barr virus and human papillomavirus infection in vulvar lichen sclerosis. *J Low Genit Tract Dis*. 2010;14(4):319-322. doi:10.1097/LGT.0b013e3181d734f1
- 71 Zhang Y, Fu Q, Zhang X. The presence of human papillomavirus and Epstein-Barr virus in male Chinese lichen sclerosis patients: A single center study. *Asian J Androl*. 2016;18(4):650-653. doi:10.4103/1008-682X.160261
- 72 Ashraf S, Al-Maweri SA, Alaizari N, et al. The association between Epstein-Barr virus and oral lichen planus: A systematic review and meta-analysis. *J Oral Pathol Med*. 2020;49(10):969-976. doi:10.1111/jop.13093
- 73 Brady G, MacArthur GJ, Farrell PJ. Epstein-Barr virus and Burkitt lymphoma. *Postgrad Med J*. 2008;84(993):372-377. doi:10.1136/jcp.2007.047977
- 74 Tsang CM, Tsao SW. The role of Epstein-Barr virus infection in the pathogenesis of nasopharyngeal carcinoma. *Viral Sin*. 2015;30(2):107-121. doi:10.1007/s12250-015-3592-5
- 75 Crombie JL, LaCasce AS. Epstein Barr virus associated B-cell lymphomas and iatrogenic lymphoproliferative disorders. *Front Oncol*. 2019;9(MAR). doi:10.3389/fonc.2019.00109
- 76 Ravel J, Gajer P, Abdo Z, et al. Vaginal microbiome of reproductive-age women. *Proc Natl Acad Sci U S A*. 2011;108 Suppl(Suppl 1):4680-4687. doi:10.1073/pnas.100261107
- 77 Borgdorff H, van der Veer C, van Houdt R, et al. The association between ethnicity and vaginal microbiota composition in Amsterdam, the Netherlands. *PLoS One*. 2017;12(7):e0181135. doi:10.1371/journal.pone.0181135
- 78 Zhou X, Hansmann MA, Davis CC, et al. The vaginal bacterial communities of Japanese women resemble those of women in other racial groups. *FEMS Immunol Med Microbiol*. 2010;58(2):169-181. doi:10.1111/j.1574-695X.2009.00618.x
- 79 Huttenhower C, Gevers D, Knight R, et al. Structure, function and diversity of the healthy human microbiome. *Nature*. 2012;486(7402):207-214. doi:10.1038/nature11234
- 80 Zhou X, Brown CJ, Abdo Z, et al. Differences in the composition of vaginal microbial communities found in healthy Caucasian and black women. *ISME J*. 2007;1(2):121-133. doi:10.1038/ismej.2007.12
- 81 Coolen MJL, Post E, Davis CC, Forney LJ. Characterization of microbial communities found in the human vagina by analysis of terminal restriction fragment length polymorphisms of 16S rRNA genes. *Appl Environ Microbiol*. 2005;71(12):8729-8737. doi:10.1128/AEM.71.12.8729-8737.2005
- 82 Graspeuntner S, Loeper N, Künzel S, Baines JF, Rupp J. Selection of validated hypervariable regions is crucial in 16S-based microbiota studies of the female genital tract. *Sci Rep*. 2018;8(1):9678. doi:10.1038/s41598-018-27757-8
- 83 Meisel JS, Hannigan GD, Tyldsley AS, et al. Skin Microbiome Surveys Are Strongly Influenced by Experimental Design. *J Invest Dermatol*. 2016;136(5):947-956. doi:10.1016/j.jid.2016.01.016
- 84 Kong HH, Andersson B, Clavel T, et al. Performing Skin Microbiome Research: A Method to the Madness. *J Invest Dermatol*. 2017;137(3):561-568. doi:10.1016/j.jid.2016.10.032

## The vulvar microbiome in lichen sclerosus and high-grade intraepithelial lesions

*Submitted to Frontiers in Microbiology, July 2023*

Lisa Pagan,<sup>1,2</sup> Bertine W. Huisman,<sup>1,2</sup> Michelle van der Wurff,<sup>3</sup>  
Rosanne G.C. Naafs,<sup>1</sup> Frank H. J. Schuren,<sup>3</sup> Ingrid M. J. G. Sanders,<sup>4</sup>  
Wiep Klaas Smits,<sup>4,5</sup> Romy D. Zwitterink,<sup>5</sup> Jacobus Burggraaf,<sup>1,7</sup>  
Robert Rissmann,<sup>1,6,7</sup> Jurgen M. J. Piek,<sup>8</sup> Jannie G. E. Henderickx,<sup>4,5</sup> and  
Mariëtte I. E. van Poelgeest.<sup>1,2</sup>

---

- 
- 1 Centre for Human Drug Research, Leiden, NL
  - 2 Department of Obstetrics and Gynaecology, LUMC, Leiden, NL
  - 3 Netherlands Organisation for Applied Scientific Research, TNO, Zeist, NL
  - 4 Center for Microbiome Analyses and Therapeutics, LUMC, Leiden, NL
  - 5 Department of Medical Microbiology and Leiden University Center of Infectious Diseases (LU-CID), LUMC, Leiden, NL
  - 6 Department of Dermatology, LUMC, Leiden, NL
  - 7 Leiden Amsterdam Centre for Drug Research, Leiden University, Leiden, NL
  - 8 Department of Obstetrics and Gynaecology, Catharina Ziekenhuis, Eindhoven, NL

## Abstract

**BACKGROUND** The role of the vulvar microbiome in the development of (pre)malignant vulvar disease is scarcely investigated. The aim of this exploratory study was to analyse vulvar microbiome composition in lichen sclerosus (LS) and vulvar high-grade squamous intraepithelial lesions (HSIL) compared to healthy controls.

**METHODS** Women with vulvar LS (n=10), HSIL (n=5) and healthy controls (n=10) were included. Swabs were collected from the vulva, vagina and anal region for microbiome characterization by metagenomic shotgun sequencing. Both lesional and non-lesional sites were examined. Biophysical assessments included trans-epidermal water loss for evaluation of the vulvar skin barrier function and vulvar and vaginal pH measurements.

**RESULTS** Healthy vulvar skin resembled vaginal, anal and skin-like microbiome composition, including the genera *Prevotella*, *Lactobacillus*, *Gardnerella*, *Staphylococcus*, *Cutibacterium* and *Corynebacterium*. No significant differences were observed in diversity and richness between healthy and diseased vulvar skin. Compared to the healthy vulvar skin, vulvar microbiome composition of both LS and vulvar HSIL patients was characterized by significantly higher proportions of respectively *Papillomaviridae* (p=0.045) and *Alphapapillomavirus* (p=0.002). In contrast, the *Prevotella* genus (p=0.031) and *Bacteroidales* orders (p=0.038) were significantly less abundant in LS, as was the *Actinobacteria* class (p=0.040) in vulvar HSIL. While bacteria and viruses were most abundant, fungal and archaeal taxa were scarcely observed. Trans-epidermal water loss was higher in vulvar HSIL compared to healthy vulvar skin (p=0.043).

**CONCLUSIONS** This study is the first to examine the vulvar microbiome through metagenomic shotgun sequencing in LS and HSIL patients. Diseased vulvar skin presents with a distinct signature compared to healthy vulvar skin with respect to bacterial and viral fractions of the microbiome. Key findings include the presence of papillomaviruses in LS as well as in vulvar HSIL, although LS is considered an HPV-independent risk factor for vulvar dysplasia. This exploratory study provides clues to the aetiology of vulvar premalignancies and may act as a steppingstone for expanding the knowledge on potential drivers of disease progression.

## Introduction

Vulvar squamous cell carcinoma (vSCC) occurs in 1 to 2 per 100.000 women and has an increasing incidence with age.<sup>1</sup> vSCC is preceded by human papillomavirus (HPV)-related or HPV-independent precursor lesions.<sup>2-4</sup> Predominantly HPV type 16 and 18 can cause vulvar high-grade squamous intraepithelial lesions (HSIL), a premalignant condition responsible for approximately 20% of vSCC.<sup>2</sup> These high-risk HPV (hrHPV) types are also notorious drivers of cervical dysplasia and carcinoma.<sup>5</sup> Vulvar lichen sclerosus (LS) is a chronic inflammatory condition that may promote development of differentiated vulvar intraepithelial neoplasia (dVIN), a premalignancy preceding the remaining 80% of all vSCC.<sup>6,7</sup> dVIN has low disease incidence and poses a diagnostic challenge for both clinicians and pathologists. The central symptom in LS is pruritus, while scarring and anatomical changes of the labia minora and clitoral phimosis occur in severe cases. The aetiology of LS remains debated, with indications of a genetic or autoimmune root cause.<sup>6,8</sup> A considerable amount of taboo is associated with vulvar disease, resulting in delays in clinical recognition and treatment, adding to substantial physical, sexual and psychological morbidity.<sup>9-12</sup>

Changes in microbiome composition have been associated with several disease conditions, including cancer.<sup>13,14</sup> The research field started off with recognition of single malignancy-driving micro-organisms (such as HPV for cervical cancer) and has expanded to include association of microbiome composition patterns to cancer development.<sup>15</sup> In vaginal diseases, higher grades of HPV-driven cervical dysplasia are correlated with a non-*Lactobacillus* dominated vaginal microbiome composition.<sup>16-18</sup> Moreover, the presence of *Sneathia* spp. and *Mycoplasma* spp. has been correlated with co-infection with hrHPV types.<sup>16,19-23</sup> These findings can expand our understanding of cervical diseases and serve as biomarkers and potential targets for drug development to treat cervical (pre)malignant disease.

In contrast to the vaginal microbiome, the vulvar microbiome and its role in the development of (pre)malignant vulvar disease is scarcely investigated and current knowledge is inconclusive.<sup>24</sup> The bacterial genera and species described on the healthy vulva include the genera *Lactobacillus*, *Corynebacterium*, *Staphylococcus* and *Prevotella*, suggesting transfer from vaginal, cutaneous and intestinal origin. Current literature lacks longitudinal, case-controlled studies and elucidation of microbiome components other than bacteria, such

as viruses, fungi and archaea. Therefore, the aim of this study was to describe and compare the vulvar microbiome composition by metagenomic shotgun sequencing in patients with LS and vulvar HSIL compared to healthy controls. Biophysical properties of the vulvar skin were additionally explored as the microbiome composition can influence the skin barrier function.<sup>25</sup>

## Methods

### TRIAL DESIGN AND SUBJECTS

This study was part of an observational clinical trial to identify biomarkers for premalignant vulvar disease to increase the understanding of the aetiology of vSCL. The trial was conducted at the Centre of Human Drug Research in Leiden (the Netherlands) from February 2021 to October 2021. The Declaration of Helsinki was the guiding principle for trial execution and the study was approved by the medical ethics committee 'Medisch-Ethische Toetsingscommissie Leiden Den Haag Delft' prior to initiation. Written informed consent from all participants was obtained prior to any study-related procedure.

Criteria for inclusion were women aged between 25 to 95 years with BMI <30kg/m<sup>2</sup>. Patients with vulvar HSIL were required to have ≥1 demarcated lesion(s) ≥15 mm in diameter with confirmed histologic diagnosis. Patients with lichen sclerosus were considered eligible in case of a clinical and/or histological diagnosis of LS. Exclusion criteria were significant concomitant diseases, pregnancy, immunodeficiency, sexually transmitted disease, AIDS or hepatitis. Furthermore, individuals with other dermatological conditions in the genital area were excluded.

Lifestyle restrictions were incorporated to standardize vulvar conditions for microbiome sampling. A ≥28-day wash-out applied for systemic immunomodulatory medication and antibiotic use (topical or systemic). Wash-out for topical medication on the vulvar area was ≥14 days. Participants were instructed to refrain from sexual intercourse, vigorous exercise, applying vulvar products and shaving, waxing or other depilatory treatments at least 24 hours before every visit. Additionally, they were instructed not to wash the vulvar area from midnight onwards on every visit. In total, 10 healthy volunteers, 5 patients with HSIL and 10 patients with LS were enrolled in this observational study. Anal, vaginal and vulvar samples were obtained at a single time point for vulvar HSIL and LS patients, as well as healthy volunteers.

### MICROBIOME CHARACTERISATION

#### Sample collection

The vulvar microbiome was characterised in LS and HSIL patients as well as in the healthy volunteers. Microbiome samples were obtained using a 1 mL DNA/RNA Shield™ Collection Tube with Swab (Zymo Research, Freiburg, Germany). The pre-wetted swab with saline was rubbed along the vulvar skin for 30 seconds while slowly rotating the swab. Sampling locations on the vulva (i.e. labia minora, labia majora or perineum) depended on the location of the vulvar lesions (*Supplementary Table 1*). Healthy-appearing vulvar skin contralateral to the HSIL lesion was selected as non-lesional HSIL reference site where possible. Of note for LS, the non-hirsute vulvar skin should be considered affected, even if the skin appears healthy. Therefore, non-lesional LS sites were selected on the distal side of the labia majora towards the groin. Reference samples of the vaginal microbiome were obtained by introducing a dry swab mid-vaginally and once rotating 360 degrees along the vaginal wall, without touching the vulvar area upon introduction or removal. Another reference sample of the anal microbiome was obtained by rubbing a dry swab along the anus five times. Samples were stored in DNA/RNA shield at -80°C until DNA extraction was performed.

#### DNA extraction

DNA of vulvar, vaginal and anal swabs was extracted with the Quick-DNA Fecal/Soil Microbe Miniprep kit (Zymo Research; D6010). During DNA extraction, positive controls (D6300 ZymoBIOMICS Microbial Community standard, Zymo Research, USA) and negative controls (empty tubes) were included. In short, 600 µL BashingBead Buffer was added to the swabs and processed with Precellys 24 Homogenizer (Bertin Technologies) at 5500 RPM for three rounds of 60 seconds each. Subsequently, samples were centrifuged (10,000 RCF; 1 minute), 800 µL supernatant was transferred to a Zymo-Spin III-F Filter and centrifuged again (8000 RCF; 1 minute). Next, 1200 µL Genomic Lysis Buffer was added to the filtrate. Of the resulting mixture, 800 µL was transferred to a Zymo-Spin IIC Column and centrifuged (10,000 RCF; 1 minute). After discarding the flowthrough, 200 µL of DNA Pre-Wash Buffer was added to the Zymo-Spin IIC Column and centrifuged (10,000 RCF; 1 minute). 500 µL g-DNA Wash Buffer was added to the Zymo-Spin IIC Column and centrifuged (10,000 RCF; 1 minute) after which 50 µL DNA Elution Buffer was added

and centrifuged (10,000 RCF; 30 seconds). The eluted DNA was transferred over the same column and centrifuged (10,000 RCF; 30 seconds). Lastly, the eluted DNA was transferred to a prepared Zymo-Spin III-HRC Filter and centrifuged (16,000 RCF; 3 minutes). The resulting DNA was quantified with a Qubit 4 fluorometer (Invitrogen). In total, 175 out of 178 samples yielded measurable concentrations of DNA.

### **Shotgun metagenomic sequencing**

DNA and additional positive sequencing controls were analysed using shotgun metagenomic sequencing by GenomeScan (Leiden, the Netherlands). Upon sample entry, quality of samples was assessed by the Fragment Analyzer (Advanced Analytical Technologies) according to GenomeScan protocol. Given their low biomass, 118/175 (67%) samples passed quality control of >30 pg/ml (of which 24/44 (55%) anal, 45/45 (100%) vaginal, 45/78 (58%) vulvar samples, 0/4 (0%) negative controls and 4/4 (100%) positive controls), yet all samples were included for shotgun metagenomic sequencing.

Sequencing libraries were prepared using Illumina's DNA PCR-Free Prep kit and checked on quality with the Fragment Analyzer. Libraries were sequenced with the Illumina NovaSeq6000 platform to a target depth of 3.3 million reads per sample.

## **BIOPHYSICAL ASSESSMENTS**

### **Trans-epidermal water loss**

Measurement of the trans-epidermal water loss (TEWL) determines the skin barrier function in a non-invasive manner (AquaFlux AF200 System, Biox, London, UK). The measurements were performed under standard environmental conditions and patients were acclimatized with removed clothing for ≥15 minutes before initiation of the measurements. All TEWL measurement conditions were constant during the study, with mean probe temperatures of 24.3 °C and average humidity of 39.2%. A measurement was considered valid at the settling of the flux curves at a final steady level, as described previously.<sup>27</sup>

### **Vulvar and vaginal pH analysis**

Vulvar skin pH was determined using an electronic pH probe (Skin-pH-Meter PH905, Courage and Khazaka, Cologne, Germany). The average of three consecutive readings was recorded. The vaginal pH was measured by collecting

vaginal fluid using a sterile Puritan swab rotated once mid-vaginally and subsequently applied to colour-coded pH paper (Macherey-Nagel, pH 4.0-7.0), as described previously.<sup>28</sup>

## **BIOINFORMATIC PROCESSING**

### **Metagenomics pre-processing**

Raw data were pre-processed with an in-house workflow (online available at: <https://git.lumc.nl/snooij/metagenomics-preprocessing>). In short, the workflow removes the host genome reads and subsequently performs quality trimming of the reads. First, the host genome was removed using *bowtie2* (version 2.4.2) by mapping reads to the human reference genome.<sup>29</sup> The parameters passed in *bowtie2* included 'very-sensitive-local' and reference genome 'GRCh38.p7' [[https://www.ncbi.nlm.nih.gov/assembly/GCF\\_000001405.33/](https://www.ncbi.nlm.nih.gov/assembly/GCF_000001405.33/)]. Unmapped, paired reads were filtered from the output using *samtools* (version 1.11).<sup>30</sup> Subsequent filtered reads were processed with *fastp* (version 0.20.1) performing quality trimming, adapter removal and low-complexity filtering.<sup>31</sup> *Fastp* parameters included trim 'cut-right, cut\_window\_size 4 cut\_mean\_quality 20'; minlen '-l 50'; adapter 'detected\_adapter\_for\_pe'; complexity '-y'. The mean total reads before processing, after filtering for human reads and after quality trimming, were calculated per study group and sample type (*Supplementary Table 2*).

### **Microbial community profiling**

Pre-processed reads were analysed using *MetaPhlan* (version 3.0.14) to profile the composition of the microbial communities and to predict read counts.<sup>32</sup> To profile the composition of the microbial communities, 'add\_viruses' and 'unknown\_estimation' were added besides default parameters. The outputs were merged with 'merge\_metaphlan\_tables.py'. For the predicted read counts, parameters '-trel\_ab\_w\_read\_stats', 'add\_viruses' and 'unknown\_estimation' were included besides default parameters. Outputs were merged with an adapted version of the merge utility script. The pre-processed sequences mapped to 855 taxa (661 Bacteria, 152 Viruses, 33 Eukaryota and 9 Archaea).

### **Data analysis and availability**

The resulting abundance tables were analysed and visualized using R version 4.1.2 (Vienna, Austria).<sup>33</sup> For data analyses, samples of timepoint 1 were

selected resulting in 89 samples (LS, n=39; HSIL, n=20; healthy controls, n=30). Shannon diversity and Chao1 richness were computed with the *phyloseq* package (version 1.38.0) at 'ASV' level.<sup>34</sup> The *stat\_compare\_means* from the *ggpubr* package (version 0.4.0) were used to compute overall significant differences with a Kruskal-Wallis test and to compare means between swab sites with the Wilcoxon Rank Sum Test.<sup>35</sup> The abundance table was transformed to compositional data with the *microbiome* package (version 1.16.0). Subsequently, the mean relative abundance of the ten most abundant genera was visualized with *ggplot2* (version 3.3.6) for the bacterial and viral kingdoms on non-lesional and lesional skin of each study group.<sup>36,37</sup> For Linear discriminant analysis Effect Size (LEfSe), an object was created with the *phyloseq2lefse* function from the *phyloseqCompanion* package (version 1.1.).<sup>38</sup>

Subsequent LEfSe analyses were performed until species level with default parameters (except LDA score > 4.0) on the Huttenhower lab Galaxy server to assess differences in relative abundance between lesional skin of LS patients and healthy vulvar skin, as well as lesional skin of vulvar HSIL patients and healthy vulvar skin.<sup>39</sup> Aitchison distance was calculated for the Principal coordinate analyses (PCOA). On genus-level data, Centered Log Ratio (CLR) transformation was performed using the *transform* function of the *microbiome* package. The *distance* function of the *phyloseq* package was used to generate a distance matrix with Euclidean distance. The *betadisper* function from the *vegan* package (version 2.6-4) was used to assess differences in variation between swab sites, while *adonis2* was used to assess differences in centroids of the swab sites and study groups with constrained permutations for each patient.<sup>40</sup> Alluvial plots were generated by calculating the mean relative abundance of the ten most abundant genera in each swab site for LS and vulvar HSIL. Since each swab site amounted to a total relative abundance of 100%, mean relative abundances for each swab site were normalized by dividing the relative abundances by the number of swab sites included. Alluvial plots were visualized using *ggplot2* and *ggalluvial* (version 0.12.3).<sup>41</sup>

### Quality control

Positive and negative controls were included during DNA extraction, and additional positive controls were included during sequencing. Positive and negative DNA extraction controls were compared for mean total reads. Mean total reads of the positive controls (4,742,574) were significantly higher (Wilcoxon Rank Sum Test, p=0.03) compared to the mean total reads of the negative

controls (12,565). Although having significantly lower number of reads, the negative controls contained skin-derived bacterium *Cutibacterium acnes*.

Additionally, the taxonomic species composition of the positive controls was compared to each other and to the theoretical mock community composition. All species of the mock community could be identified in the positive controls, except *Bacillus subtilis*. Instead, *Bacillus intestinalis* was identified, which has previously been reported as expected misclassification of *Bacillus subtilis* using the MetaPhlAn taxonomy database.<sup>42</sup> The bacterial species are present in equal ratios, indicating overrepresentation (>15% increase) of *Lactobacillus fermentum* and underrepresentation (>15% decrease) of *Pseudomonas aeruginosa*, *Enterococcus faecalis*, *Staphylococcus aureus*, *Listeria monocytogenes*, *Saccharomyces cerevisiae* and *Cryptococcus neoformans* (Supplementary Figure 1).

### Data availability

All pre-processed metagenomics data have been deposited in the European Nucleotide Archive under accession number PRJEB61325.

## Results

### COHORT CHARACTERISTICS

In total, 25 women were included in the study. Baseline characteristics were comparable between groups (Supplementary Table 3). Menopausal status and age were equally distributed. Most (24/25) participants were of Caucasian descent, with one healthy volunteer of mixed Caucasian and Latin American descent. All LS and vulvar HSIL patients had previously undergone one or multiple treatments for their vulvar condition, while healthy volunteers were naïve to any treatments of the vulvar skin.

### VULVAR MICROBIAL SKIN DIVERSITY OF DISEASED SKIN RESEMBLES THAT OF HEALTHY SKIN

Diversity and richness of the bacterial and viral fraction were used to assess differences in microbial ecology between vulvar skin of healthy controls and of LS and HSIL patients. Healthy vulvar skin had a higher mean diversity compared to the non-lesional skin of LS patients (p=0.002), while other comparisons to healthy skin were not significant (Figure 1). Interestingly, within the patient groups, lesional vulvar skin showed a non-significant rise in mean diversity and richness compared to non-lesional skin.

## THE BACTERIAL FRACTION ON DISEASED VULVAR SKIN DIFFERS FROM HEALTHY VULVAR SKIN

To further assess differences in the microbial ecology of healthy vulvar skin and vulvar skin of LS and vulvar HSIL patients, taxonomic profiles of the bacterial and viral fraction were generated (Figure 2, Supplementary Figure 2 and 3). The bacterial and viral fraction are considered separately below.

The main bacterial genera identified in non-lesional and lesional skin of LS and vulvar HSIL patients were similar as observed in healthy vulvar skin (Figure 2A). These bacterial genera included *Prevotella*, *Lactobacillus*, *Staphylococcus* and *Gardnerella*.

LEfSe analyses were used to identify differentially abundant taxa between healthy vulvar skin and skin lesions in LS and vulvar HSIL. Regarding the bacterial fraction, lesional vulvar skin of LS patients was characterized by a depletion by taxa from the *Prevotella* genus and *Bacteroidales* order compared to healthy skin (Figure 3A,C,D). Meanwhile, lesional skin of HSIL patients showed an increase in the *Fusobacteria* phylum and depletion in the *Actinobacteria* class (Figure 4A,C,D).

## PAPILLOMAVIRIDAE ARE ABUNDANT BOTH IN LS AND HSIL

For the viruses, various taxa were identified on the vulva of 6/10 healthy women, although predicted read counts were relatively low compared to the bacterial reads (565 ± 892 viral reads vs. 987,765 ± 1,140,330 bacterial reads) (Supplementary Figure 4). Viruses were more often identified in LS and vulvar HSIL patients (LS: 10/10, HSIL: 4/5). The non-lesional and lesional skin in LS and HSIL patients mainly comprised viruses within the *Papillomaviridae* family, while these were present but not dominant in healthy vulvar skin (Figure 2B). Although viruses were prevalent, the abundance of the total viral fraction on diseased skin was not significantly larger than on healthy vulvar skin ( $p = 0.15$ , Wilcoxon Rank Sum Test).

LEfSe results for the viral fraction showed that *Papillomaviridae* and *Alphapapillomaviruses* were significantly more abundant in vulvar lesional skin of LS and vulvar HSIL patients compared to healthy controls, respectively (Figure 3A,B and 4A,B). More specifically, various mucosal and cutaneous HPV types were identified in LS and vulvar HSIL (Supplementary Table 4). While non-lesional and lesional vulvar skin of HSIL patients mainly contained Alphapapillomaviruses 7 and 9 species (corresponding to clinical hrHPV types

18/45 and 16/31/33, respectively), the HPV profile of LS was more diverse.<sup>5</sup> Alphapapillomaviruses 3, 6 and 13 were detected in both non-lesional and lesional vulvar LS skin. Clinically, these species correspond to several high- and low-risk HPV types, but not HPV type 16 or 18.

## PREVOTELLA SPP. ARE SHARED BETWEEN VULVAR LESIONAL SKIN, THE VAGINA AND ANUS IN LICHEN SCLEROSUS AND VULVAR HIGH-GRADE SQUAMOUS INTRAEPITHELIAL LESIONS

To further investigate the variation in the microbiome between (non-lesional and lesional) vulvar skin and vagina and anus, a Principal Coordinates Analysis was performed. The non-lesional and lesional vulvar skin showed overlap with the anus, suggesting the microbiome in vulvar skin is similar to the anal environment (Figure 5). However, PERMANOVA indicated the variation between sampling sites was significantly different ( $p = 0.001$ ). Yet, the non-homogenous dispersion among the swab sites may have affected these PERMANOVA results.

To further assess horizontal transfer of the vaginal and anal environment to (lesional) vulvar skin and vice versa, the distribution and flow of genera was visualized (Figure 6). In both LS and HSIL patients, the *Lactobacillus* and *Gardnerella* genera were predominantly detected in the vagina and in lower relative abundances on the non-lesional and lesional skin and anus. Additionally, genera including *Campylobacter*, *Corynebacterium*, *Fingoldia* and *Gardnerella* were shared between the anus and non-lesional and lesional vulvar skin in LS and HSIL. Moreover, *Alphapapillomavirus* spp. were identified on all skin sites in vulvar HSIL patients. Interestingly, in LS patients *Prevotella* spp. was scarcely present on non-lesional vulvar skin while being detected on lesional vulvar, anal and vaginal skin sites.

## EUKARYOTA AND ARCHAEA ARE RARELY DETECTED ON VULVAR SKIN

Compared to bacterial and viral taxa, Eukaryota and Archaea were rarely identified and in low abundance (Supplementary Table 5). The most observed fungus was *Mallassezia globosa*, which was detected in low relative abundance (up to 2%) on vulvar sites of 3/10 LS patients and 1/10 healthy volunteers while being absent in the vaginal or anal milieu. *Methanobrevibacter smithii* was the most frequently found Archaea, albeit in low relative abundance (up to 1%), in anal samples of 7 participants across groups.

## THE BARRIER FUNCTION OF LESIONAL VULVAR SKIN IN VULVAR HSIL IS IMPAIRED

The barrier function of the vulvar skin was assessed with TEWL. A significantly higher TEWL flux was observed between lesional vulvar HSIL (mean (SD) 79.2 g/m<sup>2</sup>/h (±44.9)) and healthy controls (mean (SD) 42.2 g/m<sup>2</sup>/h (±27.8);  $p=0.043$ ) (Figure 7). No significant differences in TEWL flux were observed between lesional LS (mean (SD) 57.5 g/m<sup>2</sup>/h (±36.8)) and healthy controls,  $p=0.309$ , nor between the non-lesional and the lesional sites of HSIL,  $p=0.810$ . The lesional site of LS patients had a significant higher flux compared to the non-lesional LS site,  $p=0.006$ .

The mean vulvar pH of lesional LS and HSIL was 5.72 (SD 0.45) and 6.21 (SD 0.8), respectively, with no significant changes over time (Supplementary Figure 5). Non-lesional vulvar skin and vaginal pH of patients and healthy volunteers did not display group differences or changes over time (data not shown). Menopausal status was the stratifying factor for observed differences in pH in the LS and healthy control group.

## Discussion

This exploratory study shows that the vulvar skin of patients with LS and HSIL — both non-lesional and lesional — differs from healthy vulvar skin, which was most prominent for the viral fraction. Notably, papillomaviruses were characteristic for LS, despite being considered an HPV-independent condition. In the bacterial fraction, *Prevotella* spp. were less abundant in LS than healthy vulvar skin, but shared between vulvar skin, vaginal and anal sites, indicating potential horizontal transfer between sites. This study is the first to compare the vulvar microbiome composition of LS and HSIL to healthy controls using metagenomic sequencing techniques. The distinct bacteria and viruses found in both LS and vulvar HSIL warrant further investigation and may aid in future identification of driving factors or biomarkers for vulvar (pre)malignant diseases.

The bacterial fraction of vulvar LS skin shared many taxa with healthy vulvar skin, mainly comprising *Lactobacillus*, *Prevotella* and *Gardnerella* genera, which were also previously identified in LS and vulvodynia.<sup>24</sup> Specifically in vulvar LS, depletion of *Lactobacillus* and gain of *Prevotella* species has previously been described in juvenile LS.<sup>43</sup> The opposite was observed in this

study, where taxa from the *Prevotella* genus were reduced in LS compared to healthy vulvar skin. Meanwhile within the LS group, *Prevotella* spp. were shared between anal, vaginal and lesional LS skin sites, but almost absent on non-lesional vulvar skin. Thus, the exact role of *Prevotella* in LS remains inconclusive.<sup>43,44</sup> Relative abundance of *Staphylococcus* spp. seemed higher in non-lesional vulvar skin, which likely reflects the more skin-like sampling location toward the groin. Based on differential abundance analysis, a significant overrepresentation of papillomaviruses and an underrepresentation of taxa from the *Prevotella* genus and the *Bacteroidales* order were characteristic for LS compared to healthy controls. Interestingly, LS is considered a HPV-independent precursor of vSCC, although concurrent HPV-infections have been previously reported.<sup>45-47</sup> Co-occurrence of LS and papillomaviruses may be coincidental, given the high prevalence (~10%) of both high- and low-risk genital HPV infections in the general female population.<sup>46,48</sup> Alternatively, our results may point toward an etiological role of HPV in LS, in which a sub-clinical HPV-infection could hypothetically induce LS in genetically and/or immunologically predisposed women. Such infection could occur through disruption of the skin barrier and local immune environment, known as the Koebner phenomenon.<sup>49</sup> This could apply for both high- and low-risk HPV types as observed in LS patients of our cohort. However, no significant increase of TEWL — i.e. decrease in skin barrier function — in LS skin was observed compared to healthy controls. Another explanation for the observed co-occurrence of HPV in LS could be that skin damage or immunosuppression from corticosteroid treatment in pre-existing LS facilitates colonisation with papillomaviruses. These observations in LS lead to the hypothesis that women who eventually develop vSCC may display immunological variations resulting in less effective viral clearance.

Like LS, the vulvar skin of HSIL shared bacterial genera with healthy vulvar skin. The lesional skin of vulvar HSIL was characterized by significant increases in relative abundance of the Fusobacteria phylum and *Alphapapillomavirus* species, while the *Actinobacteria* class was significantly reduced compared to healthy controls. The presence of high-risk *Alphapapillomaviruses* corroborates with the HPV-driven aetiology of vulvar HSIL. Although no data on vulvar skin sites in HSIL is available hitherto, cervical dysplasia closely relates to vulvar HSIL and has been studied extensively. In cervical dysplasia, *Sneathia*, *Mycoplasma* and *Prevotella* species have been associated with co-infection and persistence of hrHPV types.<sup>16,19-23,50,51</sup> *Prevotella* has been

designated as marker genus for cervical cancer, where it may influence HPV persistence through NOD-like receptor signalling.<sup>52</sup> These findings indicate that functional processes, driven by the microbiome, potentially contribute to persistence or progression of cervical HPV-driven diseases. No significant overrepresentation of these taxa was identified in this study to vulvar HSIL. Furthermore, microbiome composition plays an integral role in the skin barrier, interacting with its other – physical, immunological and chemical – components.<sup>25</sup> For example, TEWL can change upon topical application, in which *Lactobacillus* and *Corynebacterium* formulations led to increased and reduced TEWL, respectively.<sup>53-56</sup> Our results show that TEWL was significantly increased in affected vulvar HSIL skin, indicating a disrupted skin barrier function.<sup>57,58</sup> Whether these observed differences represent a disease-driven disturbance of skin barrier function or are due to variability in sampling location will require confirmation in an expanded population.

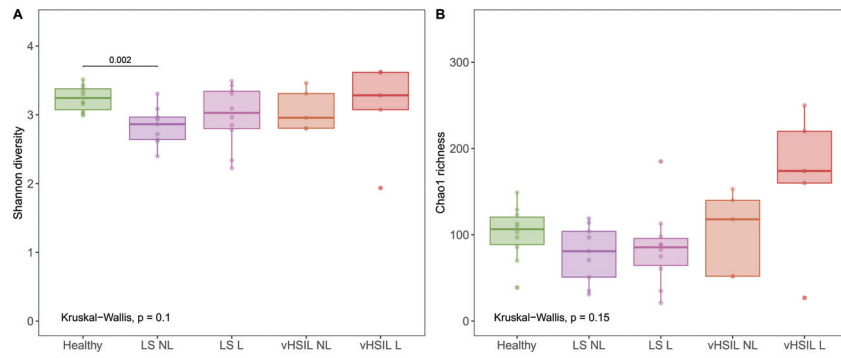
Besides bacteria and viruses, metagenomic sequencing allowed for the identification of Archaea and Eukaryota. Solely two Archaea were identified in low prevalence and abundance. To date, no Archaeal taxa are associated with pathogenesis and are generally considered commensals.<sup>59,60</sup> Eukaryotic (i.e. fungal) *Mallasezia globosa* was also identified, albeit in low relative abundance, on non-lesional vulvar sites of LS patients, but not in healthy controls or vulvar HSIL. Previously, *Mallasezia globosa* was the most identified fungal species on healthy labia majora.<sup>61</sup> *Candida* taxa were detected once in this study, despite the reported *C. albicans* colonisation rate of 20% in the general female population.<sup>62</sup>

The main strengths of this study are the case-control trial design including patients and healthy controls with inter-participant lesional and non-lesional control. Vaginal and anal samples allowed for intra-individual comparison and correlation of results with literature. Also, this study is the first to investigate microbiome composition in vulvar HSIL. Limitations of this exploratory study mostly pertain to the low sample size. As such, future studies are needed to confirm the findings described herein. In addition, our study did not include longitudinal analyses, although we assume that the vulvar and vaginal microbiome can be particularly subject to temporal changes. Factors dictating microbiome composition fluctuations may include cycle-related changes, demographic background and lifestyle choices including sexual activity, hair removal practices and intimate hygiene routines.<sup>63-69</sup> Lastly, the absence of certain taxa or inability to identify a proportion of the sequences

may be attributed to the low biomass samples as well as the non-amplification sequencing method.

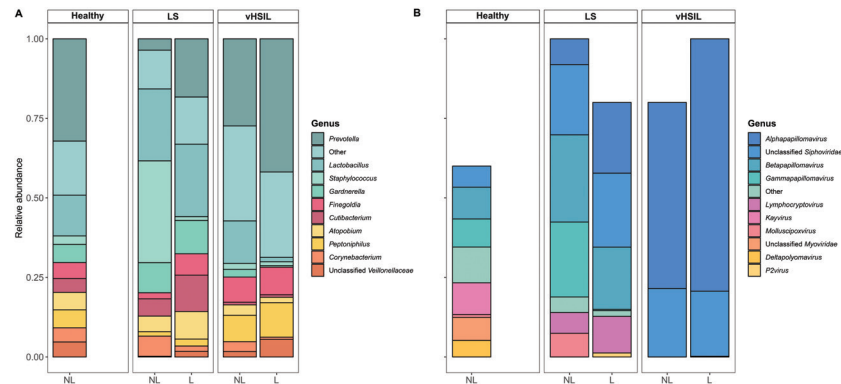
The vulvar microbiome is a growing research field, with ongoing trials in LS (NCT05671263, NCT05147129), vulvar Paget's disease (NCT03564483) and lichen planus (NCT05330572).<sup>70-73</sup> Future studies should strive to include a variety of vulvar diseases, such as dVIN and vSCC (HPV-positive or HPV-negative) to capture the full disease spectrum from healthy vulvar skin to vSCC. Linking microbiome findings to changes in the tumour microenvironment may be further explored, as recently reported for vSCC.<sup>74</sup> Novel treatments could be developed based on microbial targets, as previously attempted for bacterial vaginosis and genitourinary symptoms.<sup>75-77</sup> Studies to new treatment modalities, such as the current clinical trial applying the topical JAK-inhibitor ruxolitinib in LS, could consider assessing the microbiome composition as exploratory biomarker.<sup>78-80</sup> The vulvar research field to date has mainly identified presence of taxa without appraisal their involvement in biophysical or pathologic processes, which should be the focus for future studies to unravel.

**Figure 1 Diversity and richness of the bacterial and viral fraction of the vulvar skin microbiome.** A) Diversity measured by the Shannon index. B) Richness measured by the Chao1 index.



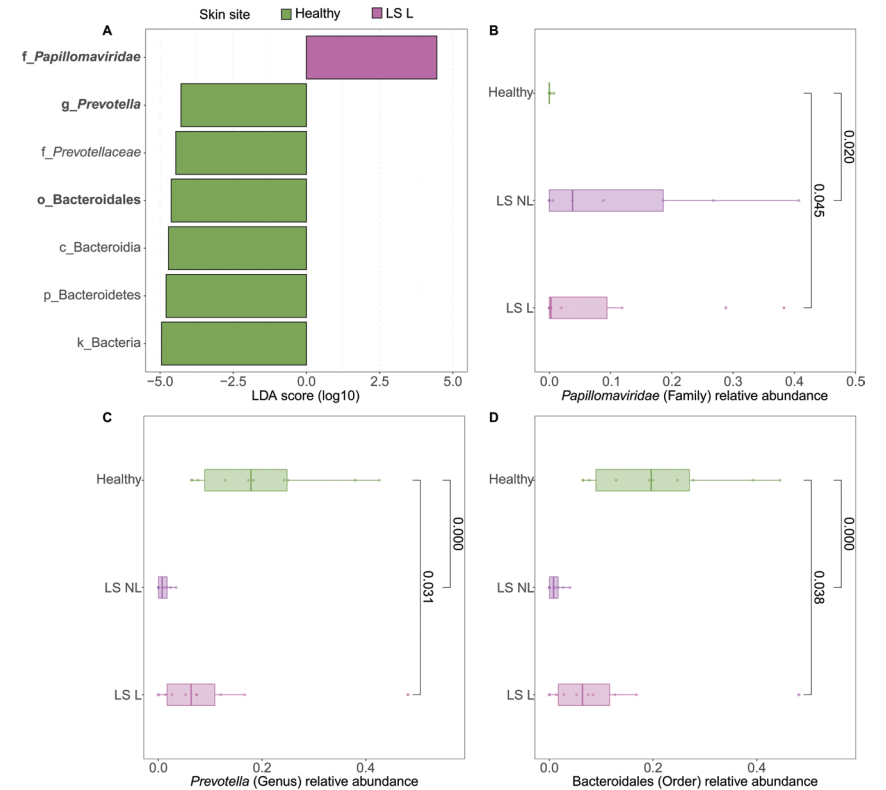
LS = lichen sclerosis, vHSIL = vulvar high-grade squamous intraepithelial lesions, NL = non-lesional (healthy appearing) vulvar skin, L = lesional vulvar skin. Only significant P-values are displayed.

**Figure 2 Mean relative abundance on genus level of A) the bacterial fraction and B) the viral fraction of the microbiome in healthy controls, LS patients and HSIL patients.** For each study group, the taxonomic profiles of non-lesional (NL) and lesional (L) vulvar skin are displayed. No viral taxa were detected in some individuals, (Supplementary Figure 1), therefore the bars do not accumulate to 100% in these summary graphs.



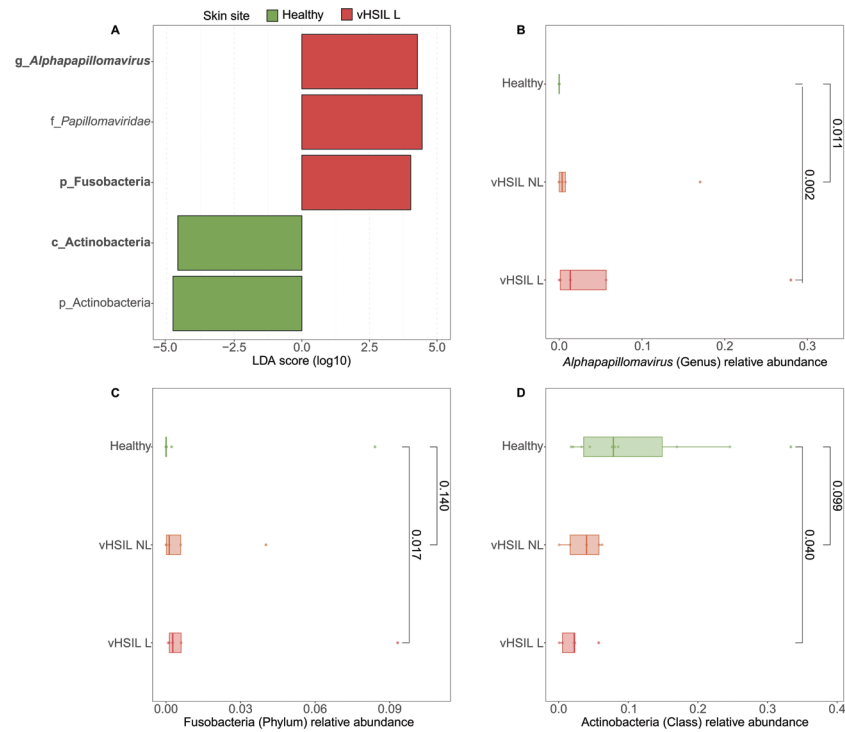
LS = lichen sclerosis, vHSIL = vulvar high-grade squamous intraepithelial lesions, NL = non-lesional (healthy appearing) vulvar skin, L = lesional vulvar skin.

**Figure 3 Differentially abundant features in lesional vulvar skin of lichen sclerosis patients compared to healthy controls.** A) LEfSe analysis histogram of LDA scores (log10) showing overrepresented taxa (pink) and underrepresented taxa (green) in lesional vulvar skin of lichen sclerosis patients. Taxa with LDA scores above 4.0 were selected and unclassified taxa were excluded for viewing purposes. Bold taxa were differential abundant features classified to the lowest taxonomic level and used for figure B, C and D. B + C + D) Distribution of differential abundant features in of individual samples per skin site with B) showing overrepresented family *Papillomaviridae*, c) the underrepresented genus *Prevotella* and D) the underrepresented order *Bacteroidales* in lesional vulvar skin of lichen sclerosis patients.



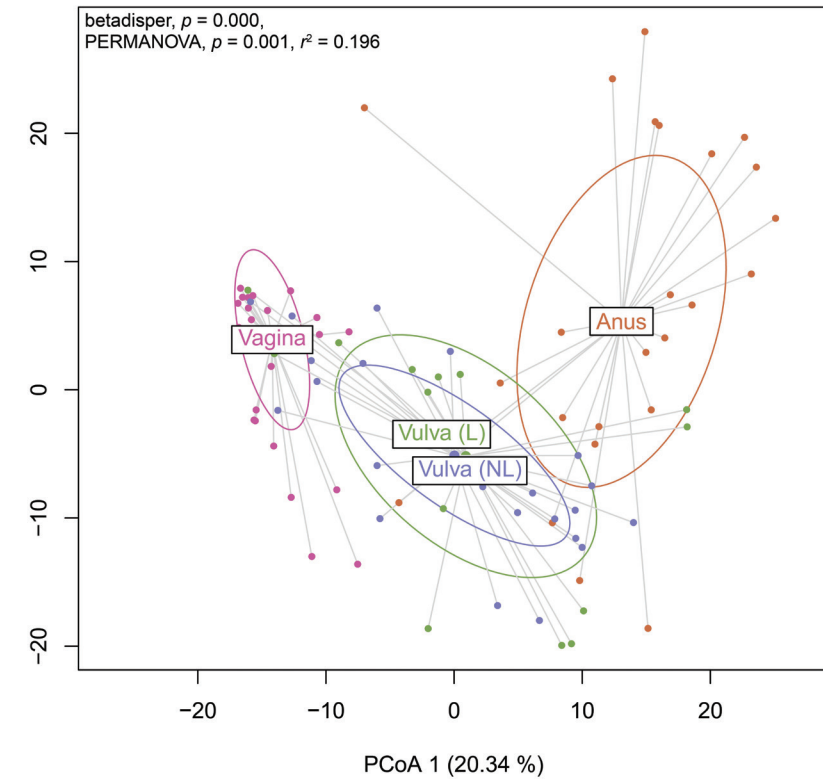
LS = lichen sclerosis, NL = non-lesional (healthy appearing) vulvar skin, L = lesional vulvar skin.

**Figure 4 Differentially abundant features in lesional skin of vulvar HSIL patients compared to healthy controls.** A) LEfSe analysis histogram of LDA scores (log<sub>10</sub>) showing overrepresented taxa (red) and underrepresented taxa (green) in lesional vulvar skin of vulvar HSIL patients. Taxa with LDA scores above 4.0 were selected and unclassified taxa were excluded for viewing purposes. Bold taxa were differential abundant features classified to the lowest taxonomic level and used for figure B, C and D. B + C + D) Distribution of differential abundant features in individual samples per skin site. with B) showing the overrepresented genus *Alphapapillomavirus*, c) showing the overrepresented phylum *Fusobacteria* and D) showing the underrepresented class *Actinobacteria* in lesional vulvar skin of vulvar HSIL patients.

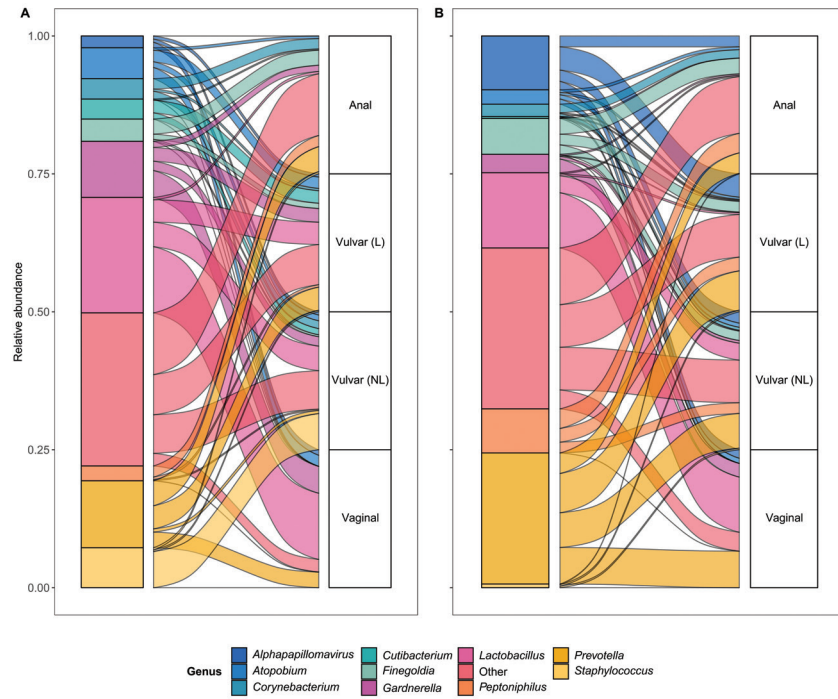


vHSIL = vulvar high-grade squamous intraepithelial lesions, NL = non-lesional (healthy appearing) vulvar skin, L = lesional vulvar skin.

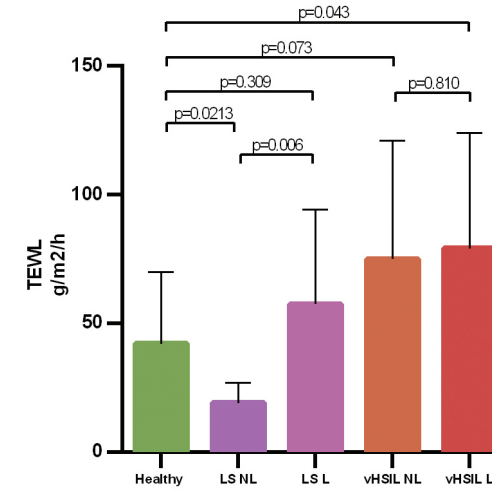
**Figure 5 Principal Coordinates Analysis (PCoA) of Aitchison distances between bacterial and viral communities associated to the swab sites including the vagina, non-lesional (NL) and lesional (L) vulva and anus.** Betadisper  $p = 0.000$ ; PERMANOVA  $p = 0.001$  and  $r^2 = 0.196$ .



**Figure 6** Alluvial plots showing distribution of genera over the different sampling sites. A) Lichen sclerosis and B) vulvar high-grade squamous intraepithelial lesions (HSIL) patients.



**Figure 7** Bar graph showing the trans-epidermal water loss at baseline level for all groups on de non-biopsy site. The mean and standard deviations are displayed for each group. Trans-epidermal water loss in g/m<sup>2</sup>/h (y-axis) plotted against measurements clustered per patient group (x-axis).



LS = lichen sclerosis, vHSIL = vulvar high-grade squamous intraepithelial lesions, NL = non-lesional (healthy appearing) vulvar skin, L = lesional vulvar skin; TEWL = trans-epidermal water loss.

**Supplementary Table 1 Vulvar sampling locations were dependent on the location of the LS and vulvar HSIL lesions.**

		Non-lesional vulvar sample	Lesional vulvar sample
Healthy volunteers	1	labia majora	-
	2	labia majora	-
	3	labia majora	-
	4	labia majora	-
	5	labia majora	-
	6	interlabial fold	-
	7	labia majora	-
	8	interlabial fold	-
	9	interlabial fold	-
	10	interlabial fold	-
vHSIL	11	interlabial fold (contralateral to lesion)	interlabial fold
	12	labia minora (1 cm ipsilateral to lesion)	labia minora
	13	labia minora (contralateral to lesion)	labia minora
	14	labia majora (contralateral to lesion)	labia majora
	15	peri-anal (1 cm ipsilateral to lesion)	peri-anal
Lichen sclerosis	31	labia majora	perineum
	32	labia majora	labia minora
	33	labia majora	labia minora
	34	labia majora	labia minora
	35	labia majora	labia minora
	36	labia majora	labia minora
	37	labia majora	perineum
	38	labia majora	labia minora
	39	labia majora	labia minora
	40	labia majora	labia minora

LS=lichen sclerosis, vHSIL = vulvar high grade squamous intraepithelial lesion

**Supplementary Table 2 Mean reads per study group and sample type.**

Study group	Swab site	Total reads	Human filtered reads	Quality trimmed reads
HV	anal	4,209,498 ± 776,337	2,913,801 ± 1,123,795	2,624,800 ± 1,050,992
HV	NL	3,802,528 ± 374,790	1,167,062 ± 1,024,775	1,020,421 ± 951,046
HV	vaginal	6,776,845 ± 6,049,009	232,400 ± 330,589	182,748 ± 292,229
LS	anal	4,432,395 ± 1,043,317	1,866,656 ± 1,247,402	1,577,247 ± 1,088,727
LS	L	4,449,482 ± 2,084,004	1,626,948 ± 2,757,321	1,446,201 ± 2,585,809
LS	NL	3,720,294 ± 278,923	813,266 ± 604,561	642,854 ± 501,359
LS	vaginal	7,441,991 ± 5,742,836	668,779 ± 1,079,685	615,314 ± 1,044,238
vHSIL	anal	3,642,566 ± 301,661	2,503,325 ± 569,821	2,270,303 ± 573,176
vHSIL	L	11,677,054 ± 9,431,292	6,850,613 ± 6,663,251	6,273,799 ± 5,913,120
vHSIL	NL	3,764,903 ± 320,388	1,488,305 ± 1,410,656	1,244,571 ± 1,191,460
vHSIL	vaginal	5,293,525 ± 526,267	298,871 ± 475,807	253,227 ± 427,368

HV = healthy volunteer, LS = lichen sclerosis, vHSIL = vulvar high-grade squamous intraepithelial lesion, NL = non-lesional, L = lesional

**Supplementary Table 3 Baseline characteristics.**

Characteristics	Healthy control (N=10)	Vulvar high grade squamous intraepithelial lesion (N=5)	Lichen sclerosus (N=10)
AGE in years - mean (range)	46.5 (25-73)	46.6 (32-66)	50.3 (25-72)
Pre-menopausal	5	3	5
Post-menopausal	5	2	5
Body mass index (BMI) in kg/m <sup>2</sup> - mean (range)	22.8 (19.6-27.6)	26.6 (21.6-30.0)	25.7 (18-30)
<b>ETHNICITY - N (%)</b>			
White	9 (90%)	5 (100%)	10 (100%)
Other	1 (10%)*	0 (0%)	0 (0%)
<b>SMOKING - N (%)</b>			
No	9 (90%)	1 (20%)	8 (80%)
Yes	1 (10%)	4 (80%)	2 (20%)
DISEASE DURATION in years - median (range)	N/A	8 (7-25)	5.5 (1-12)
Vulvar squamous cell carcinoma in medical history	0	0	1 (10%)
<b>FITZPATRICK SKIN TYPE - N (%)</b>			
I	1 (10%)	1 (20%)	3 (30%)
II	4 (40%)	1 (20%)	4 (40%)
III	5 (50%)	3 (60%)	3 (30%)
<b>HPV GENOTYPE BIOPSY - N (%)</b>			
HPV16	0	4 (80%)	0
HPV53	0	1 (20%)**	1 (10%)
Negative	10 (100%)	1 (20%)	9 (90%)
<b>PREVIOUS VULVAR TREATMENTS - N (%)</b>			
None	10 (100%)	0	0
Yes, 1 previous treatment	0	1 (20%)	7 (70%)
Yes, 2 previous treatments	0	1 (20%)	3 (30%)
Yes, 3 previous treatments	0	1 (20%)	0
Yes, 4 previous treatments	0	1 (20%)	0
Yes, 5 previous treatments	0	1 (20%)	0
Topical treatment	0	5***	9****
Surgical	0	5	2*****
Coagulation	0	1	0
Laser	0	3	0
HPV vaccination (Gardasil)	0	2	0
Estriol/estradiol (vaginal)	0	0	2

\*Mixed Latin American and Caucasian descent. \*\*One HSIL patient was both HPV 16 and 53 positive; \*\*\*5x imiquimod, 1x 5-FU; \*\*2x triamcinolone acetate, 8x dermivate; \*\*\*\*\* Surgical treatment encompassed vulvectomy and introitus plasty

**Supplementary Table 4 Observed Papillomaviruses detected per subgroup**

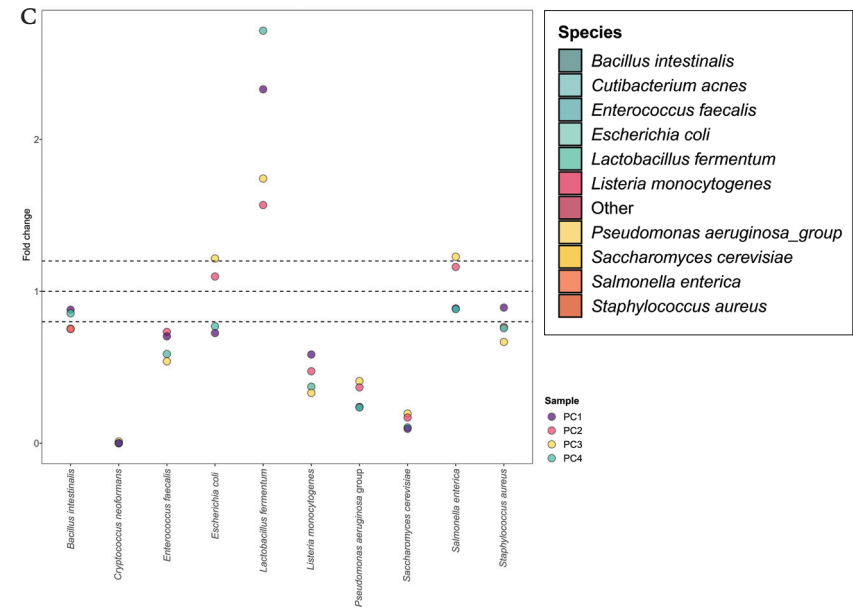
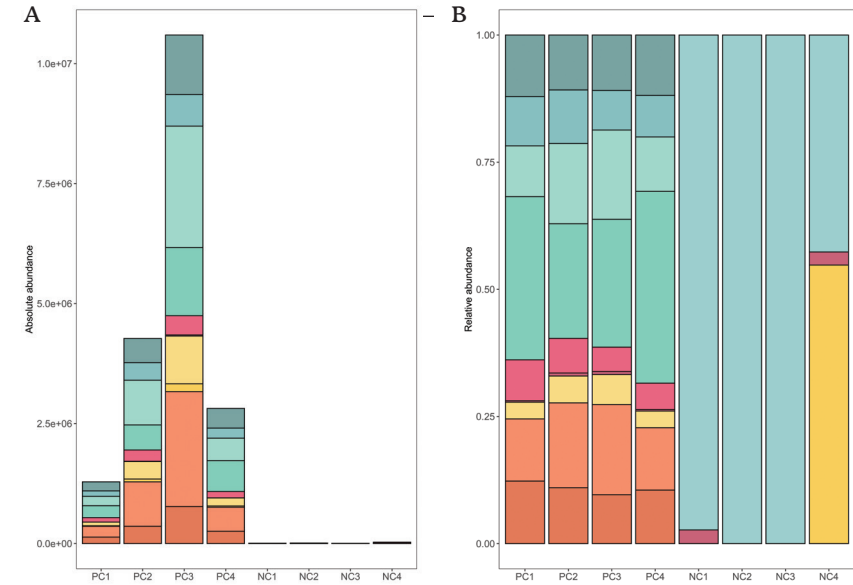
Genus + species	Clinical type	Risk type	Tissue preference	LS		VHSIL		HV	
				NL	L	NL	L	NL	L
Alphapapillomavirus 10	HPV6, HPV11	Low-risk	Mucosal/cutaneous	x		x			
Alphapapillomavirus 13	HPV32, HPV54	Low-risk	Mucosal	x	x				
Alphapapillomavirus 14	HPV3, HPV10	Low-risk	Mucosal						
Alphapapillomavirus 3	HPV3, HPV10	Low-risk	Mucosal	x	x				
Alphapapillomavirus 6	HPV51, HPV56, HPV34	High-risk	Mucosal	x	x				
Alphapapillomavirus 7	HPV18, HPV45	High-risk	Mucosal			x	x		
Alphapapillomavirus 9	HPV16, HPV31, HPV33, HPV52, HPV58	High-risk	Mucosal			x	x		
Betapapillomavirus 1-5	HPV 5, HPV 8	Mostly low risk	Cutaneous	x	x				x
Gamma papillomavirus 7, 8, 9, 11, 19	HPV 4, HPV 60	Low-risk	Cutaneous	x	x				x

Supplementary Table 5 Archaeal and Fungal species identified across groups

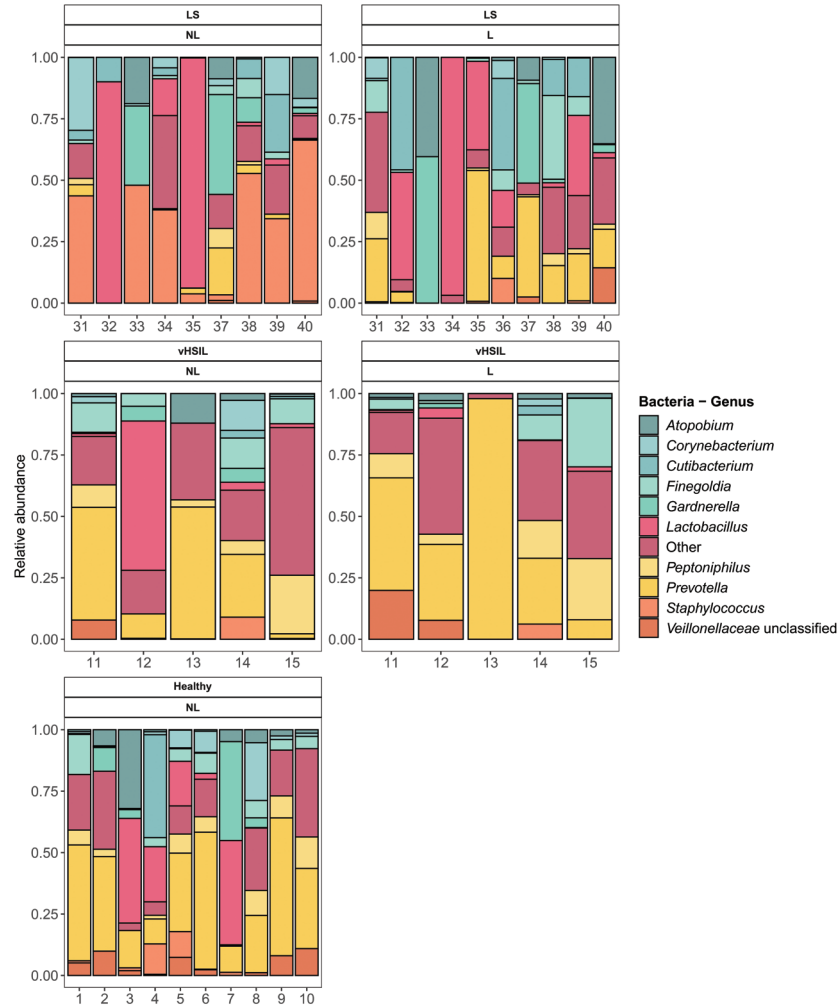
Patient group	Swab site	Total samples	Identified taxa						
			Fungi				Archaea		
			Aspergillus sydowii	Malassezia globosa	Malassezia restricta	Trichomonas vaginalis	Methanobrevibacter smithii	Methanosphaera stadtmanae	
Healthy	anal	10	-	-	-	-	5	-	
Healthy	vulva non-lesional	10	-	1	-	-	-	-	
Healthy	vaginal	10	-	-	-	-	-	-	
vHSIL	anal	5	-	-	-	-	1	1	
vHSIL	vulva-lesional	5	1	-	-	-	-	-	
vHSIL	vulva non-lesional	5	-	-	-	-	-	-	
vHSIL	vaginal	5	-	-	-	1	-	-	
Lichen sclerosis	anal	10	-	-	-	-	-	-	
Lichen sclerosis	vulva-lesional	10	-	2	-	-	1	-	
Lichen sclerosis	vulva non-lesional	9	-	1	1	-	-	-	
Lichen sclerosis	vaginal	10	-	-	-	-	-	-	

vHSIL = vulvar high-grade squamous intraepithelial lesion

Supplementary Figure 1 Positive controls, total reads and relative abundance.

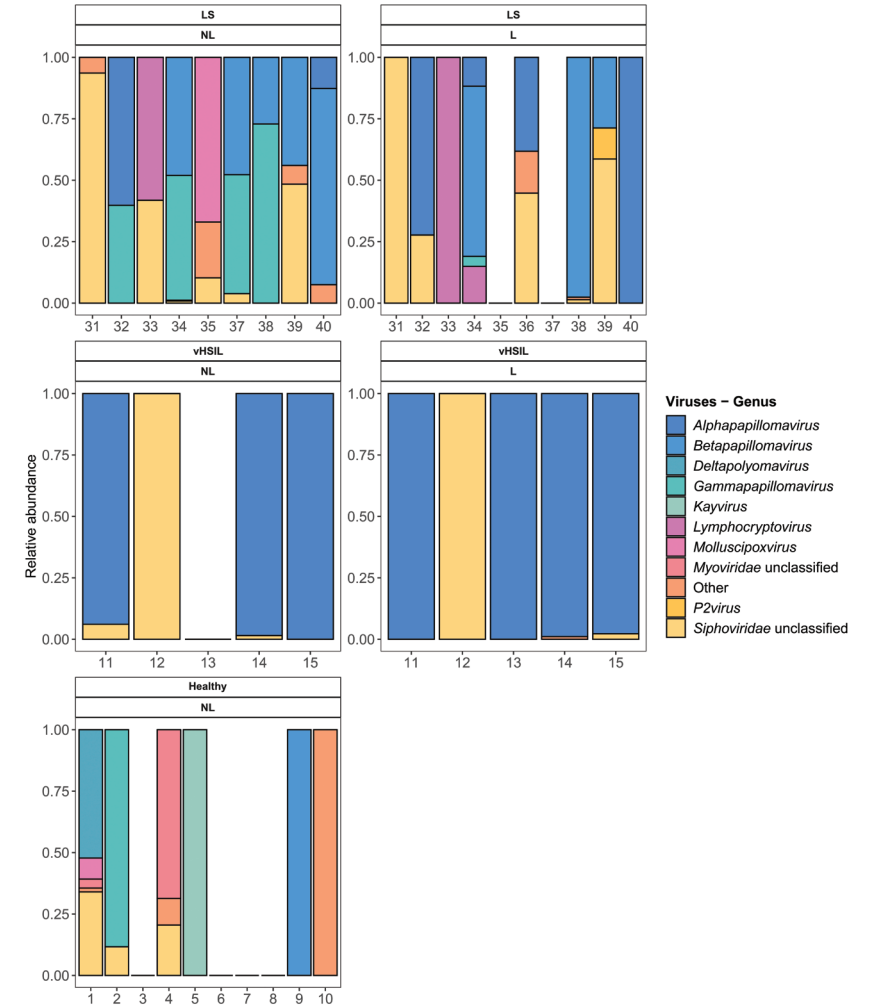


Supplementary Figure 2 Individual bacterial compositions.



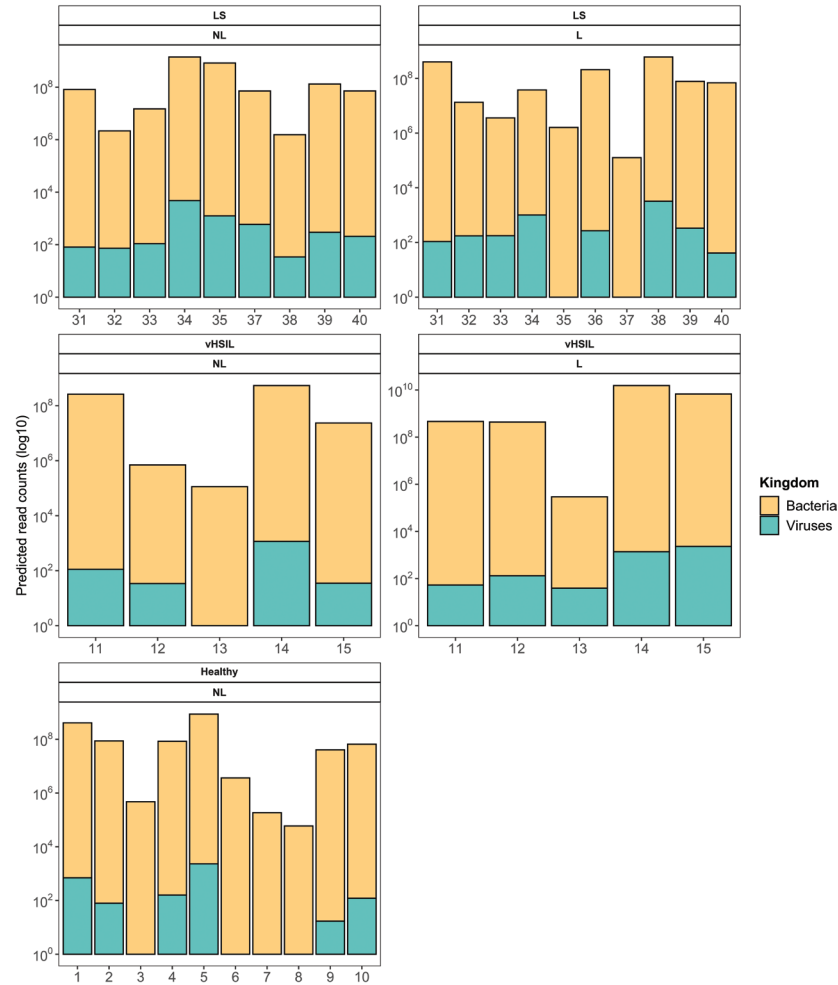
LS = lichen sclerosus, NL = non-lesional, L = lesional, vHSIL = vulvar high-grade squamous intraepithelial lesion

Supplementary Figure 3 Individual viral compositions.



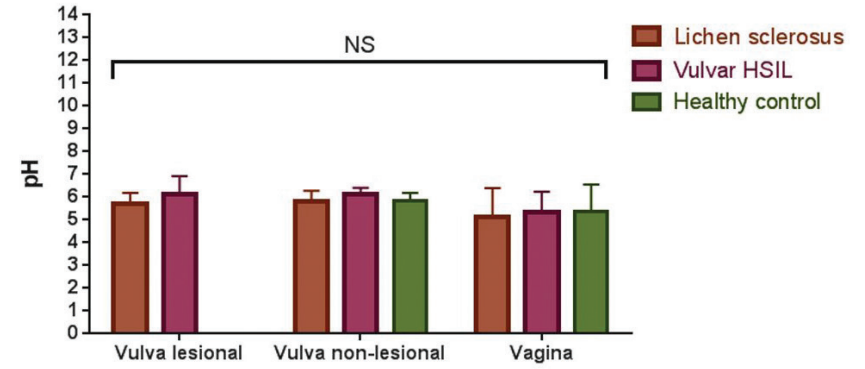
LS = lichen sclerosus, NL = non-lesional, L = lesional, vHSIL = vulvar high-grade squamous intraepithelial lesion

Supplementary Figure 4 Predicted read counts for vulvar samples.



LS = lichen sclerosus, NL = non-lesional, L = lesional, vHSIL = vulvar high-grade squamous intraepithelial lesion

Supplementary Figure 5 Vulvar and vaginal pH.



NS = not significant, vHSIL = vulvar high-grade squamous intraepithelial lesion

## REFERENCES

- 1 Hacker NF, Eifel PJ, van der Velden J. Cancer of the vulva. *Int J Gynecol Obstet.* 2012;119:590-596. doi:https://doi.org/10.1016/S0020-7292(12)60021-6
- 2 de Sanjosé S, Alemany L, Ordi J, et al. Worldwide human papillomavirus genotype attribution in over 2000 cases of intraepithelial and invasive lesions of the vulva. *Eur J Cancer.* 2013;49(16):3450-3461. doi:https://doi.org/10.1016/j.ejca.2013.06.033
- 3 Nitecki R, Feltmate CM. Human papillomavirus and non-human papillomavirus pathways to vulvar squamous cell carcinoma: A review. *Curr Probl Cancer.* 2018;42(5):476-485. doi:10.1016/j.cup.2018.06.008
- 4 van de Nieuwenhof HP, van Kempen LCLTLT, De Hullu JA, et al. The Etiologic Role of HPV in Vulvar Squamous Cell Carcinoma Fine Tuned. *Cancer Epidemiol Biomarkers & Prev.* 2009;18(7):2061 LP - 2067. doi:10.1158/1055-9965.EPI-09-0209
- 5 Cubie HA. Diseases associated with human papillomavirus infection. *Virology.* 2013;445(1-2):21-34. doi:10.1016/j.virol.2013.06.007
- 6 Thuijs NB, van Beurden M, Bruggink AH, Steenberg RDM, Berkhof J, Bleeker MCGG. Vulvar intraepithelial neoplasia: Incidence and long-term risk of vulvar squamous cell carcinoma. *Int J cancer.* 2021;148(1):90-98. doi:10.1002/ijc.33198
- 7 Voss FO, Thuijs NB, Vermeulen RFM, Wilthagen EA, van Beurden M, Bleeker MCG. The vulvar cancer risk in differentiated vulvar intraepithelial neoplasia: A systematic review. *Cancers (Basel).* 2021;13(24). doi:10.3390/CANCERS13246170/S1
- 8 Van De Nieuwenhof HP, Van Kempen LCLT, De Hullu JA, et al. The etiologic role of HPV in vulvar squamous cell carcinoma fine tuned. *Cancer Epidemiol Biomarkers Prev.* 2009;18(7):2061-2067. doi:10.1158/1055-9965.EPI-09-0209
- 9 Lockhart J, Gray NM, Cruickshank ME. The development and evaluation of a questionnaire to assess the impact of vulval intraepithelial neoplasia: a questionnaire study. *BJOG.* 2013;120(9):1133-1142. doi:10.1111/1471-0528.12229
- 10 Pérez-López FR, Vieira-Baptista P. Lichen sclerosus in women: a review. *Climacteric.* 2017;20(4):339-347. doi:10.1080/13697137.2017.1343295
- 11 Mullen MM, Merfeld EC, Palisoul ML, et al. Wound Complication Rates After Vulvar Excisions for Premalignant Lesions. *Obstet Gynecol.* 2019;133(4):658-665. doi:10.1097/AOG.0000000000003185
- 12 Grimm D, Eulenburger C, Brummer O, et al. Sexual activity and function after surgical treatment in patients with (pre)invasive vulvar lesions. *Support Care Cancer.* 2016;24(1):419-428. doi:10.1007/s00520-015-2812-8
- 13 Byrd AL, Belkaid Y, Segre JA. The human skin microbiome. *Nat Rev Microbiol.* 2018;16(3):143-155. doi:10.1038/nrmicro.2017.157
- 14 Feng Q, Liang S, Jia H, et al. Gut microbiome development along the colorectal adenoma-carcinoma sequence. *Nat Commun.* 2015;6:6528. doi:10.1038/ncomms7528
- 15 Picardo SL, Coburn B, Hansen AR. The microbiome and cancer for clinicians. *Crit Rev Oncol Hematol.* 2019;141:1-12. doi:10.1016/j.critrevonc.2019.06.004
- 16 Mitra A, MacIntyre DA, Lee YS, et al. Cervical intraepithelial neoplasia disease progression is associated with increased vaginal microbiome diversity. *Sci Rep.* 2015;5(September):1-11. doi:10.1038/srep16865
- 17 Norenhag J, Du J, Olovsson M, Verstraeten H, Engstrand L, Brusselaers N. The vaginal microbiota, human papillomavirus and cervical dysplasia: a systematic review and network meta-analysis. *BJOG An Int J Obstet Gynaecol.* 2020;127(2):171-180. doi:10.1111/1471-0528.15854
- 18 Piyathilake CJ, Ollberding NJ, Kumar R, Macaluso M, Alvarez RD, Morrow CD. Cervical microbiota associated with higher grade cervical intraepithelial neoplasia in women infected with high-risk human papillomaviruses. *Cancer Prev Res.* 2016;9(5):357-366. doi:10.1158/1940-6207.CAPR-15-0350
- 19 Audirac-Chalifour A, Torres-Poveda K, Bahena-Román M, et al. Cervical microbiome and cytokine profile at various stages of cervical cancer: A pilot study. *PLoS One.* 2016;11(4). doi:10.1371/journal.pone.0153274
- 20 Klein C, Gonzalez D, Kahesa C, et al. The Relationship Between the Cervical Microbiome, HIV Status, and Pre-Cancerous Lesions. *bioRxiv.* 2018;10(1):1-12. doi:10.1101/375592
- 21 Adebamowo SN, Ma B, Zella D, Famooto A, Ravel J, Adebamowo C. Mycoplasma hominis and mycoplasma genitalium in the vaginal microbiota and persistent high-risk human papillomavirus infection. *Front Public Heal.* 2017;5(June):1-10. doi:10.3389/fpubh.2017.00140
- 22 Lee JE, Lee S, Lee H, et al. Association of the Vaginal Microbiota with Human Papillomavirus Infection in a Korean Twin Cohort. *PLoS One.* 2013;8(5). doi:10.1371/journal.pone.0063514
- 23 Łaniewski P, Cui H, Roe DJ, et al. Features of the cervicovaginal microenvironment drive cancer biomarker signatures in patients across cervical carcinogenesis. *Sci Rep.* 2019;9(1):1-14. doi:10.1038/s41598-019-43849-5
- 24 Pagan L, Ederveen RAM, Huisman BW, et al. The human vulvar microbiome: A systematic review. *Microorganisms.* 2021;9(12). doi:10.3390/microorganisms9122568
- 25 Harris-Tryon TA, Grice EA. Microbiota and maintenance of skin barrier function. *Science (80-).* 2022;376(6596):940-945. doi:10.1126/SCIENCE.ABO0693
- 26 Huisman BW, Pagan L, Naafs RGC, et al. Dermatoscopy and Optical Coherence Tomography in Vulvar High-Grade Squamous Intraepithelial Lesions and Lichen Sclerosus: A Prospective Observational Trial. *J Low Genit Tract Dis.* Published online March 2023. doi:10.1097/LGT.0000000000000731
- 27 Niemeyer-van der Kolk T, Buters TP, Krouwels L, et al. Topical antimicrobial peptide omiganan recovers cutaneous dysbiosis but does not improve clinical symptoms in patients with mild to moderate atopic dermatitis in a phase 2 randomized controlled trial. *J Am Acad Dermatol.* 2022;86(4):854-862. doi:10.1016/j.jaad.2020.08.132
- 28 Donders GGGG, Caeyers T, Tydhoof P, Riphagen I, van den Bosch T, Bellen G. Comparison of two types of dipsticks to measure vaginal pH in clinical practice. *Eur J Obstet Gynecol Reprod Biol.* 2007;134(2):220-224. doi:10.1016/j.ejogrb.2006.07.016
- 29 Langmead B, Salzberg SL. Fast gapped-read alignment with Bowtie 2. *Nat Methods.* 2012;9(4):357-359. doi:10.1038/nmeth.1923
- 30 Li H, Handsaker B, Wysoker A, et al. The Sequence Alignment/Map format and SAMtools. *Bioinformatics.* 2009;25(16):2078-2079. doi:10.1093/bioinformatics/btp352
- 31 Chen S, Zhou Y, Chen Y, Gu J. fastp: an ultra-fast all-in-one FASTQ preprocessor. *Bioinformatics.* 2018;34(17):i1884-i1890. doi:10.1093/bioinformatics/bty560
- 32 Beghini F, McIver LJ, Blanco-Míguez A, et al. Integrating taxonomic, functional, and strain-level profiling of diverse microbial communities with bioBakery 3. *Elife.* 2021;10. doi:10.7554/eLife.65088
- 33 Team R. R: A language and environment for statistical computing. MSOR Connect. Published online 2014.
- 34 McMurdie PJ, Holmes S. phyloseq: An R Package for Reproducible Interactive Analysis and Graphics of Microbiome Census Data. *PLoS One.* 2013;8(4):e61217. https://doi.org/10.1371/journal.pone.0061217
- 35 Kassambara A. Package 'ggpubr'. Published online 2023. https://cran.r-project.org/web/packages/ggpubr/index.html
- 36 Lahti L, Shetty S. Microbiome R package. Published 2017. http://microbiome.github.io
- 37 Wickham H. Ggplot2: elegant graphics for data analysis. Accessed January 16, 2023. https://books.google.com/books/about/ggplot2.html?hl=nl&id=XgFkDAAAQBAJ
- 38 Stagaman K. phyloseqCompanion: Provides additional functions to work with phyloseq objects. R package version 1.1. phyloseqCompanion: Provides additional functions to work with phyloseq objects. R package version 1.1. Published 2023. https://rdrr.io/github/kstagaman/phyloseqCompanion/
- 39 Segata N, Izard J, Waldron L, et al. Metagenomic biomarker discovery and explanation. *Genome Biol.* 2011;12(6):R60. doi:10.1186/gb-2011-12-6-r60
- 40 Oksanen J, Simpson GL, Blanchet FG, et al. Vegan Community Ecology Package. *Vegan Community Ecol Packag.* Published online 2022.
- 41 Brunson JC. [ggalluvial]: Layered Grammar for Alluvial Plots. *J Open Source Softw.* 2020;5(49):2017. doi:10.21105/joss.02017
- 42 Wright ML, Podnar J, Longoria KD, et al. Comparison of commercial DNA extraction kits for whole metagenome sequencing of human oral, vaginal, and rectal microbiome samples. *bioRxiv Prepr Serv Biol.* Published online February 2023. doi:10.1101/2023.02.01.526597
- 43 Chattopadhyay S, Arnold JD, Malayil L, et al. Potential role of the skin and gut microbiota in premenarchal vulvar lichen sclerosus: A pilot case-control study. *PLoS One.* 2021;16(1):e0245243. doi:10.1371/journal.pone.0245243
- 44 Liu X, Zhuo Y, Zhou Y, Hu J, Wen H, Xiao C. Analysis of the Vulvar Skin Microbiota in Asymptomatic Women and Patients With Vulvar Lichen Sclerosus Based on 16S rRNA Sequencing. *Front cell Dev Biol.* 2022;10:842031. doi:10.3389/fcell.2022.842031
- 45 Van Der Avoort IAM, Shirango H, Hoevenaars BM, et al. Vulvar squamous cell carcinoma is a multifactorial disease following two separate and independent pathways. *Int J Gynecol Pathol.* 2006;25(1):22-29. doi:10.1097/01.pgp.0000177646.38266.6a
- 46 Hald AK, Blaakaer J. The possible role of human papillomavirus infection in the development of lichen sclerosus. *Int J Dermatol.* 2018;57(2):139-146. doi:10.1111/ijd.13697
- 47 Aidé S, Lattario FR, Almeida G, Do Val IC, Da Costa Carvalho M. Epstein-barr virus and human papillomavirus infection in vulvar lichen sclerosus. *J Low Genit Tract Dis.* 2010;14(4):319-322. doi:10.1097/LGT.0b013e3181d734f1
- 48 Kombe Kombe AJ, Li B, Zahid A, et al. Epidemiology and Burden of Human Papillomavirus and Related Diseases, Molecular Pathogenesis, and Vaccine Evaluation. *Front Public Heal.* 2020;8:552028. doi:10.3389/fpubh.2020.552028
- 49 Tasker GL, Wojnarowska F. Lichen sclerosus. *J Dermatol Nurses Assoc.* 2013;5(4):213-216. doi:10.1097/JDN.0b013e31829cde87
- 50 So KA, Yang EJ, Kim NR, et al. Changes of vaginal microbiota during cervical carcinogenesis in women with human papillomavirus infection. *PLoS One.* 2020;15(9):e0238705. https://doi.org/10.1371/journal.pone.0238705
- 51 Ritu W, Enqi W, Zheng S, Wang J, Ling Y, Wang Y. Evaluation of the associations between cervical microbiota and HPV infection, clearance, and persistence in cytologically normal women. *Cancer Prev Res.* 2019;12(1):43-56. doi:10.1158/1940-6207.CAPR-18-0233
- 52 Wu S, Ding X, Kong Y, et al. The feature of cervical microbiota associated with the progression of cervical cancer among reproductive females. *Gynecol Oncol.* 2021;163(2):348-357. doi:10.1016/j.ygyno.2021.08.016
- 53 Park SB, Im M, Lee Y, et al. Effect of emollients containing vegetable-derived lactobacillus in the treatment of atopic dermatitis symptoms: split-body clinical trial. *Ann Dermatol.* 2014;26(2):150-155. doi:10.5021/ad.2014.26.2.150
- 54 Li Z, Koban KC, Schenck TL, Giunta RE, Li Q, Sun Y. Artificial Intelligence in Dermatology Image Analysis: Current Developments and Future Trends. *J Clin Med.* 2022;11(22). doi:10.3390/jcm11226826
- 55 Kim J-H, Son S-M, Park H, et al. Taxonomic profiling of skin microbiome and correlation with clinical skin parameters in healthy Koreans. *Sci Rep.* 2021;11(1):16269. doi:10.1038/s41598-021-95734-9
- 56 Management of symptomatic vulvovaginal atrophy: 2013 position statement of The North American Menopause Society. *Menopause.* 2013;20(9):884-888. doi:10.1097/GME.0b013e3182a122c2.10.1097/GME.0b013e3182a122c2.
- 57 Alexander H, Brown S, Danby S, Flohr C. Research Techniques Made Simple: Transepidermal Water Loss Measurement as a Research Tool. *J Invest Dermatol.* 2018;138(11):2295-2300.e1. doi:10.1016/j.jid.2018.09.001
- 58 Akdeniz M, Gabriel S, Lichtenfeld-Kottner A, Blume-Peytavi U, Kottner J. Transepidermal water loss in healthy adults: a systematic review and meta-analysis update. *Br J Dermatol.* 2018;179(5):1049-1055. doi:10.1111/BJD.17025
- 59 Wirth J, Young M. The intriguing world of archaeal viruses. *PLoS Pathog.* 2020;16(8):e1008574. doi:10.1371/JOURNAL.PPAT.1008574
- 60 Aminov RI. Role of archaea in human disease. *Front Cell Infect Microbiol.* 2013;3:42. doi:10.3389/fcimb.2013.00042
- 61 Bruning E, Chen Y, McCue KA, Rubino JR, Wilkinson JE, Brown ADG. A 28 Day Clinical Assessment of a Lactic Acid-containing Antimicrobial Intimate Gel Wash Formulation on Skin Tolerance and Impact on the Vulvar Microbiome. *Antibiot (Basel, Switzerland).* 2020;9(2). doi:10.3390/antibiotics9020055
- 62 Bradford LL, Ravel J. The vaginal mycobiome: A contemporary perspective on fungi in women's health and diseases. *Virulence.* 2017;8(3):342-351. doi:10.1080/21505594.2016.1237332
- 63 Gajer P, Brotman RM, Bai G, et al. Temporal dynamics of the human vaginal microbiota. *Sci Transl Med.* 2012;4(132):132ra52-132ra52. doi:10.1126/scitranslmed.3003605
- 64 Hickey RJ, Zhou X, Settles ML, et al. Vaginal microbiota of adolescent girls prior to the onset of menarche resemble those of reproductive-age women. *MBio.* 2015;6(2). doi:10.1128/mBio.00097-15

- 65 Shiraishi T, Fukuda K, Morotomi N, et al. Influence of menstruation on the microbiota of healthy women's labia minora as analyzed using a 16S rRNA gene-based clone library method. *Jpn J Infect Dis.* 2011;64(1):76-80.
- 66 Krog MC, Hugerth LW, Fransson E, et al. The healthy female microbiome across body sites: effect of hormonal contraceptives and the menstrual cycle. *Hum Reprod.* 2022;37(7):1525-1543. doi:10.1093/humrep/deac094
- 67 Song SD, Acharya KD, Zhu JE, et al. Daily Vaginal Microbiota Fluctuations Associated with Natural Hormonal Cycle, Contraceptives, Diet, and Exercise. *mSphere.* 2020;5(4). doi:10.1128/msphere.00593-20
- 68 Gupta S, Kakkar V, Bhushan I. Crosstalk between Vaginal Microbiome and Female Health: A review. *Microb Pathog.* 2019;136:103696. doi:10.1016/j.micpath.2019.103696
- 69 Ravel J, Gajer P, Abdo Z, et al. Vaginal microbiome of reproductive-age women. *Proc Natl Acad Sci U S A.* 2011;108 Suppl(Suppl 1):4680-4687. doi:10.1073/pnas.100261107
- 70 Characterizing the Microbiome in Postmenopausal Women With Vulvar Lichen Sclerosus - Full Text View - ClinicalTrials.gov. Accessed January 11, 2023. <https://clinicaltrials.gov/ct2/show/NCT05147129?cond=lichen+sclerosus&draw=2&rank=10>
- 71 Genital Lichen Sclerosus - Epidemiology, Comorbidities and the Role of Vulvar and Penile Microbiome - Full Text View - ClinicalTrials.gov. Accessed January 14, 2023. <https://clinicaltrials.gov/ct2/show/NCT05671263?cond=lichen+sclerosus&draw=2&rank=2>
- 72 Gynecologic Extramammary Paget's Disease - Full Text View - ClinicalTrials.gov. Accessed January 18, 2023. <https://clinicaltrials.gov/ct2/show/NCT03564483?term=microbiome&cond=vulva&draw=2&rank=3>
- 73 Clinical and Molecular Correlates of Response to First Line Treatment in Lichen Planus - Full Text View - ClinicalTrials.gov. Accessed January 18, 2023. <https://clinicaltrials.gov/ct2/show/NCT05330572?term=microbiome&cond=vulva&draw=2&rank=2>
- 74 Rustetska N, Szczepaniak M, Goryca K, Zalewska EB, Figat M. The intratumour microbiota and neutrophilic inflammation in squamous cell vulvar carcinoma microenvironment. *J Transl Med.* Published online 2023;1-11. doi:10.1186/s12967-023-04113-7
- 75 Yoshikata R, Yamaguchi M, Mase Y, Tatsuyuki A, Myint KZY, Ohta H. Evaluation of the efficacy of Lactobacillus-containing feminine hygiene products on vaginal microbiome and genitourinary symptoms in pre- and postmenopausal women: A pilot randomized controlled trial. *PLoS One.* 2022;17(12):e0270242. doi:10.1371/journal.pone.0270242
- 76 Armstrong E, Kaul R, Cohen CR. Optimizing the vaginal microbiome as a potential strategy to reduce heterosexual HIV transmission. *J Intern Med.* Published online December 2022. doi:10.1111/joim.13600
- 77 Falagas ME, Betsi GI, Athanasiou S. Probiotics for the treatment of women with bacterial vaginosis. *Clin Microbiol Infect Off Publ Eur Soc Clin Microbiol Infect Dis.* 2007;13(7):657-664. doi:10.1111/j.1469-0691.2007.01688.x
- 78 A Study to Evaluate the Efficacy and Safety of Ruxolitinib Cream in Participants With Lichen Sclerosus - Full Text View - ClinicalTrials.gov. Accessed January 3, 2023. <https://clinicaltrials.gov/ct2/show/NCT05593445?cond=Lichen+Sclerosus&draw=2&rank=4>
- 79 Rissmann R, Moerland M, van Doorn MBA. Blueprint for mechanistic, data-rich early phase clinical pharmacology studies in dermatology. *Br J Clin Pharmacol.* Published online 2020. doi:10.1111/bcp.14293
- 80 Papp K, Szepletowski JC, Kircik L, et al. Long-Term Safety and Disease Control With Ruxolitinib Cream in Atopic Dermatitis: Results From Two Phase 3 Studies. *J Am Acad Dermatol.* Published online November 2022. doi:10.1016/j.jaad.2022.09.060

## CHAPTER 8

# Summary and Discussion



The scope of this thesis was to identify objective, non-invasive biomarkers for vulvar premalignant disease. The aetiology of vulvar diseases, including LS, vulvar HSIL, dVIN and vSCC is poorly understood. Clinically, these diseases can be challenging to monitor and therapeutic management options are limited. The envisaged application of improving non-invasive biomarkers is therefore threefold: 1) enhanced recognition of the underlying cause 2) augmenting clinical detection and 3) contributing to the investigation of potential new drug targets for vulvar premalignant diseases. Early phase clinical trials should include assessments that can show pharmacodynamic effects ideally leading to proof-of-mechanism and/or proof-of-concept.<sup>1</sup> For the vulvar diseases, the outcome measures currently utilized to evaluate efficacy are non-sensitive, non-objective and inadequate, mostly relying on non-standardized clinician-based scoring alone.<sup>2</sup> The drivers of pathogenesis or disease progression are not fully understood. Disease mechanisms need to be clarified and biomarkers need to be discovered that can indicate changes in disease states. Then, novel drug compounds can be developed specifically targeting a disease process and tested appropriately.

It is imperative to apply a structured methodology for the recognition of applicable and valid biomarkers per disease entity. This was incorporated in this thesis using a model across a variety of domains.<sup>3</sup> This thesis has extensively focused on two of the domains from this approach. In the first section, novel imaging techniques for disease characterisation were described for feasibility and applicability in vulvar diseases and HPV-related cutaneous disease. In the second part, the vulvar microbiome composition is explored in relation to health and disease. The other domains of the comprehensive model were also addressed as auxiliary biomarkers during the studies described in this thesis, including clinical assessments, patient reporting, histological references, immunohistochemistry and HPV-typing.

This final chapter provides a summary and discussion of the results presented in this thesis. This chapter addresses the potential steps to expand and integrate this knowledge for future studies to improved understanding of vulvar diseases. In addition, this chapter is a call for other research groups to optimise biomarkers for vulvar diseases.

## SECTION I: CHARACTERISING VULVAR AND HPV-DRIVEN DISEASE WITH NOVEL IMAGING TECHNIQUES

As a health care provider with a vulvar clinic, it can be challenging to keep up with the rapidly changing technological field of medical imaging. Every new

technique brings financial investments and time-consuming efforts for acquisition, training and maintenance. Choosing which imaging applications are relevant for integration into patient care requires translational collaboration by researchers, clinicians and industry. In skin research and the dermatological practice, traditional digital cameras are gradually being replaced by more advanced technologies. These may, in addition to lesion capture, include incorporated algorithms for disease recognition, lesion size determination or blood flow measurements.<sup>4,5</sup> These enhanced systems include, but are not limited to, stereophotogrammetric 3D photography, dermatoscopy, optical coherence tomography (OCT) and reflectance confocal microscopy (RCM). None of these techniques are routinely applied in the vulvar clinic, and even their application in vulvar research is sparse and without consensus on scoring systems to describe observations. Technical application and clinical exploration of these highlighted imaging techniques have been described in this thesis.

Performing clinical trials requires accurate measurement tools and it is imperative that reduction of lesion count and size is carefully monitored during the trials to obtain an accurate reflection of efficacy parameters. Especially for vulvar HSIL, which is often irregularly shaped, lesion size is challenging to determine. In **chapter 2**, stereophotogrammetric 3D photography was validated as a method for the determination of lesion size of vulvar HSIL, anogenital and cutaneous warts. 3D photography was considered precise and accurate during technical validation with good to excellent agreement between operators and raters. Clinical validation was achieved by comparing 3D photography to caliper measurements, which was used as the clinical golden standard for lesion size determination. Agreement between methods was good to excellent for the determination of lesion diameter of all three lesion types. However, the height of cutaneous warts could not accurately be determined. 3D photography is also applicable for the determination of surface area and volume of lesions. To conclude, stereophotogrammetric 3D imaging was found to be an accurate and reliable method for the clinical visualization and quantification of HPV-induced skin lesions. This technique can consequently be applied to explore the efficacy of novel therapeutics, especially in the early clinical phase.<sup>6</sup>

Next, an extensive prospective observational clinical feasibility trial was performed to characterize novel, non-invasive methods for the recognition of vulvar HSIL and LS and to compare these outcomes to histology. The aim was to describe the practical applicability of these new techniques, also considering physician-oriented handling and patient tolerability. In

addition, characteristics and features of vulvar HSIL and LS were compared to healthy vulvar skin. In total, 25 women were included in this study, of which 10 healthy controls, 5 patients with vulvar HSIL and 10 patients with lichen sclerosus. The results of the studied non-invasive imaging modalities, dermatoscopy, D-OCT and RCM, were described in **chapter 3** and **chapter 4**, respectively.

Dermatoscopic characteristics were identified in vulvar HSIL and LS that may differentiate these conditions from healthy vulvar skin, but none of these features were specific for a particular disease in our study population. This technique could be applied to aid identification of vulvar lesions, or recognition of the most suspicious part of a lesion to guide biopsy or excision. Assembly of reference images of all diseases found on vulvar tissue and identification of a distinct set of features for each disease entity is required, however, before this technique can routinely be applied in the vulvar clinic. Recently, several research groups have described collections of dermatoscopic references for genital disease, but vulvar specialists are yet to adopt the technique in practice.<sup>7-9</sup> The study performed in this thesis only serves as a pilot with a focus on precursors of vSCL, but expansion of the study population in numbers and diversity is essential for training and reference. Changes over time, including (side-)effects of topical treatment, scarring from surgery and disease progression, ought to be recognized and documented. For instance, discrepant observations have been described for the dermatoscopic vessel structure in LS, prompting discussion in literature on the distinct dermatoscopic presentation based on disease activity or state.<sup>10</sup> Dermatoscopic and histological references have generally described a reduction, or *desertification*, in vessel concentration and intensity in LS.<sup>9</sup> In contrast, presence of thick, arborizing vessels against a white or pink background was a feature almost exclusively observed in a subset of the LS population studied in this thesis. Our vascular finding reflects the gap in our knowledge about the diverse presentation of LS and underlines the importance of creating a reference catalogue. These limitations notwithstanding, dermatoscopy is a technique that could easily be incorporated into the vulvar clinic. Dermatoscopy already is a fundamental part of the modern dermatology practice, therefore acquisition of the technology and training of specialized personnel in the vulvar clinic should be straightforward. Yet, further validation and operator training specifically for the vulvar field will be imperative for successful integration of this technique.

D-OCT uses laser-light to generate images of sub-surface structures of a biological tissue, such as the retina or the skin. The scattering pattern translates into a graphical representation of the imaged tissue and displays dynamic features of the skin. Integrated algorithms can determine epidermal thickness, skin roughness and blood flow. Morphologically, major histological structures up to 1-2 mm depth can be recognized in a non-invasive manner using D-OCT, although the resolution of the technology is insufficient for the identification of individual cellular changes. Epidermal thickness of normal, non-genital skin can be determined using algorithms, although our study found that these automatic measurements are unsuitable for the irregular and hirsute vulvar skin.<sup>11</sup> Manual measurements did identify a thinner epidermis in LS patients (both of lesional and seemingly non-lesional skin) compared to healthy volunteers. On histology, LS presents with thinning of the epidermis, and vulvar HSIL with acanthosis. Practically, there is no clinical application for using epidermal thickness as a proxy for the diagnostics of vulvar diseases. Additionally, manual measurements would be too time-consuming to be considered applicable for the clinical setting. Hence, epidermal thickness determination using D-OCT is considered suitable for research rather than clinical practice. Blood flow, as ascertained by D-OCT, was increased in the lesional vulvar skin of LS patients, which reflects the newly identified arborizing vasculature on dermatoscopy. Furthermore, seemingly non-lesional vulvar skin of vulvar HSIL displayed a higher blood flow than healthy controls or lesional vulvar HSIL skin. However, the irregular, warty shape of vulvar HSIL and the modest sample size in this study should be considered in the interpretation of these findings. The data from blood flow and epidermal thickness measurements in this study also reflect that vulvar skin adjacent to visible diseased skin should not automatically be regarded as healthy vulvar skin, as changes compared to healthy controls were found. Bordering, seemingly non-lesional skin may have undergone changes due to previous treatments or changes in the immune and vascular microenvironment due to the adjacent disease process. Within-patient controls are thus intrinsically invalid, and the inclusion of a healthy, ideally age-matched, control population, is essential in similar investigations and follow-up studies.

RCM is an imaging technique can generate real time, non-invasive, transversal images of the skin at a cellular resolution to a depth of 250 µm. RCM provides horizontal images of the scanned surface, starting at the epidermis through to the dermis, in contrast to the familiar transversal slides in

histology. While D-OCT and dermatoscopy are incorporated clinical tools in ophthalmology and dermatology, respectively, the application of RCM is mostly applied in research settings. Most dermatological studies using RCM have focused on the investigation of pigmented lesions to aid identification of melanoma.<sup>12-14</sup> RCM imaging of the vulvar area had only been described in a handful of case reports. No studies had previously focused on practical steps of obtaining and analysing vulvar RCM images, nor the patient acceptability of this technique. Our study provided a practical application framework and identified several cellular features identified in a non-invasive manner that are known from histological literature on LS and vulvar HSIL. Dermal sclerosis and hyalinized vessels on RCM, as observed in LS, may in time prove pathognomonic for the disease, as both features were almost exclusively identified in LS in a clear pattern. However, a follow-up study including the whole spectrum of vulvar diseases and all stages of LS should confirm or repudiate this hypothesis. Downsides of RCM that could hinder integration into the clinic is the time-consuming nature of the procedure, extensive operator training and the steep expenses of acquisition and maintenance of the equipment. Individual cells can be recognised and discriminated, but nuclear changes cannot be discerned using RCM. Neither does this imaging technique replace routine diagnostic staining procedures, e.g. for P16 or P53. Especially for vulvar HSIL, nuclear clumping, mitotic figure patterns and strong P16 positivity are pathological hallmarks of disease.<sup>15</sup> It is therefore unlikely that biopsies for histological confirmation of premalignant diagnosis will be replaced by introducing RCM imaging. In the future, if RCM is adopted as tool by vulvar specialists, it could potentially be utilised to guide differential diagnosis and recognise the most suspicious lesion area for biopsy.

Due to the paucity of patients with vulvar HSIL and taboo surrounding genital disease, recruitment of these patient groups into clinical trials is often challenging. More common HPV-driven diseases such as plantar and cutaneous warts are caused by different phylotypes. These disease entities can supply a pool of potential patients in which HPV-targeting therapies can be studied, while remembering that grouping of these diseases may overlook pertinent clinical dissimilarities. In addition, novel imaging tools described in the first chapters of this thesis can also be applied in broader dermatology research. In **chapter 5**, 3D photography and D-OCT were applied as a research tool to monitor efficacy during a first-on-human, double-blind, randomized, placebo-controlled clinical trial. In this study, a novel synthetic peptide with

anti-neoplastic activity, CY-002 with anti-neoplastic activity, was tested in 63 patients with cutaneous warts with low-risk HPV types. The primary objective of this study was to assess safety and tolerability of topical CY-002 on the skin. Exploratory analysis of potential clinical effect on the cutaneous warts was performed by wart count, imaging (3D photography and D-OCT), viral HPV load measurements, biopsy analysis and morphological assessment.<sup>16</sup> In this study, we found that CY-002 was safe and tolerable for daily topical use under occlusion for up to 4 weeks. No statistically significant effects were observed comparing efficacy outcomes of CY-002 to placebo, possibly due to relatively high placebo responses. Preclinically, CY-002 had selectively targeted tumour cell lines whilst sparing normal cells. The discrepancy of the cell membrane charge is thought to be the key to the working mechanism of CY-002. Issues with permeation of the callous wart structure could explain the lack of observed effects. Studying topical therapies is always limited by uncertainty whether the medication has reached its intended intradermal target. Intralesional therapy or abrasion of the lesions can circumvent these issues but are considered painful by patients.

### *Considerations and future applications*

Making a clinical diagnosis and following up treatment effect can be subjective and challenging, especially for diseases such as vulvar HSIL and dVIN. It is fundamental to make early and accurate diagnoses to reduce associated morbidity and guide fitting treatment. Going forward, the clinical field should consider incorporating the technological advancements to aid their clinical decision making. However, medical imaging is a rapidly developing field; today's studies are virtually outdated tomorrow. In the few years since the setup of the studies described in this section, technical advancements now allow for even higher resolution and improved orientation of the visualised tissue.<sup>17</sup> Choosing the correct appliances for clinical application requires prior validation and integration in clinical studies (*Table 1*). Visualisation of the superficial layer of the vulva can currently be achieved by using the naked eye, conventional photography, colposcopy, or, as recommended in this thesis, dermatoscopy. Colposcopy and dermatoscopy observations should be compared for accuracy and practicality in a future clinical study, as both techniques rely on magnification of the cutaneous surface.<sup>18</sup> Dermatoscopy is currently considered the most applicable the evaluation of vulvar disease out the techniques studied in this thesis, despite the need for robust

scoring systems and a collection of reference images. Adopting dermatology would be especially feasible for in the vulvar clinics affiliated with dermatological practices, which will probably have the systems readily available. This is not the case for D-OCT, stereophotogrammetry or RCM systems, which are more cumbersome for image capture and subsequent analysis and interpretation. RCM probably is the most promising novel technique to follow in the upcoming years, because of the non-invasive nature combined with real-time cellular-resolution image capture down to the dermis. Further improvements of the image resolution and building of a reference log of all vulvar diseases may in the future lead to application of this non-invasive technique in the outpatient clinic or operation rooms.

Two highlighted technical advancements that are expected to have a substantial impact in the future are line field confocal optical coherence tomography (LC-OCT) and artificial intelligence (AI). LC-OCT is a new imaging system that combines the cross-sectional view and blood flow measurements of OCT with the cellular resolution of RCM.<sup>19</sup> LC-OCT has improved resolution at depth and the system allows for further automated analyses, including cell type count and recognition, using automated analysis software. Recent pilot studies in dermatology have used LC-OCT for the characterisation of melanocytic lesions and basal and squamous cell carcinoma.<sup>20-23</sup> This new technique has not previously been used on the vulvar area, but may have the potential to overcome several of the limitations identified for D-OCT and RCM imaging. Technological advancements has also made way for development and integration of deep-learning-based algorithms for image analysis in the medical field.<sup>24</sup> Dermatology is especially suitable for incorporation of AI-aided pattern recognition to support clinical diagnosis. This also applies to the pathological examination of biopsy tissue.<sup>25</sup> The expectation is that AI will be incorporated into dermatological image analysis to improve objective and accurate scoring and diagnosis in the near future.<sup>26</sup>

## SECTION II: THE VULVAR MICROBIOME

Investigations pertaining to the microbiome composition, the collective of all microbial taxa and their genes within a community, are subject to significant attention of researchers and industry alike.<sup>27-29</sup> The crosstalk observed between the human body and 'our second genome' can explain a great deal of diversity in our population.<sup>30</sup> The microbiome constitutes essential components of the digestive system and has direct effects on drug metabolism

and interactions. In addition, the immune system is shaped by our co-existing micro-organisms, forming a barrier against pathogens and directly influencing immune reactions.<sup>31</sup> Perturbations of the microbiome have been described in a wide variety of disciplines, including gastroenterology, gynaecology, neurology and psychiatry, endeavouring to describe a causative role in diseases ranging from bacterial vaginosis to depression.<sup>32,33</sup> Many of these findings have proven robust over the years, but the research field should keep in mind that the microbiome is highly complex and the direction of causality of observed correlations should always be critically appraised. Upon the discovery of certain dysbiosis patterns in disease states, industry has responded with a panacea of pro- and pre-biotics with insistent claims loosely based on scientific consensus.<sup>34-36</sup> These formulations often contain a single modified strain or species. However, the microbiome composition as a balanced, holistic system seems forgotten. These potential shortfalls in the microbiome field are considerations that should be appraised critically, especially during the development of pharmaceutical products. In this thesis, we have attempted to remain prudent in the elucidation of the microbiome composition of the vulvar niche. Although the vaginal microbiome has been a focal subject in gynaecological microbiome research, little to no attention has been given to the vulva. This untapped field may clarify aetiological factors for LS or provide clues that can explain malignant disease progression of other vulvar premalignancies.

Firstly, the normal vulvar microbiome composition and the diversity within what is considered 'healthy' should be defined. Therefore, we performed a systematic review of the available literature in **chapter 6**. In this review, 10 studies were identified that describe the microbiome composition of 261 women. Most studies were performed in healthy, Caucasian or Asian women aged 18-55 years. Only two studies reported on the vulvar microbiome composition of premenarchal girls, one of which included 5 girls with LS. The main findings showed that the bacterial composition of the vulva contains a mix of commensals often associated with vaginal, intestinal and cutaneous niches, with a distinctly higher diversity on the vulva than the vagina. This supports the function of the vulva as transitional epithelium from the vaginal mucosa to the genital skin. Overall, the available data on the vulvar microbiome composition contains an underrepresentation of age categories, diverse ethnic groups and patients with vulvar disease. Discoveries in microbiome research are highly dependent on the applied sequencing and analysis

techniques. Therefore, we recommended metagenomic sequencing as preferred method for future studies to the vulvar microbiome composition. This technique can determine the complete genomic makeup in a sample, also supplying functional information of the gene pool in addition to identification of the present species.

The findings of the review also showed an absence of comprehensive, prospective studies in premalignant and malignant patient groups. The microbiome composition of vulvar HSIL and LS was compared to healthy volunteers in **chapter 7**. This study was performed as part of the multi-modal pilot study described in the first section of this thesis. Metagenomic sequencing was performed on vulvar, vaginal and anal swabs of 10 patients with LS, 5 patients with vulvar HSIL and 10 healthy controls. No significant differences were observed in diversity and richness between healthy and diseased vulvar skin. The labia minora of LS patients was mainly populated by bacteria of the *Lactobacillus*, *Prevotella* and *Gardnerella* genera. In vulvar HSIL, *Prevotella* and *Alphapapillomavirus* were the most described taxa. Healthy vulvar skin mainly comprised of *Prevotella* and *Lactobacillus*. Compared to the healthy vulvar skin, the vulvar microbiome composition of both LS and vulvar HSIL patients was characterized by significantly higher proportions of *Papillomaviridae*. In contrast, *Bacteroidia* and *Actinobacteria* were less abundant in respectively LS and vulvar HSIL compared to healthy vulvar skin. While bacteria and viruses were most abundant, fungal and archaeal taxa were scarcely observed. Trans-epidermal water loss, a biomarker for the barrier function of the skin, was increased in affected skin compared to healthy vulvar skin. This could be due to a disruption in barrier function from disease processes or locational differences in vulvar skin composition (mucosal vs. hirsute). Alternatively in LS, increased skin permeability may enable HPV infection of affected vulvar skin. This study was the first to describe the vulvar microbiome composition in LS and vulvar HSIL using sequencing-based methods on the vulva compared to healthy controls. It should be noted that this study remains a cross-sectional pilot with low numbers of participants, with a predominantly Caucasian population. Therefore, the observations from this study require validation in an expanded and more diverse group, also including women with dVIN and vSCC to capture the complete disease range from healthy vulvar skin to cancer. This study provides new clues to the aetiology of LS and a steppingstone for expansion of knowledge on potential drivers of vulvar premalignant disease.

## Considerations and future applications

The current findings of the vulvar microbiome composition reflect its transitional anatomical location, with identified commensals associated with vaginal, cutaneous and intestinal milieus. Extra layers of complexity can be expected from demographics including age and ethnicity, in addition to biological processes as menstruation and lifestyle factors such as hygiene practices, sexual activities and contraceptive use. Although the vulvar microbiome research field is of modest size, one recently published study was appraised the microbiome composition in adult women with LS, identifying a reduction of *Lactobacillus* genera and a higher proportion of *Prevotella spp.* in patients.<sup>38</sup> In addition, two new studies have recently been initiated focusing on the vulvar microbiome composition in adult women with LS (NCT05671263, NCT05147129).<sup>39,40</sup> Urology research in male LS may also be informative for translation understanding the interactions of the microbiome and vulvar disease, although the hypothesised aetiology of LS in males is centred around chronic irritation due to micro-incontinence.<sup>41,42</sup> For vulvar HSIL, no recent or ongoing microbiome studies were identified. Still, the described relationships between the microbiome and cervical dysplasia poses potential for guiding hypotheses in the vulvar field. Interactions between the microbiome and existing and novel treatments can be appraised after the microbiome signature of vulvar diseases has been clarified further. Remarkably, there is no understanding of the effect of topical corticosteroids on the microbiome composition of the skin, although this is the golden standard for treatment of a multitude of dermatological diseases. The description of the microbiome composition in vulvar diseases is still in its infancy. The vulvar location is still a minute niche within microbiome research. Extensive efforts are yet needed to fully understand the exact relationships between the microbiome and vulvar health and disease (*Table 2*).

## Perspectives

### DEVELOPMENT PIPELINES AND FUTURE THERAPEUTIC OPTIONS FOR VULVAR (PRE)MALIGNANT DISEASE

A joint feature of the diseases described in this thesis is the paucity of disease-specific, patient-friendly and effective therapeutic options. However, the development pipeline of novel treatments for vSCC and its precursors appears depleted compared to other, more prevalent, (pre)malignant diseases. This

situation can partially be attributed to the persisting social taboo on vulvar disease and numerous other factors common to ‘orphan’ diseases. These include difficulty of recruiting patients for research, lack of industry incentive to develop therapies for small markets, shortfalls of clinical detection techniques and, as a consequence, the absence of effective screening approaches.<sup>54</sup> Both for vulvar HSIL and LS, there is gap in our knowledge on the cause of disease origins and drivers of malignant development. Unlike for LS, we have recognised the causative agent of vulvar HSIL: persistent high-risk HPV infections. Yet, exactly which factors contribute to disease progression from vulvar HSIL to HPV-positive vSCC, and of LS into dVIN and HPV-negative vSCC remains largely unknown.<sup>55</sup> The survival rate for vSCC has been stagnant over the past decades, with some recent reports are even suggesting a decrease in survival numbers and rise in vSCC incidence rates, possibly stemming from increased incidence of precursor lesions.<sup>54,56-58</sup>

### *Lichen sclerosus*

Ongoing clinical trials to LS are sparse, with a few noteworthy observational studies on histological biomarkers (NCT03561428) and the microbiome composition (NCT05671263, NCT05147129).<sup>39,40,59</sup> The majority of current interventional trials investigate the application of several types of ablative lasers on LS (e.g. NCT05010421).<sup>60</sup> However, laser treatment for LS is currently advised against by international guidelines due to low-quality evidence and lack of long-term follow up.<sup>61,62</sup> In 2022, a clinical trial was initiated with topical ruxolitinib (brand name Opzelura) in vulvar LS patients (NCT0593445).<sup>63</sup> Ruxolitinib is a small molecule Janus kinase (JAK) type 1-2 inhibitor that has been on the market as oral immune modulator for the past two decades. It was approved in topical formulation by the FDA for the treatment of vitiligo in 2022.<sup>64,65</sup> The inhibition of the JAK/STAT signalling pathway leads to prevention of cytotoxic T-cell recruitment through reducing IFN- $\gamma$  and downstream chemokine ligand 9 and 10 (CXCL9/CXCL10) signalling. In vitiligo, cytotoxic T-cell mediated inflammatory damage to melanocytes is an established cause of the condition.<sup>66,67</sup> For LS, however, the aetiology of disease remains unknown. Inhibition of the JAK/STAT pathway may well reduce cytotoxic T-cell driven inflammation in diseased LS skin, but a mechanistic rationale to target this mechanism specifically in LS seems lacking from a pharmacological standpoint.

A major shortfall in several recent and ongoing clinical trials to LS is the requirement of ‘histologically proven LS’ as an inclusion criterium.<sup>68</sup> In a recently published study with primarily non-invasive outcome measures, 63% (65/102) of potential patients were excluded based to a lack of diagnosis confirmation by pathology.<sup>69</sup> We emphasize that LS is primarily a clinical diagnosis. According to national and international clinical guidelines, LS is a diagnosis made on clinical examination and patient history. Clinical invasive biopsy procedures must be limited to one of the following three conditions: 1) diagnostic uncertainty, 2) suspicion for malignancy or 3) unsatisfactory treatment results.<sup>70</sup> LS can present heterogenic on histology, prompting uncertainties from a pathological point of view.<sup>71,72</sup> Disease duration, disease activity, cutaneous thinning from corticosteroid use, scarring and previous surgical interventions can influence the histological presentation. The clinical diagnosis must take precedent in case of ambiguous findings from pathology.<sup>73</sup> Obtaining histological ‘proof’ of a LS diagnosis should be considered a disservice to the patient, in the absence of the aforementioned conditions on the contrary. If clinical studies primarily focus on non-invasive assessments for clinical follow up, it is misguided to adopt ‘histologically proven LS’ as inclusion criterium. Primarily, the study results will only apply for a subset of LS phenotypes. Secondly, these study protocols should be flagged by medical ethical committees, as the LS patients are exposed to unnecessary invasive procedures. On a more practical note, otherwise eligible patients are excluded from study participation, impacting financial resources and logistical study timelines. Thus, collecting biopsies in a LS population should be limited to clinical studies with objectives that require tissue analysis, including histology, immunohistochemistry and gene expression analyses.

### *Vulvar HSIL*

The efficacy evaluation of existing and experimental treatments for vulvar HSIL and dVIN mainly depends on non-standardized clinician-based scoring and rarely ( $\pm 1/3$  of studies) on patient-reported symptoms.<sup>2</sup> Objective and sensitive efficacy core outcome measures are required, but identifying and selecting reliable and reproducible biomarkers for vulvar (pre)malignant diseases remains challenging. Different vulvar disease subtypes can have varying therapeutic responses. For instance, subcategories of vSCC can be stratified by immunohistochemical P16 and P53 mutant or wildtype

signatures.<sup>74</sup> These molecular vsCC subtypes have distinct overall survival, relative survival and recurrence-free period rates. Additionally, the response rates to immunotherapy (e.g. therapeutic HPV vaccination) in vulvar HSIL are correlated to specific pre-existent inflammatory microenvironments.<sup>75</sup> These findings exemplify that there are distinctive potential biological targets for treatment of vulvar (pre)malignant disease, which require specific efficacy evaluations. These findings underline the importance of venturing beyond clinician and patient-reporting alone in the appraisal of vulvar disease, potentially including imaging, molecular, biophysical and sequencing techniques, as discussed in this thesis.

Imiquimod was approved for the treatment of external genital warts in 1997 by the FDA and has since been recognized as effective first-line topical treatment option for vulvar HSIL.<sup>76,77</sup> Therapeutic HPV-vaccination has been identified as effective treatment for vulvar and vaginal HSIL, with approximately 50% efficacy.<sup>78,79</sup> This clinical response to HPV-vaccination relates to the strength of vaccine-induced HPV-16-specific T-cell immunity.<sup>80</sup> International preventive HPV-vaccination strategies are showing decreases in cervical dysplasia rates and other HPV-related disease incidence, which is also promising for the future of HPV-dependent SCC and its precursors.<sup>81,82</sup> In the meantime, few novel therapeutic options are being investigated specifically targeting vulvar HSIL. A proportion originates from re-purposing of antiviral or immunomodulatory drugs (NCT03792516).<sup>83-85</sup> Alternatively, experimental treatments for cervical dysplasia are occasionally also tested for efficacy in vulvar HSIL, conjecturing that the shared HPV-mediated aetiology could also yield comparable treatment responses.<sup>86,87</sup> This could lead to co-developed breakthroughs for the treatment of vulvar HSIL, as was the case with the HPV vaccine. However, this grouping of diseases may erroneously dismiss some clinically relevant differences (i.e. clinical presentation, embryonic nature of affected tissue, natural disease history, management and follow up) between cervical and vulvar dysplasia. These discrepancies between disease types should be considered in the appraisal of these traversing treatment strategies.<sup>88</sup>

#### CALL FOR MULTI-MODAL BIOMARKERS FOR INTEGRATION INTO FUTURE STUDIES TO VULVAR DISEASES

Novel therapeutic options should be developed based on expanded proficiency of biological and pharmacological processes. In depth understanding

of the processes that drive disease can be obtained using the multi-modal approach for dermatological disease characterisation introduced in the introduction of this thesis. Once more, these core domains are:

- 1 Clinician
- 2 Patient-reporting
- 3 Biophysical assessments
- 4 Analysis of invasive procedures such as biopsies, including histology and gene expression analyses
- 5 Microbiome research
- 6 Imaging

The latter two areas have extensively been discussed in this thesis. The remaining domains have also evolved regarding vulvar premalignant disease.

Clinician-based scoring is generally considered an objective outcome measurement for the appraisal of treatment effects. However, the definition of clinical response is heterogeneously applied. For LS, several clinical scoring systems have been suggested, but are not widely adopted in clinical practice.<sup>89,90</sup> These may report excellent intra- and inter-rater performance, but are not applicable or validated for the follow up of treatment effects. Classification of lesional dimensions according to the ‘response evaluation criteria in solid tumours’ (RECIST) guidelines into response categories can be used to follow disease regression or progression in vulvar HSIL.<sup>91,92</sup> This does require improvements in reliable lesion size measurement and accurate photo-documentation. The current clinical scoring algorithms alone are therefore not the optimal measurement tool to reliably evaluate the response to novel treatments. Current evidence for the treatment of the LS or vulvar HSIL is particularly lacking implementation of the traditionally considered ‘subjective’ patient-oriented outcome measures, including their symptoms, behaviours and experiences.<sup>2,93</sup> Arguably, the patient perspective should be an integral part of both clinical trials and clinical practice, considering the substantial morbidity associated with these vulvar diseases. Fortunately, an increasing amount of research and therapeutic efforts are focusing on the impact of LS on the quality of life, including sexual aspects (NCT03419377).<sup>68,94-96</sup> For vulvar HSIL, few quality of life instruments have been developed and validated specifically for this population, usually relying on adaptations of questionnaires developed for other diseases.<sup>97,98</sup> This patient-oriented domain is therefore a fundamental part of the multi-modal model proposed in this thesis that requires further expansion in future

research. Biophysical measurements have rarely been evaluated on the vulvar area, nor for the evaluation of therapeutic effect. The makeup of the healthy vulvar skin barrier function has previously been determined using the ceramide content in the epidermis after tape-stripping or determining the trans-epidermal water loss.<sup>45,99</sup> The state of the skin barrier function can relate to the permeability of topically applied drugs, influencing dermal pharmacokinetics. Similarly, the solubility of pharmaceutical compounds can depend on local pH. Neither of these biophysical properties have been described for LS or vulvar HSIL. Whereas this thesis has focused on non-invasive biomarkers for vulvar diseases, many lessons are yet to be learned from analyses of biopsy tissue. Improvements in the histological recognition dVIN are acutely needed to make robust diagnoses.<sup>100-102</sup> The pathological presentation LS is heterogeneous.<sup>71,72</sup> Several immunohistochemical biomarkers have been recognized to offset specific disease subtypes, but accurate disease recognition remains challenging.<sup>103</sup> Gene expression analyses may uncover leads to understand vulvar disease aetiology or drivers of malignant progression.<sup>104,105</sup> Considerable collaborative efforts are needed across research groups and clinical institutions to obtain sufficient patient material and supporting clinical data to detect meaningful results.

Each domain from this comprehensive approach has become a distinct specialty, with required proficiency in methodology, interpretation, analytics, and clinical integration. The integrated analysis of multi-omics will be the major challenge in the years to come (*Figure 1*).<sup>106</sup> Sequencing-based domains (e.g. microbiome composition analyses, genetic sequencing, transcriptomics and protein identification) yield highly complex data. Combining these datasets could delineate meaningful biological signatures of disease processes. However, that process will demand considerable computational power and comprehension of each separate method.<sup>107</sup> For the vulvar disease, these developments will hopefully lead to improved clinical outcomes through accelerated disease recognition and identification of new, disease-specific therapeutic targets.

**Table 1** Current advantages and disadvantages for each imaging system studied in this thesis for practical application in vulvar disease monitoring.

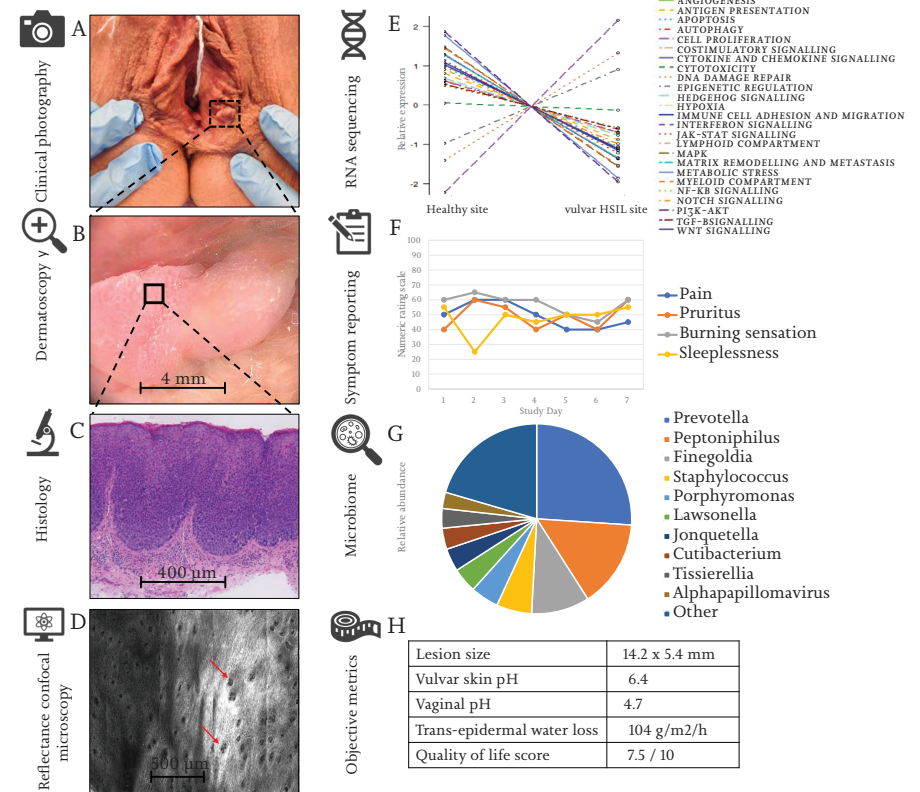
	3D	Dermatoscopy	D-OCT	RCM
Easy to use	Yes	Yes	No	No
Easy to analyse	No	Yes	No	No
Acquisition costs	Moderate	High*	High	High
Training of staff	Low	Moderate*	High	High
Resolution	Good	Good	Moderate	Excellent
Sub-surface visualisation	No	No	Yes	Yes
Patient burden**	Low	Low	Mild	Moderate
Correlation golden standard?	Yes	Yes	No	Yes
Clinical validation	No	No	No	No
Ready for clinical use?	No	No	No	No
Clinical integration?	No	Yes*	No	No

3D dynamic optical coherence tomography (D-OCT), reflectance confocal microscopy (RCM). / \*A dermatoscopy system is often already present in dermatology clinic, thus acquisition and training costs may be reduced in practice. / \*\* All techniques are non-invasive procedures, but the amount time of having to remain still for the duration of image acquisition of the vulvar area (30 seconds for D-OCT, 5-15 minutes for RCM) can be considered a burden to some patients.

**Table 2 Overview of all studies performed to the vulvar microbiome composition to date, illustrating factors and disease states that have previously been studied, but more importantly which numerous conditions that remains unknown, in addition to currently ongoing clinical trials.**

	Health	Disease
Previously studied (small studies)	<p>Specific vulvar locations</p> <ul style="list-style-type: none"> <li>• Labia majora<sup>43-46</sup>, this thesis</li> <li>• Labia minora<sup>43,46-50</sup>, this thesis</li> <li>• Vestibulum<sup>51,52</sup></li> </ul> <p>Cycle-related factors</p> <ul style="list-style-type: none"> <li>• Menarche<sup>49</sup></li> <li>• Menstruation<sup>48</sup></li> </ul> <p>Obesity<sup>46</sup></p>	<p>Lichen sclerosus</p> <ul style="list-style-type: none"> <li>• Pre-pubertal girls<sup>50</sup></li> <li>• Post-menopausal<sup>38</sup></li> <li>• Adult women<sup>this thesis</sup></li> </ul> <p>Vulvar HSIL<sup>this thesis</sup></p> <p>Provoked vestibulodynia<sup>52</sup></p> <p>Vulvar vestibulitis syndrome<sup>51</sup></p>
Not previously investigated (Incomplete overview)	<p>Demographic factors</p> <ul style="list-style-type: none"> <li>• Age (including menopause)</li> <li>• Ethnicity</li> </ul> <p>Lifestyle factors</p> <ul style="list-style-type: none"> <li>• Washing and bathing</li> <li>• Shaving habits</li> <li>• Toilet hygiene practices</li> <li>• Sexual practices</li> <li>• Underwear choice</li> <li>• Topical products</li> <li>• Contraceptives</li> </ul> <p>Within-subject location control</p> <p>Balance between niches</p> <ul style="list-style-type: none"> <li>• Vagina</li> <li>• Skin</li> <li>• Gut</li> </ul>	<p>Vulvar cancer</p> <ul style="list-style-type: none"> <li>• VSCC</li> <li>• Melanoma</li> <li>• Merkel cell</li> </ul> <p>Hidradenitis suppurativa</p> <p>Vulvar ulcerative disease</p> <p>Sexual transmitted disease</p> <ul style="list-style-type: none"> <li>• Condyloma acuminata</li> <li>• Syphilis</li> <li>• Herpes</li> </ul> <p>Medication use</p> <ul style="list-style-type: none"> <li>• Topical imiquimod</li> <li>• Topical corticosteroids</li> <li>• Oral or topical antibiotics</li> </ul>
Prospective studies	None	<p>Lichen sclerosus<sup>39,40</sup></p> <p>Lichen planus<sup>52</sup></p> <p>Vulvar Paget's disease<sup>53</sup></p>

**Figure 1 An example of integration of exploratory biomarkers. An example in one individual with vulvar HSIL.**



HSIL = high-grade squamous intraepithelial lesions. RNA = Ribonucleic acid

REFERENCES

- 1 Cohen AF, Burggraaf J, Van Gerven JMA, Moerland M, Groeneveld GJ. The use of biomarkers in human pharmacology (Phase I) studies. *Annu Rev Pharmacol Toxicol.* 2015;55:55-74. doi:10.1146/ANNUREV-PHARMTOX-011613-135918
- 2 Jamieson A, Tse SS, Proctor L, Sadownik LA. A Scoping Review of Treatment Outcome Measures for Vulvar Intraepithelial Neoplasia. *J Low Genit Tract Dis.* 2022;26(4):328-338. doi:10.1097/LGT.0000000000000698
- 3 Rissmann R, Moerland M, van Doorn MBA. Blueprint for mechanistic, data-rich early phase clinical pharmacology studies in dermatology. *Br J Clin Pharmacol.* Published online 2020. doi:10.1111/bcp.14293
- 4 Shahriari N, Grant-Kels JM, Rabinovitz H, Oliviero M, Scope A. Reflectance confocal microscopy: Principles, basic terminology, clinical indications, limitations, and practical considerations. *J Am Acad Dermatol.* 2021;84(1):1-14. doi:10.1016/j.jaad.2020.05.153
- 5 Wan B, Ganier C, Du-Harpur X, et al. Applications and future directions for optical coherence tomography in dermatology. *Br J Dermatol.* 2021;184(6):1014-1022. doi:10.1111/BJD.19553
- 6 Rijsbergen M, Niemeijer-van der Kolk T, Hogendoorn G, et al. A randomized controlled proof-of-concept trial of digoxin and furosemide in adults with cutaneous warts. *Br J Dermatol.* 2019;180(5):1058-1068. doi:10.1111/bjd.17583
- 7 Borghi A, Virgili A, Corazza M. Dermoscopy of Inflammatory Genital Diseases: Practical Insights. *Dermatol Clin.* 2018;36(4):451-461. doi:10.1016/j.det.2018.05.013
- 8 Maatouk I, Apalla Z, Errichetti E, Lallas A. Dermoscopy for urologists: an update on patterns of tumors, inflammatory and infectious diseases of the genitalia, and tips for differential diagnosis. *Int J Dermatol.* 2021;60(10):1211-1218. doi:10.1111/IJD.15333
- 9 Lacarrubba F, Borghi A, Verzi AE, Corazza M, Stinco G, Micali G. Dermoscopy of genital diseases: a review. *J Eur Acad Dermatol Venereol.* 2020;34(10):2198-2207. doi:10.1111/jdv.16723
- 10 Larre Borges A, Tiodorovic-Zivkovic D, Lallas A, et al. Clinical, dermoscopic and histopathologic features of genital and extragenital lichen sclerosus. *J Eur Acad Dermatol Venereol.* 2013;27(11):1433-1439. doi:10.1111/j.1468-3083.2012.04595.x
- 11 Katkar RA, Tadinada SA, Amaechi BT, Fried D. Optical Coherence Tomography. *Dent Clin North Am.* 2018;62(3):421-434. doi:10.1016/j.cden.2018.03.004
- 12 Braga JCT, Macedo MP, Pinto C, et al. Learning reflectance confocal microscopy of melanocytic skin lesions through histopathologic transversal sections. *PLoS One.* 2013;8(12). doi:10.1371/journal.pone.0081205
- 13 Dinnes J, Deeks JJ, Saleh D, et al. Reflectance confocal microscopy for diagnosing cutaneous melanoma in adults. *Cochrane database Syst Rev.* 2018;12(12):CD013190. doi:10.1002/14651858.CD013190
- 14 Lan J, Wen J, Cao S, et al. The diagnostic accuracy of dermoscopy and reflectance confocal microscopy for amelanotic/hypomelanotic melanoma: a systematic review and meta-analysis. *Br J Dermatol.* 2020;183(2):210-219. doi:10.1111/bjd.18722
- 15 Hoang LN, Park KJ, Soslow RA, Murali R. Squamous precursor lesions of the vulva: current classification and diagnostic challenges. *Pathology.* 2016;48(4):291-302. doi:10.1016/j.pathol.2016.02.015
- 16 Hogendoorn GK, Bruggink SC, de Koning MNC, et al. Morphological characteristics and human papillomavirus genotype predict the treatment response in cutaneous warts. *Br J Dermatol.* 2018;178(1):253-260. doi:10.1111/bjd.15758
- 17 Hibler BP, Qi Q, Rossi AM. Current state of imaging in dermatology. *Semin Cutan Med Surg.* 2016;35(1):2-8. doi:10.12788/sjder.2016.001
- 18 Gagné HM. Colposcopy of the vagina and vulva. *Obstet Gynecol Clin North Am.* 2008;35(4):659-669; x. doi:10.1016/j.jogc.2008.10.002
- 19 Chauvel-Picard J, Bérout V, Tognetti L, et al. Line-field confocal optical coherence tomography as a tool for three-dimensional in vivo quantification of healthy epidermis: A pilot study. *J Biophotonics.* 2022;15(2):e202100236. doi:10.1002/jbio.202100236
- 20 Cinotti E, Bertello M, Cartocci A, et al. Comparison of reflectance confocal microscopy and line-field optical coherence tomography for the identification of keratinocyte skin tumours. *Ski Res Technol Off J Int Soc Bioeng Ski [and] Int Soc Digit Imaging Ski [and] Int Soc Ski Imaging.* Published online November 2022. doi:10.1111/srt.13215
- 21 Verzi AE, Micali G, Lacarrubba F. Line-Field Confocal Optical Coherence Tomography May Enhance Monitoring of Superficial Basal Cell Carcinoma Treated with Imiquimod 5% Cream: A Pilot Study. *Cancers (Basel).* 2021;13(19). doi:10.3390/cancers13194913
- 22 Schuh S, Ruini C, Perwein MKE, et al. Line-Field Confocal Optical Coherence Tomography: A New Tool for the Differentiation between Nevi and Melanomas? *Cancers (Basel).* 2022;14(5). doi:10.3390/cancers14051404
- 23 Perez-Anker J, Puig S, Alos L, et al. Morphological evaluation of melanocytic lesions with three-dimensional line-field confocal optical coherence tomography: correlation with histopathology and reflectance confocal microscopy. A pilot study. *Clin Exp Dermatol.* 2022;47(12):2222-2233. doi:10.1111/ced.15383
- 24 Li Z, Koban KC, Schenck TL, Giunta RE, Li Q, Sun Y. Artificial Intelligence in Dermatology Image Analysis: Current Developments and Future Trends. *J Clin Med.* 2022;11(22). doi:10.3390/jcm11226826
- 25 Jartarkar SR, Cockerell CJ, Patil A, et al. Artificial intelligence in Dermatopathology. *J Cosmet Dermatol.* Published online December 2022. doi:10.1111/jocd.15565
- 26 Ring C, Cox N, Lee JB. Dermatoscopy. *Clin Dermatol.* 2021;39(4):635-642. doi:10.1016/j.clindermatol.2021.03.009
- 27 Byrd AL, Belkaid Y, Segre JA. The human skin microbiome. *Nat Rev Microbiol.* 2018;16(3):143-155. doi:10.1038/nrmicro.2017.157
- 28 Marcon AR, Turvey S, Caulfield T. 'Gut health' and the microbiome in the popular press: a content analysis. *BMJ Open.* 2021;11(7):e052446. doi:10.1136/bmjopen-2021-052446
- 29 KBV Research. *Global Printed Electronics Market Size, Share & Industry Trends Analysis Report By Material, By Technology, By Device, By Regional Outlook and Forecast, 2022 - 2028.*; 2022. Accessed January 22, 2023. <https://www.globenewswire.com/en/news-release/2022/11/02/2546254/28124/en/Global-Human-Microbiome-Market-Report-2022-Rising-Focus-on-the-Development-of-Therapeutics-Driving-Growth.html>
- 30 Grice EA, Segre JA. The human microbiome: our second genome. *Annu Rev Genomics Hum Genet.* 2012;13:151-170. doi:10.1146/ANNUREV-GENOM-090711-163814
- 31 Picardo SL, Coburn B, Hansen AR. The microbiome and cancer for clinicians. *Crit Rev Oncol Hematol.* 2019;141:1-12. doi:10.1016/j.critrevonc.2019.06.004
- 32 Valles-Colomer M, Falony G, Darzi Y, et al. The neuroactive potential of the human gut microbiota in quality of life and depression. *Nat Microbiol* 2019 44. 2019;4(4):623-632. doi:10.1038/s41564-018-0337-x
- 33 Zwitterink RD, van den Munkhof EHA, Leverstein-van Hall MA, et al. The vaginal microbiota in the course of bacterial vaginosis treatment. *Eur J Clin Microbiol Infect Dis.* 2021;40(3):651-656. doi:10.1007/s10096-020-04049-6
- 34 Yoshikata R, Yamaguchi M, Mase Y, Tatsuyuki A, Myint KZY, Ohta H. Evaluation of the efficacy of Lactobacillus-containing feminine hygiene products on vaginal microbiome and genitourinary symptoms in pre- and postmenopausal women: A pilot randomized controlled trial. *PLoS One.* 2022;17(12):e0270242. doi:10.1371/journal.pone.0270242
- 35 Falagas ME, Betsi GI, Athanasiou S. Probiotics for the treatment of women with bacterial vaginosis. *Clin Microbiol Infect Off Publ Eur Soc Clin Microbiol Infect Dis.* 2007;13(7):657-664. doi:10.1111/j.1469-0691.2007.01688.x
- 36 Armstrong E, Hemmerling A, Miller S, et al. Sustained effect of LACTIN-V (Lactobacillus crispatus CTV-05) on genital immunology following standard bacterial vaginosis treatment: results from a randomised, placebo-controlled trial. *The Lancet Microbe.* 2022;3(6):e435-e442. doi:10.1016/S2666-5247(22)00043-X
- 37 Management of symptomatic vulvovaginal atrophy: 2013 position statement of The North American Menopause Society. *Menopause.* 2013;20(9):884-888. doi:10.1097/GME.0b013e3182a122c210.1097/GME.0b013e3182a122c2
- 38 Liu X, Zhuo Y, Zhou Y, Hu J, Wen H, Xiao C. Analysis of the Vulvar Skin Microbiota in Asymptomatic Women and Patients With Vulvar Lichen Sclerosus Based on 16S rRNA Sequencing. *Front Cell Dev Biol.* 2022;10:842031. doi:10.3389/fcell.2022.842031
- 39 Characterizing the Microbiome in Postmenopausal Women With Vulvar Lichen Sclerosus - Full Text View - ClinicalTrials.gov. Accessed January 11, 2023. <https://clinicaltrials.gov/ct2/show/NCT05147129?cond=lichen+sclerosus&draw=2&rank=10>
- 40 Genital Lichen Sclerosus - Epidemiology, Comorbidities and the Role of Vulvar and Penile Microbiome - Full Text View - ClinicalTrials.gov. Accessed January 14, 2023. <https://clinicaltrials.gov/ct2/show/NCT05671263?cond=lichen+sclerosus&draw=2&rank=2>
- 41 Watchorn RE, van den Munkhof EHAA, Quint KD, et al. Balanopreputial sac and urine microbiota in patients with male genital lichen sclerosus. *Int J Dermatol.* 2020;60(2):201-207. doi:10.1111/ijd.15252
- 42 Cohen AJ, Gaither TW, Srirangapatnam S, et al. Symchronous genitourinary lichen sclerosus signals a distinct urinary microbiome profile in men with urethral stricture disease. *World J Urol.* 2020;39(2). doi:10.1007/s00345-020-03198-9
- 43 Brown CJ, Wong M, Davis CC, Kanti A, Zhou X, Forney LJ. Preliminary characterization of the normal microbiota of the human vulva using cultivation-independent methods. *J Med Microbiol.* 2007;55(PART 2):271-276. doi:10.1099/jmm.0.46607-0
- 44 Bruning E, Chen Y, McCue KA, Rubino JR, Wilkinson JE, Brown ADG. A 28 Day Clinical Assessment of a Lactic Acid-containing Antimicrobial Intimate Gel Wash Formulation on Skin Tolerance and Impact on the Vulvar Microbiome. *Antibiot (Basel, Switzerland).* 2020;9(2). doi:10.3390/antibiotics9020055
- 45 Miyamoto T, Akiba S, Sato N, et al. Study of the vulvar skin in healthy Japanese women: components of the stratum corneum and
- 46 Vongsa R, Hoffman D, Shepard K, Koenig D. Comparative study of vulva and abdominal skin microbiota of healthy females with high and average BMI. *BMC Microbiol.* 2019;19(1):16. doi:10.1186/s12866-019-1391-0
- 47 Costello EK, Lauber CL, Hamady M, Fierer N, Gordon JI, Knight R. Bacterial community variation in human body habitats across space and time. *Science (80- ).* 2009;326(5960):1694-1697. doi:10.1126/science.1177486
- 48 Shiraishi T, Fukuda K, Morotomi N, et al. Influence of menstruation on the microbiota of healthy women's labia minora as analyzed using a 16S rRNA gene-based clone library method. *Jpn J Infect Dis.* 2011;64(1):76-80.
- 49 Hickey RJ, Zhou X, Settles ML, et al. Vaginal microbiota of adolescent girls prior to the onset of menarche resemble those of reproductive-age women. *MBio.* 2015;6(2). doi:10.1128/mBio.00097-15
- 50 Chattopadhyay S, Arnold JD, Malayil L, et al. Potential role of the skin and gut microbiota in premenarchal vulvar lichen sclerosus: A pilot case-control study. *PLoS One.* 2021;16(1):e0245243. doi:10.1371/journal.pone.0245243
- 51 Jayaram A, Witkin SS, Zhou X, et al. The bacterial microbiome in paired vaginal and vestibular samples from women with vulvar vestibulitis syndrome. *Pathog Dis.* 2014;72(3):161-166. doi:10.1111/2049-632X.12197
- 52 Murina F, Caimi C, Di Piero F, Di Francesco S, Cetin I. Features of the Vaginal and Vestibular Microbioma in Patients With Vestibulodynia: A Case-Control Study. *Journal of Lower Genital Tract Disease.* 24(3), 290-294. *J Low Genit Tract Dis.* 2020;24(3):290-294. doi:10.1097/LGT.0000000000000523
- 53 Gynecologic Extramammary Paget's Disease - Full Text View - ClinicalTrials.gov. Accessed January 18, 2023. <https://clinicaltrials.gov/ct2/show/NCT03564483?term=microbiome&cond=vulva&draw=2&rank=3>
- 54 Bodelon C, Madeleine MM, Voigt LF, Weiss NS. Is the incidence of invasive vulvar cancer increasing in the United States? *Cancer Causes Control.* 2009;20(9):1779-1782. doi:10.1007/s10552-009-9418-8
- 55 Pinto AP, Miron A, Yassin Y, et al. Differentiated vulvar intraepithelial neoplasia contains Tps3 mutations and is genetically linked to vulvar squamous cell carcinoma. *Mod Pathol an Off J United States Am Acad Pathol Inc.* 2010;23(3):404-412. doi:10.1038/modpathol.2009.179
- 56 Thuijs NB, van Beurden M, Bruggink AH, Steenbergen RDMM, Berkhof J, Bleeker MCGG. Vulvar intraepithelial neoplasia: Incidence and long-term risk of vulvar squamous cell carcinoma. *Int J cancer.* 2021;148(1):90-98. doi:10.1002/ijc.33198
- 57 Akhtar-Danesh N, Elit L, Lytwyn A. Trends in incidence and survival of women with invasive vulvar cancer in the United States and Canada: A population-based study. *Gynecol Oncol.* 2014;134(2):314-318. doi:https://doi.org/10.1016/j.ygyno.2014.05.014
- 58 Olawaiye AB, Cuello MA, Rogers LJ. Cancer of the vulva: 2021 update. *Int J Gynecol Obstet.* 2021;155(S1):7-18. doi:10.1002/IJGO.13881
- 59 Biomarkers of Lichen Sclerosus - Full Text View - ClinicalTrials.gov. Accessed January 3, 2023. <https://clinicaltrials.gov/ct2/show/NCT03561428?cond=Lichen+Sclerosus&draw=2&rank=1>
- 60 Laser vs Clobetasol for Lichen Sclerosus - Full Text View - ClinicalTrials.gov. Accessed January 14, 2023. <https://clinicaltrials.gov/ct2/show/NCT05010421>
- 61 Krapf JM, Mitchell L, Holton MA, Goldstein AT. Vulvar lichen sclerosus: Current perspectives. *Int J Womens*

- Health. 2020;12:11-20. doi:10.2147/IJWH.S191200
- 62 Preti M, Vieira-Baptista P, Digesu GA, et al. The clinical role of LASER for vulvar and vaginal treatments in gynecology and female urology: An ICS/ISSVD best practice consensus document. *Neurol Urodyn*. 2019;38(3):1009-1023. doi:https://doi.org/10.1002/nau.23931
- 63 A Study to Evaluate the Efficacy and Safety of Ruxolitinib Cream in Participants With Lichen Sclerosus - Full Text View - ClinicalTrials.gov. Accessed January 3, 2023. <https://clinicaltrials.gov/ct2/show/NCT05593445?cond=Lichen+Sclerosus&draw=2&rank=4>
- 64 FDA approves topical treatment addressing repigmentation in vitiligo in patients aged 12 and older | FDA. Accessed January 10, 2023. <https://www.fda.gov/drugs/news-events-human-drugs/fda-approves-topical-treatment-addressing-repigmentation-vitiligo-patients-aged-12-and-older>
- 65 Hwang JR, Driscoll MS. Review of Ruxolitinib for Treatment of Non-Segmental Vitiligo. *Ann Pharmacother*. Published online December 2022;10600280221143748. doi:10.1177/10600280221143748
- 66 Marchioro HZ, Silva de Castro CC, Fava VM, Sakiyama PH, Dellatorre G, Miot HA. Update on the pathogenesis of vitiligo. *An Bras Dermatol*. 2022;97(4):478-490. doi:10.1016/j.abd.2021.09.008
- 67 Chapman S, Gold LS, Lim HW. Janus kinase inhibitors in dermatology: Part II. A comprehensive review. *J Am Acad Dermatol*. 2022;86(2):414-422. doi:10.1016/j.jaad.2021.06.873
- 68 Wijaya M, Lee G, Fischer G. Why do some patients with vulval lichen sclerosus on long-term topical corticosteroid treatment experience ongoing poor quality of life? *Australas J Dermatol*. 2022;63(4):463-472. doi:https://doi.org/10.1111/ajd.13926
- 69 Günthert AR, Limacher A, Beltraminelli H, et al. Efficacy of topical progesterone versus topical clobetasol propionate in patients with vulvar lichen sclerosus - A double-blind randomized phase II pilot study. *Eur J Obstet Gynecol Reprod Biol*. 2022;272:88-95. doi:10.1016/j.ejogrb.2022.03.020
- 70 Lewis FM, Tatnall FM, Velangi SS, et al. British Association of Dermatologists guidelines for the management of lichen sclerosus, 2018. *Br J Dermatol*. 2018;178(4):839-853. doi:10.1111/bjd.16241
- 71 Scurry J, Whitehead J, Healey M. Histology of lichen sclerosus varies according to site and proximity to carcinoma. *Am J Dermatopathol*. 2001;23(5):413-418. doi:10.1097/00000372-200110000-00005
- 72 Regauer S, Liegl B, Reich O. Early vulvar lichen sclerosus: A histopathological challenge. *Histopathology*. 2005;47(4):340-347. doi:10.1111/j.1365-2559.2005.02209.x
- 73 Nederlandse Vereniging voor Dermatologie en Venerologie. Lichen Sclerosus Richtlijn 2021. Published online 2021:99.
- 74 Kortekaas KE, Santeogoets SJ, Tas L, et al. Primary vulvar squamous cell carcinomas with high T cell infiltration and active immune signaling are potential candidates for neoadjuvant PD-1/PD-L1 immunotherapy. *J Immunother cancer*. 2021;9(10). doi:10.1136/JITC-2021-003671
- 75 Abdulrahman Z, De Miranda N, Van Esch EMG, et al. Pre-existing inflammatory immune microenvironment predicts the clinical response of vulvar high-grade squamous intraepithelial lesions to therapeutic HPV16 vaccination. 2020;8(1):e000563. doi:10.1136/JITC-2020-000563
- 76 van Seters M, van Beurden M, ten Kate FJW, et al. Treatment of vulvar intraepithelial neoplasia with topical imiquimod. *N Engl J Med*. 2008;358(14):1465-1473. doi:10.1056/NEJMoa072685
- 77 Trutnovsky G, Reich O, Joura EA, et al. Topical imiquimod versus surgery for vulvar intraepithelial neoplasia: a multicentre, randomised, phase 3, non-inferiority trial. *Lancet*. 2022;399(10337):1790-1798. doi:10.1016/S0140-6736(22)00469-X
- 78 Kenter GG, Welters MJP, Valentijn ARPM, et al. Vaccination against HPV-16 oncoproteins for vulvar intraepithelial neoplasia. *N Engl J Med*. 2009;361(19):1838-1847. doi:10.1056/NEJMoa0810097
- 79 Welters MJP, Kenter GG, de Vos van Steenwijk PJ, et al. Success or failure of vaccination for HPV16-positive vulvar lesions correlates with kinetics and phenotype of induced T-cell responses. *Proc Natl Acad Sci U S A*. 2010;107(26):11895-11899. doi:10.1073/pnas.1006500107
- 80 van Poelgeest MIE, Welters MJP, Vermeij R, et al. Vaccination against Oncoproteins of HPV16 for Noninvasive Vulvar/Vaginal Lesions: Lesion Clearance Is Related to the Strength of the T-Cell Response. *Clin Cancer Res an Off J Am Assoc Cancer Res*. 2016;22(10):2342-2350. doi:10.1158/1078-0432.CCR-15-2594
- 81 Huh WK, Joura EA, Giuliano AR, et al. Final efficacy, immunogenicity, and safety analyses of a nine-valent human papillomavirus vaccine in women aged 16-26 years: a randomised, double-blind trial. *Lancet (London, England)*. 2017;390(10108):2143-2159. doi:10.1016/S0140-6736(17)31821-4
- 82 Kamolratanakul S, Pitisuttithum P. Human Papillomavirus Vaccine Efficacy and Effectiveness against Cancer. *Vaccines*. 2021;9(12). doi:10.3390/vaccines9121413
- 83 Artesunate Ointment for the Treatment of High Grade Vulvar Intraepithelial Neoplasia (HSIL VIN2/3) - Full Text View - ClinicalTrials.gov. Accessed January 12, 2023. <https://clinicaltrials.gov/ct2/show/NCT03792516?cond=vulvar+HSIL&draw=2&rank=5>
- 84 Stier EA, Goldstone SE, Einstein MH, et al. Safety and efficacy of topical cidofovir to treat high-grade perianal and vulvar intraepithelial neoplasia in HIV-positive men and women. *AIDS*. 2013;27(4):545-551. doi:10.1097/QAD.0b013e32835a9b16
- 85 Rijsbergen M, Rijneveld R, Todd M, et al. Results of phase 2 trials exploring the safety and efficacy of omiganan in patients with human papillomavirus-induced genital lesions. *Br J Clin Pharmacol*. 2020;86(11):2133-2143. doi:10.1111/BCP.14181
- 86 Trimble CL, Morrow MP, Kraynyak KA, et al. Safety, efficacy, and immunogenicity of VGX-3100, a therapeutic synthetic DNA vaccine targeting human papillomavirus 16 and 18 E6 and E7 proteins for cervical intraepithelial neoplasia 2/3: a randomised, double-blind, placebo-controlled phase 2b trial. *Lancet (London, England)*. 2015;386(10008):2078-2088. doi:10.1016/S0140-6736(15)00239-1
- 87 Evaluation of VGX-3100 and Electroporation Alone or in Combination With Imiquimod for the Treatment of HPV-16 and/or HPV-18 Related Vulvar HSIL (Also Referred as: VIN 2 or VIN 3) - Full Text View - ClinicalTrials.gov. Accessed January 13, 2023. <https://clinicaltrials.gov/ct2/show/NCT03180684?cond=vulvar+HSIL&draw=2&rank=2>
- 88 Maclean AB, Jones RW. Differences Between Squamous Intraepithelial Lesions of the Vulva and the Cervix. *J Low Genit Tract Dis*. 2020;24(3):330-331. doi:10.1097/LGT.0000000000000545
- 89 Boero V, Liverani CA, Brambilla M, et al. The 'CIV Classification,' a New Proposal for the Architectural Grading of Vulvar Lichen Sclerosus. *J Low Genit Tract Dis*. 2021;25(4):291-295. doi:10.1097/LGT.0000000000000627
- 90 Günthert AR, Duclos K, Jahns BG, et al. Clinical Scoring System for Vulvar Lichen Sclerosus. *J Sex Med*. 2012;9(9):2342-2350. doi:10.1111/j.1743-6109.2012.02814.x
- 91 Eisenhauer EA, Therasse P, Bogaerts J, et al. New response evaluation criteria in solid tumours: revised RECIST guideline (version 1.1). *Eur J Cancer*. 2009;45(2):228-247. doi:10.1016/j.ejca.2008.10.026
- 92 Rijsbergen M, Rijneveld R, Todd M, et al. Results of phase 2 trials exploring the safety and efficacy of omiganan in patients with human papillomavirus-induced genital lesions. *Br J Clin Pharmacol*. 2020;86(11):2133-2143. doi:10.1111/BCP.14181
- 93 Pergialiotis V, Bellos I, Biliou E-C, Varnava P, Mitsopoulou D, Doumouchtsis SK. An arm-based network meta-analysis on treatments for vulvar lichen sclerosus and a call for development of core outcome sets. *Am J Obstet Gynecol*. 2020;222(6):542-550.e6. doi:10.1016/j.ajog.2019.10.095
- 94 Pope R, Lee MH, Myers A, et al. Lichen Sclerosus and Sexual Dysfunction: A Systematic Review and Meta-Analysis. *J Sex Med*. 2022;19(11):1616-1624. doi:10.1016/j.JSXM.2022.07.011
- 95 Vittrup G, Westmark S, Riis J, et al. The Impact of Psychosexual Counseling in Women With Lichen Sclerosus: A Randomized Controlled Trial. *J Low Genit Tract Dis*. 2022;26(3):258-264. doi:10.1097/LGT.0000000000000669
- 96 Lichen Sclerosus - the Influence on Quality of Life - Full Text View - ClinicalTrials.gov. Accessed January 14, 2023. <https://clinicaltrials.gov/ct2/show/NCT03419377>
- 97 Cedejas BR, Smith-McCune KK, Khan MJ. Does treatment for cervical and vulvar dysplasia impact women's sexual health? *Am J Obstet Gynecol*. 2015;212(3):291-297.
- 98 Likes WM, Stegbauer C, Hathaway D, Brown C, Tillmanns T. Use of the female sexual function index in women with vulvar intraepithelial neoplasia. *J Sex Marital Ther*. 2006;32(3):255-266. doi:10.1080/00926230600575348
- 99 Elsner P, Wilhelm D, Maibach HI. Mechanical properties of human forearm and vulvar skin. *Br J Dermatol*. 1990;122(5):607-614. doi:10.1111/j.1365-2133.1990.tb07282.x
- 100 Morrel B, Ewing-Graham PC, van der Avoort IAM, Pasmans SGMA, Damman J. Structured analysis of histopathological characteristics of vulvar lichen sclerosus in a juvenile population. *Hum Pathol*. 2020;106:23-31. doi:10.1016/j.humpath.2020.09.003
- 101 Hoang LN, Park KJ, Soslow RA, Murali R. Squamous precursor lesions of the vulva: current classification and diagnostic challenges. *Pathology*. 2016;48(4):291-302. doi:10.1016/j.pathol.2016.02.015
- 102 Thuijs NB, Schonck WAM, Klaver LLJ, et al. Biomarker Expression in Multifocal Vulvar High-Grade Squamous Intraepithelial Lesions. *Cancers (Basel)*. 2021;13(2). doi:10.3390/CANCERS13225646
- 103 Nooij LS, Dreef EJ, Smit VTHBM, Van Poelgeest MIE, Bosse T. Stathmin is a highly sensitive and specific biomarker for vulvar high-grade squamous intraepithelial lesions. *J Clin Pathol*. 2016;69(12):1070-1075. doi:10.1136/jclinpath-2016-203676
- 104 Yang M, Sun K, Chang J. Screening differential circular RNAs expression profiles in Vulvar Lichen Sclerosus. *Biomed Eng Online*. 2022;21(1):51. doi:10.1186/s12938-022-01013-7
- 105 Oyama N, Hasegawa M. Lichen Sclerosus: A Current Landscape of Autoimmune and Genetic Interplay. *Diagnostics (Basel, Switzerland)*. 2022;12(12):3070. doi:10.3390/DIAGNOSTICS12123070
- 106 Subramanian I, Verma S, Kumar S, Jere A, Anamika K. Multi-omics Data Integration, Interpretation, and Its Application. *Bioinform Biol Insights*. 2020;14:1177932219899051. doi:10.1177/1177932219899051
- 107 McDermott JE, Wang J, Mitchell H, et al. Challenges in Biomarker Discovery: Combining Expert Insights with Statistical Analysis of Complex Omics Data. *Expert Opin Med Diagn*. 2013;7(1):37-51. doi:10.1517/17530059.2012.718329



De vulva is het zichtbare gedeelte van de vrouwelijke geslachtsdelen. De vulva moet tegen veel invloeden bestand zijn, waaronder frictie van wandelen of fietsen, alsook urine en vaginale afscheiding. Daarnaast vervult de vulva een seksuele rol. Zodoende is het begrijpelijk dat aandoeningen van de vulva voor aanzienlijke lichamelijke en psychologische problemen kunnen zorgen. Desondanks zijn vulvaire aandoeningen een onderbelicht onderwerp in de geneeskunde, mede door taboe in de samenleving.

Vulvaire ziekten kunnen goedaardig en kwaadaardig zijn. De focus van dit proefschrift ligt op premaligne vulvaire laesies. Vulvakanker is zeldzaam, maar de voorstadia van vulvakanker zijn relatief veelvoorkomend. Er worden twee aparte ontstaansvormen van vulvakanker erkend. Ongeveer 30% van de vulvatumoren kunnen ontstaan vanuit vulvaire HSIL (hooggradige squameuze intra-epitheliale laesies). Deze huidaanandoening komt door een infectie met het humaan papillomavirus (HPV), hetzelfde virus dat ook baarmoederhalskanker veroorzaakt. De overige 70% van vulvakanker ontstaat zonder HPV vanuit huidafwijkingen genaamd gedifferentieerde vulvaire intra-epitheliale neoplasie (dVIN). Deze ziekte komt op diens beurt vaak voor in een achtergrond van lichen sclerosus (LS), een chronische inflammatoire huidaanandoening dat ongeveer 0.3% van alle mannen, vrouwen en kinderen treft. LS is een veelvoorkomende, levenslange aandoening dat voor jeuk en verdunning van de genitale huid zorgt. Het gevolg bij vrouwen met LS is dat structuren zoals de kleine schaamlippen en de clitoris over tijd kunnen verdwijnen. De oorzaak van LS is onbekend. Wel zijn er aanwijzingen voor een genetische aanleg en wordt een associatie gezien met auto-immuunziekten.

Deze nauw verbonden vulvaire aandoeningen hebben met elkaar gemeen dat de bestaande behandelopties suboptimaal zijn. Vulvakanker en gedifferentieerde VIN worden operatief behandeld door middel van resectie van het aangedane vulvaire weefsel. Desalniettemin hebben beide ziekten ongeveer 40% kans om terug te keren met een zogenaamd recidief. Bovendien heeft opereren in een delicaat gebied zoals de vulva aanzienlijke gevolgen op dagelijks functioneren en seksualiteit. Vulvaire HSIL kan operatief of met lasertherapie worden behandeld. Topicale vulvaire HSIL-behandeling kan met imiquimod crème, welke immuun cellen stimuleert via inductie van de Toll-like 7 receptor (TLR-7). Helaas is imiquimod op termijn niet patiëntvriendelijk door bijwerkingen van pijn en irritatie, wat de toepassing en effectiviteit van imiquimod beperkt. Bovendien is de kans op een recidief vulvaire HSIL-laesie ongeveer 50%. Ondanks behandeling blijft er een kans van ongeveer 3%

dat alsnog vulvakanker ontstaat vanuit een vulvaire HSIL-laesie. LS wordt niet operatief behandeld, maar door levenslang smeren met ultra-potente (klasse 4) corticosteroiden, zoals clobetasol. Dit kan de jeukklachten doen verminderen en ziekteprogressie afremmen, maar niet volledig voorkomen. Veel klinici en patiënten zijn nog altijd huiverig over het inzetten van een ultra-potent middel, aangezien topicale corticosteroiden doorgaans niet is geïndiceerd voor applicatie op de delicate genitale huid. Zodoende wordt LS vaak niet agressief genoeg behandeld. Deze terughoudendheid kan desastreuze gevolgen hebben op de ziekteprogressie. Alle patiëntengroepen rapporteren hoge psychosociale en lichamelijke morbiditeit ten gevolge van hun vulvaire aandoening.

Bij al deze vulvaire ziekten is er dus een gebrek aan effectieve, specifieke en patiëntvriendelijke behandelopties. Om nieuwe therapie op de markt te brengen moet het ontstaan en beloop van een ziekte goed te begrepen en herkend worden. Pas daarna kan gerichte therapie worden ontwikkeld en getest. Veranderingen door nieuwe therapie worden in beeld gebracht door middel van zogenaamde 'biomarkers' die ziekte kunnen onderscheiden van een gezonde staat. Met deze meetmethoden kan je het effect van je nieuwe therapie beter volgen en beoordelen of een nieuwe therapie werkzaam is in klinische trials. Dit proefschrift beschrijft onderdelen van de ontwikkeling van nieuwe therapieën en herkenningpunten voor de behandeling van vulvakanker en voorstadia van vulvakanker. De these bestaat uit twee onderdelen:

**Sectie I** beschrijft de ontwikkeling en validatie van verschillende beeldvormende biomarkers voor vulvaire en HPV-gemedieerde ziekten.

In **Sectie II** wordt kennis opgedaan over het vulvaire microbiom. Hierdoor zijn inzichten vergaard met betrekking tot de ontstaansgeschiedenis van vulvaire ziekten, alsmede worden nieuwe biomarkers en targets voor therapie geïdentificeerd.

## SECTIE I: TOEPASSING EN VALIDATIE VAN BEELDVORMENDE BIOMARKERS VOOR VULVAIRE EN HPV-GEMEDIEERDE ZIEKTEN

Meetmethoden die nauwkeurig de ziekte-ernst en -last van vulvaire ziekten kunnen bepalen zijn schaars. Het eerste onderdeel van dit proefschrift focust op de ontwikkeling van betere beeldvormende biomarkers voor vulvaire en HPV-gemedieerde aandoeningen. Allereerst wordt de validatie van driedimensionale (3D) fotografie bij vulvaire HSIL, genitale wratten en wratten van de handen en voeten gerapporteerd. Vervolgens is een studie

uitgevoerd waarbij een multimodale aanpak is ingezet om vulvaire HSIL en LS te typeren en vergeleken met gezonde vrijwilligers. Tijdens deze diepe fenotypering zijn onder andere technieken zoals dermatoscopie, dynamische optische coherentie tomografie (D-OCT) en reflecterende confocale microscopie (RCM) toegepast. Vervolgens wordt een studie beschreven waarbij 3D fotografie is ingezet in een klinisch onderzoek met een nieuw geneesmiddel tegen wratten op de handen.

Wanneer nieuwe therapieën worden getest, is het van belang om het verschil in grootte over tijd accuraat vast te kunnen stellen. Vulvaire HSIL-laesies zijn vaak grillig van vorm en de oppervlakte van de aandoening wordt slechts matig ingeschat. In **hoofdstuk 2** wordt verbetering van de groottebepaling van HPV-gemedieerde laesies door middel van 3D fotografie gevalideerd. Deze techniek is vervolgens toegepast in later beschreven klinische studies in dit proefschrift. Tijdens de technische validatie bleek 3D fotografie zeer precies, accuraat en nauwkeurig voor de bepaling van de grootte van vulvaire HSIL, genitale wratten en wratten van de handen en voeten. Deze precisie werd gereproduceerd wanneer multipelen personen waren de beoordeling en metingen uitvoerden. De nauwkeurigheid van 3D fotografie werd vergeleken met de gouden standaard: de schuifmaat. Hier werden kleine verschillen gevonden de bepaling van de diameter van wratten van handen en voeten, genitale wratten en vulvaire HSIL. Bovendien werd een discrepantie gezien voor de bepaling van de hoogte van wratten van handen en voeten. 3D fotografie blijkt ook toepasbaar voor het opmeten van de oppervlakte en het volume van laesies. De conclusie van deze technische en klinische validatie is dat 3D fotografie de grootte van een HPV-gemedieerde laesie nauwkeurig kan vervolgen over tijd. Deze techniek kan zodoende worden ingezet om de werkzaamheid van een nieuwe therapie in te bepalen een vroege klinische fase.

Vervolgens is een grote multimodale studie uitgevoerd waarbij een scala aan beeldvormingstechnieken en analysemethoden zijn ingezet om vulvaire HSIL en LS te typeren en vergelijken met gezond vulvaweefsel. In **hoofdstuk 3** worden de resultaten van twee beeldvormingstechnieken, dermatoscopie en D-OCT besproken en vergeleken met histologie. Het doel van deze studie was om karakteristieken per ziekte te identificeren en om de praktische applicatie en verdraagzaamheid van deze technieken te onderzoeken. Hiervoor zijn in totaal 5 vrouwen met vulvaire HSIL, 10 vrouwen met LS en 10 gezonde vrijwilligers geïnccludeerd in een prospectieve studie. Hieruit bleek dat dermatoscopie en D-OCT beiden goed werden getolereerd door de

patiënten en gezonde vrijwilligers om toe te passen op het vulvaire gebied. Bij dermatoscopische analyse werd gezien dat de meeste karakteristieken niet onderscheidend genoeg zijn tussen de verschillende ziekte-entiteiten en gezond vulvaire weefsel. Wel was een wrachtige structuur specifiek voor vulvaire HSIL, echter is deze bevinding klinisch niet van toegevoegde waarde aangezien deze structuur ook zichtbaar is tijdens visuele inspectie tijdens het gynaecologisch onderzoek. Bij LS werden dikke vertakkende vaten geobserveerd in een subset van de patiënten. Dit is niet eerder herkend door andere auteurs die dermatoscopie bij LS hebben onderzocht. Deze toename aan vaten in LS wordt teruggevonden in verhoogde bloeddorstrooming gemeten met de D-OCT. Bij vulvaire HSIL werd gevonden dat niet-zieke vulvaire huid van vulvaire HSIL-patiënten verhoogde bloeddorstrooming vertoonden opzichte van de vulvaire huid van gezonde vrijwilligers. Deze bevinding benadrukt de consensus dat gezond-ogende huid bij patiënten niet als gezonde controle meegenomen dient te worden, aangezien ook veranderingen in de aangrenzende huid optreden ten gevolge van het ziekteproces of de toegepaste therapieën. Epidermale dikte kan gemeten worden met een geïntegreerd algoritme van de D-OCT, maar deze blijkt niet geoptimaliseerd voor de oneven vulvaire huid. Bij handmatige nameting van de epidermale dikte werd gezien dat de huid van LS dunner is dan gezonde controles, een bevinding die teruggezien werd in histologie. Al in al demonstreert deze studie dat dermatoscopie na verdere validatie in een vulvaire kliniek mogelijk kan worden ingezet om de beeldvorming en opvolging van vulvaire ziekten te bevorderen. D-OCT lijkt in dit stadium meer geschikt voor onderzoeksdoel-einden, allereerst met technische optimalisatie en vervolgens voor translatie van observaties naar klinisch relevante eindpunten.

In dezelfde multimodale studie bij patiënten met vulvaire HSIL, LS en gezonde vrijwilligers is een techniek genaamd confocale microscopie (RCM) toegepast. Deze bevindingen zijn beschreven in **hoofdstuk 4**. RCM is een op laser gebaseerde techniek welke op non-invasieve wijze de epidermis en dermis tot cellulaire resolutie kan visualiseren tot een diepte van 250 µm. Deze techniek is al veelvuldig ingezet onderzoek naar melanomen en andere huidziekten, maar nog zelden op de vulva. Bovendien was het onbekend of de RCM technisch uitvoerbaar was op de vulva en of patiënten het een verdraagbare techniek vonden. Het doel van deze studie was daarom om de technische applicatie en patiënt verdraagzaamheid van de RCM-techniek te onderzoeken en karakteristieken van vulvaire HSIL, LS en gezonde vulvaire huid te

beschrijven. De bevindingen laten zien dat de RCM als applicatie, na enkele praktische aanpassingen welke uitgebreid beschreven zijn in het manuscript, technisch goed uit te voeren is door getrainde artsen en onderzoekers. Patiënten en gezonde vrijwilligers vonden de RCM-techniek verdraagzaam. De huid van vulvaire HSIL werd gekarakteriseerd door een atypische honingraatstructuur en aanwezigheid van melanofagen en lymfocyteninfiltraat in de dermis en epidermis. Bij LS werden vergelijkbare karakteristieken teruggevonden, maar specifiek ook de aanwezigheid van dermale sclerose en gehyelaniseerde vaten. Gezonde vulvaire huid werd gekarakteriseerd door het gebrek van deze karakteristieken in aanwezigheid van een intacte junctie van de epidermis naar de dermis. Deze bevindingen zijn bekende ziekte-karakteristieken die worden teruggevonden in biopten. RCM non-invasief en daarmee patiëntvriendelijker en toepasbaarder dan biopten, alhoewel histologie voor deze ziekten nog lang de gouden standaard zal blijven. Voordat RCM voor zodanige doeleinden kan worden ingezet moet de applicatie worden gevalideerd in een grotere, diverse groep patiënten bij de vulvapoli om de kennis en specificiteit van de hier beschreven bevindingen te objectiveren.

Nieuwe meetmethoden en biomarkers op zichzelf dragen nog niet bij aan de ontwikkeling van nieuwe en verbeterde therapieën voor vulvaire ziekten. Deze inzichten over beeldvormingstechnieken moeten daarvoor ook worden ingezet in de studies naar het effect van geneesmiddelen. In **hoofdstuk 5** wordt de 3D-camera techniek geïncorporeerd in een vroege-fase klinische dubbelblind gerandomiseerde, placebo-gecontroleerde klinische studie. Hierbij werd een nieuw synthetisch peptide, CY-002, werd getest bij 63 patiënten met wratten op de handen. Wratten op de handen of in het genitale gebied zijn veelvoorkomende, benigne laesies die door HPV worden veroorzaakt. Dit zijn andere fylotypen dan de HPV-typen die vulvaire en cervicale dysplasie veroorzaken. Rekrutering van patiënten met vulvaire aandoeningen voor klinisch wetenschappelijk onderzoek verloopt in de praktijk moeizaam, mede door de zeldzaamheid, morbiditeit en taboe rondom de ziekte. Daarom is het soms mogelijk om in andere patiëntengroepen potentiële targets voor nieuwe HPV-gemedieerde geneesmiddelen te onderzoeken. Wratten op de handen of genitale wratten komen veelvuldig voor en zijn kunnen daarom fungeren als model voor onderzoek naar behandelingen voor HPV-gemedieerde aandoeningen. De huidige behandelvormen van hand- en genitale wratten zijn ontoereikend. In plaats van eliminatie de HPV-infectie staat in huidige behandelingen destructie van het geïnfecteerde epitheel voorop. De

infectiehaard is daarmee niet altijd weggenomen, waardoor patiënten hardnekkige laesies kunnen behouden ondanks therapie. In deze klinische studie naar wratten op de handen stond onderzoek van patiëntveiligheid voorop, aangevuld met een exploratieve analyse voor klinisch effect. Deze effectmaten werden in kaart gebracht door het vervolgen van de klinische response, waaronder aantal en grootte van de laesies. Tevens zijn biomarkers waaronder HPV virale lading, OCT, 3D-fotografie, biopten en morfologische analyse van de laesies onderzocht. Het beoogde werkingsmechanisme van CY-002 is gebaseerd op een discrepantie in de lading van het celmembraan van maligne en HPV-geïnfecteerde cellen ten opzichte van gezonde cellen. Preklinisch werd in multipale tumorcellijnen celdood geïnduceerd door CY-002, terwijl normale cellen werden gespaard. Dit maakt CY-002 een potentieel middel dat gericht maligne of HPV-geïnfecteerde cellen uit de weg kan ruimen. In deze klinische studie werd het werkingsmechanisme van dit middel allereerst in een benigne aandoening getoetst. CY-002 werd veilig bevonden met geen of minimale lokale irritatie na 4 weken dagelijks toedienen onder occlusie. Helaas werd geen significant effect gevonden tussen CY-002 en placebo in de exploratieve analyse van het klinische effect, noch bij de additionele biomarkers. Dit kan mogelijk te verklaren zijn door een hoge mate van geobserveerde effecten in de placebogroep. Bovendien heeft de huid heeft een barrièrefunctie die lastig te penetreren kan zijn door geneesmiddelen. Het zodoende mogelijk dat CY-002 ondanks de occlusie niet volledig tot de HPV-geïnfecteerde cellen in de handwrat is doorgedrongen. Al in al kan deze klinische studie als voorbeeld dienen om toetsing van het werkingsmechanisme van topicale geneesmiddelen in de allereerste klinische fase te integreren om zo rationele geneesmiddelenontwikkeling in kracht bij te zetten.

## SECTIE II: HET VULVAIRE MICROBIOOM

Het menselijk lichaam is in symbiose met een spectrum aan bacteriën, virussen, fungi en parasieten. Dit geheel heet het microbiom. Het microbiom speelt een grote rol in het behouden van gezondheid en het ontstaan van ziekte. Ondanks het feit dat er al veelvuldige connecties zijn gevonden tussen ontregelingen in het microbiom en kanker, is nog niet eerder gekeken naar de rol van het vulvaire microbiom op het ontstaan van vulvakanker, LS en vulvaire HSIL. Dit is des te opmerkelijker aangezien het welbekend is dat een micro-organisme, HPV, verantwoordelijk is voor het ontstaan van vulvaire HSIL. Alhoewel er geen eerder onderzoek is gedaan naar de het vulvaire

microbioom in relatie tot kanker, is er wel veel bekend in hoeverre het cervicovaginale microbioom verstaat tot cervicale dysplasie. Daaruit blijkt dat het verdwijnen van *Lactobacillus* in combinatie met een meer divers vaginaal milieu bijdraagt aan hogere cervicale dysplasie. Evenzo verhoudt de samenstelling van het vaginale microbioom tot het verkrijgen en aanhouden van een HPV-infectie en de progressie tot cervicale kanker.

Als wij vergelijkbare correlaties willen identificeren bij vulvaire aandoeningen is het van belang om allereerst een overzicht te krijgen van de samenstelling van het gezonde vulvaire microbioom. Bevindingen hier naar vanuit een systematische review van de literatuur zijn beschreven in **hoofdstuk 6**. In deze review zijn 10 studies geïdentificeerd waarbij de microbioom samenstelling van de vulva in 261 vrouwen zijn bepaald door middel van sequencing technieken. Negen van de tien studies bepaalden de bacteriële samenstelling door middel van 16S rRNA sequencing en slechts één studie bepaalde ook de fungale fractie van het microbioom middels ITS2 sequencing. De bacteriële compositie van de vulva bestaat uit verschillende genera waaronder *Lactobacillus*, *Corynebacterium*, *Staphylococcus* en *Prevotella*. Zodoende lijkt het microbioom van de gezonde vulva te correleren aan het vaginale milieu. Toch lijkt de vulva uit een meer diverse samenstelling te bestaan dan de vagina, met bacteriën die vaak op de huid en feces worden gevonden. Bovendien zijn er aanwijzingen dat er locatieafhankelijke diversiteit bestaat afhankelijk van verschillende plekken van de vulva. Deze bevindingen reflecteren de functie van de vulva als overgangsepitheel van de vaginale mucosa naar de genitale huid. Echter ontbreekt kennis van de compositie van het vulvaire fungoom en viroom. Metagenomische sequencing is een techniek die een completer beeld geeft van de volledige microbioom samenstelling dan andere technieken, inclusief de niet-bacteriële fractie. Zodoende werd de aanbeveling vanuit de systematische review gedaan om de gezonde vulvaire microbioom samenstelling, bepaald door middel van metagenomische sequencing, te vergelijken met vulvaire HSIL, LS en vulvakanker in een prospectieve klinische studie.

**Hoofdstuk 7** rapporteert de bevindingen van deze klinische studie, een onderdeel van de multimodale studie, waar de vulvaire microbioom samenstelling van patiënten met vulvaire HSIL en LS is vergeleken met gezonde vrouwen. De vaginale en anale microbioom samenstelling werd ook meegenomen in deze analyse. Vrouwen met vulvakanker konden helaas niet worden gerekruteerd. De labia minora van vrouwen met LS bevatten voornamelijk

genera van *Lactobacillus*, *Prevotella* en *Gardnerella*. Vulvaire HSIL-laesies worden voornamelijk gekoloniseerd door *Prevotella* en *Alphapapillomavirus*. Gezonde vrouwen hebben vooral *Prevotella* en *Lactobacillus* op de vulva. Bij LS werd een grotere proportie *Papillomaviridae* gevonden, terwijl er minder *Bacteroidia* aanwezig zijn ten opzichte van de gezonde controles. In vulvaire HSIL was proportioneel meer *Alphapapillomavirus* en minder *Actinobacteria* te vinden vergeleken met gezonde huid. Waterdoorlaatbaarheid (TEWL) is een proxy voor de barrièrefunctie van de huid. Deze kan aangetast zijn door ziekteprocessen (zoals bij eczeem), maar was hiervoor zelden getest bij LS of vulvaire HSIL. In deze studie werd daarom tegelijkertijd met de microbioom analyse gekeken naar de waterdoorlaatbaarheid van de vulvaire huid. Dit blijft een studie in een klein aantal patiënten en gezonde controles, en deze bevindingen zullen moeten worden gevalideerd in grotere cohorten met een diverse groep patiënten (o.a. met vSCC en dVIN) voordat robuuste conclusies geformuleerd kunnen worden. Mogelijk kunnen er zo in de toekomst vanuit het microbioom-onderzoek aanwijzingen voor de oorzaak voor LS of modulators van maligne progressie voor deze vulvaire aandoeningen worden geïdentificeerd. Tegenwoordig worden voor de vaginale niche gerichte microbioom-modulerende therapieën getest in klinische trials ter preventie van hivinfecties en behandeling van bacteriële vaginose of genito-urinaire symptomen van de menopauze. Voor de vulvaire ziekten beschreven in dit proefschrift ontbreken momenteel effectieve, specifieke en patiëntvriendelijke behandelopties. Met de beperkte beschikbare kennis is ontwikkeling van microbioom-gerichte therapie voor deze vulvaire aandoeningen echter nog toekomstmuziek.

### Perspectieven

De bevindingen in dit proefschrift worden in **hoofdstuk 8** samengevat en in perspectief van de literatuur en huidige kennis geplaatst. Hierbij ligt de focus op de toekomstige applicatie van de bevindingen voor het klinische veld. Beeldvormingstechnieken kunnen de herkenning van laesies bevorderen. In het geval van LS of vulvaire HSIL is het belangrijk om maligne progressie zo vroeg mogelijk op te sporen en behandelen. Microbioom analyses van de vulva kunnen hopelijk nieuwe aanknopingspunten voor begrip over het ontstaan van ziekte of factoren maligne progressie geven, ofwel een focus geven voor het ontwikkelen van nieuwe therapieën. Voordat de non-invasieve beeldvormingstechnieken of microbioom analyses klinisch worden

ingezet, moeten deze eerst gevalideerd worden op een grote groep patiënten met een grote groep aan vulvaire aandoeningen. Tevens is het van belang dat de gekozen karakteristieken om een ziekte te beschrijven onderscheidend genoeg zijn van de gezonde toestand en van andere ziekten. Verbeterde biomarkers kunnen ook worden ingezet tijdens geneesmiddelenonderzoek om klinische effecten op farmacologisch niveau te bewijzen. Momenteel worden slechts enkele studies uitgevoerd naar nieuwe therapieën voor vulvaire HSIL en LS. Elk geneesmiddel wordt ontwikkeld met een beoogd werkingsmechanisme waarom het aangrijpt in het ziekteproces. Om deze 'proof-of-concept' te bevestigen moeten betrouwbare biomarkers worden ingezet. Dit proefschrift heeft een voorzet gedaan van enkele potentiële biomarkers voor onderzoek naar vulvaire ziekten. Het proefschrift laat mogelijke toepassingen zien in hoeverre deze nieuwe biomarkers in een vroege fase kunnen worden ingezet om therapie-effectiviteit beter te herkennen.



## Curriculum Vitae

Lisa Pagan was born on 16 July 1992 in Amsterdam and grew up in Haarlem, The Netherlands. After completing bilingual gymnasium at the Mendelcollege in Haarlem in 2010, during which Lisa obtained a Cambridge Certificate of Proficiency in English, she started studying Biomedical Sciences at Leiden University. Her bachelor's degree was partially pursued at the Karolinska Institutet in Stockholm, Sweden, after which Lisa was selected to study Medicine at Leiden University through the 'zij-instroom'. Her clinical rotation in Dermatology was completed at the Academisch Ziekenhuis Paramaribo in Suriname. Lisa's formative clinical rotation was performed at the department of Gynaecology and Obstetrics at the Leiden University Medical Centre (LUMC). Lisa graduated in June 2018 with master's degrees in Biomedical Sciences and Medicine. During her first master's research project, she studied genetic markers in hereditary colon cancer at the Department of Clinical Genetics of the LUMC. Lisa's final research internship was realised at the Centre for Human Drug Research (CHDR) in Leiden focusing on new imaging techniques for vulvar diseases. After graduation, Lisa started as research physician and project leader at the CHDR, with a special interest in gynaecology and dermatology under the supervision of dr. Mariette van Poelgeest, prof. dr. Koos Burggraaf and prof. dr. Robert Rissmann. During her work in early-phase clinical trials, Lisa was educated as a clinical pharmacologist. As of 2023, Lisa has assumed the role of Clinical Study Manager at the CHDR.

- Lisa Pagan\***, Bertine Huisman\*, Rosanne G.C. Naafs, Wouter ten Voorde, Prof. Robert Rissmann, Jurgen M.J. Piek, Jeffrey Damman, Maria J. Juachon, Michelle Osse, Tessa Niemeyer-van der Kolk, Colette L.M. van Hees and Mariette I.E. van Poelgeest. *Dermatoscopy and optical coherence tomography in vulvar HSIL and lichen sclerosis: a prospective observational trial*. Journal of Lower Genital Tract Disease. 2023. doi: 10.1097/LGT.0000000000000731
- Lisa Pagan**, Bertine W. Huisman, Michelle van der Wurff, Rosanne C.G. Naafs, Frank H. J. Schuren, Ingrid M. J. G. Sanders, Wiep Klaas Smits, Romy D. Zwittink, Robert Rissmann, Jurgen M. J. Piek, Jannie G. E. Henderickx and Mariette I. E. van Poelgeest. *The vulvar microbiome in lichen sclerosis and vulvar HSIL; potential players in the pathway to vulvar cancer*. Submitted to Frontiers of Microbiology July 2023.
- Lisa Pagan**, Christina Yfanti, Rianne Rijneveld, Marina Todd, Peter Jongste, Joep J. Feijen, Erica S. Klaassen, Jan Nico Bouwes Bavinck, Linda Struijk, Maurits N.C. de Koning, Lars Prestegarden, Tessa Niemeyer-van der Kolk, Mariette I.E. van Poelgeest and Robert Rissmann. *Results of a randomized, placebo-controlled, first-in-human trial of topical CY-002 in patients with cutaneous warts*. Journal of the European Academy of Dermatology and Venereology. 2022. doi:10.1111/JDV.18291
- Lisa Pagan\***, Roos A. M. Ederveen\*, Bertine W. Huisman, Jan W. Schoones, Romy D. Zwittink, Frank H. J. Schuren, Robert Rissmann, Jurgen M. J. Piek and Mariëtte I. E. van Poelgeest. *The human vulvar microbiome: A systematic review*. Microorganisms. 2021. doi:10.3390/microorganisms9122568
- Bertine W. Huisman, **Lisa Pagan**, Martina Ulrich, Robert Rissmann, Jeffrey Damman, Jurgen M.J. Piek, Tessa Niemeyer-van der Kolk and Mariette I.E. van Poelgeest. *Reflectance confocal microscopy as a non-invasive imaging tool in vulvar high grade squamous intraepithelial lesions and lichen sclerosis: a descriptive morphological study in patients and healthy volunteers*. Experimental Dermatology. 2023. doi: 10.1111/exd.14888
- Melanie Rijsbergen, **Lisa Pagan**, Tessa Niemeyer - van der Kolk, Rianne Rijneveld, Geretta Hogendoorn, Celeste Lemoine, Yuri Meija Miranda, Gary Feiss, Jan Nico Bouwes Bavinck, Jacobus Burggraaf, Mariëtte I.E. van Poelgeest and Robert Rissmann. *Stereophotogrammetric three-dimensional photography is an accurate and precise planimetric method for the clinical visualization and quantification of human papilloma virus-induced skin lesions*. Journal of the European Academy of Dermatology and Venereology. 2019. doi:10.1111/jdv.15474
- Jannik Rousel, Andreea Nădăban, Mahdi Saghari, **Lisa Pagan**, Ahnjili Zhuparris, Bart Theelen, Tom Gambah, Hein E.C. van der Wall, Rob J Vreeken, Gary Feiss, Tessa Niemeyer-van der Kolk, Koos Burggraaf, Martijn van Doorn, Joke Bouwstra and Robert Rissmann. *Lesional Skin of Seborrheic Dermatitis Patients Is Characterized by Skin Barrier Dysfunction and Correlating Alterations in the Stratum Corneum Ceramide Composition*. Experimental Dermatology. 2023. doi: 10.1111/exd.14952
- Jannik Rousel\*, Menthe E. Bergmans\*, Laura W.J. van der Meulen, **Lisa Pagan**, Digna T. de Bruin, Marieke L. de Kam, Naomi B. Klarenbeek, Joke A. Bouwstra, Marieke M.B. Seyger, Juul M.P.A. van den Reek, Tessa Niemeyer-van der Kolk, Robert Rissmann, Martijn B.A. van Doorn and the NGID consortium. *Guselkumab induction therapy demonstrates long-lasting efficacy in patients with mild psoriasis, results from a randomized, placebo-controlled exploratory clinical trial*. Journal of the American Academy of Dermatology. 2023. doi: 10.1016/j.jaad.2023.09.071
- Jannik Rousel, Mahdi Saghari, **Lisa Pagan**, Andreea Nădăban, Tom Gambah, Bart Theelen, Marieke L. De Kam, Jorine Haakman, Hein E.C. Van der Wall, Gary L. Feiss, Tessa Niemeyer - van der Kolk, Jacobus Burggraaf, Joke A. Bouwstra, Robert Rissmann and Martijn B.A. Van Doorn. *Treatment with the Topical Antimicrobial Peptide Omiganan in Mild-To-Moderate Facial Seborrheic Dermatitis versus Ketoconazole and Placebo: Results of a Randomized Controlled Proof-Of-Concept Trial*. International Journal of Molecular Sciences. 2023. doi: 10.3390/ijms241814315
- Joost Kools, Willem Aerts, Erik H. Niks, Karlien Mul, **Lisa Pagan**, Jake S.F. Maurits, Renée Thewissen, Baziel G. van Engelen, Nicol C. Voermans. *Assessment of the Burden of Outpatient Clinic and MRI-guided Needle Muscle Biopsies As Reported By Patients with Facioscapulohumeral Muscular Dystrophy*. Neuromuscular Disorders. 2023. doi:10.1016/j.nmd.2023.04.001
- Willem de Laat, **Lisa Pagan**, R. Karl Malcolm, Maarten Wiegierinck, Victor Nickolson, Bertine Huisman, Rik Stuurman, Michiel van Esdonk and Naomi Klarenbeek. *First-in-human study to assess the pharmacokinetics, tolerability and safety of single-dose oxybutynin hydrochloride administered via a microprocessor-controlled intravaginal ring*. Drug Delivery. 2023. doi:10.1080/10717544.2023.2180113
- Michelle L. Mellion, Lucienne Ronco, Cecile L. Berends, **Lisa Pagan**, Sander Brooks, Michiel J. van Esdonk, Emilie M. J. van Brummelen, Adefowope Oduyungbo, Lorin A. Thompson, Michelle A. Badrising, Shane Raines, William G. Tracewell, Baziel van Engelen, Diego Cadavid and Geert J Groeneveld. *Phase 1 clinical trial of losmapimod in facioscapulohumeral dystrophy: Safety, tolerability, pharmacokinetics, and target engagement*. British Journal of Clinical Pharmacology. 2021. doi:10.1111/bcp.14884
- Cécile L. Berends, **Lisa Pagan**, Michiel J. van Esdonk, Naomi B. Klarenbeek, Kirsten R. Bergmann, Matthijs Moerland, Vincent van der Wel, Saco J. de Visser, Hans Büller, Frans de Loos, Wouter S. de Vries, Hans Waals, Leo G. J. de Leede, Jacobus Burggraaf and Ingrid M. C. Kamerling. *A novel sustained-release cysteamine bitartrate formulation for the treatment of cystinosis: Pharmacokinetics and safety in healthy male volunteers*. Pharmacology Research & Perspectives. 2021. doi:10.1002/prp2.739
- Melanie Rijsbergen, Rianne Rijneveld, Marina Todd, **Lisa Pagan**, Gary Feiss, Maurits N. C. de Koning, Dirk C. J. G. van Alewijk, Erica S. Klaassen, Jacobus Burggraaf, Robert Rissmann and Mariette I. E. van Poelgeest. *No effect of topical digoxin and furosemide gel for patients with external anogenital warts*. Journal of the European Academy of Dermatology and Venereology. 2020. doi:10.1111/jdv.15894
- Sanne W. ten Broeke, Fadwa A. Elsayed, **Lisa Pagan**, Maran J. W. Olderode-Berends, Encarna Gomez Garcia, Hans J. P. Gille, Liselot P. van Hest, Tom G. W. Letteboer, Lizet E. van der Kolk, Arjen R. Mensenkamp, Theo A. van Os, Liesbeth Spruijt, Bert J. W. Redeker, Manon Suerink, Yvonne J. Vos, Anja Wagner, Juul T. Wijnen, E. W. Steyerberg, Carli M. J. Tops, Tom van Wezel and Maartje Nielsen. *SNP association study in PMS2-associated Lynch syndrome*. Familial Cancer. 2018. doi:10.1007/s10689-017-0061-3

\*Primary authors

