



**Universiteit  
Leiden**  
The Netherlands

## **Which inflamed tissues explain a positive metatarsophalangeal squeeze test? A large imaging study to clarify a common diagnostic procedure**

Dijk, B.T. van; Dakkak, Y.J.; Krijbolder, D.K.; Zeben, D. van; Tchetverikov, I.; Reijnierse, M.; Helm-van Mil, A.H.M. van der

### **Citation**

Dijk, B. T. van, Dakkak, Y. J., Krijbolder, D. K., Zeben, D. van, Tchetverikov, I., Reijnierse, M., & Helm-van Mil, A. H. M. van der. (2022). Which inflamed tissues explain a positive metatarsophalangeal squeeze test?: A large imaging study to clarify a common diagnostic procedure. *Rheumatology*, 61(10), 4107-4112. doi:10.1093/rheumatology/keac019

Version: Publisher's Version

License: [Creative Commons CC BY-NC 4.0 license](https://creativecommons.org/licenses/by-nc/4.0/)

Downloaded from: <https://hdl.handle.net/1887/3458807>

**Note:** To cite this publication please use the final published version (if applicable).

## Concise report

# Which inflamed tissues explain a positive metatarsophalangeal squeeze test? A large imaging study to clarify a common diagnostic procedure

Bastiaan T. van Dijk <sup>1</sup>, Yousra J. Dakkak <sup>1</sup>, Doortje I. Krijbolder<sup>1</sup>, D. (Jendé) van Zeben<sup>2</sup>, Ilja Tchetverikov<sup>3</sup>, Monique Reijnierse<sup>4</sup> and Annette H.M. van der Helm-van Mil<sup>1,5</sup>

## Abstract

**Objectives.** The squeeze test of MTP joints is frequently used because it is easy and cheap. It is traditionally perceived as a test for synovitis. Besides classic intra-articular synovitis, also tenosynovitis and intermetatarsal bursitis (IMB) represent synovial inflammation, albeit juxta-articularly located. Both are frequently present in RA and occasionally in other arthritides. Therefore we hypothesized that tenosynovitis and IMB contribute to a positive MTP squeeze test.

**Methods.** A cross-sectional study design was used. A total of 192 early arthritis patients and 693 clinically suspect arthralgia patients underwent the MTP squeeze test and forefoot MRI at first presentation. MRI measurements in age-matched healthy controls were used to define positivity for synovitis, tenosynovitis and IMB. Logistic regression was used.

**Results.** In early arthritis patients, synovitis [odds ratio (OR) 4.8 (95% CI 2.5, 9.5)], tenosynovitis [2.4 (1.2, 4.7)] and IMB [1.7 (1.2, 2.6)] associated with MTP squeeze test positivity. Synovitis [OR 3.2 (95% CI 1.4, 7.2)] and IMB [3.9 (1.7, 8.8)] remained associated in multivariable analyses. Of patients with a positive MTP squeeze test, 79% had synovitis or IMB: 12% synovitis, 15% IMB and 52% both synovitis and IMB. In clinically suspect arthralgia patients, subclinical synovitis [OR 3.0 (95% CI 2.0, 4.7)], tenosynovitis [2.7 (1.6, 4.6)] and IMB [1.7 (1.2, 2.6)] associated with MTP squeeze test positivity, with the strongest association for synovitis in multivariable analysis. Of positive MTP squeeze tests, 39% had synovitis or IMB (10% synovitis, 15% IMB and 13% both synovitis and IMB).

**Conclusion.** Besides synovitis, IMB contributes to pain upon compression in early arthritis, presumably due to its location between MTP joints. This is the first evidence showing that MTP squeeze test positivity is not only explained by intra- but also juxta-articular inflammation.

**Key words:** squeeze test, MTP, intermetatarsal bursitis, tenosynovitis, synovitis, imaging, arthritis, arthralgia

## Rheumatology key messages

- Juxta-articular synovial inflammation (tenosynovitis, intermetatarsal bursitis) is frequently present in RA and occasionally other arthritides.
- MTP squeeze test positivity in early arthritis is explained by not only intra-articular synovitis, but also intermetatarsal bursitis.
- Clinicians may consider that the MTP squeeze test not only tests for intra-articular but also juxta-articular inflammation.

<sup>1</sup>Department of Rheumatology, Leiden University Medical Centre, Leiden, <sup>2</sup>Department of Rheumatology, Franciscus Gasthuis, Rotterdam, <sup>3</sup>Department of Rheumatology, Albert Schweitzer Hospital, Dordrecht, <sup>4</sup>Department of Radiology, Leiden University Medical Centre, Leiden and <sup>5</sup>Department of Rheumatology, Erasmus Medical Centre, Rotterdam, The Netherlands

Submitted 15 November 2021; accepted 21 December 2021

Correspondence to: B.T. van Dijk, Department of Rheumatology, Leiden University Medical Centre, P.O. Box 9600, 2300 RC Leiden, The Netherlands. E-mail: B.T.van\_Dijk@lumc.nl

## Introduction

The squeeze test of MCP and MTP joints is frequently used in clinical practice to assist in the diagnosis of arthritis and disease monitoring since it is easy, cheap and time efficient: it consists of simply tangentially compressing the MCP or MTP joints and is positive when this is unduly painful [1–5].

For proper interpretation of diagnostic tests, it is essential to know what causes positive results. Traditionally, a positive squeeze test is interpreted as a sign of synovitis at compressed joints. Previous imaging studies in early arthritis and arthralgia patients demonstrated an association with synovitis [6–8]. However, recent imaging studies have demonstrated that, besides intra-articular synovitis, juxta-articular synovitis also occurs in two forms in the forefoot: intermetatarsal bursitis (IMB), which represents inflammation of the synovium-lined intermetatarsal bursae, and tenosynovitis, which represents inflammation of the sheaths around flexor/extensor tendons in the small joints [9–11]. IMB and tenosynovitis are strongly associated with RA and occasionally present in other arthritides [9]. While the contribution of local inflammation at MCP joints to squeeze test positivity was studied extensively, the contribution of IMB to MTP squeeze test positivity is unknown and the contribution of tenosynovitis has been only partially studied [7].

Thus our comprehension of the frequently used MTP squeeze test requires updating. We hypothesized that IMB and tenosynovitis contribute to MTP squeeze test positivity. A large MRI study in early arthritis and clinically suspect arthralgia (CSA) patients was performed to assess this.

## Methods

### Patients

We studied 192 early arthritis patients from the Leiden Early Arthritis Clinic (EAC) cohort, which enrolls patients with clinically apparent early arthritis (symptom duration <2 years, RA as well as other arthritides). Second, 567 CSA patients from the Leiden CSA cohort were studied, which concerns patients presenting with recent-onset (<1 year) arthralgia of small joints with increased risk of RA development according to the clinical expertise of their rheumatologist. In addition, we studied 126 CSA patients at baseline participating in the TREAT Early Arthralgia to Reverse or Limit Impending Exacerbation to Rheumatoid arthritis (TREAT EARLIER) trial, a randomized controlled trial testing whether methotrexate prevents progression to clinical arthritis in CSA patients with subclinical MRI inflammation (synovitis, tenosynovitis and/or osteitis).

All three cohorts were described previously [12–14]. Importantly, CSA excludes patients with clinically apparent arthritis or in whom another cause of arthralgia (e.g. osteoarthritis, fibromyalgia) was more likely. Patients were included regardless of autoantibody status. We

consecutively included all patients who underwent forefoot MRI and the MTP squeeze test ([Supplementary Data S1](#), available at *Rheumatology* online, presents details on inclusion, including a flowchart).

### Ethics

The study was conducted in compliance with the Declaration of Helsinki. All patients provided written informed consent. Study protocols for the EAC cohort (B19.008), CSA cohort (P11.210) and TREAT EARLIER trial (P14.296) were approved by the medical ethical committee of the Leiden University Medical Centre. In addition, ethical approval of the TREAT EARLIER trial was obtained from the Central Committee of Research Involving Human Subjects (NL51205.058.14).

### Squeeze test

The MTP squeeze test was performed in each cohort at baseline, which was positive when compression of the MTP joints was unduly painful. Assessors were blinded for MRI scores, providing unbiased outcome assessments.

### MRI scanning and scoring

Contrast-enhanced 1.5T MRI was performed on the MTP joints on the side with the greatest symptoms, or the dominant side when symptom severity was symmetrical. Details on MRI scanning and scoring are presented in [Supplementary Data S2](#), available at *Rheumatology* online. In short, IMB was considered present in case of bursal contrast enhancement in the superior intermetatarsal space (with or without rim enhancement) on two or more consecutive slices in the axial and coronal plane, as described previously [10]. At each intermetatarsal space, IMB presence and its dorsoplantar dimension (in millimetres) were recorded. In addition, MRIs were evaluated for synovitis and tenosynovitis in line with the RA MRI scoring system [15].

Inter- and intrareader reliability [intraclass correlation coefficient (ICC)  $\geq 0.85$  for IMB,  $\geq 0.84$  for tenosynovitis,  $\geq 0.90$  for synovitis] were published previously [10, 15]. MRI readers were blinded for clinical data.

To prevent false positivity, positivity for MRI features was defined using healthy controls as a reference [16, 17]. IMB, synovitis or tenosynovitis were deemed present only if scored in a severity that was present at the same location in <5% of age-matched healthy controls. Reference scores were acquired previously from 193 healthy controls who were scanned using the same MRI machine and scan protocol [18].

### Statistical analyses

Logistic regression assessed associations of IMB, tenosynovitis and synovitis with MTP squeeze test positivity. Multivariable logistic regression models adjusted for sex and simultaneous presence of inflammation features by entering IMB, synovitis and tenosynovitis presence at the MTP joints as separate independent variables.

Nagelkerke's  $R^2$  was used to assess the explained variance in MTP squeeze test positivity.

SPSS (version 25; IBM, Armonk, NY, USA) was used. Two-sided  $P$ -values  $<0.05$  were considered statistically significant.

## Results

### Patients

A total of 192 early arthritis and 693 CSA patients were studied. The MTP squeeze test was positive in 27% of early arthritis patients and 29% of CSA patients. Patient characteristics are presented in [Supplementary Table S1](#), available at *Rheumatology* online.

### Early arthritis patients

In early arthritis patients, synovitis [odds ratio (OR) 4.8 (95% CI 2.5, 9.5)], tenosynovitis [2.4 (1.2, 4.7)] and IMB [1.7 (1.2, 2.6)] on MRI associated with MTP squeeze test positivity ([Supplementary Table S2](#), available at *Rheumatology* online). Synovitis [OR 3.2 (95% CI 1.4, 7.2)] and IMB [3.9 (1.7, 8.8)] remained independently associated with MTP squeeze test positivity in multivariable analyses adjusted for sex and simultaneous presence of MRI features. Tenosynovitis was not independently associated with MTP squeeze test positivity [OR 0.8 (95% CI 0.3, 1.8)]. Although we did not anticipate that osteitis would contribute to a positive MTP squeeze test, the multivariable analyses were repeated, including osteitis as well. This showed similar results for synovitis, IMB and tenosynovitis and no significant association for osteitis.

Next we assessed the increase in explained variance of MTP squeeze test positivity by including IMB in the multivariable model. Nagelkerke's  $R^2$  value of the model including synovitis was 19%, which increased statistically significantly to 26% when IMB was added to the model ( $P=0.001$  by likelihood ratio test).

To visualize how often IMB and synovitis underlie a positive MTP squeeze test, frequencies of both features separately and their simultaneous presence were plotted and compared with the situation wherein only synovitis would be considered explanatory for positivity of the MTP squeeze test ([Fig. 1A](#)). Of early arthritis patients with a positive MTP squeeze test, 63% had MRI detected synovitis (irrespective of IMB). Of these, 52% comprised synovitis combined with IMB. Additionally, 15% had IMB without synovitis, while 21% of early arthritis patients with a positive MTP squeeze test did not have synovitis or IMB. Test characteristics with MRI-detected local inflammation as the outcome are presented in [Supplementary Table S3](#), available at *Rheumatology* online.

### CSA patients

In CSA patients, synovitis [OR 3.0 (95% CI 2.0, 4.7)], tenosynovitis [2.7 (1.6, 4.6)] and IMB [1.7 (1.2, 2.6)] on MRI associated with MTP squeeze test positivity

([Supplementary Table S2](#), available at *Rheumatology* online). In multivariable analyses, synovitis remained independently associated [OR 2.5 (95% CI 1.5, 4.1)] while tenosynovitis [1.5 (0.8, 2.9)] and IMB did not [1.2 (0.8, 1.8)]. Also, when osteitis was added to the model, it was not associated with a positive MTP squeeze test and results for synovitis, IMB and tenosynovitis were similar. Of CSA patients with a positive MTP squeeze test, 24% had synovitis on MRI ([Fig. 1B](#)). Of these, 13% also had IMB. Additionally, 15% had IMB without synovitis, while 61% of early arthritis patients with a positive MTP squeeze test did not have synovitis or IMB.

Examples of the MTP squeeze test and MRI-detected IMB, synovitis and tenosynovitis are presented in [Fig. 2](#).

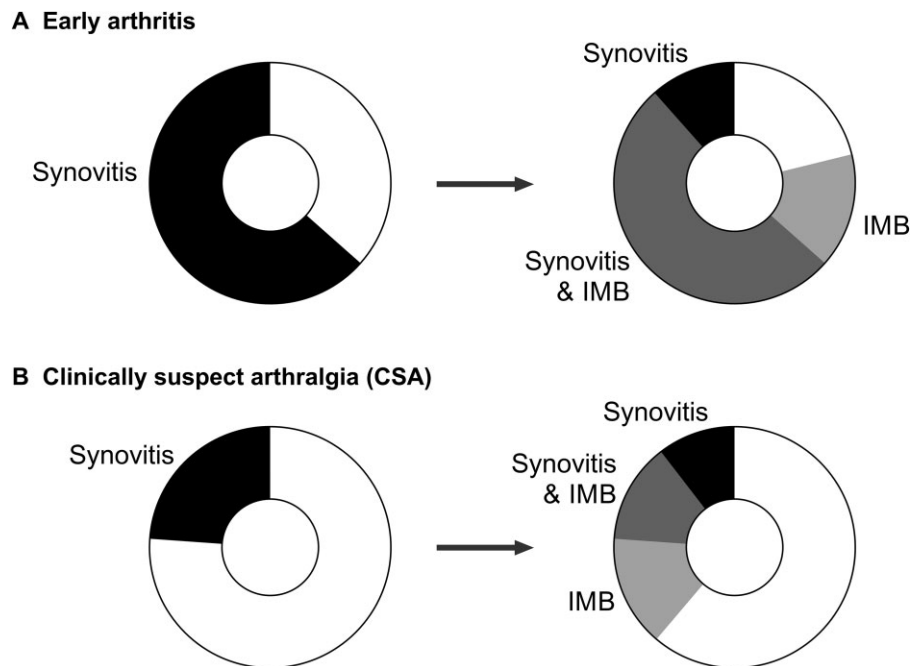
## Discussion

The MTP squeeze test is regularly used to test for synovitis. However, recent imaging studies have demonstrated that not only intra-articular synovitis, but also juxta-articular synovial inflammation (IMB and tenosynovitis) is frequently present in the forefeet in RA and occasionally in other arthritides [9, 11]. We hypothesized that IMB and tenosynovitis contribute to MTP squeeze test positivity. Our study showed that not only synovitis, but also IMB associated independently with MTP squeeze test positivity in early arthritis. This is the first evidence that MTP squeeze test positivity is not only explained by intra-, but also juxta-articular synovial inflammation.

Presumably IMB contributes to MTP squeeze test positivity because of its location between the MTP joints. Thus when performing the MTP squeeze test, clinicians should realize that they are not only testing for intra-articular synovitis, but also for IMB, which is a form of juxta-articular synovial inflammation with high specificity for RA [9]. In patients with CSA, IMB is associated with future RA development [17]. Although the squeeze test alone may not be sufficient in detecting or excluding arthritis of the MTP joints, our findings expand the scientific basis for its use as a complementary diagnostic tool as part of the total clinical evaluation of patients with suspected early arthritis.

Our findings also add to mounting evidence that juxta-articular inflammation contributes to typical symptoms and signs of arthritis, in addition to intra-articular inflammation [10, 11]. Previous research showed that IMB may co-occur with higher frequencies with other imaging-depicted inflamed tissues in the forefoot and that it associates with systemic measures of inflammation and disease activity and with functional limitations [9, 10, 17, 19, 20]. Moreover, MRI-detected IMB and tenosynovitis contribute to joint tenderness and joint swelling in early arthritis, independent from other forefoot inflammation, while this association was not found for synovitis. Together with current findings, this implies that the clinical picture of early arthritis depends not only on intra-articular, but also juxta-articular synovial inflammation.

**Fig. 1** Presence of synovitis, IMB and simultaneous presence of synovitis and IMB in patients with a positive MTP squeeze test



Left: the situation wherein only synovitis is considered to explain test positivity. Right: the situation wherein, in addition to synovitis, IMB is considered to explain test positivity. The total surface of each chart represents all MTP squeeze test-positive patients. Shaded areas represent patients in whom local inflammation was detected on forefoot MRI. Blank areas represent patients in whom test positivity is unexplained by MRI-detected inflammation.

**(A)** Early arthritis. Percentages: left; synovitis 63%, right; synovitis 12%, synovitis and IMB 52%, IMB 15%.  
**(B)** CSA. Percentages: left; synovitis 24%, right; synovitis 10%, synovitis and IMB 13%, IMB 15%.

While in multivariable analyses synovitis contributed to MTP squeeze test positivity in both early arthritis and CSA patients, IMB contributed only in early arthritis and not in CSA patients. This finding, which is in line with a previous study showing that synovitis is the most important contributor to local joint tenderness in CSA [21], may relate to the fact that most CSA patients do not develop clinical arthritis (the percentage of progression is roughly 20%). Additionally, MRI-detected subclinical inflammation is less prevalent in the phase of CSA than in early arthritis. Likewise, IMB presence was 21% in CSA patients and 38% in early arthritis patients. Possibly IMB severity may increase during development of arthritis and does not yet reach the threshold of inducing compression pain in some CSA patients.

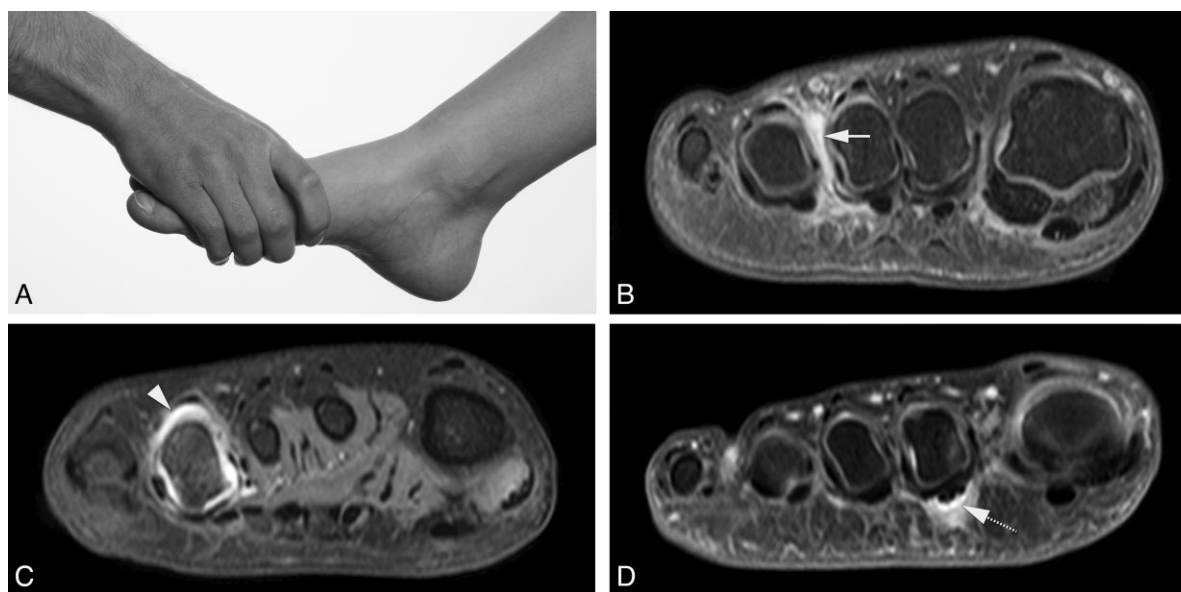
In line with the complexity of forefoot anatomy, additional anatomical structures may be involved in MTP squeeze test positivity. Morton's neuroma co-occurring with IMB may have contributed to MTP squeeze test positivity. Both features can be imaged using contrast-enhanced MRI, but IMB associates with RA more strongly and has a higher sensitivity for RA and for other arthritides. Smaller Morton's neuromas may be difficult to discern from IMB [9]. Therefore the current study focussed on IMB and Morton's neuroma was not assessed separately. However, to prevent interference of Morton's

neuroma with IMB measurements, any plantar protrusion from the bursa that exceeded the deep transverse metatarsal ligament (the location of the plantar nerve, from which Morton's neuromas originate) was not included in IMB measurements, as reported previously [9, 10].

There were some limitations. First, deviations of forefoot bones (e.g. hallux valgus and hammer toes) were not specifically accounted for, as no weight-bearing radiographs were available. Second, validated scoring methods for IMB are non-existent. Therefore IMB was scored using an approach that was developed locally in collaboration with a musculoskeletal radiologist with >20 years of experience [9, 10]. Reliability measures were reassuring (inter- and intrareader ICCs  $\geq 0.85$ ; [Supplementary data S2](#), available at *Rheumatology* online). Strengths of our study include the large sample size and the adjustment of MRI findings for normal variations.

In conclusion, this large cross-sectional MRI study in early arthritis and CSA patients examined the contribution of IMB and tenosynovitis to positivity of the MTP squeeze test. Although traditionally assumed to screen for synovitis, we demonstrated that IMB contributes to positivity of the test in early arthritis patients. These findings may enhance our understanding of this frequently used procedure among clinicians. Moreover, these data show that besides intra-articular synovial inflammation,

**Fig. 2** Example images of the execution of the MTP squeeze test and of IMB, synovitis and tenosynovitis on forefoot MRI



(A) The MTP squeeze test was performed as described previously by van den Bosch *et al.* [6]. The assessor places his/her thumb and fingers laterally and medially on the patient's forefoot, at the level of the MTP joints, and applies a compressive force equivalent to a firm handshake. (B–D) Axial T1-weighted gadolinium post-contrast MRIs at the level of the metatarsal heads. (B) Contrast enhancement of the bursa between the third and fourth metatarsals is present, consistent with IMB (arrow). (C) Contrast enhancement of the synovium lining the fourth MTP joint is present, consistent with synovitis (arrowhead). (D) Contrast enhancement is present around the flexor tendon at the second MTP joint, consistent with tenosynovitis (dotted arrow).

juxta-articular synovial inflammation also contributes to the clinical picture and diagnostics of early arthritis and RA.

### Acknowledgements

We thank G. Kracht (medical photographer) for preparing Fig. 2.

**Funding:** This work was supported by the European Research Council under the European Union's Horizon 2020 research and innovation programme (starting grant, agreement no. 714312) and by the Dutch Arthritis Society.

**Disclosure statement:** The authors have declared no conflicts of interest.

### Data availability statement

Data are available from the corresponding author upon reasonable request.

### Supplementary data

Supplementary data are available at *Rheumatology* online.

### References

- Emery P, Breedveld FC, Dougados M *et al.* Early referral recommendation for newly diagnosed rheumatoid arthritis: evidence based development of a clinical guide. *Ann Rheum Dis* 2002;61:290–7.
- Visser H, le Cessie S, Vos K, Breedveld FC, Hazes JM. How to diagnose rheumatoid arthritis early: a prediction model for persistent (erosive) arthritis. *Arthritis Rheum* 2002;46:357–65.
- Visser H. Early diagnosis of rheumatoid arthritis. *Best Pract Res Clin Rheumatol* 2005;19:55–72.
- Wiesinger T, Smolen JS, Aletaha D, Stamm T. Compression test (Gaenslen's squeeze test) positivity, joint tenderness, and disease activity in patients with rheumatoid arthritis. *Arthritis Care Res (Hoboken)* 2013; 65:653–7.
- de Jong PH, Weel AE, de Man YA *et al.* Brief report: to squeeze or not to squeeze, that is the question! Optimizing the Disease Activity Score in 28 joints by adding the squeeze test of metatarsophalangeal joints in early rheumatoid arthritis. *Arthritis Rheum* 2012;64: 3095–101.
- van den Bosch WB, Mangnus L, Reijniere M, Huizinga TWJ, van der Helm-van Mil AHM. The diagnostic accuracy of the squeeze test to identify arthritis: a cross-sectional cohort study. *Ann Rheum Dis* 2015; 74:1886–9.

- 7 Wouters F, Niemantsverdriet E, van der Helm-van Mil AHM. The value of the squeeze test for detection of sub-clinical synovitis in patients with arthralgia suspicious for progression to RA. *Rheumatology* 2020;59:3106–8.
- 8 Castañeda Martínez DD, Morales DV, Esquivel Valerio JA *et al.* AB1128 Sensitivity and specificity of the automated squeeze test (Gaenslen's maneuver) for identifying metacarpophalangeal synovitis by magnetic resonance imaging. *Ann Rheum Dis* 2019;78:2027.
- 9 Dakkak YJ, Niemantsverdriet E, van der Helm-van Mil AHM, Reijnierse M. Increased frequency of intermetatarsal and submetatarsal bursitis in early rheumatoid arthritis: a large case-controlled MRI study. *Arthritis Res Ther* 2020;22:277.
- 10 van Dijk BT, Dakkak YJ, Matthijssen XME *et al.* Intermetatarsal bursitis, a novel feature of juxta-articular inflammation in early rheumatoid arthritis that is related to clinical signs: results of a longitudinal MRI-study. *Arthritis Care Res (Hoboken)* 2021;doi: 10.1002/acr.24640.
- 11 Rogier C, Hayer S, van der Helm-van Mil A. Not only synovitis but also tenosynovitis needs to be considered: why it is time to update textbook images of rheumatoid arthritis. *Ann Rheum Dis* 2020;79:546–7.
- 12 de Rooy DPC, van der Linden MPM, Knevel R, Huizinga TWJ, van der Helm-van Mil AHM. Predicting arthritis outcomes—what can be learned from the Leiden Early Arthritis Clinic? *Rheumatology (Oxford)* 2011;50:93–100.
- 13 van Steenberg HW, van Nies JAB, Huizinga TWJ *et al.* Characterising arthralgia in the preclinical phase of rheumatoid arthritis using MRI. *Ann Rheum Dis* 2015;74:1225–32.
- 14 Niemantsverdriet E, Dakkak YJ, Burgers LE *et al.* TREAT Early Arthralgia to Reverse or Limit Impending Exacerbation to Rheumatoid arthritis (TREAT EARLIER): a randomized, double-blind, placebo-controlled clinical trial protocol. *Trials* 2020;21:862.
- 15 Dakkak YJ, Matthijssen XME, van der Heijde D, Reijnierse M, van der Helm-van Mil AH. Reliability of magnetic resonance imaging (MRI) scoring of the metatarsophalangeal joints of the foot according to the Rheumatoid Arthritis MRI score. *J Rheumatol* 2020;47:1165–73.
- 16 Boer AC, Burgers LE, Mangnus L *et al.* Using a reference when defining an abnormal MRI reduces false-positive MRI results—a longitudinal study in two cohorts at risk for rheumatoid arthritis. *Rheumatology (Oxford)* 2017;56:1700–6.
- 17 van Dijk BT, Wouters F, van Mulligen E, Reijnierse M, van der Helm-van Mil AHM. During development of rheumatoid arthritis, intermetatarsal bursitis may occur before clinical joint swelling: a large imaging study in patients with clinically suspect arthralgia. *Rheumatology* 2022;61:2805–14.
- 18 Mangnus L, van Steenberg HW, Reijnierse M, van der Helm-van Mil AHM. Magnetic resonance imaging-detected features of inflammation and erosions in symptom-free persons from the general population. *Arthritis Rheumatol* 2016;68:2593–602.
- 19 Hammer HB, Kvien TK, Terslev L. Intermetatarsal bursitis is frequent in patients with established rheumatoid arthritis and is associated with anti-cyclic citrullinated peptide and rheumatoid factor. *RMD Open* 2019;5:e001076.
- 20 Bowen CJ, Culliford D, Dewbury K *et al.* The clinical importance of ultrasound detectable forefoot bursae in rheumatoid arthritis. *Rheumatology (Oxford)* 2010;49:191–2.
- 21 Burgers LE, Ten Brinck RM, van der Helm-van Mil AHM. Is joint pain in patients with arthralgia suspicious for progression to rheumatoid arthritis explained by subclinical inflammation? A cross-sectional MRI study. *Rheumatology (Oxford)* 2019;58:86–93.