



Universiteit
Leiden
The Netherlands

Feasibility of salvage resection following locoregional failure after chemoradiotherapy and consolidation durvalumab for unresectable stage III non-small cell lung cancer

Dickhoff, C.; Unal, S.; Heineman, D.J.; Winkelman, J.A.; Braun, J.; Bahce, I.; ... ; Dahele, M.

Citation


Dickhoff, C., Unal, S., Heineman, D. J., Winkelman, J. A., Braun, J., Bahce, I., ... Dahele, M. (2023). Feasibility of salvage resection following locoregional failure after chemoradiotherapy and consolidation durvalumab for unresectable stage III non-small cell lung cancer. *Lung Cancer*, 182. doi:10.1016/j.lungcan.2023.107294

Version: Publisher's Version

License: [Creative Commons CC BY 4.0 license](https://creativecommons.org/licenses/by/4.0/)

Downloaded from: <https://hdl.handle.net/1887/3643267>

Note: To cite this publication please use the final published version (if applicable).



Feasibility of salvage resection following locoregional failure after chemoradiotherapy and consolidation durvalumab for unresectable stage III non-small cell lung cancer

C. Dickhoff^{a,e,1,*}, S. Unal^{a,e,1}, D.J. Heineman^{a,e}, J.A. Winkelman^{a,e}, J. Braun^{a,d}, I. Bahce^{b,e}, M. van Dorp^{a,e}, S. Senan^{c,e}, M. Dahele^{c,e}

^a Department of Cardiothoracic Surgery, Amsterdam UMC Location Vrije Universiteit Amsterdam, Boelelaan 1117, Amsterdam, The Netherlands

^b Department of Pulmonary Medicine, Amsterdam UMC Location Vrije Universiteit Amsterdam, Boelelaan 1117, Amsterdam, The Netherlands

^c Department of Radiation Oncology, Amsterdam UMC Location Vrije Universiteit Amsterdam, Boelelaan 1117, Amsterdam, The Netherlands

^d Department of Cardiothoracic Surgery, Leiden University Medical Center, Albinusdreef 2, Leiden, The Netherlands

^e Cancer Center Amsterdam, Cancer Treatment and Quality of Life, Amsterdam, The Netherlands

ARTICLE INFO

Keywords:

Salvage surgery
Non-small cell lung cancer
Locoregional recurrence
Chemoradiotherapy
Immunotherapy

ABSTRACT

Introduction: In patients with unresectable stage III non-small cell lung cancer, high-dose chemoradiotherapy (CRT) followed by consolidation durvalumab improves the 5-year overall survival compared to CRT alone. The feasibility and safety of salvage surgery for such patients who subsequently develop locoregional failure (LRF) is unclear. We evaluated our institutional experience with radical-intent salvage surgery in this patient population. **Materials and methods:** Details of patients undergoing salvage surgery for locoregional failure after CRT and durvalumab were identified from an institutional surgical database. Each patient's case underwent multidisciplinary discussion at initial disease presentation, and again at time of progression. **Results:** Ten patients underwent salvage surgery for LRF after prior concurrent (n = 9) or sequential (n = 1) platinum-based high-dose chemo-radiotherapy followed by durvalumab. Consolidation durvalumab was completed in 4 patients, and discontinued in 6, due to either toxicity or disease progression. Median time between end of radiotherapy to detection of LRF was 19 months (range 6–75). Seven patients underwent a lobectomy, 1 a bilobectomy and 2 patients a pneumonectomy. Postoperative morbidity (Clavien-Dindo grade III–V) and 90-day mortality were 10% and 0%, respectively. Median follow-up after surgery was 7 months (range 1–25) during which 2 patients died (both 9 months post-operatively), one due to distant progression, and one of sepsis/bleeding. Eight patients are alive at 1–23 months post-surgery, with 6 showing no evidence of disease. **Conclusions:** Our results suggest that salvage pulmonary resection can be performed safely in selected patients with LRF following chemoradiotherapy and durvalumab. This radical-intent treatment option merits consideration by multidisciplinary lung tumor boards.

1. Introduction

The PACIFIC trial investigated the effect of adding durvalumab (D), an anti-programmed death ligand 1 (PD-L1) antibody, to concurrent chemoradiotherapy (CRT) in patients with unresectable stage III non-small cell lung cancer (NSCLC), and found a marked improvement in both progression-free survival and overall survival [1]. Based on these results, the PACIFIC treatment scheme has become the standard of care

for patients with unresectable stage III NSCLC. Other investigators have reported 1-year loco-regional failure (LRF) rates of up to 18% with this treatment strategy, which suggests that multidisciplinary tumor boards will more frequently encounter patients who present for salvage therapies [2]. Experiences in the pre-immunotherapy era suggest that highly selected patients with LRF may be candidates for salvage resection [3,4]. Although several studies have reported that surgery can be performed safely after neoadjuvant mono/dual immunotherapy [5,6], or

* Corresponding author at: Department of Cardiothoracic Surgery, Amsterdam University Medical Center, Location VUmc, Cancer Center Amsterdam, de Boelelaan 1117, 1081HV Amsterdam, The Netherlands.

E-mail address: c.dickhoff@amsterdamumc.nl (C. Dickhoff).

¹ Shared first author.

<https://doi.org/10.1016/j.lungcan.2023.107294>

Received 8 February 2023; Received in revised form 5 May 2023; Accepted 8 July 2023

Available online 11 July 2023

0169-5002/© 2023 The Author(s). Published by Elsevier B.V. This is an open access article under the CC BY license (<http://creativecommons.org/licenses/by/4.0/>).

immunotherapy in combination with chemotherapy or radiotherapy [7,8], the role of salvage surgery after prior high dose CRT + D has not yet been adequately defined. We describe our institutional experience with salvage surgery in selected patients with LRF after CRT + D.

2. Materials and methods

This retrospective study was approved by the Institutional Review Board of Amsterdam UMC, location Vrije Universiteit Medical Center. Patients with initially unresectable stage III NSCLC who underwent salvage pulmonary resection for LRF after high-dose CRT and consolidation durvalumab were identified from an institutional surgical database and included in this report. All patients were discussed at a multidisciplinary tumor board (MTB), both at initial disease presentation, and subsequently at time of LRF.

LRF was defined as objective tumor progression after CRT + D, in the area of the primary tumor and/or irradiated regional lymph nodes. Patient and treatment characteristics were extracted from individual patient records, specifically focussing on surgical data and outcome. If required, the referring physician or general practitioner were contacted for missing data.

Staging was performed according to the 8th edition of the TNM classification for lung cancer, and investigations included FDG PET-CT, MRI brain, and mediastinal lymph node sampling when indicated. Patients were considered candidates for salvage resection if (i) their cardiopulmonary fitness permitted surgery, and (ii) when a complete (R0) tumor removal was considered technically feasible and likely. Pathology confirmation of tumor recurrence by transthoracic biopsy or endobronchial ultrasound (EBUS) was preferred before surgery, but absence of a tissue confirmation did not preclude an MTB recommendation for surgery if the clinical suspicion was high. The Clavien-Dindo classification for grading complications after surgery was used to evaluate postoperative morbidity [9]. Follow-up and survival were calculated from the date of salvage surgery to December 29th, 2022.

Post-surgical imaging was typically planned once every 3–4 months in the first two years after surgery, biannually in year 2–5 after surgery, and once yearly thereafter, in accordance with ESMO guidelines [10].

3. Results

From Oct 2020 to Dec 2022, 10 consecutive patients with inoperable stage III NSCLC who had been treated with CRT + D, underwent salvage pulmonary resection for LRF. CT and FDG PET-CT images in all patients

suggested tumor recurrence, with one patient suspected of single level ipsilateral mediastinal nodal involvement. No patients had distant metastases. Patient and treatment characteristics are summarized in Table 1. Median age at start of chemotherapy was 58 years (IQR 55 – 69). Nine patients received concurrent platinum-based chemotherapy with high-dose radiotherapy (median dose 60 Gy, given in 2 Gy fractions, IQR 60 – 66), and one patient received sequential chemotherapy and radiotherapy. Planned consolidation durvalumab was completed in 4 patients; in 6 patients it was stopped because of either tumor progression (n = 1) or adverse events, namely malaise (n = 1), grade III pneumonitis (n = 2), dermatitis (n = 2) and colitis (n = 1). Median time from end of radiotherapy to first detection of LRF was 19 months (range 6–75) (Fig. 1). Preoperative pathological confirmation of disease recurrence in the original primary tumor-bed was obtained in 8 patients. A total of 5 patients underwent mediastinal evaluation by EBUS, which confirmed a single-level mediastinal nodal metastasis in one patient.

At the time of surgery, the median age-adjusted Charlson Comorbidity Index of patients was 4 (range 3–7). Median time between the end of radiotherapy and surgery was 23 months (range 7–77). All patients underwent surgery via posterolateral thoracotomy: 7 patients had a lobectomy (including one arterial sleeve lobectomy), 1 patient an inferior bi-lobectomy and 2 patients a pneumonectomy (Table 2). A pedicled intercostal muscle flap was used to buttress the transected airway in all patients. Median operation time was 225 min (range 126–525), and median blood loss was 225 ml (range 50–4000). Two patients had blood loss > 1000 ml, which in one case resulted from a tear in the central pulmonary artery (patient 5) and in another from a tear in a segmental branch of the pulmonary artery and transected azygos vein (patient 2). Both patients with a blood loss > 1000 ml had dense hilar and perivascular fibrosis. A radical excision was performed in all but one patient, whose pathology specimen revealed a microscopically non-radical (R1) resection based on extra-nodal growth in a peri-bronchial (Naruke station 11) lymph node. In addition, unforeseen N2-disease (Naruke station 9) was identified in a single patient in a node that was not suspicious on pre-operative EBUS.

The median duration of hospital admission was 6.0 days (IQR 6 – 8) and no 90-day postoperative mortality occurred. A single patient developed a COVID-19 infection during the post-surgical period, but recovered uneventfully (Clavien-Dindo Gr I). One patient developed an empyema and a late bronchopleural fistula (Clavien-Dindo Gr IIIb) which required a thoracic fenestration after non-successful attempt at surgical closure (patient 5). This was the only patient requiring an overnight stay in the intensive care unit. All patients received 5 days of

Table 1

Patient, tumor, and treatment characteristics of patients treated with salvage surgery for locoregional failure after chemoradiotherapy and durvalumab for initially unresectable stage III non-small cell lung cancer.

	Year of resection	Sex	Age (index tumor)	cTNM-i	Stage (TNM-8)	Histology	RT-dose (Gy)	Time RT-surg (months)	Cycles durva	Reason stop durva	Attempted PA/PA-proven	Pre-salvage mediastinal evaluation	r-cTNM
1	2020	F	53	TxN2 (N4L)	IIIA	large cell	66	29	25 ^{\dag}	–	+/+	–	T2aN0
2	2021	M	53	T4N0	IIIA	adca	66	24	19 ^{\dag}	dermatitis	+/+	–	T2N0
3	2021	M	64	T4N2	IIIB	scc	60	19	18 ^{\dag}	colitis	+/+	EBUS	T1cN0
4	2021	M	56	T4N1	IIIA	scc	65	22	24 ^{\dag}	–	+/+	EBUS	T1bN2
5	2022	M	56	T2N2 (N4L, 7)	IIIA	scc	66	77	25 ^{\dag}	–	+/+	EBUS	T1bN0
6	2022	M	57	T3N2 (N7)	IIIB	scc	60	7	9 ^{\dag}	progressive disease	+/+	–	T2aN0
7	2022	F	59	T2bN3	IIIC	adca	60	47	4 [#]	pneumonitis dermatitis	+/-	–	T3(mf) N0
8	2022	F	73	T1N2	IIIA	scc	60	17	3 [#]	pneumonitis	+/+	–	T2aN0
9	2022	M	67	T2N2 (N7)	IIIA	scc	60	23	10 [#]	malaise	+/-	EBUS	T3(mf) N0
10	2022	M	74	T4N0	IIIA	scc	55*	18	12 [#]	–	+/+	EBUS	T3N0

* = sequential, \dag = Durvalumab bimonthly (750 mg), # = Durvalumab monthly (1500 mg).

M = male, F = female, c-TNM-i = clinical TNM stage of index tumor, EBUS = endobronchial ultrasound, RT = radiotherapy, PA = pathology, r-cTNM = recurrence-clinical TNM, r-pTNM = recurrence- pathological TNM, Surg = surgery, durva = durvalumab, Gy = Gray.

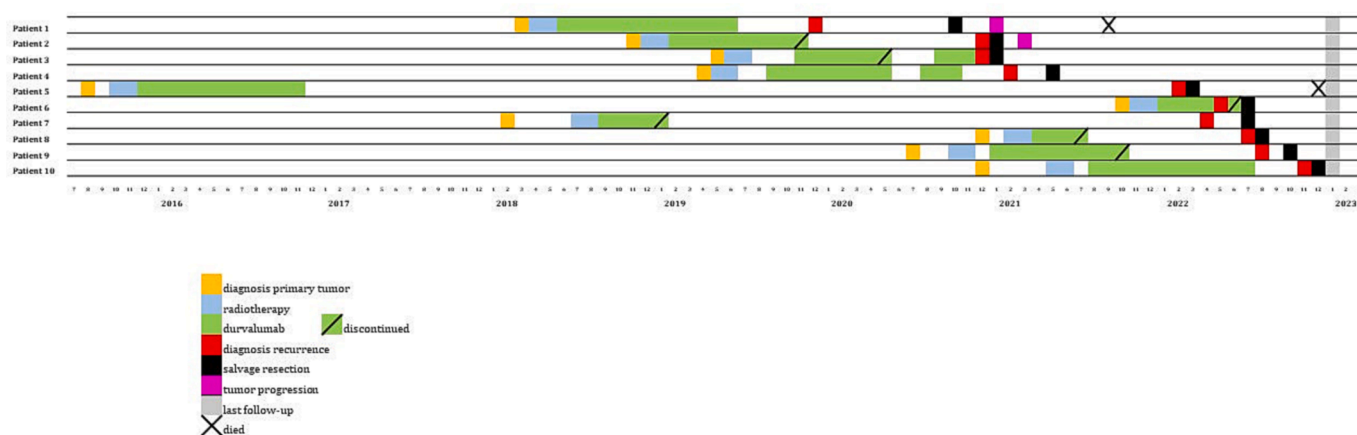


Fig. 1. Timeline of diagnosis, treatment and follow-up of patients with locoregional failure after chemoradiotherapy and durvalumab.

perioperative intravenous antibiotic prophylaxis (Ceftriaxone 2000 mg, once-daily), and aggressive *peri*-operative nutritional support and physiotherapy.

After a median post-operative follow-up of 7 months (range 1–25), 8 patients are alive at 1–23 months after surgery, of which 6 have no evidence of disease, 1 patient has histology proven distant progression, and in 1 patient EBUS failed to prove suspected nodal recurrence on imaging (patient 6 with an R1 resection due to extra-nodal (N1) tumor growth). One patient died from distant disease progression at 9 months postoperatively (patient 1), and another died 9 months after pneumonectomy from subclavian artery bleeding (Clavien-Dindo Gr V) secondary to empyema and bronchopleural fistula with persistent infection of the sternoclavicular joint and surrounding structures (patient 5).

4. Discussion

To the best of our knowledge, this report represents the largest series of patients undergoing a salvage resection for LRF after high dose chemoradiotherapy and consolidation immunotherapy. The results in patients who were initially considered to have unresectable stage III NSCLC show a high rate of complete resection ($R_0 = 90\%$), with acceptable (Gr III-V) morbidity (10%) and no 90-day post-operative mortality. These findings compare favourably with the morbidity and mortality in patients undergoing salvage surgery after high dose chemoradiotherapy alone (29–50% and 4.8–11%, respectively), a finding which may reflect an appropriately selected patient population [3,4]. Extensive hilar/perivascular fibrosis after high dose (chemo)radiotherapy, is largely attributed to the effects of ionizing radiation, augmented by systemic therapy, which causes localized inflammation, characterized by FDG-PET uptake in the first months after radiotherapy, and ultimately leads to impaired vascularity, collagen deposition and scarring [11,12]. This potentially increases the risks of surgery. In addition, a higher rate of tissue fibrosis and inflammation is reported in several studies on surgery after maintenance treatment with immune checkpoint inhibitors without radiotherapy [13,14]. Currently, there is little data on the extent to which the inflammatory effects of chemoradiotherapy and immunotherapy may be exacerbated by combining these modalities. The majority of patients in the present series had only local failure, with just one patient having pre-operatively identified single station N2 disease, and another with a final diagnosis of unforeseen N2 disease.

The long-term findings of the PACIFIC trial [1] are now supported by “real-world” data (PACIFIC-R), even though fewer than 50% of patients complete durvalumab consolidation [3]. The improved distant-metastases free survival after the PACIFIC schedule could lead to an increase in the absolute numbers of patients with LRF. Other studies have reported on the use of salvage surgery for local failure after

immunotherapy for initially unresectable lung cancer [15–17]. Although these authors concluded that salvage lung resection could be performed safely, the patients reported were heterogeneous in terms of initial clinical stage (IIIA-IVB) and their prior therapies (immune therapy only, chemotherapy plus immunotherapy or chemoradiotherapy plus immunotherapy). This present report identifies a subgroup of fitter patients with no or limited mediastinal nodal involvement who may benefit from resection despite having disease that was initially classified as unresectable. Referral of such potentially salvageable patients to expert multidisciplinary teams may result in improved patient outcomes.

We acknowledge the limitation of this small, single-institution, retrospective study, and recognize the need for longer follow-up for salvage surgery after CRT + D in initially unresectable stage III NSCLC, our findings may also reflect outcomes from an academic hospital with interest in performing complex lung cancer surgery, which highlights the importance of discussing similar patients in experienced MTB’s to maximise radical-intent chances for this complex patient group.

5. Conclusion

Selected patients with LRF after undergoing CRT + D for unresectable stage III NSCLC can safely undergo salvage pulmonary resection, which potentially results in long term disease control.

Funding

This research did not receive any funding from agencies in the public, commercial, or not-for-profit sectors.

Disclosures

DH, SU, TW, JB and MvD declare no conflicts of interest. IB reports research grants from AstraZeneca, Bristol Myers Squibb and Boehringer Ingelheim, and participates in the Advisory boards of AstraZeneca, Bristol Myers Squibb and Boehringer Ingelheim. CD reports research grants from AstraZeneca, Bristol Myers Squibb and participates in the advisory boards of AstraZeneca, Bristol Myers Squibb. MD reports grants and honoraria from Varian Medical Systems. SS reports research grants from AstraZeneca, ViewRay Inc and Varian Medical Systems, consulting fees from ViewRay Inc, Astra Zeneca and MSD.

CRedit authorship contribution statement

C. Dickhoff: Conceptualization, Data curation, Formal analysis, Investigation, Methodology, Project administration, Resources, Supervision, Visualization, Writing – original draft, Writing – review &

Table 2
Surgical details and outcome of salvage surgery for locoregional failure after chemoradiotherapy and durvalumab for initially unresectable stage III non-small cell lung cancer.

Patient	CCI	Type of resection*	Operating time (mins)	Dissected LN-stations	Peroperative complication	Blood loss (cc)	90-day post-op complications (Clavien-Dindo Gr III-V)	Reintervention < 30 days	ICU/MCU stay (days)	Hospital stay (days)	r-pTNM	Resection margin	LF/DP	Survival (months)
1	4	LUL-L	159	4,6,7,9,11	-	50	-	-	0	5	T1cN1	R0	DP	9 (dead)
2	4	RUL-L (en-bloc RLL-W)	525	10,11,12	Tear v. azygos and posterior ascending branch PA	1100	-	-	0	6	T1bN0	R0	DP	23 (alive)
3	4	LLL-L	126	5/6,7,9,10,11	-	75	-	-	0	6	T2aN0	R0	-	23 (alive)
4	3	RUL-L	237	3,4,7,10,11	-	100	-	-	0	6	T2aN2	R0	-	19 (alive)
5	3	LP	444	7,9	Tear PA	4000	BPF, sepsis and bleeding (Gr V)	thoracotomy x2	1	80	T2bN0	R0	-	9 (dead)
6	4	ip-RP	245	4,7,9,10	-	500	-	-	0	7	T2bN1	R1*	DP	5 (alive)
7	4	LUL-L (sleeve PA)	213	5/6,7,9,10	-	300	-	-	0	7	T3N0	R0	-	5 (alive)
8	5	RUL-L	232	4,7,9,10,11	-	50	-	-	0	4	T3N0	R0	-	4 (alive)
9	4	RLL-L	298	4,7,9,11,12	-	150	-	-	0	6	T3N2 (N9)	R0	-	2 (alive)
10	7	ip-BL (RML/RLL)	358	7,8,11	-	400	-	-	0	10	T4N0	R0	-	1 (alive)

* = extra nodal.

CCI = Charlson Comorbidity Index, RP = right pneumonectomy, LP = left pneumonectomy, BL = bilobectomy, L = lobectomy, W = wedge resection, ip = intrapericardial resection, ICU = intensive care unit, MCU = medium care unit, R0 = radical resection, R1 = microscopic non-radical resection, PA = pulmonary artery, PD = persistent disease, R = recurrence, r-pTNM = recurrence-pathological TNM, LN = lymph node, LF = local failure, DP = distant progression.

editing. **S. Unal:** Conceptualization, Data curation, Formal analysis, Investigation, Methodology, Resources, Software, Visualization, Writing – original draft. **D.J. Heineman:** Writing – original draft, Writing – review & editing. **J.A. Winkelman:** Data curation, Resources, Writing – original draft. **J. Braun:** Writing – review & editing. **I. Bahce:** Writing – review & editing. **M. van Dorp:** Formal analysis, Methodology, Software, Visualization, Writing – original draft. **S. Senan:** Conceptualization, Writing – review & editing. **M. Dahele:** Conceptualization, Formal analysis, Methodology, Resources, Software, Supervision, Visualization, Writing – original draft, Writing – review & editing.

Declaration of Competing Interest

The authors declare that they have no known competing financial interests or personal relationships that could have appeared to influence the work reported in this paper.

Acknowledgement

None

References

- [1] D.R. Spigel, C. Faivre-Finn, J.E. Gray, D. Vicente, D. Planchard, L. Paz-Ares, J. F. Vansteenkiste, M.C. Garassino, R. Hui, X. Quantin, A. Rimner, Y.-L. Wu, M. Özgüroğlu, K.H. Lee, T. Kato, M. de Wit, T. Kurata, M. Reck, B.C. Cho, S. Senan, J. Naidoo, H. Mann, M. Newton, P. Thiagarajah, S.J. Antonia, Five-year survival outcomes from the PACIFIC trial: durvalumab after chemoradiotherapy in stage III non-small-cell lung cancer, *J. Clin. Oncol.* 40 (12) (2022) 1301–1311.
- [2] M. Offin, N. Shaverdian, A. Rimner, S. Lobaugh, A. Shepherd, C.B. Simone, D. Y. Gelblum, A.-C. Wu, N.Y. Lee, M.G. Kris, C.M. Rudin, Z. Zhang, M.D. Hellmann, J. E. Chaft, D.R. Gomez, Locoregional control, failure patterns and clinical outcomes in patients with stage III non-small cell lung cancers treated with chemoradiation and durvalumab, *J. Clin. Oncol.* 38 (15 suppl) (2020) e21058.
- [3] C. Dickhoff, M. Dahele, M.A. Paul, P.M. van de Ven, A.J. de Langen, S. Senan, E. F. Smit, K.J. Hartemink, Salvage surgery for locoregional recurrence or persistent tumor after high dose chemoradiotherapy for locally advanced non-small cell lung cancer, *Lung Cancer* 94 (2016) 108–113.
- [4] Dickhoff C, Otten RHJ, Heymans MW, et al. Salvage surgery for recurrent or persistent tumour after radical (chemo)radiotherapy for locally advanced non-small cell lung cancer: a systematic review. *Ther. Adv. Med. Oncol.* 2018;10:1-12.
- [5] P.M. Forde, J.E. Chaft, K.N. Smith, V. Anagnostou, T.R. Cottrell, M.D. Hellmann, M. Zahurak, S.C. Yang, D.R. Jones, S. Broderick, R.J. Battafarano, M.J. Velez, N. Rekhtman, Z. Olah, J. Naidoo, K.A. Marrone, F. Verde, H. Guo, J. Zhang, J. X. Caushi, H.Y. Chan, J.-W. Sidhom, R.B. Scharpf, J. White, E. Gabrielson, H. Wang, G.L. Rosner, V. Rusch, J.D. Wolchok, T. Merghoub, J.M. Taube, V.E. Velculescu, S. L. Topalian, J.R. Brahmer, D.M. Pardoll, Neoadjuvant PD-1 blockade in resectable lung cancer, *N. Engl. J. Med.* 378 (21) (2018) 1976–1986.
- [6] B. Sepesi, N. Zhou, W.N. William, H.Y. Lin, C.H. Leung, A. Weissferdt, K. G. Mitchell, A. Pataer, G.L. Walsh, D.C. Rice, J.A. Roth, R.J. Mehran, W. L. Hofstetter, M.B. Antonoff, R. Rajaram, M.V. Negrao, A.S. Tsao, D.L. Gibbons, J. J. Lee, J.V. Heymach, A.A. Vaporciyan, S.G. Swisher, T. Cascone, Surgical outcomes after neoadjuvant nivolumab or nivolumab with ipilimumab in patients with non-small cell lung cancer, *J. Thorac. Cardiovasc. Surg.* 164 (5) (2022) 1327–1337.
- [7] P.M. Forde, J. Spicer, S. Lu, M. Provencio, T. Mitsudomi, M.M. Awad, E. Felip, S. R. Broderick, J.R. Brahmer, S.J. Swanson, K. Kerr, C. Wang, T.-E. Ciuleanu, G. B. Saylor, F. Tanaka, H. Ito, K.-N. Chen, M. Liberman, E.E. Vokes, J.M. Taube, C. Dorange, J. Cai, J. Fiore, A. Jarkowski, D. Balli, M. Sausen, D. Pandya, C. Y. Calvet, N. Girard, Neoadjuvant nivolumab plus chemotherapy in resectable lung cancer, *N. Engl. J. Med.* 386 (21) (2022) 1973–1985.
- [8] N.K. Altorki, T.E. McGraw, A.C. Borczuk, A. Saxena, J.L. Port, B.M. Stiles, B.E. Lee, N.J. Sanfilippo, R.J. Scheff, B.B. Pua, J.F. Gruden, P.J. Christos, C. Spinelli, J. Gakuria, M. Uppal, B. Binder, O. Elemento, K.V. Ballman, S.C. Formenti, Neoadjuvant durvalumab with or without stereotactic body radiotherapy in patients with early-stage non-small-cell lung cancer: a single-centre, randomised phase 2 trial, *Lancet Oncol.* 22 (6) (2021) 824–835.
- [9] D. Dindo, N. Demartines, P.A. Clavien, Classification of surgical complications: a new proposal with evaluation in a cohort of 6336 patients and results of a survey, *Ann. Surg.* 204 (2004) 205–213.
- [10] P.E. Postmus, K.M. Kerr, M. Oudkerk, S. Senan, D.A. Waller, J. Vansteenkiste, C. Escriu, S. Peters, Early and locally advanced non-small cell lung cancer (NSCLC): ESMO Clinical Practice Guidelines for diagnosis, treatment and follow-up, *Ann. Oncol.* 28 (2017) iv1–iv21.
- [11] J.M. Straub, J. New, C.D. Hamilton, C. Lominska, Y. Shnyder, S.M. Thomas, Radiation-induced fibrosis: mechanisms and implications for therapy, *J. Cancer Res. Clin. Oncol.* 141 (11) (2015) 1985–1994.

- [12] M.F. Benveniste, D. Gomez, B.W. Carter, S.L. Betancourt Cuellar, G.S. Shroff, A.P. A. Benveniste, E.G. Odisio, E.M. Marom, Recognizing radiation therapy-related complications in the chest, *Radiographics* 39 (2) (2019) 344–366.
- [13] K. El Hussein, N. Piton, M. De Marchi, A. Grégoire, R. Vion, P. Blavier, L. Thiberville, J.-M. Baste, F. Guisier, Lung cancer surgery after treatment with anti- PD1/PD-L1 immunotherapy for non-small cell lung cancer: a case-cohort study, *Cancers* 13 (19) (2021) 4915.
- [14] M.J. Bott, J. Cools-Lartigue, K.S. Tan, J. Dycoco, M.S. Bains, R.J. Downey, J. Huang, J.M. Isbell, D. Molena, B.J. Park, V.W. Rusch, S. Sihag, D.R. Jones, P. S. Adusumilli, Safety and feasibility of lung resection after immunotherapy for metastatic or unresectable tumors, *Ann. Thor. Surg.* 106 (1) (2018) 178–183.
- [15] T. Ueno, M. Yamashita, N. Yamashita, M. Uomoto, O. Kawamata, Y. Sano, H. Inokawa, S. Hirayama, M. Okazaki, S. Toyooka, Safety of salvage lung resection after immunotherapy for unresectable non-small cell lung cancer, *Gen. Thor. Cardiovasc. Surg.* 70 (9) (2022) 812–817.
- [16] K. Minegishi, H. Tsubochi, K. Ohno, K. Komori, M. Ozeki, S. Endo, Salvage Surgery Post Definitive Chemoradiotherapy and Durvalumab for Lung Cancer, *Ann. Thorac. Surg.* 112 (1) (2021) e53–e55.
- [17] S. Nagata, M. Hamaji, H. Ozasa, Y. Yamada, A. Ohsumi, H. Date, Salvage surgery after immune checkpoint inhibitors for advanced non-small cell lung cancer: potential association between immune-related adverse events and longer survival, *Clin. Lung Cancer* 23 (5) (2022) e321–e324.