



Universiteit
Leiden
The Netherlands

Balanopreputial sac and urine microbiota in patients with male genital lichen sclerosus

Watchorn, R.E.; Munckhof, E.H.A. van den; Quint, K.D.; Dlshtm, J.E.; Koning, M.N.C. de; Quint, W.G.V.; Bunker, C.B.

Citation

Watchorn, R. E., Munckhof, E. H. A. van den, Quint, K. D., Dlshtm, J. E., Koning, M. N. C. de, Quint, W. G. V., & Bunker, C. B. (2020). Balanopreputial sac and urine microbiota in patients with male genital lichen sclerosus. *International Journal Of Dermatology*, 60(2), 201-207. doi:10.1111/ijd.15252

Version: Publisher's Version

License: [Creative Commons CC BY 4.0 license](https://creativecommons.org/licenses/by/4.0/)

Downloaded from: <https://hdl.handle.net/1887/3280191>

Note: To cite this publication please use the final published version (if applicable).

Report

Balanopreputial sac and urine microbiota in patients with male genital lichen sclerosis

Richard E. Watchorn^{1,*}, MD, FRCP, Ellen H. A. van den Munckhof^{2,*}, MSc, Koen D. Quint³, MD, PhD, Joseph Eliahoo⁴, MSc DLSHTM, Maurits N. C. de Koning², PhD, Wim G. V. Quint², PhD and Christopher B. Bunker¹, MA, MD, FRCP

¹Department of Dermatology, University College Hospital, London, UK, ²DDL Diagnostic Laboratory, Rijswijk, Netherlands, ³Department of Dermatology, Leiden University Medical Center, Leiden, Netherlands, and ⁴Statistical Advisory Service, Imperial College London, London, UK

Correspondence

Richard E. Watchorn, MD, FRCP
Department of Dermatology
University College London Hospitals
NHS Foundation Trust
250 Euston Road
London NW1 2PG, UK
E-mail: rwatchorn@gmail.com

*These authors contributed equally to this work.

Conflict of interest: None.

Funding source: None.

doi: 10.1111/ijd.15252

Introduction

Lichen sclerosis (LSc) is a chronic lichenoid inflammatory fibrosing disorder with a predilection for genital skin.^{1,2} Genital (G)LSc can cause substantial dermatological, sexual, and urological morbidity and predisposes to intraepithelial neoplasia and squamous cell carcinoma (SCC).^{1,2} The etiology is disputed.^{1,2} Claims have been advanced for autoimmunity, immunodysregulation, and infective agents.^{1–4} The obligate role of the foreskin in male (M)GLSc is acknowledged; MGLSc is exceptionally rare in those circumcised at birth, and circumcision is usually curative. The exact role of the foreskin is unclear, although occlusion and koebnerization appear relevant. Unlike in women, MGLSc does not affect perianal or perineal skin; the exception to this rule is the observation of peri-urethrostomy LSc in males, indicating a link with urinary exposure. Furthermore, MGLSc is associated with high rates of post-micturition ‘micro-incontinence’.^{2,5} Together, these observations have led

Abstract

Background Male genital lichen sclerosis (MGLSc) is a chronic inflammatory scarring dermatosis associated with penile carcinoma. The prepuce is pivotal in its etiology. Other proposed etiological factors are the subject of dispute and include occluded urinary exposure, autoimmunity, immunodysregulation, and infectious agents.

Objective To determine whether the bacterial microbiota of the balanopreputial sac and urine are associated with MGLSc.

Subjects and methods Twenty uncircumcised patients with MGLSc and 20 healthy uncircumcised males were enrolled in a prospective case-control study. Balanopreputial swabs and urine specimens were subjected to 16S rRNA gene amplicon sequencing.

Results Microbiota analysis indicated differences between the groups. In the balanopreputial sac, the median relative abundance of *Fingoldia* spp. was lower (9% [range 0–60%]) in MGLSc patients than in controls (28% [range 0–62%]). Conversely, the median relative abundance of *Fusobacterium* spp. was higher in MGLSc patients (4% [range 0–41%]) than in controls (0% [range 0–28%]). In the urine, the median relative abundance of *Fingoldia* spp. was comparable between groups, whereas that of *Fusobacterium* spp. was higher in MGLSc patients (0% [range 0–18%] vs. 0% [range 0–5%]). There was a strong association between the microbiota composition of the balanopreputial sac and urine in MGLSc.

Conclusion Dysbiosis could be involved in the etiopathogenesis of MGLSc. Further studies are required to confirm the association suggested herein and to determine its nature.

to the hypothesis that MGLSc arises from occluded exposure of a susceptible epithelium to urine. However, to date, no specific constituent or property of urine nor specific susceptibility factor has been identified.^{2,6,7}

The defining characteristics of the LSc are inflammation, sclerosis, and neoplasia, but the pathogenesis remains poorly defined at a molecular level. It is plausible that a unified pathogenic pathway could account for each of these characteristics.

In recent years, evidence has emerged (i) that variations in the composition of the human microbiota may contribute to the development of many previous pathogenically unexplained chronic inflammatory diseases^{8–10} and (ii) that commensal bacteria can beneficially regulate host immunity, decreasing the risk of infection-induced autoimmune diseases and/or inflammation.¹¹ Conversely, maladaptive alterations in microbiota composition (dysbiosis) may lead to perturbed immune homeostasis and disease.¹¹ In addition, dysbiosis is implicated in fibrotic disease¹² and carcinogenesis.^{8,13}

The ecosystem of the skin is divided into multiple anatomical 'niches' each with a site-specific microbiota.¹⁴ Various inflammatory dermatoses manifest preferentially at certain sites; for example, acne predominantly affects the face, chest, and back,¹⁴ while LSc usually affects the genitalia. It is conceivable that the genital predilection of LSc could reflect site-specific dysbiosis.

Previous studies of the penile microbiota indicate that circumcision dramatically changes its composition, with significant decreases in the abundance of anaerobic bacteria.¹⁵ Anaerobic bacteria in the coronal sulcus of uncircumcised men correlate with the presence of specific inflammatory cytokines,¹⁶ several of which are elevated in LSc.^{17,18}

The microbiota composition of the balanopreputial sac has not been previously investigated in MGLSc. Dysbiosis may account for unresolved questions about the exact nature of the relationship between urine and epithelial susceptibility in MGLSc, and the pathways from lichenoid inflammation to fibrosis and carcinogenesis; hence, this analysis of the microbiota of the balanopreputial sac and urine in MGLSc.

Subjects and methods

Study design

Ethical approval for this prospective case-control study was obtained through the NHS Health Research Authority Research Ethics Service (RES); London – Riverside Research Ethics Committee references 07/H0706/62, amendment number 4.

Twenty uncircumcised adult males with untreated, clinically pathognomonic MGLSc were recruited from the Male Genital Dermatoses Clinic at our institution. The clinical diagnosis of MGLSc was based on a comprehensive history and examination by highly experienced clinicians. Controls were recruited from general dermatology clinics and the Male Genital Dermatoses Clinic. They were uncircumcised, with clinically healthy balanopreputial tissue. No participant was immunocompromised.

From each participant, a swab of the balanopreputial sac (glans and inner prepuce) and a first void urine sample was collected. The swab was obtained by rubbing a sterile cotton swab (Puritan, Guilford, ME, USA) soaked in 1 ml 0.9% NaCl Tween Solution firmly five times across the balanopreputial skin. First-void urine was collected using a Colli-Pee (Novosanis, Wijnegem, Belgium). All samples were stored at -20°C until DNA extraction.

DNA extraction

DNA was extracted from 200 μl samples and eluted in a final volume of 50 μl with the MagNA pure 96 instruments using the MagNA pure 96 DNA and Viral NA small volume kit and the pathogen universal protocol (Roche Diagnostics, Basel, Switzerland).

Quantitative real-time PCR

Quantitative real-time PCR (qPCR) was performed as described elsewhere.¹⁹ Briefly, the total bacterial load of the samples was established by targeting the 16S rRNA gene. Amplification reactions were performed using a LightCycler 480 Instrument (Roche Diagnostics) under the following conditions: 5 minutes at 95°C followed by 45 cycles of 95°C for 10 seconds, 60°C for 15 seconds, and 72°C for 1 second, and a final step of 10 seconds at 40°C . For quantification, a 10-fold dilution series of a plasmid was included in each run, and the second derivative analysis method was used for data analysis. A concentration of $\geq 5.00\text{E}+02$ copies/ μl was considered positive.

Amplicon sequencing of the 16S rRNA gene

Amplicon sequencing of the 16S rRNA gene to determine the microbiota composition was performed as described elsewhere.¹⁹ Briefly, a fragment of approximately 464 bp of the V3-V4 region of the 16S rRNA gene was amplified using the universal primers described by Klindworth *et al.*²⁰ PCR products with a positive agarose gel result were further processed and subsequently sequenced with the MiSeq desktop sequencer (Illumina, San Diego, CA, USA).

Sequencing data were processed following the standard QIIME pipeline. High quality sequences (length >100 bp, quality score >20) were clustered at a 97% similarity level using a pre-clustered version of the Augustus 2013 Greengenes database. Low abundance OTUs (a fraction <0.005 of all sequences) were removed. A sample was considered positive for a specific genus when more than 1% of the sequences were assigned to that genus.

Statistical analysis

The software package SPSS version 26 was used for statistical analysis. For bacterial load, alpha diversity, and relative abundance data, the Mann-Whitney *U* test was employed. For analysis of the prevalence data and assessment of association between urinary and balanopreputial data, Fisher's exact test was performed, only for patients with available microbiota data for both balanopreputial sac and urine.

Results

Population characteristics

Twenty uncircumcised patients with MGLSc and 20 healthy uncircumcised males were enrolled in this study. The MGLSc patients had a median age of 37 years (range 26–73). The control group had a median age of 42 years (range 19–63).

Bacterial load

To determine whether the bacterial load in the balanopreputial sac and urine differed between MGLSc patients and controls, a qPCR targeting the 16S rRNA gene was performed (Supplementary data Figure S1, Table S1). For the balanopreputial

sac, the median bacterial load was 8.20 (range 5.34–9.44) log gene copies/ml for the MGLSc patients and 7.88 (range 5.57–9.24) log 16S rRNA gene copies/ml for the controls. The median bacterial load of the urine was 4.23 (range 0–6.18) log gene copies/ml for the MGLSc patients and 4.26 (range 0.98–7.19) log 16S rRNA gene copies/ml for the controls. No significant difference in bacterial load between both groups in either the balanopreputial sac ($P = 0.758$) or urine ($P = 0.235$) was observed.

Microbiota analysis

To determine the bacterial microbiota composition of the balanopreputial sac and urine, amplicon sequencing of the 16S rRNA gene was performed. For seven MGLSc patients and five controls, the bacterial load of the urine specimen was too low for microbiota analysis. For the remaining specimens, the alpha-diversity, beta-diversity, and microbiota profiles were analyzed.

The median alpha-diversity was 2.61 and 2.17 for the balanopreputial sac of MGLSc patients and the controls, respectively (Fig. 1). For urine, it was 2.38 and 2.33 for MGLSc patients and the controls, respectively. No significant difference was observed between the MGLSc patients and the controls in either the balanopreputial sac ($P = 0.201$) or urine ($P = 1.000$).

Beta-diversity analysis of the balanopreputial sac showed a relatively high variation in microbiota composition between the MGLSc patients and between the controls (Fig. 2a). The microbiota composition of the balanopreputial sac differed between the MGLSc patients and the controls, whereas that of the urine was more comparable between the groups (Fig. 2b).

Analysis of the microbiota profiles of both balanopreputial sac and urine indicated differences between the groups (Fig. 3 and

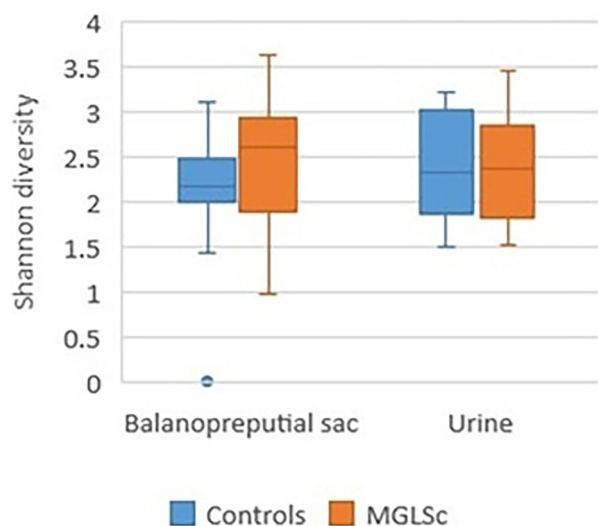


Figure 1 Alpha diversity of swabs of balanopreputial sac and urine of controls and MGLSc patients

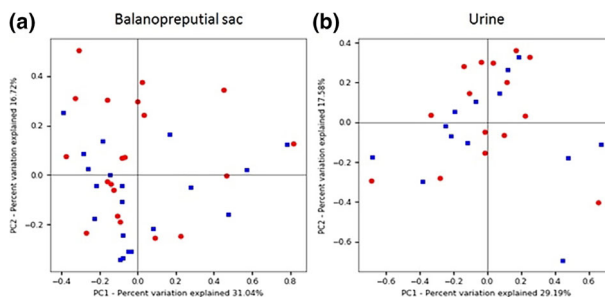


Figure 2 Unifrag weighted PCOA plots of (a) balanopreputial sac and (b) urine of healthy controls and MGLSc patients. The blue squares are the healthy controls, and the red dots are the MGLSc patients

Tables S2 and S3, supplementary data). In the balanopreputial sac, the genus *Finigoldia* was present in 17 (85%) of both the MGLSc patients and controls (Table S4, supplementary data), but the median relative abundance of 9% (range 0–60%) in MGLSc patients was lower than in controls (28%, range 0–62%) (Table S1). Furthermore, the presence and/or relative abundance of the genera *Fusobacterium* and *Prevotella* was higher in patients with MGLSc. *Fusobacterium* spp. was present in 10 (50%) of the patients, while it was detected in three (15%) of the controls; its median relative abundance was higher in MGLSc patients (4% [range 0–41%] vs. 0% [range 0–28%]) (see supplementary Tables S4 and S5 for more details). *Prevotella* was present in 15 (75%) of the patients with MGLSc and 11 (55%) of the controls; its median relative abundance was higher in MGLSc patients (20% [range 0–59%]) than in controls (4% [range 0–51%]).

The microbiota profiles of the urine specimens differed between the participants of both groups and from the skin microbiota (Supplementary Table S5). However, there was an association between the presence of several genera, including *Fusobacterium*, in the balanopreputial sac and urine in patients with MGLSc (Table S6). These data suggest an association between the microbiota of the urine and that of the balanopreputial sac.

Discussion

To our knowledge, this represents the first combined investigation of the composition of the microbiota of both the balanopreputial sac and urine in MGLSc. The presented data suggest that dysbiosis of the balanopreputial sac microbiota could be involved in MGLSc. The relative abundance of *Finigoldia* spp. was decreased in patients with MGLSc, while the relative abundance of *Fusobacterium* spp. was higher in patients with MGLSc. *Fusobacterium* spp. exhibits properties and associations that could be relevant to the defining characteristics of MGLSc.

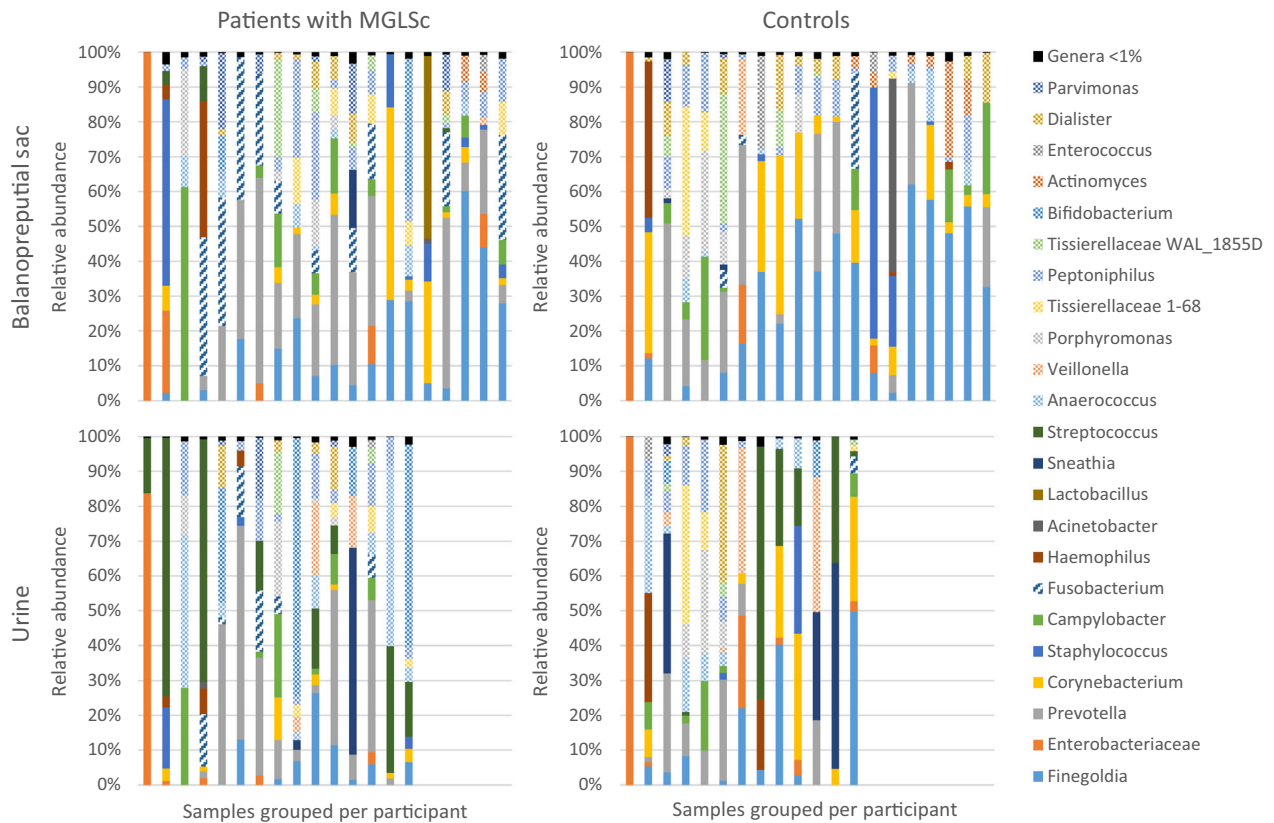


Figure 3 Microbiota composition of the balanopreputial sac and urine in healthy controls and MGLSc at genus level

Recent advances in culture-independent microbial detection technology have shed light on the important role of the genus *Fusobacterium*, in particular *F. nucleatum*, in inflammatory diseases such as periodontitis and inflammatory bowel disease.²¹ *In vitro* and *in vivo* studies of the specific proinflammatory properties of *Fusobacterium* spp. indicate potential relevance in LSc; *F. nucleatum* upregulates the antimicrobial peptides hBD-2 and S100A7 that are also upregulated in LSc.^{22–25} *F. nucleatum* also upregulates several cytokines, including IL-1, IL-4, IL-6, CCL5, CXCL10, CXCL11, and TNF- α that are upregulated in LSc.^{17,18,21–23,26–28}

LSc is a fibrosing disease.¹ The cause of fibrogenesis remains unexplained by previously proposed etiological factors, and the mechanism leading to aberrant fibrogenesis in LSc has not been the focus of specific investigation. Studies in other fibrotic diseases such as systemic sclerosis and idiopathic pulmonary fibrosis implicate perturbations in the Wnt/ β -catenin^{29,30} and mitogen activated protein kinase (MAPK) signaling pathways, including the subfamilies JNK and p38 MAPK.^{31,32} These pathways are involved in regulation of extracellular matrix deposition and degradation and collagen gene expression, and induction of these pathways can cause fibrosis.^{31–35} Whether dysbiosis could play a role in aberrant fibrogenesis in LSc remains unknown.

Several *Fusobacterium* spp. have the capacity to activate the Wnt/ β -catenin and MAPK signaling pathways, including JNK and p38 MAPK.^{36,37} *In vitro* studies of keratinocyte lines have shown that *Fusobacterium* spp., upregulates secretion of matrix metalloproteinases (MMPs), including MMP-1, MMP-2, and MMP-9, in keratinocytes^{23,26,38} that are also upregulated in LSc.^{18,39,40} The pathway of fibrogenesis in LSc, and any involvement of the microbiota therein, require further investigation.

MGLSc and human papillomavirus represent the two main risk factors for penile carcinoma.^{41,42} However, little is known of the molecular mechanisms involved in progression from MGLSc to penile carcinoma, and the role of dysbiosis has not been investigated in this context. The role of dysbiosis in carcinogenesis has been demonstrated in other cancers, including oral squamous cell carcinoma and colorectal carcinoma; studies have highlighted the important role of *F. nucleatum* in particular.^{13,37,43–47} Studies in murine models and *in vitro* studies indicate that *F. nucleatum*-mediated carcinogenesis is affected via upregulation of Wnt/ β -catenin signaling and STAT3 signaling.^{37,43,48} Upregulation of Wnt/ β -catenin signaling is observed in penile carcinoma.⁴⁹ These observations suggest that *Fusobacterium* spp. deserve specific focus in future studies of the link between MGLSc and penile carcinoma.

Circumcision has a dramatic impact on the composition of the penile microbiota, significantly reducing the abundance of anaerobes, particularly *Fusobacterium* spp.^{15,50} The changes in microbiota composition following circumcision could explain the curative and preventative effect of circumcision in MGLSc.

Involvement of the urethra in MGLSc appears to support the etiological role of urine,¹ however, the specific property of urine has not been identified^{1,6}; the strong association identified between the balanopreputial sac and urine microbiota composition may account for the link. While this study represents the only study to date of both the balanopreputial microbiota and urinary microbiota, Cohen *et al.* investigated the urinary microbiota of men with urethral MGLSc and demonstrated a unique microbiota profile in MGLSc compared with controls, with enrichment of the orders *Bacillales*, *Bacteroidales*, and *Pasteurellales*.⁵¹ They did not report any differences in the relative abundance of the order *Fusobacteriales*. The variable findings may relate to methodology in specimen collection; while Cohen *et al.* analyzed midstream urine, first void urine was analyzed herein and was selected on the basis that urethral involvement in MGLSc typically develops distally and progresses proximally.⁵²

Notably, *Borrelia* spp., previously proposed as an etiological factor in MGLSc,² was not identified in any specimen in this study.

The notion that dysbiosis may be involved in the etiopathogenesis of MGLSc is a novel one. This study, with a low number of subjects, is essentially pilot in nature; as such, no firm conclusions can be drawn. Other limitations include the lack of longitudinal data, precluding determination of whether balanopreputial dysbiosis represents the cause or consequence of the disease. The diagnosis of MGLSc was based on clinical features, and histopathology was not sought to confirm the diagnosis. There has been historical discussion regarding the role of biopsy in the diagnosis of LSc; the literature indicates that histology may be nonspecific and falsely negative, and reliance on histology can lead to delayed diagnosis and progression of the disease.^{53,54} For these reasons, histopathology was not sought in this study. Identification of bacteria at the genus level also represents a limitation, since virulence factor expression can vary between species or even strains.⁸ Finally, the clinical phenotype arising from dysbiosis is likely to depend upon factors such as genetic predisposition,⁸ but host factors were not analyzed herein. Further studies with increased numbers of participants are required to confirm the results and investigate the molecular role, if any, that dysbiosis may play in MGLSc.

Conclusion

This study suggests that dysbiosis of the balanopreputial sac microbiota may play a role in the etiopathogenesis of MGLSc. Further studies are required to determine if dysbiosis could form

the 'missing link' between occlusion, urinary exposure, epithelial susceptibility, inflammation, fibrosis, and carcinogenesis.

Acknowledgements

The authors are grateful to Dr. Emily McGrath (Royal Devon & Exeter Hospital) for her early support. This project received funding from the European Academy of Dermatology and Venereology and the Skin Treatment and Research Trust.

References

- Bunker CB, Shim TN. Male genital lichen sclerosus. *Indian J Dermatol* 2015; **60**: 111–117.
- Lewis FM, Tatnall FM, Velangi SS, *et al.* British Association of Dermatologists guidelines for the management of lichen sclerosus, 2018. *Br J Dermatol* 2018; **178**: 839–853.
- Regauer S, Reich O, Beham-Schmid C. Monoclonal gamma-T cell receptor rearrangement in vulvar lichen sclerosus and squamous cell carcinomas. *Am J Pathol* 2002; **160**: 1035–1045.
- Powell JJ, Wojnarowska F. Lichen sclerosus. *Lancet* 2000; **353**: 1777–1783.
- Bunker CB, Patel N, Shim TN. Urinary voiding symptomatology (micro-incontinence) in male genital lichen sclerosus. *Acta Derm Venereol* 2013; **93**: 246–248.
- Edmonds EV, Bunker CB. Nuclear magnetic resonance spectroscopy of urine in male genital lichen sclerosus. *Br J Dermatol* 2010; **163**: 1355–1356.
- Shim TN, Brown SJ, Francis ND, *et al.* Male genital lichen sclerosus and filaggrin. *Clin Exp Dermatol* 2020; **45**: 127–128.
- Grice EA, Segre JA. The human microbiome: our second genome. *Annu Rev Genomics Hum Genet* 2012; **13**: 151–170.
- Zanvit P, Konkel JE, Jiao X, *et al.* Antibiotics in neonatal life increase murine susceptibility to experimental psoriasis. *Nat Commun* 2015; **6**: 8424.
- Szabó K, Erdei L, Bolla BS, *et al.* Factors shaping the composition of the cutaneous microbiota. *Br J Dermatol* 2017; **176**: 344–351.
- Gallo RL, Nakatsuji T. Microbial symbiosis with the innate immune defense system of the skin. *J Invest Dermatol* 2011; **131**: 1974–1980.
- Rieder F. The gut microbiome in intestinal fibrosis: environmental protector or provocateur? *Sci Transl Med* 2013; **5**: 190ps10.
- Sears CL, Garrett WS. Microbes, microbiota, and colon cancer. *Cell Host Microbe* 2014; **15**: 317–328.
- Grice EA, Kong HH, Conlan S, *et al.* Topographical and temporal diversity of the human skin microbiome. *Science* 2009; **324**: 1190–1192.
- Price LB, Liu CM, Johnson KE, *et al.* The effects of circumcision on the penis microbiome. *PLoS One* 2010; **5**: e8422.
- Liu CM, Prodger JL, Tobian AAR, *et al.* Penile anaerobic dysbiosis as a risk factor for HIV infection. *MBio* 2017; **8**: e00996-17.
- Terlou A, Santegoets LA, van der Meijden WI, *et al.* An autoimmune phenotype in vulvar lichen sclerosus and lichen planus: a Th1 response and high levels of microRNA-155. *J Invest Dermatol* 2012; **132**: 658–666.
- Pilatz A, Altinkilic B, Schormann E, *et al.* Congenital phimosis in patients with and without lichen sclerosus: distinct expression

- patterns of tissue remodeling associated genes. *J Urol* 2013; **189**: 268–274.
- 19 van den Munckhof EHA, de Koning MNC, Quint WGV, *et al.* Evaluation of a stepwise approach using microbiota analysis, species-specific qPCRs and culture for the diagnosis of lower respiratory tract infections. *Eur J Clin Microbiol Infect Dis* 2019; **38**: 747–754.
 - 20 Klindworth A, Pruesse E, Schweer T, *et al.* Evaluation of general 16S ribosomal RNA gene PCR primers for classical and next-generation sequencing-based diversity studies. *Nucleic Acids Res* 2013; **41**: e1.
 - 21 Han YW. *Fusobacterium nucleatum*: a commensal-turned pathogen. *Curr Opin Microbiol* 2015; **23**: 141–147.
 - 22 Krisanaprakornkit S, Kimball JR, Weinberg A, *et al.* Inducible expression of human β -defensin 2 by *Fusobacterium nucleatum* in oral epithelial cells: multiple signaling pathways and role of commensal bacteria in innate immunity and the epithelial barrier. *Infect Immun* 2000; **68**: 2907–2915.
 - 23 Yin L, Dale BA. Activation of protective responses in oral epithelial cells by *Fusobacterium nucleatum* and human beta-defensin-2. *J Med Microbiol* 2007; **56**: 976–987.
 - 24 Algermissen B, Sitzmann J, LeMotte P, *et al.* Differential expression of CRABP II, psoriasin, and cytokeratin mRNA in human skin disease. *Arch Dermatol Res* 1996; **288**: 426–430.
 - 25 Gambichler T, Skrygan M, Tigges C, *et al.* Significant upregulation of antimicrobial peptides and proteins in lichen sclerosis. *Br J Dermatol* 2009; **161**: 1136–1142.
 - 26 Gursoy UK, Könönen E, Uitto VJ. Stimulation of epithelial cell matrix metalloproteinase (MMP-2, -9, -13) and interleukin-8 secretion by fusobacteria. *Oral Microbiol Immunol* 2008; **23**: 432–434.
 - 27 Zhang G, Rudney JD. *Streptococcus cristatus* attenuates *Fusobacterium nucleatum*-induced cytokine expression by influencing pathways converging on nuclear factor- κ B. *Mol Oral Microbiol* 2011; **26**: 150–163.
 - 28 Park SR, Kim DJ, Han SH, *et al.* Diverse Toll-like receptors mediate cytokine production by *Fusobacterium nucleatum* and *Aggregatibacter actinomycetemcomitans* in macrophages. *Infect Immun* 2014; **82**: 1914–1920.
 - 29 Chilosi M, Poletti V, Zamò A, *et al.* Aberrant Wnt/ β -catenin pathway activation in idiopathic pulmonary fibrosis. *Am J Pathol* 2003; **162**: 1495–1502.
 - 30 Wei J, Fang F, Lam AP, *et al.* Wnt/ β -catenin signaling is hyperactivated in systemic sclerosis and induces Smad-dependent fibrotic responses in mesenchymal cells. *Arthritis Rheum* 2012; **64**: 2734–2745.
 - 31 Ihn H, Yamane K, Tamaki K. Increased phosphorylation and activation of mitogen-activated protein kinase p38 in scleroderma fibroblasts. *J Invest Dermatol* 2005; **125**: 247–255.
 - 32 Yoshida K, Kuwano K, Hagimoto N, *et al.* MAP kinase activation and apoptosis in lung tissues from patients with idiopathic pulmonary fibrosis. *J Pathol* 2002; **198**: 388–396.
 - 33 Lam AP, Gottardi CJ. β -catenin signaling: a novel mediator of fibrosis and potential therapeutic target. *Curr Opin Rheumatol* 2001; **23**: 562–567.
 - 34 Sato M, Shegogue D, Gore EA, *et al.* Role of p38 MAPK in transforming growth factor beta stimulation of collagen production by scleroderma and healthy dermal fibroblasts. *J Invest Dermatol* 2002; **118**: 704–711.
 - 35 Molkentin JD, Bugg D, Ghearing N, *et al.* Fibroblast-specific genetic manipulation of p38 mitogen-activated protein kinase in vivo reveals its central regulatory role in fibrosis. *Circulation* 2017; **136**: 549–561.
 - 36 Krisanaprakornkit S, Kimball JR, Dale BA. Regulation of human beta-defensin-2 in gingival epithelial cells: the involvement of mitogen-activated protein kinase pathways, but not the NF- κ B transcription factor family. *J Immunol* 2002; **168**: 316–324.
 - 37 Rubinstein MR, Wang X, Liu W, *et al.* *Fusobacterium nucleatum* promotes colorectal carcinogenesis by modulating E-cadherin/ β -catenin signaling via its FadA adhesin. *Cell Host Microbe* 2013; **14**: 195–206.
 - 38 Uitto VJ, Bailey D, Wu Q, *et al.* *Fusobacterium nucleatum* increases collagenase-3 production and migration of epithelial cells. *Infect Immun* 2005; **73**: 1171–1179.
 - 39 de Oliveira GA, de Almeida MP, Soares FA, *et al.* Metalloproteinases 2 and 9 and their tissue inhibitors 1 and 2 are increased in vulvar lichen sclerosis. *Eur J Obstet Gynecol Reprod Biol* 2012; **161**: 96–101.
 - 40 Gambichler T, Skrygan M, Czempel V, *et al.* Differential expression of connective tissue growth factor and extracellular matrix proteins in lichen sclerosis. *J Eur Acad Dermatol Venereol* 2012; **26**: 207–212.
 - 41 Chaux A, Velazquez EF, Amin A, *et al.* Distribution and characterization of subtypes of penile intraepithelial neoplasia and their association with invasive carcinomas: a pathological study of 139 lesions in 121 patients. *Hum Pathol* 2012; **43**: 1020–1027.
 - 42 Olesen TB, Sand FL, Rasmussen CL, *et al.* Prevalence of human papillomavirus DNA and p16INK4a in penile cancer and penile intraepithelial neoplasia: a systematic review and meta-analysis. *Lancet Oncol* 2019; **20**: 145–158.
 - 43 Binder Gallimidi A, Fischman S, Revach B, *et al.* Periodontal pathogens *Porphyromonas gingivalis* and *Fusobacterium nucleatum* promote tumor progression in an oral-specific chemical carcinogenesis model. *Oncotarget* 2015; **6**: 22613–22623.
 - 44 Castellarin M, Warren RL, Freeman JD, *et al.* *Fusobacterium nucleatum* infection is prevalent in human colorectal carcinoma. *Genome Res* 2012; **22**: 299–306.
 - 45 Kostic AD, Gevers D, Pedamallu CS, *et al.* Genomic analysis identifies association of *Fusobacterium* with colorectal carcinoma. *Genome Res* 2012; **22**: 292–298.
 - 46 Al-Hebshi NN, Nasher AT, Maryoud MY, *et al.* Inflammatory bacteriome featuring *Fusobacterium nucleatum* and *Pseudomonas aeruginosa* identified in association with oral squamous cell carcinoma. *Sci Rep* 2017; **7**: 1834.
 - 47 Zhao H, Chu M, Huang Z, *et al.* Variations in oral microbiota associated with oral cancer. *Sci Rep* 2017; **7**: 11773.
 - 48 Chen Y, Peng Y, Yu J, *et al.* Invasive *Fusobacterium nucleatum* activates beta-catenin signaling in colorectal cancer via a TLR4/P-PAK1 cascade. *Oncotarget* 2017; **8**: 31802–31814.
 - 49 Arya M, Thrasivoulou C, Henrique R, *et al.* Targets of Wnt/ β -catenin transcription in penile carcinoma. *PLoS One* 2015; **10**: e0124395.
 - 50 Liu CM, Hungate BA, Tobian AA, *et al.* Male circumcision significantly reduces prevalence and load of genital anaerobic bacteria. *MBio* 2013; **4**: e00076.
 - 51 Cohen AJ, Gaither TW, Srirangapattanam S, *et al.* Synchronous genitourinary lichen sclerosis signals a distinct urinary microbiome profile in men with urethral stricture disease. *World J Urol* 2020. <https://doi.org/10.1007/s00345-020-03198-9>. Online ahead of print.
 - 52 Belsante MJ, Selph JP, Peterson AC. The contemporary management of urethral strictures in men resulting from lichen sclerosis. *Transl Androl Urol* 2015; **4**: 22–28.

- 53 McCarthy S, MacEoin N, O'Driscoll M, *et al.* Should we always biopsy in clinically evident lichen sclerosus? *J Low Genit Tract Dis* 2019; **23**: 182–183.
- 54 Kravvas G, Shim TN, Doiron PR, *et al.* The diagnosis and management of male genital lichen sclerosus: a retrospective review of 301 patients. *J Eur Acad Dermatol Venereol* 2018; **32**: 91–95.

Supporting Information

Additional Supporting Information may be found in the online version of this article:

Fig S1. Bacterial load of balanopreputial sac and urine in healthy controls and MGLSc patients

Table S1. (a) Bacterial load of balanopreputial swabs; (b) Bacterial load of first catch urine.

Table S2. Number of bacterial genera found in each group

Table S3. Bacterial genera found in each of the four groups (balanopreputial sac in healthy controls, balanopreputial sac in MGLSc, urine in healthy controls, urine in MGLSc)

Table S4. Balanopreputial sac: prevalences and median relative abundances of bacteria in healthy controls and MGLSc patients

Table S5. Urine – prevalences and median relative abundances of bacteria of healthy controls and MGLSc patients

Table S6. Association between the balanopreputial sac and urine bacterial microbiota