



**Universiteit
Leiden**
The Netherlands

Incidence of mycosis fungoides and Sezary syndrome in the Netherlands between 2000 and 2020

Ottevanger, R.; deBruin, D.T.; Willemze, R.; Jansen, P.M.; Bekkenk, M.W.; deHaas, E.R.M.; ... ; Quint, K.D.




Citation

Ottevanger, R., DeBruin, D. T., Willemze, R., Jansen, P. M., Bekkenk, M. W., DeHaas, E. R. M., ... Quint, K. D. (2021). Incidence of mycosis fungoides and Sezary syndrome in the Netherlands between 2000 and 2020, *185*(2), 434-435. doi:10.1111/bjd.20048

Version: Publisher's Version
License: [Creative Commons CC BY 4.0 license](#)
Downloaded from: <https://hdl.handle.net/1887/3280186>

Note: To cite this publication please use the final published version (if applicable).

Although further research is required, these findings suggest that *de novo* production of IL-17A through repolarization of the T-cell response may be a driver of psoriasiform eruption in patients with atopic dermatitis treated with dupilumab.

F.N. Mirza , A. Wang, S.M. Ramachandran, W. Damsky  and J.M. Cohen 

Department of Dermatology, Yale School of Medicine, New Haven, CT, USA

Correspondence: J.M. Cohen.

Email: jeffrey.m.cohen@yale.edu

References

- 1 Safa G, Paumier V. Psoriasis induced by dupilumab therapy. *Clin Exp Dermatol* 2019; **44**:e49–e50.
- 2 Simpson EL, Bieber T, Guttman-Yassky E et al. Two phase 3 trials of dupilumab versus placebo in atopic dermatitis. *N Engl J Med* 2016; **375**:2335–48.
- 3 Tracey EH, Elston C, Feasel P et al. Erythrodermic presentation of psoriasis in a patient treated with dupilumab. *JAAD Case Rep* 2018; **4**:708–10.
- 4 Nakamura M, Lee K, Singh R et al. Eczema as an adverse effect of anti-TNF α therapy in psoriasis and other Th1-mediated diseases: a review. *J Dermatolog Treat*. 2017; **28**:237–41.
- 5 Napolitano M, Caiazzo G, Fabbrocini G et al. Increased expression of IL-23A in lesional skin of atopic dermatitis patients with psoriasisiform reaction during dupilumab treatment. *Br J Dermatol* 2021; **184**:341–3.
- 6 Hanifin J, Rajka G. Diagnostic features of atopic dermatitis. *Acta Derm Venereol Suppl* 1980; **92**:44–7.
- 7 McMurray RW, Harisdangkul V. Mycophenolate mofetil: selective T cell inhibition. *Am J Med Sci* 2002; **323**:194–6.

Funding sources: W.D. is supported by a Career Development Award from the Dermatology Foundation.

Conflicts of interest: W.D. has received research funding from Pfizer and is a consultant for Eli Lilly, Twi Biotechnology and Pfizer. W.D. also receives licensing fees from EMD, Sigma and Millipore for work that is not related to this study.

Incidence of mycosis fungoides and Sézary syndrome in the Netherlands between 2000 and 2020

DOI: 10.1111/bjd.20048

DEAR EDITOR, Cutaneous T-cell lymphomas (CTCLs) are a heterogeneous group of non-Hodgkin lymphomas that differ greatly in clinical presentation and prognosis. Mycosis fungoides (MF) is the most frequent subtype of cutaneous lymphomas. Sézary syndrome (SS), characterized by the triad of erythroderma, lymphadenopathy and blood involvement, is less prevalent, and has a much more unfavourable prognosis.¹ Previous studies have shown that the incidence of CTCL has tripled between 1970 and 2000.² However,

studies from the USA and Canada suggest that the incidence since then has stabilized.^{2,3}

In 2000 we described a cohort of 309 patients with MF who were included in the Dutch Cutaneous Lymphoma Registry (DCLR) between October 1985 and May 1997.⁴

However, data on the incidence of MF and SS in the Netherlands have never been published. Given the reported increasing incidence of CTCL, the aim of the present study was to estimate the changes in incidence of newly diagnosed MF and SS in the Netherlands over the last 20 years. Annual incidence rates were retrieved from the DCLR. Between January 2000 and December 2019, 1044 patients with MF, including 238 patients with folliculotropic MF (FMF), and 93 patients with SS were included in the DCLR (Figure 1). In all cases, the diagnosis was based on the clinicopathological criteria of the World Health Organization–European Organisation for Research and Treatment of Cancer classification and confirmed by an expert panel of dermatologists and pathologists at a periodical meeting of the Dutch Cutaneous Lymphoma Working Group.⁵ Referral centres have remained the same throughout the study period and cover all geographical areas in the Netherlands.

A total of 30 patients with MF were diagnosed in the year 2000 and 79 in 2019. This was a 2.6-fold increase in the last two decades, with an average increase of 7.9% (SD 0.222) per year. A 1.9-fold increase was seen between 2000 and 2010. Less increase (1.4-fold) was seen between 2010 and 2019. For patients with SS, two patients were diagnosed in the year 2000 and 13 in 2019. This was a 6.5-fold increase.

Furthermore, we calculated the number of registered patients with MF and SS per 100 000 persons, corrected for the size of the Dutch population as registered by the Central Bureau of Statistics.⁶ In 2000, the corrected number of cases of MF was 0.19 per 100 000 persons, while this was 0.35 per 100 000 in 2010 and 0.46 per 100 000 persons in 2019. This means that a 2.42-fold increase, corrected for Dutch population growth, was seen between 2000 and 2019 for the incidence of MF in the Netherlands. In 2000, 2010 and 2019 the corrected incidences for SS were 0.013, 0.018 and 0.075 per 100 000 persons, respectively. The overall increase was 6.0-fold corrected for the Dutch population between 2000 and 2019.

There was no clinically relevant change in the age of diagnosis in classical MF and FMF between the first decade (2000–2009) and second decade (2010–2019). However, in patients with SS, there was a significant difference in age [years (SD)] of diagnosis in the first and second decade [65.2 (10.1) vs. 71.8 (9.9), $P = 0.004$].

In short, the number of patients with MF and SS registered in the DCLR in the Netherlands has kept increasing annually over the last two decades, in contrast to previous reports from North America where the incidence stabilized over the last 10 years.^{2,3}

Several explanations can be given for the rise in the number of patients with MF and SS in the DCLR. The most

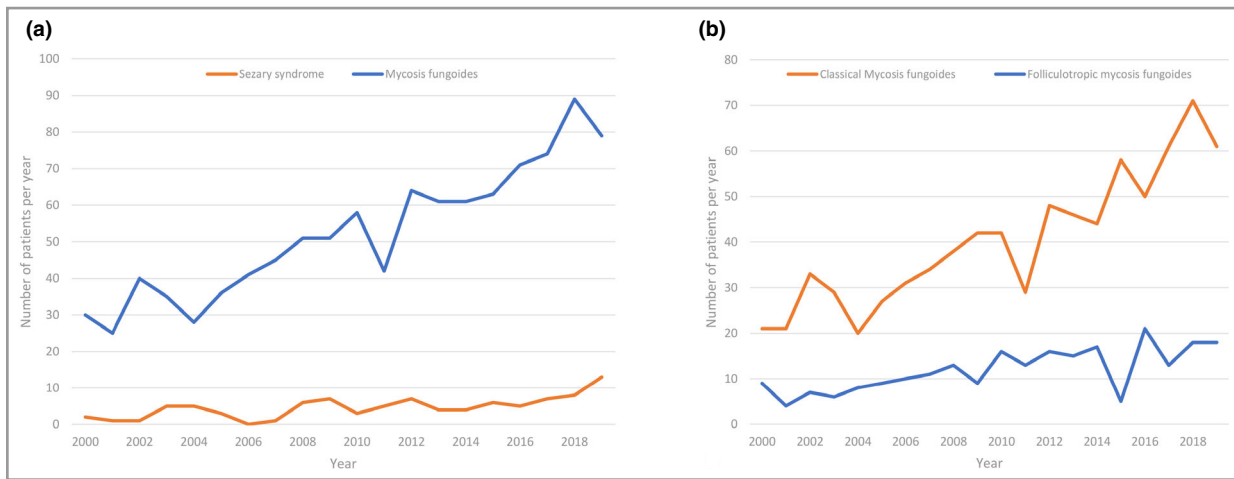










Figure 1 (a) Incidence of mycosis fungoides and Sézary syndrome per year between 2000 and 2020. (b) Incidence of classical mycosis fungoides and folliculotropic mycosis fungoides per year between 2000 and 2020.

likely explanation is that dermatologists and pathologists working outside of academic university hospitals are more aware of the Dutch Cutaneous Lymphoma Working Group resulting in more referrals and more inclusions in the DCLR. The diagnostic criteria of MF and SS have not changed over the last 30 years in the Netherlands and offer no explanation for the increased incidence. A true increase in the incidence of MF and SS cannot be excluded completely, but causative factors are unknown. Ghazawi *et al.* suggest that environmental or industrial exposures contribute to the pathogenesis of CTCL.³ This should be explored in further studies.

In summary, a significant increase of patients with classical MF, FMF and SS included in the DCLR was seen over the past 20 years. In contrast to previous studies that suggest a stabilization since 2000, this study shows that the incidence of patients with MF and SS in the Netherlands increased 2.42-fold over the past two decades. This effect is probably caused by the increased awareness of dermatologists working outside of academic university hospitals.

R. Ottevanger ¹, D.T. deBruin ¹, R. Willemze ¹, P.M. Jansen ², M.W. Bekkenk ³, E.R.M. deHaas,⁴ B. Horvath ⁵, M.M. vanRossum,⁶ C.J.G. Sanders,⁷ J.C.J.M. Veraart,⁸ M.H. Vermeer ¹ and K.D. Quint ¹

Departments of ¹Dermatology; ²Pathology, Leiden University Medical Center, Leiden, the Netherlands; ³Department of Dermatology, Academic Medical Center, Vrije University Medical Center, Amsterdam, the Netherlands; ⁴Department of Dermatology, Erasmus Medical Center, Rotterdam, the Netherlands; ⁵Department of Dermatology, University Medical Center of Groningen, Groningen, the Netherlands; ⁶Department of Dermatology, Radboud University Medical Center, Nijmegen, the Netherlands; ⁷Department of Dermatology, University Medical Center Utrecht, the Netherlands; and ⁸Department of Dermatology, Maastricht University Medical Center, Maastricht, the Netherlands
Email: r.ottevanger@lumc.nl

References

- Prasad A, Rabionet R, Espinet B *et al.* Identification of gene mutations and fusion genes in patients with Sézary syndrome. *J Invest Dermatol* 2016; **136**:1490–9.
- Korgavkar K, Xiong M, Weinstock M. Changing incidence trends of cutaneous T-cell lymphoma. *JAMA Dermatol* 2013; **149**:1295–9.
- Ghazawi FM, Netchiporouk E, Rahme E *et al.* Comprehensive analysis of cutaneous T-cell lymphoma (CTCL) incidence and mortality in Canada reveals changing trends and geographic clustering for this malignancy. *Cancer* 2017; **123**:3550–67.
- van Doorn R, van Haselen CW, van Voorst Vader PC *et al.* Mycosis fungoides: disease evolution and prognosis of 309 Dutch patients. *Arch Dermatol* 2000; **136**:504–10.
- Willemze R, Jaffe ES, Burg G *et al.* WHO-EORTC classification for cutaneous lymphomas. *Blood* 2005; **105**:3768–85.
- Central Bureau of Statistics. Bevolking: Kerncijfers, 12 December 2019. <https://www.cbs.nl/nl-nl/cijfers/detail/37296ned> (accessed 21 October 2020).

Funding sources: this study was made possible by an unrestricted research grant from Kyowa Kirin Pharma BV.

Conflicts of interest: none to declare.

New recommendations for retinal monitoring in hydroxychloroquine users: baseline testing is no longer supported

DOI: 10.1111/bjd.20073

DEAR EDITOR, The Royal College of Ophthalmologists (RCOphth) has published new recommendations for retinal monitoring for hydroxychloroquine and chloroquine users in the UK (2020).¹ The recommendations aim to protect both patients and prescribers by reducing the risk of irreversible visual loss from hydroxychloroquine retinopathy. Importantly,