



**Universiteit
Leiden**
The Netherlands

Quantitative perfusion assessment using indocyanine green during surgery - current applications and recommendations for future use

Hoven, P. van den; Osterkamp, J.; Nerup, N.; Svendsen, M.B.S.; Vahrmeijer, A.; Vorst, J.R. van der; Achiam, M.P.

Citation

Hoven, P. van den, Osterkamp, J., Nerup, N., Svendsen, M. B. S., Vahrmeijer, A., Vorst, J. R. van der, & Achiam, M. P. (2023). Quantitative perfusion assessment using indocyanine green during surgery - current applications and recommendations for future use. *Langenbeck's Archives Of Surgery*, 408(1). doi:10.1007/s00423-023-02780-0

Version: Publisher's Version

License: [Creative Commons CC BY 4.0 license](https://creativecommons.org/licenses/by/4.0/)

Downloaded from: <https://hdl.handle.net/1887/3566975>

Note: To cite this publication please use the final published version (if applicable).



Quantitative perfusion assessment using indocyanine green during surgery — current applications and recommendations for future use

P. Van Den Hoven¹ · J. Osterkamp² · N. Nerup² · M. B. S. Svendsen³ · Alexander Vahrmeijer¹ · J. R. Van Der Vorst¹ · M. P. Achiam²

Received: 29 September 2022 / Accepted: 12 December 2022
© The Author(s) 2023

Abstract

Purpose Incorrect assessment of tissue perfusion carries a significant risk of complications in surgery. The use of near-infrared (NIR) fluorescence imaging with Indocyanine Green (ICG) presents a possible solution. However, only through quantification of the fluorescence signal can an objective and reproducible evaluation of tissue perfusion be obtained. This narrative review aims to provide an overview of the available quantification methods for perfusion assessment using ICG NIR fluorescence imaging and to present an overview of current clinically utilized software implementations.

Methods PubMed was searched for clinical studies on the quantification of ICG NIR fluorescence imaging to assess tissue perfusion. Data on the utilized camera systems and performed methods of quantification were collected.

Results Eleven software programs for quantifying tissue perfusion using ICG NIR fluorescence imaging were identified. Five of the 11 programs have been described in three or more clinical studies, including Flow® 800, ROIs Software, IC Calc, SPY-Q™, and the Quest Research Framework®. In addition, applying normalization to fluorescence intensity analysis was described for two software programs.

Conclusion Several systems or software solutions provide a quantification of ICG fluorescence; however, intraoperative applications are scarce and quantification methods vary abundantly. In the widespread search for reliable quantification of perfusion with ICG NIR fluorescence imaging, standardization of quantification methods and data acquisition is essential.

Keywords Near-infrared fluorescence imaging · Indocyanine green · Quantification · Perfusion

Introduction

Surgeons rely on physical examination and inspection for perfusion assessment. Although clinical observations are vital, a non-invasive, objective, and reliable instrument to

support clinical decision-making would be advantageous [1, 2]. For example, within gastrointestinal surgery, it has been reported that subjective perfusion assessment lacks predictive accuracy for anastomotic leakage after intestinal resection [3]. In the search for objective perfusion assessment, several techniques have been examined, including but not limited to hyperspectral imaging, computed tomography, and laser speckle contrast imaging [4–7]. Near-infrared (NIR) fluorescence imaging using indocyanine green (ICG) is a technique gaining popularity for tissue perfusion assessment. This non-invasive imaging technique consists of a light source to excite the target tissue, combined with a camera measuring returning fluorescence intensity [8]. Imaging in the NIR spectrum has an advantage over visible light due to a relatively deep tissue penetration of up to 1 cm and the low effect of autofluorescence [9]. The usability of ICG for NIR imaging is primarily the excellent fluorescence properties in the NIR light spectrum and the binding

Van Der Vorst JR and Achiam MP share last authorship.

✉ P. Van Den Hoven
P.van_den_hoven@lumc.nl

¹ Department of Surgery, Leiden University Medical Center, Leiden, The Netherlands

² Department of Surgery and Transplantation, Copenhagen University Hospital Rigshospitalet, The Capital Region of Denmark, Copenhagen, Denmark

³ CAMES Engineering, Copenhagen Academy for Medical Education and Simulation, Centre for Human Resources and Education, The Capital Region of Denmark, Copenhagen, Denmark

to plasma proteins following intravenous administration, making it feasible for perfusion assessment [10]. Since the first introduction of ICG for angiography in ophthalmology, the technique has been adopted by various surgical fields, including but not limited to vascular-, gastrointestinal-, cardiac-, and reconstructive surgery [11–17]. Within vascular surgery, ICG NIR fluorescence imaging has been reported to potentially predict clinical outcomes and guide treatment strategies [18–21]. In gastrointestinal surgery, tissue perfusion assessment using ICG NIR fluorescence imaging has several promising indications, including anastomosis perfusion evaluation to identify patients at risk for anastomotic leakage [22–24]. Other surgical fields in which the prediction of tissue viability can improve patient outcome include reconstructive-, endocrine- and transplant surgery [25–27]. However, despite the widespread use of ICG NIR fluorescence imaging in clinical practice, there is still debate about the interpretation of the observed fluorescence intensity. Several clinical studies have been performed demonstrating visual (i.e., qualitative) ICG NIR perfusion assessment to be able to reduce the risk of, for example, anastomotic leakage [28]. However, the high heterogeneity among these studies and the lack of large randomized controlled trials hamper fierce statements on the value of qualitative ICG. Furthermore, outcomes on several of these phase III studies have yet to be finalized and published [29, 30]. The increased interest in quantitative perfusion assessment can be explained by the fact that a visual interpretation is subjective and inhibits the establishment of perfusion cutoff values. It has also been shown that a visual interpretation might lead to an incorrect understanding of tissue perfusion [31, 32]. In recent years, both clinical—and preclinical studies on quantification of the fluorescence intensity are increasingly being performed

using specifically designed software programs [33, 34]. However, there is ongoing discussion on the most reliable method of quantitative perfusion assessment precluding standardized use in clinical practice. Despite this lack of reliability, however, there is a rapidly growing use of commercially available systems for quantification of ICG NIR fluorescence imaging. Therefore, this review aims to provide an overview of the various quantification methods for ICG NIR fluorescence imaging described in clinical studies with recommendations for future development.

Material and methods

PubMed was searched for clinical studies on quantitative tissue perfusion assessment using ICG NIR fluorescence imaging published before January 2022. Studies lacking a description of the camera system or utilized software program were excluded. The search strategy (Appendix A) identified 199 articles of which 16 were eligible for use, alongside 48 articles published in an earlier review by our study group [34]. The following features concerning the quantitative perfusion assessment were identified: (1) software program, (2) the camera system, (3) the surgical specialty of use, and (4) featured quantification method(s).

Quantification

Quantitative perfusion assessment with ICG NIR fluorescence imaging is performed in three steps. First, an ICG NIR fluorescence imaging camera system visualizes the fluorescence intensity in the camera's field of view, producing a grayscale image or video (Fig. 1 and Video 1). Secondly, the target area for quantification, the region

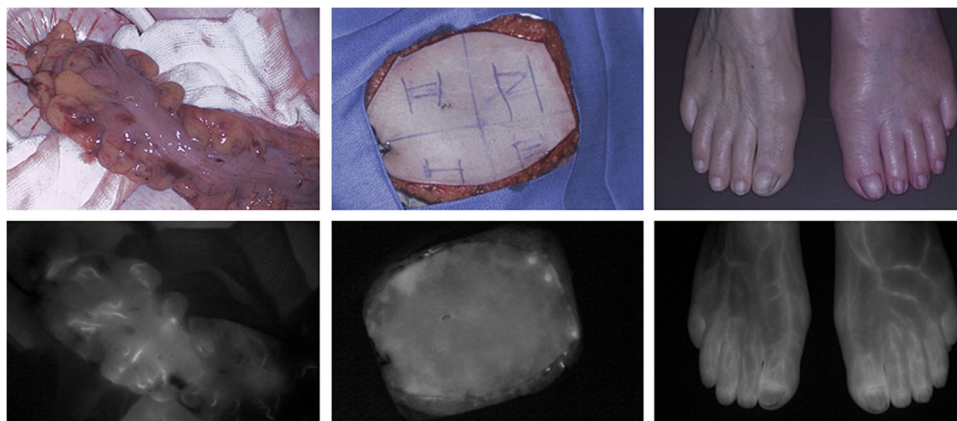


Fig. 1 ICG NIR fluorescence imaging using the Quest Spectrum Platform® showing the visual (above) and near-infrared fluorescence (below) output for three potential indications. Left: intraoperative perfusion assessment of the descending colon in a 65-year old female patient undergoing a low anterior resection. Middle: intraop-

erative perfusion assessment of a profunda artery perforator flap in reconstructive breast surgery of a 38-year old female patient. Right: postoperative perfusion assessment of a 73-year old female patient following peripheral arterial bypass surgery on the left side

of interest (ROI), is selected. Following selection of one or multiple ROIs, the measured fluorescence intensity, defined in arbitrary units (AU), is quantified by specifically designed software programs. In short, three quantification methods can be distinguished and subdivided into (1) static fluorescence analysis, (2) dynamic absolute fluorescence analysis, and (3) dynamic normalized fluorescence analysis (Fig. 2).

1. Static analysis is performed by measuring the absolute intensity in an ROI in a single point in time, either displayed in AU or as a percentage relative to a reference point [16, 35, 36]. The absolute or relative perfusion units can be displayed in the image or visualized in a color-coded heat map.
2. In dynamic absolute fluorescence analysis, the intensity is described as the change in AU over time, most often using a time-intensity curve. Of these curves, several parameters including in- and outflow values can be extracted, which have been outlined in previous review articles on quantification of tissue perfusion with ICG NIR fluorescence imaging [24, 33, 34].
3. In dynamic normalized fluorescence analysis, the fluorescence intensity is adjusted for the maximum intensity (i.e., normalized) in the selected ROI [37, 38]. This

method describes the fluorescence intensity as a percentual change of the maximum intensity over time rather than an absolute intensity change.

Results

The PubMed search identified 11 software programs for quantifying tissue perfusion with ICG NIR fluorescence imaging. Of these 11 programs, five have been described in three or more clinical studies, including Flow® 800, ROIs Software, IC Calc, SPY-Q™, and the Quest Research Framework®. An overview of currently used quantification software for ICG NIR fluorescence perfusion assessment is presented in Table 1.

Static fluorescence analysis

Most clinical studies in which static analysis was used were performed with the proprietary quantification software SPY-Q™ [77, 78]. This software program is compatible with the SPY Elite fluorescence imaging system, which features real-time intraoperative visualization of

Fig. 2 Standardized work flow for quantitative perfusion assessment using near-infrared fluorescence imaging with indocyanine green. First, ICG NIR fluorescence imaging is performed creating a fluorescence intensity image or video. Secondly, the target area or region of interest (ROI) is selected using specifically designed software programs for quantitative analysis of the fluorescence intensity. The third and final step of the quantification workflow is the actual quantitative analysis of the fluorescence intensity which can be performed using three methods: (1) static analysis (i.e., point analysis without dynamics over time), (2) absolute dynamic analysis by using so called time-intensity curves, and (3) normalized dynamic analysis, i.e., describing the fluorescence intensity over time as a percentage relative to the maximum intensity. *Created with BioRender*

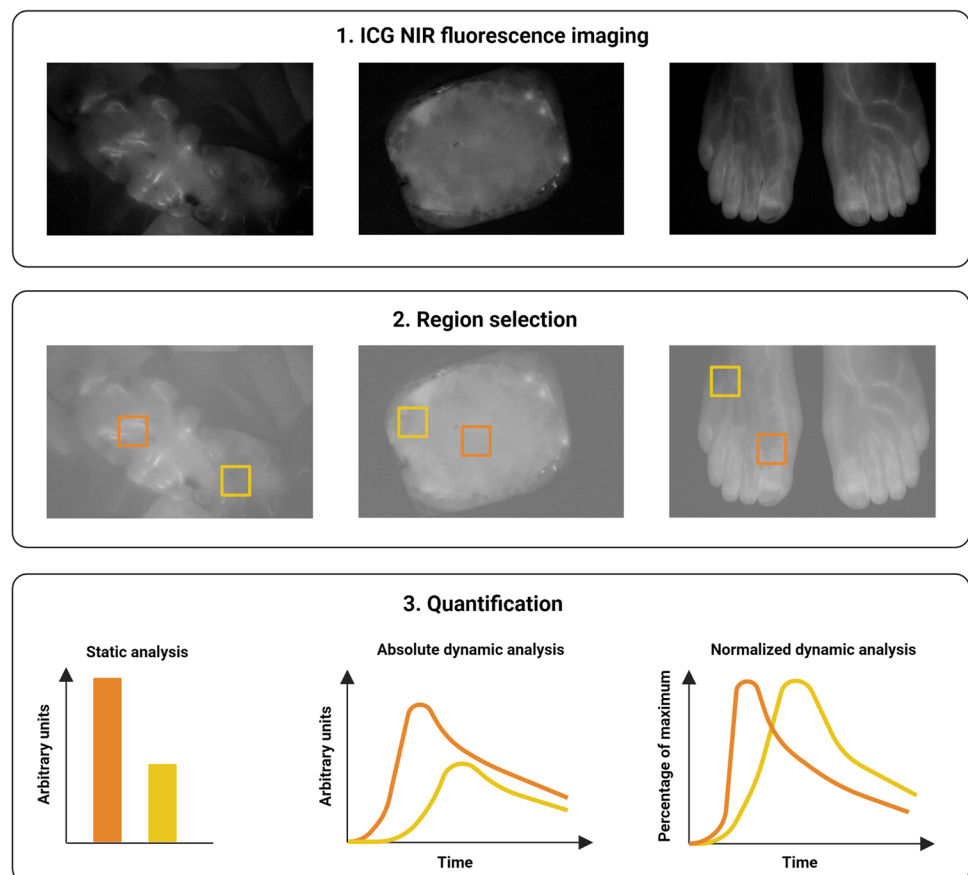


Table 1 Overview of ICG NIR fluorescence quantification software used in clinical studies with featured quantification methods

| Specifications | References | Specialty of use | Quantification method | | Intraoperative use |
|--|------------------------|---|-----------------------|---------------------------|-----------------------------|
| | | | Static analysis | Dynamic absolute analysis | Dynamic normalized analysis |
| Software program | Utilized camera system | | | | |
| VISIONSENSE® (Medtronic, Minneapolis, MN, USA) | [39] | Endocrine surgery | Yes | NS | NS |
| FLER | [40] | Gastrointestinal surgery | NS | Yes | NS |
| Flow® 800 (Zeiss Meditec, Oberkochen, Germany) | [41–54] | Neurosurgery | NS | Yes | NS |
| ROIs software (Hamamatsu Photonics K.K., Hamamatsu, Japan) | [55–65] | Gastrointestinal surgery Breast surgery Vascular surgery | NS | Yes | NS |
| IC-Calcul | [66–71] | Reconstructive surgery Endocrine surgery Neurosurgery | NS | Yes | NS |
| ImageJ (National Institutes of Health, Maryland, USA), ImageJ (National Institute of Health, Bethesda, MD) | [72–74] | Gastrointestinal surgery Reconstructive surgery | NS | Yes | NS |
| NIRx NAVI | [75] | Breast surgery | NS | Yes | NS |
| Q-ICG | [32] | Gastrointestinal surgery | NS | Yes | Yes |
| Quest Research Framework® | [18, 26, 38, 76] | Vascular surgery Endocrine surgery | No | Yes | Yes |
| Spy-Q™ | [20, 27, 77–92] | Reconstructive surgery Vascular surgery Breast surgery Transplantation surgery | Yes | Yes | NS |
| Tracker 4.97 (Douglas Brown, Open Source Physics, Boston MA, USA) | [93] | Gastroenterology | NS | Yes | NS |

NS, not specified

quantification. Upon manual selection of a reference region, Newman et al. described significant correlation with mastectomy skin necrosis following mastectomy using a relative perfusion value of 25.2% [77]. Similar results were obtained in a study by Moyer et al., demonstrating a cutoff of 25% to increase the likelihood of mastectomy skin flap necrosis [78]. Static analysis has also been investigated with VISIONSENSE®, a relatively new program allowing perfusion imaging laparoscopically using color-coded heat maps with a near-infrared overlay. An adjustable threshold for relative perfusion value makes it possible to visualize perfusion differences. In a recent study, Kamada et al. proved the system to be feasible in differentiating thyroid and parathyroid tissue using a relative perfusion value of 50% [94]. Although cutoff values for static analysis were found to be significant within these studies, no phase III studies have been identified for perfusion assessment with ICG NIR fluorescence imaging for intraoperative decision-making.

Dynamic fluorescence analysis—absolute intensity

Dynamic fluorescence analysis using absolute intensity was the most reported method for quantifying ICG NIR fluorescence imaging. Of the 11 described software programs, ten are able to describe the change in absolute fluorescence intensity over time. Of these, five have been described in three or more clinical studies, including Flow® 800, ROIs Software, IC Calc, SPY-Q™, and the Quest Research Framework® (Table 1). The Flow® 800, solely used in neurosurgery, allows for intraoperative visualization of time-intensity curves in up to eight regions of interest [95]. The program also features the visualization of a color-coded map describing the start of the fluorescence intensity increase, a semi-quantitative analysis [41]. Clear map visualization is enhanced using motion tracking assistance [95]. The most reported software program for dynamic absolute fluorescence analysis was SPY-Q™. This intra-operatively usable software system provides both absolute in- and outflow parameters and has an automatic baseline fluorescence adjustment [20]. Results on dynamic analysis can be readily displayed in relative values, providing cutoff values for perfusion [79]. Another program allowing the intraoperative quantification of dynamic fluorescence analysis is ROIs software. This software program by Hamamatsu Photonics has been proven compatible with various camera systems (Table 1). Intraoperative selection of a region of interest generates absolute time-intensity curves [55]. As for static analysis, studies beyond the scope of a pilot setting are yet to be performed.

Dynamic fluorescence analysis—normalization

The feature of applying normalization to the dynamic analysis was described by two software programs: Q-ICG and the Quest Research Framework®. Of these two techniques, Q-ICG is the only one that enables real-time intraoperative analysis [32]. This algorithm has a built-in quality control that allows surgeons to disregard information from regions with poor data quality. The system is compatible with videos in various file types and any imaging system, as a plug and play solution [32]. The Quest Research Framework® program, which is proprietary software to the Quest Spectrum platform®, enables the generation of normalized time-intensity curves [76]. This program has a built-in motion tracker adjusting for movement, limiting influence of target area movement in the horizontal plane. As with absolute fluorescence analysis, no studies have been performed assessing the value of normalization for perfusion assessment in advanced stage clinical trials.

Discussion

This narrative review demonstrates the variety of featured quantification methods for ICG NIR fluorescence imaging within the currently described software programs. Interestingly, none of these 11 software programs can apply all three methods of quantification, despite the demonstrated potential of all three quantification methods towards clinical implementation [16, 25, 33, 34, 36, 96]. However, there is a lack of studies exploring the use of currently available quantification software programs in studies beyond the scope of feasibility. This might be due to the limitations associated with each quantification method. Static fluorescence analysis, for example, is sensitive to several factors impeding its reliability. First of all, the measured fluorescence intensity is subject to camera- and patient-related settings [97, 98]. Hence, the differences in camera distance and angle to the target area influence the measured intensity. Second, in case of relative static fluorescence analysis, the chosen reference point significantly influences the effect on other ROIs. This might, for example, lead to relative perfusion units above 100% [25]. Third, the timing of analysis following ICG administration can lead to misinterpretation, since it is known that ICG will also diffuse into ischemic tissue over time [40]. Dynamic absolute fluorescence analysis overcomes this time-related issue by describing the intensity change over time. However, with absolute intensity, there is still an ongoing debate on which parameter is most appropriate [34, 96]. This could partly be explained

Table 2 Three methods of quantification with recommendations for use in clinical practice

| Quantification method | Advantage(s) | Disadvantage(s) | Preferred indication |
|-----------------------------|-------------------------------------|--|------------------------|
| Static analysis | - Easy to perform | - Incorrect timing leads to misinterpretation - Sensitive to factors influencing intensity | - None |
| Absolute dynamic analysis | - Information about in- and outflow | - Sensitive to factors influencing intensity - Subject to variations among arbitrary unit scale in camera systems | - Tissue viability |
| Normalized dynamic analysis | - Information about in- and outflow | - Inaccuracy with low intensity | - Perfusion assessment |

by influencing factors, including camera distance and angle, compromising the reliability of using absolute perfusion units [97]. Furthermore, as outlined in an earlier review on the quantification of ICG in gastrointestinal surgery, camera-specific characteristics will influence the measured fluorescence intensity [99]. Hence illumination, NIR spectrum bandwidth and filters, optical settings, including exposure time- and gain influence the signal [9]. Normalization tends to minimize the effects of patient- and camera-related settings by adjusting the fluorescence for the maximum intensity [100]. Although normalization enhances reliability and validity by reducing influencing factors, intensity-related parameters are depleted. These absolute parameters, such as maximum intensity, could be useful in the assessment of tissue viability, as was shown in several studies [18, 72, 101]. Furthermore, normalization of time-intensity curves in areas with low fluorescence intensity (for example within tissue necrosis), i.e., magnifying the signal to 100%, might lead to fluttering of the curves, making them non-interpretable. In the quest for developing a reliable and clinically usable quantification system, these limitations as well as the advantages associated with each quantification method should be carefully addressed (Table 2). A recently published review highlighted the significance of a clear guideline for fluorescence imaging to be valuable for implementation in clinical practice [102]. Reliable quantification of the fluorescence intensity faces the same challenges and mandates a clear guideline. The rapidly emerging field of quantitative perfusion assessment with ICG is increasingly becoming multidisciplinary teamwork, including physicians, technicians, and commercial developers. In the quest for reliable quantification, it is pivotal that all involved parties focus in the same direction, that is, towards clinical implementation. To reach this goal, it is of utmost importance that data on fluorescence intensity is findable, accessible, interoperable, and reusable, according to FAIR principles [103]. The use of a standardized method for quantification of tissue perfusion with ICG NIR fluorescence imaging then marks a starting point towards necessary clinical trials.

Conclusion

Currently utilized software programs for the quantification of ICG NIR fluorescence imaging vary in their methods of quantification and usability. In the widespread search for reliable quantification of perfusion with ICG NIR fluorescence imaging, standardization of quantification methods and data acquisition is essential.

Supplementary Information The online version contains supplementary material available at <https://doi.org/10.1007/s00423-023-02780-0>.

Authors' contributions All authors contributed to the study conception and design. Material preparation, data collection, and analysis were performed by P. van den Hoven and J.R. van der Vorst. The first draft of the manuscript was written by Pim van den Hoven, and all authors commented on previous versions of the manuscript. All authors read and approved the final manuscript.

Declarations

Conflict of interest The authors declare no competing interests.

Open Access This article is licensed under a Creative Commons Attribution 4.0 International License, which permits use, sharing, adaptation, distribution and reproduction in any medium or format, as long as you give appropriate credit to the original author(s) and the source, provide a link to the Creative Commons licence, and indicate if changes were made. The images or other third party material in this article are included in the article's Creative Commons licence, unless indicated otherwise in a credit line to the material. If material is not included in the article's Creative Commons licence and your intended use is not permitted by statutory regulation or exceeds the permitted use, you will need to obtain permission directly from the copyright holder. To view a copy of this licence, visit <http://creativecommons.org/licenses/by/4.0/>.

References

1. Misra S, Shishehbor MH, Takahashi EA, Aronow HD, Brewster LP, Bunte MC et al (2019) Perfusion assessment in critical limb ischemia: principles for understanding and the development of evidence and evaluation of devices: a scientific statement from the American Heart Association. *Circulation* 140(12):e657–e672. <https://doi.org/10.1161/CIR.0000000000000708>
2. Urbanavicius L, Pattyn P, de Putte DV, Venskutonis D (2011) How to assess intestinal viability during surgery: a review of techniques. *World J Gastrointest Surg* 3(5):59–69. <https://doi.org/10.4240/wjgs.v3.i5.59>

3. Karliczek A, Harlaar NJ, Zeebregts CJ, Wiggers T, Baas PC, van Dam GM (2009) Surgeons lack predictive accuracy for anastomotic leakage in gastrointestinal surgery. *Int J Colorectal Dis* 24(5):569–576. <https://doi.org/10.1007/s00384-009-0658-6>
4. Benitez E, Sumpio BJ, Chin J, Sumpio BE (2014) Contemporary assessment of foot perfusion in patients with critical limb ischemia. *Semin Vasc Surg* 27(1):3–15. <https://doi.org/10.1053/j.semvascsurg.2014.12.001>
5. Cindil E, Erbas G, Akkan K, Cerit MN, Sendur HN, Zor MH et al (2020) Dynamic volume perfusion CT of the foot in critical limb ischemia: response to percutaneous revascularization. *AJR Am J Roentgenol* 214(6):1398–1408. <https://doi.org/10.2214/AJR.19.21520>
6. Draijer M, Hondebrink E, van Leeuwen T, Steenberg W (2009) Review of laser speckle contrast techniques for visualizing tissue perfusion. *Lasers Med Sci* 24(4):639–651. <https://doi.org/10.1007/s10103-008-0626-3>
7. Ronn JH, Nerup N, Strandby RB, Svendsen MBS, Ambrus R, Svendsen LB et al (2019) Laser speckle contrast imaging and quantitative fluorescence angiography for perfusion assessment. *Langenbecks Arch Surg* 404(4):505–515. <https://doi.org/10.1007/s00423-019-01789-8>
8. AV DS, Lin H, Henderson ER, Samkoe KS, Pogue BW (2016) Review of fluorescence guided surgery systems: identification of key performance capabilities beyond indocyanine green imaging. *J Biomed Opt* 21(8):080901. <https://doi.org/10.1117/1.JBO.21.8.080901>
9. Alander JT, Kaartinen I, Laakso A, Patila T, Spillmann T, Tuchin VV, et al. A review of indocyanine green fluorescent imaging in surgery. *Int J Biomed Imaging*. 2012;2012:940585. <https://doi.org/10.1155/2012/940585>.
10. Landsman ML, Kwant G, Mook GA, Zijlstra WG (1976) Light-absorbing properties, stability, and spectral stabilization of indocyanine green. *J Appl Physiol* 40(4):575–583. <https://doi.org/10.1152/jappl.1976.40.4.575>
11. Vahrmeijer AL, Hutteman M, van der Vorst JR, van de Velde CJ, Frangioni JV (2013) Image-guided cancer surgery using near-infrared fluorescence. *Nat Rev Clin Oncol* 10(9):507–518. <https://doi.org/10.1038/nrclinonc.2013.123>
12. Schaafsma BE, Mieog JS, Hutteman M, van der Vorst JR, Kuppen PJ, Lowik CW et al (2011) The clinical use of indocyanine green as a near-infrared fluorescent contrast agent for image-guided oncologic surgery. *J Surg Oncol* 104(3):323–332. <https://doi.org/10.1002/jso.21943>
13. Yamamoto M, Nishimori H, Handa T, Fukutomi T, Kihara K, Tashiro M et al (2017) Quantitative assessment technique of HyperEye medical system angiography for coronary artery bypass grafting. *Surg Today* 47(2):210–217. <https://doi.org/10.1007/s00595-016-1369-6>
14. Detter C, Russ D, Iffland A, Wipper S, Schurr MO, Reichenspurner H et al (2002) Near-infrared fluorescence coronary angiography: a new noninvasive technology for intraoperative graft patency control. *Heart Surg Forum* 5(4):364–369
15. Munabi NC, Olorunnipa OB, Goltsman D, Rohde CH, Ascherman JA (2014) The ability of intra-operative perfusion mapping with laser-assisted indocyanine green angiography to predict mastectomy flap necrosis in breast reconstruction: a prospective trial. *J Plast Reconstr Aesthet Surg* 67(4):449–455. <https://doi.org/10.1016/j.bjps.2013.12.040>
16. Driessen C, Arnardottir TH, Lorenzo AR, Mani MR (2020) How should indocyanine green dye angiography be assessed to best predict mastectomy skin flap necrosis? A systematic review. *J Plast Reconstr Aesthet Surg* 73(6):1031–1042. <https://doi.org/10.1016/j.bjps.2020.02.025>
17. Kogure K, Choromokos E (1969) Infrared absorption angiography. *J Appl Physiol* 26(1):154–157. <https://doi.org/10.1152/jappl.1969.26.1.154>
18. Van Den Hoven P, Van Den Berg SD, Van Der Valk JP, Van Der Krogt H, Van Doorn LP, Van De Bogt KEA et al (2021) Assessment of tissue viability following amputation surgery using near-infrared fluorescence imaging with indocyanine green. *Ann Vasc Surg*. <https://doi.org/10.1016/j.avsg.2021.04.030>
19. Zimmermann A, Roenneberg C, Wendorff H, Holzbach T, Giunta RE, Eckstein HH (2010) Early postoperative detection of tissue necrosis in amputation stumps with indocyanine green fluorescence angiography. *Vasc Endovascular Surg* 44(4):269–273. <https://doi.org/10.1177/1538574410362109>
20. Settembre N, Kauhanen P, Alback A, Spillerova K, Venermo M (2017) Quality control of the foot revascularization using indocyanine green fluorescence imaging. *World J Surg* 41(7):1919–1926. <https://doi.org/10.1007/s00268-017-3950-6>
21. Arsenault KA, Al-Otaibi A, Devereaux PJ, Thorlund K, Tittley JG, Whitlock RP (2012) The use of transcutaneous oximetry to predict healing complications of lower limb amputations: a systematic review and meta-analysis. *Eur J Vasc Endovasc Surg* 43(3):329–336. <https://doi.org/10.1016/j.ejvs.2011.12.004>
22. Degett TH, Andersen HS, Gogenur I (2016) Indocyanine green fluorescence angiography for intraoperative assessment of gastrointestinal anastomotic perfusion: a systematic review of clinical trials. *Langenbecks Arch Surg* 401(6):767–775. <https://doi.org/10.1007/s00423-016-1400-9>
23. Jafari MD, Lee KH, Halabi WJ, Mills SD, Carmichael JC, Stamos MJ et al (2013) The use of indocyanine green fluorescence to assess anastomotic perfusion during robotic assisted laparoscopic rectal surgery. *Surg Endosc* 27(8):3003–3008. <https://doi.org/10.1007/s00464-013-2832-8>
24. Lutken CD, Achiam MP, Svendsen MB, Boni L, Nerup N (2020) Optimizing quantitative fluorescence angiography for visceral perfusion assessment. *Surg Endosc* 34(12):5223–5233. <https://doi.org/10.1007/s00464-020-07821-z>
25. Lauritzen E, Damsgaard TE (2021) Use of indocyanine green angiography decreases the risk of complications in autologous- and implant-based breast reconstruction: a systematic review and meta-analysis. *J Plast Reconstr Aesthet Surg*. <https://doi.org/10.1016/j.bjps.2021.03.034>
26. Noltes ME, Metman MJH, Jansen L, Peepkorn EWM, Engelsman AF, Kruijff S (2021) Parathyroid function saving total thyroidectomy using autofluorescence and quantified indocyanine green angiography. *VideoEndocrinology* 8(2). <https://doi.org/10.1089/ve.2021.0008>
27. Gerken ALH, Nowak K, Meyer A, Weiss C, Kruger B, Nawroth N, et al. (2020) Quantitative assessment of intraoperative laser fluorescence angiography with indocyanine green predicts early graft function after kidney transplantation. *Ann Surg*; Publish Ahead of Print. <https://doi.org/10.1097/SLA.00000000000004529>.
28. Pang HY, Chen XL, Song XH, Galiullin D, Zhao LY, Liu K et al (2021) Indocyanine green fluorescence angiography prevents anastomotic leakage in rectal cancer surgery: a systematic review and meta-analysis. *Langenbecks Arch Surg* 406(2):261–271. <https://doi.org/10.1007/s00423-020-02077-6>
29. Meijer RPJ, Faber RA, Bijlstra OD, Braak J, Meershoek-Klein Kranenbarg E, Putter H, et al. (2022) AVOID; a phase III, randomised controlled trial using indocyanine green for the prevention of anastomotic leakage in colorectal surgery. *BMJ Open* 12(4):e051144. <https://doi.org/10.1136/bmjopen-2021-051144>.
30. Armstrong G, Croft J, Corrigan N, Brown JM, Goh V, Quirke P et al (2018) IntAct: intra-operative fluorescence angiography to prevent anastomotic leak in rectal cancer surgery: a randomized

- controlled trial. *Colorectal Dis* 20(8):O226–O234. <https://doi.org/10.1111/codi.14257>
31. Nerup N, Svendsen MBS, Ronn JH, Konge L, Svendsen LB, Achiam MP (2021) Quantitative fluorescence angiography aids novice and experienced surgeons in performing intestinal resection in well-perfused tissue. *Surg Endosc*. <https://doi.org/10.1007/s00464-021-08518-7>
 32. Nerup N, Svendsen MBS, Svendsen LB, Achiam MP (2020) Feasibility and usability of real-time intraoperative quantitative fluorescent-guided perfusion assessment during resection of gastroesophageal junction cancer. *Langenbecks Arch Surg* 405(2):215–222. <https://doi.org/10.1007/s00423-020-01876-1>
 33. Lutken CD, Achiam MP, Osterkamp J, Svendsen MB, Nerup N (2020) Quantification of fluorescence angiography: toward a reliable intraoperative assessment of tissue perfusion—a narrative review. *Langenbecks Archives of Surgery* 21:21
 34. Goncalves LN, van den Hoven P, van Schaik J, Leeuwenburgh L, Hendricks CHF, Verduijn PS, et al. (2021) Perfusion parameters in near-infrared fluorescence imaging with indocyanine green: a systematic review of the literature. *Life (Basel)* 11(5), <https://doi.org/10.3390/life11050433>.
 35. Smit JM, Negenborn VL, Jansen SM, Jaspers MEH, de Vries R, Heymans MW et al (2018) Intraoperative evaluation of perfusion in free flap surgery: a systematic review and meta-analysis. *Microsurgery* 38(7):804–818. <https://doi.org/10.1002/micr.30320>
 36. Yang AE, Hartranft CA, Reiss A, Holden CR (2018) Improving outcomes for lower extremity amputations using intraoperative fluorescent angiography to predict flap viability. *Vasc Endovascular Surg* 52(1):16–21. <https://doi.org/10.1177/1538574417740048>
 37. Osterkamp J, Strandby R, Nerup N, Svendsen M, Svendsen L, Achiam M (2020) Quantitative fluorescence angiography detects dynamic changes in gastric perfusion. *Surg Endosc*. <https://doi.org/10.1007/s00464-020-08183-2>
 38. Van den Hoven P, F SW, Van De Bent M, Goncalves LN, Ruig M, S DVDB, et al. Near-infrared fluorescence imaging with indocyanine green for quantification of changes in tissue perfusion following revascularization. *Vascular*. 2021:17085381211032826, <https://doi.org/10.1177/17085381211032826>.
 39. Kamada T, Yoshida M, Suzuki N, Takeuchi H, Takahashi J, Marukuchi R et al (2020) Introduction of VISIONSENSE(R) for indocyanine green fluorescence-guided parathyroidectomy: report of a case. *Int J Surg Case Rep* 75:418–421. <https://doi.org/10.1016/j.ijscr.2020.09.139>
 40. D'Urso A, Agnus V, Barberio M, Seeliger B, Marchegiani F, Charles AL et al (2021) Computer-assisted quantification and visualization of bowel perfusion using fluorescence-based enhanced reality in left-sided colonic resections. *Surg Endosc* 35(8):4321–4331. <https://doi.org/10.1007/s00464-020-07922-9>
 41. Zhang X, Ni W, Feng R, Li Y, Lei Y, Xia D et al (2020) Evaluation of hemodynamic Change by indocyanine green-FLOW 800 videoangiography mapping: prediction of hyperperfusion syndrome in patients with moyamoya disease. *Oxid Med Cell Longev* 2020:8561609. <https://doi.org/10.1155/2020/8561609>
 42. Goertz L, Hof M, Timmer M, Schulte AP, Kabbasch C, Krischek B et al (2019) Application of intraoperative FLOW 800 indocyanine green videoangiography color-coded maps for microsurgical clipping of intracranial aneurysms. *World Neurosurg* 131:e192–e200. <https://doi.org/10.1016/j.wneu.2019.07.113>
 43. Rennert RC, Strickland BA, Ravina K, Brandel MG, Bakhsheshian J, Fredrickson V et al (2019) Assessment of ischemic risk following intracranial-to-intracranial and extracranial-to-intracranial bypass for complex aneurysms using intraoperative indocyanine green-based flow analysis. *J Clin Neurosci* 67:191–197. <https://doi.org/10.1016/j.jocn.2019.06.036>
 44. Rennert RC, Strickland BA, Ravina K, Bakhsheshian J, Fredrickson V, Carey J et al (2019) Intraoperative assessment of cortical perfusion after intracranial-to-intracranial and extracranial-to-intracranial bypass for complex cerebral aneurysms using Flow 800. *Oper Neurosurg (Hagerstown)* 16(5):583–592. <https://doi.org/10.1093/ons/opy154>
 45. Rennert RC, Strickland BA, Ravina K, Bakhsheshian J, Russin JJ (2018) Assessment of hemodynamic changes and hyperperfusion risk after extracranial-to-intracranial bypass surgery using intraoperative indocyanine green-based flow analysis. *World Neurosurg* 114:352–360. <https://doi.org/10.1016/j.wneu.2018.03.189>
 46. Shi W, Qiao G, Sun Z, Shang A, Wu C, Xu B (2015) Quantitative assessment of hemodynamic changes during spinal dural arteriovenous fistula surgery. *J Clin Neurosci* 22(7):1155–1159. <https://doi.org/10.1016/j.jocn.2015.01.024>
 47. Prinz V, Hecht N, Kato N, Vajkoczy P. (2014) FLOW 800 allows visualization of hemodynamic changes after extracranial-to-intracranial bypass surgery but not assessment of quantitative perfusion or flow. *Neurosurgery* 10 Suppl 2:231–8; discussion 8–9, <https://doi.org/10.1227/NEU.0000000000000277>.
 48. Ye X, Liu XJ, Ma L, Liu LT, Wang WL, Wang S et al (2013) Clinical values of intraoperative indocyanine green fluorescence video angiography with Flow 800 software in cerebrovascular surgery. *Chin Med J (Engl)* 126(22):4232–4237
 49. Holling M, Brokinkel B, Ewelt C, Fischer BR, Stummer W (2013) Dynamic ICG fluorescence provides better intraoperative understanding of arteriovenous fistulae. *Neurosurgery* 73(1 Suppl Operative):ons93–8; discussion ons9, <https://doi.org/10.1227/NEU.0b013e31828772a4>.
 50. Kamp MA, Sloty P, Turowski B, Etminan N, Steiger HJ, Hanggi D, et al. (2012) Microscope-integrated quantitative analysis of intraoperative indocyanine green fluorescence angiography for blood flow assessment: first experience in 30 patients. *Neurosurgery* 70(1 Suppl Operative):65–73; discussion -4, <https://doi.org/10.1227/NEU.0b013e31822f7d7c>.
 51. Uchino H, Nakamura T, Houkin K, Murata J, Saito H, Kuroda S (2013) Semiquantitative analysis of indocyanine green videoangiography for cortical perfusion assessment in superficial temporal artery to middle cerebral artery anastomosis. *Acta Neurochir (Wien)* 155(4):599–605. <https://doi.org/10.1007/s00701-012-1575-y>
 52. Uchino H, Kazumata K, Ito M, Nakayama N, Kuroda S, Houkin K (2014) Intraoperative assessment of cortical perfusion by indocyanine green videoangiography in surgical revascularization for moyamoya disease. *Acta Neurochir (Wien)* 156(9):1753–1760. <https://doi.org/10.1007/s00701-014-2161-2>
 53. Jung EM, Prantl L, Schreyer AG, Schreyer CI, Rennert J, Walter M et al (2009) New perfusion imaging of tissue transplants with contrast harmonic ultrasound imaging (CHI) and magnetic resonance imaging (MRI) in comparison with laser-induced indocyanine green (ICG) fluorescence angiography. *Clin Hemorheol Microcirc* 43(1–2):19–33. <https://doi.org/10.3233/CH-2009-1218>
 54. Kobayashi S, Ishikawa T, Tanabe J, Moroi J, Suzuki A (2014) Quantitative cerebral perfusion assessment using microscope-integrated analysis of intraoperative indocyanine green fluorescence angiography versus positron emission tomography in superficial temporal artery to middle cerebral artery anastomosis. *Surg Neurol Int* 5:135. <https://doi.org/10.4103/2152-7806.140705>
 55. Ishige F, Nabeya Y, Hoshino I, Takayama W, Chiba S, Arimitsu H et al (2019) Quantitative assessment of the blood perfusion of the gastric conduit by indocyanine green imaging. *J Surg Res* 234:303–310. <https://doi.org/10.1016/j.jss.2018.08.056>
 56. Hayami S, Matsuda K, Iwamoto H, Ueno M, Kawai M, Hirono S et al (2019) Visualization and quantification of anastomotic

- perfusion in colorectal surgery using near-infrared fluorescence. *Tech Coloproctol* 23(10):973–980. <https://doi.org/10.1007/s10151-019-02089-5>
57. Kamiya K, Unno N, Miyazaki S, Sano M, Kikuchi H, Hiramatsu Y et al (2015) Quantitative assessment of the free jejunal graft perfusion. *J Surg Res* 194(2):394–399. <https://doi.org/10.1016/j.jss.2014.10.049>
 58. Gorai K, Inoue K, Saegusa N, Shimamoto R, Takeishi M, Okazaki M, et al. (2017) Prediction of skin necrosis after mastectomy for breast cancer using indocyanine green angiography imaging. *Plast Reconstr Surg Glob Open* 5(4):e1321. <https://doi.org/10.1097/GOX.0000000000001321>
 59. Miyazaki H, Igari K, Kudo T, Iwai T, Wada Y, Takahashi Y et al (2017) Significance of the lateral thoracic artery in pectoralis major musculocutaneous flap reconstruction: quantitative assessment of blood circulation using indocyanine green angiography. *Ann Plast Surg* 79(5):498–504. <https://doi.org/10.1097/SAP.0000000000001123>
 60. Tanaka K, Okazaki M, Yano T, Miyashita H, Homma T, Tomita M (2015) Quantitative evaluation of blood perfusion to nerves included in the anterolateral thigh flap using indocyanine green fluorescence angiography: a different contrast pattern between the vastus lateralis motor nerve and femoral cutaneous nerve. *J Reconstr Microsurg* 31(3):163–170. <https://doi.org/10.1055/s-0034-1390382>
 61. Igari K, Kudo T, Toyofuku T, Jibiki M, Inoue Y, Kawano T (2013) Quantitative evaluation of the outcomes of revascularization procedures for peripheral arterial disease using indocyanine green angiography. *Eur J Vasc Endovasc Surg* 46(4):460–465. <https://doi.org/10.1016/j.ejvs.2013.07.016>
 62. Igari K, Kudo T, Uchiyama H, Toyofuku T, Inoue Y (2014) Indocyanine green angiography for the diagnosis of peripheral arterial disease with isolated infrapopliteal lesions. *Ann Vasc Surg* 28(6):1479–1484. <https://doi.org/10.1016/j.avsg.2014.03.024>
 63. Nishizawa M, Igari K, Kudo T, Toyofuku T, Inoue Y, Uetake H (2016) A Comparison of the regional circulation in the feet between dialysis and non-dialysis patients using indocyanine green angiography. *Scand J Surg*. <https://doi.org/10.1177/1457496916666412>
 64. Terasaki H, Inoue Y, Sugano N, Jibiki M, Kudo T, Lepantalo M et al (2013) A quantitative method for evaluating local perfusion using indocyanine green fluorescence imaging. *Ann Vasc Surg* 27(8):1154–1161. <https://doi.org/10.1016/j.avsg.2013.02.011>
 65. Venermo M, Settembre N, Alback A, Vikatmaa P, Aho PS, Lepantalo M et al (2016) Pilot assessment of the repeatability of indocyanine green fluorescence imaging and correlation with traditional foot perfusion assessments. *Eur J Vasc Endovasc Surg* 52(4):527–533. <https://doi.org/10.1016/j.ejvs.2016.06.018>
 66. Mothes H, Donicke T, Friedel R, Simon M, Markgraf E, Bach O (2004) Indocyanine-green fluorescence video angiography used clinically to evaluate tissue perfusion in microsurgery. *J Trauma* 57(5):1018–1024. <https://doi.org/10.1097/01.ta.0000123041.47008.70>
 67. Siedek V, Waggshauser T, Berghaus A, Matthias C (2009) Intraoperative monitoring of intraarterial paraganglioma embolization by indocyanine green fluorescence angiography. *Eur Arch Otorhinolaryngol* 266(9):1449–1454. <https://doi.org/10.1007/s00405-008-0879-2>
 68. Woitzik J, Pena-Tapia PG, Schneider UC, Vajkoczy P, Thome C (2006) Cortical perfusion measurement by indocyanine-green videoangiography in patients undergoing hemispherectomy for malignant stroke. *Stroke* 37(6):1549–1551. <https://doi.org/10.1161/01.STR.0000221671.94521.51>
 69. Betz CS, Zhorzel S, Schachenmayr H, Stepp H, Havel M, Siedek V et al (2009) Endoscopic measurements of free-flap perfusion in the head and neck region using red-excited indocyanine green: preliminary results. *J Plast Reconstr Aesthet Surg* 62(12):1602–1608. <https://doi.org/10.1016/j.bjps.2008.07.042>
 70. Betz CS, Zhorzel S, Schachenmayr H, Stepp H, Matthias C, Hopfer C et al (2013) Endoscopic assessment of free flap perfusion in the upper aerodigestive tract using indocyanine green: a pilot study. *J Plast Reconstr Aesthet Surg* 66(5):667–674. <https://doi.org/10.1016/j.bjps.2012.12.034>
 71. Zimmermann A, Roenneberg C, Reeps C, Wendorff H, Holzbach T, Eckstein HH (2012) The determination of tissue perfusion and collateralization in peripheral arterial disease with indocyanine green fluorescence angiography. *Clin Hemorheol Microcirc* 50(3):157–166. <https://doi.org/10.3233/CH-2011-1408>
 72. Hitier M, Cracowski JL, Hamou C, Righini C, Bettega G (2016) Indocyanine green fluorescence angiography for free flap monitoring: a pilot study. *J Craniomaxillofac Surg* 44(11):1833–1841. <https://doi.org/10.1016/j.jcms.2016.09.001>
 73. Amagai H, Miyauchi H, Muto Y, Uesato M, Ohira G, Imanishi S et al (2020) Clinical utility of transanal indocyanine green near-infrared fluorescence imaging for evaluation of colorectal anastomotic perfusion. *Surg Endosc* 34(12):5283–5293. <https://doi.org/10.1007/s00464-019-07315-7>
 74. Fichter AM, Ritschl LM, Georg R, Kolk A, Kesting MR, Wolff KD et al (2019) Effect of segment length and number of osteotomy sites on cancellous bone perfusion in free fibula flaps. *J Reconstr Microsurg* 35(2):108–116. <https://doi.org/10.1055/s-0038-1667364>
 75. Schneider P, Piper S, Schmitz CH, Schreiter NF, Volkwein N, Ludemann L et al (2011) Fast 3D Near-infrared breast imaging using indocyanine green for detection and characterization of breast lesions. *Rofo* 183(10):956–963. <https://doi.org/10.1055/s-0031-1281726>
 76. van den Hoven P, Goncalves LN, Quax PHA, Van Rijswijk CSP, Van Schaik J, Schepers A, et al. (2021) Perfusion patterns in patients with chronic limb-threatening ischemia versus control patients using near-infrared fluorescence imaging with indocyanine green. *Biomedicine* 9(10):ARTN 1417 <https://doi.org/10.3390/biomedicine9101417>
 77. Newman MI, Jack MC, Samson MC (2013) SPY-Q analysis toolkit values potentially predict mastectomy flap necrosis. *Ann Plast Surg* 70(5):595–598. <https://doi.org/10.1097/SAP.0b013e3182650b4e>
 78. Moyer HR, Losken A (2012) Predicting mastectomy skin flap necrosis with indocyanine green angiography: the gray area defined. *Plast Reconstr Surg* 129(5):1043–1048. <https://doi.org/10.1097/PRS.0b013e31824a2b02>
 79. Abdelwahab M, Spataro EA, Kandathil CK, Most SP (2019) Neovascularization perfusion of melolabial flaps using intraoperative indocyanine green angiography. *JAMA Facial Plast Surg* 21(3):230–236. <https://doi.org/10.1001/jamafacial.2018.1874>
 80. Abdelwahab M, Kandathil CK, Most SP, Spataro EA (2019) Utility of indocyanine green angiography to identify clinical factors associated with perfusion of paramedian forehead flaps during nasal reconstruction surgery. *JAMA Facial Plast Surg* 21(3):206–212. <https://doi.org/10.1001/jamafacial.2018.1829>
 81. Rudy SF, Abdelwahab M, Kandathil CK, Most SP (2021) Paramedian forehead flap pedicle division after 7 days using laser-assisted indocyanine green angiography. *J Plast Reconstr Aesthet Surg* 74(1):116–122. <https://doi.org/10.1016/j.bjps.2020.05.079>
 82. Girard N, Delomenie M, Malhaire C, Sebbag D, Roulot A, Sabaila A, et al. (2019) Innovative DIEP flap perfusion evaluation tool: qualitative and quantitative analysis of indocyanine green-based fluorescence angiography with the SPY-Q proprietary software. *PLoS One* 14(6):e0217698. <https://doi.org/10.1371/journal.pone.0217698>
 83. Rother U, Muller-Mohnssen H, Lang W, Ludolph I, Arkudas A, Horch RE et al (2020) Wound closure by means of free flap and

- arteriovenous loop: development of flap autonomy in the long-term follow-up. *Int Wound J* 17(1):107–116. <https://doi.org/10.1111/iwj.13239>
84. Yang CE, Chung SW, Lee DW, Lew DH, Song SY (2018) Evaluation of the relationship between flap tension and tissue perfusion in implant-based breast reconstruction using laser-assisted indocyanine green angiography. *Ann Surg Oncol* 25(8):2235–2240. <https://doi.org/10.1245/s10434-018-6527-1>
 85. Colvard B, Itoga NK, Hitchner E, Sun Q, Long B, Lee G et al (2016) SPY technology as an adjunctive measure for lower extremity perfusion. *J Vasc Surg* 64(1):195–201. <https://doi.org/10.1016/j.jvs.2016.01.039>
 86. Rother U, Lang W, Horch RE, Ludolph I, Meyer A, Gefeller O et al (2018) Pilot assessment of the angiosome concept by intraoperative fluorescence angiography after tibial bypass surgery. *Eur J Vasc Endovasc Surg* 55(2):215–221. <https://doi.org/10.1016/j.ejvs.2017.11.024>
 87. Mironov O, Zener R, Eisenberg N, Tan KT, Roche-Nagle G (2019) Real-time quantitative measurements of foot perfusion in patients with critical limb ischemia. *Vasc Endovasc Surg* 53(4):310–315. <https://doi.org/10.1177/1538574419833223>
 88. Regus S, Klingler F, Lang W, Meyer A, Almasi-Sperling V, May M et al (2019) Pilot study using intraoperative fluorescence angiography during arteriovenous hemodialysis access surgery. *J Vasc Access* 20(2):175–183. <https://doi.org/10.1177/1129729818791989>
 89. Rother U, Lang W, Horch RE, Ludolph I, Meyer A, Regus S (2017) Microcirculation evaluated by intraoperative fluorescence angiography after tibial bypass surgery. *Ann Vasc Surg* 40:190–197. <https://doi.org/10.1016/j.avsg.2016.07.084>
 90. Rother U, Amann K, Adler W, Nawroth N, Karampinis I, Keese M, et al. (2019) Quantitative assessment of microperfusion by indocyanine green angiography in kidney transplantation resembles chronic morphological changes in kidney specimens. *Microcirculation* 26(3):e12529. <https://doi.org/10.1111/micc.12529>
 91. Phillips BT, Fourman MS, Rivara A, Dagum AB, Huston TL, Ganz JC et al (2014) Comparing quantitative values of two generations of laser-assisted indocyanine green dye angiography systems: can we predict necrosis? *Eplasty* 14:e44
 92. Phillips BT, Lanier ST, Conkling N, Wang ED, Dagum AB, Ganz JC et al (2012) Intraoperative perfusion techniques can accurately predict mastectomy skin flap necrosis in breast reconstruction: results of a prospective trial. *Plast Reconstr Surg* 129(5):778e–788. <https://doi.org/10.1097/PRS.0b013e31824a2ae8>
 93. Son GM, Kwon MS, Kim Y, Kim J, Kim SH, Lee JW (2019) Quantitative analysis of colon perfusion pattern using indocyanine green (ICG) angiography in laparoscopic colorectal surgery. *Surg Endosc* 33(5):1640–1649. <https://doi.org/10.1007/s00464-018-6439-y>
 94. Kamada T, Yoshida M, Suzuki N, Takeuchi H, Takahashi J, Marukuchi R et al (2020) Introduction of VISIONSENSE (R) for indocyanine green fluorescence-guided parathyroidectomy: report of a case. *Int J Surg Case Rep* 75:418–421. <https://doi.org/10.1016/j.ijscr.2020.09.139>
 95. Shah KJ, Cohen-Gadol AA (2019) The application of FLOW 800 ICG videoangiography color maps for neurovascular surgery and intraoperative decision making. *World Neurosurg* 122:e186–e197. <https://doi.org/10.1016/j.wneu.2018.09.195>
 96. van den Hoven P, Ooms S, van Manen L, van der Bogt KEA, van Schaik J, Hamming JF, et al. A systematic review of the use of near-infrared fluorescence imaging in patients with peripheral artery disease. *J Vasc Surg.* 2019;70(1):286–97 e1, <https://doi.org/10.1016/j.jvs.2018.11.023>.
 97. Pruijboom T, van Kuijk SMJ, Qiu SS, van den Bos J, Wieringa FP, van der Hulst R et al (2020) Optimizing indocyanine green fluorescence angiography in reconstructive flap Surgery: a systematic review and ex vivo experiments. *Surg Innov* 27(1):103–119. <https://doi.org/10.1177/1553350619862097>
 98. van den Bos J, Wieringa FP, Bouvy ND, Stassen LPS (2018) Optimizing the image of fluorescence cholangiography using ICG: a systematic review and ex vivo experiments. *Surg Endosc* 32(12):4820–4832. <https://doi.org/10.1007/s00464-018-6233-x>
 99. Slooter MD, Mansvelders MSE, Bloemen PR, Gisbertz SS, Bemelman WA, Tanis PJ, et al. (2021) Defining indocyanine green fluorescence to assess anastomotic perfusion during gastrointestinal surgery: systematic review. *Bjs Open* 5(2):ARTN zraa074 <https://doi.org/10.1093/bjsopen/zraa074>.
 100. Van Den Hoven P, Tange F, Van Der Valk J, Nerup N, Putter H, Van Rijswijk C, et al. Normalization of time-intensity curves for quantification of foot perfusion using near-infrared fluorescence imaging with indocyanine green. *J Endovasc Ther.* 2022:15266028221081085, <https://doi.org/10.1177/15266028221081085>.
 101. Wada H, Vargas CR, Angelo J, Faulkner-Jones B, Paul MA, Ho OA et al (2017) Accurate prediction of tissue viability at postoperative day 7 using only two intraoperative subsecond near-infrared fluorescence images. *Plast Reconstr Surg* 139(2):354–363. <https://doi.org/10.1097/PRS.0000000000003009>
 102. Heeman W, Vonk J, Ntziachristos V, Pogue BW, Dierckx R, Kruijff S et al (2022) A guideline for clinicians performing clinical studies with fluorescence imaging. *J Nucl Med* 63(5):640–645. <https://doi.org/10.2967/jnumed.121.262975>
 103. Wilkinson MD, Dumontier M, Aalbersberg IJ, Appleton G, Axton M, Baak A, et al. The FAIR guiding principles for scientific data management and stewardship. *Sci Data.* 2016;3:160018, <https://doi.org/10.1038/sdata.2016.18>.

Publisher's note Springer Nature remains neutral with regard to jurisdictional claims in published maps and institutional affiliations.