



Universiteit
Leiden
The Netherlands

The role of surgery in the treatment of oligoprogression after systemic treatment for advanced non-small cell lung cancer

Joosten, P.J.M.; Langen, A.J. de; Noort, V. van der; Monkhorst, K.; Klomp, H.M.; Veenhof, A.A.F.A.; ... ; Hartemink, K.J.

Citation


Joosten, P. J. M., Langen, A. J. de, Noort, V. van der, Monkhorst, K., Klomp, H. M., Veenhof, A. A. F. A., ... Hartemink, K. J. (2021). The role of surgery in the treatment of oligoprogression after systemic treatment for advanced non-small cell lung cancer. *Lung Cancer*, 161, 141-151. doi:10.1016/j.lungcan.2021.09.019

Version: Publisher's Version

License: [Creative Commons CC BY 4.0 license](#)

Downloaded from: <https://hdl.handle.net/1887/3638896>

Note: To cite this publication please use the final published version (if applicable).



The role of surgery in the treatment of oligoprogression after systemic treatment for advanced non-small cell lung cancer

P.J.M. Joosten^a, A.J. de Langen^b, V. van der Noort^c, K. Monkhorst^d, H.M. Klomp^a, A.A.F. A. Veenhof^a, C. Dickhoff^e, E.F. Smit^b, K.J. Hartemink^{a,*}

^a Department of Surgery, The Netherlands Cancer Institute-Antoni van Leeuwenhoek Hospital, Amsterdam, the Netherlands

^b Department of Thoracic Oncology, The Netherlands Cancer Institute-Antoni van Leeuwenhoek Hospital, Amsterdam, the Netherlands

^c Department of Biometrics, The Netherlands Cancer Institute-Antoni van Leeuwenhoek Hospital, Amsterdam, the Netherlands

^d Department of Pathology, The Netherlands Cancer Institute-Antoni van Leeuwenhoek Hospital, Amsterdam, the Netherlands

^e Department of Surgery and Department of Cardiothoracic Surgery, Amsterdam University Medical Center, location VUmc, Amsterdam, the Netherlands

ARTICLE INFO

Keywords:

Advanced NSCLC
Oligoprogression
Surgery
Outcome

ABSTRACT

Objectives: Patients with advanced stage non-small cell lung cancer (NSCLC) are generally considered incurable. The mainstay of treatment for these patients is systemic therapy. The addition of local treatment, including surgery, remains controversial. Oligoprogression is defined as advanced stage NSCLC with limited progression of disease after a period of prolonged disease stabilisation or after a partial or complete response on systemic therapy. In this retrospective study we evaluated outcome and survival of patients who underwent a resection for oligoprogression after systemic therapy for advanced stage NSCLC.

Materials and Methods: Patients with oligoprogression after systemic treatment for advanced NSCLC who were operated in the Antoni van Leeuwenhoek Hospital were included. Patient and treatment characteristics were collected in relation to progression free survival (PFS) and overall survival (OS).

Results: Between January 2015 and December 2019, 28 patients underwent surgery for an oligoprogresive lesion (primary tumor lung (n = 12), other metastatic site (n = 16)). Median age at time of resection was 60 years (39–86) and 57% were female. Postoperative complications were observed in 2 patients (7%). Progression of disease after resection of the oligoprogresive site was observed in 17 patients (61%). Median PFS was 7 months since date of resection (95% CI 6.0–25.0) and median OS was not reached. Seven patients (25%) died during follow-up. Age was predictive for OS and clinical T4 stage was predictive for PFS. M1 disease at initial presentation was predictive for better PFS compared to patients who were diagnosed with M0 disease initially. Patients who underwent resection because of oligoprogression of the primary lung tumour had a better PFS, when compared to oligoprogression of another metastatic site.

Conclusion: Surgical resection of an oligoprogresive lesion in patients with advanced NSCLC treated with systemic treatment is feasible and might be considered in order to achieve long term survival.

1. Introduction

About half of all patients with non-small cell lung cancer (NSCLC) have metastatic disease at first presentation [1–3]. Furthermore, many patients with local or locally advanced NSCLC will develop metachronous metastasis during the course of the disease [4,5]. Metastatic NSCLC is considered incurable with a high cancer related mortality rate [6–8]. Although survival has improved with the introduction of immunotherapy for advanced (stage IV) NSCLC, the disease will eventually progress [9–11]. For some

patients, disease progression is limited to the primary tumour or to one or only a few distant metastasis i.e. oligoprogression [12]. For these patients, several treatment strategies have been reported to improve outcome, e.g. a systemic treatment followed by a local consolidative therapy such as stereotactic body radiation therapy (SBRT) or surgical resection [13,14]. However, surgery for oligoprogression in metastatic NSCLC has only been investigated to a limited extent [13–16]. In this study we report outcome and survival of patients who underwent a resection for an oligoprogresive lesion after systemic therapy for stage IV NSCLC.

* Corresponding author at: Department of Surgery, Plesmanlaan 121, 1066 CX Amsterdam, The Netherlands.

E-mail address: k.hartemink@nki.nl (K.J. Hartemink).

<https://doi.org/10.1016/j.lungcan.2021.09.019>

Received 3 March 2021; Received in revised form 8 September 2021; Accepted 21 September 2021

Available online 27 September 2021

0169-5002/© 2021 Elsevier B.V. All rights reserved.

Table 1
Patient-, tumour- and treatment characteristics.

| | Total (n = 28) |
|---|----------------|
| Age, years | |
| Median (range) | 60 (39–86) |
| Gender (%) | |
| Male | 12 (43) |
| Female | 16 (57) |
| Charlson Comorbidity Index (%) | |
| 6–7 | 19 (67.9) |
| 8+ | 9 (32.1) |
| Clinical T-stage at initial diagnosis (%) | |
| cT1 | 3 (10.7) |
| cT2 | 8 (28.6) |
| cT3 | 6 (21.4) |
| cT4 | 5 (17.9) |
| cTx | 6 (21.4) |
| Clinical N-stage at initial diagnosis (%) | |
| cN0 | 3 (10.7) |
| cN1 | 2 (7.1) |
| cN2 | 10 (35.7) |
| cN3 | 11 (39.3) |
| cNx | 2 (7.1) |
| Clinical M-stage at initial diagnosis (%) | |
| cM0 | 5 (17.9) |
| cM1 | 23 (82.1) |
| Histology (%) | |
| Adenocarcinoma | 26 (92.9) |
| Squamous cell carcinoma | 1 (3.4) |
| Large cell neuro endocrine carcinoma | 1 (3.4) |
| Number of metastasis (%) | |
| 1 | 3 (10.7) |
| 2–5 | 15 (53.6) |
| 6+ | 10 (35.7) |
| Localization of metastases by presentation | |
| Adrenal gland | 11 |
| Bone | 11 |
| Pulmonary | 8 |
| Liver | 5 |
| Spleen | 2 |
| Lymph node | 5 |
| Brain | 7 |
| Type of systemic treatment (%) | |
| Chemotherapy | 3 (10.7) |
| Chemoradiotherapy | 1 (3.6) |
| Targeted therapy | 6 (21.4) |
| Immunotherapy | 4 (14.3) |
| Chemotherapy + targeted therapy | 6 (21.4) |
| Chemotherapy + immunotherapy | 4 (14.3) |
| Chemoradiotherapy + immunotherapy | 1 (3.6) |
| Targeted therapy + immunotherapy | 2 (7.1) |
| Chemotherapy + targeted therapy + immunotherapy | 1 (3.6) |
| Radiotherapy | |
| Brain | 4 |
| Bone | 3 |
| Progression of lung tumour | 3 |
| Adrenal gland | 2 |
| Axillary lymph node | 1 |
| Type of resection oligoprogression (%) | |
| Primary lung tumour | 12 (42.9) |
| Lobectomy | 6 (21.4) |
| Sublobar resection | 3 (10.7) |
| Wedge resection | 3 (10.7) |
| Adrenal | 11 (39.3) |
| Laparoscopic | 10 (35.7) |
| Open | 1 (3.6) |
| Axillary lymph node | 3 (10.7) |
| Liver | 2 (7.1) |
| Hemihepatectomy | 1 (3.6) |
| Laparoscopic | 1 (3.6) |
| Pathological examination (%) | |
| R0 | 26 (92.9) |
| R1 | 1 (3.6) |
| R2 | 1 (3.6) |
| Additional systemic treatment (%) | 16 (57.1) |

Table 1 (continued)

| | Total (n = 28) |
|----------------------------|----------------|
| Progression of disease (%) | |
| Progression | 17 (60.7) |
| No progression | 11 (39.3) |

2. Material and methods

2.1. Patient cohort

This retrospective cohort analysis was performed after approval of the Institutional Review Board (IRBd20-248). Included were patients with stage IV NSCLC who underwent surgery for oligoprogression after systemic therapy in a tertiary referral hospital, the Netherlands Cancer Institute - Antoni van Leeuwenhoek Hospital, between January 2015 and December 2019. Oligoprogression was defined as progression of any tumor site (primary tumour, lymph node or metastasis) during or after systemic treatment for metastatic NSCLC with initial complete or partial response (as judged in the multidisciplinary tumour board meeting (MTB)) [12]. Patients were included if they underwent resection of the recurrent or persistent metastatic lesion or recurrence of the primary tumour. For inclusion, there was no limit in the number of metastases at the time of initial diagnosis. Patients with a second primary tumour were excluded. Routinely, a chest computed tomography (CT) scan, a fluoro-deoxyglucose (FDG) position-emission tomography (PET)-CT scan and a magnetic resonance imaging (MRI) scan of the brain were performed prior to surgery to confirm oligoprogression and exclude other or new metastases. Pathological confirmation was preferred. Patients were discussed in a MTB meeting, which consists of surgeons, thoracic oncologists, radiation oncologists, a radiologist, nuclear medicine specialist and a pathologist. Patients were offered resection if systemic therapy initially had resulted in either a period of stable disease or a partial or complete response, at the discretion of the treating multidisciplinary team.

Following data were extracted from our institutional database: age, sex, Charlson Comorbidity Index (CCI), tumour stage, date of diagnosis of the primary tumour, different systemic treatments and staging modalities. Surgical factors we evaluated were date of surgery, type and location of resection, lymph node dissection, pathological outcome after resection, in-hospital complications and in-hospital length of stay and mortality. Pathological findings of the resected tumour included histological grade, mutational status and PD-L1 status. A PD-L1 test measures what percentage of cells in a tumor “express” PD-L1, with tumors expressing high amounts of PD-L1 (>50%) possibly responding particularly well to checkpoint inhibitors. Patients who had PD-L1 > 50% were noted as “PD-L1”, for the other patients who had less percentages we added the exact measured percentages.

The paper was written according to the STROBE checklist (strengthening the reporting of observational studies in epidemiology) [17].

3. Objectives of the study

The primary objective of the study is to describe the feasibility and safety of a resection for an oligoprogressive lesion.

The secondary objective is to assess the overall survival (OS) and progression free survival (PFS) after surgery for oligoprogression.

Moreover, a more explorative objective is to assess which (if any) patient characteristics are associated with longer PFS and OS in this setting.

Part of these objectives is to see whether mortality and morbidity are low enough to consider surgery for oligoprogression feasible.

3.1. Statistical analysis

Data are presented as medians with either range or inter quartile range (IQR) for continuous data, and number of cases with percentage for count data.

Follow-up time was computed from date of initial diagnosis and from date of the resection of the oligoprogressive site. Progression free survival (PFS) and overall survival (OS) distributions were analyzed using the Kaplan-Meier method. PFS was computed from the date of the resection to the date of progression of disease (recurrence or metastasis) or death due to any cause. OS was defined as the time between date of resection and death of any cause. Patients alive without recurrence or metastasis were censored for OS at the date of their last follow-up and for PFS at the date of their last CT-scan.

Possible factors at the time of restaging for survival were evaluated with Cox proportional hazard analysis. The following prognostic factors were analyzed: age per year, CCI score (8 + vs 6–7), clinical T-stage (cT4 vs cT1–3), clinical N-stage (cN2–3 vs cN0–1), clinical M–stage (M1 vs M0), number of metastasis (1 vs 2 +), type of systemic therapy (chemotherapy, targeted therapy, immunotherapy), time between systemic therapy and resection, presence of adrenal gland metastasis, oligoprogression of the lung tumour, adjuvant therapy after resection of the oligoprogressive site.

Differences in PFS and OS between prognostic factors are represented by the hazard ratio (HR) and 95% confidence intervals (CI). Statistical significance was defined as $p \leq 0.05$. No correction for multiple testing was performed due to the exploratory nature of this analysis. All analyses performed are reported regardless of outcome.

Statistical analysis was performed using SPSS software package (SPSS, version 26, SPSS inc, Chicago, IL, USA and R version 4.0, R core team, Vienna, Austria).

4. Results

4.1. Patient and treatment characteristics

Between 2015 and 2019, 28 patients were identified who underwent resection for oligoprogression of NSCLC. At the time of initial diagnosis 23 patients were clinical stage IV NSCLC and treated with systemic therapy, and five patients (clinical stage IA (n = 1), stage IIIA (n = 2) and stage IIIB (n = 2)) of whom 4 had curative intent resection of the primary tumor, developed a metastasis during follow-up for which systemic therapy was started. In addition to systemic therapy, 13 patients underwent radiotherapy (RT) (SBRT brain metastasis n = 4, stereotactic radiosurgery (SRS) bone metastasis n = 3, RT because of progression of the lung tumour n = 3, RT at an adrenal gland metastasis n = 2, RT at an axillary lymph node metastasis n = 1). In 2 patients, resection of a brain metastasis was performed. Clinical nodal involvement at initial diagnosis was cN0 (n = 3), cN1 (n = 2), cN2 (n = 10), cN3 (n = 11) and in 2 patients the nodal status was unknown. Of all patients, 26 were diagnosed with adenocarcinoma, 1 patient had squamous cell carcinoma and 1 patient had a large cell neuroendocrine carcinoma. Detailed patient-, tumour- and treatment characteristics are presented in Tables 1 and 2. Twelve patients (41%) had a resection because of oligoprogression of the primary lung tumour (lobectomy n = 6, sublobar resection n = 3, wedge resection n = 3). Lung resections were performed with parenchymal sparing intent, preferably a wedge resection or segmentectomy. In case of a centrally located lung tumour, a lobectomy was performed and lymph nodes were resected only if these were suspected of malignancy. In total, 11 patients had resection of an adrenal gland metastasis (laparoscopic resections n = 10, open resection n = 1), in 3 patients, an axillary lymph node metastasis was resected, 1 patient underwent a hemihepatectomy and in 1 patient a laparoscopic segmental (segment 3) resection of the liver was performed. In all patients, a resection of one (metastatic or primary tumour) lesion was done. The median time between start of systemic therapy after initial diagnosis and resection of the oligoprogressive lesion was 26 months (range 5–60). Median age at the time of resection of the oligoprogressive site was 60 years (range 39–86). Surgical data and follow-up of the patients are summarized in Table 3. Pathological confirmation of disease recurrence or progression was established in 18/28 (64%) patients and 10 patients (adrenal gland

n = 4, primary lung tumour n = 4, spleen n = 1) underwent resection without preoperative pathological confirmation of malignancy.

4.2. Surgical outcome

Postoperative complications were observed in 2 patients; 1 patient developed atrial fibrillation after lobectomy of the right lower lobe and 1 patient developed a pulmonary embolism for which anticoagulants were started and had a postoperative ileus (after an open adrenal gland resection), which was treated conservatively.

Pathological examination of the resected specimen confirmed a tumour free resection margin in 26 (93%) patients. An irradical resection was observed in 2 patients (1 patient had a microscopically irradical (R1) resection after laparoscopic adrenal gland resection and 1 patient had a macroscopically irradical (R2) resection after a pulmonary wedge resection). In Table 3 pathological findings of the resected sites were described, including mutational, immunohistochemistry and programmed death-ligand 1 (PD-L1) status. We noted the tumor suppressor genes (TP53, P63, TTF1, CDX-2, P53) and proto-oncogenes (ROS1, ERBB2, BRAF V600, KRAS, EGFR), which were positive/mutated. In 17 patients, systemic therapy was continued after resection of the oligoprogressive lesion.

4.3. Progression free survival and overall survival

During follow-up after resection of the oligoprogressive site, 17 patients (61%) had distant progression of disease and 5 patients (18%) had a locoregional recurrence (irradical resection (R2) n = 1). All of the patients who developed a locoregional recurrence had also distant progression of disease. After surgery, median PFS was 7 months (95% CI 6.0–25.0) (Fig. 1) and 11 of the 17 patients with progression of disease were alive at the last date of follow-up (Table 3). Six patients died due to progression of disease (median 9 months (3–15)) and 1 patient died within 1 month after resection due to pulmonary embolism. Median OS was not reached (Fig. 2). One- and two-year survival after surgery were 48% and 21%, respectively. Median follow-up from date of initial diagnosis was 44 months (95% CI 36.0–54.0).

4.4. Prognostic factors

Prognostic factors are shown in Table 4: the presence, but not the number of metastasis at initial diagnosis, was predictive for PFS but not for OS. Patients who had clinical T4 stage at first diagnosis had inferior PFS compared with patients who had clinical T1–3 stage, however, no significant differences in OS were seen between these groups. Clinical N-stage was not predictive for neither PFS or OS (Table 4).

Patients with resected progression of the primary lung tumour, had superior PFS compared to patients who had surgery for an oligoprogressive lesion not located in the lung, although OS did not significantly differ. We observed a non-statistically-significant difference in survival between patients that had an adrenalectomy and patients after resection of another site of oligoprogression; HR 1.86 for OS (95% CI 0.75–4.6, $p = 0.18$) and HR 4.14 for PFS (95% CI 0.83–20.58, $p = 0.08$). Patients who had immunotherapy as part of systemic treatment (n = 12) had PFS and OS comparable to those patients whose systemic treatment did not include immune checkpoint inhibition (n = 16).

5. Discussion

In this retrospective study, we show that surgical resection of an oligoprogressive lesion in selected patients with stage IV NSCLC treated with systemic treatment is feasible. All patients showed partial or complete response after initial treatment and had a recurrence of the primary tumour in the lung or progression of disease at a limited number of metastatic sites during follow-up.

Data concerning the role of surgery in the oligoprogressive setting, in patients who are treated with systemic therapy for metastatic disease

Table 2
Detailed patient-, tumour- and treatment characteristics of patients treated for oligoprogressive NSCLC.

| Patient | Year of initial diagnosis | Year of resection | Sex | Age at diagnosis | CCI | cTNM at initial diagnosis NSCLC | Histology and mutation | Localisation metastasis | Systemic therapy | Time between start systemic therapy and resection for oligoprogression (months) |
|---------|---------------------------|-------------------|-----|------------------|-----|---------------------------------|---|--------------------------------------|---|---|
| 1 | 2011 | 2015 | M | 66 | 10 | T1bN1M1 | AC | Adrenal, Bone | 2011 cisplatin/ gemcitabine + RT L2; 2013 carboplatin/ gemcitabine; 2014 carboplatin/ pemetrexed; 2015 RT lung/N10 + olaparib + adrenal resection | 51 |
| 2 | 2014 | 2017 | F | 54 | 7 | T2bN3M1ab | AC, EGFR, TP53 | Pulmonary, liver, spleen, bone | 2014-8 gefitinib (EGFR exon 21 mutation); 03-2017 lung resection | 31 |
| 3 | 2016 | 2017 | M | 52 | 6 | T3N3M1 | AC. TTF1 | Pulmonary, pulmonary gland | 2016 erlotinib (EGFR mutation); 2017 lung resection | 19 |
| 4 | 2015 | 2017 | M | 64 | 9 | T4N2M0 | AC. TP53, PD- L1 (5%) | Both adrenal glands | 2015 cisplatin + RT lung; 2017-07 SBRT adrenal gland left and resection right-sided | 21 |
| 5 | 2016 | 2017 | M | 62 | 8 | T3N3M1 | AC. Keratine 7 | Pulmonary | 2016 nivolumab/ ipilimumab; 2017 lung resection | 16 |
| 6 | 2016 | 2017 | F | 63 | 7 | T4N2M1 | AC. cMET, exon 14 deletion | Brain | 2016 SBRT brain metastasis; 2016-12 cisplatin/ pemetrexed; 2017-01 carboplatin/ pemetrexed; 2017-05 capmatinib (INC280); 2017-12 lung resection | 12 |
| 7 | 2016 | 2017 | F | 48 | 6 | T3N3M1 | AC. KRAS, TTF1, STK11, PD-L1 (2%), HER2 (3%) | Axillair lymph node | 2016-02 cisplatin/ pemetrexed; 2016-09 docetaxel; 2016-11 nivolumab; 2018-01 resection axillair lymph node | 27 |
| 8 | 2016 | 2018 | F | 65 | 8 | TxN3M1 | AC. TTF1, BRAF V600E | Bone | 2016-06 carboplatin/ pemetrexed; 2016-07 RT costa 11 2016-10 dabrafenib/ trametinib 2017-11 RT ischium + RT costa 11 2018-01 resection lingula | 20 |
| 9 | 2016 | 2018 | M | 46 | 6 | T3N0M1 | AC. CK7, CAM 5.2, CD56 | Adrenal | 2017-08 cisplatin/ gemcitabine; 03-2018 lung resection | 8 |
| 10 | 2017 | 2018 | M | 57 | 7 | T4N3M1 | AC. KRAS Q61K, PD-L1, TTF1 | Pulmonary | 2017-10 pembrolizumab 2018-05 lung resection | 8 |
| 11 | 2017 | 2018 | M | 54 | 7 | T2N2M1 | AC. Exon 19 EGFR | Brain, bone | 2017-03 SBRT brain metastasis; 2017-05 erlotinib; 2018-03 osimertinib; 2018-07 lung resection | 16 |
| 12 | 2016 | 2018 | F | 56 | 6 | T2NxM1 | AC. CK7, TTF1 | Brain | 2016-04 SRT brain metastasis + cisplatin/ pemetrexed; 2018-07 lung resection | 17 |
| 13 | 2017 | 2018 | M | 34 | 6 | T3N2M1 | AC | Both adrenal glands | 2017-02 cixplatin/ pemetrexed; 2017-09 pembrolizumab; 2018-09 resection left adrenal | 60 |
| 14 | 2017 | 2018 | F | 65 | 9 | T2N2M1 | AC. Exon 19 EGFR, TP53, | Liver, bone, brain | 2017-04 EGF816; 2018-10 resection liver | 35 |

(continued on next page)

Table 2 (continued)

| Patient | Year of initial diagnosis | Year of resection | Sex | Age at diagnosis | CCI | cTNM at initial diagnosis NSCLC | Histology and mutation | Localisation metastasis | Systemic therapy | Time between start systemic therapy and resection for oligoprogression (months) |
|---------|---------------------------|-------------------|-----|------------------|-----|---------------------------------|--------------------------------------|--------------------------------------|---|---|
| 15 | 2017 | 2018 | F | 68 | 8 | T1N2M1 | TTF1, cMET, HER2 NET, PD-L1 (80%) | Adrenal, bone | 2017-01 carboplatin/ pemetrexed; 2017-05 pemetrexed; 2018-10 adrenal gland resection | 28 |
| 16 | 2013 | 2018 | M | 51 | 7 | T1N0M0 | AC. ALK | Intra-abdominal lymph nodes, Adrenal | 2013-09 Lobectomy right upper lobe; 2017-07 alectinib; 2018-10 resection right adrenal gland | 26 |
| 17 | 2015 | 2018 | F | 48 | 6 | T3N1M0 | AC. EGFR | Adrenal, pulmonary, brain | 2015-11 Lobectomy right upper lobe, adjuvant carboplatin/ pemetrexed; 2017-01 erlotinib; 2017-04 debulking brain metastasis; 2017-10 osimertinib; 2017-11 SBRT adrenal; 2018-12 resection adrenal gland | 14 |
| 18 | 2016 | 2018 | F | 62 | 7 | TxN3M0 | AC. MET, TP53, PD-L1 | Bone, adrenal, Axillar lymph node | 2016-06 carboplatin/ pemetrexed; 2016-09 RT + olaparib; 2017-11 pemproluzimab; 2019-01 resection adrenal gland | 53 |
| 19 | 2016 | 2019 | M | 81 | 10 | T4N2M1 | AC. MET exon 14, PD-L1 | Adrenal, bone, brain | 2016-08 carboplatin/ pemetrexed; 2017-10 RT lung; 2018-08 crizotinib; 04-2019 resection adrenal gland | 57 |
| 20 | 2017 | 2019 | F | 47 | 6 | TxN3M1 | AC. TTF1, ALK, PD-L1 (40%), AE1/3 | Liver, pulmonary | 2017-11 pembrolizumab; 2017-11 crizotinib; 2018-03 alectinib; 2018-04 ceritinib 2019-05 resection liver | 30 |
| 21 | 2014 | 2019 | F | 72 | 10 | TxN2M1 | AC. EGFR | Pulmonary | 2014-08 Wedge resection right upper + middele lobe; 2014-09 gefitinib; 2018-02 osimertinib; 2019-05 lung resection | 68 |
| 22 | 2016 | 2019 | F | 70 | 9 | T2N2M0 | AC. TTF1 | Adrenal | 2016-07 Lobectomy; adjuvant cisplatin/ pemetrexed; 2017-07 cisplatin; 2018-03 osimertinib; 2019-05 resection adrenal gland | 29 |
| 23 | 2018 | 2019 | M | 56 | 7 | T4N0-1 M1 | AC. KRAS, IDH1, TP53, PD-L1 | Brain, spleen | 2018-11 resection brain metastasis; 2019-01 RT + cisplatin/ pemetrexed; 2019-03 nivolumab; 2019-06 resection spleen | 39 |
| 24 | 2016 | 2019 | F | 44 | 6 | T2N3M1 | AC. KRAS | Brain, liver, adrenal | 2016-01 SRT brain metastasis; 2017-04 SRT brain metastasis; 2017-07 BMS-986016 + nivolumab; 2019-06 resection adrenal | 30 |
| 25 | 2017 | 2019 | F | 64 | 7 | T2N3M1 | AC. | Pulmonary | 2017-05 cisplatin/ pemetrexed; | 30 |

(continued on next page)

Table 2 (continued)

| Patient | Year of initial diagnosis | Year of resection | Sex | Age at diagnosis | CCI | cTNM at initial diagnosis NSCLC | Histology and mutation | Localisation metastasis | Systemic therapy | Time between start systemic therapy and resection for oligoprogression (months) |
|---------|---------------------------|-------------------|-----|------------------|-----|---------------------------------|--|-------------------------|--|---|
| 26 | 2018 | 2019 | F | 53 | 7 | T2N2M1 | AC. TP53, PD-L1 | Bone, liver, adrenal | 2017-09 pembrolizumab; 2019-09 resection lung 2018-01 pembrolizumab; 2019-10 resection adrenal gland | 23 |
| 27 | 2017 | 2019 | F | 64 | 7 | TxNxM1 | SCC. KRAS, PD-L1, keratine AE1/3, CK7, p63 en CK5/6 | Bone | 2017-12 RT bone metastasis; 2018-01 pembrolizumab; 2018-01 + 2018-10 RT bone metastasis; 2019-11 resection lung | 23 |
| 28 | 2015 | 2019 | M | 52 | 7 | TxN3M1 | AC. Keratine AE1/3, TTF1, TP53, PD-L1, HER2 | Axillar lymph node | 2015-09 carboplatin/pemetrexed; 2016-05 – 2017-04 nivolumab; 2018-04 pembrolizumab; 2019-03 RT left axillar lymph node 019-12 resection right axillar lymph node | 51 |

M = male, F = female, CCI = Charlson Comorbidity Index, NSCLC = non-small cell lung cancer, AC = adenocarcinoma, SCC = squamous cell carcinoma, RT = radiotherapy, PA = pathology, PD-L1 = Programmed death-ligand 1, TTF1 = Thyroid transcription factor-1, EGFR = Epidermal growth factor receptor, ALK = Anaplastic lymphoma kinase, HER2 = human epidermal growth factor receptor-2, ATM = ataxia telangiectasia mutated, N.A. = not applicable.

and who develop progression of disease after initial complete or partial response, is limited [18–20]. Previous studies describing stage IV NSCLC focused mainly on limited synchronous (oligometastatic) disease and showed that in selected patients, systemic treatment in combination with treatment of the metastasis with radiation therapy or surgery can improve DFS and OS [15,21–23].

The impact of surgical treatment on survival of patients with advanced NSCLC, remains controversial [24–26]. Improvements in lung cancer diagnosis and treatments in the past decade, with the addition of targeted therapies and immunotherapy have, at least partly, accounted for the improvement of PFS and OS in patients with advanced NSCLC [9,27,28]. Part of these patients develop oligoprogressive disease and the optimal therapy, in particular local therapies including SBRT and resection, remains unclear [26,29].

Selecting the patients who will benefit most from this oligoprogressive approach is challenging. The main question to be answered during MTB discussion is how to best select patients who may benefit most from surgery. Although follow-up was relatively short, we found that surgery in the oligoprogressive setting can be performed with minimal morbidity and with encouraging survival. In the treatment of metastatic disease, 79% of our selected patients received targeted therapy or immunotherapy prior to surgical resection. It is suggested that immunotherapy improves systemic control resulting in better controlled metastatic disease, with local recurrences having a more prominent role during follow-up [10,11,30]. These local recurrences with a controlled systemic situation, defined as oligoprogression might thus be suitable for a local resection to improve local tumour control [31,32].

In our study, patients with metastasis at initial presentation showed significantly improved PFS when compared to patients who had no metastasis at presentation but developing a metastasis during follow-up. A possible explanation might be that patients with M1 disease who showed no progression under systemic treatment have favourable prognostic biologic tumour characteristics when compared with patients initially staged without metastases (M0) and who develop 1 or more metastases after curative intent treatment (e.g. surgery). Improved PFS

was also found in patients in whom the primary lung tumour was an oligoprogressive site. However, these results should be interpreted with care, since the number of included patients is limited and the group of selected patients is heterogeneous.

Despite resection of the oligoprogressive lesion, progression of disease was found in 68% of patients during follow-up after resection. Whether surgery is beneficial over switching systemic therapy without resection, is unclear. Previously, it was shown that for selected patients receiving local therapy, the median progression free survival was 14 months compared to 7.2 months for those without local therapy [18]. Although only SBRT was used as local therapy in this study, it was suggested that additional local therapy improved the PFS. Moreover, in our study 11 out of the 17 patients who had progression of disease after surgery are still alive at the end of follow-up.

The goal of surgery for oligoprogressive disease is to control local disease. On the other hand, resection of an oligoprogressive lesion might postpone the start of systemic therapy in selected patients and thereby reducing the possible impact of side effects caused by chemotherapy or immunotherapy [33,34]. Also, local control through resection might allow selected patients to continue the targeted therapy and may delay the switch to other systemic treatment options [35]. In addition, resection of an oligoprogressive lesion provides the treating physician the opportunity for tissue analysis by the pathologist, possibly discovering new targetable mutations and an explanation why the oligoprogressive lesion was progressive, but all other lesions were responsive to systemic treatment given [36,37]. A targetable driver mutation (e.g. anaplastic lymphoma kinase (ALK) or epidermal growth factor receptor (EGFR)) or the presence of PD-L1 expression provides the opportunity to start additional targeted therapy after resection of the oligoprogressive lesion [38].

6. Conclusions

In conclusion, in selected patients with stage IV NSCLC, resection of an oligoprogressive lesion is feasible and safe. Although its exact impact on PFS and OS has to be further investigated, surgical resection of the

Table 3

Surgical details, morbidity, follow-up and survival of patients treated for.

| Patient | Metastasis progression | Lung progression | Type of resection | In-hospital complication | Hospital stay (days) | Radicality | PA assessment; IHC results; mutation status | Adjuvant therapy | Loco-regional recurrence | Distant metastasis and therapy | Time to progression (months) | Survival (months) |
|---------|-------------------------------|------------------|---------------------------|--------------------------|----------------------|------------|--|---------------------------------------|--------------------------|--|------------------------------|------------------------|
| 1 | Adrenal | No | LA | – | 3 | R0 | AC; PD-L1 (+), TTF1 (+) | No | No | No | – | ≥58 |
| 2 | No | Yes | L + wedge | – | 6 | R0 | AC; TTF1 (+), keratine AE1/3 (+) | Gefitinib; 2017-5 Erlotinib | No | Yes, 3 brain metastasis 05-2019 SRS | 25 | ≥36 |
| 3 | No | Yes | Bisegmental Wedge lingula | – | 6 | R2 | SCC; P63 (+), TTF1 (+) | Erlotinib | Yes, RT hilus 09-2018 | Yes, brain metastasis, 11-2018 osimertinib | 15 | ≥31 |
| 4 | Both adrenal glands (Left RT) | No | LA right sided | – | 3 | R1 | AC; TTF1 (+), keratine 7 (+), P53 (+) | No | No | Yes, lung metastasis 02-2018 cis/pem, 11-2018 nivolumab | 5 | 10 |
| 5 | No | Yes | Segmentectomy | – | 5 | R0 | AC; None | No | No | No | – | ≥29 |
| 6 | No | Yes | L | Atrial fibrillation | 12 | R0 | AC; PD-L1 (+), TTF1 (+), P63 (+); TP53 mutated | Capmatinib | No | Yes, intra-pulmonary metasis | 5 | 8 |
| 7 | Axillair lymph node | No | Lymph node extirpation | – | 2 | R0 | AC; N.A. | No | No | Yes, 11-2018 intra-pulmonary, nivolumab | 6 | ≥11 |
| 8 | Bone (RT) | Yes, lingula | Lingula excision | – | 6 | R0 | AC; PD-L1 (+), TTF1 (+); BRAF V600E mutated | Dabrefinib/trametinib | No | No | – | ≥26 |
| 9 | No | Yes | L | – | 5 | R0 | AC; N.A. | No | No | No | – | ≥24 |
| 10 | Pulmonary | No | Wedge resection | – | 4 | R0 | AC; N.A. | Pemprolzumab | No | Yes, lymph node axillar 08-2018 excision. 05-2019 progression pem/cis | 2 | ≥21 |
| 11 | No | Yes | L | – | 5 | R0 | AC; TTF1 (+); EGFR exon 1, KRAS and TP53 mutated | Osimertinib | No | Yes, metastasis adrenal gland resection 12-2019. RT os ilium metastasis. | 16 | ≥20 |
| 12 | No | Yes | L | – | 5 | R0 | AC; PD-L1 (5%), ROS1 fusion (+) | No | No | Yes, brain metastasis; 01-2019 SRS 07-2019 SRS, 01-2020 SRS | 6 | ≥20 |
| 13 | Adrenal | No | LA left sided | – | 2 | R0 | AC; TP53 and ERBB2 mutated | Pembrolizumab | No | Yes, 02-2019 brain metastasis SRS, 07-2019 adrenal R resection | 4 | ≥18 |
| 14 | Liver | No | Hemihepatectomy | – | 7 | R0 | AC; TTF1 (+), p53 (+) | EGF816 04-2019 osimertinib/crizotinib | No | No | – | ≥17 |
| 15 | Adrenal | No | LA | – | – | R0 | AC; PD-L1 (+) | Pemprolzumab | Adrenal | Yes, intra-abdominal | 3 | 7 |
| 16 | Adrenal | No | LA | – | 2 | R0 | AC; PD-L1 (+), TTF1 (+), ALK (+); ALK and TP53 mutated | Alectinib | Adrenal | Yes, 03-2019 brigatinib progression loco-regional adrenal. 06-2019 progression witch loratinib. 11-2019 progression carboplatin/pemetrexed | 13 | ≥17 |
| 17 | Brain (debulking), Adrenal | No | LA | – | – | R0 | AC; TTF1 (+); Exon 19 EGFR mutated | Osimertinib | Adrenal | Yes, 06-2019 progression lung, brain and adrenal, start carboplatin/paclitaxel/ bevacuzimab | 3 | 15 |
| 18 | Adrenal | No | LA | – | 4 | R0 | AC; TTF1 (+), GATA3 (+) | No | No | No | – | 1 (pulmonary embolism) |
| 19 | Adrenal, Brain | No | Adrenalectomy left | – | 25 | R0 | AC; MET exon 14 splice mutation | No | No | No | 1 | 3 |

(continued on next page)

Table 3 (continued)

| Patient | Metastasis progression | Lung progression | Type of resection | In-hospital complication | Hospital stay (days) | Radicality | PA assessment; IHC results; mutation status | Adjuvant therapy | Loco-regional recurrence | Distant metastasis and therapy | Time to progression (months) | Survival (months) |
|---------|------------------------|------------------|--------------------------|--------------------------------|----------------------|------------|---|----------------------|--------------------------|---|------------------------------|-------------------|
| 20 | Liver | No | Segment 3 resection | Pulmonary embolism, ileus – | 2 | R0 | AC; N.A. | Ceritinib | No | Yes, 05-2019 progression lung and adrenal gland right Yes, 12-2019 liver metastasis, pemetrexed/ carboplatin | 7 | ≥10 |
| 21 | Pulmonary | No | Wedge | – | | R0 | AC; PD-L1 (10%); EGFR and TP53 mutated | Osimertinib | Gland N5 | Yes, 10-2019 resection N5 | 8 | 9 |
| 22 | Adrenal | No | LA | – | 2 | R0 | AC; PD-L1 (1%), HER2 (5%); EGFR and TP53 mutated, MET amplification | Osimertinib | No | Yes, 01-2020 RT C6-Th1, 03-2020 crizotinib | 6 | ≥10 |
| 23 | Spleen | No | Laparoscopic splenectomy | – | 5 | R0 | AC: KRAS, TP53, KEAP1 and ASXL1 mutated, IDH1 hotspot mutation | No | No | No | – | ≥9 |
| 24 | Adrenal | No | LA | – | 2 | R0 | AC; N.A. | No | Lung | Yes, 03-2020 RT lung, 05-2020 RT brain + nivolumab | 8 | ≥9 |
| 25 | No | Yes | Wedge | – | 4 | R0 | AC; PD-L1 (+), KRAS and TP53 mutated | Pembrolizumab, RT N5 | No | No | – | ≥6 |
| 26 | Adrenal | No | LA | – | 4 | R0 | AC; CDKN2A and TP53 mutated | Pembrolizumab | No | No | – | ≥5 |
| 27 | No | Yes | RATS L + Wedge | – | 7 | R0 | AC; PD-L1 (+); KRAS mutated | Pembrolizumab | No | No | – | ≥4 |
| 28 | Axillair lymph node | No | Lymph node extirpation | – | 2 | R0 | AC; TTF1 (+) | No | No | No | – | ≥3 |

oligoprogressive NSCLC.

LA = laparoscopic adrenalectomy, L = lobectomy, RATS = robot-assisted thoracoscopic surgery, R = residual tumour, RT = radiotherapy, AC = adenocarcinoma, SCC = squamous cell carcinoma, PA = pathology, IHC = Immunohistochemistry, PD-L1 = Programmed death-ligand 1, TTF1 = Thyroid transcription factor-1, EGFR = Epidermal growth factor receptor, ALK = Anaplastic lymphoma kinase, HER2 = human epidermal growth factor receptor-2, ATM = ataxia telangiectasia mutated, N.A. = not applicable. Note; in all patients, one lesion was resected.

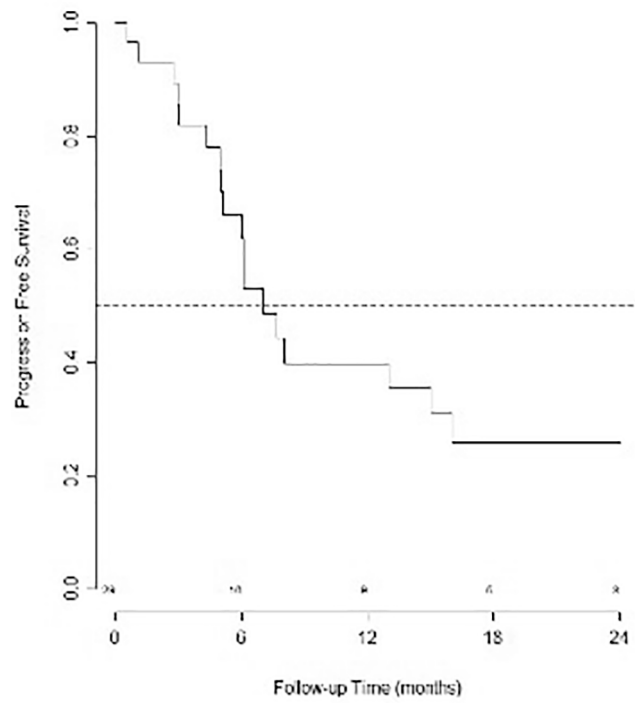


Fig. 1. Kaplan-Meier curve for progression free survival (PFS) of patients after resection of oligoprogressive NSCLC.

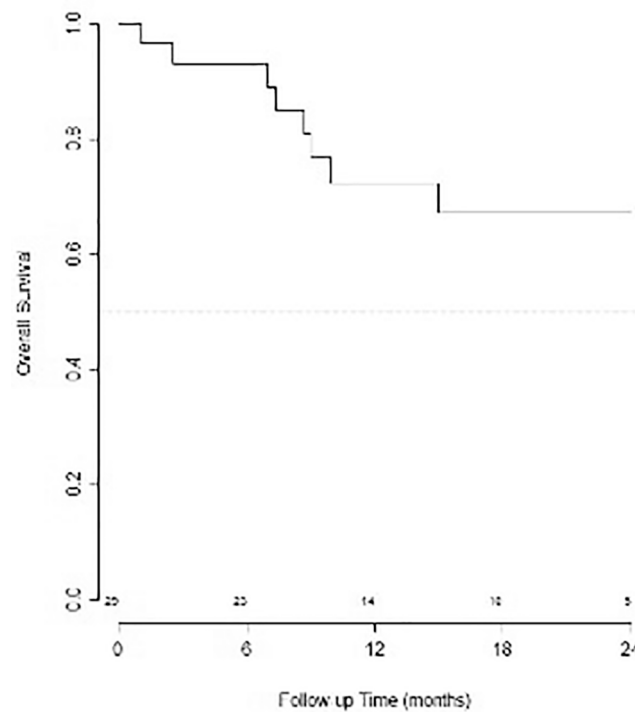


Fig. 2. Kaplan-Meier curve for overall survival (OS) of patients after resection of oligoprogressive NSCLC.

Table 4

Prognostic effect of patient-, tumour- and treatment characteristics on progression-free survival (PFS) and overall survival (OS), represented by the hazard ratio (HR) and 95% confidence interval (CI).

| Variable | PFS | | | OS | | |
|---|------|----------------------|---------|------|----------------------|---------|
| | HR | 95% CI (lower–upper) | p-value | HR | 95% CI (lower–upper) | p-value |
| Age (per year) | 1.0 | (0.95–1.05) | 0.92 | 1.12 | (1.03–1.21) | 0.01 |
| Gender (F vs M) | 1.47 | (0.58–3.7) | 0.42 | 1.73 | (0.41–7.26) | 0.46 |
| CCI (8 + vs 6–7) | 0.65 | (0.24–1.76) | 0.40 | 4.52 | (0.87–23.41) | 0.07 |
| cT4 vs cT1–3x | 5.07 | (1.4–18.35) | 0.01 | 3.51 | (0.82–14.92) | 0.09 |
| cN2–3 vs cN0–1x | 1.59 | (0.53–4.81) | 0.41 | 1.38 | (0.28–6.85) | 0.69 |
| cM1 vs cM0 | 0.34 | (0.12–0.98) | 0.05 | 0.36 | (0.09–1.53) | 0.17 |
| Number of metastases (2 + vs 1) | 0.74 | (0.3–1.85) | 0.52 | 0.36 | (0.09–1.52) | 0.16 |
| Chemotherapy (Yes vs No) | 1.77 | (0.69–4.53) | 0.23 | 5.83 | (0.72–47.46) | 0.10 |
| Targeted therapy (Yes vs No) | 1.01 | (0.4–2.53) | 0.98 | 1.12 | (0.28–4.49) | 0.87 |
| Immunotherapy (Yes vs No) | 1.22 | (0.45–3.29) | 0.69 | 0.28 | (0.03–2.28) | 0.23 |
| Adrenal metastasis (Yes vs No) | 1.86 | (0.75–4.6) | 0.18 | 4.14 | (0.83–20.58) | 0.08 |
| Resection lung lesion being oligoprogressive site (Yes vs No) | 0.23 | (0.07–0.75) | 0.01 | 0.43 | (0.09–2.26) | 0.31 |
| Adjuvant therapy/ ongoing systemic treatment (Yes vs No) | 1.30 | (0.51–3.33) | 0.59 | 0.64 | (0.16–2.57) | 0.53 |

F = female, M = male, CCI = Charlson Comorbidity Index, cT = clinical tumour stage, cN = clinical nodal stage, cM = clinical metastasis stage at initial diagnosis.

oligoprogressive site should be considered as part of multidisciplinary advanced disease management.

Funding

None.

CRediT authorship contribution statement

P.J.M. Joosten: Investigation, Data curation, Conceptualization, Visualization, Resources, Writing – original draft. **A.J. de Langen:** Conceptualization, Visualization, Writing – original draft. **V. van der Noort:** Formal analysis, Methodology, Software, Writing – original draft. **K. Monkhorst:** Writing – review & editing. **H.M. Klomp:** Writing – review & editing. **A.A.F.A. Veenhof:** Writing – review & editing. **C. Dickhoff:** Writing – review & editing. **E.F. Smit:** Writing – review & editing. **K.J. Hartemink:** Investigation, Conceptualization, Supervision, Project administration, Writing – original draft.

Declaration of Competing Interest

The authors declare that they have no known competing financial interests or personal relationships that could have appeared to influence the work reported in this paper.

Acknowledgement

None.

Appendix A. Supplementary data

Supplementary data to this article can be found online at <https://doi.org/10.1016/j.lungcan.2021.09.019>.

References

- [1] R.L. Siegel, K.D. Miller, A. Jemal, Cancer Statistics, 2017, *CA Cancer J. Clin.* 67 (1) (2017) 7–30, <https://doi.org/10.3322/caac.21387>.
- [2] V.W. Chen, B.A. Ruiz, M.-C. Hsieh, X.-C. Wu, L.A.G. Ries, D.R. Lewis, Analysis of stage and clinical/prognostic factors for lung cancer from SEER registries: AJCC staging and collaborative stage data collection system, *Cancer* 120 (2014) 3781–3792, <https://doi.org/10.1002/ncr.29045>.
- [3] Rusch VW, Rice TW, Crowley J, et al. The seventh edition of the American Joint Committee on Cancer/International Union Against Cancer Staging Manuals: the new era of data-driven revisions. *J Thorac Cardiovasc Surg* 2010;139:819–821. doi: 10.1016/j.jtcvs.2010.02.013.
- [4] J.D. Bradley, R. Paulus, R. Komaki, G. Masters, G. Blumenschein, S. Schild, J. Bogart, C. Hu, K. Forster, A. Magliocco, V. Kavadi, Y.I. Garces, S. Narayan, P. Iyengar, C. Robinson, R.B. Wynn, C. Koprowski, J. Meng, J. Beitler, R. Gaur, W. Curran, H. Choy, Standard-dose versus high-dose conformal radiotherapy with concurrent and consolidation carboplatin plus paclitaxel with or without cetuximab for patients with stage IIIA or IIIB non-small-cell lung cancer (RTOG 0617): a randomised, two-by-two factorial phase 3 study, *Lancet Oncol.* 16 (2) (2015) 187–199, [https://doi.org/10.1016/S1470-2045\(14\)71207-0](https://doi.org/10.1016/S1470-2045(14)71207-0).
- [5] G.R. Blumenschein, R. Paulus, W.J. Curran, F. Robert, F. Fossella, M. Werner-Wasik, R.S. Herbst, P.O. Doescher, H. Choy, R. Komaki, Phase II study of cetuximab in combination with chemoradiation in patients with stage IIIA/B non-small-cell lung cancer: RTOG 0324, *J. Clin. Oncol.* 29 (17) (2011) 2312–2318, <https://doi.org/10.1200/JCO.2010.31.7875>.
- [6] M. Riihimäki, A. Hemminki, M. Fallah, H. Thomsen, K. Sundquist, J. Sundquist, K. Hemminki, Metastatic sites and survival in lung cancer, *Lung Cancer* 86 (1) (2014) 78–84, <https://doi.org/10.1016/j.lungcan.2014.07.020>.
- [7] Nicholson AG, Chansky K, Crowley J, et al. The International Association for the Study of Lung Cancer Lung Cancer Staging Project: Proposals for the Revision of the Clinical and Pathologic Staging of Small Cell Lung Cancer in the Forthcoming Eighth Edition of the TNM Classification for Lung Cancer. *J Thorac Oncol* 2016;11: 300–311. doi: 10.1016/j.jtho.2015.10.008.
- [8] T. Ciuleanu, T. Brodowicz, C. Zielinski, J.H. Kim, M. Krzakowski, E. Laack, Y.-L. Wu, I. Bover, S. Begbie, V. Tzekova, B. Cucevic, J.R. Pereira, S.H. Yang, J. Madhavan, K.P. Sugarman, P. Peterson, W.J. John, K. Krejcy, C.P. Belani, Maintenance pemetrexed plus best supportive care versus placebo plus best supportive care for non-small-cell lung cancer: a randomised, double-blind, phase 3 study, *Lancet* 374 (9699) (2009) 1432–1440, [https://doi.org/10.1016/S0140-6736\(09\)61497-5](https://doi.org/10.1016/S0140-6736(09)61497-5).
- [9] M.C. Garassino, B.-C. Cho, J.-H. Kim, J. Mazières, J. Vansteenkiste, H. Lena, J. Corral Jaime, J.E. Gray, J. Powderly, C. Chouaid, P. Bidoli, P. Wheatley-Price, K. Park, R.A. Soo, Y. Huang, C. Wadsworth, P.A. Dennis, N.A. Rizvi, L. Paz-Ares Rodriguez, S. Novello, S. Hirt, P. Schmid, E. Laack, R. Califano, M. Maemondo, S.-W. Kim, J. Chaft, D. Vicente Baz, T. Berghmans, D.-W. Kim, V. Surmont, M. Reck, J.-Y. Han, E. Holgado Martin, C. Belda Iniesta, Y. Oe, A. Chella, A. Chopra, G. Robinet, H. Soto Parra, M. Thomas, P. Cheema, N. Katakami, W.-C. Su, Y.-C. Kim, J. Wolf, J.-S. Lee, H. Saka, M. Milella, I. Ramos Garcia, A. Sibille, T. Yokoi, E.J. Kang, S. Atagi, E. Spaeth-Schwalbe, M. Nishio, F. Imamura, N. Gabrail, R. Veillon, S. Derijcke, T. Maeda, D. Zylla, K. Kubiak, A. Santoro, M.N. Uy, S. Lucien Geater, A. Italiano, D. Kowalski, F. Barlesi, Y.-M. Chen, D. Spigel, B. Chewaskulyong, R. Garcia Gomez, R. Alvarez Alvarez, C.-H. Yang, T.-C. Hsia, F. Denis, H. Sakai, M. Vincent, K. Goto, J. Bosch-Barrera, G. Weiss, J.-L. Canon, C. Scholz, M. Aglietta, H. Kemmotsu, K. Azuma, P. Bradbury, R. Feld, A. Chachoua, J. Jasse, R. Juergens, R. Palmero Sanchez, A. Malcolm, N. Vrindavanam, K. Kubota, C. Waller, D. Waterhouse, B. Coudert, Z. Mark, M. Satouchi, G.-C. Chang, C. Herzmann, A. Chaudhry, S. Giridharan, P. Hesketh, N. Ikeda, R. Boccia, N. Iannotti, M. Haigentz, J. Reynolds, J. Querol, K. Nakagawa, S. Sugawara, E.H. Tan, T. Hirashima, S. Gettinger, T. Kato, K. Takeda, O. Juan Vidal, A. Mohn-Staudner, A. Panwalkar, D. Daniel, K. Kobayashi, G.E.I. Ladrera, C. Schulte, M. Sebastian, M. Cernovska, H. Coupkova, L. Havel, N. Pauk, J. Singh, S. Murakami, T. Csozsi, G. Losonczy, A. Price, I. Anderson, M. Iqbal, V. Torri, E. Juhasz, S. Khanani, L. Koubkova, B. Levy, R. Page, C. Bocskei, L. Crinò, D. Einspahr, C. Hagenstad, N. Juat, L. Overton, M. Garrison, Z. Szalai, Durvalumab as third-line or later treatment for advanced non-small-cell lung cancer (ATLANTIC): an open-label, single-arm, phase 2 study, *Lancet Oncol.* 19 (4) (2018) 521–536, [https://doi.org/10.1016/S1470-2045\(18\)30144-X](https://doi.org/10.1016/S1470-2045(18)30144-X).
- [10] M.D. Hellmann, L. Paz-Ares, R. Bernabe Caro, B. Zurawski, S.-W. Kim, E. Carcereny Costa, K. Park, A. Alexandru, L. Lupinacci, E. de la Mora Jimenez, H. Sakai, I. Albert, A. Vergnenegre, S. Peters, K. Syrigos, F. Barlesi, M. Reck, H. Borghaei, J. R. Brahmer, K.J. O'Byrne, W.J. Geese, P. Bhagavatheeswaran, S.K. Rabindran, R. S. Kasinathan, F.E. Nathan, S.S. Ramalingam, Nivolumab plus Ipilimumab in Advanced Non-Small-Cell Lung Cancer, *N. Engl. J. Med.* 381 (21) (2019) 2020–2031, <https://doi.org/10.1056/NEJMoa1910231>.
- [11] D. Planchard, N. Reinmuth, S. Orlov, J.R. Fischer, S. Sugawara, S. Mandziuk, D. Marquez-Medina, S. Novello, Y. Takeda, R. Soo, K. Park, M. McCleod, S. L. Geater, M. Powell, R. May, U. Scheuring, P. Stockman, D. Kowalski, ARCTIC:

- durvalumab with or without tremelimumab as third-line or later treatment of metastatic non-small-cell lung cancer, *Ann. Oncol.* 31 (5) (2020) 609–618, <https://doi.org/10.1016/j.annonc.2020.02.006>.
- [12] S.A. Laurie, S. Banerji, N. Blais, S. Brule, P.K. Cheema, P. Cheung, N. Daaboul, D. Hao, V. Hirsh, R. Juergens, J. Laskin, N. Leighl, R. MacRae, G. Nicholas, D. Roberge, J. Rothenstein, D.J. Stewart, M.S. Tsao, Canadian consensus: oligoprogressive, pseudoprogressive, and oligometastatic non-small-cell lung cancer, *Curr. Oncol.* 26 (1) (2019) 81–93, <https://doi.org/10.3747/co.26.4116>.
- [13] D.R. Gomez, C. Tang, J. Zhang, G.R. Blumenschein, M. Hernandez, J.J. Lee, R. Ye, D.A. Palma, A.V. Louie, D.R. Camidge, R.C. Doebele, F. Skoulidis, L.E. Gaspar, J. W. Welsh, D.L. Gibbons, J.A. Karam, B.D. Kavanagh, A.S. Tsao, B. Sepesi, S. G. Swisher, J.V. Heymach, Local Consolidative Therapy Vs. Maintenance Therapy or Observation for Patients With Oligometastatic Non-Small-Cell Lung Cancer: Long-Term Results of a Multi-Institutional, Phase II, Randomized Study, *J. Clin. Oncol.* 37 (18) (2019) 1558–1565, <https://doi.org/10.1200/JCO.19.00201>.
- [14] M.S. Ning, D.R. Gomez, J.V. Heymach, S.G. Swisher, Stereotactic ablative body radiation for oligometastatic and oligoprogressive disease, *Transl. Lung Cancer Res.* 8 (1) (2018) 97–106, <https://doi.org/10.21037/tlcr.2018.09.21>.
- [15] L. Basler, S.G. Kroeze, M. Guckenberger, SBRT for oligoprogressive oncogene addicted NSCLC, *Lung Cancer* 106 (2017) 50–57, <https://doi.org/10.1016/j.lungcan.2017.02.007>.
- [16] M. Campo, H. Al-Halabi, M. Khandekar, A.T. Shaw, L.V. Sequist, H. Willers, Integration of Stereotactic Body Radiation Therapy With Tyrosine Kinase Inhibitors in Stage IV Oncogene-Driven Lung Cancer, *Oncologist* 21 (8) (2016) 964–973, <https://doi.org/10.1634/theoncologist.2015-0508>.
- [17] E. von Elm, D.G. Altman, M. Egger, S.J. Pocock, P.C. Gøtzsche, J. P. Vandenberg, The Strengthening of Reporting of Observational Studies in Epidemiology (STROBE) Statement: guidelines for reporting observational studies, *Int. J. Surg.* 12 (12) (2014) 1495–1499, <https://doi.org/10.1016/j.ijsu.2014.07.013>.
- [18] G.N. Gan, A.J. Weickhardt, B. Scheier, R.C. Doebele, L.E. Gaspar, B.D. Kavanagh, D.R. Camidge, Stereotactic radiation therapy can safely and durably control sites of extra-central nervous system oligoprogressive disease in anaplastic lymphoma kinase-positive lung cancer patients receiving crizotinib, *Int. J. Radiat. Oncol. Biol. Phys.* 88 (4) (2014) 892–898, <https://doi.org/10.1016/j.ijrobp.2013.11.010>.
- [19] H.A. Yu, C.S. Sima, J. Huang, S.B. Solomon, A. Rimmer, P. Paik, M.C. Pietanza, C. G. Azzoli, N.A. Rizvi, L.M. Krug, V.A. Miller, M.G. Kris, G.J. Riely, Local therapy with continued EGFR tyrosine kinase inhibitor therapy as a treatment strategy in EGFR-mutant advanced lung cancers that have developed acquired resistance to EGFR tyrosine kinase inhibitors, *J. Thorac. Oncol.* 8 (3) (2013) 346–351, <https://doi.org/10.1097/JTO.0b013e31827e1f83>.
- [20] A.J. Weickhardt, B. Scheier, J.M. Burke, G. Gan, X. Lu, P.A. Bunn, D.L. Aisner, L. E. Gaspar, B.D. Kavanagh, R.C. Doebele, D.R. Camidge, Local ablative therapy of oligoprogressive disease prolongs disease control by tyrosine kinase inhibitors in oncogene-addicted non-small-cell lung cancer, *J. Thorac. Oncol.* 7 (12) (2012) 1807–1814, <https://doi.org/10.1097/JTO.0b013e3182745948>.
- [21] D.R. Gomez, G.R. Blumenschein, J.J. Lee, M. Hernandez, R. Ye, D.R. Camidge, R. C. Doebele, F. Skoulidis, L.E. Gaspar, D.L. Gibbons, J.A. Karam, B.D. Kavanagh, C. Tang, R. Komaki, A.V. Louie, D.A. Palma, A.S. Tsao, B. Sepesi, W.N. William, J. Zhang, Q. Shi, X.S. Wang, S.G. Swisher, J.V. Heymach, Local consolidative therapy versus maintenance therapy or observation for patients with oligometastatic non-small-cell lung cancer without progression after first-line systemic therapy: a multicentre, randomised, controlled, phase 2 study, *Lancet Oncol.* 17 (12) (2016) 1672–1682, [https://doi.org/10.1016/S1470-2045\(16\)30532-0](https://doi.org/10.1016/S1470-2045(16)30532-0).
- [22] H. West, Management of Oligometastatic Disease in Advanced Non-Small Cell Lung Cancer, *Clin. Chest Med.* 41 (2) (2020 Jun) 249–258, <https://doi.org/10.1016/j.ccm.2020.02.004>.
- [23] P.J. Richard, R. Rengan, Oligometastatic non-small-cell lung cancer: current treatment strategies, *Lung Cancer (Auckl.)* 4 (7) (2016 Nov) 129–140, <https://doi.org/10.2147/LC.TT.S101639>.
- [24] Y. Shi, Y. Sun, J. Yu, C. Ding, Z. Wang, C. Wang, D. Wang, C. Wang, Z. Wang, M. Wang, X. Zhi, Y. Lu, J. Feng, Y. Liu, X. Liu, W. Liu, G. Wu, X. Li, K. Li, E. Li, W. Li, G. Chen, Z. Chen, P. Yu, N. Wu, M. Wu, W. Xiao, L.i. Zhang, Y. Zhang, S. Zhang, S. Yang, X. Song, D. Lin, R. Luo, L.i. Shan, C. Zhou, Z. Zhou, Q. Zhao, C. Hu, Y.i. Hu, Q. Guo, J. Chang, C. Huang, X. Zeng, B. Han, X. Han, B.o. Jia, Y. Han, Y.u. Huang, China experts consensus on the diagnosis and treatment of advanced stage primary lung cancer (2016 version), *Asia Pac. J. Clin. Oncol.* 13 (1) (2017) 87–103, <https://doi.org/10.1111/ajco.2017.13.issue-110.1111/ajco.12608>.
- [25] O. Abdel-Rahman, Outcomes of surgery as part of the management of metastatic Non-small-cell lung cancer: A Surveillance, epidemiology and End results database analysis, *Cancer Invest.* 36 (4) (2018) 238–245, <https://doi.org/10.1080/07357907.2018.1466895>.
- [26] C. Kim, C.D. Hoang, A.H. Kesarwala, D.S. Schrupp, U. Guha, A. Rajan, Role of Local Ablative Therapy in Patients with Oligometastatic and Oligoprogressive Non-Small Cell Lung Cancer, *J. Thorac. Oncol.* 12 (2) (2017 Feb) 179–193, <https://doi.org/10.1016/j.jtho.2016.10.012>.
- [27] H. Borghaei, L. Paz-Ares, L. Horn, D.R. Spigel, M. Steins, N.E. Ready, L.Q. Chow, E. E. Vokes, E. Felip, E. Holgado, F. Barlesi, M. Kohlhäufel, O. Arrieta, M.A. Burgio, J. Fayette, H. Lena, E. Poddubskaya, D.E. Gerber, S.N. Gettinger, C.M. Rudin, N. Rizvi, L. Crino, G.R. Blumenschein, S.J. Antonia, C. Dorange, C.T. Harbison, F. Graf Finckenstein, J.R. Brahmer, Nivolumab versus Docetaxel in Advanced Nonsquamous Non-Small-Cell Lung Cancer, *N. Engl. J. Med.* 373 (17) (2015) 1627–1639, <https://doi.org/10.1056/NEJMoa1507643>.
- [28] N. Howlander, G. Forjaz, M.J. Mooradian, R. Meza, C.Y. Kong, K.A. Cronin, A. B. Mariotto, D.R. Lowy, E.J. Feuer, The Effect of Advances in Lung-Cancer Treatment on Population Mortality, *N. Engl. J. Med.* 383 (7) (2020) 640–649, <https://doi.org/10.1056/NEJMoa1916623>.
- [29] P. Cheung, Stereotactic body radiotherapy for oligoprogressive cancer, *Br. J. Radiol.* 89 (1066) (2016) 20160251, <https://doi.org/10.1259/bjr.20160251>.
- [30] T. Guo, Y. Ding, L. Chen, L. Zhu, J. Lin, J. Zhang, Y. Huang, W. Li, R. Lin, X. Pan, Evaluation of pembrolizumab for the treatment of advanced non-small cell lung cancer: a retrospective, single-centre, single-arm study, *J. Thorac. Dis.* 13 (1) (2021) 282–290, <https://doi.org/10.21037/jtd.2021037/jtd-20-3413>.
- [31] P. Lang, D.R. Gomez, D.A. Palma, Local Ablative Therapies in Oligometastatic NSCLC: New Data and New Directions, *Semin. Respir. Crit. Care Med.* 41 (3) (2020 Jun) 369–376, <https://doi.org/10.1055/s-0039-3400290>.
- [32] V. Jairam, H.S. Park, R.H. Decker, Local Ablative Therapies for Oligometastatic and Oligoprogressive Non-Small Cell Lung Cancer, *Cancer J.* 26 (2) (2020) 129–136, <https://doi.org/10.1097/PP0.0000000000000433>.
- [33] Y. Miura, A. Mouri, K. Kaira, et al., Chemoradiotherapy followed by durvalumab in patients with unresectable advanced non-small cell lung cancer: Management of adverse events, *Thorac. Cancer* 11 (2020) 1280–1287, <https://doi.org/10.1111/1759-7714.13394>.
- [34] T. Sakaguchi, K. Ito, K. Furuhashi, Y. Nakamura, Y. Suzuki, Y. Nishii, O. Taguchi, O. Hataji, Patients with unresectable stage III non-small cell lung cancer eligible to receive consolidation therapy with durvalumab in clinical practice based on PACIFIC study criteria, *Respir. Invest.* 57 (5) (2019) 466–471, <https://doi.org/10.1016/j.resinv.2019.03.011>.
- [35] H. Al-Halabi, K. Sayegh, S.R. Digamurthy, A. Niemierko, Z. Piotrowska, H. Willers, L.V. Sequist, Pattern of Failure Analysis in Metastatic EGFR-Mutant Lung Cancer Treated with Tyrosine Kinase Inhibitors to Identify Candidates for Consolidation Stereotactic Body Radiation Therapy, *J. Thorac. Oncol.* 10 (11) (2015) 1601–1607, <https://doi.org/10.1097/JTO.0000000000000648>.
- [36] G.R. Oxnard, J.C. Yang, H. Yu, et al., TATTON: a multi-arm, phase Ib trial of osimertinib combined with selumetinib, savolitinib, or durvalumab in EGFR-mutant lung cancer, *Ann. Oncol.* 31 (2020) 507–516, <https://doi.org/10.1016/j.annonc.2020.01.013>.
- [37] A.T. Shaw, B.J. Solomon, B. Besse, et al., ALK Resistance Mutations and Efficacy of Lorlatinib in Advanced Anaplastic Lymphoma Kinase-Positive Non-Small-Cell Lung Cancer, *J. Clin. Oncol.* 37 (2019) 1370–1379, <https://doi.org/10.1200/JCO.18.02236>.
- [38] C. Gauvin, V. Krishnan, I. Kaci, D. Tran-Thanh, K. Bédard, R. Albadine, C. Leduc, L. Gaboury, N. Blais, M. Tehfe, B. Routy, M. Florescu, Survival Impact of Aggressive Treatment and PD-L1 Expression in Oligometastatic NSCLC, *Curr. Oncol.* 28 (1) (2021) 593–605, <https://doi.org/10.3390/curroncol28010059>.