



**Universiteit
Leiden**
The Netherlands

Phase 1 study of chemoradiotherapy combined with nivolumab +/- Ipilimumab for the curative treatment of muscle-invasive bladder cancer

Ruiter, B.M. de; Hattum, J.W. van; Lipman, D.; Reijke, T.M. de; Moorselaar, R.J.A. van; Gennep, E.J. van; ... ; Bins, A.D.

Citation

Ruiter, B. M. de, Hattum, J. W. van, Lipman, D., Reijke, T. M. de, Moorselaar, R. J. A. van, Gennep, E. J. van, ... Bins, A. D. (2022). Phase 1 study of chemoradiotherapy combined with nivolumab +/- Ipilimumab for the curative treatment of muscle-invasive bladder cancer. *European Urology*, 82(5), 518-526. doi:10.1016/j.eururo.2022.07.009


Version: Publisher's Version

License: [Creative Commons CC BY-NC-ND 4.0 license](https://creativecommons.org/licenses/by-nc-nd/4.0/)

Downloaded from: <https://hdl.handle.net/1887/3636726>

Note: To cite this publication please use the final published version (if applicable).

available at www.sciencedirect.com
journal homepage: www.europeanurology.com



Platinum Priority – Bladder Cancer

Editorial by Pooja Ghatalia, Elizabeth R. Plimack on pp. 527–528 of this issue

Phase 1 Study of Chemoradiotherapy Combined with Nivolumab ± Ipilimumab for the Curative Treatment of Muscle-invasive Bladder Cancer

Ben-Max de Ruiter^{a,b,1}, Jons W. van Hattum^{a,b,1}, Djoeri Lipman^c, Theo M. de Reijke^{a,b}, R. Jeroen A. van Moorselaar^{b,d}, Erik J. van Gennep^e, A.H. Maartje Piet^{b,f}, Mila Donker^g, Tom van der Hulle^h, Jens Voortman^{b,i}, Jorg R. Oddens^{a,b}, Maarten C.C.M. Hulshof^{b,j}, Adriaan D. Bins^{b,k,*}

^aDepartment of Urology, Amsterdam UMC location University of Amsterdam, Amsterdam, The Netherlands; ^bCancer Center Amsterdam, Amsterdam, The Netherlands; ^cDepartment of Radiation Oncology, Isala Hospital Zwolle, Zwolle, The Netherlands; ^dDepartment of Radiotherapy, Amsterdam UMC location Vrije Universiteit Amsterdam, Amsterdam, The Netherlands; ^eDepartment of Urology, Leiden University Medical Center, Leiden University, Leiden, The Netherlands; ^fDepartment of Radiotherapy, Amsterdam UMC location Vrije Universiteit Amsterdam, Amsterdam, The Netherlands; ^gDepartment of Radiotherapy, Leiden University Medical Center, Leiden University, Leiden, The Netherlands; ^hDepartment of Medical Oncology, Leiden University Medical Center, Leiden University, Leiden, The Netherlands; ⁱDepartment of Medical Oncology, Amsterdam UMC location Vrije Universiteit Amsterdam, Amsterdam, The Netherlands; ^jDepartment of Radiotherapy, Amsterdam UMC location University of Amsterdam, Amsterdam, The Netherlands; ^kDepartment of Medical Oncology, Amsterdam UMC location University of Amsterdam, Amsterdam, The Netherlands

Article info

Article history:

Accepted July 14, 2022

Keywords:

Bladder cancer
Chemoradiotherapy
Immune checkpoint inhibition
Bladder-sparing treatment

Abstract

Background: Muscle-invasive bladder cancer (MIBC) has a poor prognosis. Chemoradiotherapy (CRT) in selected patients has comparable results to radical cystectomy. Results of neoadjuvant immune checkpoint inhibitors (ICIs) before radical cystectomy are promising. We hypothesize that ICI concurrent to CRT (iCRT) is safe and may improve treatment outcomes.

Objective: To determine the safety of iCRT for MIBC.

Design, setting, and participants: This multicenter, phase 1b, open-label, dose-escalation study determined the safety of CRT with three ICI regimens in patients with non-metastatic (T2–4aN0–1) MIBC. Twenty-six patients received mitomycin C/capecitabine and 20 × 2.75 Gy to the bladder. Tolerability was evaluated in a cohort of up to ten patients. If two or fewer out of the first six patients or three or fewer of ten patients experienced dose-limiting toxicity (DLT), accrual continued in the next cohort.

Intervention: Patients received nivolumab 480 mg (NIVO480), nivolumab 3 mg/kg and ipilimumab 1 mg/kg (NIVO3 + IPI1), or nivolumab 1 mg/kg and ipilimumab 3 mg/kg (IPI3 + NIVO1).

¹ Both these authors contributed equally.

* Corresponding author. Department of Medical Oncology, Amsterdam University Medical Centers, University of Amsterdam, De Boelelaan 1117, 1118, 1081 HV Amsterdam, The Netherlands. Tel. +31 20 566 9111.

E-mail address: a.d.bins@amsterdamumc.nl (A.D. Bins).



Outcome measurements and statistical analysis: The primary endpoint was safety. Secondary objectives were response rate, disease-free survival, metastatic-free survival (MFS), and overall survival (OS).

Results and limitations: In the NIVO480 cohort, no patients experienced DLT. The NIVO3 + IPI1 2 patients experienced DLT, thrombocytopenia (grade 4), and asystole (grade 5). IPI3 + NIVO1 was discontinued after three out of six patients experienced DLT. Clinically significant adverse events (AEs) of grade ≥ 3 occurred in zero, three, and five patients in the NIVO480, NIVO3 + IPI1, and IPI3 + NIVO1 groups, respectively. The most common AEs were immune related and gastrointestinal. MFS and OS were 90% at 2 yr for NIVO480 and 90% at 1 yr for NIVO3 + IPI1. Limitations include the absence of a centralized pathology and radiology review, and a lack of biomarker analysis.

Conclusions: In this dose-finding study of iCRT, the regimens of nivolumab monotherapy and nivolumab 3 mg/kg with ipilimumab 1 mg/kg have acceptable toxicity.

Patient summary: We tested the safety of a new bladder-sparing treatment modality for muscle-invasive bladder cancer patients, combining immune checkpoint inhibitors simultaneously with chemoradiotherapy. We report that two regimens, nivolumab monotherapy and nivolumab 3 mg/kg with ipilimumab 1 mg/kg, are safe and can be used in phase 3 trials.

© 2022 The Authors. Published by Elsevier B.V. on behalf of European Association of Urology. This is an open access article under the CC BY-NC-ND license (<http://creativecommons.org/licenses/by-nc-nd/4.0/>).

1. Introduction

Urothelial bladder cancer (UBC) is the ninth most prevalent cancer worldwide, with yearly over 500 000 new cases and 200 000 attributable deaths [1]. UBC, in which the tumor invades the detrusor muscle (muscle-invasive bladder cancer [MIBC]) contributes to approximately 30% of newly diagnosed cases [2].

Despite intensive treatments such as radical cystectomy (RC) with pelvic lymph node dissection or bladder-sparing chemoradiotherapy (CRT), the prognosis of MIBC remains poor, with 5-yr overall survival (OS) of 50% [3,4]. The high mortality rate of MIBC is explained by the early development of micrometastases [5,6]. This is supported by the fact that neoadjuvant chemotherapy (NAC) before RC improves 5-yr OS by 5–8% [7]. A similar survival benefit of NAC on CRT has not been confirmed [8].

Recently, the use of immune checkpoint inhibitors (ICIs) has improved treatment outcomes in several cancers [9–12]. ICI monotherapy targeted against programmed death 1 (PD-1) or its ligand (PDL-1) has produced clinically meaningful results and has already gained a role in the treatment of metastatic UBC [4,13,14]. Sharma et al [15] suggested that combined treatment targeted against PD-1 and cytotoxic T lymphocyte antigen 4 (CTLA-4) improved treatment results with acceptable toxicity. In line with these developments, potential benefit of neoadjuvant ICIs before RC has been demonstrated, with pathological response rates (RRs) between 33% and 58% [16–19]. These outcomes warrant further research of ICI combination therapy in the curative treatment of MIBC patients.

One such potential treatment is combining an ICI with CRT (iCRT). Both chemotherapy and radiotherapy influence the tumor microenvironment by increasing immune cell infiltration and antigen presentation, which could lead to an enhanced immune response after ICI treatment

[20–22]. There are several active iCRT studies in MIBC [23]. As yet, one trial investigating the anti-PD-L1 drug atezolizumab has been published after premature termination due to toxicity [24]. This shows that careful evaluation of iCRT in terms of ICI and CRT regimens is needed.

To our knowledge, we present the first clinical trial investigating the safety and feasibility of iCRT with nivolumab and ipilimumab for MIBC. We investigated three regimens: first anti-PD-1 monotherapy (nivolumab), followed by anti-PD-1 + anti-CTLA-4 (ipilimumab) concurrent to CRT with mitomycin C (MMC) and capecitabine to determine the maximally tolerable dose [25]. Additionally, we provide early oncological outcomes.

2. Patients and methods

2.1. Study design and patients

The CRIMI trial (NCT038442556) is a multicenter, phase 1b–2, open-label, dose-escalation study of MMC/capecitabine CRT combined with nivolumab monotherapy or nivolumab and ipilimumab as a curative bladder-sparing treatment of nonmetastatic MIBC. Between January 2019 and December 2021, participants were sequentially enrolled in three academic hospitals in The Netherlands into three consecutive treatment regimens (IRB 2018_095#B202132).

The key eligibility criteria were ≥ 18 yr, Eastern Cooperative Oncology Group performance status ≤ 1 , and histologically confirmed urothelial MIBC (>50% urothelial carcinoma, stage cT2–T4acN0–1M0 in combination with adequate organ and bone marrow function). No concurrent extravesical UBC (ie, urethra and upper urinary tract), multifocal carcinoma in situ (CIS), and prior treatment for MIBC or pelvic radiotherapy was allowed. The eligibility criteria are described in the [Supplementary material](#).

The study protocol ([Supplementary material](#)) was approved by the institutional review board of each participating center and was conducted in accordance with the Guidelines for Good Clinical Practice. Informed consent was obtained from participants. An independent data safety monitoring board was instituted and consulted at predefined stages throughout the study.

2.2. Study procedures and treatment

Patients were staged by transurethral resection of the bladder tumor (TURBT) prior to the start of study treatment and computed tomography (CT) imaging of the chest, abdomen, and pelvis, and discussed in a multidisciplinary meeting. Fluorodeoxyglucose positron emission tomography was optional following hospital guidelines. The study treatment was administered in 12 wk (Table 1) and consisted of radiotherapy using volumetric modulated arc therapy or intensity-modulated radiotherapy (IMRT) with 40 Gy in 20 fractions of 2 Gy to the whole bladder and pelvic lymph nodes up to the level of the common iliac arteries, with a simultaneous integrated focal boost (SIB) of 15 Gy in 20 fractions of 0.75 Gy to the primary tumor area. Tumors were endoscopically demarcated using lipiodol or BioXmark injections for cone beam CT scan–based daily accurate boost dose delivery, if possible [26,27]. On-line adaptive radiation techniques were used in all patients, either with a library of plans or with online adaptive planning. Radiotherapy dose constraints are displayed in Table 2. Multifocal UBC was treated with whole bladder irradiation. Chemotherapy consisted of radiosensitizing MMC 12 mg/m² intravenously on day 1 of radiation and capecitabine 750 mg/m² twice daily on days of radiotherapy.

The CRT treatment was combined with concurrent ICI therapy in three consecutive regimens. Patients were assigned to the next regimen when ten patients within one cohort were included:

1. NIVO480: nivolumab monotherapy at 480 mg fixed dose every 4 wk for three doses on weeks 1, 5, and 9.
2. NIVO3 + IPI1: nivolumab 3 mg/kg and ipilimumab 1 mg/kg every 3 wk for four doses on weeks 1, 4, 7, and 10.
3. IPI3 + NIVO1: nivolumab 1 mg/kg and ipilimumab 3 mg/kg every 3 wk for four doses on weeks 1, 4, 7, and 10.

After 12 wk, study participants could opt for fixed-dose adjuvant nivolumab 480 mg at intervals of 4 wk, from week 13 to week 52.

Dose modifications of ICIs were not allowed; however, withholding infusions was allowed in case of adverse events (AEs), as judged by the investigator. Dose reductions and discontinuation of capecitabine were allowed, with maximum discontinuation of 10 out of 20 d.

2.3. Objectives and assessment

The primary endpoint was safety and identifying the maximal tolerable ICI regimen, determined by evaluating the rate of dose-limiting toxicity (DLT) during the first 6 treatment weeks according to protocol-defined criteria (Supplementary material). A regimen was deemed safe if two or fewer out of the first six patients or three or fewer out of ten patients in a cohort experienced DLT. Patient enrolment followed a staggered design.

AEs were monitored throughout the study and for up to 180 d after the last ICI infusion, and graded according to National Cancer Institute Common Terminology Criteria for Adverse Events (CTCAE) version

Table 2 – Planning dose constraint radiotherapy

Organ at risk	Dosimetric parameter	Volume
Small bowel	V55	<3 cc
Bowel bag	V45	<300 cc
Rectum	V50	<50%
Sigmoid	V60	<3 cc
Bladder	V50	15%
Hip left	<V50	NA
Hip right	<V50	NA

NA = not available; V55, V45, and V60 = percentages of volume receiving 55, 45, or 30 Gy.

4.03. Response was assessed by cystoscopy and CT scan of chest, abdomen, and pelvis at 12 and 24 wk. Complete response was defined as absence of a tumor at cystoscopic evaluation without signs of metastasis at CT. Bladder biopsies were not required unless there was a suspicion of residual tumor or recurrence. From week 24, cystoscopy and imaging were conducted every 3 mo and used for tumor evaluation according to RECIST (response evaluation criteria in solid tumors) version 1.1.

Secondary objectives consisted of RR, disease-free survival (DFS) defined as the absence of any recurrence, metastatic-free survival (MFS), and OS per treatment regimen. Time-to-event analyses were calculated from the start of treatment and censored at last hospital contact (OS), cystoscopy (DFS), or imaging (DFS and MFS).

2.4. Statistical analysis

All analyses were conducted in R (R Foundation for Statistical Computing, Vienna, Austria). DFS, MFS, and OS intervals were defined as the time from the start of study treatment to the date of recurrence, progression, and death, respectively. The Kaplan-Meier method was used to assess survival probabilities. The sample size was based on clinical considerations and toxicity data of nivolumab and ipilimumab in metastatic UBC [21]. We estimated 10% of patients to experience DLT in the first 6 wk of treatment and the equivalent percentage in the context of capecitabine/MMC-iCRT, based on previous CRT experience. We accepted a margin of 30% (up to 40% DLT) as equivalent in the dose escalating safety evaluation phase. Ten patients were needed to be able to identify that the fraction of patients experiencing DLT with iCRT is <30% different from the target, with at least 90% power in a one-sample equivalence test.

3. Results

3.1. Patients

Between January 2019 and November 2021, 28 patients were screened and 26 were enrolled in three hospitals on three consecutive regimens. Ten patients received NIVO480

Table 1 –

Regimen	Treatment	Week																						
		1	2	3	4	5	6	7	8	9	10	11	12	13	17	21	25	29	33	37	41	45	49	
Standard	Radiotherapy 55 Gy	✓	✓	✓	✓																			
	Capecitabine 750 mg bid	✓	✓	✓	✓																			
	MMC 12 mg/m ²	✓																						
NIVO480	Nivolumab 480 mg	✓				✓				✓														
NIVO3 + IPI1	Nivolumab 3 mg/kg and ipilimumab 1 mg/kg	✓			✓			✓			✓													
IPI3 + NIVO1	Nivolumab 1 mg/kg and ipilimumab 3 mg/kg	✓			✓			✓			✓													

IPI3 + NIVO1 = nivolumab 1 mg/kg and ipilimumab 3 mg/kg; MMC = mitomycin C; NIVO480 = nivolumab 480 mg; NIVO3 + IPI1 = nivolumab 3 mg/kg and ipilimumab 1 mg/kg.

Table 3 – Baseline characteristics

		NIVO480		NIVO3 + IPI1		IPI3 + NIVO1	
Patients (n)		10		10		6	
Age (yr), median (IQR)		68 (61–75)		70 (66–75)		65 (61–67)	
		N	%	n	%	n	%
Sex	Male	9	90	9	90	4	66
	Female	1	10	1	10	2	33
ECOG performance status	0	6	60	6	60	5	83
	1	4	40	4	40	1	17
T stage	T2	7	70	8	80	5	83
	T3	3	30	2	20	1	17
	0	10	100	8	80	5	83
N stage	1			2	20	1	17
	Yes	1	10	0	0	1	17
Hydronephrosis at start of CRT	100% urothelial	10	100	10	100	4	67
	>50% urothelial + squamous					1	17
	>50% urothelial + sarcomatoid					1	17
Focality	Unifocal	10	100	9	90	6	100
	Multifocal			1	10		
Concomitant CIS	Yes	2	20	2	20	1	17

CIS = carcinoma in situ; CRT = chemoradiotherapy; ECOG = Eastern Cooperative Oncology Group; IPI3 + NIVO1 = nivolumab 1 mg/kg and ipilimumab 3 mg/kg; IQR = interquartile range; NIVO480 = nivolumab 480 mg; NIVO3 + IPI1 = nivolumab 3 mg/kg and ipilimumab 1 mg/kg; TURBT = transurethral resection of a bladder tumor.

and NIVO3 + IPI1, and six patients received IPI3 + NIVO1. The baseline characteristics are displayed in [Table 3](#). At the data cutoff on February 4, 2022, the median follow-up time was 89 (interquartile range [IQR] 50–109) wk.

3.2. DLT and AEs

Two regimens, NIVO480 and NIVO3 + IPI1, passed the dose evaluation phase. The maximally tolerated regimen was the NIVO3 + IPI1 regimen with two cases of DLT in ten patients. IPI3 + NIVO1 displayed unfavorable toxicity with three cases of DLT in six patients. AEs during the first 12 wk of treatment per treatment arm are displayed in [Table 4](#).

3.2.1. NIVO480

No DLT or AE of grade ≥ 3 requiring intervention occurred in the NIVO480 cohort. Deteriorated laboratory results not requiring treatment were present in one (10%) patient.

3.2.2. NIVO3 + IPI1

Two out of ten patients in the NIVO3 + IPI1 regimen experienced DLT. One thrombocytopenia grade 4, occurring during week 4, normalized after ICI and capecitabine discontinuation. One patient, a 78-yr-old male with a history of atrial fibrillation, died (asystole) after 4 wk following hospitalization due to grade 3 hyponatremia and vomiting. We were unable to attribute the death to a component of the study treatment.

AEs of grade ≥ 3 occurred in three (30%) patients and consisted of gastrointestinal (30%), hematological (20%), and cardiac (10%) disorders.

Deteriorated laboratory results not requiring treatment were present in seven (70%) patients.

3.2.3. IPI3 + NIVO1

Three out of six patients receiving IPI3 + NIVO1 experienced DLT (colitis, pneumonitis, and hepatitis). DLT occurred in patients with no prior medical history. All cases of DLT were treated by ICI discontinuation and prednisone.

AEs of grade ≥ 3 occurred in five (83%) patients and consisted of immune-related disorders (66%), colitis (50%), fatigue (33%), and skin and urinary disorders (both 17%). Two patients with colitis received additional infliximab.

Deteriorated laboratory results not requiring treatment were present in two (33%) patients.

3.2.4. AEs after treatment regimen

After finishing the iCRT treatment regimen, 13 patients in total (six in the NIVO480, five in the NIVO3 + IPI1, and two in the IPI3 + NIVO1 cohort) opted for 1-yr adjuvant nivolumab. AEs per regimen during the adjuvant nivolumab phase are displayed in [Supplementary Table 1](#). AEs of grade ≥ 3 occurred in four out of 13 (31%) patients, of whom two patients were in the NIVO480 cohort. One patient developed anemia leading to an episode of acute coronary syndrome and one developed grade 3 diarrhea due to pancreatitis. In both the NIVO3 + IPI1 and the IPI3 + NIVO1 cohort, one patient experienced a grade 3 AE, pneumonitis, and hydronephrosis of grade 3 after JJ stent removal. Immune-related AEs (irAEs; pancreatitis and pneumonitis) resolved after nivolumab discontinuation and prednisone. AEs in patients who did not receive adjuvant nivolumab are presented in [Supplementary Table 2](#). One patient (10%) in the NIVO3 + IPI1 cohort developed hydronephrosis and a urinary tract infection following disease progression.

3.3. Dose reductions

An overview of dose reductions is displayed in [Figure 1](#). All patients received the full radiotherapy and MMC dosages.

3.3.1. NIVO480

All participants received all infusions. Capecitabine dose reductions occurred in one out of ten (10%) patients due to nausea.

3.3.2. NIVO3 + IPI1

Five out of ten patients received all ICI infusions. Two patients missed one infusion in week 7, due to grade 2 ele-

Table 4 – CTCAE-scored adverse events per regimen

Adverse events	NIVO480		NIVO3 + IPI1				IPI3 + NIVO1		
	All	3	All	3	4	5	All	3	4
Any event	9 (90)	1 (10)	10 (100)	3 (30)	1 (10)	1 (10)	10 (100)	5 (50)	1 (10)
Gastrointestinal	8 (80)		9 (90)	2 (20)	1 (10)		6 (100)	3 (50)	
Colitis ^a							3 (50)	3 (50)	
Duodenal ulcer			1 (10)		1 (10)				
Diarrhea	7 (70)		6 (60)	1 (10)			5 (50)		
Vomiting	1 (10)		1 (10)	1 (10)					
Flatulence	2 (20)								
Abdominal pain	1 (10)		1 (10)						
Constipation	2 (20)		1 (10)				2 (33)		
Anorexia	2 (20)		2 (20)						
Nausea	2 (20)		1 (10)				2 (33)		
Rectal hemorrhage	1 (10)								
Oral mucositis							1 (17)		
GERD							1 (17)		
Cardiac	1 (10)		1 (10)			1 (10)			
Asystole			1 (10)			1 (10)			
ACS	1 (10)								
Immune system	0		3 (30)				4 (66)	4 (66)	
Colitis ^a							3 (50)	3 (50)	
Pneumonitis ^a							1 (17)	1 (17)	
Hepatitis			1 (10)				1 (17)	1 (17)	
Thyroiditis			2 (20)						
Eye	0		0				2 (33)		
Watering eyes							2 (33)		
Hematological	1 (10)		4 (40)	1 (10)	1 (10)		0		
Anemia	1 (10)		2 (20)	1 (10)			0		
General	4 (40)		6 (60)				5 (83)		
Fatigue	4 (40)		5 (50)				4 (66)	2 (33)	
Weight loss			1 (10)				2 (33)		
Fever							1 (17)		
Renal and urinary	3 (30)		4 (40)				2 (33)	1 (17)	
Bladder pain	3 (30)						2 (33)	1 (17)	
Renal failure	1 (10)		1 (10)						
Bladder spasm	1 (10)								
Cystitis, noninfective	1 (10)		1 (10)				2 (33)		
Urinary incontinence	1 (10)		1 (10)						
Urinary retention	1 (10)								
Urinary urge	1 (10)		2 (20)						
Infectious	1 (10)						1 (17)		
Urinary tract infection							1 (17)	1 (17)	
Upper respiratory infection	1 (10)								
Respiratory	1 (10)		1 (10)				2 (33)	1 (17)	
Pneumonitis ^a							1 (17)	1 (17)	
Hiccups							1 (17)		
Cough	1 (10)								
Skin disorders	8 (80)		5 (50)				3 (50)	1 (17)	
Rash	7 (70)		4 (40)				3 (50)	1 (17)	
Erythema multiforma	1 (10)						1 (17)		
Pruritus	1 (10)		1 (10)						
PPES	2 (20)								
Endocrine ^b	1 (10)		3 (30)				0		
Adrenal insufficiency			1 (10)						
Hypothyroidism			1 (10)						
Hyperthyroidism			2 (20)						
Nervous system	1 (10)		3 (30)				1 (17)		
Peroneal nerve injury			1 (10)						
PMNP							1 (17)		
Dysgeusia	1 (10)		3 (30)						
Lab investigations	5 (50)		9 (90)				4 (66)	1 (17)	1 (17)
Lymphocytes decreased	4 (40)		2 (20)	6 (60)			3 (50)		
Lipase increased			3 (30)	2 (20)	1 (10)				
Neutrophil count decreased	1 (10)	1 (10)	4 (40)	1 (10)			1 (17)		1 (17)
Platelet count decreased	0		5 (50)		1 (10)		2 (33)		
Amylase increased	0		2 (20)	1 (30)					
Hypokalemia	0		1 (10)	1 (10)					
Hyponatremia			2 (20)	2 (20)					
Hypophosphatemia			1 (10)	1 (10)					
ALT increased	1 (10)		1 (10)						
WBC count decreased	1 (10)		4 (40)				1 (17)	1 (17)	

ACS = acute coronary syndrome; AE = adverse event; ALT = alanine aminotransferase; CTCAE = National Cancer Institute Common Terminology Criteria for Adverse Events; GERD = gastroesophageal reflux disease; IPI3 + NIVO1 = nivolumab 1 mg/kg and ipilimumab 3 mg/kg; NIVO480 = nivolumab 480 mg; NIVO3 + IPI1 = nivolumab 3 mg/kg and ipilimumab 1 mg/kg; PMNP = peripheral motor neuropathy; PPES = palmar plantar erythrodysthesia syndrome; WBC = white blood cell; text in bold highlights >grade 2 adverse event.

^a Same adverse event.

^b More than one AE per participant.

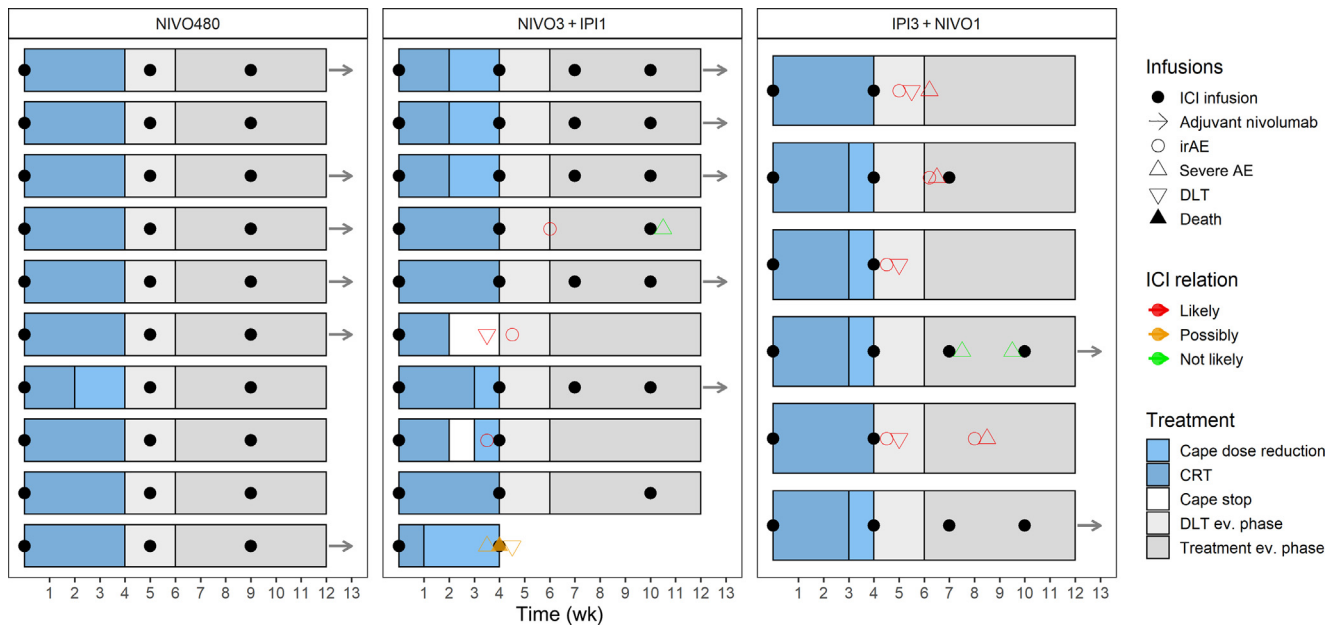


Fig. 1 – An overview of infusions and dose reductions. AE = adverse event; Cape = capecitabine; CRT = chemoradiotherapy; DLT = dose-limiting toxicity; ev. = evaluation; ICI = immune checkpoint inhibitor; IPI3 + NIVO1 = nivolumab 1 mg/kg and ipilimumab 3 mg/kg; irAE = immune-related adverse event; NIVO480 = nivolumab 480 mg; NIVO3 + IPI1 = nivolumab 3 mg/kg and ipilimumab 1 mg/kg.

vated aspartate transaminase + alanine aminotransferase and grade 2 diarrhea. Two patients received two infusions, one patient due to death, and one patient due to rash (grade 2) and an elevated lipase (grade 3). One patient received one infusion due to grade 4 thrombocytopenia. Dose reductions of capecitabine occurred in seven out of ten (70%) patients due to a low platelet count (40%), hyponatremia (10%), diarrhea (10%), or a low neutrophil count (10%).

3.3.3. IPI3 + NIVO1

Two out of six (33%) patients received all ICI infusions. Four out of six (66%) patients experienced irAEs, and ICI infusions were discontinued. Dose reductions of capecitabine occurred in four out of six (66%) patients due to low platelet counts (33%), colitis (17%), or nausea (17%).

3.4. Follow-up

Follow-up is displayed in [Figure 2](#) and [Supplementary Figure 1](#).

3.4.1. NIVO480

No recurrences were observed at 12-wk follow-up. The DFS probabilities at 1 and 2 yr are, respectively, 1 and 0.7 (confidence interval [CI] 0.47–1). The MFS probabilities at 1 and 2 yr are, respectively, 1 and 0.9 (CI 0.73–1). The OS probabilities at 1 and 2 yr are, respectively, 1 and 0.9 (CI 0.732–1). The median follow-up of survivors was 121 (IQR 109–123) wk. Intravesical noninvasive CIS recurrences occurred in two (20%) patients after 55 and 60 wk, and were treated with TURBT and adjuvant bacillus Calmette-Guérin (BCG) instillations.

3.4.2. NIVO3 + IPI1

No recurrences were observed at 12-wk follow-up. The DFS and MFS probabilities at 1 yr were 0.89 (CI 0.71–1) and 1, respectively. The OS probability at 1 yr was 0.9 (CI 0.73–1). The median follow-up of survivors was 83 (IQR 78–95) wk. One patient experienced an intravesical high-grade noninvasive recurrence after 48 wk, and was treated with TURBT and adjuvant BCG bladder instillations.

One patient who experienced DLT and received one ICI infusion experienced a muscle-invasive recurrence with simultaneous metastasis after 68 wk.

3.4.3. IPI3 + NIVO1

The median follow-up was 26 (IQR 14.6–29.8) wk. No recurrences were observed at 12-wk follow-up. One patient experienced an intravesical low-grade noninvasive recurrence after 32 wk, for which TURBT was performed, followed by a single postoperative MMC bladder instillation.

4. Discussion

To our knowledge, this is the first safety analysis of nivolumab monotherapy and combination therapy of nivolumab and ipilimumab concurrent with MMC/capecitabine CRT for MIBC. NIVO3 + IPI1 in combination with CRT was the maximal tolerable dose. NIVO3 + IPI1 and NIVO480 showed an acceptable immune-related safety profile consistent with iCRT in other tumor types [28–30]. IPI3 + NIVO1 iCRT led to unacceptable toxicity.

The most common grade ≥ 3 hematological AEs (neutropenia and thrombocytopenia) were consistent with AEs typically observed with CRT [31]. The addition of ipilimumab leads to an increase of grade ≥ 3 laboratory abnormalities, with most prevalent low lymphocyte values. The

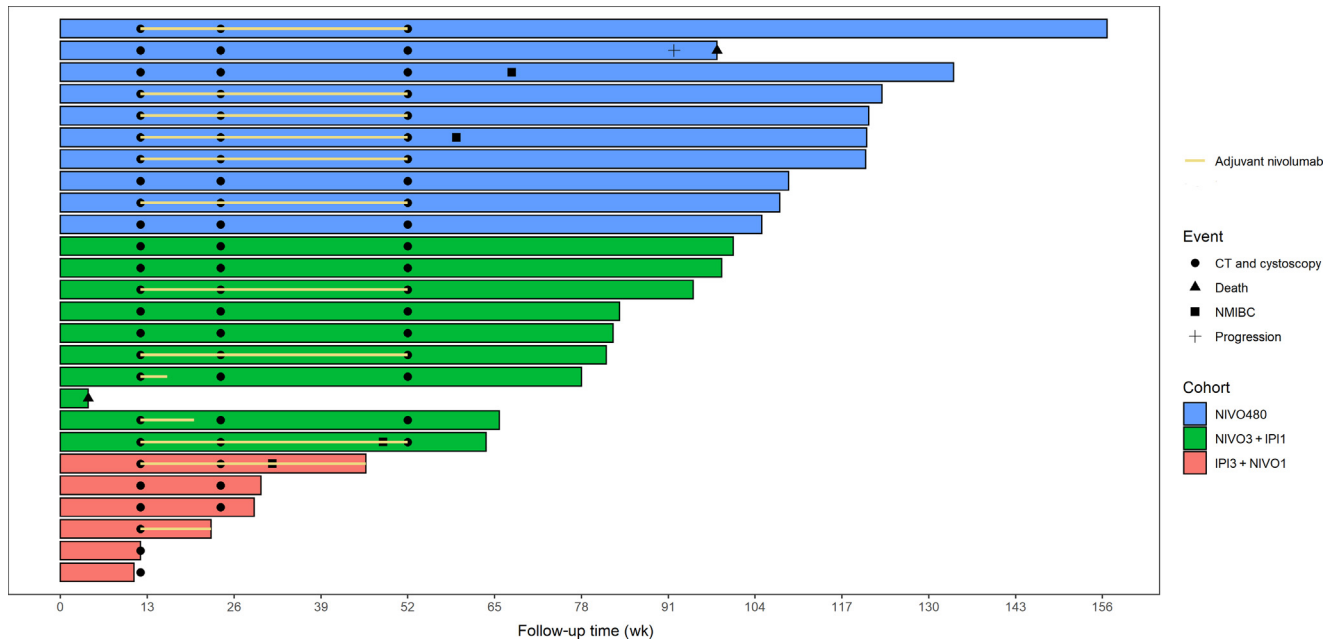


Fig. 2 – Follow-up of patients in the study. CT = computed tomography; IPI3 + NIVO1 = nivolumab 1 mg/kg and ipilimumab 3 mg/kg; NIVO480 = nivolumab 480 mg; NIVO3 + IPI1 = nivolumab 3 mg/kg and ipilimumab 1 mg/kg; NMIBC = non-muscle-invasive bladder cancer.

incidence of gastrointestinal and cardiac disorders was higher in the NIVO3 + IPI1 cohort than in the current CRT literature. Trials in metastatic cancer show that ICIs are the main drivers of toxicity. Sharma et al. [15] reported the incidence of grade 3/4 AEs to increase with the ICI dose: 26.9%, 30.8%, and 39.1% for NIVO, NIVO3 + IPI1, and IPI3 + NIVO1, respectively, a pattern similar to that observed in our study. Additionally, nivolumab combined with ipilimumab is known to cause frequent grade ≥ 3 irAEs in 39.1–59% of patients with metastatic disease [9,10,15], while in a recent phase 2 study of ICIs before RC, grade ≥ 3 irAEs occurred in 55% [18].

Interestingly, we report less toxicity with anti-PD-1 monotherapy compared with the results of the only published phase 1 trial on iCRT with atezolizumab for UBC [24]. The most common grade ≥ 3 AE in that report was colitis in four of eight patients, which we did not observe in our NIVO480 regimen. Several differences with our study may account for this difference; The ICI regimen and dose differ, but differences in chemotherapy and radiotherapy may also play a role. We administered MMC/capecitabine chemosensitization in contrast to gemcitabine. Capecitabine is an oral prodrug of 5-fluorouracil that avoids hospital admissions and infusion-related events, and has shown similar oncological outcomes to 5-fluorouracil when combined with MMC [25]. In our study, we used hypofractionated radiotherapy using IMRT, online adaptive planning, and SIB, which could have decreased intestinal radiation damage [32–35]. A recent trial however suggested that large dose fractions (6 Gy) in combination with immunotherapy might cause increased toxicity [36].

An important factor when evaluating the toxicity is the moment of onset of AEs. As shown by Marcq et al. [24], the onset of grade ≥ 3 AEs was after completing CRT and at least two doses of ICIs, with the exception of two cases

of DLT occurring in the NIVO3 + IPI1 regimen. Late onset of AEs is common in ICI treatment [37]. The absence of early ICI toxicity during hypofractionated CRT provides a possible safeguard for concurrent iCRT schedules. Additionally, recent literature shows that early ICI discontinuation due to AEs does affect treatment outcomes in melanoma patients [38]. Results of several multinational phase 2/3 trials testing several ICI regimens for both N0 and N1 MIBC are expected in the upcoming year, providing data for the timing of ICI treatment in combination with CRT [23].

No histological analyses were performed following treatment due to the nature of bladder-sparing treatment. In addition, central pathology and radiology reviews were not done. Despite stringent follow-up, the absence of an exploratory biomarker analysis makes it impossible to select responders. Additionally, oncological outcomes for the complete study cohort are limited, which complicates validation of biomarkers. However, with organ-sparing treatments, there is limited availability of tumor tissue, so researchers should be cautious in trying to validate questionable biomarkers such as PD-L1 expression [39].

Currently, we cannot determine the efficacy of iCRT for MIBC. Early oncological outcomes are promising. The results of iCRT in non-small cell lung and esophageal carcinoma are encouraging, with RRs between 30% and 70% [28,29]. In metastatic UBC, the increased toxicity of IPI3 + NIVO1 is deemed acceptable because of the higher RR [15]. A planned expansion cohort of NIVO3 + IPI1 to determine the efficacy will provide a solid basis for further randomized phase 3 trials.

5. Conclusions

This first-tested addition of nivolumab and ipilimumab to CRT for MIBC seems to be safe. The use of IPI3 + NIVO1 is

unadvised due to high toxicity. Future trials should focus on the efficacy of both anti-PD-1 monotherapy and anti-PD-1 + anti-CTLA-4 combination iCRT regimens and their comparison with standard CRT alone.

Author contributions: Ben-Max de Ruiter had full access to all the data in the study and takes responsibility for the integrity of the data and the accuracy of the data analysis.

Study concept and design: Bins, Lipman, de Reijke, van Moorselaar, Piet, Voortman, Hulshof.

Acquisition of data: de Ruiter, van Hattum, van Gennepe, Piet, Donker, van der Hulle, Voortman, Oddens.

Analysis and interpretation of data: de Ruiter, van Hattum, Bins.

Drafting of the manuscript: de Ruiter, van Hattum, Bins.

Critical revision of the manuscript for important intellectual content: de Ruiter, van Hattum, de Reijke, van Moorselaar, van Gennepe, Piet, Donker, van der Hulle, Voortman, Oddens.

Statistical analysis: de Ruiter.

Obtaining funding: Bins, de Ruiter.

Administrative, technical, or material support: de Ruiter, van Hattum, van Gennepe, Donker, van der Hulle, Voortman.

Supervision: Bins, Oddens, de Reijke, Hulshof.

Other: None.

Financial disclosures: Ben-Max de Ruiter certifies that all conflicts of interest, including specific financial interests and relationships and affiliations relevant to the subject matter or materials discussed in the manuscript (eg, employment/affiliation, grants or funding, consultancies, honoraria, stock ownership or options, expert testimony, royalties, or patents filed, received, or pending), are the following: Adriaan D. Bins received a research grant from the Dutch Cancer Society (13144/2020-1).

Funding/Support and role of the sponsor: The work of Ben-Max de Ruiter and Jons W. van Hattum is funded by the Cure for Cancer Foundation. Ben-Max de Ruiter is cofunded by the Dutch Cancer Society.

Acknowledgments: The investigational products nivolumab (OPDIVO) and ipilimumab (YERVOY) were provided by Bristol Myers Squibb.

Peer Review Summary

Peer Review Summary and Supplementary data to this article can be found online at <https://doi.org/10.1016/j.eururo.2022.07.009>.

References

- Bray F, Ferlay J, Soerjomataram I, Siegel RL, Torre LA, Jemal A. Global cancer statistics 2018: GLOBOCAN estimates of incidence and mortality worldwide for 36 cancers in 185 countries. *CA Cancer J Clin* 2018;68:394–424.
- Charlton ME, Adamo MP, Sun L, Deorah S. Bladder cancer collaborative stage variables and their data quality, usage, and clinical implications: a review of SEER data, 2004–2010. *Cancer* 2014;120(Suppl 23):3815–25.
- Stein JP, Skinner DG. Radical cystectomy for invasive bladder cancer: long-term results of a standard procedure. *World J Urol* 2006;24:296–304.
- Witjes JA, Bruins HM, Cathomas R, et al. European Association of Urology guidelines on muscle-invasive and metastatic bladder cancer: summary of the 2020 guidelines. *Eur Urol* 2021;79:82–104.
- van Hoogstraten LMC, van Gennepe EJ, Kiemeneij L, et al. Occult lymph node metastases in patients without residual muscle-invasive bladder cancer at radical cystectomy with or without neoadjuvant chemotherapy: a nationwide study of 5417 patients. *World J Urol* 2022;40:111–8.
- Mertens LS, Meijer RP, Meinhardt W, et al. Occult lymph node metastases in patients with carcinoma invading bladder muscle: incidence after neoadjuvant chemotherapy and cystectomy vs after cystectomy alone. *BJU Int* 2014;114:67–74.
- Yin M, Joshi M, Meijer RP, et al. Neoadjuvant chemotherapy for muscle-invasive bladder cancer: a systematic review and two-step meta-analysis. *Oncologist* 2016;21:708–15.
- Hussain SA, Porta N, Hall E, et al. Outcomes in patients with muscle-invasive bladder cancer treated with neoadjuvant chemotherapy followed by (chemo)radiotherapy in the BC2001 trial. *Eur Urol* 2021;79:307–15.
- Hodi FS, Chiarion-Sileni V, Gonzalez R, et al. Nivolumab plus ipilimumab or nivolumab alone versus ipilimumab alone in advanced melanoma (CheckMate 067): 4-year outcomes of a multicentre, randomised, phase 3 trial. *Lancet Oncol* 2018;19:1480–92.
- Motzer RJ, Tannir NM, McDermott DF, et al. Nivolumab plus ipilimumab versus Sunitinib in Advanced Renal-Cell Carcinoma. *N Engl J Med* 2018;378:1277–90.
- Hellmann MD, Paz-Ares L, Bernabe Caro R, et al. Nivolumab plus ipilimumab in advanced non-small-cell lung cancer. *N Engl J Med* 2019;381:2020–31.
- Choueiri TK, Powles T, Burotto M, et al. Nivolumab plus cabozantinib versus sunitinib for advanced renal-cell carcinoma. *N Engl J Med* 2021;384:829–41.
- Bellmunt J, Necchi A, Wit RD, et al. Pembrolizumab (pembro) versus investigator's choice of paclitaxel, docetaxel, or vinflunine in recurrent, advanced urothelial cancer (UC): 5-year follow-up from the phase 3 KEYNOTE-045 trial. *J Clin Oncol* 2021;39(15_suppl):4532.
- van der Heijden MS, Loriot Y, Duran I, et al. Atezolizumab versus chemotherapy in patients with platinum-treated locally advanced or metastatic urothelial carcinoma: a long-term overall survival and safety update from the phase 3 IMvigor211 clinical trial. *Eur Urol* 2021;80:7–11.
- Sharma P, Siefker-Radtke A, de Braud F, et al. Nivolumab alone and with ipilimumab in previously treated metastatic urothelial carcinoma: CheckMate 032 nivolumab 1 mg/kg plus ipilimumab 3 mg/kg expansion cohort results. *J Clin Oncol* 2019;37:1608–16.
- Necchi A, Anichini A, Raggi D, et al. Pembrolizumab as neoadjuvant therapy before radical cystectomy in patients with muscle-invasive urothelial bladder carcinoma (PURE-01): an open-label, single-arm, phase II study. *J Clin Oncol* 2018;36:3353–60.
- Powles T, Kockx M, Rodriguez-Vida A, et al. Clinical efficacy and biomarker analysis of neoadjuvant atezolizumab in operable urothelial carcinoma in the ABACUS trial. *Nat Med* 2019;25:1706–14.
- van Dijk N, Gil-Jimenez A, Silina K, et al. Preoperative ipilimumab plus nivolumab in locoregionally advanced urothelial cancer: the NABUCCO trial. *Nat Med* 2020;26:1839–44.
- Gao J, Navai N, Alhalabi O, et al. Neoadjuvant PD-L1 plus CTLA-4 blockade in patients with cisplatin-ineligible operable high-risk urothelial carcinoma. *Nat Med* 2020;26:1845–51.
- Schmid TE, Multhoff G. Radiation-induced stress proteins—the role of heat shock proteins (HSP) in anti-tumor responses. *Curr Med Chem* 2012;19:1765–70.
- Heinhuis KM, Ros W, Kok M, Steeghs N, Beijnen JH, Schellens JHM. Enhancing antitumor response by combining immune checkpoint inhibitors with chemotherapy in solid tumors. *Ann Oncol* 2019;30:219–35.
- van den Ende T, van den Boorn HG, Hoonhout NM, et al. Priming the tumor immune microenvironment with chemo(radio)therapy: a systematic review across tumor types. *Biochim Biophys Acta Rev Cancer* 2020;1874:188386.
- van Hattum JW, de Ruiter BM, Oddens JR, Hulshof M, de Reijke TM, Bins AD. Bladder-sparing chemoradiotherapy combined with immune checkpoint inhibition for locally advanced urothelial bladder cancer—a review. *Cancers (Basel)* 2021;14:38.
- Marq G, Souhami L, Cury FL, et al. Phase 1 trial of atezolizumab plus trimodal therapy in patients with localized muscle-invasive bladder cancer. *Int J Radiat Oncol Biol Phys* 2021;110:738–41.
- Voskuilen CS, van de Kamp MW, Schuring N, et al. Radiation with concurrent radiosensitizing capecitabine tablets and single-dose

- mitomycin-C for muscle-invasive bladder cancer: a convenient alternative to 5-fluorouracil. *Radiother Oncol* 2020;150:275–80.
- [26] de Ridder M, Gerbrandy LC, de Reijke TM, Hinnen KA, Hulshof M. BioXmark(R) liquid fiducial markers for image-guided radiotherapy in muscle invasive bladder cancer: a safety and performance trial. *Br J Radiol* 2020;93:20200241.
- [27] Pos F, Bex A, Dees-Ribbers HM, Betgen A, van Herk M, Remeijer P. Lipiodol injection for target volume delineation and image guidance during radiotherapy for bladder cancer. *Radiother Oncol* 2009;93:364–7.
- [28] van den Ende T, de Clercq NC, van Berge Henegouwen MI, et al. Neoadjuvant chemoradiotherapy combined with atezolizumab for resectable esophageal adenocarcinoma: a single-arm phase II feasibility trial (PERFECT). *Clin Cancer Res* 2021;27:3351–9.
- [29] Jabbour SK, Lee KH, Frost N, et al. Pembrolizumab plus concurrent chemoradiation therapy in patients with unresectable, locally advanced, stage III non-small cell lung cancer: the phase 2 KEYNOTE-799 nonrandomized trial. *JAMA Oncol* 2021;7:1–9.
- [30] Welsh JW, Heymach JV, Guo C, et al. Phase 1/2 trial of pembrolizumab and concurrent chemoradiation therapy for limited-stage SCLC. *J Thorac Oncol* 2020;15:1919–27.
- [31] Hussain SA, Stocken DD, Peake DR, et al. Long-term results of a phase II study of synchronous chemoradiotherapy in advanced muscle invasive bladder cancer. *Br J Cancer* 2004;90:2106–11.
- [32] James ND, Hussain SA, Hall E, et al. Radiotherapy with or without chemotherapy in muscle-invasive bladder cancer. *N Engl J Med* 2012;366:1477–88.
- [33] Lutkenhaus LJ, Visser J, de Jong R, Hulshof MC, Bel A. Evaluation of delivered dose for a clinical daily adaptive plan selection strategy for bladder cancer radiotherapy. *Radiother Oncol* 2015;116:51–6.
- [34] Choudhury A, Porta N, Hall E, et al. Hypofractionated radiotherapy in locally advanced bladder cancer: an individual patient data meta-analysis of the BC2001 and BCON trials. *Lancet Oncol* 2021;22:246–55.
- [35] Khalifa J, Supiot S, Pignot G, et al. Recommendations for planning and delivery of radical radiotherapy for localized urothelial carcinoma of the bladder. *Radiother Oncol* 2021;161:95–114.
- [36] Tree AC, Jones K, Hafeez S, et al. Dose-limiting urinary toxicity with pembrolizumab combined with weekly hypofractionated radiation therapy in bladder cancer. *Int J Radiat Oncol Biol Phys* 2018;101:1168–71.
- [37] Tang SQ, Tang LL, Mao YP, et al. The pattern of time to onset and resolution of immune-related adverse events caused by immune checkpoint inhibitors in cancer: a pooled analysis of 23 clinical trials and 8,436 patients. *Cancer Res Treat* 2021;53:339–54.
- [38] Larkin J, Chiarion-Sileni V, Gonzalez R, et al. Five-year survival with combined nivolumab and ipilimumab in advanced melanoma. *N Engl J Med* 2019;381:1535–46.
- [39] Gibney GT, Weiner LM, Atkins MB. Predictive biomarkers for checkpoint inhibitor-based immunotherapy. *Lancet Oncol* 2016;17:e542–51.



**ESU-ESUT Masterclass on
Operative management of
benign prostatic obstruction**

30-31 March 2023, Ruit/Stuttgart, Germany