



Universiteit
Leiden
The Netherlands

Osteoporosis in children and adolescents: how to treat and monitor?

Ciancia, S.; Hogler, W.; Sakkers, R.J.B.; Appelman-Dijkstra, N.M.; Boot, A.M.; Sas, T.C.J.; Renes, J.S.

Citation

Ciancia, S., Hogler, W., Sakkers, R. J. B., Appelman-Dijkstra, N. M., Boot, A. M., Sas, T. C. J., & Renes, J. S. (2022). Osteoporosis in children and adolescents: how to treat and monitor? *European Journal Of Pediatrics*, 182, 501-511. doi:10.1007/s00431-022-04743-x

Version: Publisher's Version

License: [Leiden University Non-exclusive license](#)

Downloaded from: <https://hdl.handle.net/1887/3563474>

Note: To cite this publication please use the final published version (if applicable).



Osteoporosis in children and adolescents: how to treat and monitor?

Silvia Ciancia¹ · Wolfgang Högler² · Ralph J. B. Sakkers³ · Natasha M. Appelman-Dijkstra⁴ · Annemieke M. Boot⁵ · Theo C. J. Sas^{1,6} · Judith S. Renes^{7,8}

Received: 9 November 2022 / Revised: 25 November 2022 / Accepted: 28 November 2022 / Published online: 6 December 2022
© The Author(s), under exclusive licence to Springer-Verlag GmbH Germany, part of Springer Nature 2022

Abstract

Osteoporosis is a condition of increased bone fragility associated with fractures. Apart from primary genetic osteoporotic conditions, secondary osteoporosis in children is being increasingly recognized. As a result, there is growing interest in its prevention and treatment. Important goals of care are to prevent fractures, increase bone mass and trabecular and cortical thickness, reshape vertebral fractures, prevent (or correct) skeletal deformities, and improve mobility, independence, and quality of life. Secondary pediatric osteoporosis is often of multifactorial origin since affected children frequently have more than one acquired factor that is detrimental to bone health. Typical conditions causing osteoporosis are leukemias, progressive muscle or neurological disorders, as well as chronic inflammatory conditions and their treatment. Management of children with osteoporosis involves a multidisciplinary team involving pediatric experts from different subspecialties. With regard to prevention and early intervention, it is important to provide optimal management of any underlying systemic conditions including avoidance, or dose-reduction, of osteotoxic medications. Basic supporting life-style measures, such as appropriate nutrition, including adequate calcium intake and vitamin D, and physical activity are recommended, where possible. When pediatric treatment criteria for osteoporosis are met, antiresorptive drugs constitute the first pharmacological line treatment.

Conclusion: This clinical review focuses on the prevention, treatment, and follow-up of children with, or at risk of developing, osteoporosis and the transition from pediatric to adult care.

What is Known:

- Osteoporosis and associated fractures can cause significant morbidity and reduce the quality of life.
- The developing skeleton has huge potential for recovery and reshaping, thus early detection of fractures, assessment of recovery potential, and treatment of children with osteoporosis can prevent future fractures, deformities, and scoliosis, improve function and mobility, and reduce pain.

What is New:

- Osteoporosis in children and adolescents requires a multidisciplinary approach with a thorough assessment of recovery potential, and indication for therapy should be personalized.
- Although bisphosphonates still represent the drug most commonly used to increase bone mass, improve mobility, and reduce pain and recurrence of fractures, new agents are being developed and could be beneficial in children with specific conditions.

Keywords Osteoporosis · Osteoporosis treatment · Bisphosphonates · Denosumab · Whole body vibration therapy · Rodding surgery · Rehabilitation · Osteogenesis imperfecta

Abbreviations

BMD Bone mineral density

BPs Bisphosphonates

DMD Duchenne muscular dystrophy

DXA Dual-energy x-ray absorptiometry

GCs Glucocorticoids

GCTB Giant cell tumor of the bone

ISCD International Society for Clinical Densitometry

JIO Juvenile idiopathic osteoporosis

OI Osteogenesis imperfecta

ONJ Osteonecrosis of the jaw

VFA Vertebral fractures assessment

VFs Vertebral fractures

WBV Whole body vibration therapy

Communicated by Peter de Winter

✉ Silvia Ciancia
silvia.ciancia.18@gmail.com

Extended author information available on the last page of the article

Introduction

Bone mass and architecture are accrued continuously during childhood and adolescence to build a strong adult skeleton. In children with osteoporosis, this process is altered leading to fragile bones more likely to break. Primary osteoporosis usually occurs due to an underlying genetic defect, with the most common condition being osteogenesis imperfecta (OI). Acute or chronic illnesses and their treatment can also harm bone tissue, leading to acquired (secondary) osteoporosis. The diagnostic work-up of children at risk, or suspected of, osteoporosis has been recently discussed [1].

In contrast to adults, children are continuously elongating, widening, and strengthening their bones during growth and puberty. Consequently, the developing skeleton has huge potential for recovery and reshaping and the first 20 years of life represent a unique window of opportunity for the treatment of osteoporosis. Early diagnosis is therefore of utmost importance. Knowledge of these specific pediatric principles is essential to make logical decisions about if and when to start treatment.

Several treatment options are available, mostly medications that can prevent or reduce the number of fractures and further bone loss, improve bone mass, and enhance the reshaping of vertebral fractures (VFs). To date, bisphosphonates (BPs) are mainly used in osteoporotic conditions that are characterized by intrinsically elevated bone turnover and/or by increased osteoclast activity (e.g., OI) [2]. However, in recent years, novel drugs acting on signaling pathways that control bone formation and remodeling have become available.

In this clinical review, we discuss the goals of care and the available treatment options for primary and secondary osteoporosis in children and adolescents, ranging from conservative measures to pharmacological and surgical interventions. Guidance regarding the treatment indications and follow-up is summarized. Finally, the transition from pediatric to adult care is discussed.

Management of osteoporosis in children

Goals of care

Osteoporosis and associated fractures (e.g., VFs) can cause significant morbidity and reduce the quality of life [3–6]. The goals of care in children and adolescents are the early detection of VFs, the prevention of future fractures, deformities and scoliosis, the improvement of function and mobility, and the reduction of pain. Furthermore, by promoting

bone mass accrual during the critical years for skeletal development, lifelong fracture risk is likely diminished [5, 7].

To reach these goals, a multidisciplinary approach is advised involving pediatricians (often subspecialized, e.g., oncology, gastroenterology, neurology), pediatric bone specialists (i.e., pediatric endocrinologist), orthopedic surgeons, physio- and occupational therapists, rehabilitation specialists, pharmacists, psychologists, and specialized nurse practitioners. This list of healthcare professionals is not exhaustive and should be personalized to the needs of the individual patient and his/her medical condition [3, 4, 7, 8].

Whether and when to initiate treatment in children is difficult to decide for most general clinicians. The clinical disease spectrum is broad, and therefore no one-size-fits-all strategy is available and the expertise of a pediatric bone specialist is required. Important factors to consider are, amongst others, the presence of symptoms (e.g., back pain or musculoskeletal pain), the nature and severity of any underlying condition, the level of mobility, and the possibility for spontaneous or medication-assisted recovery. For example, osteoporosis secondary to leukemia has a completely different timing and recovery potential compared to osteoporosis secondary to Duchenne muscular dystrophy (DMD), and therefore requires different modes and duration of treatment. Nevertheless, general recommendations can be made and will be discussed further on in this manuscript, as well as guidance for follow-up.

Conservative measures

Conservative measures in at-risk children include the optimization of the nutritional status, the promotion of physical activity, where possible, and the best available treatment of underlying conditions that can harm bone or increase the risk of falls [9, 10]. Although these modifiable factors play a substantial role in bone mass accrual and maintenance, they are often difficult to improve in chronically ill children, e.g., in case of progressive immobility from neuromuscular disease or unavoidable corticosteroid- or chemotherapy.

Appropriate intake of calcium and vitamin D is essential for the prevention (and treatment) of rickets/osteomalacia [11] and to maintain normal bone mineralization; 25-OH-vitamin D levels should be kept above 20 ng/mL (50 nmol/L), and vitamin D supplementation should be considered in children with osteoporosis and in at risk groups (specifically in those with gastro-intestinal disorders). However, vitamin D supplementation in people with sufficient vitamin D levels has no effect on BMD and does not reduce the fracture risk [12, 13].

In healthy children and adolescents, regular intense physical activity increases bone quality and strength in adulthood [14, 15]. Therefore, ambulatory children with osteoporosis should perform an exercise with a low risk of falls and bodily contact if feasible [16, 17].

In conditions and situations where muscle training is possible, rehabilitation can be employed to reduce pain and increase mobility. Physiotherapy should include strengthening exercises to improve muscle force, coordination, balance, and manage muscle contractures [18]. Whole-body vibration therapy (WBV) can be considered in some patients to increase muscle force. Data are controversial, mainly because randomized controlled trials are very difficult to conduct in these patient groups. Also, the necessary intensity and duration of WBV for muscle and/or bone benefit still needs to be determined and it is not clear yet whether children with OI could benefit from WBV [18–20]. In patients with DMD, a potential beneficial effect of WBV on BMD and muscle strength has been described. However, the results are conflicting [21–23]. In contrast, there is convincing evidence that children with cerebral palsy do benefit from WBV with improvement of their mobility and femoral BMD, in absence of major adverse events [24–27]. Quite likely, WBV is most beneficial in children affected by muscular impairment rather than in children affected by primary bone defects [28].

In children affected by secondary osteoporosis, the treatment of the underlying condition and the optimization of osteotoxic drugs dose are essential for spontaneous recovery [29]. Lastly, children with a chronic illness often experience a delay in growth and puberty or even hypogonadism, which has a huge potential to worsen bone mass acquisition. Monitoring of growth and pubertal development and eventually induction of puberty will help to improving bone health in such cases. For example, in boys with DMD and pubertal delay, testosterone administration enhances the effects of BPs by increasing bone mass and stabilizing VFs [30].

Pharmacological interventions

Bisphosphonates

BPs inhibit osteoclasts and represent the most widely used medications to treat osteoporosis (Table 1). BPs are synthetic analogs of pyrophosphate, a by-product of cell metabolism inhibiting bone resorption. The addition of nitrogen-chains defines the strength of the BPs by making the binding with hydroxyapatite more potent and explains why different BPs have different potency and dosage regimens [31, 32]. Around 50% of the administered BPs is excreted rapidly by the kidneys, while the other 50% is taken up by the skeleton.

The embedded BPs can be measured years after their use [33].

As a result of reduced bone resorption and continuous bone formation, bone mass and bone strength (i.e., cortical and trabecular thickness) increase over time during BPs administration [34]. Typical band-like metaphyseal sclerosis is seen on radiographs of patients treated with BPs (Fig. 1A), without affecting bone growth. However, long-term use of BPs traps growth plate cartilage in mature bone and impairs bone repair, with the risk of atypical femur fractures. Therefore, a treatment pause in young adult life is required to allow the removal of cartilage and bone remodeling [33].

BPs can be given orally and intravenously, although oral administration might be less effective and thus might better be reserved for children with milder osteoporosis [35]. Also, esophagitis consequent to oral BPs administration is commonly described. To reduce this risk the child should keep an upright position for at least 30 min after taking an oral bisphosphonate but this could be very difficult in specific patient categories. With regard to intravenous BP's, the vast majority of patients experience an acute phase reaction (mainly after the first administration) characterized by fever, nausea, and malaise, which is usually self-limiting and responds to paracetamol [36, 37]. More severe side effects can occur in a smaller percentage of children, such as hypocalcemia, uveitis, diarrhea, vomiting, and (in infants) respiratory distress [38]. BPs administration has also been associated with delayed osteotomy healing after intramedullary rodding procedures and altered reshaping of existing fractures in patients with OI [34, 39, 40]. Contraindications to use BPs in children are renal impairment, untreated hypovitaminosis D, or hypocalcemia [34].

BPs are still used off-label in pediatric age, although several studies, mainly in children with OI, support their efficacy and safety [41–44]. BP administration in children with OI has been associated with increased bone mass, improved mobility, reduction of pain, and fracture rate [45–48]. In disuse-related bone fragility conditions, e.g., cerebral palsy, BPs also increased BMD Z-scores of both the lumbar spine and hip [49] but their effect is limited due to low bone turnover. In boys with DMD, the administration of pamidronate or zoledronate resulted in resolution or decrease of back pain, stabilization of previous fractures or improvement of vertebral height, and partially prevented the occurrence of new fractures [50]. The efficacy of zoledronate in glucocorticoid-induced osteoporosis has been shown with a significant increase in lumbar spine BMD Z-score compared to placebo after 1 year of treatment. No new VFs occurred in the treated group ($n = 18$), while new VFs occurred in two children on placebo ($n = 16$) [51].

Table 1 Main bisphosphonates used in pediatric patients: indications, contraindications, route of administration, dosing, adverse effects

Indications	Contraindications	Route of administration	Dosing*	Most common adverse effects,**	Notes
Alendronate	Osteoporosis, OI, Gaucher's disease Hypocalcemia, delayed esophageal emptying, severe renal failure, hypersensitivity, inability to stand or sit for at least 30 min	Oral	Up to 30 kg: 5 mg once daily 30–40 kg: 5–10 mg once daily Above 40 kg: 10 mg once daily Continuously for 24 months	Hypocalcemia and/or hypophosphatemia, esophagitis (possible ulcers), dysphagia, retrosternal pain, abdominal pain, diarrhea, constipation, rash, musculoskeletal pain	Children > 2 years old
Neridronate	OI, Paget's disease Hypocalcemia, severe renal failure, hypersensitivity	Intravenously	1–2 mg/kg in one day (max 100 mg) every 3 months	Hypocalcemia, acute phase reaction, rash	Possible intramuscular administration (same dose divided in 4 days)
Pamidronate	Hypocalcemia, OI, Steroid-induced osteoporosis, Idiopathic Juvenile Osteoporosis, Paget's disease Hypocalcemia, severe renal failure, hypersensitivity	Intravenously	Hypercalcemia: 0.5–1.5 mg/kg over 4 h 2–3 consecutive days, every 6–8 weeks. OI and osteoporosis: 0.5–1 mg/kg once a day per 3 days or 2 mg/kg once, every 4 months, max 9 mg/kg/year	Hypocalcemia, acute phase reaction, rash, hypophosphatemia, hypomagnesemia, hypokalemia, anemia, hypertension, cough	Possible reduction of the first dose to reduce the acute phase reaction symptoms and hypocalcemia
Risedronate	Osteoporosis, Paget's disease Hypocalcemia, delayed esophageal emptying, severe renal failure, hypersensitivity, inability to stand or sit for at least 30 min	Oral	5 mg/daily for 1 year (30 mg/daily for Paget's disease) or 35 mg/weekly	Hypocalcemia, abdominal pain, esophagitis, gastritis, constipation, diarrhea, headache, musculoskeletal pain, rash	Possible use in children with OI (2.5–5 mg/daily)
Zoledronate	OI, steroid-induced osteoporosis, immobility-induced osteoporosis Hypocalcemia, severe renal failure, hypersensitivity	Intravenously	children aged 1–3 years: 0.025 mg/kg every 3 months, children aged 3–17 years: 0.05 mg/kg (max 4 mg/dose) every 3–6 months	Hypocalcemia, acute phase reaction, rash, hypophosphatemia	Possible reduction of the first dose to reduce the acute phase reaction symptoms and hypocalcemia. Not used < 2 years old

*The choice and dosing of BPs can vary according to the national (and local) guidelines. After BMD Z-score above – 2 SD is reached, BPs should be continued on a maintenance regimen (e.g. half dose). After a BMD Z-score value above 0 is reached, administration at a lower dosage or reduced frequency should be considered until the end of growth. Dosing regimens characterized by less frequent administrations should be preferred, in the interest of the patient and to reduce the costs for the health systems

**For intravenous BPs an acute phase reaction is experienced by the vast majority of patients and it is characterized by fever, arthralgias, myalgias, headache, nausea, and vomiting

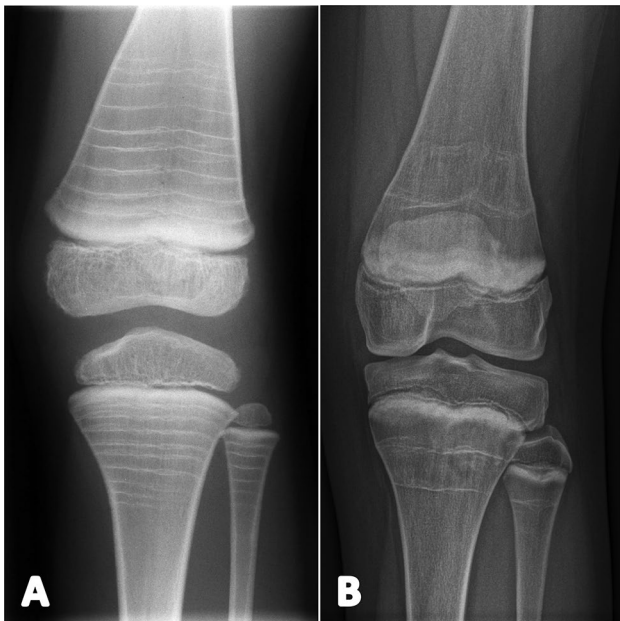


Fig. 1 Effect of BPs and denosumab on bone metaphysis; left knee radiographs. **A** Band-like metaphyseal sclerosis in a boy diagnosed with OI by the age of 3.5 years, 3 years after the start of BPs (pamidronate intravenously at 4-month intervals). **B** Metaphyseal sclerosis in a 13-year-old girl long-term treated with denosumab because of a recurring spinal aneurysmal bone cyst

Denosumab

Denosumab is a human monoclonal antibody administered subcutaneously which, like BPs, inhibits bone resorption by inhibiting osteoclasts. Denosumab does this by binding to RANK-L, mimicking the inhibitory effects of osteoprotegerin and leading to a decrease in bone turnover [52]. Denosumab is not embedded in the bone matrix, thus its effects are rapidly reversed after cessation of treatment. Rapid onset of bone resorption with sudden massive increase of bone turnover markers follows cessation of treatment, potentially resulting in rebound hypercalcemia in children and in rebound VFs in adults.

Little is known about the risks of denosumab in children. The first clinical trial in children with OI was stopped because of rebound hypercalcemia [53]. Concerns have been raised regarding linear growth and fracture healing because of the potent effect of denosumab on bone remodeling. In children, continued epiphyseal activity both during and after treatment and normal growth velocity have been reported [54–58], although the metaphyseal sclerosis and the retention of calcified cartilage at the growth plates consequent to denosumab administration may potentially have negative effects on growth and bone shape, Fig. 1B [54]. In adults, osteonecrosis of the jaw (ONJ) is a known complication of

denosumab therapy, when high doses are used to treat a giant cell tumor of the bone (GCTB). To date, ONJ has only been reported in two children receiving denosumab because of a GCTB [59, 60], who also developed, after cessation of treatment, acute severe hypercalcemia with acute kidney failure. Although normally transient, hypercalcemia with subsequent risk of acute kidney failure can be a severe complication of denosumab discontinuation, thus careful monitoring of serum and urinary calcium is required [52, 59, 61–63].

To date, denosumab has only been used off-label in children with OI, and non-osteoporotic conditions such as juvenile Paget's disease, fibrous dysplasia, GCTB, and aneurysmal bone cysts. In this last condition, successful treatment with denosumab has been reported in several cases, supporting the use of denosumab as alternative treatment especially in patients with spinal and pelvic tumors, for whom surgery would be associated with potentially high morbidity [64–66].

Up until now, denosumab does not have a pediatric license and does not represent a first-line medication in children and adolescents affected by osteoporosis. However, it can represent an off-label treatment in patients with renal failure or those with poor response or severe side effects to BPs, and certainly those with GCTB and aneurysmal bone cysts, if used with extreme precaution.

Sclerostin inhibitors

Sclerostin inhibitors are a novel class of monoclonal antibodies that, through their binding to sclerostin, act with a dual effect on bone metabolism, inhibiting bone resorption and increasing bone formation [67]. Romosozumab effectiveness has been shown by two phase 3 clinical trials performed in women with postmenopausal osteoporosis and a high risk of fractures [68, 69]. Up until now, there is no licensed indication for romosozumab use in children, but an ongoing international trial is evaluating the drug in children affected by OI [70]. Also, a second sclerostin inhibitor (setrusumab) is currently under evaluation in patients with OI [71].

Surgical interventions

Next to conservative approaches and pharmacological treatment, sometimes surgical intervention is needed to correct deformities of the limbs (corrective osteotomy and intramedullary rodding), to improve limb function, or to treat progressive scoliosis and kyphosis of the spine to prevent pulmonary insufficiency, pain, and disability.

In children with OI, the rodding of lower limbs is often associated with a significant increase in mobility. Also, the rodding of upper extremities can have a good impact on a

child's mobility by improving grip and upper arm strength and arm length, with subsequent higher functional abilities (for example the child can use supports for walking, e.g., K-walkers or crutches, more easily). Indications to perform surgery (e.g., rodding of severely deformed long bones with or without frequent fractures) usually start from the age when the child can stand more or less independently to assist locomotion and reduce the risk of fractures [72]. Another benefit to consider is the improved aesthetic appearance of the limb which can have a positive impact on the child's self-perception [73].

The patient and his/her parents should however be aware that surgery does not always improve mobility and might only reduce fracture risk. Lack of access to regular physiotherapy and rehabilitation can represent important limitations for mobility improvement. Also, intramedullary rodding in children with brittle bones is associated with relatively high rates of complications (such as an outgrown nail, nail migration, impaired osteotomy healing, and re-fracture) and revision surgeries are often necessary. Consultation of a pediatric orthopedic surgeon experienced with surgery in OI is crucial for the patient [74].

Treatment indications

Apart from OI, there is at present a relative paucity of studies investigating treatment interventions in children with different forms of secondary osteoporosis. Therefore, and given the potential of spontaneous recovery of bone disease in acquired conditions, a conservative approach is still advised by the International Society for Clinical Densitometry (ISCD) [75] with pharmacological therapy typically reserved for children with recurrent long bone fractures or those experiencing at least one VF [76].

In children affected by primary osteoporosis such as OI, BPs are the most widely used treatment, administered intravenously in moderate and severe forms of OI while in mild forms and in the absence of VFs, oral administration should be considered [34]. After the initial phase of treatment and once BMD Z-score is above -2 SD, BPs should be continued on a maintenance regimen (e.g., half dose) to enhance and stabilize the increase of BMD. After a BMD Z-score value above 0 is reached, administration at a lower dosage or reduced frequency should be considered until the end of growth [77, 78].

Less is known about the effect of BPs on children and adolescents affected by juvenile idiopathic osteoporosis (JIO). Although JIO tends to spontaneously recover at the end of adolescence, VFs and long bone fractures can occur with a risk of permanent bone deformities. Administration of BPs is beneficial, by reducing pain, fracture recurrence and by reducing the chance of future disability as a consequence of permanent deformities [79].

In patients affected by secondary osteoporosis and sufficient remaining growth potential, spontaneous recovery and reshaping of VFs can occur, if the underlying condition is under control, cured or the corticosteroid treatment is stopped. However, if ISCD criteria for pediatric osteoporosis are met, BPs are indicated. Re-evaluation of treatment continuation is conducted in yearly intervals, judged by reassessment of bone pain, fractures, vertebral reshaping, activity of the underlying conditions, osteotoxic medications, remaining growth potential, and DXA scan results [34]. In immobility-induced osteopenia (BMD Z-scores below -2 , without VFs or long bone fractures) or other chronic conditions, BPs can be considered if there is a declining trend in BMD and persisting risk factors [29]. The principal aspect to evaluate is the underlying (temporary or permanent) condition determining bone fragility [76]. For example, children affected by acute leukemia are mostly diagnosed at a young age: in this case, the insult to the bone is transient and the residual potential growth still high; consequently, the majority of VFs have a potential to reshape without any bone-active treatment if they remain in remission [80]. On the contrary, children affected by DMD and chronically treated with GCs present persistent severe risk factors for bone damage that make spontaneous fracture healing unlikely. An annual spinal radiography from the start of GCs is thus recommended [81].

Considering the heterogeneity of conditions, the diagnostic challenges, treatment indications, dosing regimens, and follow-up strategies, a pediatric endocrinologist with expertise in bone health must be involved in the management of these patients [38].

Follow-up

Children at risk of or with osteoporosis require careful monitoring by a pediatric specialist in order to detect new fractures early on, start treatment when appropriate, and prevent permanent deformities. For some conditions (e.g., OI, DMD, glucocorticoid-induced osteoporosis, disuse-induced osteoporosis, osteoporosis secondary to β -thalassemia) there are guidelines available with regard to follow-up [29, 77, 81–83]. However, some general recommendations can be given.

In children treated with high-dose and long-term steroids, BMD by DXA might be determined at the baseline, and then yearly, during the treatment period. Lateral spine radiographs, or VFA, should be conducted at baseline and yearly if (1) VFs are present at baseline and (2) there is a presence of continuous high-dose steroid therapy, worsening mobility, and/or poor control of the underlying disease. A lateral spine radiograph should always be performed in children at high risk for VFs who develop back pain or demonstrate a

decline in BMD Z-score ≥ 0.5 SD in two consecutive measurements [84].

For example, in children with DMD follow-up is required due to the persistent insult to their bones as a consequence of chronic treatment with GCs, progressive myopathy, reduced mobility, and often delayed puberty. There is a high risk of VFs and routine spine radiographs often detect otherwise asymptomatic fractures. Any first VF in DMD necessitates prompt BP treatment initiation. The detection of VFs at any time point is predictive of future VFs, according to the so-called vertebral fracture cascade. Routine thoracolumbar spine radiographs are therefore indicated yearly. To reduce the exposure to radiations, vertebral fracture assessment (VFA) using DXA, or MRI, should be used instead of lateral spine radiographs, where possible [81, 85].

Transition from pediatric to adult care

In general, the transition of care from pediatric to adult healthcare services is challenging. Up to 50% of young adults with an endocrine disorder are lost to follow-up after transfer to adult healthcare [86]. With regard to osteoporosis management, there is no consensus on the optimal timing of transition, but the majority of patients prefer the transfer at the age of 18–24 years [87]. The transition should be gradual, starting with structured education by the healthcare team at the age of 14 years, to accomplish independent and autonomous behavior over time [88, 89].

After transition, adult caregivers will lower the frequency of out-patient clinic visits and the frequency of BPs administration if adult height is reached, pubertal development is completed, and the cognitive functioning is adequate. However, 18-year-old adolescents still in follow-up for growth and pubertal development should be managed according to pediatric guidelines. Of note, treatment indications differ between pediatric and adult care as well as the dosage of intravenous BPs. For example, zoledronate in children is usually dosed at 0.05 mg/kg twice a year (max. 4 mg/dose); however, in adults, a dose of 5 mg is given yearly independently of weight, although adjustments are made in regard to renal function. Patients and adult health care providers need to be aware that, despite previous administrations of BPs, an acute phase reaction can (re)occur if a higher dose is given. Furthermore, it needs to be clear that these patients will not be covered by osteoporosis guidelines for adults as those can be applied by the age of 50 years onwards. The establishment of joint transition clinics between the pediatric and adult specialist is a successful model in which the patient can be seen more than once by both specialists to discuss all patient needs holistically, before being transferred to adult care.

Conclusion

The management of osteoporosis requires a multidisciplinary approach and treatment options include conservative measures, rehabilitation through physiotherapy and occupational therapy, medication (mainly BPs administration), orthopedic surgery, and orthotic devices. The choice of treatment and/or a combination of treatments needs to be tapered to the nature and severity of the disease and the needs of each child and thus personalized. New drugs, such as denosumab, offer hope for children with specific conditions, but with the risk of rebound hypercalcemia and ONJ. A careful follow-up is required to detect and monitor VFs, achieve vertebral reshaping, but also prevent the decline in BMD in untreated children at risk. Overall, the aim of therapy remains to build a stronger skeleton, a larger frame for adult life.

Authors' contributions All authors contributed to the study conception and design and to the literature search. The first draft of the manuscript was written by Silvia Ciancia and Judith S. Renes. All authors commented on previous versions of the manuscript. All authors read and approved the final manuscript.

Declarations

Ethical approval Not applicable.

References

1. Ciancia S, van Rijn RR, Hogler W, Appelman-Dijkstra NM, Boot AM, Sas TCJ, Renes JS (2022) Osteoporosis in children and adolescents: when to suspect and how to diagnose it. *Eur J Pediatr* 181:2549–2561. <https://doi.org/10.1007/s00431-022-04455-2>
2. El-Gazzar A, Hogler W (2021) Mechanisms of bone fragility: from osteogenesis imperfecta to secondary osteoporosis *Int J Mol Sci* 22. <https://doi.org/10.3390/ijms22020625>
3. Biggin A, Munns CF (2014) Osteogenesis imperfecta: diagnosis and treatment. *Curr Osteoporos Rep* 12:279–288. <https://doi.org/10.1007/s11914-014-0225-0>
4. Hurley T, Zareen Z, Stewart P, McDonnell C, McDonald D, Molloy E (2021) Bisphosphonate use in children with cerebral palsy. *Cochrane Database Syst Rev* 7:CD012756. <https://doi.org/10.1002/14651858.CD012756.pub2>
5. Weber DR (2020) Bone health in childhood chronic disease. *Endocrinol Metab Clin North Am* 49:637–650. <https://doi.org/10.1016/j.ecl.2020.07.002>
6. Bell JM, Shields MD, Watters J, Hamilton A, Beringer T, Elliott M, Quinlivan R, Tirupathi S, Blackwood B (2017) Interventions to prevent and treat corticosteroid-induced osteoporosis and prevent osteoporotic fractures in Duchenne muscular dystrophy. *Cochrane Database Syst Rev* 1:CD010899. <https://doi.org/10.1002/14651858.CD010899.pub2>
7. Saraff V, Hogler W (2015) Osteoporosis in children: diagnosis and management. *Eur J Endocrinol* 173:R185–197. <https://doi.org/10.1530/EJE-14-0865>

8. Gonzalez Ballesteros LF, Ma NS, Gordon RJ, Ward L, Backeljauw P, Wasserman H, Weber DR, DiMeglio LA, Gagne J, Stein R, Cody D, Simmons K, Zimakas P, Topor LS, Agrawal S, Calabria A, Tebben P, Faircloth R, Imel EA, Casey L, Carpenter TO (2017) Unexpected widespread hypophosphatemia and bone disease associated with elemental formula use in infants and children. *Bone* 97:287–292. <https://doi.org/10.1016/j.bone.2017.02.003>
9. Misra M, Pacaud D, Petryk A, Collett-Solberg PF, Kappy M, Drug, Therapeutics Committee of the Lawson Wilkins Pediatric Endocrine S (2008) Vitamin D deficiency in children and its management: review of current knowledge and recommendations. *Pediatrics* 122:398–417. <https://doi.org/10.1542/peds.2007-1894>
10. Tan VP, Macdonald HM, Kim S, Nettlefold L, Gabel L, Ashe MC, McKay HA (2014) Influence of physical activity on bone strength in children and adolescents: a systematic review and narrative synthesis. *Journal of bone and mineral research: the official journal of the American Society for Bone and Mineral Research* 29:2161–2181. <https://doi.org/10.1002/jbmr.2254>
11. Munns CF, Shaw N, Kiely M, Specker BL, Thacher TD, Ozono K, Michigami T et al (2016) Global consensus recommendations on prevention and management of nutritional rickets. *J Clin Endocrinol Metab* 101:394–415. <https://doi.org/10.1210/jc.2015-2175>
12. Högler W, Baumann U, Kelly D (2012) Endocrine and bone metabolic complications in chronic liver disease and after liver transplantation in children. *J Pediatr Gastroenterol Nutr* 54:313–321. <https://doi.org/10.1097/MPG.0b013e31823e9412>
13. Reid IR (2017) Vitamin D effect on bone mineral density and fractures. *Endocrinol Metab Clin North Am* 46:935–945. <https://doi.org/10.1016/j.ecl.2017.07.005>
14. Daly RM, Bass SL (2006) Lifetime sport and leisure activity participation is associated with greater bone size, quality and strength in older men. *Osteoporos Int* 17:1258–1267. <https://doi.org/10.1007/s00198-006-0114-1>
15. Sayar Y, Arikan FI, Tasar MA, Dallar Y (2015) Effect of sportive activity on bone mineral density during adolescence. *Türk Fiz Tip Rehab Derg* 61:120–124. <https://doi.org/10.5152/tftrd.2015.81905>
16. Dubnov-Raz G, Azar M, Reuveny R, Katz U, Weintraub M, Constantini NW (2015) Changes in fitness are associated with changes in body composition and bone health in children after cancer. *Acta Paediatr* 104:1055–1061. <https://doi.org/10.1111/apa.13052>
17. Hough JP, Boyd RN, Keating JL (2010) Systematic review of interventions for low bone mineral density in children with cerebral palsy. *Pediatrics* 125:e670-678. <https://doi.org/10.1542/peds.2009-0292>
18. Hoyer-Kuhn H, Semler O, Stark C, Struebing N, Goebel O, Schoenau E (2014) A specialized rehabilitation approach improves mobility in children with osteogenesis imperfecta. *J Musculoskelet Neuronal Interact* 14:445–453
19. Semler O, Fricke O, Vezyroglou K, Stark C, Stabrey A, Schoenau E (2008) Results of a prospective pilot trial on mobility after whole body vibration in children and adolescents with osteogenesis imperfecta. *Clin Rehabil* 22:387–394. <https://doi.org/10.1177/0269215507080763>
20. Hogler W, Scott J, Bishop N, Arundel P, Nightingale P, Mughal MZ, Padidela R, Shaw N, Crabtree N (2017) The effect of whole body vibration training on bone and muscle function in children with osteogenesis imperfecta. *J Clin Endocrinol Metab* 102:2734–2743. <https://doi.org/10.1210/jc.2017-00275>
21. Bianchi ML, Vai S, Morandi L, Baranello G, Pasanisi B, Rubin C (2013) Effects of low-magnitude high-frequency vibration on bone density, bone resorption and muscular strength in ambulant children affected by duchenne muscular dystrophy. *J Bone Miner Res* 28:S341. <https://doi.org/10.1002/central/CN-01064425/full?contentLanguage=en>
22. Söderpalm AC, Kroksmark AK, Magnusson P, Karlsson J, Tulinius M, Swolin-Eide D (2013) Whole body vibration therapy in patients with Duchenne muscular dystrophy – A prospective observational study. *J Musculoskelet Neuronal Interact* 13:13–18
23. Petryk A, Polgreen LE, Grames M, Lowe DA, Hodges JS, Karachunski P (2017) Feasibility and tolerability of whole-body, low-intensity vibration and its effects on muscle function and bone in patients with dystrophinopathies: a pilot study. *Muscle Nerve* 55:875–883. <https://doi.org/10.1002/mus.25431>
24. Ruck J, Chabot G, Rauch F (2010) Vibration treatment in cerebral palsy: a randomized controlled pilot study. *J Musculoskelet Neuronal Interact* 10:77–83
25. Saquetto M, Carvalho V, Silva C, Conceição C, Gomes-Neto M (2015) The effects of whole body vibration on mobility and balance in children with cerebral palsy: a systematic review with meta-analysis. *J Musculoskelet Neuronal Interact* 15:137–144
26. Tekin F, Kavlak E (2021) Short and long-term effects of whole-body vibration on spasticity and motor performance in children with hemiparetic cerebral palsy. *Percept Mot Skills* 128:1107–1129. <https://doi.org/10.1177/0031512521991095>
27. Tupimai T, Peungsuwan P, Prasertnoo J, Yamauchi J (2016) Effect of combining passive muscle stretching and whole body vibration on spasticity and physical performance of children and adolescents with cerebral palsy. *J Phys Ther Sci* 28:7–13. <https://doi.org/10.1589/jpts.28.7>
28. Swolin-Eide D, Magnusson P (2020) Does whole-body vibration treatment make children's bones stronger? *Curr Osteoporos Rep* 18:471–479. <https://doi.org/10.1007/s11914-020-00608-0>
29. Galindo-Zavala R, Bou-Torrent R, Magallares-Lopez B, Mir-Perello C, Palmou-Fontana N, Sevilla-Perez B, Medrano-San Ildefonso M, Gonzalez-Fernandez MI, Roman-Pascual A, Alcaniz-Rodriguez P, Nieto-Gonzalez JC, Lopez-Corbeto M, Grana-Gil J (2020) Expert panel consensus recommendations for diagnosis and treatment of secondary osteoporosis in children. *Pediatr Rheumatol Online J* 18:20. <https://doi.org/10.1186/s12969-020-0411-9>
30. Lee SL, Lim A, Munns C, Simm PJ, Zacharin M (2020) Effect of testosterone treatment for delayed puberty in Duchenne muscular dystrophy. *Horm Res Paediatr* 93:108–118. <https://doi.org/10.1159/000508290>
31. Michigami T, Ozono K (2019) Roles of phosphate in skeleton. *Front Endocrinol (Lausanne)* 10:180. <https://doi.org/10.3389/fendo.2019.00180>
32. Iolascon G, Moretti A (2022) The rationale for using neridronate in musculoskeletal disorders: from metabolic bone diseases to musculoskeletal pain. *Int J Mol Sci* 23. <https://doi.org/10.3390/ijms23136921>
33. Papapoulos SE, Cremers SC (2007) Prolonged bisphosphonate release after treatment in children. *N Engl J Med* 356:1075–1076. <https://doi.org/10.1056/NEJMc062792>
34. Simm PJ, Biggin A, Zacharin MR, Rodda CP, Tham E, Siafarikas A, Jefferies C, Hofman PL, Jensen DE, Woodhead H, Brown J, Wheeler BJ, Brookes D, Lafferty A, Munns CF, Group ABMW (2018) Consensus guidelines on the use of bisphosphonate therapy in children and adolescents. *J Paediatr Child Health* 54:223–233. <https://doi.org/10.1111/jpc.13768>
35. Bishop N, Adami S, Ahmed SF, Antón J, Arundel P, Burren CP, Devogelaer JP, Hangartner T, Hosszú E, Lane JM, Lorenc R, Mäkitie O, Munns CF, Paredes A, Pavlov H, Plotkin H, Raggio CL, Reyes ML, Schoenau E, Semler O, Sillence DO, Steiner RD (2013) Risedronate in children with osteogenesis imperfecta: a randomised, double-blind, placebo-controlled trial. *Lancet* 382:1424–1432. [https://doi.org/10.1016/s0140-6736\(13\)61091-0](https://doi.org/10.1016/s0140-6736(13)61091-0)
36. Högler W, Yap F, Little D, Ambler G, McQuade M, Cowell CT (2004) Short-term safety assessment in the use of intravenous zoledronic acid in children. *J Pediatr* 145:701–704. <https://doi.org/10.1016/j.jpeds.2004.06.066>
37. Munns CF, Rauch F, Mier RJ, Glorieux FH (2004) Respiratory distress with pamidronate treatment in infants with severe osteogenesis imperfecta. *Bone* 35:231–234. <https://doi.org/10.1016/j.bone.2004.03.008>


38. Ward L, Tricco AC, Phuong P, Cranney A, Barrowman N, Gaboury I, Rauch F, Tugwell P, Moher D (2007) Bisphosphonate therapy for children and adolescents with secondary osteoporosis. *Cochrane Database Syst Rev*:CD005324. <https://doi.org/10.1002/14651858.CD005324.pub2>
39. Munns CF, Rauch F, Zeitlin L, Fassier F, Glorieux FH (2004) Delayed osteotomy but not fracture healing in pediatric osteogenesis imperfecta patients receiving pamidronate. *Journal of bone and mineral research: the official journal of the American Society for Bone and Mineral Research* 19:1779–1786. <https://doi.org/10.1359/jbmr.040814>
40. Anam EA, Rauch F, Glorieux FH, Fassier F, Hamdy R (2015) Osteotomy healing in children with osteogenesis imperfecta receiving bisphosphonate treatment. *Journal of bone and mineral research: the official journal of the American Society for Bone and Mineral Research* 30:1362–1368. <https://doi.org/10.1002/jbmr.2486>
41. Land C, Rauch F, Munns CF, Sahebjam S, Glorieux FH (2006) Vertebral morphometry in children and adolescents with osteogenesis imperfecta: effect of intravenous pamidronate treatment. *Bone* 39:901–906. <https://doi.org/10.1016/j.bone.2006.04.004>
42. Land C, Rauch F, Montpetit K, Ruck-Gibis J, Glorieux FH (2006) Effect of intravenous pamidronate therapy on functional abilities and level of ambulation in children with osteogenesis imperfecta. *J Pediatr* 148:456–460. <https://doi.org/10.1016/j.jpeds.2005.10.041>
43. Rauch F, Munns C, Land C, Glorieux FH (2006) Pamidronate in children and adolescents with osteogenesis imperfecta: effect of treatment discontinuation. *J Clin Endocrinol Metab* 91:1268–1274. <https://doi.org/10.1210/jc.2005-2413>
44. Rauch F, Travers R, Glorieux FH (2006) Pamidronate in children with osteogenesis imperfecta: histomorphometric effects of long-term therapy. *J Clin Endocrinol Metab* 91:511–516. <https://doi.org/10.1210/jc.2005-2036>
45. Sakkars R, Kok D, Engelbert R, van Dongen A, Jansen M, Pruijs H, Verbout A, Schweitzer D, Uiterwaal C (2004) Skeletal effects and functional outcome with olpadronate in children with osteogenesis imperfecta: a 2-year randomised placebo-controlled study. *Lancet* 363:1427–1431. [https://doi.org/10.1016/s0140-6736\(04\)16101-1](https://doi.org/10.1016/s0140-6736(04)16101-1)
46. Rauch F, Travers R, Plotkin H, Glorieux FH (2002) The effects of intravenous pamidronate on the bone tissue of children and adolescents with osteogenesis imperfecta. *J Clin Invest* 110:1293–1299. <https://doi.org/10.1172/jci200215952>
47. Glorieux FH, Bishop NJ, Plotkin H, Chabot G, Lanoue G, Travers R (1998) Cyclic administration of pamidronate in children with severe osteogenesis imperfecta. *N Engl J Med* 339:947–952
48. Plotkin H, Rauch F, Bishop NJ, Montpetit K, Ruck-Gibis J, Travers R, Glorieux FH (2000) Pamidronate treatment of severe osteogenesis imperfecta in children under 3 years of age. *J Clin Endocrinol Metab* 85:1846–1850
49. Kim MJ, Kim SN, Lee IS, Chung S, Lee J, Yang Y, Lee I, Koh SE (2015) Effects of bisphosphonates to treat osteoporosis in children with cerebral palsy: a meta-analysis. *J Pediatr Endocrinol Metab* 28:1343–1350. <https://doi.org/10.1515/jpem-2014-0527>
50. Sbrocchi AM, Rauch F, Jacob P, McCormick A, McMillan HJ, Matzinger MA, Ward LM (2012) The use of intravenous bisphosphonate therapy to treat vertebral fractures due to osteoporosis among boys with Duchenne muscular dystrophy. *Osteoporos Int* 23:2703–2711. <https://doi.org/10.1007/s00198-012-1911-3>
51. Ward LM, Choudhury A, Alos N, Cabral DA, Rodd C, Sbrocchi AM, Taback S, Padidela R, Shaw NJ, Hosszu E, Kostik M, Alexeeva E, Thandrayan K, Shenouda N, Jaremko JL, Sunkara G, Sayeed S, Afring RP, Munns CF (2021) Zoledronic acid vs placebo in pediatric glucocorticoid-induced osteoporosis: a randomized, double-blind, phase 3 trial. *J Clin Endocrinol Metab* 106:e5222–e5235. <https://doi.org/10.1210/clinem/dgab458>
52. Boyce AM (2017) Denosumab: an emerging therapy in pediatric bone disorders. *Curr Osteoporos Rep* 15:283–292. <https://doi.org/10.1007/s11914-017-0380-1>
53. ClinicalTrials.gov (2022) Open-label extension denosumab study in children and young adults with osteogenesis imperfecta. *ClinicalTrials.gov Identifier*: NCT03638128.
54. Wang HD, Boyce AM, Tsai JY, Gafni RI, Farley FA, Kasa-Vubu JZ, Molinolo AA, Collins MT (2014) Effects of denosumab treatment and discontinuation on human growth plates. *J Clin Endocrinol Metab* 99:891–897. <https://doi.org/10.1210/jc.2013-3081>
55. Kobayashi E, Setsu N (2015) Osteosclerosis induced by denosumab. *The Lancet* 385. [https://doi.org/10.1016/s0140-6736\(14\)61338-6](https://doi.org/10.1016/s0140-6736(14)61338-6)
56. Hoyer-Kuhn H, Semler O, Schoenau E (2014) Effect of denosumab on the growing skeleton in osteogenesis imperfecta. *J Clin Endocrinol Metab* 99:3954–3955. <https://doi.org/10.1210/jc.2014-3072>
57. Hoyer-Kuhn H, Franklin J, Allo G, Kron M, Netzer C, Eysel P, Hero B, Schoenau E, Semler O (2016) Safety and efficacy of denosumab in children with osteogenesis imperfecta - a first prospective trial. *J Musculoskelet Neuronal Interact* 16:24–32
58. Hoyer-Kuhn H, Netzer C, Koerber F, Schoenau E, Semler O (2014) Two years' experience with denosumab for children with Osteogenesis imperfecta type VI. *Orphanet J Rare Dis* 9:1–8. <https://doi.org/10.1186/s13023-014-0145-1>
59. Uday S, Gaston CL, Rogers L, Parry M, Joffe J, Pearson J, Sutton D, Grimer R, Högl W (2018) Osteonecrosis of the jaw and rebound hypercalcemia in young people treated with denosumab for giant cell tumor of bone. *J Clin Endocrinol Metab* 103:596–603. <https://doi.org/10.1210/jc.2017-02025>
60. Mariz B, Migliorati CA, Alves FA, Penteado FM, Carvalho NPF, Santos-Silva AR, Rocha AC (2021) Successful denosumab treatment for central giant cell granuloma in a 9-year-old child. *Spec Care Dentist* 41:519–525. <https://doi.org/10.1111/scd.12588>
61. Horiuchi K, Kobayashi E, Mizuno T, Susa M, Chiba K (2021) Hypercalcemia following discontinuation of denosumab therapy: a systematic review. *Bone Rep* 15:101148. <https://doi.org/10.1016/j.bonr.2021.101148>
62. Setsu N, Kobayashi E, Asano N, Yasui N, Kawamoto H, Kawai A, Horiuchi K (2016) Severe hypercalcemia following denosumab treatment in a juvenile patient. *J Bone Miner Metab* 34:118–122. <https://doi.org/10.1007/s00774-015-0677-z>
63. Gossai N, Hilgers MV, Polgreen LE, Greengard EG (2015) Critical hypercalcemia following discontinuation of denosumab therapy for metastatic giant cell tumor of bone. *Pediatr Blood Cancer* 62:1078–1080. <https://doi.org/10.1002/psc.25393>
64. H Marcus M, Aldridge S, Abudu A, Jeys L, Senniappan S, Morgan H, Pizer B (2020) The efficacy of denosumab in the management of a tibial paediatric aneurysmal bone cyst compromised by rebound hypercalcaemia. *Case Rep Pediatr* 2020:8854441. <https://doi.org/10.1155/2020/8854441>
65. Kurucu N, Akyuz C, Ergen FB, Yalcin B, Kosemehmetoglu K, Ayvaz M, Varan A, Aydin B, Kutluk T (2018) Denosumab treatment in aneurysmal bone cyst: evaluation of nine cases. *Pediatr Blood Cancer* 65. <https://doi.org/10.1002/pbc.26926>
66. Dürr HR, Grahneis F, Baur-Melnyk A, Knösel T, Birkenmaier C, Jansson V, Klein A (2019) Aneurysmal bone cyst: results of an off label treatment with Denosumab. *BMC Musculoskelet Disord* 20:456. <https://doi.org/10.1186/s12891-019-2855-y>
67. Kocijan R, Haschka J, Feurstein J, Zwerina J (2021) New therapeutic options for bone diseases. *Wien Med Wochenschr* 171:120–125. <https://doi.org/10.1007/s10354-020-00810-w>
68. Cosman F, Crittenden DB, Adachi JD, Binkley N, Czerwinski E, Ferrari S, Hofbauer LC, Lau E, Lewiecki EM, Miyauchi A, Zerbini CA, Milmont CE, Chen L, Maddox J, Meisner PD, Libanati C, Grauer A (2016) Romosozumab treatment in postmenopausal

- women with osteoporosis. *N Engl J Med* 375:1532–1543. <https://doi.org/10.1056/NEJMoa1607948>
69. Saag KG, Petersen J, Brandi ML, Karaplis AC, Lorentzon M, Thomas T, Maddox J, Fan M, Meisner PD, Grauer A (2017) Romosozumab or alendronate for fracture prevention in women with osteoporosis. *N Engl J Med* 377:1417–1427. <https://doi.org/10.1056/NEJMoa1708322>
 70. ClinicalTrials.gov Identifier: NCT04545554 (2020) Study to evaluate romosozumab in children and adolescents with osteogenesis imperfecta.
 71. ClinicalTrials.gov Identifier: NCT05125809 (2021) Study to assess the efficacy and safety of setrusumab in participants with osteogenesis imperfecta.
 72. Fassier FR (2021) Osteogenesis imperfecta-who needs rodding surgery? *Curr Osteoporos Rep* 19:264–270. <https://doi.org/10.1007/s11914-021-00665-z>
 73. Ashby E, Montpetit K, Hamdy RC, Fassier F (2016) Functional outcome of forearm rodding in children with osteogenesis imperfecta. *J Pediatr Orthop* 38:54–59. <https://doi.org/10.1097/BPO.0000000000000724>
 74. Sakkars RJ, Montpetit K, Tsimicalis A, Wirth T, Verhoef M, Hamdy R, Ouellet JA, Castelein RM, Damas C, Janus GJ, Nijhuis WH, Panzeri L, Pavari S, Mekking D, Thorstad K, Kruse RW (2021) A roadmap to surgery in osteogenesis imperfecta: results of an international collaboration of patient organizations and interdisciplinary care teams. *Acta Orthop* 92:608–614. <https://doi.org/10.1080/17453674.2021.1941628>
 75. Bishop N, Arundel P, Clark E, Dimitri P, Farr J, Jones G, Makitie O, Munns CF, Shaw N, International Society of Clinical D (2014) Fracture prediction and the definition of osteoporosis in children and adolescents: the ISCD 2013 Pediatric Official Positions. *J Clin Densitom* 17:275–280. <https://doi.org/10.1016/j.jocd.2014.01.004>
 76. Ward LM, Weber DR, Munns CF, Hogler W, Zemel BS (2020) A contemporary view of the definition and diagnosis of osteoporosis in children and adolescents. *J Clin Endocrinol Metab* 105:e2088–e2097. <https://doi.org/10.1210/clinem/dgz294>
 77. Trejo P, Rauch F (2016) Osteogenesis imperfecta in children and adolescents-new developments in diagnosis and treatment. *Osteoporos Int* 27:3427–3437. <https://doi.org/10.1007/s00198-016-3723-3>
 78. Dwan K, Phillipi CA, Steiner RD, Basel D (2016) Bisphosphonate therapy for osteogenesis imperfecta. *Cochrane Database Syst Rev* 10:CD005088. <https://doi.org/10.1002/14651858.CD005088.pub4>
 79. Baroncelli GI, Vierucci F, Bertelloni S, Erba P, Zampollo E, Giuca MR (2013) Pamidronate treatment stimulates the onset of recovery phase reducing fracture rate and skeletal deformities in patients with idiopathic juvenile osteoporosis: comparison with untreated patients. *J Bone Miner Metab* 31:533–543. <https://doi.org/10.1007/s00774-013-0438-9>
 80. Ward LM, Ma J, Lang B, Ho J, Alos N, Matzinger MA, Shenouda N et al (2018) Bone morbidity and recovery in children with acute lymphoblastic leukemia: results of a six-year prospective cohort study. *J Bone Miner Res* 33:1435–1443. <https://doi.org/10.1002/jbmr.3447>
 81. Birnkrant DJ, Bushby K, Bann CM, Alman BA, Apkon SD, Blackwell A, Case LE, Cripe L, Hadjiyannakis S, Olson AK, Sheehan DW, Bolen J, Weber DR, Ward LM (2018) Diagnosis and management of Duchenne muscular dystrophy, part 2: respiratory, cardiac, bone health, and orthopaedic management. *The Lancet Neurology* 17:347–361. [https://doi.org/10.1016/s1474-4422\(18\)30025-5](https://doi.org/10.1016/s1474-4422(18)30025-5)
 82. Birnkrant DJ, Bushby K, Bann CM, Apkon SD, Blackwell A, Brumbaugh D, Case LE, Clemens PR, Hadjiyannakis S, Pandya S, Street N, Tomezsko J, Wagner KR, Ward LM, Weber DR (2018) Diagnosis and management of Duchenne muscular dystrophy, part 1: diagnosis, and neuromuscular, rehabilitation, endocrine, and gastrointestinal and nutritional management. *The Lancet Neurology* 17:251–267. [https://doi.org/10.1016/s1474-4422\(18\)30024-3](https://doi.org/10.1016/s1474-4422(18)30024-3)
 83. Bhardwaj A, Swe KM, Sinha NK, Osunkwo I (2016) Treatment for osteoporosis in people with β -thalassaemia. *Cochrane Database Syst Rev* 3:CD010429. <https://doi.org/10.1002/14651858.CD010429.pub2>
 84. Ward LM (2020) Glucocorticoid-induced osteoporosis: why kids are different. *Front Endocrinol (Lausanne)* 11:576. <https://doi.org/10.3389/fendo.2020.00576>
 85. Joseph S, Wang C, Di Marco M, Horrocks I, Abu-Arafah I, Baxter A, Cordeiro N, McLellan L, McWilliam K, Naismith K, Stephen E, Ahmed SF, Wong SC (2019) Fractures and bone health monitoring in boys with Duchenne muscular dystrophy managed within the Scottish Muscle Network. *Neuromuscul Disord* 29:59–66. <https://doi.org/10.1016/j.nmd.2018.09.005>
 86. Gleeson H, Davis J, Jones J, O'Shea E, Clayton PE (2013) The challenge of delivering endocrine care and successful transition to adult services in adolescents with congenital adrenal hyperplasia: experience in a single centre over 18 years. *Clin Endocrinol (Oxf)* 78:23–28. <https://doi.org/10.1111/cen.12053>
 87. Godbout A, Tejedor I, Malivoir S, Polak M, Touraine P (2012) Transition from pediatric to adult healthcare: assessment of specific needs of patients with chronic endocrine conditions. *Horm Res Paediatr* 78:247–255. <https://doi.org/10.1159/000343818>
 88. Campbell F, Biggs K, Aldiss SK, O'Neill PM, Clowes M, McDonagh J, While A, Gibson F (2016) Transition of care for adolescents from paediatric services to adult health services. *Cochrane Database Syst Rev* 4:CD009794. <https://doi.org/10.1002/14651858.CD009794.pub2>
 89. Blum RW, Garell D, Hodgman CH, Jorissen TW, Okinow NA, Orr DP, Slap GB (1993) Transition from child-centered to adult health-care systems for adolescents with chronic conditions. A position paper of the Society for Adolescent Medicine. *J Adolesc Health* 14:570–576. [https://doi.org/10.1016/1054-139x\(93\)90143-d](https://doi.org/10.1016/1054-139x(93)90143-d)

Publisher's Note Springer Nature remains neutral with regard to jurisdictional claims in published maps and institutional affiliations.

Springer Nature or its licensor (e.g. a society or other partner) holds exclusive rights to this article under a publishing agreement with the author(s) or other rightsholder(s); author self-archiving of the accepted manuscript version of this article is solely governed by the terms of such publishing agreement and applicable law.

Authors and Affiliations

Silvia Ciancia¹  · Wolfgang Högler² · Ralph J. B. Sakkers³ · Natasha M. Appelman-Dijkstra⁴ · Annemieke M. Boot⁵ · Theo C. J. Sas^{1,6} · Judith S. Renes^{7,8}

Wolfgang Högler
wolfgang.hoegler@kepleruniklinikum.at

Ralph J. B. Sakkers
r.sakkers@umcutrecht.nl

Natasha M. Appelman-Dijkstra
n.m.appelman-dijkstra@lumc.nl

Annemieke M. Boot
a.m.boot@umcg.nl

Theo C. J. Sas
t.sas@erasmusmc.nl

Judith S. Renes
j.s.renes@asz.nl

¹ Department of Pediatrics, Subdivision of Endocrinology, Erasmus University Medical Center, Sophia Children's Hospital, Rotterdam, The Netherlands

² Department of Pediatrics and Adolescent Medicine, Johannes Kepler University Linz, Linz, Austria

³ Department of Orthopedic Surgery, Wilhelmina Children's Hospital, University Medical Center Utrecht, Utrecht, The Netherlands

⁴ Department of Internal Medicine, Subdivision of Endocrinology, Center for Bone Quality, Leiden University Medical Center, Leiden, The Netherlands

⁵ Department of Pediatrics, Subdivision of Endocrinology, University Medical Center Groningen, Beatrix Childrens Hospital, University of Groningen, Groningen, The Netherlands

⁶ Center for Pediatric and Adult Diabetes Care and Research, Rotterdam, The Netherlands

⁷ Department of Pediatrics, Albert Schweitzer Hospital, Dordrecht, The Netherlands

⁸ Dutch Growth Research Foundation, Rotterdam, The Netherlands