



**Universiteit
Leiden**
The Netherlands

Diagnostic accuracy of the AGA, IAP, and European guidelines for detecting advanced neoplasia in intraductal papillary mucinous neoplasm/neoplasia

Huijgevoort, N.C.M. van; Hoogenboom, S.A.M.; Lekkerkerker, S.J.; Busch, O.R.; Chiaro, M. del; Fockens, P.; ... ; Hooft, J.E. van

Citation


Huijgevoort, N. C. M. van, Hoogenboom, S. A. M., Lekkerkerker, S. J., Busch, O. R., Chiaro, M. del, Fockens, P., ... Hooft, J. E. van. (2023). Diagnostic accuracy of the AGA, IAP, and European guidelines for detecting advanced neoplasia in intraductal papillary mucinous neoplasm/neoplasia. *Pancreatology*, 23(3), 251-257. doi:10.1016/j.pan.2023.01.011

Version: Publisher's Version

License: [Licensed under Article 25fa Copyright Act/Law \(Amendment Taverne\)](#)

Downloaded from: <https://hdl.handle.net/1887/3633632>

Note: To cite this publication please use the final published version (if applicable).



Diagnostic accuracy of the AGA, IAP, and European guidelines for detecting advanced neoplasia in intraductal papillary mucinous neoplasm/neoplasia

Nadine C.M. van Huijgevoort^a, Sanne A.M. Hoogenboom^a, Selma J. Lekkerkerker^a, Olivier R. Busch^b, Marco Del Chiaro^c, Paul Fockens^a, Inne Somers^{d,e}, Joanne Verheij^f, Rogier P. Voermans^a, Marc G. Besselink^{b,1}, Jeanin E. van Hooft^{g,1,*}

^a Department of Gastroenterology and Hepatology, Amsterdam Gastroenterology and Metabolism, Amsterdam UMC, University of Amsterdam, the Netherlands

^b Department of Surgery, Cancer Center Amsterdam, Amsterdam UMC, University of Amsterdam, the Netherlands

^c Department of Surgical Oncology, University of Colorado Anschutz Medical Campus, Aurora, CO, USA

^d Department of Radiology, Amsterdam UMC, University of Amsterdam, the Netherlands

^e Department of Radiology, Meander Medical Center, Amersfoort, the Netherlands

^f Department of Pathology, Cancer Center Amsterdam, Amsterdam UMC, University of Amsterdam, the Netherlands

^g Department of Gastroenterology and Hepatology, Leiden University Medical Center, Leiden, the Netherlands

ARTICLE INFO

Article history:

Received 4 July 2022

Received in revised form

31 December 2022

Accepted 23 January 2023

Available online 6 February 2023

ABSTRACT

Background: Follow-up in patients with intraductal papillary mucinous neoplasm (IPMN) aims to detect advanced neoplasia (high-grade dysplasia/cancer) in an early stage. The 2015 American Gastroenterological Association (AGA), 2017 International Association of Pancreatology (IAP), and the 2018 European Study Group on Cystic tumours of the Pancreas (European) guidelines differ in their recommendations on indications for surgery. However, it remains unclear which guideline is most accurate in predicting advanced neoplasia in IPMN.

Methods: Patients who underwent surgery were extracted from a prospective database (January 2006–January 2021). In patients with IPMN, final pathology was compared with the indication for surgery according to the guidelines. ROC-curves were calculated to determine the diagnostic accuracy for each guideline.

Results: Overall, 247 patients underwent surgery for cystic lesions. In 145 patients with IPMN, 52 had advanced neoplasia, of which the AGA guideline would have advised surgery in 14 (27%), the IAP and European guideline in 49 (94%) and 50 (96%). In 93 patients without advanced neoplasia, the AGA, IAP, and European guidelines would incorrectly have advised surgery in 8 (8.6%), 77 (83%) and 71 (76%).

Conclusion: The European and IAP guidelines are clearly superior in detecting advanced neoplasia in IPMN as compared to the AGA, albeit at the cost of a higher rate of unnecessary surgery. To harmonize care and to avoid confusion caused by conflicting statements, a global evidence-based guideline for PCN in collaboration with the various guidelines groups is required once the current guidelines require an update.

© 2023 Published by Elsevier B.V. on behalf of IAP and EPC.

* Corresponding author. Dept. of Gastroenterology and Hepatology, C4-19 Leiden University Medical Center Albinusdreef 2, C4P 2300, RC, Leiden, the Netherlands.

E-mail address: J.E.van_Hooft@lumc.nl (J.E. van Hooft).

¹ Shared senior authorship.

1. Introduction

Increased use of high-quality cross-sectional imaging and the trend for healthy individuals to undergo preventive health check-ups, including full-body magnetic resonance imaging (MRI), has increased the detection of pancreatic cystic neoplasms (PCN). The increased detection and awareness of PCN led to the development of several, mainly consensus-based, periodically revised national

Abbreviations	
ACG	American College of Gastroenterology
AGA	American Gastroenterological Association
AI	Artificial Intelligence
AN	Advanced Neoplasia
AUC	Area Under the Curve
CA 19.9	Cancer Antigen 19.9
CI	Confidence Interval
cm	Centimeter
cNET	Cystic Neuroendocrine Tumor
CT	Computed Tomography
European	European Study Group of Cystic tumours of the Pancreas
EUS	Endoscopic Ultrasound
GNAS	Guanine nucleotide binding protein (G protein), alpha stimulating activity polypeptide 1
HGD	High-grade dysplasia
IAP	International Association of Pancreatology
IPMN	Intraductal Papillary Mucinous Neoplasm
IQR	Interquartile Range
KRAS	v-Ki-ras2 Kirsten rat sarcoma 2 viral oncogene homolog
LGD	Low-grade dysplasia
MCN	Mucinous Cystic Neoplasm
MD	Main Duct
mm	millimeter
MRI	Magnetic Resonance Imaging
MT	Mixed Type
n	Number
PCN	Pancreatic Cystic Neoplasm
PD	Pancreatic Duct
PDAC	Pancreatic ductal adenocarcinoma
PIK3CA	Phosphatidylinositol-4,5-Bisphosphate 3-Kinase Catalytic Subunit Alpha
PTEN	Phosphatase and Tensin Homolog deleted on Chromosome 10
ROC curve	Receiver operating characteristic curve
SB	Side Branch
SCN	Serous Cystic Neoplasm
SD	Standard Deviation
SPN	Solid Pseudopapillary Neoplasm
TP53	Tumor Protein 53

and international guidelines. Currently, the 2015 American Gastroenterological Association (AGA) [1], the 2017 International Association of Pancreatology (IAP) [2] and the 2018 European Study Group on Cystic tumours of the Pancreas (European) [3] guidelines provide recommendations on follow-up and surgical resection based on symptoms and the (perceived) risk of malignancy. An additional fourth guideline, the American College of Gastroenterology (ACG) Clinical Guideline, does not give recommendations on follow-up or surgical treatment of PCN [4]. The IAP [2] and European [3] guidelines are revisions of earlier guidelines. The primary goal of these guidelines is to prevent malignancy and/or alleviate symptoms, while avoiding unnecessary surgery. Surgical resection is generally considered justifiable, in hindsight, in patients with advanced neoplasia (i.e. high-grade dysplasia (HGD) or invasive cancer) or in patients with symptom improvement after resection of symptomatic PCN.

The exact recommendations on indications for surgical resection of IPMN and symptomatic PCN differ between guidelines (Table 1). For IPMN, the IAP and European guidelines advise resection in case of involvement of the main pancreatic duct (i.e. main duct (MD)- or mixed type (MT)-IPMN), whereas the AGA guideline requires the presence of a nodule or cytology positive for malignancy. Management of side branch (SB)-IPMN also differs between guidelines. Considering the variation in recommendations for surgery, it remains indeterminate which guideline is most accurate in predicting advanced neoplasia.

Therefore, this study aimed to evaluate and compare the diagnostic accuracy of each guideline in predicting advanced neoplasia in IPMN. Furthermore, we evaluated the diagnostic accuracy of a multidisciplinary team of experts.

2. Patients and methods

2.1. Study cohort

This study was designed as a monocenter, retrospective cohort study describing the accuracy of the different guidelines in identifying advanced neoplasia in patients with IPMN. This study was reviewed by the Medical Ethics Review Committee of the

Amsterdam UMC, location Academic Medical Center, whom waived the need for informed consent under the Dutch Medical Research Involving Human Subjects Act (reference number WH17_330 # 17.384).

Since November 2006, all patients presenting at our tertiary care center with a potential PCN were registered in a prospective database. Surveillance modalities and intervals were based on the 2006 and 2012 IAP guidelines and the 2018 European guideline. All patients who underwent surgical resection because of PCN up to January 2021 were selected from the prospectively maintained database. The decision for surgical treatment was made in our multidisciplinary hepato-pancreato-biliary team meetings (including radiologists, interventional radiologists, surgeons and gastroenterologists). The diagnosis was made based on the combination of findings on cross-sectional imaging (computed tomography (CT), magnetic resonance imaging (MRI)) and/or endoscopic ultrasound (EUS) with or without fine needle aspiration for cyst fluid analysis, depending on the investigations that were performed.

Patient were referred for surgery in case of a suspected pancreatic malignancy, MCN, solid pseudopapillary neoplasm (SPN), cystic neuroendocrine tumor (cNET) and symptomatic PCN. Patients suspected for IPMN with at least one of the following features were referred for surgical resection: a(n) (enhancing) nodule, a dilated pancreatic duct (PD) of 10 mm or more, jaundice or cytology suspicious of malignancy. Relative indications for surgery in patients with IPMN were the presence of one or more of the following features: pancreatitis, dilated PD between 5 and 9 mm, cyst size of 3 cm or more, thickened/enhancing wall or abrupt caliber change of the PD with distal pancreatic atrophy. These absolute and relative indications were based on the IAP guidelines of 2006 and 2012 [5,6].

2.2. Data collection

Data were extracted retrospectively from the prospectively maintained database, including baseline characteristics, surgical characteristics, and histopathological outcomes. Cyst size was recorded as the maximum diameter on imaging (CT/MRI/EUS) as

Table 1
Absolute and relative indications for surgical resection in MCN and IPMN by the current AGA, IAP and European guidelines.

Guidelines	Cyst type	Absolute indications for surgery	Relative indications for surgery
AGA	MCN IPMN	MCN PD ≥ 5 mm (on MRI AND EUS) AND solid component OR cytology positive for malignancy	
IAP	MCN IPMN	MCN Cytology suspicious or positive for malignancy Jaundice (tumour related) Enhancing mural nodule (≥5 mm) PD dilatation ≥10 mm	Grow-rate ≥5 mm/2 years Increased levels of serum CA 19.9 PD dilatation between 5 and 9 mm Cyst diameter ≥ 30 mm Acute pancreatitis (caused by IPMN) Enhancing mural nodule (<5 mm) Abrupt change in caliber of PD with distal pancreatic atrophy Lymphadenopathy Thickened/enhancing cyst walls
European	MCN IPMN	Cyst diameter ≥40 mm Enhancing mural nodule Symptoms Positive cytology for malignancy/HGD Solid mass Jaundice (tumour related) Enhancing mural nodule (≥5 mm) PD dilatation ≥10 mm	Grow-rate ≥5 mm/year Increased levels of serum CA 19.9 (>37U/mL)* PD dilatation between 5 and 9.9 mm Cyst diameter ≥ 40 mm New onset of diabetes mellitus Acute pancreatitis (caused by IPMN) Enhancing mural nodule (<5 mm)

AGA, American Gastroenterological Association; CA 19.9, Cancer Antigen 19.9; EUS, endoscopic ultrasound; HGD, high-grade dysplasia; IAP, International Association of Pancreatology; IPMN, Intraductal papillary mucinous neoplasm; MCN, mucinous cystic neoplasm; MRI, Magnetic resonance imaging; PD, Pancreatic duct.

stated in the (radiological) report. If multiple cyst were present, the size of the largest cyst was used for the analysis. Cyst growth was defined as growth rate of at least 5 mm/year. A pancreatic duct of 5 mm or more was considered dilated. A serum cancer antigen CA 19.9 of more than 37 U/mL was considered elevated. Level of dysplasia was recorded as the highest grade of dysplasia, subdivided into low-grade, high-grade or invasive cancer according to the two-tiered grading system of dysplasia in PCN [7]. According to this two-tiered classification system, low-grade dysplasia included both low-grade and intermediate-grade dysplasia (IGD) [7]. Advanced neoplasia was defined as PCN with high-grade dysplasia or invasive cancer at surgical pathology.

2.3. Outcomes

The primary outcome was the diagnostic accuracy of the AGA, IAP, and European guidelines for detecting advanced neoplasia in IPMN. Resection was considered indicated if there was at least one absolute indication (or high-risk stigmata) present, or at least two relative indications (or worrisome features). The ACG guideline [4] was not included in the analysis, as the ACG only provides a recommendation for referral to a multidisciplinary team and not for surgical resection. Secondary outcomes included the number of patients in whom the preoperative differentiation between the type of cysts was made correctly by our multidisciplinary team of experts. For this analysis MD- and MT-IPMN were considered as the same entity. We also evaluated the number of patients in whom the preoperative differentiation between benign and (pre)malignant cyst was made correctly by our multidisciplinary team of experts.

2.4. Definitions

SB-IPMN is characterized by a cyst of 5 mm or more in diameter that communicates with the PD. MD-IPMN is characterized by segmental or diffuse dilation of the PD of 5 mm or more without other causes of obstruction. MT-IPMN is characterized by segmental or diffuse dilation of the PD of 5 mm or more without

other causes of obstruction and a cyst of 5 mm or more in diameter that communicates with the PD. Symptom improvement was defined as any (subjective) symptom improvement (abdominal pain, gastric outlet obstruction, or pancreatitis) after resection because of a cystic lesion suspected to be the cause of the symptoms. Benign cysts were defined as SCN or all the other non-neoplastic cysts. Pre(malignant) cysts were defined as MCN, IPMN, SPN, cNET, cystic ductal adenocarcinoma. Surgical resection was considered justified in retrospect for patients with invasive cancer, high-grade dysplasia, cNET, SPN or in patients with symptom improvement after resection of symptomatic pancreatic cysts (i.e. abdominal pain, gastric outlet obstruction, pancreatitis).

2.5. Statistical analysis

Continuous data were reported as mean ± standard deviation (SD) or as median and interquartile range (IQR), depending on the distribution. Categorical data were reported as frequency or percentage. Sensitivity, specificity, and accuracy were calculated to evaluate the diagnostic value. The area under the receiver operating characteristic curve (AUC) for the guidelines were statistically compared using MedCalc Statistical Software version 18.5 (MedCalc Software bvba, Ostend, Belgium; <http://www.medcalc.org>; 2018). P values of <0.05 were considered to be statistically significant. Statistical analysis were performed using IBM SPSS statistics version 24 (IBM, Armonk, NY, USA).

3. Results

From the 748 patients in our PCN database, 255 underwent surgical resection. Since 7 patients had incomplete data and 1 patient refused participation, 247 patients were included in our analysis (Fig. 1).

Baseline characteristics of these patients are shown in Table 2. We previously reported accuracy of the preoperative diagnosis in 115 of these patients based on the previous IAP and European guidelines [8].

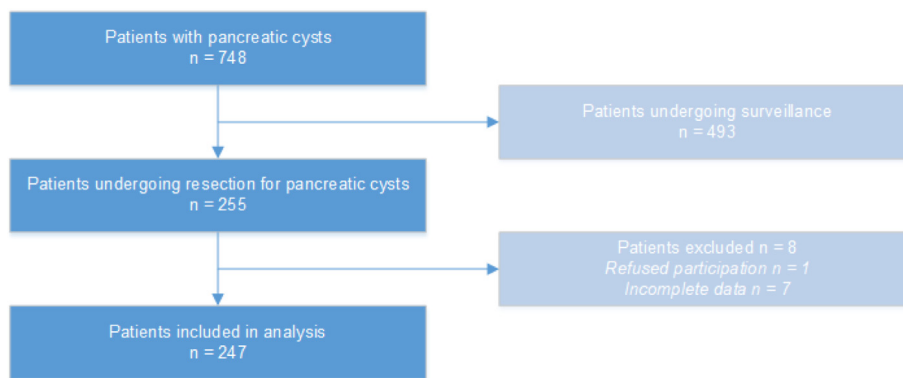


Fig. 1. Flow chart of patient selection.

Table 2

Baseline characteristics.

Characteristics	Total cohort (n = 247)
Female, n (%)	142 (57%)
Age, y, mean (SD)	60 (±14)
Any symptoms at diagnosis, n (%)	165 (67%)
Jaundice, n (%)	19 (7.7%)
Pancreatitis, n (%)	47 (19%)
PD size, mm	
<5 mm, n (%)	122 (49%)
5–9 mm, n (%)	60 (24%)
≥10 mm, n (%)	65 (26%)
Type of surgery	
Pancreatoduodenectomy, n (%)	116 (47%)
Central pancreatectomy, n (%)	11 (4.5%)
Distal pancreatectomy, n (%)	100 (40%)
Total pancreatectomy, n (%)	8 (3.2%)
Cyst enucleation, n (%)	8 (3.2%)
Diagnostic laparoscopy, n (%)	4 (1.6%)

IQR, interquartile range; n, number; PD, pancreatic duct; SD, standard deviation; y, year.

3.1. Diagnostic accuracy of the current guidelines in identifying advanced neoplasia in IPMN

Overall, 145 patients with IPMN (97 MD/MT-IPMN, 48 SB-IPMN) on surgical pathology were included in the analysis to identify the accuracy of the different guidelines for predicting advanced neoplasia. Three patients with IPMN were excluded from the final analysis as the indication for resection was not the IPMN, but a concurrent malignancy. Of the 145 patients with IPMN, 52 were diagnosed with advanced neoplasia; 19 patients with HGD and 33 patients with invasive cancer.

According to the AGA guideline, 22 of the 145 patients (15%) had at least one absolute indication for resection (Table 3). According to the IAP guideline, 97 of the 145 patients (67%) had at least one absolute indication and 47 (of the remaining 48) had at least one relative indication for resection. According to the European guideline, 97 of the 145 patients (67%) had at least one absolute indication, and 43 (of the remaining 48) had at least one relative indication for resection.

Of the 52 patients with advanced neoplasia on final pathology, 49 and 50 patients were detected by the IAP and the European guidelines, with a sensitivity of 94% and 96%, respectively (Table 4). In total, 3/52 patients with advanced neoplasia were missed by the IAP guidelines, and 2/52 by the European guidelines. One patient with a SB-IPMN of 49 mm with a non-enhancing nodule of 8 mm and one patient with a SB-IPMN of 23 mm with a non-enhancing

nodule of 8 mm were missed by both the IAP and European guidelines. A patient with recurrent episodes of pancreatitis, new onset diabetes, and a SB-IPMN of 16 mm was missed by the IAP guideline. Of the 19 patients with HGD on final pathology, 16 and 17 were detected by the IAP and the European guidelines, with a sensitivity of 84% and 89%, respectively. In contrast, 14/52 patients with advanced neoplasia were correctly suggested for surgical resection by the AGA guideline. Consequently, 38 patients with advanced neoplasia would have been missed, including 21 patients with invasive cancer, resulting in a sensitivity of 27%. Of the 19 patients with HGD on final pathology, 2 were detected by the AGA guideline. Of those patients without advanced neoplasia, 8 (8.6%), 77 (83%) and 71 (76%) would have been incorrectly suggested for surgical resection by the AGA, IAP and European guidelines, respectively. The ROC curve comparison analyses showed that the European guideline (AUC 0.599 95% CI 0.514–0.679) was superior to the IAP guideline (AUC 0.557 95% CI 0.472–0.640) in identifying advanced neoplasia (p = 0.009) (Fig. 2A), whereas no statistical difference was seen between the European and AGA guidelines (AUC 0.592 (0.507–0.672)) (p = 0.854) (Fig. 2B).

3.2. Diagnostic accuracy of multidisciplinary team

The preoperative classification of type of cysts by the multidisciplinary team was correct in 174/245 (70%) (Table 5). No final pathology was available in two patients; in one patient the lesion was unresectable, which resulted in an open-close procedure, and in the other patient no cystic lesion was found during surgery and therefore no resection was performed (this lesion was most likely a pseudocyst which had already resolved). Overall, MD/MT-IPMN, SB-IPMN and MCN were diagnosed with an accuracy of 89%, 71% and 81%, respectively. In 213/245 (87%) patients the correct preoperative differentiation was made between benign and (pre)malignant cysts by the multidisciplinary team.

In hindsight, surgery was justified in 100/247 patients (40%) based on final pathology (concurrent malignancy (n = 5, 2.0%), invasive cancer (n = 43, 17%), HGD (n = 21, 8.5%), SPN (n = 13, 5.3%), cNET (n = 4, 1.6%) and symptom improvement (n = 14, 5.7%). In hindsight, surgery could be seen as overtreatment for the remaining 147/247 patients (60%); resection of premalignant cystic neoplasms without advanced neoplasia (MD/MT-IPMN 57 (23%), SB-IPMN 28 (11%), MCN 25 (10%)), a benign/inflammatory cystic lesion 32 (13%), or no symptom improvement after resection because of a supposed symptomatic lesion (n = 5, 2.0%). The individual cases of patients with pancreatic cystic lesion undergoing surgery for supposed symptomatic lesions are described in Supplementary Table 1.

Table 3
Absolute and relative indications according to the different guidelines in the resected IPMN.

Diagnosis	AGA guideline (2015)	IAP guideline (2017)	European guideline (2018)
Absolute indications	n (%)	n (%)	n (%)
0	123 (85%)	48 (33%)	48 (33%)
1	15 (10%)	71 (49%)	71 (49%)
2	7 (4.8%)	20 (14%)	20 (14%)
3	0 (0.0%)	5 (3.4%)	5 (3.4%)
4	0 (0.0%)	1 (0.7%)	1 (0.7%)
Relative indications			
0	145 (100%)	26 (18%)	40 (28%)
1	0 (0.0%)	55 (38%)	63 (43%)
2	0 (0.0%)	43 (30%)	37 (26%)
3	0 (0.0%)	16 (11%)	5 (3.4%)
4	0 (0.0%)	5 (3.5%)	0 (0.0%)

IPMN, Intraductal Papillary Mucinous Neoplasm.

Table 4
Comparison of the current AGA, IAP, and European guidelines based on surgical pathology.

Guidelines	Advice guideline	Surgery indicated based on surgical pathology, n (%)	Surgery not indicated based on surgical pathology, n (%)
AGA guideline	Surveillance	38 (26%)	85 (59%)
	Surgery	14 (9.7%)	8 (5.5%)
IAP guideline	Surveillance	3 (2.1%)	16 (11%)
	Surgery	49 (35%)	77 (53%)
European guideline	Surveillance	2 (1.4%)	22 (15%)
	Surgery	50 (35%)	71 (49%)

AGA, American Gastroenterological Association; IAP, International Association of Pancreatology; European, European Study Group of Cystic tumours of the Pancreas.

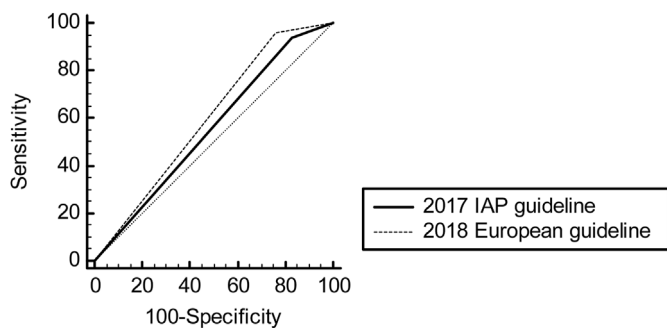


Fig. 2A. The area under the receiver operating characteristic curve for European [3] compared to the IAP(2) guideline. The ROC curve comparison analyses showed that European (AUC 0.599 95% CI 0.514–0.679) was superior to the IAP guideline (AUC 0.557 95% CI 0.472–0.640) in identifying advanced neoplasia ($p = 0.009$).

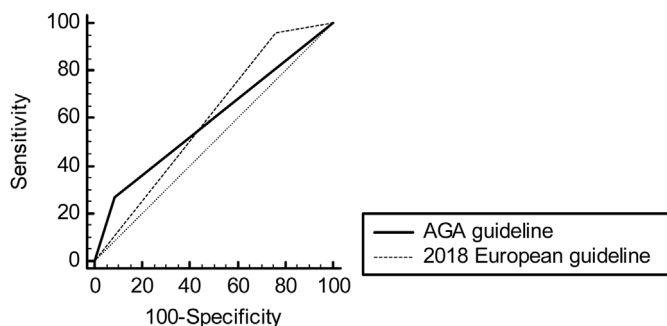


Fig. 2B. The area under the receiver operating characteristic curve for European [3] compared to the AGA(1) guideline. The ROC curve comparison analyses showed no statistical difference between the European guideline (AUC 0.599 95% CI 0.514–0.679) and the AGA guideline (AUC 0.592 (0.507–0.672)) ($p = 0.854$).

4. Discussion

This study comparing the diagnostic accuracy of the three current guidelines for predicting advanced neoplasia in IPMN, found a lower sensitivity for the AGA as compared to the IAP and European guidelines (27% vs. 94% and 96%). The risk of missing advanced neoplasia in patients with IPMN was 26% with the AGA guidelines compared to 2.1% and 1.4% with the IAP and European guidelines. This comes at the costs of more unnecessary surgery with the IAP and European guidelines (8.6% vs. 83%, and 76%).

Recently, a comparable study with a limited sample size investigated the accuracy of the current AGA, IAP, and European guidelines in detecting advanced neoplasia [9]. They reported a sensitivity of 96% for the European guidelines, similar with our results (96%). In contrast, the sensitivity of the AGA guidelines in their study was considerably higher (80%) than the IAP guidelines (67%). This discrepancy may be explained by the fact that in patients with worrisome features, the IAP guideline recommends confirmation of these features with EUS, and leaves the decision for surgery in healthy patients with inconclusive EUS results to the physician. Vanden Bulcke et al. [9] considered surgery only indicated by the IAP guideline when these features were confirmed by EUS, whereas we considered surgery indicated in the presence of two worrisome features on any imaging modality (CT, MRI and/or EUS).

Several studies have investigated the accuracy of the current AGA guidelines [1], and the previous 2012 IAP guidelines [6], and 2013 European guidelines [10] in predicting advanced neoplasia in IPMN. Four previous studies have identified the accuracy of the 2015 AGA guideline and demonstrated that advanced neoplasia was missed in 12–93% of patients with IPMN [8,11–13].

Two previous multicenter studies assessed the accuracy of the current IAP guideline for predicting advanced neoplasia in IPMN [14,15]. Sharib et al. reported a sensitivity of 98% and specificity of 16% for the presence of ≥ 1 worrisome features or ≥ 1 high-risk

Table 5
Preoperative and postoperative diagnosis and the accuracy of preoperative diagnosis.

Diagnosis	Preoperative diagnosis n (%)	Definitive diagnosis n (%)	Correctly diagnosed preoperatively n (%)
Overall diagnosis	-	-	174 (70%)
(Pre)malignant	-	-	213 (87%)
(Pre)malignant			
MD/MT-IPMN	104 (42%)	99 (40%)	88/99 (89%)
SB-IPMN	53 (21%)	49 (20%)	35/49 (71%)
MCN	60 (24%)	36 (15%)	29/36 (81%)
SPN	12 (4.9%)	13 (5.3%)	9/13 (69%)
NET	4 (1.6%)	4 (1.6%)	2/4 (50%)
Cystic acinar cell carcinoma	1 (0.4%)	1 (0.4%)	1/1 (100%)
Ductal adenocarcinoma	0 (0.0%)	3 (1.2%)	0/3 (0.0%)
Benign			
SCN	7 (2.8%)	21 (8.5%)	7/21 (33%)
Pseudocyst	3 (1.2%)	14 (5.7%)	2/14 (8.3%)
Mesenteric cyst	1 (0.4%)	0 (0%)	0/0 (0.0%)
Lymphangioma	0 (0.0%)	1 (0.4%)	0/1 (0.0%)
Lymphoepithelial cyst	0 (0.0%)	1 (0.4%)	0/1 (0.0%)
Ciliated foregut cyst	0 (0.0%)	1 (0.4%)	0/1 (0.0%)
Retention cyst	0 (0.0%)	2 (0.8%)	0/2 (0.0%)
Undefined	2 (0.8%)	2 (0.8%)	0/2 (0.0%)

IPMN, Intraductal Papillary Mucinous Neoplasm; MCN, Mucinous Cystic Neoplasm; MD, Main Duct; MT, Mixed Type; SB Side Branch; SCN, Serous Cystic Neoplasm; SPN, Solid Pseudopapillary Neoplasm.

stigmata for predicting advanced neoplasia in IPMN [14]. We found a 98% sensitivity for the presence of ≥ 1 worrisome features or ≥ 1 high-risk stigmata for predicting advanced neoplasia in IPMN. Watanabe et al. described a 90% sensitivity and 67% specificity of high-risk stigmata for identifying advanced neoplasia in IPMN [15]. The sensitivity of high-risk stigmata for predicting advanced neoplasia is comparable to our study (90% vs. 88%), however we found a lower specificity (67% vs. 45%).

Only one previous multicenter study assessed the accuracy of the new European guideline for predicting advanced neoplasia in patients with SB-IPMN [16]. The rate of advanced neoplasia in this study was 40%, including HGD (27%) and invasive cancer (13%) [16]. This analysis showed that patients with only one relative indication for resection had a lower risk of invasive cancer than those with ≥ 1 relative indication, nevertheless, the rate of advanced neoplasia in both groups were comparable. The accuracy of ≥ 1 relative indication for predicting invasive cancer in SB-IPMN was 65% [16]. In contrast to our study, the accuracy of absolute indications for predicting advanced neoplasia was not determined.

The current study identified that new diagnostic approaches are needed to more accurately identify patients with high-risk PCN. Next-generation sequencing of cyst fluid DNA have identified key driver gene mutations that can reliably distinguish IPMN from other cystic lesions, and low-grade from high-grade premalignant lesions [17–22]. A prospective study with 102 patients with surgical follow-up identified that the combination of KRAS/GNAS mutations and alterations in TP53/PIK3CA/PTEN had an 89% sensitivity and 100% specificity for advanced neoplasia [23].

Recently, a multimodality test named CompCyst was developed that evaluates clinical features, imaging characteristics, genetic and biochemical markers, to guide the management of patients with a PCN [24]. Springer et al. showed that CompCyst was more accurate than conventional clinical tools for identifying patients with cysts that required surgery, cysts that should be monitored, and cysts that were benign and did not require monitoring at all [24]. However, CompCyst does not replace conventional clinical tools. Instead, it contributes additional information, allowing clinicians to make more informed decisions.

Artificial intelligence (AI)-based clinical decision-making is another promising innovation that might be useful to identify and stratify IPMN lesions based on their risk for advanced neoplasia [25]. Recently, Corral et al. developed a deep-learning neural

network for the detection of advanced dysplasia on MRI in IPMN [26]. Their network provided an automated identification and risk-stratification of IPMN with a diagnostic accuracy comparable to current AGA and IAP guidelines. They showed that this deep learning neural network is able to generate a faster risk-stratification of IPMN with slightly increased sensitivity. However, these results should still be validated in a large prospective trial.

Our study has several limitations. First, we only evaluated patients with PCN who underwent surgical resection. It is therefore unknown in how many patients in our surveillance cohort, surgical resection would have been actually necessary, because of high-grade dysplasia or invasive cancer. Unfortunately, this selection bias is inevitably, because the highest-grade of dysplasia of PCN can only be determined reliable with surgical histopathology. As a result, the number of false negative preoperatively diagnosed ‘innocent’ PCN is therefore unknown and could not be compared between the three guidelines. This question should be evaluated in a large prospective study, possible within the scope of the ongoing PACYFIC study, an international prospective cohort study with 5000 patients aiming to optimize pancreatic cystic neoplasm surveillance [27]. Second, although we state that surgical resection was not indicated in hindsight according to surgical pathology in a substantial number of PCN, we cannot predict whether these cysts would have progressed to HGD or invasive cancer if they had not been resected. Especially in younger, surgically fit patients, resection of MD-IPMN with LGD could be considered justified. Third, determining the presence of vascularity in mural nodules with contrast enhanced EUS is useful to distinguish mural nodules from mucin clots [28–30]. In this cohort, evaluation of mural nodules was not performed uniformly with intravenous contrast, therefore the number of preoperatively diagnosed mural nodules with enhancement could be underestimated.

In conclusion, this monocenter cohort showed that all current guidelines lead to surgical overtreatment of IPMN based on histopathological outcomes. The European and IAP guidelines are clearly superior in detecting advanced neoplasia in IPMN as compared to the AGA, albeit at the cost of a higher rate of unnecessary surgery. To harmonize care and to avoid confusion caused by conflicting statements, a global evidence-based guideline for PCN in collaboration with the various guidelines groups is required once the current guidelines require an update.

Grant support

None.

Disclosures

- N.C.M. van Huijgevoort: none
- S.A.M. Hoogenboom: none
- S.J. Lekkerkerker: none
- O.R. Busch: none
- M. Del Chiaro: none
- P. Fockens: none
- I. Somers: none
- J. Verheij: none
- R.P. Voermans: research grant and consultancy fee Boston Scientific
- M.G. Besselink: received a grant from the Dutch Cancer Society (grant number UVA2013-5842) for studies on pancreatic cancer.
- J.E. van Hooft: research grant cook medical, consultancy fee Boston Scientific, Medtronic

Appendix A. Supplementary data

Supplementary data to this article can be found online at <https://doi.org/10.1016/j.pan.2023.01.011>.

References

- [1] Vege SS, Ziring B, Jain R, Moayyedi P. Clinical Guidelines C, American Gastroenterology A. American gastroenterological association institute guideline on the diagnosis and management of asymptomatic neoplastic pancreatic cysts. *Gastroenterology* 2015;148(4):819–22. quiz12–3.
- [2] Tanaka M, Fernandez-Del Castillo C, Kamisawa T, Jang JY, Levy P, Ohtsuka T, et al. Revisions of international consensus Fukuoka guidelines for the management of IPMN of the pancreas. *Pancreatology* 2017;17(5):738–53.
- [3] European Study Group on Cystic Tumours of the P. European evidence-based guidelines on pancreatic cystic neoplasms. *Gut* 2018;67(5):789–804.
- [4] Elta GH, Enestvedt BK, Sauer BG, Lennon AM. ACG clinical guideline: diagnosis and management of pancreatic cysts. *Am J Gastroenterol* 2018;113(4):464–79.
- [5] Tanaka M, Chari S, Adsay V, Fernandez-del Castillo C, Falconi M, Shimizu M, et al. International consensus guidelines for management of intraductal papillary mucinous neoplasms and mucinous cystic neoplasms of the pancreas. *Pancreatology* 2006;6(1–2):17–32.
- [6] Tanaka M, Fernandez-del Castillo C, Adsay V, Chari S, Falconi M, Jang JY, et al. International consensus guidelines 2012 for the management of IPMN and MCN of the pancreas. *Pancreatology* 2012;12(3):183–97.
- [7] Basturk O, Hong SM, Wood LD, Adsay NV, Albores-Saavedra J, Biankin AV, et al. A revised classification system and recommendations from the Baltimore consensus meeting for neoplastic precursor lesions in the pancreas. *Am J Surg Pathol* 2015;39(12):1730–41.
- [8] Lekkerkerker SJ, Besselink MG, Busch OR, Verheij J, Engelbrecht MR, Rauws EA, et al. Comparing 3 guidelines on the management of surgically removed pancreatic cysts with regard to pathological outcome. *Gastrointest Endosc* 2017;85(5):1025–31.
- [9] Vanden Bulcke A, Jaekers J, Topal H, Vanbeckevoort D, Vandecaveye V, Roskams T, et al. Evaluating the accuracy of three international guidelines in identifying the risk of malignancy in pancreatic cysts: a retrospective analysis of a surgically treated population. *Acta Gastroenterol Belg* 2021;84(3):443–50.
- [10] Del Chiaro M, Verbeke C, Salvia R, Kloppel G, Werner J, McKay C, et al. European experts consensus statement on cystic tumours of the pancreas. *Dig Liver Dis* 2013;45(9):703–11.
- [11] Singhi AD, Zeh HJ, Brand RE, Nikiforova MN, Chennat JS, Fasanella KE, et al. American Gastroenterological Association guidelines are inaccurate in detecting pancreatic cysts with advanced neoplasia: a clinicopathologic study of 225 patients with supporting molecular data. *Gastrointest Endosc* 2016;83(6):1107–11017 e2.
- [12] Sighinolfi M, Quan SY, Lee Y, Ibaseta A, Pham K, Dua MM, et al. Fukuoka and AGA criteria have superior diagnostic accuracy for advanced cystic neoplasms than sendai criteria. *Dig Dis Sci* 2017;62(3):626–32.
- [13] Xu MM, Yin S, Siddiqui AA, Salem RR, Schrope B, Sethi A, et al. Comparison of the diagnostic accuracy of three current guidelines for the evaluation of asymptomatic pancreatic cystic neoplasms. *Medicine (Baltimore)* 2017;96(35):e7900.
- [14] Sharib JM, Fonseca AL, Swords DS, Jaradeh K, Bracci PM, Firpo MA, et al. Surgical overtreatment of pancreatic intraductal papillary mucinous neoplasms: do the 2017 International Consensus Guidelines improve clinical decision making? *Surgery* 2018;164(6):1178–84.
- [15] Watanabe Y, Endo S, Nishihara K, Ueda K, Mine M, Tamiya S, et al. The validity of the surgical indication for intraductal papillary mucinous neoplasm of the pancreas advocated by the 2017 revised International Association of Pancreatology consensus guidelines. *Surg Today* 2018;48(11):1011–9.
- [16] Perez-Cuadrado-Robles E, Uribarri-Gonzalez L, Borbath I, Vila JJ, Lopez-Lopez S, Deprez PH. Risk of advanced lesions in patients with branch-duct IPMN and relative indications for surgery according to European evidence-based guidelines. *Dig Liver Dis* 2019;51(6):882–6.
- [17] Wu J, Jiao Y, Dal Molin M, Maitra A, de Wilde RF, Wood LD, et al. Whole-exome sequencing of neoplastic cysts of the pancreas reveals recurrent mutations in components of ubiquitin-dependent pathways. *Proc Natl Acad Sci U S A* 2011;108(52):21188–93.
- [18] Pea A, Yu J, Rezaee N, Luchini C, He J, Dal Molin M, et al. Targeted DNA sequencing reveals patterns of local progression in the pancreatic remnant following resection of intraductal papillary mucinous neoplasm (IPMN) of the pancreas. *Ann Surg* 2017;266(1):133–41.
- [19] Kanda M, Sadakari Y, Borges M, Topazian M, Farrell J, Syngal S, et al. Mutant TP53 in duodenal samples of pancreatic juice from patients with pancreatic cancer or high-grade dysplasia. *Clin Gastroenterol Hepatol* 2013;11(6):719–730 e5.
- [20] Schonleben F, Qiu W, Ciau NT, Ho DJ, Li X, Allendorf JD, et al. PIK3CA mutations in intraductal papillary mucinous neoplasm/carcinoma of the pancreas. *Clin Cancer Res* 2006;12(12):3851–5.
- [21] Garcia-Carracedo D, Chen ZM, Qiu W, Huang AS, Tang SM, Hruban RH, et al. PIK3CA mutations in mucinous cystic neoplasms of the pancreas. *Pancreas* 2014;43(2):245–9.
- [22] Garcia-Carracedo D, Turk AT, Fine SA, Akhavan N, Tweel BC, Parsons R, et al. Loss of PTEN expression is associated with poor prognosis in patients with intraductal papillary mucinous neoplasms of the pancreas. *Clin Cancer Res* 2013;19(24):6830–41.
- [23] Singhi AD, McGrath K, Brand RE, Khalid A, Zeh HJ, Chennat JS, et al. Preoperative next-generation sequencing of pancreatic cyst fluid is highly accurate in cyst classification and detection of advanced neoplasia. *Gut* 2018;67(12):2131–41.
- [24] Springer S, Masica DL, Dal Molin M, Douville C, Thoburn CJ, Afsari B, et al. A multimodality test to guide the management of patients with a pancreatic cyst. *Sci Transl Med* 2019;11(501).
- [25] Lakhani P. Deep convolutional neural networks for endotracheal tube position and X-ray image classification: challenges and opportunities. *J Digit Imag* 2017;30(4):460–8.
- [26] Corral JE, Hussein S, Kandel P, Bolan CW, Bagci U, Wallace MB. Deep learning to classify intraductal papillary mucinous neoplasms using magnetic resonance imaging. *Pancreas* 2019;48(6):805–10.
- [27] Netherlands Trial Register. [TrialRegister.nl. https://www.trialregister.nl/trial/43652014](https://www.trialregister.nl/trial/43652014).
- [28] Yamashita Y, Ueda K, Itonaga M, Yoshida T, Maeda H, Maekita T, et al. Usefulness of contrast-enhanced endoscopic sonography for discriminating mural nodules from mucous clots in intraductal papillary mucinous neoplasms: a single-center prospective study. *J Ultrasound Med* 2013;32(1):61–8.
- [29] Fujita M, Itoi T, Ikeuchi N, Sofuni A, Tsuchiya T, Ishii K, et al. Effectiveness of contrast-enhanced endoscopic ultrasound for detecting mural nodules in intraductal papillary mucinous neoplasm of the pancreas and for making therapeutic decisions. *Endosc Ultrasound* 2016;5(6):377–83.
- [30] Yamamoto N, Kato H, Tomoda T, Matsumoto K, Sakakihara I, Noma Y, et al. Contrast-enhanced harmonic endoscopic ultrasonography with time-intensity curve analysis for intraductal papillary mucinous neoplasms of the pancreas. *Endoscopy* 2016;48(1):26–34.