



Universiteit
Leiden
The Netherlands

Can screening for degenerative cervical myelopathy (SCREEN-DCM) be effectively undertaken based on signs, symptoms and known risk factors? Rationale and research protocol for a prospective, multicentre, observational study

Nouri, A.; Molliqaj, G.; Gondar, R.; Lave, A.; Jannelli, G.; Davies, B.; ... ; Tessitore, E.

Citation

Nouri, A., Molliqaj, G., Gondar, R., Lave, A., Jannelli, G., Davies, B., ... Tessitore, E. (2022). Can screening for degenerative cervical myelopathy (SCREEN-DCM) be effectively undertaken based on signs, symptoms and known risk factors?: Rationale and research protocol for a prospective, multicentre, observational study. *Bmj Open*, 12(7). doi:10.1136/bmjopen-2021-060689


Version: Publisher's Version

License: [Creative Commons CC BY-NC 4.0 license](#)

Downloaded from: <https://hdl.handle.net/1887/3570564>

Note: To cite this publication please use the final published version (if applicable).

BMJ Open Can screening for degenerative cervical myelopathy (SCREEN-DCM) be effectively undertaken based on signs, symptoms and known risk factors? Rationale and research protocol for a prospective, multicentre, observational study

Aria Nouri ,¹ Granit Molliqaj,¹ Renato Gondar,¹ Alexandre Lavé,¹ Gianpaolo Jannelli,¹ Benjamin Davies,² Mark Kotter,² Allan Martin,³ Justin Virojanapa,⁴ Joseph S Cheng,⁴ Teresa Somma,⁵ Paolo Cappabianca,⁵ Carmen L A Vleggeert-Lankamp,⁶ Valerie ter Wengel,⁶ Torstein Meling,¹ Karl Schaller,¹ Enrico Tessitore¹

To cite: Nouri A, Molliqaj G, Gondar R, *et al*. Can screening for degenerative cervical myelopathy (SCREEN-DCM) be effectively undertaken based on signs, symptoms and known risk factors? Rationale and research protocol for a prospective, multicentre, observational study. *BMJ Open* 2022;**12**:e060689. doi:10.1136/bmjopen-2021-060689

► Prepublication history for this paper is available online. To view these files, please visit the journal online (<http://dx.doi.org/10.1136/bmjopen-2021-060689>).

Received 30 December 2021
Accepted 03 July 2022



© Author(s) (or their employer(s)) 2022. Re-use permitted under CC BY-NC. No commercial re-use. See rights and permissions. Published by BMJ.

For numbered affiliations see end of article.

Correspondence to

Dr Aria Nouri;
arianouri9@gmail.com

ABSTRACT

Introduction Degenerative cervical myelopathy (DCM) is the most common cause of spinal cord impairment. Unfortunately, the condition remains poorly recognised and underdiagnosed. To better identify patients, screening tests that target individuals at high risk would be helpful. One group in particular known to have a high prevalence of DCM consists of patients with lumbar degenerative disease (LDD), with the combined presentation referred to as tandem stenosis. Given that LDD is one of the most common presentations in neurosurgical practice and primary care, it is the objective of the proposed study to administer a screening test to these patients as well as those with risk factors or symptoms which raise the suspicion of underlying DCM.

Methods and analysis A screening test based on clinical signs/symptoms and known risk factors of DCM was designed. Screening will be performed in neurosurgical consultations for patients with LDD or those with any suspicion of myelopathy. Points are attributed based on the presence of signs/symptoms of DCM (eg, Hoffmann sign, hyper-reflexia) and for comorbidities that predispose or are frequently associated with cervical myelopathy (eg, rheumatoid arthritis, carpal tunnel syndrome). Patients with ≥3 points undergo cervical MRI examination. Patients with positive MRIs will be consulted and receive assessment via modified Japanese Orthopedic Association and Neck Disability Index scores, and subsequent clinical management will be based on practice guidelines. An exploratory multivariate analysis of the effectiveness and efficiency of this proposed screening test will be evaluated after positively screening 50 patients for DCM.

Ethics and dissemination This study has received research ethics approval from the Swiss Association of Research Ethics Committees (ID: 2020-02785). The results

STRENGTHS AND LIMITATIONS OF THIS STUDY

- ⇒ Screening for degenerative cervical myelopathy (DCM) will be principally undertaken for patients with lumbar spine pathology, with a target study enrolment of 600 patients.
- ⇒ The screening tool assesses common clinical signs, symptoms and risk factors present in patients with DCM, and indicates whether there is a clinical need for further evaluation of DCM via a cervical MRI.
- ⇒ The choice of signs, symptoms and risk factors included in the screening process is based on clinical evidence and supporting literature.
- ⇒ Points are attributed for the presence of signs, symptoms and risk factors, and patients with 3 or more points are advised to have a cervical MRI.

of this study will be disseminated in a journal targeting physicians commonly encountering patients with LDD.

INTRODUCTION

Degenerative cervical myelopathy (DCM) is the most common cause of spinal cord injury, often presenting in a progressive manner. DCM is caused by arthritic changes of the cervical spine that encompasses varying degrees of disc degeneration, deformation of the vertebral bodies and changes in the ligamentous support structure, which results in narrowing of the spinal canal and spinal cord injury due to static and dynamic compression.^{1 2} Patients with DCM can present with a wide range of neurological deficits including motor and sensory deficits (including



sphincter dysfunction in severe cases), walking instability (or gait impairment), and numerous signs of spinal cord dysfunction including hyper-reflexia and clonus.³ The initial onset of noticeable symptoms for patients may include numbness and loss of dexterity of the hands. Other patients may present with walking and stability issues that may initiate the search for an underlying pathology. Although some patients may suffer from osteoarthritic neck pain, spinal cord injury and dysfunction is often painless, and patients with slowly progressive symptoms often attribute these neurological deficits to their age. In younger patients, or those who require fine motor skills and sensory function for regular activities, such as musicians, changes in function may be recognised earlier.

Despite being largely under-recognised by the general medical community, there are efforts to alert the medical field about the importance and relatively commonness of DCM. However, there remains an ongoing issue related to how individuals with mild symptoms of DCM, which are unlikely to be diagnosed, can be identified. This is an important knowledge gap as it has been recognised that referral delays play a contributing role in the severity of DCM that arrives for consultations with a specialist.⁴⁵ It is also evident with the rise in central cord syndromes among the elderly due to falls⁶ that many of these patients likely suffered from undiagnosed DCM or significant cervical canal stenosis, which may have contributed to their initial fall. Indeed, it has also been shown that nearly one in five patients with femoral neck fractures have been identified with undiagnosed DCM.⁷

Screening tools present an attractive tool for improving the diagnosis of DCM. Two screening tools have been proposed so far;^{8,9} however, these are based on questionnaires, target the general population and have not yet been validated. A more specific approach would be to target high-risk patients, such as those who are already followed in clinic for lumbar radiculopathy or stenosis. Indeed, the prevalence of tandem stenosis (both lumbar and cervical stenosis) has been estimated between 5% and 28%.^{10,11} These patients already consulted a specialist and as a consequence undergo expert clinical examination. Furthermore, some of the patients with lumbar degenerative disease (LDD) may undergo lumbar decompression in the prone position. Early postoperative neurological deterioration related to surgical positioning or anaesthetic manoeuvres is described in literature.¹² Recognition of DCM before a lumbar surgical procedure might prevent this unexpected complication. In light of this, a screening tool to unmask undiagnosed degenerative cervical myelopathy tailored for this population is highly desirable.

METHODS

Design and identification of population to be screened

In order to develop an effective screening tool based on clinical symptoms and history, a large number of individuals with a high risk of subclinical or mild myelopathy need to be within the screened population. Patients with lumbar radiculopathy/stenosis represent the optimal cohort of patients to screen given the high prevalence of tandem stenosis. This condition also represents the most

common problem present in our neurosurgical practice and therefore a large volume of individuals can be screened. Each new patient or patient actively followed for lumbar radiculopathy will be screened consecutively. In addition, at the discretion of the physician, the screening may be carried out as well on patients who describe symptoms or present with clinical signs suggestive of myelopathy. The envisioned clinical pathway of screened patients is presented in [figure 1](#)—with the rationale further discussed in the following sections. Patients will be excluded from screening if they are <18 years of age, were previously operated in the cervical spine, have known metastatic spine disease, are pregnant or prisoners.

The study will be conducted at multiple centres within Europe and the USA. The study began enrolling patients in February 2021 and is expected to be completed within 3 years (February 2024).

Identification of symptoms and signs of DCM to be screened

The list of symptoms and signs with which patients can present with myelopathy is listed in [table 1](#). While all of these symptoms and signs can be present in patients with DCM, the complete list rarely presents together unless patients are severely affected, and patients typically present with a subset of these. The prevalence of signs in patients with and without myelopathy has been previously reported ([table 2](#)).¹³ As is evident from this list, false positives also occur in patients without myelopathy. The combinations of symptoms and signs most appropriate for screening are those that are highly sensitive. However, given that patients are presenting to neurosurgical consultation, tests with high specificity are also desirable. The most appropriate symptoms and signs to incorporate into the screening tool were discussed among 11 neurosurgeons, and consensus for the use of symptoms was required for incorporation.

Identification of risk factors or comorbidities to be screened

Patients with DCM often present with symptoms that are indicative of other conditions, and may thus be inadvertently referred for these problems. In other cases, patients may suffer from both conditions, as with tandem stenosis. Furthermore, there are some comorbidities that are known to exist in patients with DCM, unfortunately however, the literature remains sparse. Based on previous publications^{1,14–17} and anecdotal knowledge, a list of comorbidities, risk factors or symptoms/signs relevant for screening DCM is listed in [box 1](#).

Screening criteria and identifying the threshold for further investigation

Once patients screen positive for a potential diagnosis of DCM, the typical next step in the diagnostic process includes cervical imaging via MRI, and in some cases electrophysiological examination may be undertaken. However, as has been shown in the literature, false positive signs such as hyper-reflexia or a positive Hoffmann sign may be present in patients without myelopathy.^{13,18}

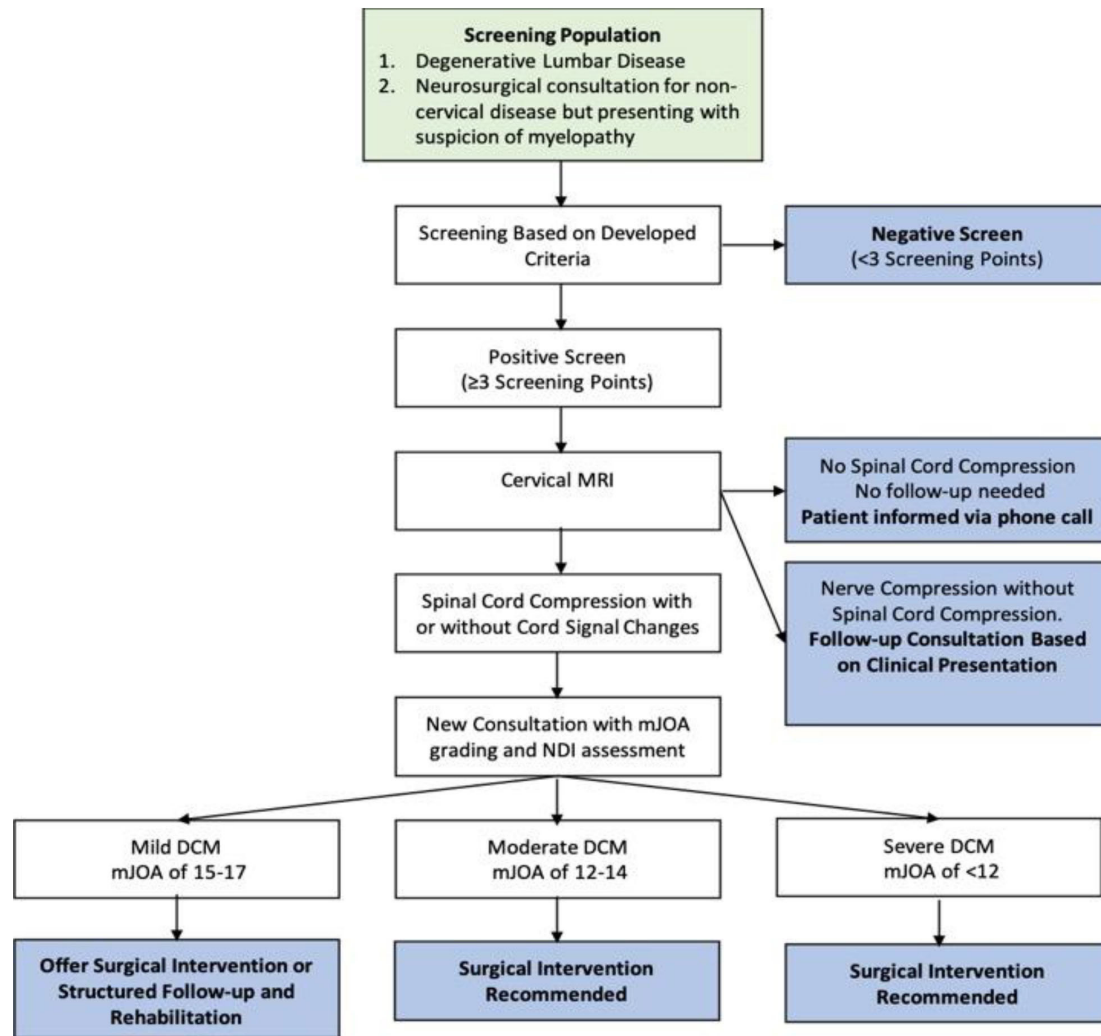


Figure 1 Flow chart showing the clinical pathway of screened patients. DCM, degenerative cervical myelopathy; mJOA, modified Japanese Orthopedic Association; NDI, Neck Disability Index.

Furthermore, it is also known that a large proportion of the population, particularly elderly patients, can present with asymptomatic spinal cord compression.^{19 20} It is thus imperative to devise a screening tool that is based on a combination of clinical symptoms and signs, and patient history. We therefore propose that patients must have 3 or more points in our screening checklist displayed in

Clinical symptoms	Clinical signs
Motor deficits	Inverted brachioradialis reflex
Numbness of hands	Hoffmann sign
Loss of hand dexterity	Ankle clonus
Hypothenar/thenar atrophy	Babinski sign
Incontinence	Spasticity
Clumsy hands	Hyper-reflexia
Subjective weakness	Romberg sign
Paresthesia	Gait ataxia
Walking instability	Lhermitte's phenomenon

table 3. All positive findings are given 1 point, with the exception of bilateral carpal tunnel syndrome, which will be attributed 2 points.

As the individuals under screening are principally those referred for lumbar disc disease or stenosis, symptoms and signs that are related to this, such as lower limb radicular symptoms, motor weakness in the legs and sensory problems in the lower limbs, were not included in the screening to avoid falsely attributing points for non-cervical pathology.

Clinical pathway of patients after screening

As outlined in figure 1, after a positive screen, the patients will undergo a cervical MRI. If no cord compression is seen, the patients are informed of this over the phone. If they should have nerve root compression, a follow-up can be scheduled based on the clinical presentation of the patient, whereas no follow-up is required in asymptomatic patients. Should patients have cord compression with or without cord signal changes suggestive of possible spinal cord injury, a new consultation will be arranged. In equivocal cases, additional examination may be required

**Table 2** Prevalence of signs in patients with DCM, taken from Rhee *et al.*¹³

	CM (n=39)	Control (n=37)	P value*	Sensitivity	Specificity
Any (≥1) myelopathic sign	79%	57%	0.05†	79%	43%
Any (≥1) provocative sign	69%	32%	0.003†	69%	68%
Hoffmann	59%	16%	0.0001†	59%	84%
IBR	51%	19%	0.004†	51%	81%
Babinski	13%	0%	0.05†	13%	100%
Clonus	13%	0%	0.05†	13%	100%
Any (≥1) hyper-reflexia	72%	57%	0.2	72%	43%
Biceps	62%	51%	0.5	62%	49%
Triceps	36%	22%	0.2	36%	78%
Brachioradialis	21%	11%	0.3	21%	89%
Patella	33%	24%	0.5	33%	76%
Achilles	26%	19%	0.6	26%	81%
No myelopathic signs	21%	43%	0.05†	21%	57%

*Fisher's exact test.

†Indicates statistical significance at the 0.05 level.

CM, Cervical Myelopathy; DCM, degenerative cervical myelopathy; IBR, inverted brachioradialis reflex.

such as flexion/extension MRI or electrophysiological examination to establish a positive screen for DCM. The determination of a diagnosis of DCM will be left at the discretion of the supervising physician considering the totality of clinical examination and data available. Once a determination has been made, a consultation will be undertaken where a modified Japanese Orthopedic Association (mJOA)²¹ and Neck Disability Index²² scores will be gathered. Patients will then be classified based on their level of neurological severity, separated in mild, moderate and severe impairment based on the mJOA scale.²³ Subsequent management of patients thereafter will be based on practice guidelines for the management for mild, moderate and severe DCM.²⁴

In some instances, it is possible that a patient has already received a cervical MRI for other reasons; if such an MRI

has been undertaken within the preceding 6 months, it may be used instead of a new MRI if the patient has not remarked a recent change in symptoms.

Refinement of screening tool

After having obtained at least 50 patients with a confirmed diagnosis of DCM, a statistical analysis will be undertaken to investigate which positive factors and the number

Table 3 Screening test for DCM

Signs	Points	Comorbidity	Points
Hyper-reflexia	1	Rheumatoid arthritis	1
Hoffmann sign	1	Klippel-Feil syndrome	1
Ankle clonus	1	Carpal tunnel syndrome*	1 or 2
Neck pain	1		
Babinski sign	1		
Upper limb hypoesthesia/paresthesia	1		
Inverted brachioradialis reflex	1		
Gait ataxia	1		
Hand clumsiness/dropping items	1		
Romberg sign	1		
Total		Total	

*1 point for unilateral carpal tunnel surgery/diagnosis, 2 points if bilateral.
DCM, degenerative cervical myelopathy.

Box 1 Important presentations and comorbidities frequently encountered in patients with degenerative cervical myelopathy

Referral for:

- ⇒ Cervical pain
- ⇒ Cervical radiculopathy
- ⇒ Lumbar radiculopathy
- ⇒ Lumbar stenosis
- ⇒ Carpal tunnel syndrome

History of:

- ⇒ Rheumatoid arthritis
- ⇒ Klippel-Feil syndrome
- ⇒ Parkinson's disease
- ⇒ Ehlers-Danlos syndrome
- ⇒ Diffuse idiopathic skeletal hyperostosis
- ⇒ Carpal tunnel syndrome

of positive factors that are present in patients with a confirmed diagnosis of DCM. The screening tool and the threshold of symptoms, signs and patients' history necessary before considering patients as having a positive screen will then be re-evaluated.

Statistical analysis

It is difficult to identify the number of patients needed to screen in order to obtain 50 positive screening results, as the initial study is exploratory. Furthermore, it is difficult to say whether 50 positive screens will provide sufficient data to perform a rigorous analysis. Having said this, if we estimate that 10% of patients with LDD have DCM, and that 20% of these patients will be lost to follow-up, 600 patients would need to be screened to achieve 50 positive cases.

It is our aim to perform a multivariate logistic regression analysis where positive and negative screens will be the dependent variable, and individuals' risk factors or positive clinical signs will be independent variables. Age and other demographic factors such as smoking may also be assessed as independent factors to improve the diagnostic capacity of the multivariable model.

Evaluation of the efficacy of the predictors to identify positive screens will be based on the area on the receiver operating characteristic curve and also on their clinical utility. For example, a highly predictive factor with a prevalence of 1 or 2 among the 50 positive cases may not be sufficiently useful for screening.

Additionally, economic evaluation of screening will be carried out by dividing the cost of all MRI examinations by the number of patients diagnosed to determine the cost per positive diagnostic screen.

Patient and public involvement

No patients or members of the public were involved.

Ethics and dissemination

All patients will be informed about the study objectives and details, and informed consent will be obtained. Patients will not undergo any harmful examination or additional radiation exposure as a consequence of this screening; however, patients may receive a diagnosis for a condition they may not have been aware of. While being informed that they may have DCM may provoke anxiety, knowing that patients with DCM are likely to progress and may be irreversibly harmed suggests that providing the opportunity to address this is ultimately in the patient's best interest. This study has received research ethics approval from the Swiss Association of Research Ethics Committees (ID: 2020-02785).

The results of this study will be disseminated in a journal targeting physicians commonly encountering patients with LDD. In addition, depending on the effectiveness and efficiency of our screening test, we will share our findings at national and international conferences.

Limitations and special considerations

It is possible that for a positive screen, the cervical MRI may be equivocal and that further examination will be necessary via electrophysiological testing, particularly

for patients with carpal tunnel syndrome, Parkinson's disease or other neurological conditions (eg, cerebral stroke), which may increase the risks of false positives. Other common conditions such as diabetes mellitus may also perturbate the neurological clinical presentation and may limit the efficacy of the screening tool. In rare circumstances, it may also be possible that symptoms may be the result of cord compression in the thoracic region. However, given the relative rarity of thoracic myelopathy,²⁵ it is believed that this will be an exceptional circumstance. Finally, as patients are undergoing a consultation for lumbar problems, they may not be inclined to undertake testing for their cervical spine even though there is a high suspicion for a problem and it is thus possible that while positive screens are made, confirmation via imaging may not always be achievable.

Author affiliations

- ¹Division of Neurosurgery, Geneva University Hospitals, Geneva, Switzerland
²Department of Clinical Neurosurgery, Cambridge University, Cambridge, UK
³Department of Neurological Surgery, University of California Davis, Sacramento, California, USA
⁴Department of Neurosurgery, University of Cincinnati Academic Health Center, Cincinnati, Ohio, USA
⁵Department of Neuroscience and Reproductive and Dental Sciences, Division of Neurosurgery, Università degli Studi di Napoli Federico II, Naples, Italy
⁶Department of Neurosurgery, Leiden University, Leiden, The Netherlands

Twitter Aria Nouri @xANMD

Contributors Conceptual idea—AN. Writing the initial draft of the manuscript—AN. Methodology design—AN, GM, RG, AL, GJ, BD, MK, AM, JV, JSC, TS, PC, CLAV-L, VtW, TM, KS and ET. Critical review and revision of the manuscript—AN, GM, RG, AL, GJ, BD, MK, AM, JV, JSC, TS, PC, CLAV-L, VtW, TM, KS and ET. Supervision of the project—ET.

Funding The writing of this manuscript received no funding. The SCREEN-DCM Study has received funding from CSRS-Europe and EANS Research Grants (both in 2021).

Competing interests None declared.

Patient and public involvement Patients and/or the public were not involved in the design, or conduct, or reporting, or dissemination plans of this research.

Patient consent for publication Not required.

Provenance and peer review Not commissioned; externally peer reviewed.

Open access This is an open access article distributed in accordance with the Creative Commons Attribution Non Commercial (CC BY-NC 4.0) license, which permits others to distribute, remix, adapt, build upon this work non-commercially, and license their derivative works on different terms, provided the original work is properly cited, appropriate credit is given, any changes made indicated, and the use is non-commercial. See: <http://creativecommons.org/licenses/by-nc/4.0/>.

ORCID iD

Aria Nouri <http://orcid.org/0000-0002-4965-3059>

REFERENCES

- Nouri A, Tetreault L, Singh A, *et al*. Degenerative cervical myelopathy: epidemiology, genetics, and pathogenesis. *Spine* 2015;40:E675–93.
- Nouri A, Cheng JS, Davies B, *et al*. Degenerative cervical myelopathy: a brief review of past perspectives, present developments, and future directions. *J Clin Med* 2020;9:535.
- Gibson J, Nouri A, Krueger B, *et al*. Degenerative cervical myelopathy: a clinical review. *Yale J Biol Med* 2018;91:43–8.
- Hilton B, Tempest-Mitchell J, Davies B, *et al*. Route to diagnosis of degenerative cervical myelopathy in a UK healthcare system: a retrospective cohort study. *BMJ Open* 2019;9:e027000.



- 5 Behrbalk E, Salame K, Regev GJ, *et al*. Delayed diagnosis of cervical spondylotic myelopathy by primary care physicians. *Neurosurg Focus* 2013;35:E1.
- 6 Singh A, Tetreault L, Kalsi-Ryan S, *et al*. Global prevalence and incidence of traumatic spinal cord injury. *Clin Epidemiol* 2014;6:309–31.
- 7 Radcliff KE, Curry EP, Trimba R, *et al*. High incidence of undiagnosed cervical myelopathy in patients with hip fracture compared with controls. *J Orthop Trauma* 2016;30:189–93.
- 8 Barkoh K, Ohiorhenuan IE, Lee L, *et al*. The Down questionnaire: a novel screening tool for cervical spondylotic myelopathy. *Global Spine J* 2019;9:607–12.
- 9 Kobayashi H, Kikuchi S-ichi, Otani K, *et al*. Development of a self-administered questionnaire to screen patients for cervical myelopathy. *BMC Musculoskelet Disord* 2010;11:268.
- 10 LaBan MM, Green ML. Concurrent (tandem) cervical and lumbar spinal stenosis: a 10-yr review of 54 hospitalized patients. *Am J Phys Med Rehabil* 2004;83:187–90.
- 11 Jannelli G, Baticam NS, Tizi K, *et al*. Symptomatic tandem spinal stenosis: a clinical, diagnostic, and surgical challenge. *Neurosurg Rev* 2020;43:1–7.
- 12 Boyle SL, Unger Z, Kulkarni V, *et al*. Prone positioning of patients with cervical spine pathology. *J Neuroanaesthesiol Critic Care* 2020;07:070–6.
- 13 Rhee JM, Heflin JA, Hamasaki T, *et al*. Prevalence of physical signs in cervical myelopathy: a prospective, controlled study. *Spine* 2009;34:890–5.
- 14 Janssen I, Nouri A, Tessitore E, *et al*. Cervical myelopathy in patients suffering from rheumatoid arthritis—a case series of 9 patients and a review of the literature. *J Clin Med* 2020;9:811.
- 15 Nouri A, Martin AR, Lange SF, *et al*. Congenital cervical fusion as a risk factor for development of degenerative cervical myelopathy. *World Neurosurg* 2017;100:531–9.
- 16 Nouri A, Fehlings MG. Diffuse idiopathic skeletal hyperostosis with cervical myelopathy. *CMAJ* 2017;189:E410.
- 17 Baucher G, Taskovic J, Troude L, *et al*. Risk factors for the development of degenerative cervical myelopathy: a review of the literature. *Neurosurg Rev* 2022;45:1–15.
- 18 Harrop JS, Naroji S, Maltenfort M, *et al*. Cervical myelopathy: a clinical and radiographic evaluation and correlation to cervical spondylotic myelopathy. *Spine* 2010;35:620–4.
- 19 Kovalova I, Kerkovsky M, Kadanka Z, *et al*. Prevalence and imaging characteristics of nonmyelopathic and myelopathic spondylotic cervical cord compression. *Spine* 2016;41:1908–16.
- 20 Kato F, Yukawa Y, Suda K, *et al*. Normal morphology, age-related changes and abnormal findings of the cervical spine. Part II: magnetic resonance imaging of over 1,200 asymptomatic subjects. *Eur Spine J* 2012;21:1499–507.
- 21 Benzel EC, Lancon J, Kesterson L, *et al*. Cervical laminectomy and dentate ligament section for cervical spondylotic myelopathy. *J Spinal Disord* 1991;4:286–95.
- 22 Vernon H, Mior S. The neck disability index: a study of reliability and validity. *J Manipulative Physiol Ther* 1991;14:409–15.
- 23 Tetreault L, Kopjar B, Nouri A, *et al*. The modified Japanese orthopaedic association scale: establishing criteria for mild, moderate and severe impairment in patients with degenerative cervical myelopathy. *Eur Spine J* 2017;26:78–84.
- 24 Fehlings MG, Tetreault LA, Riew KD, *et al*. A clinical practice guideline for the management of patients with degenerative cervical myelopathy: recommendations for patients with mild, moderate, and severe disease and nonmyelopathic patients with evidence of cord compression. *Global Spine J* 2017;7:70S–83.
- 25 Chen G, Fan T, Yang X, *et al*. The prevalence and clinical characteristics of thoracic spinal stenosis: a systematic review. *Eur Spine J* 2020;29:2164–72.