



Universiteit  
Leiden  
The Netherlands

## **Vascular dysfunction: the disregarded partner of Alzheimer's disease**

Sweeney, M.D.; Montagne, A.; Sagare, A.P.; Nation, D.A.; Schneider, L.S.; Chui, H.C.; ... ; Zlokovic, B.V.

### **Citation**


Sweeney, M. D., Montagne, A., Sagare, A. P., Nation, D. A., Schneider, L. S., Chui, H. C., ... Zlokovic, B. V. (2019). Vascular dysfunction: the disregarded partner of Alzheimer's disease. *Alzheimer's & Dementia: The Journal Of The Alzheimer's Association*, 15(1), 158-167.  
doi:10.1016/j.jalz.2018.07.222

Version: Publisher's Version  
License: [Creative Commons CC BY 4.0 license](https://creativecommons.org/licenses/by/4.0/)  
Downloaded from: <https://hdl.handle.net/1887/3214942>

**Note:** To cite this publication please use the final published version (if applicable).



ELSEVIER



Special Topic Section: Responses to the NIA-AA Research Framework

## Vascular dysfunction—The disregarded partner of Alzheimer's disease

Melanie D. Sweeney<sup>a</sup>, Axel Montagne<sup>a</sup>, Abhay P. Sagare<sup>a</sup>, Daniel A. Nation<sup>b,c</sup>,  
Lon S. Schneider<sup>c,d,e</sup>, Helena C. Chui<sup>c,d</sup>, Michael G. Harrington<sup>f</sup>, Judy Pa<sup>g</sup>, Meng Law<sup>c,h</sup>,  
Danny J. J. Wang<sup>g</sup>, Russell E. Jacobs<sup>a</sup>, Fergus N. Doubal<sup>i</sup>, Joel Ramirez<sup>j,k,l</sup>, Sandra E. Black<sup>m</sup>,  
Maiken Nedergaard<sup>n,o</sup>, Helene Benveniste<sup>p</sup>, Martin Dichgans<sup>q</sup>, Costantino Iadecola<sup>r</sup>, Seth Love<sup>s</sup>,  
Philip M. Bath<sup>t,u</sup>, Hugh S. Markus<sup>v</sup>, Rustam Al-Shahi Salman<sup>i</sup>, Stuart M. Allan<sup>w</sup>, Terence J. Quinn<sup>x</sup>,  
Rajesh N. Kalara<sup>y</sup>, David J. Werring<sup>z</sup>, Roxana O. Carare<sup>aa</sup>, Rhian M. Touyz<sup>bb</sup>,  
Steve C. R. Williams<sup>cc</sup>, Michael A. Moskowitz<sup>dd</sup>, Zvonimir S. Katusic<sup>ee</sup>, Sarah E. Lutz<sup>ff</sup>,  
Orly Lazarov<sup>ff</sup>, Richard D. Minshall<sup>gg,hh</sup>, Jalees Rehman<sup>ii,jj</sup>, Thomas P. Davis<sup>kk</sup>,  
Cheryl L. Wellington<sup>ll</sup>, Hector M. González<sup>mm</sup>, Chun Yuan<sup>nn</sup>, Samuel N. Lockhart<sup>oo,pp</sup>,  
Timothy M. Hughes<sup>oo,pp</sup>, Christopher L. H. Chen<sup>qq,rr</sup>, Perminder Sachdev<sup>ss</sup>, John T. O'Brien<sup>tt</sup>,  
Ingmar Skoog<sup>uu</sup>, Leonardo Pantoni<sup>vv</sup>, Deborah R. Gustafson<sup>ww</sup>, Geert Jan Biessels<sup>xx</sup>,  
Anders Wallin<sup>yy</sup>, Eric E. Smith<sup>zz</sup>, Vincent Mok<sup>aaa,bbb</sup>, Adrian Wong<sup>aaa</sup>, Peter Passmore<sup>ccc</sup>,  
Frederick Barkof<sup>ddd,eee</sup>, Majon Muller<sup>fff</sup>, Monique M. B. Breteler<sup>ggg,hhh</sup>, Gustavo C. Román<sup>iii</sup>,  
Edith Hamel<sup>jjj</sup>, Sudha Seshadri<sup>kkk,lll</sup>, Rebecca F. Gottesman<sup>mmm</sup>, Mark A. van Buchem<sup>nnn</sup>,  
Zoe Arvanitakis<sup>ooo,ppp</sup>, Julie A. Schneider<sup>ooo,ppp</sup>, Lester R. Drewes<sup>qqq</sup>, Vladimir Hachinski<sup>rrr</sup>,  
Caleb E. Finch<sup>sss</sup>, Arthur W. Toga<sup>c,g</sup>, Joanna M. Wardlaw<sup>i,1</sup>, Berislav V. Zlokovic<sup>a,c,\*;1</sup>

<sup>a</sup>Department of Physiology and Neuroscience, Zilkha Neurogenetic Institute, Keck School of Medicine, University of Southern California, Los Angeles, CA, USA

<sup>b</sup>Department of Psychology, University of Southern California, Los Angeles, CA, USA

<sup>c</sup>Alzheimer's Disease Research Center, Keck School of Medicine at the University of Southern California, Los Angeles, CA, USA

<sup>d</sup>Department of Neurology, Keck School of Medicine, University of Southern California, Los Angeles, CA, USA

<sup>e</sup>Department of Psychiatry and the Behavioral Sciences, Keck School of Medicine, University of Southern California, Los Angeles, CA, USA

<sup>f</sup>Huntington Medical Research Institutes, Pasadena, CA, USA

<sup>g</sup>Laboratory of Neuro Imaging (LONI), Stevens Institute for Neuroimaging and Informatics, Keck School of Medicine, University of Southern California, Los Angeles, CA, USA

<sup>h</sup>Department of Radiology, Keck School of Medicine, University of Southern California, Los Angeles, CA, USA

<sup>i</sup>Neuroimaging Sciences and Brain Research Imaging Center, Division of Neuroimaging Sciences, Center for Clinical Brain Sciences, UK Dementia Research Institute at the University of Edinburgh, UK

<sup>j</sup>LC Campbell Cognitive Neurology Research Unit, Sunnybrook Research Institute, University of Toronto, Toronto, ON, Canada

<sup>k</sup>Hurvitz Brain Sciences Research Program, Sunnybrook Research Institute, University of Toronto, Toronto, ON, Canada

<sup>l</sup>Heart and Stroke Foundation Canadian Partnership for Stroke Recovery, Sunnybrook Health Sciences Centre, University of Toronto, Toronto, ON, Canada

<sup>m</sup>Department of Medicine (Neurology), Hurvitz Brain Sciences Program, Canadian Partnership for Stroke Recovery, and LC Campbell Cognitive Neurology Research Unit, Sunnybrook Research Institute, Sunnybrook Health Sciences Centre, Toronto Dementia Research Alliance, University of Toronto, Toronto, Canada

<sup>n</sup>Section for Translational Neuroscience, Faculty of Health and Medical Sciences, University of Copenhagen, Copenhagen, Denmark

<sup>o</sup>Division of Glia Disease and Therapeutics, Center for Translational Neuromedicine, University of Rochester Medical School, Rochester, NY, USA

<sup>p</sup>Department of Anesthesiology, Yale School of Medicine, New Haven, CT, USA

<sup>q</sup>Institute for Stroke and Dementia Research (ISD), Ludwig-Maximilians-University Munich, Munich, Germany

<sup>r</sup>Feil Family Brain and Mind Research Institute, Weill Cornell Medicine, New York, NY, USA

<sup>s</sup>Institute of Clinical Neurosciences, University of Bristol, School of Medicine, Level 2 Learning and Research, Southmead Hospital, Bristol, UK

<sup>t</sup>Stroke Trials Unit, Division of Clinical Neuroscience, University of Nottingham, City Hospital Campus, Nottingham, UK

<sup>u</sup>Stroke, Nottingham University Hospitals NHS Trust, City Hospital Campus, Nottingham, UK

[Correction added on 20 April 2022, after first online publication: The name Rustam A. Salman was corrected to Rustam Al-Shahi Salman.]

<sup>1</sup>Co-sharing senior authors.

E-mail address: zlokovic@usc.edu

\*Corresponding author. Tel.: +323 442 2722; Fax: +323 666 2184.

- <sup>v</sup>Stroke Research Group, Department of Clinical Neurosciences, University of Cambridge, Cambridge Biomedical Campus, Cambridge, UK
- <sup>w</sup>Faculty of Biology, Medicine and Health, Division of Neuroscience and Experimental Psychology, School of Biological Sciences, University of Manchester, Manchester, UK
- <sup>x</sup>Institute of Cardiovascular and Medical Sciences, University of Glasgow, Glasgow, UK
- <sup>y</sup>Neurovascular Research Group, Institute of Neuroscience, Newcastle University, Newcastle upon Tyne, UK
- <sup>z</sup>Stroke Research Centre, Department of Brain Repair and Rehabilitation, UCL Institute of Neurology and the National Hospital for Neurology and Neurosurgery, London, UK
- <sup>aa</sup>Faculty of Medicine, University of Southampton, Southampton, UK
- <sup>bb</sup>British Heart Foundation, Glasgow Cardiovascular Research Centre, Institute of Cardiovascular and Medical Sciences, University of Glasgow, UK
- <sup>cc</sup>Department of Neuroimaging, Institute of Psychiatry, Psychology & Neuroscience, King's College London, London, UK
- <sup>dd</sup>Stroke and Neurovascular Regulation Laboratory, Departments of Radiology and Neurology Harvard Medical School, Massachusetts General Hospital, Boston, MA, USA
- <sup>ee</sup>Department of Anesthesiology and Molecular Pharmacology and Experimental Therapeutics, Mayo Clinic College of Medicine, Rochester, MN, USA
- <sup>ff</sup>Department of Anatomy and Cell Biology, University of Illinois at Chicago, Chicago, IL, USA
- <sup>gg</sup>Department of Anesthesiology, University of Illinois at Chicago, Chicago, IL, USA
- <sup>hh</sup>Department of Pharmacology, University of Illinois at Chicago, Chicago, IL, USA
- <sup>ii</sup>Department of Pharmacology, The Center for Lung and Vascular Biology, The University of Illinois College of Medicine, Chicago, IL, USA
- <sup>jj</sup>Department of Medicine, The Center for Lung and Vascular Biology, The University of Illinois College of Medicine, Chicago, IL, USA
- <sup>kk</sup>Department of Pharmacology, University of Arizona, Tucson, AZ, USA
- <sup>ll</sup>Department of Pathology and Laboratory Medicine, Djavad Mowafaghian Centre for Brain Health, University of British Columbia, Vancouver, British Columbia, Canada
- <sup>mmm</sup>Department of Neurosciences, University of California, San Diego, CA, USA
- <sup>nn</sup>Department of Radiology, University of Washington, Seattle, WA, USA
- <sup>oo</sup>Department of Internal Medicine, Wake Forest School of Medicine, Winston-Salem, NC, USA
- <sup>pp</sup>Alzheimer's Disease Research Center, Wake Forest School of Medicine, Winston-Salem, NC, USA
- <sup>qq</sup>Department of Pharmacology, Yong Loo Lin School of Medicine, National University of Singapore, Memory Aging and Cognition Centre, National University Health System, Singapore
- <sup>rr</sup>Department of Psychological Medicine, Yong Loo Lin School of Medicine, National University of Singapore, Memory Aging and Cognition Centre, National University Health System, Singapore
- <sup>ss</sup>Centre for Healthy Brain Ageing, School of Psychiatry, University of New South Wales Australia, Sydney, Australia
- <sup>tt</sup>Department of Psychiatry, University of Cambridge School of Clinical Medicine, Cambridge, UK
- <sup>uu</sup>Department of Psychiatry and Neurochemistry, Institute of Neuroscience and Physiology, Sahlgrenska Academy, University of Gothenburg, Mölndal, Sweden
- <sup>vv</sup>"L. Sacco" Department of Biomedical and Clinical Sciences, University of Milan, Milan, Italy
- <sup>www</sup>Department of Neurology, State University of New York-Downstate Medical Center, Brooklyn, NY, USA
- <sup>xx</sup>Department of Neurology, Brain Center Rudolf Magnus, University Medical Center Utrecht, Utrecht, The Netherlands
- <sup>yy</sup>Institute of Neuroscience and Physiology, University of Gothenburg, Gothenburg, Sweden
- <sup>zz</sup>Hotchkiss Brain Institute, University of Calgary, Alberta, Canada
- <sup>aaa</sup>Department of Medicine and Therapeutics, Therese Pei Fong Chow Research Centre for Prevention of Dementia, The Chinese University of Hong Kong, Hong Kong SAR, China
- <sup>bbb</sup>Gerald Choa Neuroscience Centre, Lui Che Woo Institute of Innovative Medicine, The Chinese University of Hong Kong, Hong Kong SAR, China
- <sup>ccc</sup>School of Medicine, Dentistry and Biomedical Sciences, Queen's University Belfast, Belfast, UK
- <sup>ddd</sup>Department of Radiology and Nuclear Medicine, Amsterdam Neuroscience, VU University Medical Center, Amsterdam, The Netherlands
- <sup>eee</sup>Institutes of Neurology and Healthcare Engineering, University College London, London, UK
- <sup>fff</sup>Section of Geriatrics, Department of Internal Medicine, VU University Medical Center, Amsterdam, The Netherlands
- <sup>ggg</sup>Department of Population Health Sciences, German Center for Neurodegenerative Diseases (DZNE), Bonn, Germany
- <sup>hhh</sup>Institute for Medical Biometry, Informatics and Epidemiology (IMBIE), Faculty of Medicine, University of Bonn, Bonn, Germany
- <sup>iii</sup>Department of Neurology, Methodist Neurological Institute, Houston, TX, USA
- <sup>jjj</sup>Laboratory of Cerebrovascular Research, Montreal Neurological Institute, McGill University, Montréal, QC, Canada
- <sup>kkk</sup>The Framingham Heart Study, Framingham, MA, USA
- <sup>lll</sup>Department of Neurology, Boston University School of Medicine, Boston, MA, USA
- <sup>mmm</sup>Departments of Neurology and Epidemiology, Johns Hopkins University, Baltimore, MD, USA
- <sup>nnn</sup>Department of Radiology, Leiden University Medical Center, Leiden, The Netherlands
- <sup>ooo</sup>Department of Neurological Sciences, Rush University Medical Center, Chicago, IL, USA
- <sup>ppp</sup>Rush Alzheimer's Disease Center, Rush University Medical Center, Chicago, IL, USA
- <sup>qqq</sup>Laboratory of Cerebral Vascular Biology, Department of Biomedical Sciences, University of Minnesota Medical School Duluth, Duluth, MN, USA
- <sup>rrr</sup>Division of Neurology, Department of Clinical Neurological Sciences, Western University, London, Ontario, Canada
- <sup>sss</sup>Leonard Davis School of Gerontology, Dornsife College, University of Southern California, Los Angeles, CA, USA

## Abstract

Increasing evidence recognizes Alzheimer's disease (AD) as a multifactorial and heterogeneous disease with multiple contributors to its pathophysiology, including vascular dysfunction. The recently updated AD Research Framework put forth by the National Institute on Aging–Alzheimer's Association describes a biomarker-based pathologic definition of AD focused on amyloid, tau, and neuronal injury. In response to this article, here we first discussed evidence that vascular dysfunction is an important early event in AD pathophysiology. Next, we examined various imaging sequences that could be easily implemented to evaluate different types of vascular dysfunction associated

with, and/or contributing to, AD pathophysiology, including changes in blood-brain barrier integrity and cerebral blood flow. Vascular imaging biomarkers of small vessel disease of the brain, which is responsible for >50% of dementia worldwide, including AD, are already established, well characterized, and easy to recognize. We suggest that these vascular biomarkers should be incorporated into the AD Research Framework to gain a better understanding of AD pathophysiology and aid in treatment efforts.

© 2018 the Alzheimer's Association. Published by Elsevier Inc. All rights reserved.

**Keywords:** Alzheimer's disease; Vascular; Blood-brain barrier; Cerebral blood flow; MRI; Biomarkers

## 1. Commentary on the “NIA-AA Research Framework: Towards a Biological Definition of Alzheimer's Disease” and the need to include biomarkers of vascular dysfunction

The recent 2018 NIA-AA Research Framework “Towards a Biological Definition of Alzheimer's Disease” (referred to below as the Research Framework) outlines a biomarker system to classify individuals in the Alzheimer's disease (AD) continuum using imaging biomarkers and cerebrospinal fluid (CSF) biomarkers focused on amyloid- $\beta$  ( $A\beta$ ) [A], tau [T], and neurodegeneration [(N)]—the “AT(N)” biomarker system [1]. The AT(N) system has been proposed to define a biomarker-based approach to diagnose AD for observational and interventional research studies but at the same time does not imply a specific order of events nor causality and acknowledges an uncertain relationship between the A and T biomarkers and disease symptoms [1]. The Research Framework defines an individual with biomarker evidence of both  $A\beta$  deposition and patho-

logic tau as having AD yet acknowledges that amyloid and tau deposits may not be causal to AD [1]. The Research Framework distinguishes between AD that is reserved for the pathologic entity (defined by amyloid and tau biomarkers) and the Alzheimer's clinical syndrome. As Alzheimer's clinical syndrome has been shown to be a disease with mixed pathologies and AD may also be multifactorial, other factors as illustrated in Fig. 1 will likely contribute to and/or modify onset and progression of symptoms, as discussed more in the following sections. Below we use the term AD (not strictly defined as amyloid+ and tau+ biomarkers), but rather more broadly inclusive of AD as a multifactorial and heterogeneous disease.

Despite the substantial evidence indicating early vascular contributions to AD pathophysiology and dementia, vascular disease very commonly accompanies AD and may also be in the causal pathway. Below, we first briefly discuss evidence that vascular dysfunction is a prominent and early feature in prodromal AD, and, without implying a causality, order of events, or specificity, suggest that adding vascular biomarkers to the proposed AT(N) biomarker system will help to better characterize and understand contributions of vascular dysfunction to cognitive impairment in patients suffering from AD. Next, we focus on  $2\text{-}^{18}\text{F}$ -fluoro-2-deoxy-D-glucose (FDG) positron emission tomography (PET), a molecular imaging biomarker for early preclinical AD and mild cognitive impairment (MCI) mentioned in the AT(N), and examine the evidence indicating that FDG-PET should also be considered a biomarker of vascular and/or blood-brain barrier (BBB) transport dysfunction rather than uniquely neuronal hypometabolism and neurodegeneration, as elaborated in recent reviews [2,3]. Recognizing these concepts will achieve a more balanced view of AD pathophysiology and its multifactorial origin and provide even better tools for early diagnosis of AD as well as pave the way for novel therapeutic approaches.

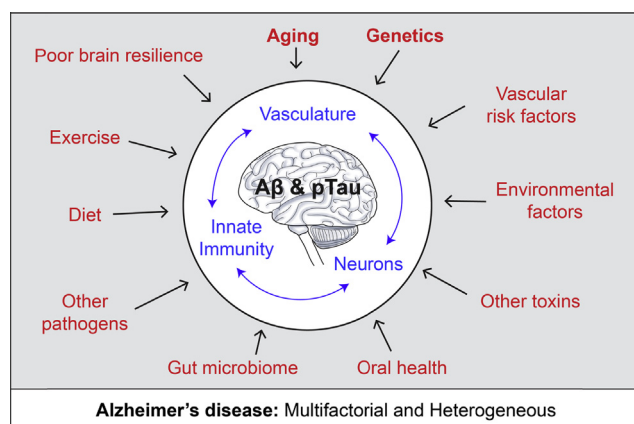


Fig. 1. Alzheimer's disease (AD) is a multifactorial and heterogeneous disease. AD is defined as a unique neurodegenerative disease based on the presence of amyloid- $\beta$  ( $A\beta$ ) and tau deposits. Additional factors (red), however, contribute to the onset and progression of AD pathophysiological changes directly affecting brain vascular system (i.e., blood-brain barrier leakages, blood flow shortfalls) and innate immune system, and neuronal health and functioning independently and/or simultaneously with  $A\beta$  and tau pathologies. This includes but is not limited to genetic risk factors, vascular factors, and environmental factors including socioeconomic stress, microbiome, and lifestyle. Aging still remains the key risk factor for AD and also profoundly affects brain vasculature, innate immune responses, and neuronal functions (blue).

### 1.1. Vascular dysfunction and vascular biomarkers in AD

Neuropathological studies have shown that cerebrovascular pathology is a major risk factor for clinically diagnosed AD-type dementia with clinical expression associated with low scores in most cognitive domains [4]. A large autopsy-based neuropathological study importantly revealed that 80% of patients diagnosed with AD and no evidence of

mixed (vascular) dementia had vascular pathology including cortical infarcts, lacunes, cerebral microbleeds, and multiple microinfarcts indicative of small vessel disease (SVD), intracranial atherosclerosis, arteriolosclerosis, perivascular spacing, and cerebral amyloid angiopathy (CAA) [5], supporting the concept that cerebrovascular dysfunction is prominent in AD and lowers the threshold for dementia for a given AD pathology burden. Furthermore, mounting evidence shows that vascular risk factors (VRFs) are associated with lower FDG-PET [6], cerebrovascular disease as expected [7], higher cerebral A $\beta$  burden [6,8], and higher tau burden [9] and act synergistically with A $\beta$  burden to promote cognitive decline [10]. Structural arterial changes leading to functional changes in cerebral blood flow (CBF) [11] are associated with the rate of accumulation of cerebral A $\beta$  over time [12] and the overlap of cerebrovascular and cerebral A $\beta$  pathologies in older adults [13]. The overlap of cerebrovascular and traditional AD pathologies is not exclusive to the late-onset form of AD but also present in autosomal-dominant AD (ADAD) [14]. It is important to extend epidemiology research beyond clinical VRFs to subclinical vascular measures that point to the mechanistic pathways linking vascular dysfunction to the various aspects of AD and dementia pathology in diverse cohorts.

Vascular dysfunction appears early in AD, as shown using different imaging biomarkers of BBB integrity [15–20], brain microbleeds [20–25], cerebrovascular reactivity [20,26,27], resting CBF [17,20,28–41], and increased cerebrovascular resistance [42]. BBB permeability to gadolinium, measured by dynamic contrast-enhanced (DCE) magnetic resonance imaging (MRI), is routinely used for clinical diagnosis of multiple sclerosis, stroke, and brain tumors [43,44]. Only recently has the DCE-MRI technique been modified and advanced to detect subtle changes in BBB permeability in the living human brain with a subregional spatial resolution capable of detecting changes at the level of hippocampal subfields and different gray and white matter regions studied in parallel [15,19,20,45]. Early BBB breakdown has been shown in the hippocampus and its CA1 and dentate gyrus subregions in individuals with MCI [15], and in several gray and white matter regions in early stages of AD [16–18]. In addition, BBB failure was found to be a core mechanism in cerebral SVD and dementia (see below) [45].

Widespread utilization of various imaging sequences could be easily implemented to evaluate different types of vascular dysfunction in AD pathophysiology. Fluid-attenuated inversion recovery (FLAIR) is the most common sequence used in aging and AD studies to define macrostructural white matter hyperintensities. Microstructural changes at tissue-level interstitial fluid (ISF) shifts are easily detected on diffusion tensor imaging sequences and quantified using the mean diffusivity parameter, which several studies have shown is highly sensitive to white matter microstructural damage and correlates with BBB failure [46,47]. Another vascular biomarker, microbleeds, can be measured with

short 5-minute T2\*-weighted sequences [20–25]; this would be easy to add to existing AD MRI protocols. Cerebral microbleeds are related to vascular wall damage by arteriosclerosis or CAA and also reflect a marker of ischemic white matter disease [3]. In addition, the DCE sequence to evaluate subtle, subregional BBB permeability lasts about 15 minutes, requires intravenous injection of a gadolinium contrast agent, and can be obtained in either coronal or transverse orientations for individual input function analysis. The DCE sequence has already been added to imaging protocols at several Alzheimer's Disease Centers, including University of Southern California (USC), Washington University in St. Louis, and Banner Alzheimer's Institute, and is also being used to study individuals with ADAD at USC in addition to its frequent use in patients with SVD (sporadic and genetic) and Binswanger's type of dementia. Functional changes such as impaired cerebrovascular reactivity that reflects diminished vasodilation of cerebral vessels in response to a CO<sub>2</sub> inhalation challenge can be measured using either blood oxygenation level dependent (BOLD) functional MRI [48,49] or arterial spin labeling (ASL) [26] at the tissue level, or transcranial Doppler (TCD) [27]. CBF reductions are detected by several different imaging methods, including pseudo-continuous ASL-MRI [17,28,33–37,41,50–52], four-dimensional phase contrast angiography [53], dynamic susceptibility-contrast (DSC) MRI [38], single-photon emission computed tomography [30–32,54], TCD [55], perfusion computed tomography [56], and [<sup>15</sup>O]-PET [29]. Recently, using advanced DSC methods, it is now possible to specifically detect capillary dysfunction that is impaired in AD [57].

Beyond the recognized microvascular dysfunction, emerging evidence also indicates CBF reductions at large- and medium-sized arteries in adults at risk for AD [52] and in AD models [58], supporting that quantification of vascular changes at all levels of the intracranial vasculature may provide a more comprehensive and possibly more sensitive marker for detecting early AD changes. New methods of evaluating angiography of three-dimensional vascular anatomy using time-of-flight (TOF) MRI sequences can provide several quantitative parameters such as number and order of branches, branch artery lengths and volumes, tortuosity, planarity, intensity, and so on, can be derived [59]. TOF sequences are already used to clinically evaluate vascular stenosis and detect aneurysms and vascular disease, and they could easily be added to MRI protocols and applied to cognitively normal older adults, MCI and AD for comprehensive analysis of angiographic data with the potential to provide new insights into vascular contributions to AD.

In addition to imaging biomarkers, CSF and blood-based biomarkers of vascular damage in the AD continuum are emerging such as, for example, CSF soluble platelet-derived growth factor receptor- $\beta$  reflecting mural cell injury [15,60] and CSF fibrinogen and standard albumin CSF/plasma quotient reflecting BBB breakdown [15,61,62]. Biofluid (CSF and blood) biomarkers of vascular damage

should continue to be validated by multiple independent studies. Furthermore, the more conventional pattern of low  $A\beta_{42}$  in the CSF reflects a failure of drainage of  $A\beta$  from the ISF of the brain across blood vessels and by perivascular ISF flow [63,64].

Moreover, imaging biomarkers of SVD are already established, well characterized, and easy to recognize, including white matter hyperintensities, lacunes (subcortical infarcts of vascular origin), microbleeds, and so on, as well as more subtle markers emerging now (such as microinfarcts and perivascular spaces) [19,63]. Beyond the vascular imaging biomarkers defined previously, further inclusion of SVD features in the differential biological approach in sporadic AD, ADAD [65], and other dementias would be relatively easy to achieve and is highly relevant because SVD of the brain contributes to >50% of all dementias worldwide including AD [19,66-69]. Neuroimaging techniques already used in SVD and vascular dementia should similarly be applied to AD and other dementias [70]. Acknowledging and further characterizing vascular contributions to the AD and association with biomarker-based AD pathology is important for ongoing observational studies in diverse cohorts and to target interventional strategies to prevent or slow down cognitive decline and dementia. This may be particularly important in underrepresented minority groups including African-Americans and Latinos at greater risk for cardiovascular disease, cerebrovascular disease, and AD.

## 1.2. FDG-PET

FDG, a radiolabeled form of 2-deoxy-D-glucose (2DG), which is an analog of glucose, is frequently used as a ligand for FDG-PET studies as a “surrogate” marker for glucose brain uptake [20]. Impaired FDG-PET uptake is often considered an exclusive biomarker of brain hypometabolism or neurodegeneration as proposed in the NIA-AA Research

Framework [1]. However, below we examine evidence that FDG also tracks BBB transport of glucose, and therefore low FDG-PET uptake should also be considered as a biomarker of vascular dysfunction.

Glucose and its 2DG and FDG analogs are transported across the BBB via brain endothelial-specific glucose transporter-1 (GLUT1) and then taken up by different cell types (e.g., neurons) in the brain via their respective glucose transporters, which does not include GLUT1 [71-73]. The ubiquitous intracellular hexokinase then phosphorylates glucose, 2DG, and FDG to their respective 6-phosphates (6P) [74-77]. However, after this initial phosphorylation step by hexokinase, there are critical differences between glucose versus 2DG/FDG metabolic fates in brain [71,74-77] as illustrated in Fig. 2. After phosphorylation, glucose-6P is converted to fructose-6P that undergoes glycolysis followed by pyruvate entry into the Krebs cycle and oxidative phosphorylation. But, glucose analogs 2DG and FDG are not substrates for glucose-6P isomerase and thus cannot be converted into fructose-6P, which is the necessary step to enter the glycolytic pathway as well as the subsequent Krebs cycle [74-77]. Instead, 2DG-6P and FDG-6P remain trapped in the brain in their 6P forms and are only slowly eliminated from the brain [74-77], as has been shown by multiple independent studies. For example, 60-90 minutes after 2DG [75] or FDG [76,78] systemic administration, ~90%-97% of 2DG or FDG was found in the mouse brain [75,76] or rat brain [76,78] in the form of 2DG-6P or FDG-6P, whereas <10% remains as pure 2DG or FDG with no other significant metabolites found in the brain. Because of very low brain glucose-6-phosphatase activity and poor 2DG-6P membrane permeability [74,79,80], 2DG-6P remains trapped in brain cells [78,81] and is slowly eliminated from the brain.

Importantly, FDG-PET studies show diminished glucose uptake in several brain regions (e.g., precuneus, posterior

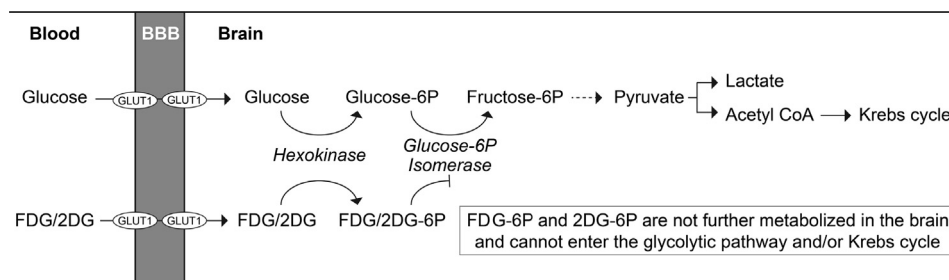


Fig. 2. Schematic illustrating key differences in brain metabolic fate of glucose and its nonmetabolizable surrogate analog 2-deoxy-D-glucose (2DG) and its radiolabeled form 2-<sup>18</sup>F-fluoro-2-deoxy-D-glucose (FDG). Glucose, a key energy metabolite in the brain, is transported across the blood-brain barrier (BBB) via endothelial-specific glucose transporter-1 (GLUT1) hexose transporter. After uptake by brain cells, glucose undergoes glycolysis followed by Krebs cycle and oxidative metabolism providing the fuel for physiological brain functions through the generation of high-energy adenosine-3 phosphate (ATP) molecules, the foundation for neuronal and nonneuronal cell maintenance, and the generation of neurotransmitters. On the other hand, glucose surrogate analogs 2DG and FDG, although still transported across the BBB via GLUT1 hexose transporter, cannot enter the glycolytic pathway or Krebs cycle in brain. After the initial hexokinase step, 2DG-6P and FDG-6P get trapped in the brain because they are not substrates for glucose-6P isomerase, which is a necessary metabolic step in the glycolytic pathway. Therefore, 2DG and FDG are not metabolized by the glycolytic pathway or Krebs cycle and do not generate any ATP energy-donor molecules in the brain, and their net metabolic rate in brain is zero joules.

cingulate, right angular gyrus, bilateral temporal cortices) before any detectable neurodegenerative changes, brain atrophy, and/or conversion to AD [82]. Reduced regional FDG brain uptake in AD is not due to brain atrophy, as confirmed by studies in the posterior cingulate gyrus and parieto-temporal cortex [83]. Longitudinal FDG-PET findings have suggested that reductions in hippocampal glucose uptake during normal aging can predict cognitive decline years in advance of clinical AD diagnosis [84]. Diminished glucose uptake in the hippocampus, parieto-temporal cortex, and/or posterior cingulate cortex has been repeatedly shown by FDG-PET in early AD [85] and also in individuals at genetic risk for AD [86,87], with a positive family history of AD [88], and/or MCI or no cognitive impairment before progression to AD [89]. The patterns of FDG brain uptake can also discriminate individuals with normal cognition from MCI and AD patients [85], suggesting region-specific insufficiency in brain delivery and uptake of glucose to the brain. FDG-PET changes preceding neurodegeneration are not only found in humans [82-84,90] but also in transgenic AD models [91].

Although FDG-PET changes in AD are typically interpreted as the result of neuronal glucose hypometabolism, *in vivo* dynamic FDG-PET kinetic studies in humans consistently show significant reductions in glucose BBB transport in AD subjects compared to controls [92-95], consistent with postmortem studies showing significantly reduced GLUT1 levels in brain capillaries, a site of the BBB *in vivo* [96-99]. On the other hand, a few studies that directly measured hexokinase activity levels in AD brains reported rather conflicting results showing a decrease [92,94], increase [100], or no change [93,101]. In addition, in contrast to glucose, 2DG does not proceed beyond the initial phosphorylation step into glycolytic or Krebs metabolic pathways as shown by rodent [74-78] and human [92-95] studies and does not generate a single high-energy adenosine-3-phosphate molecule to maintain functions of neurons and nonneuronal cells in the brain. The lack of FDG contribution to brain energy metabolism supports the concept that FDG-PET tracks BBB transport of glucose and an initial phosphorylation step by hexokinase, but it does not dependably track all steps involved in energy metabolism of glucose in neurons and is not metabolized by neurons. New tracers such as 3-O-[<sup>11</sup>C]-methylglucose that exclusively track BBB transport and are not phosphorylated by hexokinase or metabolized should be used by future studies to specifically determine the role of glucose transport in AD as possibly an early biomarker [102].

### 1.3. Recommendations

We recommend the following extensions of the Research Framework: (1) Incorporate biomarkers of vascular dysfunction to assess vascular contributions to AD using imaging biomarkers such as FLAIR, diffusion tensor imaging, T2\*-

weighted sequences, DCE, ASL, and DSC MRI sequences, TCD, BOLD-fMRI, and TOF, and molecular biomarkers of vascular damage in individuals with AD or dementia risk or with suspected dementia; whenever and whichever possible, vascular imaging biomarkers should be adopted in AD research studies, large epidemiological studies, and interventional trials [103]. Integration of vascular dysfunction biomarkers into the diagnostic process may allow for earlier diagnosis of AD in some patient subsets. Recognizing and including the wealth of knowledge on how to prevent and treat vascular disease and on interventions to modify vascular dysfunction could significantly advance research in AD and dementia, thus ultimately helping patients. (2) Reclassify diminished FDG brain uptake by PET not as a unique biomarker of neuronal hypometabolism due to diminished hexokinase activity, but also as a biomarker tracking vascular, that is, BBB transport, abnormality. This particularly, as a few direct studies determining hexokinase activity in AD subjects showed mixed results including a decrease [92,94], increase [100], or no change [93,101], suggests that equating diminished FDG-PET uptake with cellular hypometabolism should not be made unless both transport and phosphorylation components are measured simultaneously by FDG-PET kinetic studies, which should show directly whether metabolism is affected or not, but unfortunately has not been done in most FDG-PET studies. This reclassification could have profound consequences for the diagnosis and treatment of AD patients because it would highlight the potential of FDG uptake to identify therapeutic windows of opportunity before the onset of irreversible neurodegeneration.

Recent evidence indicates that reducing stroke incidence also reduces dementia incidence [69,104]. Later, this year (October 2018), a one-day satellite meeting held by the World Health Summit will jointly discuss cerebrovascular and neurodegeneration diseases and the concept of dementia prevention by stroke prevention: <https://www.worldhealthsummit.org/satellites/dementia-stroke-prevention.html>. Similarly, managing and reducing VRFs may protect against cognitive decline because VRFs act synergistically with A $\beta$  to promote cognitive decline [10]. VRF reduction approaches may be particularly effective in ethnic minorities at greater risk for cardiovascular disease, cerebrovascular disease, and AD. Remarkably, a third of elderly individuals have considerable Alzheimer-type pathology (plaques and tangles) in brain but no cognitive impairment [105]. We are only beginning to understand some of the potential mechanisms of brain resistance and brain resilience [106]; just as biomarkers of disease are important, so are biomarkers of resilience. Finally, future longitudinal studies in individuals at genetic risk for AD should examine how changes in vascular biomarkers relate to amyloid and tau biomarker changes, structural and functional brain connectivity, and cognitive measures over time.

The 2018 Research Framework attempts to unify language of biomarker-based definition of AD, but it

underrecognizes AD as a heterogeneous disease and does not clearly define AD in the context of multifactorial and functional systems contributing to disease pathophysiology. Many factors can influence onset and progression of cognitive dysfunction in AD, which besides aging, includes genetics, VRFs, environmental factors, microbiome, and lifestyle, to mention a few (see Fig. 1). All these factors influence aging of the vascular system, innate immunity, and neuronal health and function directly independent of amyloid and tau, as well as synergistically with A $\beta$  and tau (see Fig. 1). The Research Framework acknowledges vascular biomarkers could be added when they are defined but unfortunately does not fully appreciate that several vascular biomarkers “ready-to-be-used” already exist and are well defined. Because amyloid and tau deposits may not be causal in AD pathogenesis, as recognized by the Research Framework [1], it is the right time to encourage inclusion of biomarkers of vascular dysfunction in observational and interventional research studies. Finally, rather than focusing only on amyloid and tau, broadening the perspective and study of contributing factors to AD will aid in patient-directed therapeutic efforts to apply the right drug(s)—at the right dose—at the right time—in the right study design—and with the right outcome measures for successful intervention to delay, prevent, and/or reverse dementia and AD. Individualized, targeted therapies for AD patients will be successful when the complexity of AD pathophysiology is fully appreciated so that multidisciplinary team efforts can be mounted to successfully address one of the most challenging diseases in the 21st century.

## Acknowledgments

Supported by the National Institutes of Health (NIH) grants R01AG023084 (B.V.Z.), R01NS090904 (B.V.Z.), R01NS034467 (B.V.Z.), R01AG039452 (B.V.Z.), 1R01NS100459 (B.V.Z.), 5P01AG052350 (B.V.Z.), 5P50AG005142 (H.C.C.; University of Southern California Alzheimer's Disease Research Center), EB015922 (A.W.T.; Laboratory of Neuro Imaging, LONI), R37-NS089323 (C.I.), R01-NS100447 (C.I.), R01-NS09544 (C.I.), R01-NS/HL037853 (C.I.), R01-NS034179 (C.I.), KL2-TR002002 (S.E.L.), R01-AG064248 (H.M.G.), RF1-AG054548 (H.M.G.), P30-AG005131 (H.M.G.), R21-AG056952 (H.M.G.), P30AG049638 (T.M.H.; S.N.L.), R01AG054069 (T.M.H.; S.N.L.), R01HL096814 (T.M.H.), and R01AG053938 (T.M.H.) in addition to the Alzheimer's Association, Cure Alzheimer's Fund, and the Foundation Leducq Transatlantic Network of Excellence for the Study of Perivascular Spaces in Small Vessel Disease reference no. 16CVD 05.

## References

[1] Jack CR, Bennett DA, Blennow K, Carrillo MC, Dunn B, Haeberlein SB, et al. NIA-AA Research Framework: Toward a bio-

- logical definition of Alzheimer's disease. *Alzheimers Dement* 2018;14:535–62.
- [2] Montagne A, Zhao Z, Zlokovic BV. Alzheimer's disease: A matter of blood-brain barrier dysfunction? *J Exp Med* 2017;241:3151–69.
- [3] Sweeney MD, Sagare AP, Zlokovic BV. Blood-brain barrier breakdown in Alzheimer disease and other neurodegenerative disorders. *Nat Rev Neurol* 2018;14:133–50.
- [4] Arvanitakis Z, Capuano AW, Leurgans SE, Bennett DA, Schneider JA. Relation of cerebral vessel disease to Alzheimer's disease dementia and cognitive function in elderly people: A cross-sectional study. *Lancet Neurol* 2016;15:934–43.
- [5] Toledo JB, Arnold SE, Raible K, Brettschneider J, Xie SX, Grossman M, et al. Contribution of cerebrovascular disease in autopsy confirmed neurodegenerative disease cases in the National Alzheimer's Coordinating Centre. *Brain J Neurol* 2013;136:2697–706.
- [6] Langbaum JBS, Chen K, Launer LJ, Fleisher AS, Lee W, Liu X, et al. Blood pressure is associated with higher brain amyloid burden and lower glucose metabolism in healthy late middle-age persons. *Neurobiol Aging* 2012;33:827.e11–827.e19.
- [7] Bangen KJ, Nation DA, Delano-Wood L, Weissberger GH, Hansen LA, Galasko DR, et al. Aggregate effects of vascular risk factors on cerebrovascular changes in autopsy-confirmed Alzheimer's disease. *Alzheimers Dement* 2015;11:394–403.e1.
- [8] Gottesman RF, Schneider ALC, Zhou Y, Coresh J, Green E, Gupta N, et al. Association between midlife vascular risk factors and estimated brain amyloid deposition. *JAMA* 2017;317:1443–50.
- [9] Vemuri P, Lesnick TG, Przybelski SA, Knopman DS, Lowe VJ, Graff-Radford J, et al. Age, vascular health, and Alzheimer disease biomarkers in an elderly sample. *Ann Neurol* 2017;82:706–18.
- [10] Rabin JS, Schultz AP, Hedden T, Viswanathan A, Marshall GA, Kilpatrick E, et al. Interactive associations of vascular risk and  $\beta$ -amyloid burden with cognitive decline in clinically normal elderly individuals findings from the Harvard Aging Brain Study. *JAMA Neurol* 2018;75:1124–31.
- [11] Avolio A, Kim MO, Adji A, Gangoda S, Avadhanam B, Tan I, et al. Cerebral haemodynamics: effects of systemic arterial pulsatile function and hypertension. *Curr Hypertens Rep* 2018;20:20.
- [12] Hughes TM, Kuller LH, Barinas-Mitchell EJM, McDade EM, Klunk WE, Cohen AD, et al. Arterial stiffness and  $\beta$ -amyloid progression in nondemented elderly adults. *JAMA Neurol* 2014;71:562–8.
- [13] Hughes TM, Wagenknecht LE, Craft S, Mintz A, Heiss G, Palta P, et al. Arterial stiffness and dementia pathology: Atherosclerosis Risk in Communities (ARIC)-PET Study. *Neurology* 2018;90:e1248–56.
- [14] Lee S, Viqar F, Zimmerman ME, Narkhede A, Tosto G, Benzinger TLS, et al. White matter hyperintensities are a core feature of Alzheimer's disease: Evidence from the dominantly inherited Alzheimer network. *Ann Neurol* 2016;79:929–39.
- [15] Montagne A, Barnes SR, Sweeney MD, Halliday MR, Sagare AP, Zhao Z, et al. Blood-brain barrier breakdown in the aging human hippocampus. *Neuron* 2015;85:296–302.
- [16] van de Haar HJ, Burgmans S, Jansen JFA, van Osch MJ, van Buchem MA, Muller M, et al. Blood-brain barrier leakage in patients with early Alzheimer disease. *Radiology* 2016;281:527–35.
- [17] van de Haar HJ, Jansen JFA, van Osch MJ, van Buchem MA, Muller M, Wong SM, et al. Neurovascular unit impairment in early Alzheimer's disease measured with magnetic resonance imaging. *Neurobiol Aging* 2016;45:190–6.
- [18] van de Haar HJ, Jansen JFA, Jeukens CRLPN, Burgmans S, van Buchem MA, Muller M, et al. Subtle blood-brain barrier leakage rate and spatial extent: Considerations for dynamic contrast-enhanced MRI. *Med Phys* 2017;44:4112–25.
- [19] Wardlaw JM, Smith EE, Biessels GJ, Cordonnier C, Fazekas F, Frayne R, et al. Neuroimaging standards for research into small



- vessel disease and its contribution to ageing and neurodegeneration. *Lancet Neurol* 2013;12:822–38.
- [20] Montagne A, Naton DA, Pa J, Sweeney MD, Toga AW, Zlokovic BV. Brain imaging of neurovascular dysfunction in Alzheimer's disease. *Acta Neuropathol* 2016;131:687–707.
- [21] Poliakova T, Levin O, Arablinskiy A, Vasenina E, Zerr I. Cerebral microbleeds in early Alzheimer's disease. *J Neurol* 2016;263:1961–8.
- [22] Vernooij MW, van der Lugt A, Ikram MA, Wielopolski PA, Niessen WJ, Hofman A, et al. Prevalence and risk factors of cerebral microbleeds: the Rotterdam Scan Study. *Neurology* 2008;70:1208–14.
- [23] Heringa SM, Reijmer YD, Leemans A, Koek HL, Kappelle LJ, Biessels GJ, et al. Multiple microbleeds are related to cerebral network disruptions in patients with early Alzheimer's disease. *J Alzheimers Dis* 2014;38:211–21.
- [24] Shams S, Martola J, Granberg T, Li X, Shams M, Fereshtehnejad SM, et al. Cerebral microbleeds: Different prevalence, topography, and risk factors depending on dementia diagnosis—the Karolinska Imaging Dementia Study. *AJNR Am J Neuroradiol* 2015;36:661–6.
- [25] Shams S, Wahlund L-O. Cerebral microbleeds as a biomarker in Alzheimer's disease? A review in the field. *Biomark Med* 2016;10:9–18.
- [26] Suri S, Mackay CE, Kelly ME, Germuska M, Tunbridge EM, Frisoni GB, et al. Reduced cerebrovascular reactivity in young adults carrying the APOE  $\epsilon$ 4 allele. *Alzheimers Dement* 2015;11:648–657.e1.
- [27] Hajjar I, Sorond F, Lipsitz LA. Apolipoprotein E, carbon dioxide vasoreactivity, and cognition in older adults: Effect of hypertension. *J Am Geriatr Soc* 2015;63:276–81.
- [28] Iturria-Medina Y, Sotero RC, Toussaint PJ, Mateos-Pérez JM, Evans ACA Alzheimer's Disease Neuroimaging Initiative. Early role of vascular dysregulation on late-onset Alzheimer's disease based on multifactorial data-driven analysis. *Nat Commun* 2016;7:11934.
- [29] Thambisetty M, Beason-Held L, An Y, Kraut MA, Resnick SM. APOE epsilon4 genotype and longitudinal changes in cerebral blood flow in normal aging. *Arch Neurol* 2010;67:93–8.
- [30] Hirao K, Ohnishi T, Matsuda H, Nemoto K, Hirata Y, Yamashita F, et al. Functional interactions between entorhinal cortex and posterior cingulate cortex at the very early stage of Alzheimer's disease using brain perfusion single-photon emission computed tomography. *Nucl Med Commun* 2006;27:151–6.
- [31] Kogure D, Matsuda H, Ohnishi T, Asada T, Uno M, Kunihiro T, et al. Longitudinal evaluation of early Alzheimer's disease using brain perfusion SPECT. *J Nucl Med* 2000;41:1155–62.
- [32] Matsuda H, Kitayama N, Ohnishi T, Asada T, Nakano S, Sakamoto S, et al. Longitudinal evaluation of both morphologic and functional changes in the same individuals with Alzheimer's disease. *J Nucl Med* 2002;43:304–11.
- [33] Alexopoulos P, Sorg C, Förchler A, Grimmer T, Skokou M, Wohlschläger A, et al. Perfusion abnormalities in mild cognitive impairment and mild dementia in Alzheimer's disease measured by pulsed arterial spin labeling MRI. *Eur Arch Psychiatry Clin Neurosci* 2012;262:69–77.
- [34] Dai W, Lopez OL, Carmichael OT, Becker JT, Kuller LH, Gach HM. Mild cognitive impairment and Alzheimer disease: Patterns of altered cerebral blood flow at MR imaging. *Radiology* 2009;250:856–66.
- [35] Hirao K, Ohnishi T, Hirata Y, Yamashita F, Mori T, Moriguchi Y, et al. The prediction of rapid conversion to Alzheimer's disease in mild cognitive impairment using regional cerebral blood flow SPECT. *NeuroImage* 2005;28:1014–21.
- [36] Naton DA, Wierenga CE, Clark LR, Dev SI, Stricker NH, Jak AJ, et al. Cortical and subcortical cerebrovascular resistance index in mild cognitive impairment and Alzheimer's disease. *J Alzheimers Dis* 2013;36:689–98.
- [37] Michels L, Warnock G, Buck A, Macaudo G, Leh SE, Kaelin AM, et al. Arterial spin labeling imaging reveals widespread and A $\beta$ -independent reductions in cerebral blood flow in elderly apolipoprotein epsilon-4 carriers. *J Cereb Blood Flow Metab* 2016;36:581–95.
- [38] Wirth M, Pichet Binette A, Brunecker P, K $\phi$ be T, Witte AV, Fl $\phi$ el A. Divergent regional patterns of cerebral hypoperfusion and gray matter atrophy in mild cognitive impairment patients. *J Cereb Blood Flow Metab* 2017;37:814–24.
- [39] de Eulate RG, Gopi I, Galiano A, Vidorrera M, Recio M, Riverol M, et al. Reduced cerebral blood flow in mild cognitive impairment assessed using phase-contrast MRI. *J Alzheimers Dis* 2017;58:585–95.
- [40] Leijenaar JF, van Maurik IS, Kuijper JPA, van der Flier WM, Scheltens P, Barkhof F, et al. Lower cerebral blood flow in subjects with Alzheimer's dementia, mild cognitive impairment, and subjective cognitive decline using two-dimensional phase-contrast magnetic resonance imaging. *Alzheimers Dement (Amst)* 2017;9:76–83.
- [41] Alsop DC, Detre JA, Grossman M. Assessment of cerebral blood flow in Alzheimer's disease by spin-labeled magnetic resonance imaging. *Ann Neurol* 2000;47:93–100.
- [42] Yew B, Naton DA Alzheimer's Disease Neuroimaging Initiative. Cerebrovascular resistance: Effects on cognitive decline, cortical atrophy, and progression to dementia. *Brain J Neurol* 2017;140:1987–2001.
- [43] Sourbron S, Ingrisch M, Siefert A, Reiser M, Herrmann K. Quantification of cerebral blood flow, cerebral blood volume, and blood-brain-barrier leakage with DCE-MRI. *Magn Reson Med* 2009;62:205–17.
- [44] Larsson HBW, Courivaud F, Rostrup E, Hansen AE. Measurement of brain perfusion, blood volume, and blood-brain barrier permeability, using dynamic contrast-enhanced T(1)-weighted MRI at 3 tesla. *Magn Reson Med* 2009;62:1270–81.
- [45] Wardlaw JM, Makin SJ, Valdus Hernández MC, Armitage PA, Heye AK, Chappell FM, et al. Blood-brain barrier failure as a core mechanism in cerebral small vessel disease and dementia: Evidence from a cohort study. *Alzheimers Dement* 2017;13:634–43.
- [46] Mupoze Maniega S, Chappell FM, Valdus Hernández MC, Armitage PA, Makin SD, Heye AK, et al. Integrity of normal-appearing white matter: Influence of age, visible lesion burden and hypertension in patients with small-vessel disease. *J Cereb Blood Flow Metab* 2017;37:644–56.
- [47] Baykara E, Gesierich B, Adam R, Tuladhar AM, Biesbroek JM, Koek HL, et al. A novel imaging marker for small vessel disease based on skeletonization of white matter tracts and diffusion histograms. *Ann Neurol* 2016;80:581–92.
- [48] Sam K, Peltenburg B, Conklin J, Sobczyk O, Poulblanc J, Crawley AP, et al. Cerebrovascular reactivity and white matter integrity. *Neurology* 2016;87:2333–9.
- [49] Pillai JJ, Mikulis DJ. Cerebrovascular reactivity mapping: an evolving standard for clinical functional imaging. *AJNR Am J Neuroradiol* 2015;36:7–13.
- [50] Wang T, Li Y, Guo X, Huang D, Ma L, Wang DJJ, et al. Reduced perfusion in normal-appearing white matter in mild to moderate hypertension as revealed by 3D pseudocontinuous arterial spin labeling. *J Magn Reson Imaging* 2016;43:635–43.
- [51] Xekardaki A, Rodriguez C, Montandon M-L, Toma S, Tombeur E, Herrmann FR, et al. Arterial spin labeling may contribute to the prediction of cognitive deterioration in healthy elderly individuals. *Radiology* 2015;274:490–9.
- [52] Clark LR, Berman SE, Rivera-Rivera LA, Hoscheidt SM, Darst BF, Engelman CD, et al. Macrovascular and microvascular cerebral blood flow in adults at risk for Alzheimer's disease. *Alzheimers Dement (Amst)* 2017;7:48–55.
- [53] Rivera-Rivera LA, Turski P, Johnson KM, Hoffman C, Berman SE, Kilgas P, et al. 4D flow MRI for intracranial hemodynamics assessment in Alzheimer's disease. *J Cereb Blood Flow Metab* 2016;36:1718–30.
- [54] Makedonov I, Black SE, MacIntosh BJ. Cerebral small vessel disease in aging and Alzheimer's disease: A comparative study using MRI and SPECT. *Eur J Neurol* 2013;20:243–50.
- [55] Ruitenbergh A, den Heijer T, Bakker SLM, van Swieten JC, Koudstaal PJ, Hofman A, et al. Cerebral hypoperfusion and clinical

- onset of dementia: The Rotterdam Study. *Ann Neurol* 2005; 57:789–94.
- [56] Zhang B, Gu G-J, Jiang H, Guo Y, Shen X, Li B, et al. The value of whole-brain CT perfusion imaging and CT angiography using a 320-slice CT scanner in the diagnosis of MCI and AD patients. *Eur Radiol* 2017;27:4756–66.
- [57] Nielsen RB, Egeffjord L, Angley H, Mouridsen K, Gejl M, Møller A, et al. Capillary dysfunction is associated with symptom severity and neurodegeneration in Alzheimer's disease. *Alzheimers Dement* 2017;13:1143–53.
- [58] El Tayara NET, Delatour B, Volk A, Dhenain M. Detection of vascular alterations by in vivo magnetic resonance angiography and histology in APP/PS1 mouse model of Alzheimer's disease. *MAGMA* 2010;23:53–64.
- [59] Chen L, Mossa-Basha M, Balu N, Canton G, Sun J, Pimentel K, et al. Development of a quantitative intracranial vascular features extraction tool on 3D MRA using semiautomated open-curve active contour vessel tracing. *Magn Reson Med* 2018;79:3229–38.
- [60] Sagare AP, Sweeney MD, Makshanoff J, Zlokovic BV. Shedding of soluble platelet-derived growth factor receptor- $\beta$  from human brain pericytes. *Neurosci Lett* 2015;607:97–101.
- [61] Sweeney MD, Sagare AP, Zlokovic BV. Cerebrospinal fluid biomarkers of neurovascular dysfunction in mild dementia and Alzheimer's disease. *J Cereb Blood Flow Metab* 2015;35:1055–68.
- [62] Craig-Schapiro R, Kuhn M, Xiong C, Pickering EH, Liu J, Misko TP, et al. Multiplexed immunoassay panel identifies novel CSF biomarkers for Alzheimer's disease diagnosis and prognosis. *PLoS One* 2011;6:e18850.
- [63] Weller RO, Hawkes CA, Kalaria RN, Werring DJ, Carare RO. White matter changes in dementia: Role of impaired drainage of interstitial fluid. *Brain Pathol* 2015;25:63–78.
- [64] Mawuenyega KG, Sigurdson W, Ovod V, Munsell L, Kasten T, Morris JC, et al. Decreased clearance of CNS beta-amyloid in Alzheimer's disease. *Science* 2010;330:1774.
- [65] Lee S, Zimmerman ME, Narkhede A, Nasrabad SE, Tosto G, Meier IB, et al. White matter hyperintensities and the mediating role of cerebral amyloid angiopathy in dominantly-inherited Alzheimer's disease. *PLoS One* 2018;13:e0195838.
- [66] Iadecola C. The pathobiology of vascular dementia. *Neuron* 2013; 80:844–66.
- [67] Montine TJ, Koroshetz WJ, Babcock D, Dickson DW, Galpern WR, Glymour MM, et al. Recommendations of the Alzheimer's disease-related dementias conference. *Neurology* 2014;83:851–60.
- [68] Snyder HM, Corriveau RA, Craft S, Faber JE, Greenberg SM, Knopman D, et al. Vascular contributions to cognitive impairment and dementia including Alzheimer's disease. *Alzheimers Dement* 2014;11:710–7.
- [69] Hachinski V. World Stroke Organization. Stroke and potentially preventable dementias proclamation: Updated World Stroke Day Proclamation. *Stroke* 2015;46:3039–40.
- [70] Filippi M, Agosta F, Barkhof F, Dubois B, Fox NC, Frisoni GB, et al. EFNS task force: The use of neuroimaging in the diagnosis of dementia. *Eur J Neurol* 2012;19:e131–40. 1487–501.
- [71] Cunnane S, Nugent S, Roy M, Courchesne-Loyer A, Croteau E, Tremblay S, et al. Brain fuel metabolism, aging, and Alzheimer's disease. *Nutrition* 2011;27:3–20.
- [72] Winkler EA, Nishida Y, Sagare AP, Rege SV, Bell RD, Perlmutter D, et al. GLUT1 reductions exacerbate Alzheimer's disease vasculoneuronal dysfunction and degeneration. *Nat Neurosci* 2015; 18:521–30.
- [73] Zhao Z, Nelson AR, Betsholtz C, Zlokovic BV. Establishment and dysfunction of the blood-brain barrier. *Cell* 2015;163:1064–78.
- [74] Sokoloff L, Reivich M, Kennedy C, Des Rosiers MH, Patlak CS, Pettigrew KD, et al. The [ $^{14}$ C]deoxyglucose method for the measurement of local cerebral glucose utilization: Theory, procedure, and normal values in the conscious and anesthetized albino rat. *J Neurochem* 1977;28:897–916.
- [75] McDougal DB, Ferrendelli JA, Yip V, Pusateri ME, Carter JG, Chi MM, et al. Use of nonradioactive 2-deoxyglucose to study compartmentation of brain glucose metabolism and rapid regional changes in rate. *Proc Natl Acad Sci U S A* 1990; 87:1357–61.
- [76] Rokka J, Grönroos TJ, Viljanen T, Solin O, Haaparanta-Solin M. HPLC and TLC methods for analysis of [(18)F]FDG and its metabolites from biological samples. *J Chromatogr B Analyt Technol Biomed Life Sci* 2017;1048:140–9.
- [77] Sols A, Crane RK. Substrate specificity of brain hexokinase. *J Biol Chem* 1954;210:581–95.
- [78] Southworth R, Parry CR, Parkes HG, Medina RA, Garlick PB. Tissue-specific differences in 2-fluoro-2-deoxyglucose metabolism beyond FDG-6-P: A 19F NMR spectroscopy study in the rat. *NMR Biomed* 2003;16:494–502.
- [79] Hers HG, De Duve C. [The hexosephosphatase system; partition of activity of glucose-6-phosphatase in the tissues]. *Bull Soc Chim Biol (Paris)* 1950;32:20–9.
- [80] Sokoloff L. Measurement of local cerebral glucose utilization and its relation to local functional activity in the brain. *Adv Exp Med Biol* 1991;291:21–42.
- [81] Huang MT, Veech RL. Metabolic fluxes between [ $^{14}$ C]2-deoxy-D-glucose and [ $^{14}$ C]2-deoxy-D-glucose-6-phosphate in brain in vivo. *J Neurochem* 1985;44:567–73.
- [82] Hunt A, Schönknecht P, Henze M, Seidl U, Haberkorn U, Schröder J. Reduced cerebral glucose metabolism in patients at risk for Alzheimer's disease. *Psychiatry Res* 2007;155:147–54.
- [83] Samuraki M, Matsunari I, Chen W-P, Yajima K, Yanase D, Fujikawa A, et al. Partial volume effect-corrected FDG PET and grey matter volume loss in patients with mild Alzheimer's disease. *Eur J Nucl Med Mol Imaging* 2007;34:1658–69.
- [84] Mosconi L, Tsui WH, Herholz K, Pupi A, Drzezga A, Lucignani G, et al. Multicenter standardized 18F-FDG PET diagnosis of mild cognitive impairment, Alzheimer's disease, and other dementias. *J Nucl Med* 2008;49:390–8.
- [85] Landau SM, Harvey D, Madison CM, Koeppe RA, Reiman EM, Foster NL, et al. Associations between cognitive, functional, and FDG-PET measures of decline in AD and MCI. *Neurobiol Aging* 2011;32:1207–18.
- [86] Ossenkoppele R, van der Flier WM, Zwan MD, Adriaanse SF, Boellaard R, Windhorst AD, et al. Differential effect of APOE genotype on amyloid load and glucose metabolism in AD dementia. *Neurology* 2013;80:359–65.
- [87] Protas HD, Chen K, Langbaum JBS, Fleisher AS, Alexander GE, Lee W, et al. Posterior cingulate glucose metabolism, hippocampal glucose metabolism, and hippocampal volume in cognitively normal, late-middle-aged persons at 3 levels of genetic risk for Alzheimer disease. *JAMA Neurol* 2013;70:320–5.
- [88] Mosconi L, Rinne JO, Tsui WH, Murray J, Li Y, Glodzik L, et al. Amyloid and metabolic positron emission tomography imaging of cognitively normal adults with Alzheimer's parents. *Neurobiol Aging* 2013;34:22–34.
- [89] Landau SM, Harvey D, Madison CM, Reiman EM, Foster NL, Aisen PS, et al. Comparing predictors of conversion and decline in mild cognitive impairment. *Neurology* 2010;75:230–8.
- [90] Mosconi L, Sorbi S, de Leon MJ, Li Y, Nacmias B, Myoung PS, et al. Hypometabolism exceeds atrophy in presymptomatic early-onset familial Alzheimer's disease. *J Nucl Med* 2006;47:1778–86.
- [91] Niwa K, Kazama K, Younkin SG, Carlson GA, Iadecola C. Alterations in cerebral blood flow and glucose utilization in mice overexpressing the amyloid precursor protein. *Neurobiol Dis* 2002;9:61–8.
- [92] Piert M, Koeppe RA, Giordani B, Berent S, Kuhl DE. Diminished glucose transport and phosphorylation in Alzheimer's disease determined by dynamic FDG-PET. *J Nucl Med* 1996;37:201–8.
- [93] Jagust WJ, Seab JP, Huesman RH, Valk PE, Mathis CA, Reed BR, et al. Diminished glucose transport in Alzheimer's disease: dynamic PET studies. *J Cereb Blood Flow Metab* 1991;11:323–30.

- [94] Fukuyama H, Kameyama M, Harada K, Nishizawa S, Senda M, Mukai T, et al. Glucose metabolism and rate constants in Alzheimer's disease examined with dynamic positron emission tomography scan. *Acta Neurol Scand* 1989;80:307-13.
- [95] Gejl M, Brock B, Egefjord L, Vang K, Rungby J, Gjedde A. Blood-brain glucose transfer in Alzheimer's disease: Effect of GLP-1 analog treatment. *Sci Rep* 2017;7:17490.
- [96] Simpson IA, Chundu KR, Davies-Hill T, Honer WG, Davies P. Decreased concentrations of GLUT1 and GLUT3 glucose transporters in the brains of patients with Alzheimer's disease. *Ann Neurol* 1994;35:546-51.
- [97] Mooradian AD, Chung HC, Shah GN. GLUT-1 expression in the cerebra of patients with Alzheimer's disease. *Neurobiol Aging* 1997;18:469-74.
- [98] Kalaria RN, Harik SI. Reduced glucose transporter at the blood-brain barrier and in cerebral cortex in Alzheimer disease. *J Neurochem* 1989;53:1083-8.
- [99] Horwood N, Davies DC. Immunolabelling of hippocampal microvessel glucose transporter protein is reduced in Alzheimer's disease. *Virchows Arch Int J Pathol* 1994;425:69-72.
- [100] Iwangoff P, Armbruster R, Enz A, Meier-Ruge W. Glycolytic enzymes from human autoptic brain cortex: Normal aged and demented cases. *Mech Ageing Dev* 1980;14:203-9.
- [101] Bigl M, Brückner MK, Arendt T, Bigl V, Eschrich K. Activities of key glycolytic enzymes in the brains of patients with Alzheimer's disease. *J Neural Transm (Vienna)* 1996;1999:499-511.
- [102] Kilbourn MR. Small molecule PET tracers for transporter imaging. *Semin Nucl Med* 2017;47:536-52.
- [103] Wardlaw JM, Smith C, Dichgans M. Mechanisms of sporadic cerebral small vessel disease: Insights from neuroimaging. *Lancet Neurol* 2013;12:483-97.
- [104] Sposato LA, Kapral MK, Fang J, Gill SS, Hackam DG, Cipriano LE, et al. Declining incidence of stroke and dementia: Coincidence or prevention opportunity? *JAMA Neurol* 2015;72:1529-31.
- [105] Azarpazhooh MR, Avan A, Cipriano LE, Munoz DG, Sposato LA, Hachinski V. Concomitant vascular and neurodegenerative pathologies double the risk of dementia. *Alzheimers Dement* 2018;14:148-56.
- [106] Arenaza-Urquijo EM, Vemuri P. Resistance vs resilience to Alzheimer disease: Clarifying terminology for preclinical studies. *Neurology* 2018;90:695-703.