



Universiteit
Leiden
The Netherlands

Subretinal fluid morphology in chronic central serous chorioretinopathy and its relationship to treatment: a retrospective analysis on PLACE trial data

Subhi, Y.; Bjerager, J.; Boon, C.J.F.; Dijk, E.H.C. van

Citation

Subhi, Y., Bjerager, J., Boon, C. J. F., & Dijk, E. H. C. van. (2021). Subretinal fluid morphology in chronic central serous chorioretinopathy and its relationship to treatment: a retrospective analysis on PLACE trial data. *Acta Ophthalmologica*, 100(1), 89-95.
doi:10.1111/aos.14901

Version: Publisher's Version
License: [Creative Commons CC BY-NC-ND 4.0 license](https://creativecommons.org/licenses/by-nc-nd/4.0/)
Downloaded from: <https://hdl.handle.net/1887/3627482>

Note: To cite this publication please use the final published version (if applicable).

Subretinal fluid morphology in chronic central serous chorioretinopathy and its relationship to treatment: a retrospective analysis on PLACE trial data

Yousif Subhi,^{1,2} Jakob Bjerager,¹ Camiel J.F. Boon^{3,4} and Elon H.C. van Dijk³

¹Department of Ophthalmology, Rigshospitalet-Glostrup, Copenhagen, Denmark

²Department of Ophthalmology, Zealand University Hospital, Roskilde, Denmark

³Department of Ophthalmology, Leiden University Medical Center, Leiden, the Netherlands

⁴Department of Ophthalmology, Amsterdam University Medical Centers, University of Amsterdam, the Netherlands

ABSTRACT.

Purpose: To explore subretinal fluid (SRF) morphology in chronic central serous chorioretinopathy (cCSC) after one session of either high-density subthreshold micropulse laser (HSML) treatment or half-dose photodynamic therapy (PDT).

Methods: We retrospectively obtained optical coherence tomography (OCT) scans from a subset of patients from a randomized controlled trial on treatment-naïve eyes with cCSC allocated to either HSML treatment or half-dose PDT. OCT scans were evaluated prior to treatment and 6–8 weeks post-treatment, where we measured maximum SRF height and width, calculated the *maximum height-to-maximum width-ratio* (maxHWR) and calculated the total SRF volume.

Results: Forty-one eyes of 39 cCSC patients were included. SRF morphology ranged from flat to dome-shaped, quantified as maxHWR ranging between 0.02 and 0.12. SRF volume was median 0.373 μl (range: 0.010–4.425 μl) and did not correlate to maxHWR ($\rho = -0.004$, $p = 0.982$). Half-dose PDT was superior to HSML treatment in complete SRF resolution (RR = 3.28, $p = 0.003$) and in morphological changes of SRF ($\Delta_{\text{maximum height}}$, $p = 0.001$; $\Delta_{\text{maximum width}}$, $p < 0.001$; Δ_{volume} , $p = 0.025$). SRF resolved completely in 19/22 PDT-treated eyes (86%) and 5/19 HSML-treated eyes (26%). SRF volume increased in five eyes (26%) after HSML treatment, and in none of the eyes after half-dose PDT. SRF morphology at baseline did not predict treatment outcomes.

Conclusion: SRF morphology changed after both HSML treatment and half-dose PDT in cCSC, with SRF disappearing in most PDT-treated patients, whereas SRF volume increased in a sizeable proportion of HSML-treated patients. Baseline SRF characteristics measured in this study were unable to predict outcomes after either HSML treatment or half-dose PDT.

Key words: central serous chorioretinopathy – imaging – optical coherence tomography – subretinal fluid – volume analysis

Funding: This research was supported by the Stichting Blindenhulp, Mathilde Grant, Stichting Leids Oogheelkundig Ondersteuningsfonds, Rotterdamse Stichting Blindenbelangen, Stichting Ooglijders, Stichting tot Verbetering van het Lot der Blinden, and the Netherlands Organisation for Scientific Research (NWO). The funding organizations Macula Fonds, Retina Nederland Onderzoek Fonds, Landelijke Stichting voor Blinden en Slechtienden, Algemene Nederlandse Vereniging ter Voorkoming van Blindheid, and Stichting Blinden-Penning contributed through UitZicht. The aforementioned founding funding sources provided unrestricted grants and had no role in the design or conduct of this research.

Acta Ophthalmol. 2022; 100: 89–95

© 2021 The Authors. Acta Ophthalmologica published by John Wiley & Sons Ltd on behalf of Acta Ophthalmologica Scandinavica Foundation

This is an open access article under the terms of the Creative Commons Attribution-NonCommercial-NoDerivs License, which permits use and distribution in any medium, provided the original work is properly cited, the use is non-commercial and no modifications or adaptations are made.

doi: 10.1111/aos.14901

Introduction

Central serous chorioretinopathy (CSC) is a common chorioretinal disease and an important cause of loss of central vision. Its key clinical manifestation is the accumulation of subretinal fluid (SRF) in the macula and it is etiologically linked to dysfunction of the blood-retina barrier, that is leakage from the choroid and defects in the retinal pigment epithelium (Daruich et al. 2015). The incidence of CSC peaks at age 30–50 years and is up to eight times more prevalent among males (Kitzmann et al. 2008). The disease has been associated with corticosteroid use, stressful life or endogenous hypercortisolism, and a certain genetic predisposition (Daruich et al. 2015; van Dijk et al. 2016; van Dijk et al. 2017; Schellevis et al. 2019; van Dijk et al. 2019; van Rijssen et al. 2019c; Mohabati et al. 2020). Acute CSC cases are often observed, in which SRF usually spontaneously regresses in typically 3–4 months, without the need of treatment (van Rijssen et al. 2019c). Chronic CSC (cCSC) is considered to require treatment, because chronic persistence of SRF leads to progressive photoreceptor damage and vision loss, which in turn significantly impairs the quality of life of the patients (Breukink et al. 2016). It is currently unknown if acute CSC and cCSC are either a

continuum or different disease entities, despite being part of the same pachy-choroid disease spectrum, with overlapping genetic risk factors (Cheung et al. 2019; van Rijssen et al. 2019c; Mohabati et al. 2020).

For cCSC, several treatment options are available (van Rijssen et al. 2019c). Treatments that are most often prescribed are half-dose or half-fluence photodynamic therapy (PDT), oral mineralocorticoid antagonist treatment (eplerenone or spironolactone), and high-density subthreshold micropulse laser (HSML) treatment. In the first randomized controlled treatment trial studying the efficacy of oral eplerenone treatment versus placebo, eplerenone was not superior to placebo (Lotery et al. 2020). The half-dose PDT versus high-density subthreshold micropulse laser treatment in patients with chronic central serous chorioretinopathy (PLACE) trial was the first large investigator-initiated multicentre randomized controlled trial in cCSC, comparing half-dose PDT to HSML as a treatment for treatment-naïve cCSC patients (Breukink et al. 2015; van Dijk et al. 2018). The PLACE trial showed that half-dose PDT was superior to HSML treatment in achieving a complete resolution of SRF on optical coherence tomography (OCT) as well as change in retinal sensitivity on microperimetry (van Dijk et al. 2018). To date, little is known on how SRF morphology changes with treatment, and whether SRF morphology at baseline can predict SRF morphology after treatment.

In this study, we obtained data from a subsample of the PLACE trial and analysed OCT data for SRF morphology using both two- and three-dimensional measures of SRF. We then compared the treatment effects of one session of half-dose PDT to one session of HSML treatment.

Methods

Study design

This was a retrospective clinical study based on the data that were collected prospectively in the PLACE trial (ClinicalTrials.gov: NCT01797861, EudraCT: 2012-004555-36). The PLACE trial was an investigator-initiated, open-label, multicentre, randomized controlled trial, which compared half-dose PDT to

HSML treatment (Breukink et al. 2015; van Dijk et al. 2018). Informed consent was obtained from all participants. Institutional review board approval was obtained from all participating centres and all aspects of this study adhered to the tenets of the Declaration of Helsinki. Details of the study design are available in the previously published protocol (Breukink et al. 2015). For the current study, we obtained data from one study centre (Leiden University Medical Center, Leiden, the Netherlands). We only included data from eyes of which the available OCT scans contained the entire area of SRF accumulation. This was to allow accurate estimates of SRF morphology, especially in terms of SRF width and SRF volume which otherwise would be impossible if only a part of the SRF was visible on the available OCT scan. No meaningful *a priori* power calculation was possible for this exploratory imaging study.

Eligibility of participants and eyes

The PLACE trial included adults with cCSC. In brief, for inclusion in the PLACE trial, visual symptoms had to be present for at least six weeks, in combination with presence of SRF including the fovea on OCT, hyperfluorescent changes typical of cCSC on indocyanine green angiography (ICGA), and one or more ill-defined hyperfluorescent leakage areas on fluorescein angiography (FA) with retinal pigment epithelium window defect(s) compatible with cCSC (Breukink et al. 2015). Eyes were excluded in case of previous treatment for active CSC, recent (defined as current or within three months before the baseline visit of the current study) use of either topical or systemic corticosteroids, presence of SRF that could have been caused by other ocular diseases, best-corrected visual acuity (BCVA) of Snellen 20/200 or worse, profound central chorioretinal atrophy, myopia of six diopters or more, continuous and/or progressive visual loss for more than 18 months or serous detachment on OCT for more than 18 months, presence of intraretinal fluid, contraindications for any procedures related to the study, presence of soft drusen in treated or follow eye or any macular neovascularization (Breukink et al. 2015; van Dijk et al. 2018).

Treatment and follow-up evaluation

Eligible patients were randomly assigned to either half-dose PDT or HSML treatment. The area to be treated was determined by a central reading centre and was based on the hyperfluorescent changes on ICGA (Breukink et al. 2015; van Dijk et al. 2018). This approach was used because ICGA-guided therapy targets the primary affected tissue (the choroid) in CSC, while decreasing the risk of undertreatment because ICGA generally reveals more extensive abnormalities compared to FA (van Rijssen et al. 2019a; van Rijssen et al. 2019b). Overlying focal area(s) of leakage on FA, which generally correspond to SRF accumulation on OCT, were always included in the treatment area. Specific details regarding half-dose PDT and HSML treatment are described in detail elsewhere (Breukink et al. 2015; van Dijk et al. 2018; van Rijssen et al. 2020).

Prior to therapy, patients were examined using BCVA using Early Treatment of Diabetic Retinopathy Study (ETDRS) charts, retinal microperimetry, a quality of life questionnaire, ophthalmoscopy, fundus photography, fundus autofluorescence, retinal OCT, FA, and ICGA (Breukink et al. 2015; van Dijk et al. 2018). Importantly for this study, these examinations included a macular OCT using the Heidelberg HRA-Spectralis Special Domain (Heidelberg Engineering, Heidelberg, Germany) with the enhanced-depth imaging mode used to capture at least 25 B-scans with a 20° × 20° field (Breukink et al. 2015; van Dijk et al. 2018). This scan was performed with the use of the high-resolution module. Each B-scan in this mode consisted of a minimum of 20 averaged scans (ART) and is registered over the infrared reflectance image. OCT imaging was performed at baseline and 6–8 weeks after either HSML treatment or half-dose PDT (Breukink et al. 2015; van Dijk et al. 2018).

Morphological analysis of the subretinal fluid

All individual OCT scans of each eye were measured for SRF height and SRF width (Fig. 1). Within one stack of OCT scans, we scrolled through the OCT scans to measure the SRF width

from left to right, and measured the visually observed highest point of SRF height (from retinal pigment epithelium layer to photoreceptor layer). The highest measured values of SRF height and SRF width within the OCT scans were defined as the maximum SRF height and the maximum SRF width, respectively. We then used these measures to calculate the SRF *maximum height-to-maximum width-ratio* (maxHWR). We used a previously described method to calculate the volume of the SRF (Subhi & Sørensen 2018). Briefly, we extracted OCT images to an image processing program, identified SRF as regions of interest whereby such regions were coloured manually, and imported these images to an image-stack using IMAGEJ version 1.51a (<http://www.imagej.net>) (National Institute of Mental Health, Bethesda, MA, USA) (Schneider et al. 2012). Here, coloured regions of interests in stack images can be extrapolated into volumes using the plug-in MEASURE STACK version 1 (OptiNav Inc., Bellevue, Washington, USA) if the distance between the images is known (Fig. 1). The exact distance between the images was extracted for each scan from the Heidelberg Eye Explorer software (Heidelberg Engineering, Heidelberg, Germany).

Data analysis and statistics

We first explored the relationships between maximum SRF height, maximum SRF width, maxHWR and SRF volume in treatment-naïve cCSC eyes. BCVA was converted from ETDRS letters to logMAR and used for correlation studies to the measured morphological variables. Then, we evaluated the treatment effect on SRF morphology. Finally, we compared SRF morphology change after one session of treatment with HSML treatment versus one session of treatment with half-dose PDT. Categorical values were reported in numbers and percentages. Continuous variables were reported in mean and standard deviation (SD) and compared using parametric tests if normal distribution was present, otherwise these non-normally distributed variables were reported in median and interquartile range (IQR) and compared using non-parametric tests. Correlation analyses were made using Pearson’s correlation if both variables were normally distributed, otherwise Spearman’s correlation was employed. All statistical analyses were made using IBM SPSS 26 (IBM, Armonk, NY, USA). Figures were made using GRAPH-PAD PRISM 9.0.0 (GraphPad Software, La Jolla, CA, USA). p values < 0.05 were considered statistically significant.

Results

Study sample

We screened data from 72 eyes of 61 cCSC patients, of which 41 eyes (39 patients) fulfilled the eligibility criteria for this study. Nineteen eyes (18 patients) were allocated to the HSML treatment, and 22 eyes (21 patients) to half-dose PDT. Patient characteristics did not differ significantly between the study groups (Table 1).

Morphology of subretinal fluid at baseline

Looking at all 41 eyes, we measured a mean maximum SRF height of 185 µm (SD: 102 µm, range: 36–582 µm) and a mean maximum SRF width of 2942 µm (SD: 1399 µm, range 798–6471 µm). The interrelationship between maximum height and maximum width was quantified by looking at the maxHWR, which when low indicates a flatter SRF and when high indicates more dome-shaped SRF (Fig. 2). This unit-free measure had a mean of 0.07 (SD: 0.03) and ranged from 0.02 to 0.12, exhibiting that SRF accumulation in cCSC is subject to a certain morphological variation. We observed a moderate correlation between the maxHWR and both the maximum SRF height ($\rho = 0.381$, $p = 0.014$, Pearson’s correlation) and maximum SRF width ($\rho = -0.345$, $p = 0.027$, Pearson’s correlation) (Fig. 2).

The SRF volume was measured to be a median of 0.373 µl (IQR: 0.133–0.881 µl, range 0.010–4.425 µl). Although SRF volumes strongly correlated with both maximum SRF height ($\rho = 0.838$, $p < 0.001$, Spearman’s correlation) and maximum SRF width ($\rho = 0.868$, $p < 0.001$, Spearman’s correlation), no correlation was observed to the maxHWR ($\rho = -0.004$, $p = 0.982$, Spearman’s correlation) (Fig. 3).

The BCVA at baseline did not correlate significantly with the maximum SRF height ($\rho = 0.055$, $p = 0.734$, Pearson’s correlation), the maximum SRF width ($\rho = -0.102$, $p = 0.527$, Pearson’s correlation), the maxHWR ($\rho = 0.025$, $p = 0.879$, Spearman’s correlation), and the SRF volume ($\rho = -0.029$, $p = 0.858$, Pearson’s correlation).

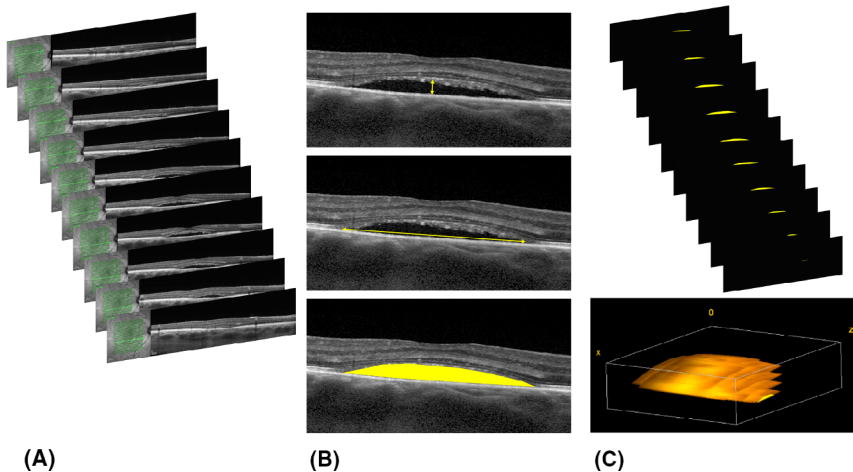


Figure 1. Methodological approach to measuring subretinal fluid morphology in a chronic central serous chorioretinopathy patient. (A) We imported a stack of images of optical coherence tomography scans with subretinal fluid (SRF). (B) Each scan was measured for SRF height (top), SRF width (middle) and SRF area for volume calculation (bottom). From the measured SRF heights and widths, highest values were noted for the measures of maximum SRF height and maximum SRF width. (C) By summarizing the SRF areas in each scan and with the distance between the scans known, it is possible to estimate the three-dimensional structure of the SRF and to calculate its volume.

Table 1. Characteristics of study groups at baseline.

	HSML treatment group (N = 19 eyes)	Half-dose PDT group (N = 22 eyes)	p value
Demographics			
Age, years, mean (SD)	48.4 (7.8)	47.5 (7.6)	0.69*
Male gender, N (%)	17 (89%)	21 (95%)	0.46 [†]
SRF characteristics at baseline			
Maximum height, μm , mean (SD)	175 (76)	194 (122)	0.54*
Maximum width, μm , mean (SD)	2.834 (1.552)	3.036 (1.282)	0.66*
MaxHWR, median (IQR)	0.07 (0.06–0.09)	0.07 (0.05–0.08)	0.51 [‡]
Volume, μl , median (IQR)	0.387 (0.178–0.874)	0.352 (0.111–0.888)	0.92 [‡]
BCVA at baseline, logMAR, mean (SD)	0.10 (0.20)	0.15 (0.16)	0.44*

BCVA = best-corrected visual acuity; HSML = high-density subthreshold micropulse laser; IQR = interquartile range; MaxHWR = maximum height-to-maximum width-ratio; N = number; PDT = photodynamic therapy; SD = standard deviation; SRF = subretinal fluid.

* Independent samples *t*-test.

[†] χ^2 -test.

[‡] Mann–Whitney *U*-test.

Treatment effect on subretinal fluid morphology

One session of treatment resulted in complete SRF resolution in a total of 24 out of 41 eyes (59%); in 19 out of 22 eyes treated with half-dose PDT (86%), and in five out of 19 eyes treated with HSML treatment (26%). This difference in favour of half-dose PDT was statistically significant (RR = 3.28, 95% CI: 1.52–7.09, $p = 0.003$). Differences in SRF morphology characteristics between half-dose PDT treatment

and HSML treatment were statistically significant in favour of half-dose PDT for all measured parameters (Fig. 4).

In the half-dose PDT group, the three eyes without complete SRF resolution had all experienced a reduction in SRF, quantified as a decrease in SRF maximum height (cases: $-60 \mu\text{m}$, $-216 \mu\text{m}$, $-510 \mu\text{m}$), a decrease in SRF maximum width (cases: $-286 \mu\text{m}$, $-2749 \mu\text{m}$, $-3588 \mu\text{m}$), and a decrease in SRF volume (cases: $-0.025 \mu\text{l}$, $-0.890 \mu\text{l}$, $-4347 \mu\text{l}$). The

maxHWR decreased in all cases (cases: -0.02 , -0.02 , -0.07). The case with the largest SRF volume decrease was also the case with the largest maxHWR decrease.

Out of the 14 remaining eyes without complete SRF resolution on OCT in the HSML treatment group, eight (57%) experienced a decrease in SRF accumulation ($\Delta_{\text{maximum height}}$ median $-52 \mu\text{m}$ (IQR: -32 to $-119 \mu\text{m}$), $\Delta_{\text{maximum width}}$ median $-393 \mu\text{m}$ (IQR: -195 to $-1401 \mu\text{m}$), Δ_{volume} median $-0.195 \mu\text{l}$ (IQR: -0.037 to $-0.525 \mu\text{l}$)), one (7 %) did not experience any significant change ($\Delta_{\text{maximum height}}$ $-1 \mu\text{m}$, $\Delta_{\text{maximum width}}$ $-6 \mu\text{m}$, Δ_{volume} $0.000 \mu\text{l}$); and five (36%) experienced SRF increase ($\Delta_{\text{maximum height}}$ median $50 \mu\text{m}$ (IQR: 27 to $84 \mu\text{m}$), $\Delta_{\text{maximum width}}$ median $497 \mu\text{m}$ (IQR: 214 to $841 \mu\text{m}$), Δ_{volume} median $0.717 \mu\text{l}$ (IQR: 0.093 to $0.845 \mu\text{l}$)). The Δ_{maxHWR} decreased in six out of seven (86%) eyes with SRF volume decrease (median -0.01 ; IQR: -0.02 to -0.002), decreased very slightly (-0.0004) in the only eye without any significant change in SRF volume, and increased in all five eyes with SRF volume increase (median 0.003 ; IQR: 0.0006 – 0.02).

Across groups, change in BCVA from baseline to first follow-up (Δ_{BCVA}) correlated significantly with $\Delta_{\text{maximum height}}$ ($\rho = 0.310$, $p = 0.048$, Spearman's correlation), $\Delta_{\text{maximum width}}$

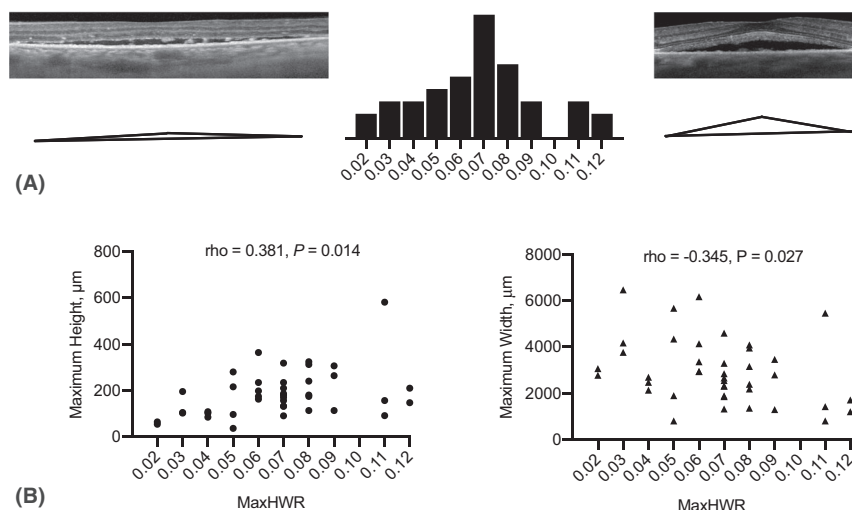


Figure 2. The maximum height-to-maximum width-ratio of subretinal fluids in chronic central serous chorioretinopathy patients. (A) A histogram of the calculated maximum height-to-maximum width-ratio (maxHWR) in this study highlights the morphological variation of subretinal fluid (SRF) in chronic central serous chorioretinopathy. As shown here on the left, a low maxHWR indicates relatively flatter SRF, whereas the example on the right shows a case of high maxHWR with relatively more dome-shaped SRF. (B) A strict correlation between maxHWR and the maximum height or the maximum width would indicate that the variation of maxHWR was strictly a question of SRF size. However, correlation analyses using Pearson's correlation indicated that maxHWR only moderately correlated with the maximum SRF height and the maximum SRF width.

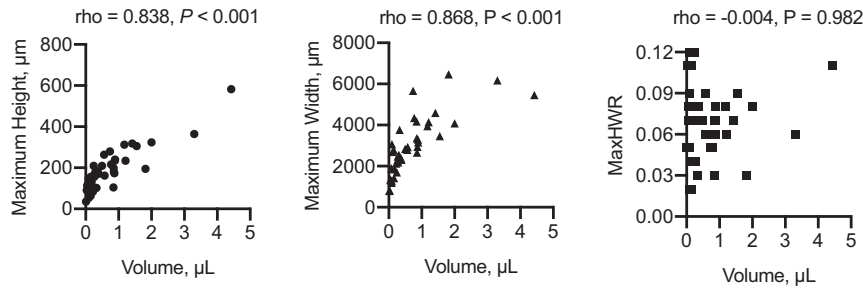


Figure 3. Correlation analyses using Spearman's correlation between the subretinal fluid (SRF) volume and the maximum height (left), the maximum width (middle), and the *maximum height-to-maximum width-ratio* (maxHWR; right). SRF volume strongly correlated with maximum SRF height and maximum SRF width, whereas no correlation was observed to the maxHWR

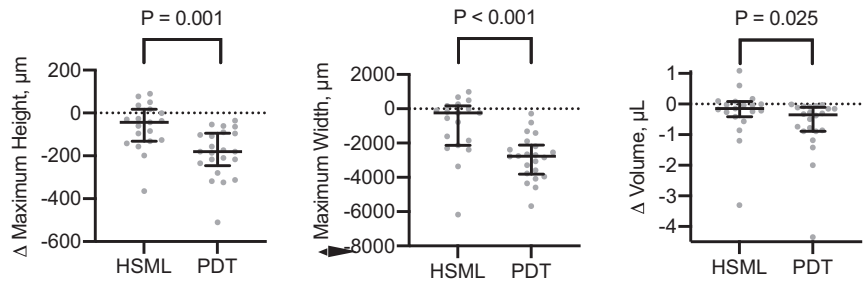


Figure 4. Comparison of treatment-associated change in subretinal fluid (SRF) after one session of high-density subthreshold micropulse laser (HSML) treatment versus one session of half-dose photodynamic therapy (PDT). Individual data are annotated in grey dots, summarized in black bars and whiskers representing the median and the interquartile range, and comparisons are made using the Mann–Whitney *U*-test. We conclude that characteristics of SRF morphology (maximum height, maximum width, and volume) all improve significantly after half-dose PDT as opposed to HSML treatment.

(rho = 0.493, p = 0.001, Spearman's correlation) and Δ_{volume} (rho = 0.339, p = 0.030, Spearman's correlation), but not Δ_{maxHWR} (rho = -0.196, p = 0.450, Spearman's correlation). Since BCVA is analysed in logMAR, these correlations state that a decrease in SRF height, SRF width or SRF volume correlate with an improvement in BCVA (Fig. 5).

We did not find any convincing evidence of a predictive value of the measured SRF morphology characteristics at baseline, since none of the

measures were clearly associated with complete SRF resolution after treatment (Table 2).

Discussion

In this study, we explored SRF morphology in cCSC using OCT scans from one centre in the PLACE trial. We document the extent of the variation of SRF morphology in cCSC when quantified as maximum height, maximum width, maxHWR, and volume. We found that documenting SRF

morphology gives a more detailed insight into changes after treatment. A key finding of this study is that HSML treatment is not only associated with a higher proportion of cases without complete SRF resolution as compared to half-dose PDT, which was previously known (van Dijk et al. 2018), but also to a quantifiable SRF increase in five out of 19 eyes (26%). Hence, HSML treatment often did not provide the desired treatment effect, but even increased the SRF volume in a significant proportion of patients. This

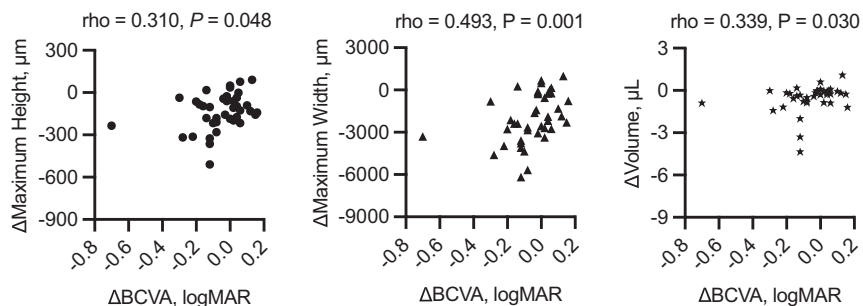


Figure 5. Correlation analyses using Spearman's correlation between the change in best-corrected visual acuity and the change in subretinal fluid (SRF) maximum height (left), change in SRF maximum width (middle) and change in SRF volume. Change in BCVA correlated significantly with change in SRF maximum height, change in SRF maximum width, and change in SRF volume, and the correlation was strongest to the change in SRF maximum width.

Table 2. Comparison of baseline subretinal fluid morphology characteristics between chronic central serous chorioretinopathy patients who did and those who did not experience complete resolution of the subretinal fluid after treatment.

	Complete resolution of SRF after treatment	No complete resolution of SRF after treatment	p value
<i>Eyes allocated to HSML treatment</i>	<i>N = 5</i>	<i>N = 14</i>	
Maximum height, μm , mean (SD)	170 (66)	187 (107)	0.76*
Maximum width, μm , mean (SD)	2717 (1519)	3161 (1777)	0.64*
MaxHWR, median (IQR)	0.08 (0.06–0.09)	0.06 (0.06–0.07)	0.34 [†]
Volume, μl , median (IQR)	0.475 (0.088–0.874)	0.265 (0.219–0.854)	0.89 [†]
<i>Eyes allocated to half-dose PDT</i>	<i>N = 19</i>	<i>N = 3</i>	
Maximum height, μm , mean (SD)	175 (91)	318 (235)	0.40*
Maximum width, μm , mean (SD)	2.962 (1.229)	3.501 (1.812)	0.66*
MaxHWR, median (IQR)	0.08 (0.07–0.11)	0.07 (0.05–0.08)	0.16 [†]
Volume, μl , median (IQR)	0.893 (0.088–4.425)	0.330 (0.111–0.861)	0.41 [†]

HSML = high-density subthreshold micropulse laser; IQR = interquartile range; MaxHWR = maximum height to maximum width ratio; PDT = photodynamic therapy; SD = standard deviation; SRF = subretinal fluid.

* Independent samples *t*-test.

[†] Mann–Whitney *U*-test.

was in contrast to half-dose PDT, which has been found to lead to either SRF resolution (in 86%) or SRF volume decrease (in 14%).

Our study also revealed further structural insight into the SRF dynamics after HSML treatment and half-dose PDT. A single session of half-dose PDT resulted in a complete SRF resolution in all but three eyes. In the remaining three eyes, SRF volume decreased, in a fashion where the SRF decrease lead to a flatter SRF structure, that is a decrease in both SRF maximum height and SRF maximum width but with a relatively stronger decrease in SRF maximum height leading to a lower maxHWR. For the HSML-treated patients, we saw a similar pattern in that an SRF volume decrease leads to a lower maxHWR and therefore a flatter SRF structure in all but one eye. However, this group also had eyes with SRF volume increase, wherein the SRF obtained a higher maxHWR and therefore a more dome-shaped structure.

The clinical importance of these SRF dynamics in relation to therapy in cCSC remains largely unknown and warrants further studies. Of

importance, our correlation analyses revealed that a BCVA improvement after therapy was correlated with a reduction of SRF maximum height, SRF maximum width, and SRF volume. Interestingly, the correlation coefficient was ~ 0.3 for $\Delta_{\text{maximum height}}$ and Δ_{volume} , which indicate a low/small correlation, whereas the correlation coefficient was ~ 0.5 for $\Delta_{\text{maximum width}}$, which indicates a moderate correlation. Thus, our study suggests that an improvement of the SRF width may have a larger influence on the BCVA than the improvement of either SRF height or SRF volume.

From a morphological point of view, it was not possible to predict the treatment outcome for either HSML treatment or half-dose PDT using baseline SRF morphology, and it was not possible to provide a clinically meaningful quantity of expected SRF regression after one session of either half-dose PDT or HSML treatment. This indicates that it may be difficult to predict the efficacy of treatment based on SRF morphology characteristics on OCT.

Strengths and limitations of this study should be kept in mind when

interpreting its results. First, although the PLACE trial was a randomized controlled trial, the current study was designed after the trial, and is therefore retrospective in nature. The area of the OCT scans performed in each eyes was not designed according to whether or not they would suffice for this study. Because of this, we were unable to include patients with very large areas of SRF accumulation, because they extended beyond the scan area. Second, because of practical reasons, this study only had access to a subsample through a single site of the multicentre PLACE trial, which is a limitation. However, all centres in the PLACE trial used the same in- and exclusion criteria (Breukink et al. 2015; van Dijk et al. 2018), and there did not appear to be site-specific selection bias between the groups. Third, our morphological study was exploratory and not sampled according to a power calculation. We cannot exclude the possibility that a study with a larger sample would be able to find a significant predictive ability of treatment response based on the measured SRF morphology characteristics. Finally, our study delineated SRF morphology based on four parameters, and we extrapolate our understanding of SRF morphology based on these parameters, which is also a limitation. Therefore, we can only speculate on the (lack of) predictability on the measures we have investigated but cannot fully rule out that potentially other SRF morphological parameters not considered in this study may possess predictive abilities. Hence, further imaging studies are warranted.

In conclusion, we here document the extent of SRF morphology in cCSC, and explore changes after a single session of either HSML treatment or half-dose PDT. Analysis of SRF morphology revealed that a significant proportion of HSML-treated cCSC patients have a persistent or even increased SRF volume after treatment, while half-dose PDT induces a complete resolution of SRF in the vast majority of patients.

References

Breukink MB, Dingemans AJ, den Hollander AI et al. (2016): Chronic central serous chorioretinopathy: long-term follow-up and

- vision-related quality of life. *Clin Ophthalmol* **11**: 39–46.
- Breukink MB, Downes SM, Querques G et al. (2015): Comparing half-dose photodynamic therapy with high-density subthreshold micropulse laser treatment in patients with chronic central serous chorioretinopathy (the PLACE trial): study protocol for a randomized controlled trial. *Trials* **16**: 419.
- Cheung CMG, Lee WK, Koizumi H, Dansingani K, Lai TYY & Freund KB (2019): Pachychoroid disease. *Eye* **33**: 14–33.
- Daruich A, Matet A, Dirani A, Bousquet E, Zhao M, Farman N, Jaisser F & Behar-Cohen F (2015): Central serous chorioretinopathy: recent findings and new physiopathology hypothesis. *Prog Retin Eye Res* **48**: 82–118.
- Kitzmann AS, Pulido JS, Diehl NN, Hodge DO & Burke JP (2008): The incidence of central serous chorioretinopathy in Olmsted County, Minnesota, 1980–2002. *Ophthalmology* **115**: 169–173.
- Lotery A, Sivaprasad S, O'Connell A et al. (2020): Eplerenone for chronic central serous chorioretinopathy in patients with active, previously untreated disease for more than 4 months (VICI): a randomised, double-blind, placebo-controlled trial. *Lancet* **395**: 294–303.
- Mohabati D, Schellevis RL, van Dijk EHC et al. (2020): Genetic risk factors in severe, nonsevere and acute phenotypes of central serous chorioretinopathy. *Retina* **40**: 1734–1741.
- Schellevis RL, van Dijk EHC, Breukink MB et al. (2019): Exome sequencing in families with chronic central serous chorioretinopathy. *Mol Genet Genomic Med* **7**: e00576.
- Schneider CA, Rasband WS & Eliceiri KW (2012): NIH Image to ImageJ: 25 years of image analysis. *Nat Methods* **9**: 671–675.
- Subhi Y & Sørensen TL (2018): Three-dimensional visualization and volume quantification of pigment epithelium detachments. *Acta Ophthalmol* **96**: e747–e749.
- van Dijk EH, Dijkman G, Biermasz NR, van Haalen FM, Pereira AM & Boon CJ (2016): Chronic central serous chorioretinopathy as a presenting symptom of Cushing syndrome. *Eur J Ophthalmol* **26**: 442–448.
- van Dijk EHC, Fauser S, Breukink MB et al. (2018): Half-dose photodynamic therapy versus high-density subthreshold micropulse laser treatment in patients with chronic central serous chorioretinopathy: the PLACE trial. *Ophthalmology* **125**: 1547–1555.
- van Dijk EHC, Schellevis RL, Breukink MB et al. (2019): Familial central serous chorioretinopathy. *Retina* **39**: 398–407.
- van Dijk EHC, Schellevis RL, van Bergen MGJM et al. (2017): Association of a haplotype in the NR3C2 gene, encoding the mineralocorticoid receptor, with chronic central serous chorioretinopathy. *JAMA Ophthalmol* **135**: 446–451.
- van Rijssen TJ, van Dijk EHC, Scholz P et al. (2019a): Focal and diffuse chronic central serous chorioretinopathy treated with half-dose photodynamic therapy or subthreshold micropulse laser: PLACE trial report No. 3. *Am J Ophthalmol* **205**: 1–10.
- van Rijssen TJ, van Dijk EHC, Scholz P et al. (2019b): Patient characteristics of untreated chronic central serous chorioretinopathy patients with focal versus diffuse leakage. *Graefes Arch Clin Exp Ophthalmol* **257**: 1419–1425.
- van Rijssen TJ, van Dijk EHC, Scholz P et al. (2020): Reply to comment on: focal and diffuse chronic central serous chorioretinopathy treated with half-dose photodynamic therapy or subthreshold micropulse laser: PLACE trial report No. 3. *Am J Ophthalmol* **212**: 187–188.
- van Rijssen TJ, van Dijk EHC, Yzer S et al. (2019c): Central serous chorioretinopathy: towards an evidence-based treatment guideline. *Prog Retin Eye Res* **73**: 100770.

Received on March 7th, 2021.
Accepted on April 18th, 2021.

**Correspondence*

Elon H.C. van Dijk
Department of Ophthalmology
Leiden University Medical Center
P. O. Box 9600
2300 RC Leiden
the Netherlands
Tel: 071-5262374
Fax: 071-5266576
Email: ehcvandijk@lumc.nl

Acknowledgements: None.