



**Universiteit  
Leiden**  
The Netherlands

## **Nikolay Ivanovich Pirogov (1810-1881) anatomical research to develop surgery**

Hendriks, I.F.; Zhuravlev, D.A.; Bovill, J.G.; Boer, F.; Gaivoronskii, I.V.; Hogendoorn, P.C.W.; DeRuiter, M.C.

### **Citation**

Hendriks, I. F., Zhuravlev, D. A., Bovill, J. G., Boer, F., Gaivoronskii, I. V., Hogendoorn, P. C. W., & DeRuiter, M. C. (2020). Nikolay Ivanovich Pirogov (1810-1881): anatomical research to develop surgery. *Clinical Anatomy*, 33(5), 714-730. doi:10.1002/ca.23493

Version: Publisher's Version

License: [Creative Commons CC BY-NC-ND 4.0 license](https://creativecommons.org/licenses/by-nc-nd/4.0/)

Downloaded from: <https://hdl.handle.net/1887/3627010>

**Note:** To cite this publication please use the final published version (if applicable).

## ORIGINAL COMMUNICATION

# Nikolay Ivanovich Pirogov (1810–1881): Anatomical Research to Develop Surgery

I.F. HENDRIKS <sup>1\*</sup> D.A. ZHURAVLEV <sup>2</sup> J.G. BOVILL <sup>3</sup> F. BOER <sup>3</sup>  
I.V. GAIVORONSKII <sup>4</sup> P.C.W. HOGENDOORN <sup>1</sup> AND M.C. DERUITER <sup>5</sup>

<sup>1</sup>Department of the Executive Board, Leiden University Medical Center, Leiden, The Netherlands

<sup>2</sup>Department Executive Board, Voенno-Meditsinskoe Museum, St. Petersburg, Russian Federation

<sup>3</sup>Department of Anaesthesiology, Leiden University Medical Center, Leiden, The Netherlands

<sup>4</sup>Department of Anatomy, Voенno-Meditsinskaya Academy, St. Petersburg, Russian Federation

<sup>5</sup>Department Anatomy and Embryology, Leiden University Medical Center, Leiden, The Netherlands

The 19th century Russian surgeon Nikolay Ivanovich Pirogov believed passionately in the importance of anatomy for surgeons. His interest in anatomy began as a medical student in Moscow. After graduating in 1828 Pirogov entered the postgraduate German-Baltic University of Dorpat (now Tartu in the Republic of Estonia) where he studied anatomy and surgery. After completing his study, he remained to research the consequences of ligation of the aorta in a series of animal experiments, which formed the core of his doctoral thesis. He wanted to determine the feasibility of aortic ligation as a treatment for patients with an aneurysm of the aorta or iliac artery. He discovered that success was only likely when the aorta was ligated between the two mesenteric arteries and the ligature gradually tightened, an approach surgically difficult in humans. Pirogov then spent 2 years at the Charité Hospital in Berlin before returning to Russia. In 1841, he was appointed Professor of Applied Anatomy and Surgery at the Imperial Medico-Surgical Academy in Saint Petersburg. He instituted the teaching of microscopy and histology to the medical curriculum and in 1846 formed the Institute for Applied Anatomy within the academy, where in addition to teaching medical students future teachers of anatomy in Russia were trained. Pirogov published extensively on anatomy, including several anatomical atlases, the most notable his three-dimensional atlas of topographical anatomy published in four volumes between 1852 and 1859. Today Pirogov's contributions to anatomy are remembered in a number of anatomical structures named after him. Clin. Anat. 33:714–730, 2020. © 2019 Wiley Periodicals, Inc.

**Key words:** anatomy; medical education; medicine; surgery; history; Pirogov; Russia (pre-1917)

## INTRODUCTION

During the early history of Russia, the majority of its citizens had little or no access to qualified medical care, relying on traditional folk and herbal remedies (Kuzmin and Sorokina, 1984; Likhachev, 2003; Sorokina, 2008). Up until 1700 there were no medical doctors of Russian origin in the country. It was Tsar Peter the Great (1672–1725) who radically reformed

\*Correspondence to: I.F. Hendriks, Department of the Executive Board, Post Zone H-01-46, Leiden University Medical Centre, PO Box 9600, 2300 RC Leiden, The Netherlands. E-mail: ingfehndriks@gmail.com

Received 13 July 2019; Revised 22 September 2019; Accepted 24 September 2019

Published online 11 November 2019 in Wiley Online Library (wileyonlinelibrary.com). DOI: 10.1002/ca.23493

© 2019 The Authors. *Clinical Anatomy* published by Wiley Periodicals, Inc. on behalf of American Association of Clinical Anatomists.

This is an open access article under the terms of the Creative Commons Attribution-NonCommercial-NoDerivs License, which permits use and distribution in any medium, provided the original work is properly cited, the use is non-commercial and no modifications or adaptations are made.

the health care system and medical education. With his Dutch court physician, Nicolaas Bidloo, Peter the Great founded the first Medical Hospital and medical school in Moscow in 1717 and in 1725 the Academy of Sciences in Saint Petersburg (Richter, 1817; Oborin, 1990; Sorokina, 2008; Abashin and Tsvelev, 2009). His successors established the first university in Moscow in 1755 and in 1798 the Imperial Medico-Surgical Academy, now the Military Medical Academy named S.M. Kirov. But it would be another 100 years after the changes introduced by Peter the Great before medical education in Russia reached the standards of elsewhere in Europe. It was the Russian physician Nikolay Ivanovich Pirogov who helped develop a modern scientific approach to medicine. He was the first to emphasize the importance of anatomy and its application in surgery.

Nikolay Pirogov was born in Moscow on November 13 (25), 1810 the youngest of 13 children (Pirogov, 1990, 2011). As a child, one of the family friends, Efrem Osipovich Mukhin, Professor of Medicine at the Medical Faculty of the Imperial University of Moscow, made a deep impression on the young Pirogov. One of his older brothers was bedridden with rheumatic fever. He was treated by several doctors, but nothing helped. Finally, the family called in Professor Mukhin, and within a few days under his care, the patient started to recover. This made a lasting impression on the young Pirogov and stimulated an interest in medicine.

Later, when Pirogov was 13 years old, Professor Mukhin, aware of Pirogov's interest in medicine, suggested that he enter Moscow University as a medical student (Pirogov, 2011). Nikolay sat and passed the university entrance examination and began his studies 3 years earlier than the conventional age of 16. Pirogov later wrote about the teaching methods of the medical faculty, that it was a rather theoretical education based on textbooks from the 1750s (Pirogov, 2011). However, during his time as a medical student, one teacher really inspired him—anatomist, Professor Loder, encouraged Pirogov to study anatomy seriously. Pirogov graduated as a physician in May 1828 at the age of 17.

### **Pirogov's Time in Dorpat**

After Pirogov qualified as a physician, Professor Mukhin, now Dean of the Moscow University Medical Faculty, was once again to influence the young Pirogov in a way that would define his future career. Aware of Pirogov's considerable talent, Mukhin persuaded him to enter as a candidate for the prestigious postgraduate institute of the German-Baltic University of Dorpat (nowadays called Tartu in the Republic of Estonia) with the chance to study there for 2 years and a further 2 years elsewhere in Europe. Only 20 students from all Russian universities were admitted to Dorpat each year. Pirogov passed the university entrance examination and, on a scholarship granted by the Russian Government, began his postgraduate training in July 1828. He originally wanted to study physiology, since he believed that anatomy and physiology were intimately related,

but unfortunately, physiology was not available as a subject at Dorpat. He chose to specialize in surgery and anatomy under the mentorship of Professor Johann Christian Moier, a student of the famous Italian surgeon and anatomist, Antonio Scarpa. Moier gave genuine help to all his students and worked along with them for long hours in the anatomical theater, teaching them the skills needed for dissecting cadavers (Pirogov, 2011).

Students of the medical faculty in their first year at Dorpat were required to write a research essay on an assigned topic (Geselevich, 1956). The author of the best essay was awarded a gold medal. Pirogov was allocated the topic "What is observed when a large artery is ligated?" The ligation of an artery in a patient with an aneurysm was a new and potentially dangerous procedure at that time (Fearn, 1836–1837) and Pirogov's essay on the topic won him the gold medal (Geselevich, 1956). The government scholarship to study in Dorpat was only for 2 years, after which students were expected to spend a further period in another European country. However, because of the outbreak of hostilities between Russia and Poland in 1830–1831, Russians were not allowed by the government to travel outside Russia (the current Republic of Estonia was then part of Russia). Pirogov was thus forced to remain in Dorpat for a further 2 years. At that time, there was also an outbreak of cholera in Russia and Pirogov went daily to the mortuary to autopsy the victims of cholera. His autopsies were attended by some visiting French professors who were astonished at the ability of the young Russian and invited him to France. Pirogov declined their offer and remained at Dorpat for a further 2 years to work on a research project "Is ligation of an aneurysm of the abdominal aorta in the groin a feasible and safe intervention?" It was this paper that would lead to his doctoral thesis (Pirogov, 1832).

From the available literature, Pirogov was aware of a number of publications on the topic, including those by the French surgeons, Jacques Lisfranc de St. Martin and Alfred Velpeau; and Sir Astley Cooper, a London surgeon and anatomist and professor of comparative anatomy at the Royal College of Surgeons in London. In 1808, Cooper attempted ligation of the external iliac artery in a patient with an aneurysm and in 1816 he was the first to ligate the abdominal aorta for treatment of an iliac aneurysm (Anonymous, 1911b, 1989; Bettany, 1887). Pirogov wrote, "This interested me with respect to both its surgical and physiological aspects" (Pirogov, 2011). Although the patient died, "It remained to be decided whether, in fact, such an operation could be carried out with a hope of success" (Pirogov, 2011). In his animal experiments, Cooper had only investigated the effects of ligation of the aorta in medium-sized dogs (Pirogov, 1832). Pirogov suspected that the results of such an operation might depend both on the size of the animal and the species studied. He therefore set out to investigate this in a series of animal experiments. His objectives were:

1. To get a clear and accurate insight into the structure and function of the abdominal aorta.

2. To perform a thorough study of the position of the abdominal aorta in relationship to the surrounding organs.
3. To get a detailed understanding of the circumstances leading to collateral formation after ligation of the abdominal aorta.
4. To determine the impact of the ligation on the artery and the surrounding tissues, on the lateral branches of the aorta, and which general changes the body underwent.

Pirogov spent long hours in the anatomy theater conducting 28 experiments involving dogs, cats, sheep or calves; the results of which formed the core of his doctoral thesis (Pirogov, 1832). In his zeal and youthful passion he was indifferent to suffering and operated on both dead and living animals to learn as much as possible about their anatomy and how they reacted to ligation of the aorta (Pirogov, 1990). In his biography Pirogov wrote, "I was so surprised at my indifference to the torments of animals during vivisection, that with a knife in my hand, I turned toward an assisting colleague, and exclaimed: The way we go about things, perhaps it is just as easy to cut open a human being" (Pirogov, 1990).

In most of the early experiments, Pirogov placed a ligature around the aorta close to its bifurcation and immediately tightened it (Pirogov, 1832). In other animals, the ligature was placed just below the inferior mesenteric artery. He then checked for the effect on blood flow through the femoral arteries—in most cases, this was either absent or markedly reduced. When some femoral flow remained, Pirogov concluded that in these animals there was enough collateral circulation to allow some restoration of blood flow distal to the site of the aortic ligation. After the first four experiments, he remarked that the abdominal aorta appears not to follow the general surgical rule, but that the further from the heart an artery is ligated, the greater the chance of blood supply distal to the ligature via collateral vessels. In contrast, he found that the chance of collateral circulation is greater when the ligature is placed between the mesenteric arteries since blood can flow from the superior mesenteric artery to the inferior mesenteric arteries; thus, providing a blood supply to the lower abdominal organs and the lower limbs.

In his sixth experiment, in a large dog, Pirogov compressed the aorta under the lower mesenteric artery with a ligature. A second ligature was placed around the aorta between the two mesenteric arteries but not tightened. After amputation of the thigh, blood spurted from the femoral artery. The first ligature was loosened and the second one tightened. The blood spurted stronger for a while, but then flowed as before. In order to destroy the anastomoses of the epigastric artery, he incised the anterior abdominal walls, but still the blood flowed from the amputated thigh. A third ligature was applied, the aorta was incised between them, but the femoral blood flow remained as before. Pirogov pointed out that this result did not conform to the above-mentioned theory, but that it should be noted that the inferior

mesenteric artery is relatively small in dogs, about the size of the lumbar arteries, which might explain this result.

In the discussion that follows, Pirogov hints at a possible motive for his research—namely the potential for the treatment of patients with an aneurysm of the iliac artery where ligation of the abdominal aorta could be considered a feasible option. Pirogov discusses the circumstances that could have a special impact on the outcome of such a procedure. He also described in some detail the various anastomoses/branches of the aorta between the superior mesenteric artery and its bifurcation and how these vessels are related to the abdominal organs and nerve networks such as the coeliac plexus, which cover the whole external surface of the aorta in this area (see page 129 in his German publication [Pirogoff, 1838b]). Pirogov then asked, "Which part of the abdominal aorta is the most suitable for ligation, between the two mesenteric arteries or between the inferior mesenteric artery and the bifurcation?" (Pirogov, 1832). He concluded that at first sight, the region between the two mesenteric arteries might have preference because of the important branches that would favor collateral circulation. However, he pointed out that for the surgeon this has significant disadvantages as it is covered by the stomach, duodenum, pancreas, and several large arteries and nerve networks, making access to the aorta difficult. He explained it as follows:

As for the position of the abdominal aorta, it is covered on the second lumbar vertebra by the tight-fitting diaphragm, the stomach, pancreas, and solar plexus. The coeliac trunk and superior mesenteric artery, which are covered with a dense network of nerves, leaves little space for access to the aorta. For us as surgeons, only the space between the second and fourth or fifth lumbar vertebrae remains, and thus, that part of the aorta that is located between the origin of the superior mesenteric artery and its bifurcation. This lower part of the abdominal aorta, which I will call *Portio ileo-mesenteric*, is in the adult about 4 inches long, and gives off the following arteries: the inferior mesenteric artery, the two renal arteries, the *arteria sacra media*, and 4 or 6 lumbar arteries. The peritoneum occupies the posterior part of the abdominal cavity, goes from both sides forward, covers the vertebral column, and closes between its two plates a triangular space, and then forms the mesentery. This space, that can be compared with the mediastinum in the thoracic cavity, is filled by the aorta, the lower vena cava, the thoracic duct, and the branches of the *nervus sympathicus*. Because the peritoneum here only adheres to the abdominal walls due to weak cellular tissue, it can easily be separated. Surgeons can access that room in two ways: either one of the two peritoneum plates must be cut, from which the mediastinum consists; or, one can, if

one penetrates laterally and leaves the peritoneal bag unharmed, separate it from the abdominal muscles. So either with incision in the peritoneum or without it (Pirogoff, 1838b).

Thus, for Pirogov the best option is ligation of the abdominal aorta between the inferior mesenteric artery and the aortic bifurcation.


In the majority of the animals, paralysis of the hind legs was present soon after recovery from the surgery, although there were a few exceptions. While many of the animals died soon after the operation, a cat (Experiment 15) and dog (Experiment 16) lived for 1 year and one calf (Experiment 19) lived for 60 days, all without signs of paralysis. After their death, Pirogov performed a postmortem. In all the animals that died soon after surgery, a common finding at postmortem was the presence of significant amounts of thrombi in the vena cava and the right ventricle, together with a virtually empty left ventricle.

After describing his first 17 experiments, Pirogov performed a few additional experiments in calves (number not reported), and in most cases, results were similar to the earlier experiments. However, in some animals, the changes after ligation of the aorta were hardly noticeable; he wrote "the reasons were not obvious to me" (Pirogov, 1832, 1957). He mentions one example of a calf in which there was little evidence of paralysis of the hind legs and that after 16 days it had been restored to perfect health. But for some unexplained reason 8 days after the first operation, Pirogov tied both the animal's carotid arteries (which should have led to the animal's immediate death). It is amazing then that Pirogov could claim that the animal continued to be healthy.

In the opening discussion of part two of his German article (Pirogoff, 1838a), based on his Latin thesis, the principle objective of Pirogov's research is made clear: to determine the applicability of ligation of the aorta in the treatment of patients with an aneurysm of the aorta or the iliac artery. Based on his observations from the first 17 experiments, he reiterated that ligation of the aorta can only be considered reliable if the ligature is placed between the two mesenteric arteries, but the approach to this area makes it difficult for a surgeon. Modern surgeons would not have this difficulty, partly due to the use of anesthesia and muscle relaxation that were not available in the 1830s. Pirogov believed that the only surgical alternative was the approach used by Brasdor and Wardrop (Anonymous, 1836-1837, 1911a; Pirogov, 1957). Pierre Brasdor (1721-1797) was a French surgeon and anatomist who developed a method for the treatment of arterial aneurysms by ligation of the artery immediately below the aneurysm, which became known as the Brasdor method. James Wardrop (1782-1869), a Scottish surgeon working in London, proposed a modification of the Brasdor method for the treatment of aneurysms, described in a monograph published in London in 1828 (On aneurism and its cure by a new operation...) (Pirogov, 1957). Like

Brasdor, Wardrop had treated patients with aneurysms of the innominate artery by ligation of the carotid artery (Anonymous, 1836-1837; Pirogov, 1957). However, based on the findings from his animal experiments and what others had observed in patients in whom this procedure was performed, Pirogov had considerable reservations about the safety of this procedure in humans. He was concerned that much of the available evidence came either from a limited number of animal experiments or from findings based on autopsies in humans. He remarked that the ligation of the abdominal aorta in small animals is more likely to be successful because the ligature is almost always placed between the two mesenteric arteries and secondly because the anastomoses from the aorta to the lower parts of the body (i.e., greater ability to form a collateral circulation) plays a much more important role in the smaller animal. In larger animals, the sudden obstruction of the aorta beneath the mesenteric arteries is seldom associated with a successful outcome. Today, it is accepted that, at least in humans, there are numerous branches of the aorta arising between the mesenteric arteries that form an extensive network of collateral blood vessels.

In all subsequent experiments, Pirogov used a modified version of the method described by the French surgeon and anatomist, Antoine Dubois (1756-1837) in *Bulletin de la Faculté de Médecine de Paris, 1810* (Pirogov, 1957). He inserted a ligature, consisting of 7-8 in.-long silk threads composed of six to eight strands, around the aorta and attached both ends of the ligature to a device known as the compressor (Fig. 1), which had been developed by Buyalsky, and which allowed the ligature to be gradually tightened over a period of several days. For example, a ligature was placed around the aorta of a sheep and tightened with the compressor so that it lay just taut against the surface of the vessel. It was then slowly tightened over 8 days, but within 30 hr, the sheep had obvious paralysis of its hind legs. Pirogov loosened the ligature a little and muscle power was restored. Forty-five hours after the operation the sheep was able to walk without signs of paralysis, but when the ligature was further tightened it fell with difficult breathing. When the ligature was made a little looser it regained full use of its hind legs. This procedure was repeated several times until the animal died 12 days after the operation. At postmortem, the atria and pulmonary blood vessels were partially filled with thrombi, but there was only a small amount of thrombus in the right ventricle and none in the left ventricle. The ligature, three fingers above the bifurcation, was covered with lymph and pus, but the lumen of the aorta at the site of the ligature was not completely occluded. What Pirogov observed in this animal and others treated using the same method, was that after gradually occluding of the aorta, the results were different from those in earlier experiments where the aorta was immediately and completely occluded. Pirogov concluded that to carry out this procedure successfully in living animals, the following three conditions must be absolutely adhered to:



**Fig. 1.** Tourniquet (or compressor) designed by Ilya V. Buyalsky, used by Nikolay Pirogov to narrow the aorta by tightening a ligature (Pirogov, 1957). *Source:* Reproduced with permission from the Military Medical Museum of the Ministry of Defense of the Russian Federation, Saint Petersburg.

1. Gradually tighten the ligature over not less than 1 week.
2. Moisten ligature before each adjustment.
3. The ligature must be made from at least four lengths of extremely strong silk strands.

Pirogov believed that preventing the full blood flow to the lower limbs cannot be the whole story. He believed that there were two reasons for the paralysis, disturbed blood circulation to the lower limbs and changes in the spinal cord due to a lack of blood supply, as shown by Legallois. Julien Jean César Legallois (1770–1814) was the first of the great French physiologists. From his experiments on living animals he concluded that sensation and motility could only reside in the spinal cord, and that the brain acts on the spinal cord in the same way that the spinal cord acts on the muscles. Legallois believed that the paralysis of the hind limbs following ligation of the

abdominal aorta in the lumbar region was caused by loss of blood supply to the spinal cord (Legallois, 1824). To explore this further Pirogov carried out a number of experiments to determine the cause or causes of the paralysis seen in his earlier experiments.

Following the method of Legallois, he placed a ligature around the aorta of a cat. The animal sprung up immediately, but after a few minutes, the movement in the hind legs diminished. He then opened the right femoral artery and immediately blood gushed out. Pirogov then placed a second ligature around the aorta and cut the vessel between them. He then opened the spinal canal and inserted an iron rod into the lower part of the spinal canal. Contractions of the thigh muscles appeared immediately. Again, he pushed the rod into the spinal canal destroying the cord; now there were no muscle contractions. He repeated the experiment in a dog with the same results. In each of the above experiments, the aorta was ligated just above the bifurcation, and thus maintaining blood flow via the lumbar arteries to allow a sufficient supply to the cord. Pirogov speculated that this explained why his results differed from those of Legallois. Legallois destroyed the spinal cord 15 min after ligating the aorta; whereas, Pirogov did so after only 8 min when paralysis had not yet occurred. Second, Legallois cut through the abdominal muscles to reach the spinal cord, and this would have destroyed the internal mammary and the epigastric arteries while Pirogov approached the spinal cord from the back, thus leaving those anastomoses intact.

Pirogov concluded that, based on the results of his experiments:

1. Immediate ligation of the aorta beneath the inferior mesenteric artery is not a reliable method.
2. Success with this procedure is only possibility when the aorta is ligated between the two mesenteric arteries (which is hardly possible in humans) and the ligature gradually tightened.
3. When death occurs, it is due to congestion of the lungs and heart.
4. There are sufficient branches from the aorta above the site of the ligature to allow an adequate flow of blood to the regions supplied by the lower aorta.
5. The cause of the paralysis is most likely to be found in the spinal cord.

Pirogov successfully defended his thesis "Num vinctura aortae abdominalis in aneurysmate inguinali adhibitu facile ac tutum sit remedium" and was awarded his doctorate in 1832 (Pirogov, 1957). He published a German translation in 1838 (Pirogoff, 1838a, 1838b). A Russian translation was published later in 1957 (Pirogov, 1957). Pirogov opened his thesis with a quotation from François Magendie (1783–1855) (Lazorthes, 1984; Shampo and Kyle, 1987; Haas, 1994), a French pharmacologist and physiologist. He, together with the German physiologist Johan Müller, one of Pirogov's teachers in Dorpat, laid the foundations of experimental physiology. Magendie wrote "Expressing or believing an opinion in

science without evidence is nothing else than ignoring the truth" (Pirogov, 1832). Pirogov included this quotation to emphasize his core belief that in science nothing should be taken for granted—a principle that permeated his whole career and characterized his approach not only to science but also to every aspect of his life. For him, like Magendie, "...Science is not built from what people think, but from what people have discovered..." (Pirogov, 1832).

In his thesis, Pirogov criticized his fellow scientists because he considered many of their descriptions of anatomical details and surgical procedures to be inadequate. In his opinion, their main focus was to obtain the most accurate measurement of the dimensions, location, shapes, and directions of anatomical structures. But for Pirogov surgery was much more than just finding a path to a particular structure, be it a nerve, vein, artery or an internal organ. Surgery must be based on an intimate knowledge of anatomy and the topography of the relevant structures as well as the changes caused by pathological processes. An operation performed without this basic knowledge cannot be fully successful.

Pirogov added an appendix to his thesis (not included in the German article of 1838, but it is in the Russian translation of the Latin thesis of 1957) in which he summarized the most important results of his latter experiments (21–28).

## Time in Berlin

After gaining his doctorate Pirogov had to wait some time for permission from the Ministry of National Education (also named Ministry of Enlightenment) to travel to Germany to complete a further 2 years postdoctoral study of anatomy and surgery at the Charité Hospital in Berlin in 1833 (Pirogov, 2011). During his first semester in Berlin he was assigned the following mentors:

- Professor Friedrich Schlemm for anatomy and for surgical studies on cadavers.
- Professor Johan Nepomuk Rust for clinical lectures.
- Professor Karl Ferdinand von Gräfe for ophthalmology.
- Professor Johann Friedrich Dieffenbach for surgery.

He also attended many of the lectures by the physiologist Johann Müller, who conducted demonstrations on animals (mainly frogs), often making use of a microscope.

Before Pirogov came to Germany, he could not imagine that a skilled surgeon could doubt the importance of anatomy, but this was indeed what he found in Berlin. For Pirogov, knowledge of anatomy was essential for a surgeon, "...It is advisable that only someone who is familiar with the body, the position of the organs in their unaltered state and the painful changes, should operate on a person..." (Pirogov, 1832) and without a thorough knowledge of anatomy and physiology, surgery could never rise to the level of a science but would remain a craft (Pirogov, 1832, 1957). He was surprised that neither Rust, Gräfe, nor

Dieffenbach—all highly respected German surgeons—had only a basic knowledge of anatomy (Pirogov, 2011). Surgery seemed to be isolated from its most important basis, anatomy and physiology; all three disciplines were considered independent of each other. He wrote "...who of my compatriots will believe me when I say that in Germany, in the educated Germany, famous teachers proclaim that anatomical knowledge is of no use to surgeons..." (Pirogov, 2011).

In defense of the German surgeons, it needs to be realized that, in the absence of anesthesia, the scope of surgery in the early 19th century was limited to amputations and other superficial types of operations. Surgical access to the abdomen was restricted and the thoracic cavity was a "no go" area. This changes dramatically with the arrival of anesthesia with the first public demonstration of ether anesthesia by William Morton in Boston on Friday, 16 October 1846 (Bigelow, 1846). News of this discovery quickly reached Russia. Pirogov initially hesitated to use ether because he was worried about the safety of the technique and the effects during the recovery from anesthesia. Pirogov carried out experiments with ether in January 1847, and the results convinced him that his earlier misgivings were unfounded and that ether anesthesia was "...a remedy, that in one sense can transform the whole of surgery..." (Pirogov, 1847b, 1849a). He carried out his first two operations under ether anesthesia on 14 February 1847 in the Second Military Land Force Hospital in Saint Petersburg using a simple green bottle with a rubber tube inserted into the patient's nose for inhalation of ether vapor (Anonymous, 1847; Pirogov, 1847b, 1849a). Within a year, he had operated on more than 300 patients using ether in his own surgical practice and on the battlefield (Pirogov, 1849a). He published his first monograph on the subject on 17 May 1847 (Pirogov, 1847a, 1847b; Shabinin and Zhuravlev, 2004). He used it widely in the summer of 1847 during the Caucasian War (Hendriks et al., 2015). He also carried out experiments with rectal administration of ether on animals and later in patients. Compared to the inhalation route, rectal administration of anesthesia developed much quicker (within 2–3 min) and the patients were more deeply anesthetized with better muscle relaxation. Rectal administration of anesthesia also lasted longer (about 15–20 min) than inhalation anesthesia, allowing more major operations to be carried out. Although initially enthusiastic about this method, he soon became much less enthusiastic and rectal ether never achieved widespread popularity. After his return from the Caucasian War, Pirogov administered his first anesthesia with chloroform on 21 December 1847 in Moscow; the subject was a large dog (Zhorov, 1951; Pirogov, 1992). On the basis of his subsequent observations and analyses, he was convinced that mortality was not increased by administration of ether or chloroform (Pirogov, 1849a). Chloroform had obvious advantages over ether for use in the field. The quantity needed for effective anesthesia was small; unlike ether, it was not inflammable, and it did not require complicated equipment

since chloroform could easily be induced using a simple rag-and-bottle technique.

The only surgeon in Berlin to perform surgical experiments on human corpses was professor Schlemm, who allowed Pirogov to work with him on these experiments. The other person with whom Pirogov cooperated was the former midwife, madame Vogelsang, who was devoted to anatomy (Pirogov, 2011). She provided Pirogov with large numbers of cadavers against payment; one thaler for one cadaver to carry any operation on it (nowadays the equivalent of approximately 80 Euros) and 15 silbergroschen (nowadays the equivalent of about 29 Euros) for dissecting the arteries in the limbs and for opening up the joints (Pirogov, 2011). They spent long hours together in the Charité Hospital in Berlin; she taught Pirogov the intricacies of anatomy. In 1834, Pirogov spent his summer holidays in Göttingen where he attended lectures by the surgeon-anatomist Konrad Langenbeck, who was famous for his speed and precision involving amputations. Pirogov understood that a fast and skilled surgeon was important for saving the patient for pain and trauma. Even later when anesthesia was introduced, Pirogov wrote: "...a slow operation even using anesthetics could be harmful for the patient, because of the prolonged anesthesia and the trauma..." (Pirogov, 1849a, 2011).

While Pirogov felt passionately that a good knowledge of anatomy was an essential prerequisite for a surgeon, he realized that a surgeon's approach to anatomy must differ from that of an anatomist or pathologist. Even though the anatomist has a thorough knowledge of the human body, the surgeon was the expert in the application of that anatomy. Pirogov pointed out that when the surgeon makes his incisions, he needs to have a detailed knowledge of the location of the various fascia, muscles, arteries, and nerves within the layers under his knife in order to avoid damaging them, or at least causing minimum damage. He went on to say that none of the anatomical-surgical manuscripts that he had read reflected this opinion. He considered the papers published by French surgeon-anatomists such as Alfred-Armand-Louis-Marie Velpeau and Philippe-Frédéric Blandin were incomplete because they did not show the brachial artery (a. brachialis) or the femoral artery (a. femoralis) in their manuscripts (Pirogov, 1838). He advocated that the chair of surgical anatomy should be held by the professor of surgery, *not* by the professor of anatomy.

## Return to Dorpat

In May 1835, Pirogov returned to Dorpat where Professor Moier asked him to join his department as professor extraordinary, a proposal that was unanimously supported by all the staff members (Pirogov, 2011). However, such an appointment needed to be confirmed by the Ministry of National Education, necessitating Pirogov's travel to Saint Petersburg, then the capital of Russia. While he waited for the confirmation, Pirogov gave, over a period of 6 weeks,

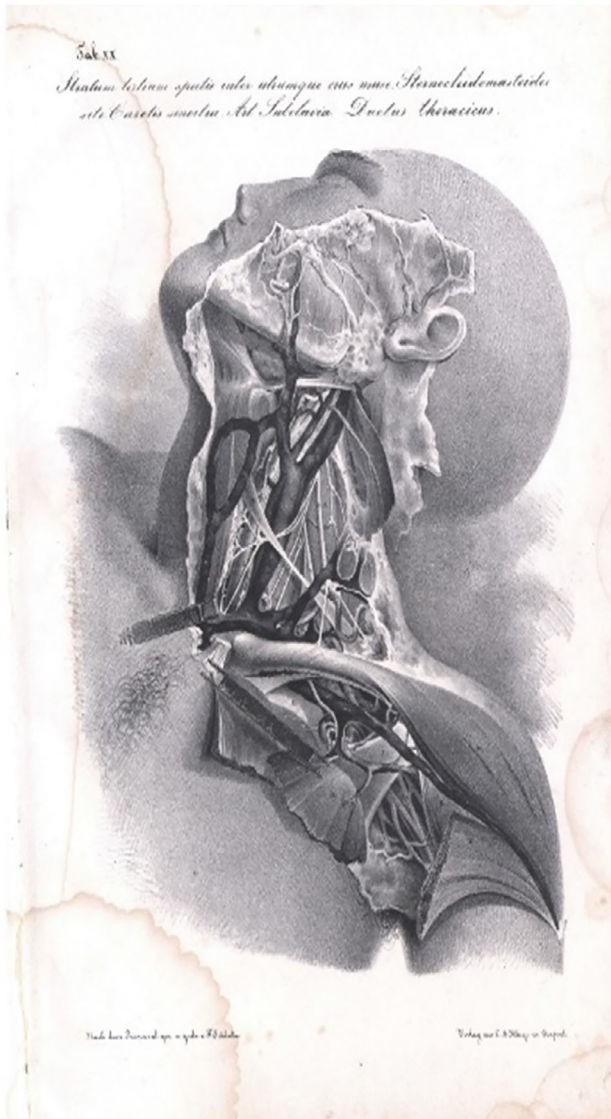
a number of anatomy demonstrations held in the mortuary of the Obukhov hospital. They were attended by 20 or more of his fellow surgeons and doctors from the Obukhov hospital and the Imperial Medico-Surgical Academy.

Pirogov was strongly interested in the opinion of his students and in the exchange of experiences in order to further develop the clinical judgment of students (Geselevich, 1956; Pirogov, 1957, 2011). During an operation, Pirogov made his students name the different anatomical structures, thereby enhancing their knowledge of the relevant topographical area and helping to raise the standard of medicine in Russia. He used the same method for his students during his experimental research involving animals. This was quite a different approach from the education he experienced at the University of Moscow, which was only theoretical and excluded practical experience. He introduced what is now called interactive education, and with these fundamentally new methods, he quickly raised the standards in his clinic to higher levels.

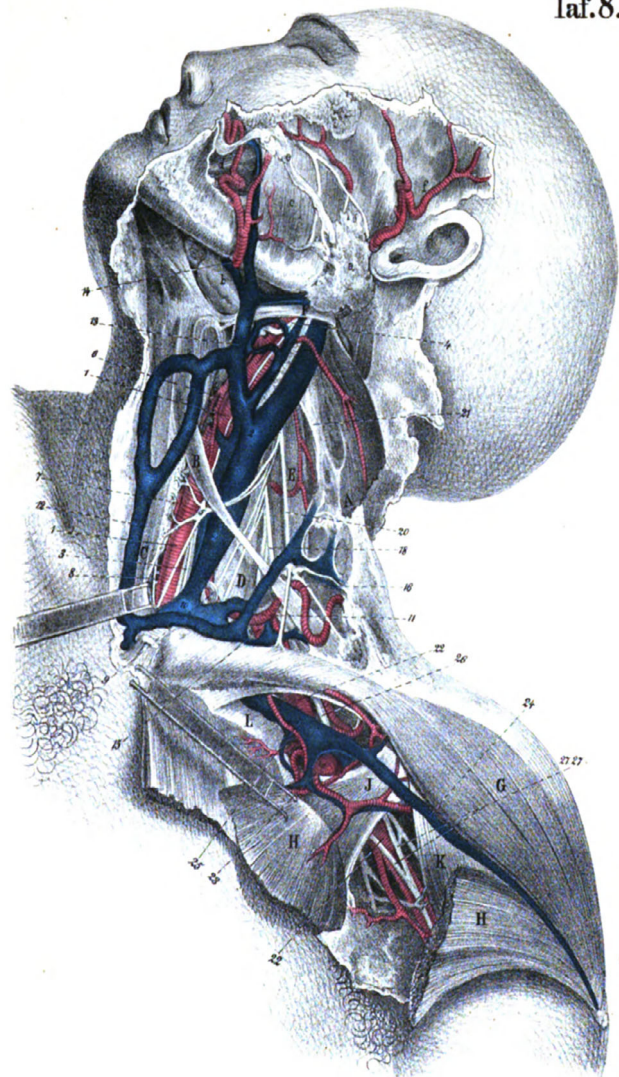
In addition to his clinical duties, Pirogov spent 8 hr each day carrying out and analyzing anatomical experiments. During these experiments, he made at least two or three drawings of his dissections, as he believed that these would be useful to surgeons in helping them during operations in patients. One image represented the relative position of the fascia in relation to the arteries, the second and third represented those of the muscles, veins, and nerves. The branches of nerves, arteries, lymph vessels and glands as well as bundles of fibrous tissues were accurately reproduced in his drawings. These served to define the detailed topography of an area (Adstrum and Nicholson, 2019). The results of these experiments were published in black-and-white in an extensively illustrated atlas of arterial trunks and fascia. The publication was put out first in German in 1837, in Latin in 1838 (Pirogov, 1838), and in Russian in 1840 (Geselevich, 1956) (Fig. 2). In it he wrote: "A real anatomical-surgical image must be for the surgeon what a map is for the traveler." (Pirogov, 1838). The atlas was republished with the permission of Pirogov by Julius Szymanowski in 1860, who added one extra page detailing a drawing of the total body with the arteries colored red and the veins colored blue (Szymanowski, 1860) (Fig. 3).

In 1837, Pirogov was given a grant to visit Paris where he met a number of surgeons, among them Alfred-Armand-Louis-Marie Velpeau, a skilled surgeon renowned for his knowledge of surgical anatomy. Velpeau, at that time, was reviewing Pirogov's publication "Surgical Anatomy of the Arteries and Fasciae," with the goal to have it acknowledged by the Paris Academy of Science (Pirogov, 1838, 2011). He praised Pirogov for his work on surgery and his research into facias and on his drawings. Pirogov was invited by the surgeon Jean Zuleman Amussat to his home where he met fellow surgeons Astley Cooper, Dieffenbach, Roux, and Lisfranc. During a discussion on the urinary tract, Amussat spoke of his conviction that the urinary tract in men was totally straight.





**Fig. 2.** Plate XX, Illustration of the neck and shoulder region (Stratum tertium spatii inter untrumque crus muze Sternocleidomastoides site Carotis sinister Arteri Subclavia. Ductus Thoracicus), by Nikolay Ivanovich Pirogov, *Anatomica Chirurgica truncorum arterialium nec non fasciarum fibrosarum*, Dorpat, Imperial Russia: C.A. Kluge, 1838. (In public domain). [Color figure can be viewed at [wileyonlinelibrary.com](http://wileyonlinelibrary.com)]



**Fig. 3.** Plate 8, Illustration of the neck and shoulder region (Stratum tertium spatii inter untrumque crus muze Sternocleidomastoides site Carotis sinister Arteri Subclavia. Ductus Thoracicus), by Julius Szymanovski, Nicol. Pirogoff's *Anatomia chirurgica truncorum arterialium nec non faciarum fibrosarum*, Leipzig und Heidelberg, C.F. Winter'sche Verlangshandlung, 1860. (In public domain). [Color figure can be viewed at [wileyonlinelibrary.com](http://wileyonlinelibrary.com)]

Pirogov disagreed and told him about his findings in frozen corpses. They continued to disagree on this subject, so Pirogov showed them specimens that he had previously prepared to prove his findings. He also brought pelvis sections to prove the absurdity of Amussat's view on the relationship of the urinary tract with the prostate gland. Despite Pirogov's visual proofs, Amussat disagreed. Pirogov stated "People, particularly scientists and more so the vain French,

with preconceived notions, never admit their errors and mistakes." (Pirogov, 2011).

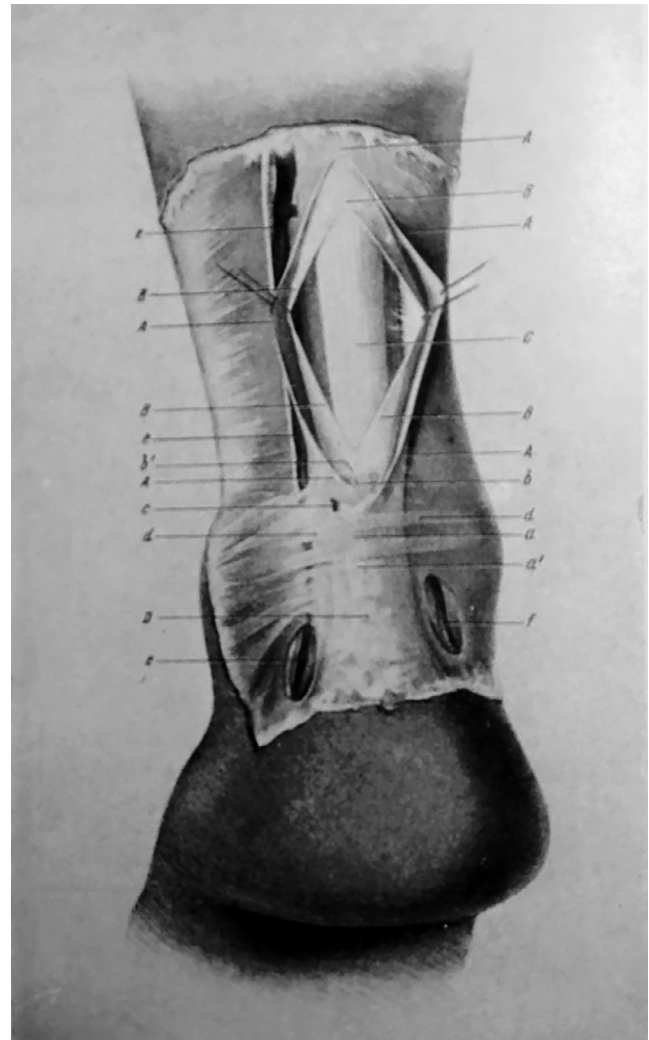
**Orthopedic treatment: The transection of the Achilles tendon.** Nikolay Pirogov's first encounter with orthopedic surgery was a 14-year-old female patient with a clubfoot (Pirogov, 1840). He was only aware of the orthopedic specialty through the

publications of the German surgeon, Georg Friedrich Louis Stromeyer (1804–1876), a pioneer in orthopedic surgery. In 1831, Stromeyer performed the first subcutaneous tenotomy of the Achilles tendon on a patient with clubfoot (Stromeyer, 1833; Hernigou et al., 2017). Pirogov considered the operation of tenotomy, the transection of the Achilles tendon advocated by Stromeyer, as one possible treatment for his patient, although he thought it rather risky. Nonetheless, he decided to proceed and cut the tendon. Fortunately, the operation was successful. From what he read about the procedure in the available literature, no one before him had shown by animal experiments why the operation was successful, or what the exact consequences were of cutting the tendon. In 1837, he began his own research into the anatomy of the Achilles tendon and changes induced by its transection. He carried out 80 experiments using various species of animal and subsequently performed 40 tenotomies in humans, applying the knowledge he had learned from his animal experiments.

From his research and his observations during operations on his patients, Pirogov reported that the Achilles tendon was enclosed in a double sheath and not by a single one as previously thought. One is the aponeurotic sheath—the continuation of the fascia cruris—and the other, a peculiar cellular-synovial tissue. He believed that a satisfactory regeneration of the tendon following tenotomy appeared to require maintaining a blood supply to, and a thrombus present, in the tendon sheath. He published his results, which included seven plates with drawings in 1840 (Pirogov, 1840) (Fig. 4). Pirogov faithfully believed in impartial research and considered surgery to be successful only if the theory is firmly confirmed by experiments and anatomical-physiological and pathological studies (Pirogov, 1840).

### Professor in Saint Petersburg

In 1839, Nikolay Pirogov was invited to become professor of applied anatomy and surgery in the Imperial Medico-Surgical Academy in Saint Petersburg (Pirogov, 1957, 2011). Before he accepted the appointment he negotiated his terms, which included improvements in medical education with a greater emphasis on the practical aspects of patient treatment and the application of scientific advances. It took Pirogov 2 years before he got what he asked for, and was officially appointed in March 1841 as Professor of Applied Anatomy and Hospital Surgery at the Imperial Medico-Surgical Academy and Chief Surgeon of the Second Military Landforce Hospital in Saint Petersburg (Pirogov, 1957, 2011). Immediately after taking up his new post, Pirogov was also appointed as Technical Director of the Medical Instruments Factory, a member of the committee to improve the medical curriculum for students under the Ministry of Public Education and a member of the Medical Council of the Ministry of Internal Affairs (Hendriks et al., 2018). Pirogov reorganized medical education. He introduced a new curriculum for medical students that for the first



**Fig. 4.** Both sheaths of the Achilles tendon after the subcutaneous tenotomy (according to Stromeyer), freed from the skin. A, A, A, A, A—incision in the posterior wall of the aponeurotic sheath of the Achilles tendon; B, B, B, B—incision in the connective-synovial sheath of the tendon; C—the upper end of the cut tendon; D—its lower end; a—a gap (2.5 cm long between the ends of the tendon), which remained after the transection of the tendon in the aponeurotic sheath between the ends of the tendon; b—the same gap in the cellular sheath; a', b'—the edges of the incised tendon, which are visible through the translucent sheath; c—place of the puncture in the sheath; d, d—ray-shaped fibers of the fascia of the tibia in the grooves lateral to the Achilles tendon; e, e—vena saphena parva; f—posterior tibial artery.

time included the teaching of topographical and applied anatomy. His aim was: "To assist in raising the medical skills in Russia to a standard equal to that of the advanced countries of Europe." (Pirogov, 1854, 2011).

**Introduction of the microscope.** In 1825, while Pirogov was still studying in Berlin, practical and theoretical courses in microscopy were introduced in the main medical institutes of the city (Pirogov, 1839). Since then, Pirogov attached great educational value to practical studies in microscopic anatomy and histology and introduced this to the Medico-Surgical Academy (Pirogov, 1839). The anatomy department was the proud owner of the best available achromatic microscope at that time, manufactured by Simon Plössel (1794–1868); and a selection of microscopic slides, a gift from Vienna University. Simon Plössel was an Austrian optical instrument maker, who started his own workshop in 1823, but was trained by the Voigtlander company (Wikipedia, 2019b). In a book published in 1839 (Pirogov, 1839), Pirogov described the importance of the microscope for investigating the influence of altered blood corpuscles on the capillary system. In 1841, Pirogov, with his new colleague Karl Ernst von Baer, presented the case to the Academy for the teaching of microscopy and histology in order to acquaint students with the latest developments in medical science. Pirogov even promoted the creation of a histology chair, but this only came to fruition in 1857. Von Baer was a naturalist, biologist, and a founding father of embryology, who likes Pirogov, had studied at the University of Dorpat (Wikipedia, 2019a). In 1817, he was appointed professor of zoology and anatomy at Königsberg University (now Kaliningrad University). In 1929, he taught briefly in Saint Petersburg, but soon returned to Königsberg. In 1834, Baer returned to Saint Petersburg and joined the Saint Petersburg Academy of Sciences, first in zoology (1834–1846) and then in comparative anatomy and physiology (1846–1862).

In the first of his series of monographs on clinical surgery, published in 1854, Pirogov argued that microscopic examination is indispensable in distinguishing the various forms of lip carcinoma from trivial injuries like a burn from a cigarette or a neglected tear of the lip. He wrote that "...The microscope is much more indispensable than the stethoscope, which in most cases can be replaced by a practiced ear..." (Pirogov, 1854). He recommended the Brunner pocket microscope to his readers as it magnifies up to  $\times 400$  and had a field of view almost as wide as the portable field microscope that Pirogov always carried with him.

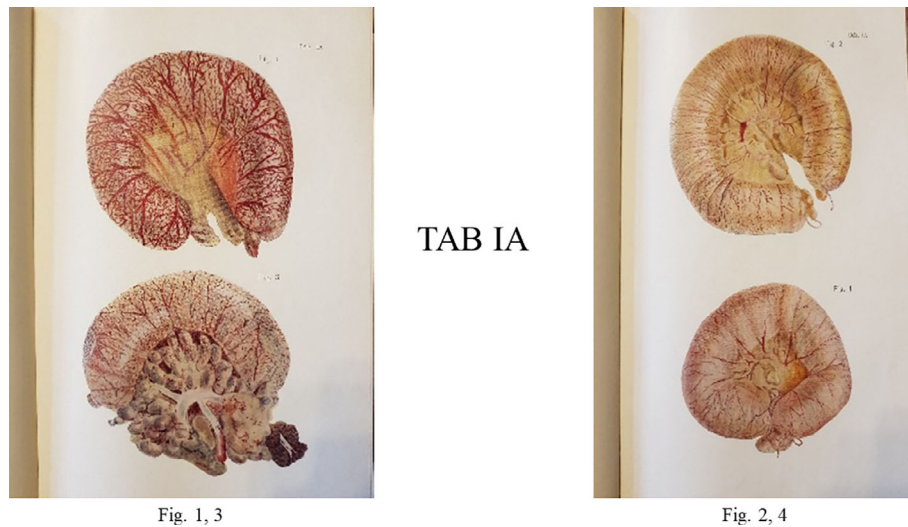
**The Anatomical Institute.** In 1844, Pirogov wanted to add an Anatomical Institute to the Academy (Pirogov, 1957). The Academy agreed with the idea, but not without a struggle, and it took another 2 years before permission was granted. In 1846, Pirogov, together with Carl Johann von Seidlitz and Karl Baer, formed the Institute for Applied Anatomy, with Pirogov as the director. Von Seidlitz was also a former student of the German-Baltic University of Dorpat, graduating in 1819. From 1836 to 1846, he was professor of therapeutics at the Medico-Surgical Academy in Saint Petersburg. The original correspondence and other documents concerning the decision making for the Institute are still held in the original library of

the Academy. Unfortunately, at the end of January 1846, before Pirogov could take up his post as director, his wife died after the birth of their second son (Pirogov, 1957). To help overcome his grief, the Academy gave him a grant to visit anatomical departments in Italy, France, Switzerland, and Austria. During his travels, he met Wencheslav Leopoldovich (Wenzel) Gruber, a former student of the Viennese anatomist, Josef Hyrtl (1810–1894)—and an outstanding anatomist in his own right (Pirogov, 1957; Gaivoronskii, 2018). In 1847, Pirogov invited Gruber to become his first prosector at the Imperial Medico-Surgical Academy. The prosector is a skilled person, comparable to the present-day mortuary technician, who undertakes the special task of preparing the dissection of a cadaver for demonstration purposes—usually in medical schools or hospitals. Many important anatomists began their careers as prosectors. The combined skill of Pirogov and Gruber was a marriage made in heaven. They had an excellent and fruitful cooperation. After Pirogov's resignation in 1855, Gruber took over the leadership of the Anatomical Institute, and in 1858, he became a full professor.

In the anatomical institute, Pirogov instructed medical students in pathological and surgical anatomy. He combined practical work and teaching, demonstrating surgical procedures on cadavers. Teaching was done in rooms specially designed for microscopy studies and for experimental work on animals. He also created a museum to provide a visual presentation to help the students learn the subjects. The institute also functioned as a postgraduate education center for those who wanted to improve their knowledge in the field of surgery and of surgical and pathological anatomy. Further, the institute had a function to train future teachers of anatomy, not only for the Academy, but also for other educational and medical institutions in Russia. Other Russian medical institutes later followed the path taken by the Imperial Medico-Surgical Academy. During his 15 years at the Academy, Pirogov carried out and/or supervised about 12,000 autopsies, which were done on all patients who died in the hospital clinics of the Academy. The introduction of the new diagnostics methods in the clinic and the practical microscopic courses, histology, anatomy and symptomatology, were important new steps in medical teaching in the 1840s in Russia (Kichigina, 2009).

### **The Cholera Epidemic of 1847**

During the war in the Caucasus (1847), Pirogov traveled to the war zone to provide surgical services for the wounded soldiers during the Siege of Salty (Pirogov, 1849a). When he returned to Saint Petersburg later that winter an epidemic of Asian cholera raged in Russia. Pirogov observed the disease at the various stages of the epidemic and was able to study the progress, symptoms, and treatment of the disease. He developed an atlas of the pathological anatomy of the disease (Pirogov, 1849b), together with a textbook on the subject (Pirogov, 1850b), based on



**Fig. 5.** Pathological anatomy of the Asian cholera. External views of the intestines affected by cholera. From N.I. Pirogov (Pirogov, 1849b). In public domain. The four images depict the main degrees of blood-filled subserosal and axillary vascular networks of the intestines. The change in color of the outer surface of the intestines is caused by the altered distribution of blood in the subserosal and axillary vascular network. This change is so characteristic of the disease that it can help identify cholera as the cause of death at postmortem. [Color figure can be viewed at [wileyonlinelibrary.com](http://wileyonlinelibrary.com)]

the approximately 500 autopsies that he had carried out or supervised. His objective was to provide clear pictures that would help his colleagues better understand the disease (Figs. 5 and 6). The drawings for both were done by Mr. Terebeniev and Mr. Meyer with significant financial support from the Imperial Medico-Surgical Academy in Saint Petersburg. Most of the atlas depicted pathological changes in the intestinal mucosa. Pirogov believed that the damage caused by cholera was largely to the intestinal canal. The atlas of the Asian cholera was extensively reviewed by Virchow in 1852 (Virchow, 1852). He praised the quality of the atlas, although he expressed some reservations about what he thought was a lack of detail in some areas. Virchow concludes in his review with an invitation to Pirogov to deliver an extensive text to the atlas and to take advantage of Virchow's remarks. By this invitation it is clear that Virchow did not have access to Pirogov's textbook to the atlas. This textbook extensively described the plates and the systematic analysis of his comparative research on the pathological anatomy of the Asian cholera that was published in 1850 (Pirogov, 1850b).

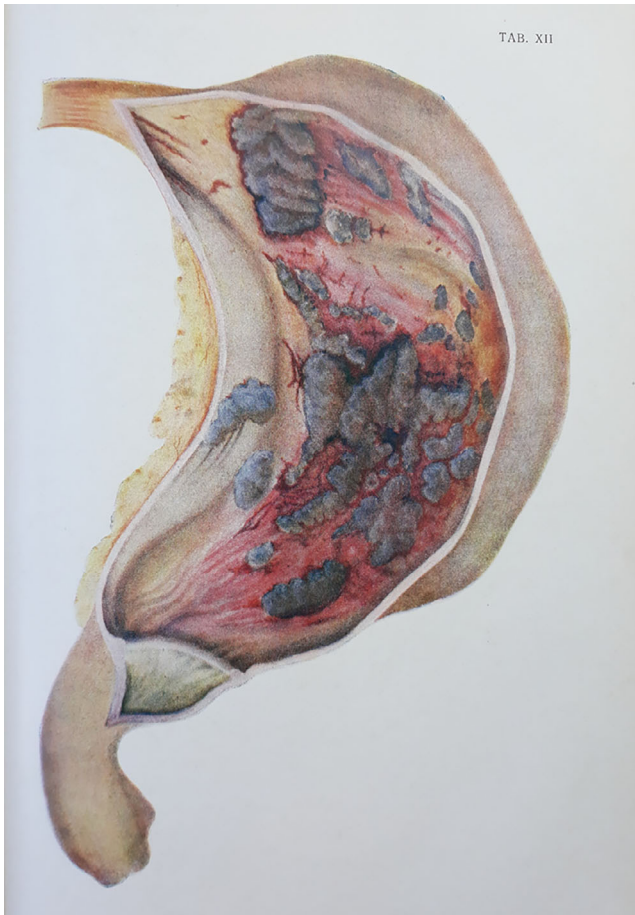
### Applied and Forensic Anatomy

Between 1843 and 1848, Pirogov worked on a book that reproduced natural drawings of the human body with the objective of teaching physicians about applied anatomy (Pirogov, 1844) (Fig. 7). The drawings in the book were layered so that readers could obtain a

three-dimensional image of the structures. The fascial and synovial sheaths and inter-fascial spaces in the lower limbs were illustrated in detail. He published the book on the upper and lower limbs inclusive of the foot and the hand in several issues. In an accompanying textbook, printed in both Russian and German, a detailed one-and-a-half-page explanation was given of each illustration. His original intention was to publish 25 issues, but was only able to manage 12 issues because the publisher was declared bankrupt.

Nikolay Pirogov was interested not only in anatomy and its application to surgery, but also in its value to forensic pathology (Pirogov, 1849a, 1957). During the Caucasian conflict in the summer and autumn of 1847, between insurgent rebels in the Caucasus and the Russian army, Pirogov was sent by Tsar Nicolas I to use surgical cover, and in particular to use the recently developed ether anesthesia in surgical operations. This was the first-time anesthesia was used under battle conditions (Hendriks et al., 2015). Pirogov was able to observe and analyze the characteristics of over 2,000 gunshot wounds, of which only 15 serious injuries were caused by large projectiles such as shells. All other injuries were the result of gunfire from Russian, Lesgian,<sup>1</sup> or Asian rifles. The differences he observed in the gunshot wounds he

<sup>1</sup> Lesgians, or Lesghis (from the Persian Leksi, called Leki by the Grusians or Georgians, Armenians and Ossetes), the collective name for a number of tribes of the eastern Caucasus.



**Fig. 6.** A reproduction of Figure XII from N.I. Pirogov's *Atlas on Pathological Anatomy of the Asian Cholera*. It represents a rare example of what Pirogov referred to as "diphtheria-cholera" in the gastric mucosa. The mucous membrane of the stomach is hyperemic and swollen, covered with a thin layer of gray colored exudate with a granular structure (Pirogov, 1849b). (In public domain). [Color figure can be viewed at [wileyonlinelibrary.com](http://wileyonlinelibrary.com)]

attributed to the weapons used and the size and weight of the bullets. The Russian bullets were larger and heavier with a low velocity in contrast to those used by the Lesgian and Asian troops. Their rifles used bullets that had a high velocity. Pirogov noted that the entry and the exit wounds of these Asian bullets were similar, and the wounds were hardly visible. In contrast, the lower velocity Russian bullets caused considerably greater damage. He considered a gunshot wound the headache of a surgeon because "...an injury produced by a bullet must be seen as the path of a fistula, which needs to be opened to give passage to the pus that constantly accumulates and let the law of hydraulics do its work..." (Pirogov, 1849a). The availability of anesthesia allowed Pirogov to carry out a much greater examination of the soldiers with large


bone fractures caused by gunshots (Pirogov, 1849a; Hendriks et al., 2018).

After the Caucasian conflict, Pirogov was able to put the experience he had gained to good use. In 1862, he was asked for a consultation by the surgeons treating the Italian freedom fighter Giuseppe Garibaldi, who had been shot in his foot during the Italian unification conflict (Pirogov, 1864). None of the surgeons from Italy, Britain, or France could decide where the bullet was located, and thus the best method of treatment. Pirogov was able to determine that the bullet was located at the lower part of the tibia close to the lateral malleolus. He advised a conservative treatment, that is, no immediate surgical intervention to remove the bullet. Pirogov's advice was followed and within 6 weeks the bullet had spontaneously migrated to just under the skin and was easily removed. The patient made a full recovery and in a letter, Garibaldi warmly thanked Pirogov, "My dear doctor Pirogov! My wound has almost healed. I feel the need to thank you for the cordial care that you lent me generously. Accept, dear doctor, my guarantees of devotion. Your Giuseppe Garibaldi" (Garibaldi, 1863).

In 1850, Nikolay Pirogov produced an anatomical atlas with illustrations in color, which was published by the *Military Medical Journal*, and which still exists today (Pirogov, 1850a) (Fig. 8). The journal editors decided to reproduce Pirogov's anatomical drawings using lithography in order to preserve the elegance and accuracy of the originals. However, because of the considerable costs involved in producing each individual lithograph, it was published in limited edition. This allowed the price to be kept lower and more affordable for those involved in anatomy, especially for the forensic specialist, as both Pirogov and the editors considered it a textbook for those carrying out autopsies. It was difficult to reproduce the lithographs in the atlas because of the small dimensions requested, not only for the journal itself, but also for the five engravers involved.

### Three-Dimensional Topographic Anatomy of the Human Body

When visiting the local meat market during the cold winter of 1846, Pirogov noticed in a butcher's shop the frozen carcasses of pigs on display. The carcasses had been sliced open and gave a clear view of the positions of the animals internal organs (Vasiliev, 1947). He realized that he could also take advantage of the cold Russian winters to freeze cadavers "to the density of the thickest wood" and then cut them into thin slices. This would allow him to describe the topographical anatomy of the human body in a detail never before attempted. It would allow him to overcome one of the problems associated with the standard approach to determining the exact location of organs within the living body. During an autopsy, the incisions made in the corpse, and the opening of the body cavities, can cause the position of the internal organs to change. This is especially the case when the

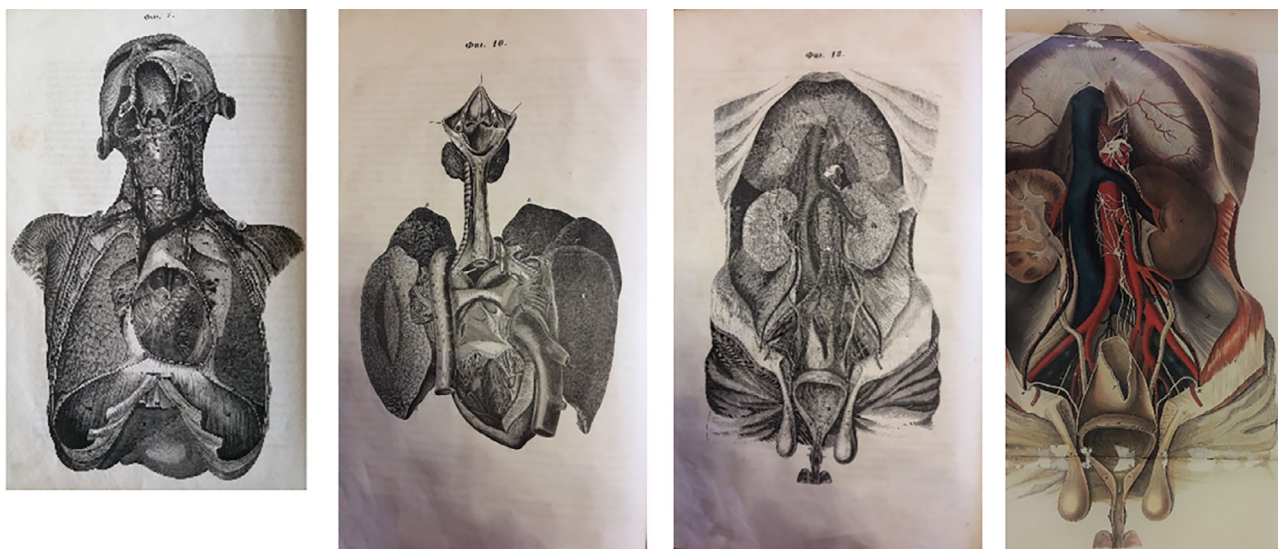


**Fig. 7.** Drawings of the anatomy of the lower arm and hand from N.I. Pirogov (Pirogov, 1844). (In public domain). [Color figure can be viewed at [wileyonlinelibrary.com](http://wileyonlinelibrary.com)]

abdomen or the thoracic cavity is opened; the intestines fall away from the abdominal wall and in the thorax the lungs collapse.

Pirogov and his team studied cadavers that had been frozen to at least  $-15^{\circ}\text{C}$  (Pirogov, 1852). As director of the Medical Instruments Factory in Saint Petersburg, Pirogov was able to use its facilities to make a special mechanical saw constructed along the lines of those used by furniture makers, which

allowed him to make cuts of  $1$ ;  $\frac{1}{2}$ ; or  $\frac{1}{4}$  cm thickness. Pirogov was of course aware that thin cuts in only one direction would not allow the exact location of organs to be determined. What was needed was to make cuts in several directions and when the images were finally observed in the correct order the result would be a three-dimensional effect. Pirogov made, in different cadavers, a series of transverse, longitudinal, and anteroposterior cuts. Rectangular grids were drawn



**Fig. 8.** Plates 7, 10, and 13 from N.I. Pirogov (Pirogov, 1850a) showing the external appearance and positions of organs in the thoracic and abdominal cavities of the human body. (In public domain). [Color figure can be viewed at [wileyonlinelibrary.com](http://wileyonlinelibrary.com)]

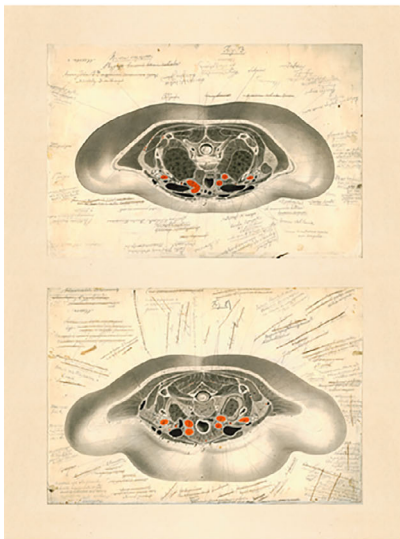


Plate I

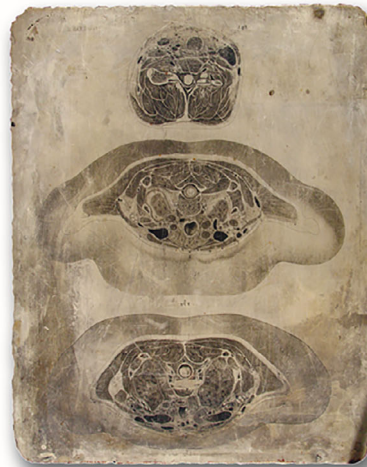

Plate II

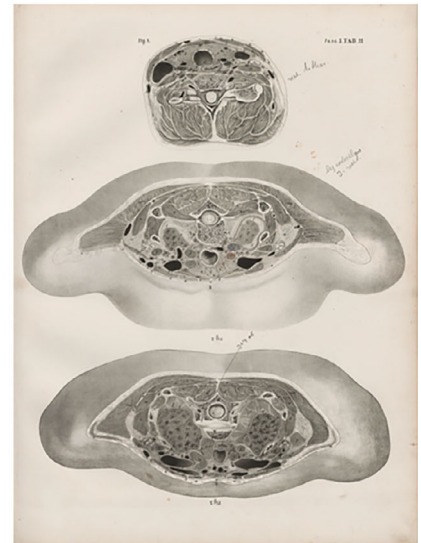


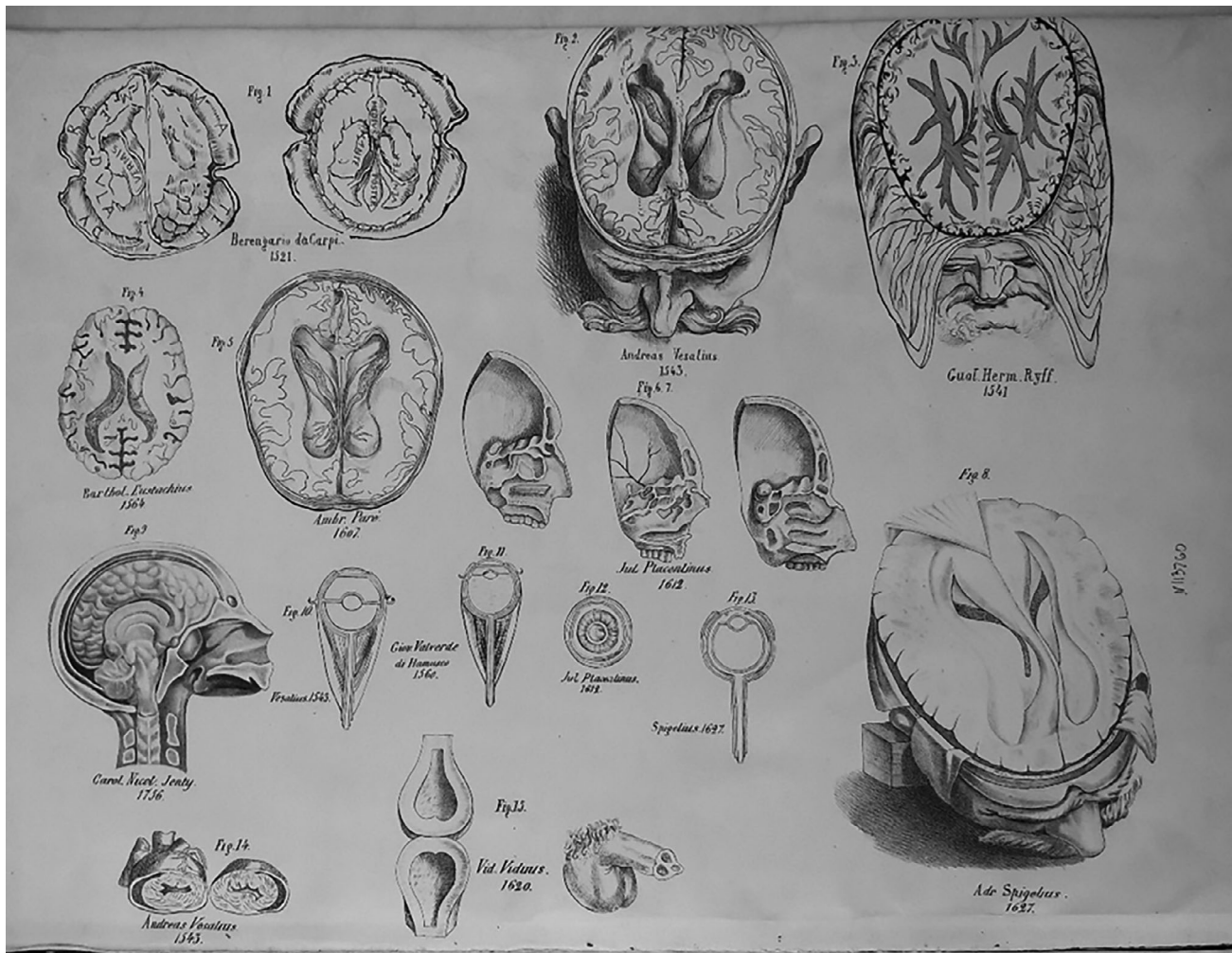
Plate III

**Fig. 9.** Plate I, The original drawings in their original size and the handwritten explanation by Nikolay Pirogov, exhibited in the Nikolay I. Pirogov Museum in the Military Medical Museum in Saint Petersburg, Russian Federation. Reproduced with permission from the Military Medical Museum of the Ministry of Defense of the Russian Federation, Saint Petersburg. Plate II, The marble stone on which the body cuts are engraved in their original size, exhibited in the Nikolay I. Pirogov Museum in the Military Medical Museum in Saint Petersburg, Russian Federation. Reproduced with permission from the Military Medical Museum of the Ministry of Defense of the Russian Federation, Saint Petersburg. Plate III, The drawings as in Plates I and II printed on page 18, Volume I of Pirogov's atlas of Topographic Anatomy (Pirogov, 1853a). (In public domain). [Color figure can be viewed at [wileyonlinelibrary.com](http://wileyonlinelibrary.com)]

on a sheet of paper on a glass plate that was placed over the cut. An accurate drawing was made of the cut, which allowed the detailed position and appearance of the various parts of the body to be recorded on marble in their natural position (Fig. 9). To improve the separation of organs and structures such as plural folds, peritoneum, glands, and heart valves, the cuts were first rinsed with warm water to remove frozen blood or serous fluids. The frozen layers were then allowed to thaw gradually, and pieces of ice carefully removed with an anatomical tweezer. In addition to the three-dimensional cuts they used another method, which Pirogov named the sculptural method. This method displays the complex position of the abdominal organs. This involved using a chisel and hammer to carefully remove ice from areas that were frozen hard. After 8 years of work, Pirogov published his atlas of topographical anatomy in four volumes (Pirogov, 1852, 1853a, 1853b, 1853c, 1859). The fifth volume described and explained in detail the contents of plates in the first four volumes. The atlas had become a rarity by the beginning of the 20th century but was reprinted in 1997 for a limited edition of 500 copies (Lichterhan, 2008).

Pirogov did not claim originality in the use of his three-dimensional method; he was aware of the

topographical atlases produced by earlier anatomists based on the anatomy found during autopsies (Standing, 2016) (Fig. 10). Later, longitudinal cuts of the skull, the eye, ear, uterus, and penis were found in the works of Valverde, A. Spigeli, Weseling, and others (Pirogov, 1859). Other famous anatomists such as A. Haller and C.T. Semmering preferred simple drawings instead of the exact cuts made by Pirogov. Later in the 18th-century Peter Camper was the first to make copper engraving of a longitudinal cut of the male pelvis. The Edinburg anatomist, John Lizars, produced a topographical atlas with over 100 engraved colored plates in 12 parts from 1822 to 1826 with a separate explanatory text. A later edition was published in 1840 (Lizars, 1822–1826). However, Pirogov did claim that nobody before him had used a method similar to his, namely making thin cuts on a frozen human corpse to achieve a three-dimensional image. Nor did he claim that his method was the only sufficiently accurate method to locate the exact position of the organs. On the contrary, he thought his method and the traditional methods should be used together for the most effective study of the position of organs. His method was not only useful for topographical anatomy, but also for histology and pathology. He added drawings showing the position of organs whose location had been changed by disease.



**Fig. 10.** Reproduced from N.I. Pirogov (Pirogov, 1853a) comparing anatomical drawings published by various anatomists; Berengario de Capri, Andreas Vesalius, Guaf. Herm. Ryff, Barthol. Eustachius, Ambr. Parré, Julius Placentinus, Carol. Nicol. Jenty, Giovan Valverde di Humasco, Adr. Spigelius, Vid. Viduus, Plate 0053. (In public domain).

The first drawings of the cuts using both methods, which he performed on frozen corpses in 1836, were published in Saint Petersburg in 1852 (Pirogov, 1852). Two years later he submitted the first pages of the manuscript to the Parisian Academy of Sciences for their acknowledgement. This was the standard method to have a manuscript internationally accepted in the 19th century—the equivalent to the peer-review process today (Perpetuelles, 1857). Four years later, the Parisian Academy announced that a French doctor had made numerous slices of frozen corpses and won a prize named after the Montyon Foundation (Perpetuelles, 1857).

Nikolay Pirogov received a letter dated 10 August 1862 about his three-dimensional topographic atlas from the renowned French surgeon, Félix Hippolyte Larrey (1808–1895), in which he praised the quality of the atlas and asked Pirogov's permission to discuss

the atlas with his French medical colleagues (Larrey, 1862). In a second letter dated 9 February 1869, he informed Pirogov that after discussion with his colleagues they had decided to promote both the atlas and his textbook on military surgery (Larrey, 1869) in France.

The topographical atlas was Pirogov's last work on medicine before he took part in the Crimean War (1854–1856). After the Crimean War, he resigned his position at the Imperial Medico-Surgical Academy and focused more on education and supervising students during their foreign internship in Germany. He became involved with the development of and consultancy for the Red Cross societies. Nikolay Pirogov died on 5 December 1881 at his estate in Vishnya (now Vinnytsia in Ukraine). In 1897, during the XII International Congress of Medicine in Moscow, attended by approximately 10,000 physicians from all over the world, Pirogov was posthumously



honored with the following statement and also a monument of him erected in his honor:

For a long time two main directions existed in surgery: empiricism and theory. For centuries, the practice of our art was in the hands of artisans, who in the barber shop climbed from apprentice to companion. There was no more theory here than with other crafts. The predominantly technical nature of surgery could not derive general concepts and scientific guidelines from its operations. This only took shape when lessons were learned from science, which so far had no connection with surgery, and this science organically learned to connect with surgery.

The first scientific principle that appeared in surgery after the development of the medical sciences was anatomy. Ambroise Pare, "the first barber of kings," as he called himself, had also worked as a dissector on the anatomical floor, symbolizing the merger of barber-surgeon with anatomy. Jean Louis Petit, Desault, and Bichat are then the other formidable landmarks in the scientific development of surgery. When we go outside to the Djevichje field here in Moscow, we are vividly reminded of this combination of surgery and anatomy. We can see from the beautiful and historical true monument of Pirogov that, among his many other accomplishments, he also had the great merit of contributing to the introduction of anatomy into surgery (Braatz, 1899).

Pirogov's passion for anatomy arose from his strongly held belief that surgery could only function if it was closely coupled to anatomy. Based on his knowledge of anatomy he invented a number of surgical operations, the best known of which, the osteoplastic foot amputation, is named after him. Today, his contribution to anatomy is remembered in a number of anatomical structures named after him. The Pirogov triangle is a triangular area between the intermediate tendon of the digastric muscle and the hypoglossal nerve. The Pirogov angle (or venous angle) lies at the junction of the internal jugular and the subclavian veins; and the Pirogov aponeurosis, also known as the biceps aponeurosis, is a broad aponeurosis of the biceps muscle in the cubital fossa of the elbow separating superficial from deep structures in much of the fossa.

## ACKNOWLEDGMENTS

The authors are grateful for the immense and generous help and support they received from Mrs. Liudmila B. Narusova, President of the Anatoly Sobchak Foundation, for allowing access to the archives and libraries of museums and of scientific institutes in Saint Petersburg. We are also very thankful to Prof. Dr. A.A. Budko, director of the Military Medical Museum and his staff, and to Prof. Dr. A. Ya. Fisun, general director of the Military Medical

Academy in Saint Petersburg and his staff for their kind support and enthusiasm.

## REFERENCES

- Abashin VG, Tsvelev I. 2009. Doctor Medicinae Nikolaas Bidloo, Serving Russia. Saint Petersburg: Voенно-медицинская академия им. S.M.Kirov.
- Adstrom S, Nicholson H. 2019. A history of fascia. *Clin Anat* 32(7): 862–870.
- Anonymous. 1836–1837. Ligature of the Carotid Artery for Aneurysm of the Arteria Innominata. London: The Lancet.
- Anonymous. 1847. On 11 February 1847 in the Second Military Land Force Hospital was performed surgery without pain during the amputation of a female right breast while using of inhalation of sulfuric ether vapour. *Drug Zdraviya, Vrachebnaya Gazeta* 15: 57–64.
- Anonymous. 1911a. Brasdor, Pierre. In: Chisholm H, editor. *Encyclopaedia Britannica*. 11th Ed. Cambridge, UK: Cambridge University Press.
- Anonymous. 1911b. Cooper, Sir Astley Paston. In: Chisholm H, editor. *Encyclopaedia Britannica*. 11th Ed. Cambridge: Cambridge University Press. p 79.
- Anonymous. 1989. Astley Cooper. In: *The New Encyclopaedia Britannica*. Vol. 3. 15th Ed. p 302.
- Bettany GT. 1887. Cooper, Astley Paston. In: Stephen L, editor. *Dictionary of National Biography*. London: Smith, Elder & Co. p 137–139.
- Bigelow HJ. 1846. Insensibility during surgical operations produced by inhalation. *Boston Med Surg J* 35:309–317.
- Braatz E. 1899. Section IX: Surgery. In: Roth W, editor. *Minutes XII International Congress of Medicine*. Moscow, 7(19)–14 (26) August 1897. Vol. 5. Moscow: S.P. Yakovlev, Saltykovskii Pereuouluok 9. p 320–336.
- Fearn SW. 1836–1837. Case of Aneurysm of the Arteria Innominata and of the Origin of the Subclavian Artery, Treated by Ligature of the Common Carotid Artery. London: The Lancet.
- Gaivoronskii IV. 2018. Historical Essay on the Department of Normal Anatomy of the Military-Medical (Medical-Surgical) Academy. (On the 220th Anniversary of the Foundation of the Department). Saint Petersburg: SpetsLit.
- Garibaldi G. 1863. A Letter from G. Garibaldi with Thanks for the Treatment. Saint Petersburg, Russian Federation: Fundamental Library of the Military Medical Academy. p In Ed.Ep.III-38: 35.
- Geselevich AM. 1956. In: Bakulev AN, editor. *Scientific, Literary and Epistolary Heritage of Nikolay Ivanovich Pirogov*. Moscow: State Publisher of Medical Literature.
- Haas LF. 1994. Francois François Magendie (1783–1855). *J Neurol Neurosurg Psychiatry* 57:692.
- Hendriks IF, Bovill JG, Boer F, Houwaart ES, Hogendoorn PCW. 2015. Nikolay Ivanovich Pirogov: A surgeon's contribution to military and civilian anaesthesia. *Anaesthesia* 70:219–227.
- Hendriks IF, Bovill JG, van Luijt PA, Hogendoorn PCW. 2018. Nikolay Ivanovich Pirogov (1810–1881): A pioneering Russian surgeon and medical scientist. *J Med Biogr* 26:10–22.
- Hernigou P, Gravina N, Potage D, Dubory A. 2017. History of club-foot treatment; Part II: Tenotomy in the nineteenth century. *Int Orthop (SICOT)* 41(10):2205–2212.
- Kichigina G. 2009. *The Imperial Laboratory. Experimental Physiology and Clinical Medicine in Post-Crimean Russia*. Amsterdam, NY: Editions Rodopi.
- Kuzmin MK, Sorokina TS. 1984. *Medicine in ancient Russia*. *Feldsher Akush* 49:31–37.
- Larrey FH. 1862. Letter to Nikolay I. Pirogov, 19 August 1862. Saint Petersburg, Russian Federation: Fundamental Library of the Military Medical Academy, nemd S.M. Kirov. p In Ed.Ep.III-44: 24.

- Larrey FH. 1869. Letter to Nikolay I. Pirogov, 9 February 1869. Saint Petersburg, Russian Federation: Fundamental Library of the Military Medical Academy. p In Ed.Ep.III-44: 25–26.
- Lazorthes GC. 1984. François Magendie (1783–1855). *Bull Acad Natl Med* 168:105–111.
- Legallois E. 1824. Oeuvres de J.J.C. Legallois avec des notes de M. Pariset. In Two Volumes. Paris.
- Lichterman B. 2008. Ice Anatomy by Nikolai Pirogov First Published 1851–9. *BMJ* 336:725.
- Likhachev DS. 2003. Tale of the Bygone Years. Here Is the Tale of the Bygone Years, where the Russian Land Came from, Who in Kiev Was the First Ruler, and How the Russianland Arose. Moscow, Augsburg: Im Werden Verlag.
- Lizars J. 1822. 26. A System of Anatomical Plates of the Human Body. In Three Volumes. Edinburgh: W.H. Lizars.
- Oborin NA. 1990. The first Centre for Higher Medical Education in Russia. (For the 280th anniversary of the Moscow hospital and the Moscow medical-surgical school—the Military Medical Academy named S.M. Kirov). *Klin Med (Mosk)* 68:118–121.
- Perpetuelles S. 1857. *Compte de rendus hebdomadaires des seances de l'academie publies conformement a une decision de l'academie*. Paris. p 175.
- Pirogoff NI. 1838a. Über die Möglichkeit der Unterbindung der Aorta abdominal. *Schluss. J Chir Augenheilkd* 27:241–259.
- Pirogoff NI. 1838b. Über die Möglichkeit der Unterbindung der Aorta abdominalis. *J Chir Augenheilkd* 27:122–146.
- Pirogov NI. 1832. Is Ligation of the Abdominal Aorta with an Aneurysm of the Groin a Readily Feasible and Safe Intervention?. Dorpat, Livonia: J.C. Schönmann.
- Pirogov NI. 1838. Surgical Anatomy of the Arterial Trunks and the Fibrous Fasciae. 1st Ed. Dorpat: C.A. Kluge.
- Pirogov NI. 1839. *Annals of the Surgery Department of the Clinic at the Imperial University of Dorpat* in 2 Volumes. Vol. II. Dorpat, Imperial Russia: C.A. Kluge.
- Pirogov NI. 1840. About the Intersection of the Achilles Tendon as an Operational-Orthopaedic Medicine. Dorpat: Franz Kluge.
- Pirogov NI. 1844. Full Course of Applied Anatomy of the Human Body with Drawings. Descriptive-Physiological and Surgical Anatomy. Saint Petersburg: Unknown.
- Pirogov NI. 1847a. New method for generating, by means of ether vapour, insensitivity in individuals subjected to surgical operations. *Comptes Rendus. Academie des Sciences. Séances de l'academie des sciences. Quai des Augustis, nr 55: Bachelier, Imprimeur-Libraire de l'école polytechnique, du bureau des longitudes, etc.* p 789–791.
- Pirogov NI. 1847b. *Practical and Physiological Research on Etherization* by N. Pirogoff. Saint Pétersbourg, Russia: Fd Bellizard et Co., Libraires—éditeurs, au pont de police, maison de l'Église Hollandaise.
- Pirogov NI. 1849a. Medical Report of a Journey to the Caucasus, Containing Statistical Comparison of Amputations, Experimental Research of Firearms Injuries, and a Detailed Description of the Anaesthesia Results, Obtained on the Battlefield and in Different Hospitals in Russia. 1st Ed. Saint Petersburg: Printing House of the Journal of Saint Petersburg.
- Pirogov NI. 1849b. *Pathological Anatomy of the Asian Cholera*. Atlas. Saint Petersburg: Karl Kray.
- Pirogov NI. 1850a. *Anatomical Images of the External Appearance and Position of Organs in the Three Main Cavities of the Human Body, Designated Primarily for Forensic Doctors. With Full Explanation*. Saint Petersburg: The Military Medical Journal.
- Pirogov NI. 1850b. *Pathological Anatomy of the Asian Cholera. From Observations of the Epidemic Prevailing in Russia in 1848*. Saint Petersburg: Karl Kray.
- Pirogov NI. 1852. *An Illustrated Topographic Anatomy of Saw Cuts Made in Three Dimensions across the Frozen Human Body*. Four Volumes, Vol. II, Thoracic Cavity. Petropoli: Yakob Trey.
- Pirogov NI. 1853a. *An Illustrated Topographic Anatomy of Saw Cuts Made in Three Dimensions across the Frozen Human Body*. Four Volumes. Vol. I. Petropoli: Yakobi Trey.
- Pirogov NI. 1853b. *An Illustrated Topographic Anatomy of Saw Cuts Made in Three Dimensions across the Frozen Human Body*. Four Volumes. Vol. III, Abdominal and Pelvic Cavity. Petropoli: Yakob Trey.
- Pirogov NI. 1853c. *An Illustrated Topographic Anatomy of Saw Cuts Made in Three Dimensions Across the Frozen Human Body*. Four Volumes. Vol. IV, Extrimitates. Petropoli: Yakob Trey.
- Pirogov NI. 1854. *Clinical Surgery*. Collection of Monographs in 3 Volumes. Vol. I: Osteoplastic Extension of the Lower Leg Bones in the Disarticulation of the Foot. Reflections on the Difficulty of the Surgical Diagnosis and the Good Fortune in Surgery, Illustrated by Observations and Case Histories. Leipzig: Breitkopf und Härtel.
- Pirogov NI. 1859. *An Illustrated Topographic Anatomy of Saw Cuts Made in Three Dimensions Across the Frozen Human Body*. Four Volumes Between 1852 and 1859. Saint Petersburg: Petropoli.
- Pirogov NI. 1864. *Broad Guidelines for General War Surgery, According to Reminiscences from the Wars in the Crimea and the Caucasus and from the Hospital Practice*. Leipzig: Verlag von F.C.W. Vogel.
- Pirogov NI. 1957. *Collected Works in 8 Volumes*. Vol. I: Proceedings of Experimental and Clinical Surgery (1832–1840). Moscow: Gosudarstvennoe Izdatelstvo Meditsinskoy Literatury.
- Pirogov NI. 1990. *Questions of Life*. Diary of an Old Physician. Edited and with a New Introduction by Galina V. Zarechnak, Ph.D. Canton, OH: Science History Publications.
- Pirogov NI. 1992. *Researches Practical and Physiological on Etherization*. English Translation by B. Raymond Fink from the French Original. Park Ridge, IL: Wood Library Museum of Anesthesiology.
- Pirogov NI. 2011. *Questions of Life*. Diary of an Old Physician, Written Exclusively for himself, but Not without a Second Thought, that May Be Somewhere Somebody Will Read it Also. 5 November 1879–22 October 1881]. Reprinted by the publisher. North-West, Russia: Knigovek Knizhny Klub.
- Richter WM. 1817. *History of Medicine in Russia*. Vol. III. 1st Ed. Moscow: N.S. Wsewolojsky.
- Shabinin AV, Zhuravlev DA. 2004. The year 1847 in the life and works of N.I. Pirogov. *Vestnik Istorii Voennoy Meditsiny* 4:128–134.
- Shampo MA, Kyle RA. 1987. François Magendie: Early French physiologist. *Mayo Clin Proc* 65(5):412.
- Sorokina TS. 2008. *History of Medicine*. Moscow: Academia.
- Standing S. 2016. A brief history of topographical anatomy. *J Anat* 229:32–62.
- Stromeyer GFL. 1833. Die Durchschneidung des Achillessehne, als Heilmethode des Klumpfusses, durch zwei Falle erlautert. *Mag ges Hielk (Rust)* 39:195.
- Szymanowski J. 1860. Nicol. Pirogff's Surgical Anatomy of Arterial Trunks and Fascia with 50 Drawings. Re-Edited by Julius Szymanovski. Leipzig und Heidelberg: C.F. Winter's Verlagshandlung.
- Vasiliev C. 1947. Pirogov. 1st Ed. Leningrad: Lenfilm p 1 hour 32 minutes.
- Virchow R. 1852. *Pathological anatomy of cholera-Morbus*. Carl Christian Schmidt's Jahrbücher der in- und ausländischen gesammten Medicin 73:359–377.
- Wikipedia. 2019a. Karl Ernst von Baer. URL: [en.wikipedia.org/wiki/Karl\\_Ernst\\_von\\_Baer](https://en.wikipedia.org/wiki/Karl_Ernst_von_Baer) [accessed 01 July 2019].
- Wikipedia. 2019b. Simon Plössl. URL: [en.wikipedia.org/wiki/Simon\\_Plössl](https://en.wikipedia.org/wiki/Simon_Plössl) [accessed 03 July 2019].
- Zhorov IS. 1951. *Development of Surgical Anaesthesia in Russia and the USSR: Minutes of Experience* by NI Pirogov December 21, 1847 at the University of Moscow to Study the Direct Action of Chloroform on the Nervous System with the Assistance of Dissector Alexey N. Orlovsky. Moscow: Academy Medical Science.