



**Universiteit
Leiden**
The Netherlands

Electroanatomical voltage mapping to distinguish right-sided cardiac sarcoidosis from arrhythmogenic right ventricular cardiomyopathy

Hoogendoorn, J.C.; Sramko, M.; Venlet, J.; Siontis, K.C.; Kumar, S.; Singh, R.; ... ; Zeppenfeld, K.

Citation

Hoogendoorn, J. C., Sramko, M., Venlet, J., Siontis, K. C., Kumar, S., Singh, R., ... Zeppenfeld, K. (2020). Electroanatomical voltage mapping to distinguish right-sided cardiac sarcoidosis from arrhythmogenic right ventricular cardiomyopathy. *Jacc: Clinical Electrophysiology*, 6(6), 696-707. doi:10.1016/j.jacep.2020.02.008

Version: Publisher's Version
License: [Creative Commons CC BY 4.0 license](https://creativecommons.org/licenses/by/4.0/)
Downloaded from: <https://hdl.handle.net/1887/3232568>

Note: To cite this publication please use the final published version (if applicable).

Electroanatomical Voltage Mapping to Distinguish Right-Sided Cardiac Sarcoidosis From Arrhythmogenic Right Ventricular Cardiomyopathy



Jarieke C. Hoogendoorn, MD,^a Marek Sramko, MD, PhD,^{a,b} Jeroen Venlet, MD,^a Konstantinos C. Siontis, MD,^c Saurabh Kumar, BSc(Med)/MBBS, PhD,^d Robin Singh, MD,^d Ikutaro Nakajima, MD,^e Sebastiaan R.D. Piers, MD, PhD,^a Marta de Riva Silva, MD,^a Claire A. Glashan, MD,^a Thomas Crawford, MD,^c Usha B. Tedrow, MD,^d William G. Stevenson, MD,^e Frank Bogun, MD, PhD,^c Katja Zeppenfeld, MD, PhD^a

ABSTRACT

OBJECTIVES This study sought to investigate the value of electroanatomical voltage mapping (EAVM) to distinguish cardiac sarcoidosis (CS) from arrhythmogenic right ventricular cardiomyopathy (ARVC) in patients with ventricular tachycardia from the right ventricle (RV).

BACKGROUND CS can mimic ARVC. Because scar in ARVC is predominantly subepicardial, this study hypothesized that the relative sizes of endocardial low bipolar voltage (BV) to low unipolar voltage (UV) areas may distinguish CS from ARVC.

METHODS Patients with CS affecting the RV (n = 14), patients with gene-positive ARVC (n = 13), and a reference group of patients without structural heart disease (n = 9) who underwent RV endocardial EAVM were included. RV region-specific BV and UV cutoffs were derived from control subjects. In CS and ARVC, segmental involvement was determined and low-voltage areas were measured, using <1.5 mV for BV and <3.9 mV, <4.4 mV, and <5.5 mV for UV. The ratio between low BV and low UV area was calculated generating 3 parameters: Ratio_{3.9}, Ratio_{4.4} and Ratio_{5.5}, respectively.

RESULTS In control subjects, BV and UV varied significantly among RV regions. The basal septum was involved in 71% of CS patients and in none of ARVC patients. Ratio_{5.5} discriminated CS from ARVC the best. An algorithm including Ratio_{5.5} ≥ 0.45 and basal septal involvement identified CS with 93% sensitivity and 85% specificity. This was validated in a separate population (CS [n = 6], ARVC [n = 10]) with 100% sensitivity and 100% specificity.

CONCLUSIONS EAVM provides detailed information about scar characteristics and scar distribution in the RV. An algorithm combining Ratio_{5.5} (area BV <1.5 mV/area UV <5.5 mV) and bipolar basal septal involvement allows accurate diagnosis of (isolated) CS in patients presenting with monomorphic ventricular tachycardia from the RV. (J Am Coll Cardiol EP 2020;6:696–707) © 2020 the American College of Cardiology Foundation. Published by Elsevier. All rights reserved.

From the ^aDepartment of Cardiology, Willem Einthoven Center for Cardiac Arrhythmia Research and Management, Leiden University Medical Center, Leiden, the Netherlands; ^bDepartment of Cardiology, Institute for Clinical and Experimental Medicine, Prague, Czech Republic; ^cDepartment of Cardiology, University of Michigan, Ann Arbor, Michigan, USA; ^dDepartment of Cardiology, Brigham and Women's Hospital, Boston, Massachusetts, USA; and the ^eDepartment of Cardiology, Vanderbilt Medical University Center, Nashville, Tennessee, USA. The Department of Cardiology from Leiden University Medical Center receives unrestricted grants from Edwards Lifesciences, Biotronik, Medtronic, Boston Scientific, and Biosense Webster. Dr. Sramko was supported by the Research Fellowship of the European Society of Cardiology (2017/2018). Dr. Tedrow has received honoraria from Abbott Medical and Biosense Webster; and has served as a consultant for ThermoCardia. Dr. Stevenson has received speaking honoraria from Boston Scientific, Abbott, Biotronik, and Johnson and Johnson; and is a co-holder of a patent for irrigated needle ablation that is consigned to Brigham Hospital. All other authors have reported that they have no relationships relevant to the contents of this paper to disclose. Francis Marchlinski, MD, served as Guest Editor for this paper.

The authors attest they are in compliance with human studies committees and animal welfare regulations of the authors' institutions and Food and Drug Administration guidelines, including patient consent where appropriate. For more information, visit the JACC: Clinical Electrophysiology [author instructions page](#).

Manuscript received October 15, 2019; revised manuscript received January 13, 2020, accepted February 20, 2020.

Cardiac sarcoidosis (CS) and arrhythmogenic right ventricular cardiomyopathy (ARVC) are important causes of ventricular tachycardia (VT) from the right ventricle (RV) (1), and can have similar phenotypes (2).

CS is a granulomatous disease of unknown etiology, histologically characterized by the presence of well-demarcated areas of non-necrotizing granulomas (3). The diagnosis of CS is based on a positive endomyocardial biopsy (EMB) or either myocardial fluorodeoxyglucose (^{18}F -FDG) positron emission tomography (PET) uptake or evidence of extracardiac sarcoidosis with signs of cardiac involvement (Supplemental Table 1) (4,5). However, up to 40% of patients who die suddenly due to CS have no extracardiac involvement (3). Isolated CS might be underdiagnosed, owing to the low diagnostic yield of EMB (20% to 30%) (4), particularly if myocardial ^{18}F -FDG-PET uptake is negative (6,7).

SEE PAGE 708

ARVC is an inherited cardiomyopathy, leading to fibrofatty replacement of myocardium. According to the revised Task Force Criteria (TFC) (8), neither fibrofatty replacement on EMB nor a pathogenic mutation are mandatory to diagnose “definite” ARVC, making the TFC rather nonspecific for distinguishing ARVC from other cardiomyopathies with RV involvement (2,9).

It is crucial to distinguish between these 2 diseases, as CS may respond to immunosuppressive therapy and warrants close follow-up for deterioration of ventricular function, whereas ARVC requires family screening (4,10).

ARVC appears to start at the subepicardium, such that the extent of epicardial involvement exceeds the area of endocardial involvement, and rarely involves the septum. In contrast, CS is varied in its distribution of cardiac involvement and often involves the septum. Although cardiac imaging may not reliably detect the histopathological differences in epicardial and endocardial involvement in the thin-walled RV, electroanatomical voltage mapping (EAVM) has the potential for defining endocardial and epicardial scar, manifesting as low voltage (11,12). We hypothesize that transmural and well-demarcated scar in CS may manifest as areas with diminution in both endocardial unipolar voltage (UV) and bipolar voltage (BV) (12), while the heterogeneous and subepicardial scar in ARVC may lead to areas with reduced UV but preserved BV (13).

Accuracy of voltage mapping could be influenced, however, by regional differences in wall thickness (14) and adjacent fibrous tissue from valve annuli,

even in normal hearts. This is not considered when applying singular voltage cutoffs for BV and UV in the RV (15–18).

This study therefore aims: 1) to evaluate the regional distribution of BV and UV in the RV in a reference population; and 2) to determine RV EAVM scar patterns and characteristics in CS and ARVC.

METHODS

STUDY POPULATION. Patients with CS (according to Japanese or Heart Rhythm Society guidelines) (4,5) with RV involvement and patients with definite ARVC (according to the TFC) (8) with a pathogenic mutation, who presented with monomorphic sustained VT and underwent RV endocardial EAVM between 2011 and 2018 at 3 centers (Boston, Massachusetts; Leiden, the Netherlands; Ann Arbor, Michigan), were retrospectively included. RV involvement was defined as clinical VTs suggestive of RV origin, in combination with a target ablation site in the RV. Patients with insufficient mapping density (fill threshold >15 mm) were excluded.

The reference group consisted of patients without structural heart disease referred for RV mapping and ablation of premature ventricular complexes. The study was approved by the local ethical committee (G19.005). All patients provided pre-procedural informed consent.

DATA COLLECTION. EAVM was performed during sinus rhythm or RV pacing using CARTO 3 (Biosense Webster, Diamond Bar, California) and a 3.5-mm-tip catheter (NaviStar ThermoCool [n = 19], ThermoCool SmartTouch [n = 5], or Thermocool Nav BiDirectional [n = 3]; Biosense Webster). Electrograms (EGMs) were filtered at 30 to 400 Hz (bipolar) and 1 to 240 Hz (unipolar). Information regarding electrocardiography, imaging (including echocardiography, cardiac magnetic resonance [CMR], cardiac computed tomography, and ^{18}F -FDG-PET), endomyocardial biopsy, and presence of cardiac devices was collected from medical records. The echocardiogram and ^{18}F -FDG-PET data included were those obtained at time closest to procedure (within 6 months).

PROCESSING AND ANALYSIS OF EAVM. EGMs were displayed at the same gain (0.12 mV/cm for BV and 1.0 mV/cm for UV) and sweep speed (200 mm/s) on CARTO. Points with a stable catheter position and adequate contact were selected based on review of all EGMs for stable cycle length, local activation time,

ABBREVIATIONS AND ACRONYMS

^{18}F -FDG = ^{18}F -

fluorodeoxyglucose

ARVC = arrhythmogenic right ventricular cardiomyopathy

AV = atrioventricular

BV = bipolar voltage

CMR = cardiac magnetic resonance

CS = cardiac sarcoidosis

EAVM = electroanatomical voltage mapping

EGM = electrogram

EMB = endomyocardial biopsy

LGE = late gadolinium enhancement

LVEF = left ventricular ejection fraction

PET = positron emission tomography

RV = right ventricle

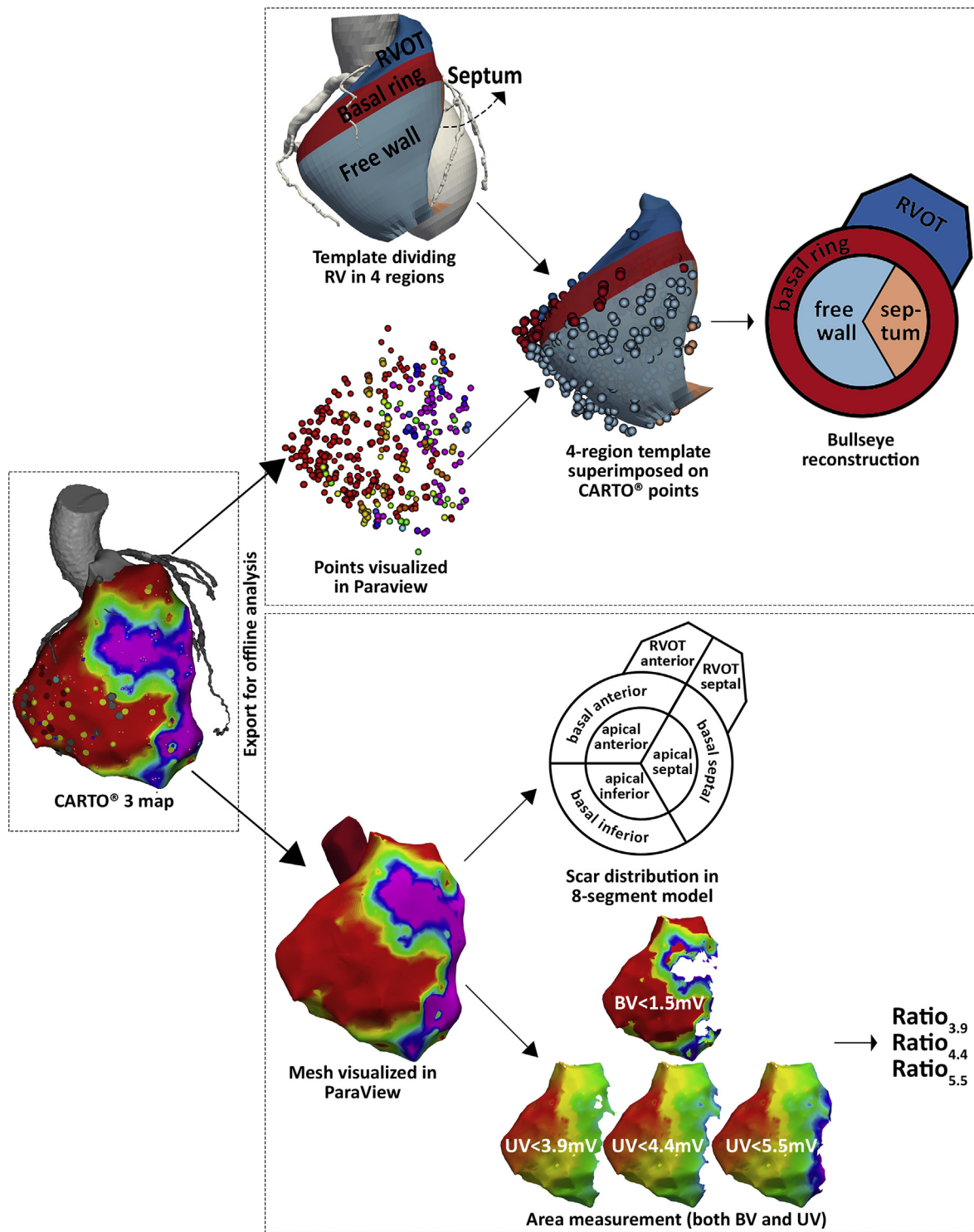
RVOT = right ventricular outflow tract

TFC = Task Force Criteria

UV = unipolar voltage

VT = ventricular tachycardia

FIGURE 1 Methods and Workflow as Described in the Methods Section



BV = bipolar voltage; RV = right ventricle; RVOT = right ventricular outflow tract; UV = unipolar voltage.

and voltage during 3 consecutive beats. Points taken during ablation or ectopic beats, floating points, and points tagged as location only, unexcitable scar, or valve annulus were excluded.

After EGM analysis, the anatomical surfaces and 3-dimensional coordinates of selected mapping points with their corresponding BV and UV were exported for offline analysis using ParaView 5.4.1. (Kitware Inc., Clifton Park, New York). Anatomical mesh files were converted to vtk files using MATLAB R2016a (The MathWorks, Natick, Massachusetts).

UNIPOLAR AND BIPOLAR VOLTAGE PER REGION. To analyze regional differences in UV and BV, the RV was divided into 4 regions: RV outflow tract (RVOT), basal ring, septum, and free wall. The basal ring was the 15-mm rim of myocardium extending apically from the tricuspid valve annulus (Figure 1).

The 4-region template was then superimposed on the CARTO map for each patient using ParaView, allowing for allocation of each mapping point to the corresponding region. The RVOT, acute margin, tricuspid annulus, and His position were used as landmarks for alignment (Supplemental Appendix). From the reference group, lower cutoffs for normal BV and UV were defined per region using the 5th percentile (18). The region-specific cutoff for UV in the free wall was validated in a second reference population without structural heart disease.

SEGMENTAL INVOLVEMENT IN CS AND ARVC. Segmental involvement in CS and ARVC was analyzed in an 8-segment model (Figure 1). A segment was considered affected if ≥ 3 adjacent mapping points were low voltage. Low voltage was defined based on previous studies (<1.5 mV for BV and <3.9 mV, <4.4 mV, and <5.5 mV for UV) (15-17) and on the region-specific cutoffs defined from the reference group in this study.

ENDOCARDIAL VOLTAGE RATIO IN CS AND ARVC. Endocardial low-voltage areas were measured in ParaView using cutoff values of <1.5 mV for BV and <3.9 mV (15), <4.4 mV (16), or <5.5 mV (17) for UV. Then, 3 ratios between the low BV and low UV areas were calculated: Ratio_{3,9}, Ratio_{4,4}, and Ratio_{5,5}.

DIAGNOSTIC VALUE OF EAVM. To evaluate the additional value of EAVM in differentiating (isolated) CS and ARVC, diagnostic criteria for CS or ARVC were compared between the groups (5,8). Then, a 2-step algorithm was constructed to diagnose (isolated) CS, excluding extracardiac findings. The first step was based on parameters previously reported to distinguish between CS with RV involvement and ARVC

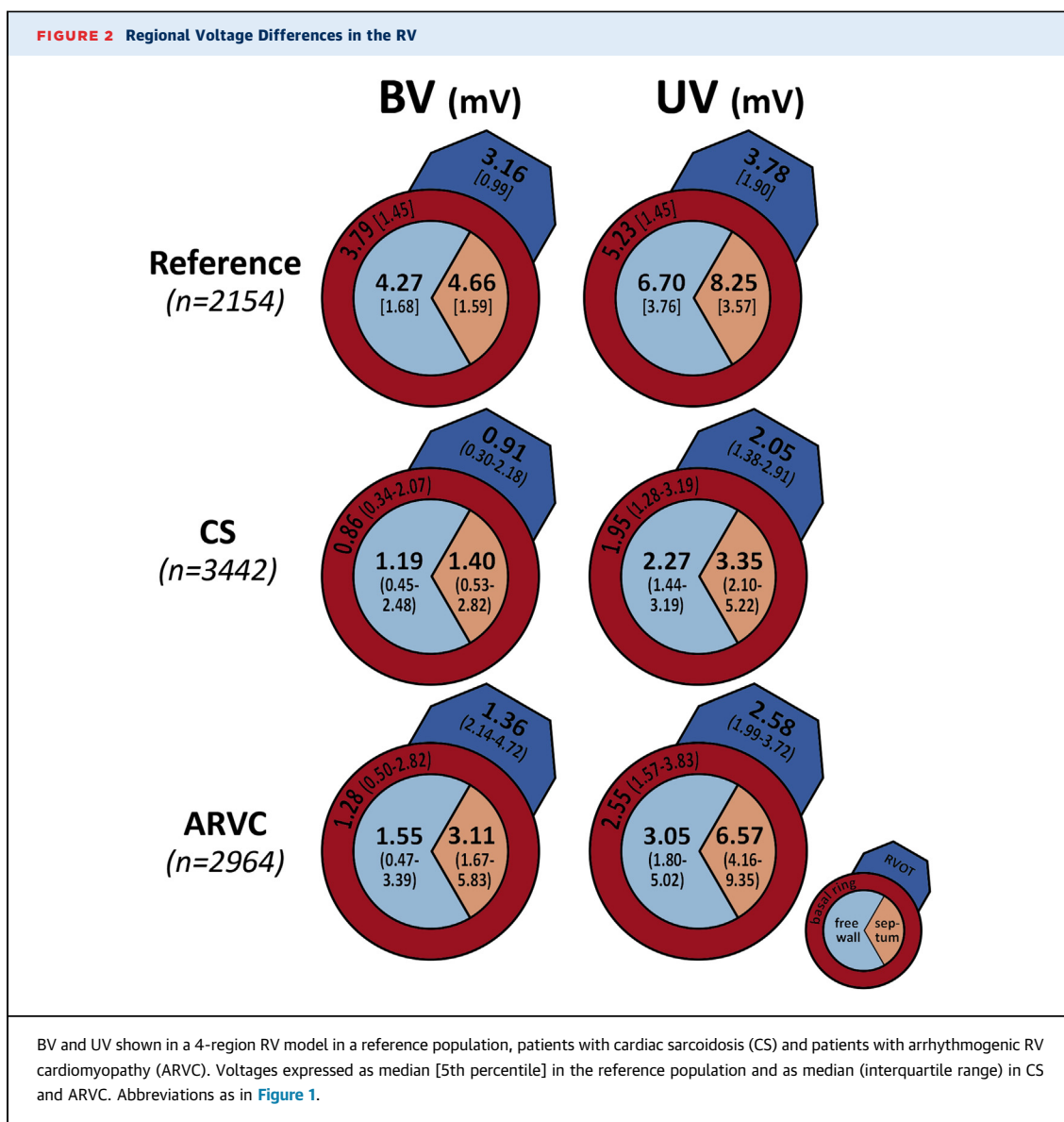
TABLE 1 Baseline Characteristics

	CS (n = 14)	ARVC (n = 13)
Age at procedure, yrs	56 \pm 6	40 \pm 12
Male	11 (77)	13 (100)
Fulfilment of diagnostic criteria		
Japanese Ministry of Health and Welfare 2006	12 (86)	0 (0)
Heart Rhythm Society 2014	10 (71)*	0 (0)
Japanese Circulation Society 2017	14 (100)	0 (0)
Task Force Criteria 2010		
Definite diagnosis	9 (64)	13 (100)
Borderline diagnosis	2 (14)	NA
Comorbidity		
Hypertension	4 (29)	1 (8)
Coronary artery disease	1 (7)	0 (0)
Dyslipidemia	3 (21)	2 (15)
Diabetes mellitus	2 (14)	0 (0)
ICD	13 (93)	10 (77)
CRT	4 (29)	0 (0)
Antiarrhythmic drugs at admission		
Amiodarone	6 (43)	1 (8)
Sotalol	2 (14)	7 (54)
Class I	4 (28)	1 (8)
Class I and III	1 (7)	0 (0)
Immunosuppressive drugs at admission	7 (50)	0 (0)

Values are mean \pm SD or n (%). *In 4 patients no positive (extra)cardiac histology could be obtained.
ARVC = arrhythmogenic right ventricular cardiomyopathy; CRT = cardiac resynchronization therapy; CS = cardiac sarcoidosis; ICD = implantable cardioverter-defibrillator; NA = not applicable.

(2,9,19), including first-, second-, or third-degree atrioventricular (AV) block, left ventricular ejection fraction (LVEF) $<50\%$, and basal septal involvement on imaging. A scoring system was used to adjust for the degree of conduction disturbances. The second step included specific EAVM characteristics based on this study. The algorithm was subsequently validated in a second separate population, including patients with the same inclusion criteria as above from 2 centers (Leiden, the Netherlands; Nashville, Tennessee).

STATISTICAL ANALYSIS. Categorical variables are expressed as number and percentage and compared using the chi-square test or Fisher exact test. Continuous variables are expressed as mean \pm SD or median (interquartile range) and compared between groups using Student's *t*-test or Mann-Whitney *U* test. Paired samples were compared using Wilcoxon signed rank test or McNemar test. Receiver-operating characteristic curve analysis was performed to determine the optimal ratio BV/UV cutoff to distinguish CS from ARVC. A *p* value ≤ 0.05 was considered significant. Statistical analysis was performed using IBM SPSS version 23 (IBM, Armonk, New York) and



Microsoft Excel 2016 (Microsoft Corporation, Redmond, Washington).

RESULTS

STUDY POPULATION. Fourteen patients with CS affecting the RV and 13 patients with ARVC were included. Baseline characteristics are summarized in Table 1.

Ten of 14 CS patients had histological confirmation of non-necrotizing granulomas; thus, together with at least 1 major criteria for cardiac involvement, they fulfilled the 2014 Heart Rhythm Society criteria. The 4 patients without biopsy-proven

sarcoidosis fulfilled Japanese criteria for CS, including a typical positive ^{18}F -FDG-PET scan responding to steroid treatment. Thirteen (93%) CS patients had extracardiac involvement. However, if excluding extracardiac findings, only 6 (43%) CS patients would have been diagnosed correctly as isolated CS based on the Japanese 2017 criteria. Of the remaining 8 CS patients, 5 (63%) patients fulfilled the TFC for definite ARVC and 2 (25%) patients fulfilled the TFC for borderline ARVC. Among the ARVC population, 11 (85%) patients would be diagnosed as definite ARVC according to the TFC, even without the positive results of genetic testing. None of these patients fulfilled criteria for CS.

UV AND BV PER RV REGION IN CONTROL SUBJECTS.

The reference group consisted of 9 patients (43 ± 10 years of age, 33% male). These patients had no evidence of structural heart disease at the time of mapping and during median follow-up of 18 (interquartile range: 2 to 24) months. Evaluation included echocardiography with detailed evaluation of the RV ($n = 9$ of 9), late gadolinium enhancement (LGE) CMR ($n = 8$ of 9) and T1-mapping ($n = 2$ of 8).

A total of 2,154 reference points (239 ± 44 points per map) were analyzed. Both BV and UV varied significantly among the RVOT, basal ring, septum, and free wall regions (both $p < 0.001$), with the lowest values observed in the RVOT and basal ring (Figure 2). Based on the 5th percentile, cutoffs per region were $BV \leq 0.99$ mV and $UV \leq 1.90$ mV for the RVOT; $BV \leq 1.45$ mV and $UV \leq 2.07$ mV for the basal ring; $BV \leq 1.59$ mV and $UV \leq 3.57$ mV for the septum; $BV \leq 1.68$ mV and $UV \leq 3.76$ mV for the RV free wall. Details of BV and UV per region are provided in Supplemental Table 2.

Supplemental Figure 1 shows the performance of $UV \leq 3.76$ mV for the RV free wall compared with previously suggested cutoffs (<4.4 mV and <5.5 mV) in a small reference validation population.

UV AND BV PER REGION IN CS AND ARVC. Both median BV and UV per region were significantly lower in CS and ARVC compared with the reference group (all $p < 0.001$). Of interest, BV and UV per region were significantly lower in CS compared with ARVC (all regions $p \leq 0.003$) (Figure 2).

SEGMENTAL INVOLVEMENT IN CS AND ARVC. CS patients had more RV segments with low BV compared with ARVC patients. Similarly, CS patients had more segments with low UV for all cutoffs (Table 2). In CS, there was no difference in the number of involved segments based on $UV < 3.9$ mV compared with involvement based on $BV < 1.5$ mV ($p = 0.160$), suggesting more transmural involvement. On the contrary, in ARVC, significantly more segments had $UV < 3.9$ mV compared with $BV < 1.5$ mV ($p = 0.016$), consistent with more extensive epicardial involvement (Table 2).

The basal inferior (79% in CS vs. 77% in ARVC) and basal anterior (86% vs. 92%, respectively) segments were most frequently affected in both etiologies ($BV < 1.5$ mV; both $p = 1.00$) (Figure 3). Bipolar basal septal involvement, however, was present in 71% of CS patients and in none of the ARVC patients ($p < 0.001$).

The region-specific cutoff for UV indicated that the RVOT was less often involved in both CS and ARVC

TABLE 2 Mapping Characteristics

	CS (n = 14)	ARVC (n = 13)	p Value
Points per map	246 \pm 73	228 \pm 81	
Mapping during sinus rhythm	11 (79)	13 (100)	
Number of segments involved			
BV <1.5 mV	5.5 \pm 1.6	3.5 \pm 1.0	0.001
BV region-specific cutoff*	5.4 \pm 1.7	3.2 \pm 1.2	0.001
UV <3.9 mV	6.0 \pm 1.8	4.5 \pm 1.5	0.029
UV <4.4 mV	6.7 \pm 1.4	4.6 \pm 1.2	0.001
UV <5.5 mV	7.1 \pm 1.0	5.4 \pm 1.0	0.001
UV region-specific cutoff*	5.2 \pm 1.8	3.4 \pm 1.3	0.006
Surfaces			
Total surface, cm ²	255 \pm 78	262 \pm 56	0.785
Area BV <0.5 mV, cm ²	33 \pm 31	13 \pm 13	0.052
% total surface	13 \pm 11	5 \pm 4	0.018
Area BV <1.5 mV, cm ²	106 \pm 58	54 \pm 32	0.009
% total surface	41 \pm 17	21 \pm 11	0.001
Area UV <3.9 mV, cm ²	164 \pm 79	109 \pm 51	0.043
% total surface	63 \pm 21	41 \pm 16	0.004
Area UV <4.4 mV, cm ²	180 \pm 79	127 \pm 55	0.057
% total surface	70 \pm 19	48 \pm 17	0.004
Area UV <5.5 mV, cm ²	209 \pm 76	163 \pm 59	0.095
% total surface	82 \pm 14	62 \pm 18	0.003
Ratios			
BV 1.5/UV 3.9	0.65 \pm 0.21	0.50 \pm 0.20	0.062
BV 1.5/UV 4.4	0.58 \pm 0.20	0.43 \pm 0.18	0.044
BV 1.5/UV 5.5	0.49 \pm 0.20	0.33 \pm 0.15	0.024

Values are mean \pm SD or n (%). *Low voltage defined based on region-specific cutoff: for the right ventricular outflow tract, $BV \leq 0.99$ mV and $UV \leq 1.90$ mV; for the basal ring, $BV \leq 1.45$ mV and $UV \leq 2.07$ mV; for the septum, $BV \leq 1.59$ mV and $UV \leq 3.57$ mV; for the free wall, $BV \leq 1.68$ mV and $UV \leq 3.76$ mV.

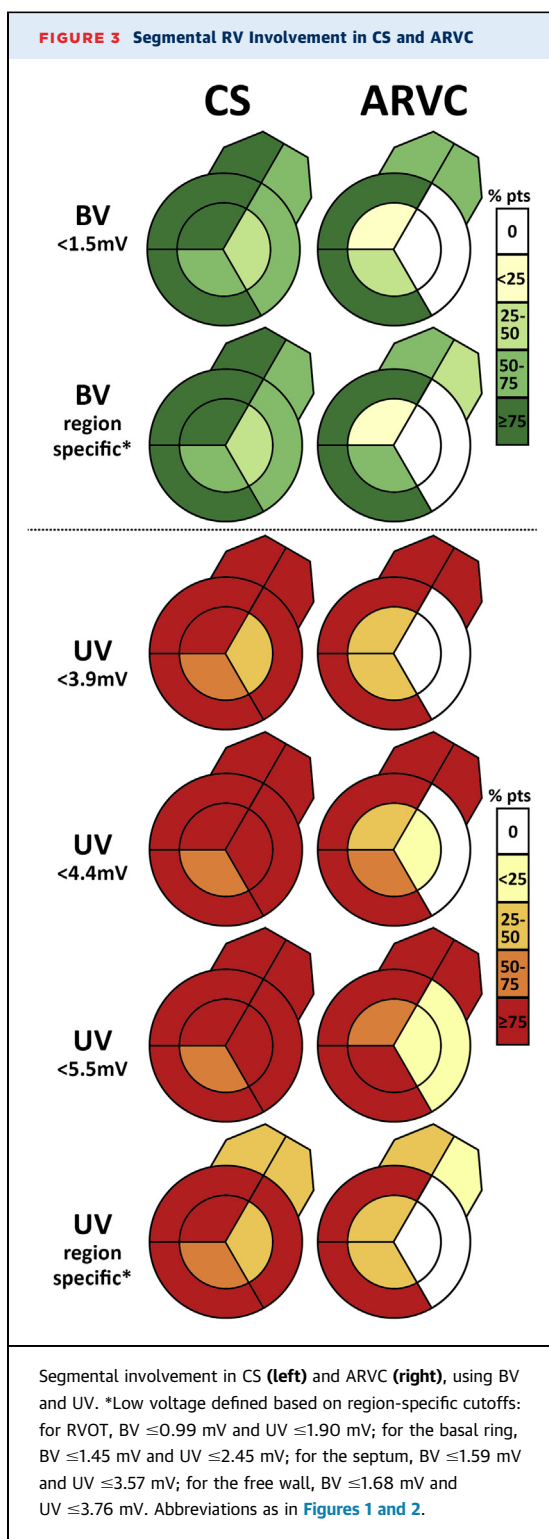
BV = bipolar voltage; UV = unipolar voltage; other abbreviations as in Table 1.

than was suggested by the prior uniformly applied UV cutoffs ($p < 0.02$ for both etiologies). For BV maps, applying the region-specific cutoff for BV (≤ 0.90 mV) did not significantly reduce the frequency of RVOT involvement (Figure 3).

ENDOCARDIAL VOLTAGE AREA RATIO IN CS AND ARVC. The area of $BV < 1.5$ mV was 106 ± 58 cm² in CS and 54 ± 32 cm² in ARVC ($p = 0.009$) (Table 2). Similarly, the low UV area was significantly larger in CS compared with ARVC for all cutoffs.

The mean Ratio_{3.9} was 0.65 in CS, compared with 0.50 in ARVC ($p = 0.062$). Mean Ratio_{4.4} and Ratio_{5.5} were also larger in CS compared with ARVC: 0.58 vs. 0.43 ($p = 0.044$) and 0.49 vs. 0.33 ($p = 0.024$), respectively (Table 2). This is consistent with relatively greater epicardial compared with endocardial involvement in ARVC.

Ratio_{5.5} (area $BV < 1.5$ mV/area $UV < 5.5$ mV) provided the best discrimination between CS and ARVC (area under the curve: 0.780; 95% confidence interval: 0.596 to 0.964; $p = 0.013$). A Ratio_{5.5} ≥ 0.45 differentiated CS from ARVC with 71% sensitivity and 85% specificity (Figure 4).



DIAGNOSTIC VALUE OF EAVM. Table 3 lists the comparison of parameters that are included in current diagnostic criteria for CS and ARVC. Any AV conduction delay was present in 7 CS patients and in

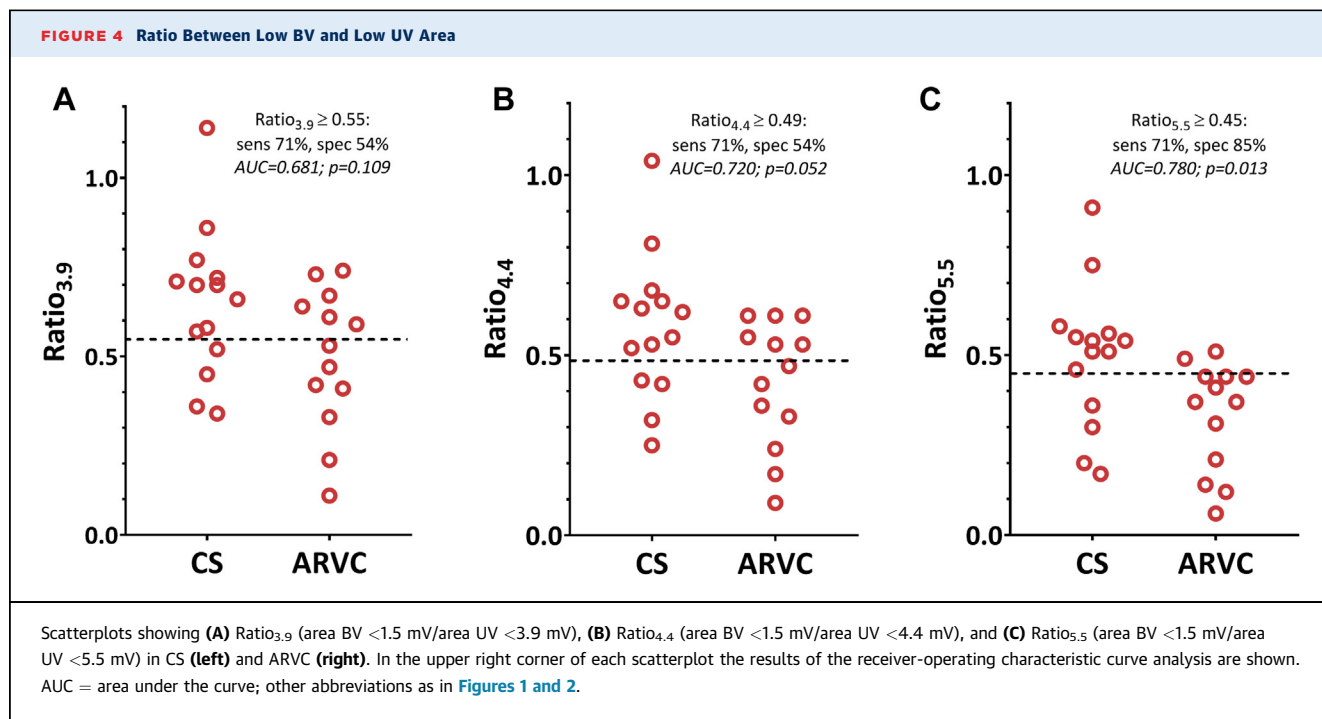
none of the ARVC patients ($p = 0.001$). Neither RV function nor RV morphological abnormalities were different between groups. However, LVEF was lower in CS compared with ARVC (median 46% vs. 63%; $p = 0.011$). CMR was not performed in 4 CS patients, and in 1 CS patient, septal LGE could not be determined due to poor quality.

A new algorithm for diagnosing (isolated) CS in patients presenting with monomorphic VT from the RV was developed, including non-EAVM and newly proposed EAVM parameters (Central Illustration). Had they not had extracardiac involvement, only 6 CS patients in the current study would have been diagnosed with CS before EAVM, based on the non-EAVM parameters and on Japanese criteria (43% sensitivity, 100% specificity). Adding Ratio_{5.5} (providing information on scar characteristics) and bipolar basal septal involvement (providing information on scar distribution) achieved 93% sensitivity and 85% specificity to diagnose CS (even in the absence of extracardiac involvement). Notably, all 6 patients identified with non-EAVM parameters would have been classified correctly when using only the EAVM information: 4 patients had a Ratio_{5.5} ≥ 0.45 and 2 patients had bipolar basal septal involvement.

VALIDATION OF DIAGNOSTIC ALGORITHM. The validation population included 6 CS patients (57 ± 8 years of age, 67% male) and 10 ARVC patients (33 ± 19 years of age, 90% male) (Table 4). The algorithm diagnosed all CS patients and all ARVC patients correctly (100% sensitivity and 100% specificity) (Supplemental Figure 2).

DISCUSSION

This is the first study to demonstrate the diagnostic value of endocardial electroanatomical voltage mapping to distinguish cardiac sarcoidosis with RV involvement from ARVC. The main findings are: 1) BV and UV differ significantly among RV regions in healthy control subjects, suggesting that voltage cutoffs for pathological involvement may need to be adjusted to specific RV regions; 2) the relative sizes of endocardial BV <1.5 mV to low UV <5.5 mV areas, Ratio_{5.5}, can help distinguish CS from ARVC; and 3) an algorithm including Ratio_{5.5} ≥ 0.45 and bipolar basal septal involvement correctly distinguished CS from ARVC with 93% sensitivity and 85% specificity, even without additional image modalities. In a validation cohort, the algorithm showed 100% sensitivity and 100% specificity for distinguishing CS from ARVC.



DISTRIBUTION OF VOLTAGES PER REGION.

Although voltage criteria for identifying scar are widely applied, they are based on relatively limited data. For BV, the cutoff of <1.5 mV is derived from the 95th percentile of 6 patients without structural heart disease (18). For UV, different cutoff values have been proposed. In a healthy population, 95% of endocardial EGMs had UV >5.5 mV (17), and this value has been suggested to identify normal RV myocardium. Unipolar recordings have a larger field-of-view than bipolar recordings hence the suggestion they may better detect subepicardial involvement. A cutoff of UV <4.4 mV has been reported for detection of RV epicardial scar (BV <1.5 mV) (16). As epicardial BV can be attenuated by fat and therefore overestimate epicardial scar, a lower cutoff of UV <3.9 mV has been suggested based on comparison with epicardial sites with BV <1.5 mV without epicardial fat (15).

The current study shows that both BV and UV significantly differ per region in normal control subjects, which may be explained by lower voltage in the vicinity of the valve annuli and regional wall thickness differences (14). Although determined with a different method, our results are in line with a previous study reporting lower voltages in the RVOT compared with the interventricular septum (20). In particular, lower UV in the RVOT may be at least partly due to the influence of adjacent unexcitable tissue. Thus, based on EAVM, the presence of

abnormalities of the RVOT may be overestimated if previously reported, singular cutoff values are applied. This may have important clinical implications for assessing the presence of RV scar.

DIAGNOSIS OF ISOLATED CS. Isolated CS is likely underdiagnosed due to the low sensitivity of current diagnostic criteria which require extracardiac sarcoidosis or positive EMB (4,5). Although CS was diagnosed as underlying etiology in our population based on accepted criteria, positive cardiac histology was only present in 1 case at autopsy, while in 10 CS patients, EMB was negative, consistent with its known low diagnostic yield. In the absence of extracardiac involvement, the TFC may lead to misclassification of isolated CS as ARVC, especially in patients presenting with VTs (2,9,19). Patients with isolated CS may therefore present with a more advanced disease (21), probably owing to delayed diagnosis. Patients with CS referred for VT ablation have a higher risk of VT recurrence, transplantation, and death compared with other etiologies (12). These findings highlight the importance of early diagnosis of (isolated) CS.

Recently, criteria for isolated CS have been proposed by the Japanese Circulation Society (5). They require a positive ¹⁸F-FDG-PET or ⁶⁷Ga scintigraphy and ≥3 of the following: high-grade AV block or VT, basal septal thinning or abnormal ventricular wall anatomy, LVEF <50%, or LGE on CMR.

TABLE 3 Major Criteria in 2017 Japanese Criteria for CS and 2010 TFC Between CS and ARVC

	CS (n = 14)	ARVC (n = 13)
Cardiac parameters		
EMB showing non-necrotizing granulomas	0/10 (0)	0/6 (0)
Electrocardiogram*		
Epsilon wave V ₁ -V ₃	3 (21)	3 (23)
PR ≥220 ms	5 (36)	0 (0)
Second- or third-degree AV block	2 (14)	0 (0)
RV function		
RVOT PLAX, mm/m ²	21 ± 3	18 ± 3
RVOT PSAX, mm/m ²	18 ± 3	17 ± 2
RV FAC, %	23 (20-42)	23 (19-47)
RV aneurysm	3 (21)	6 (46)
RV wall motion abnormality	8 (57)	8 (62)
Basal septal wall thinning or wall motion abnormality	5 (36)	0 (0)
RV dysfunction		
Major TFC	9 (64)	8 (62)
Minor TFC	1 (7)	0 (0)
LV function		
LVEF, %	46 (29-57)	63 (53-65)
LVEF <50%	8 (57)	3 (23)
LGE-CMR		
Any LGE	8 (89)	3 (60)
Basal septal LGE	7 (78)	0 (0)
LGE LV	8 (89)	2 (40)
LGE RV	8 (89)	1 (20)
Patchy myocardial uptake on ¹⁸ F-FDG-PET	7/11 (64)	0/2 (0)
Extracardiac parameters		
Presence of extracardiac sarcoidosis	13 (93)	0 (0)
Extracardiac biopsy showing non-necrotizing granulomas	10 (77)	NA
Genetic testing		
Pathogenic mutation	0 (0)	13 (100)

Values are n/N (%), n (%), mean ± SD, or median (interquartile range). *Owing to the high presence of complete right bundle branch block in the CS group (10 patients), T-wave inversion as used in TFC could not be compared between groups.

AV = atrioventricular; CMR = cardiac magnetic resonance; EAVM = electroanatomical voltage mapping; EMB = endomyocardial biopsy; FAC = fractional area change; ¹⁸F-FDG-PET = ¹⁸F-fluorodeoxyglucose positron emission tomography; LGE = late gadolinium enhancement; LV = left ventricular; LVEF = left ventricular ejection fraction; PLAX = parasternal long axis; PSAX = parasternal short axis; RV = right ventricular; RVOT = right ventricular outflow tract; TFC = Task Force Criteria; other abbreviations as in Table 1.

However, ¹⁸F-FDG-PET uptake reflects active inflammation rather than scar (6), and is negative in up to 52% of patients with CS and VT referred for catheter ablation (7). In addition, abnormal ventricular wall anatomy (including aneurysm) was not different between CS and ARVC in our cohort, consistent with a previous study (9). Although LGE-CMR has a reasonable sensitivity and specificity in CS when using Japanese criteria for CS as gold standard (22), in a prior study the presence of LGE in both LV and RV was comparable between CS and ARVC (9). As LGE-CMR was only performed in a minority of ARVC patients in this study, and was considered contraindicated in 4 CS patients because of the presence of an implantable cardioverter-defibrillator, we could not compare the presence of LGE between CS

and ARVC. In view of the need to improve methods for diagnosing isolated CS, we evaluated EAVM, which allows for high-density scar delineation, especially in RV cardiomyopathies, even in the presence of devices (11).

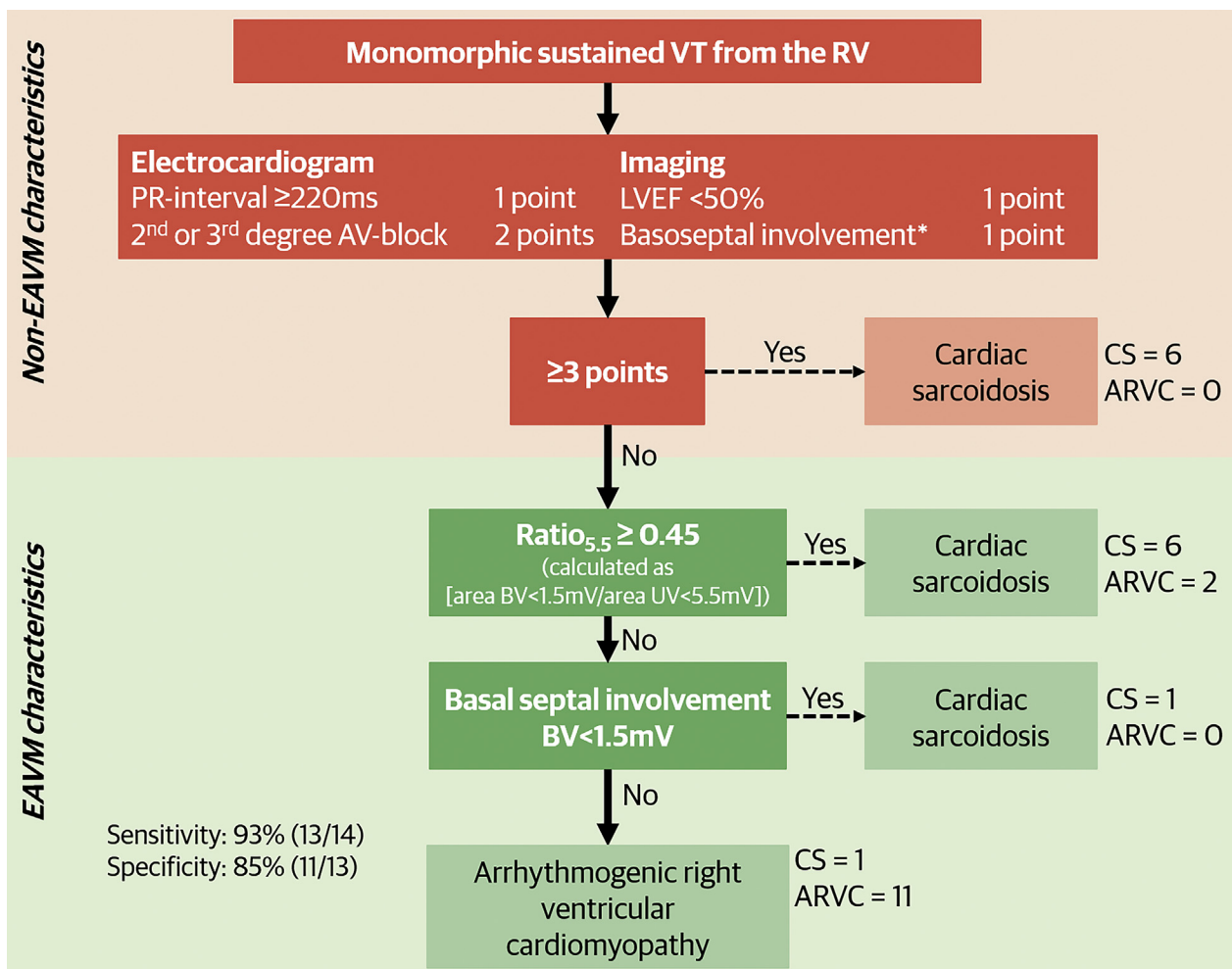
EAVM IN CS AND ARVC. Basal septal involvement (BV <1.5 mV) was present in 71% of CS patients and in none of the ARVC patients, which is in line with previous series showing involvement of the septum by EAVM in 56% to 75% of CS patients (1,12,23). The more frequent involvement of the septum in CS compared with ARVC is also consistent with previous studies using LGE-CMR (9,24). However, not all CS patients had basal septal involvement, and basal septal scar has also been reported in other arrhythmogenic cardiomyopathies including ARVC (1,25), which emphasizes the need for additional EAVM parameters to distinguish between CS and other arrhythmogenic cardiomyopathies.

Based on disease-specific pathological findings and the differences in the field of view between BV and UV, we hypothesized that EAVM scar characteristics differ between CS and ARVC. Transmural CS scars may lead to both UV and BV reduction at affected sites, whereas dominant subepicardial ARVC involvement may show relatively larger low UV areas, reflected by a lower endocardial BV/UV area ratio. Indeed, in our cohort, a Ratio_{5,5} ≥0.45 could differentiate CS from ARVC with 71% sensitivity and 85% specificity. This endocardial voltage ratio is easily available from routinely performed substrate mapping in patients referred for RV VT ablation.

Previous studies have reported BV/UV ratios in ARVC patients fulfilling the 2010 TFC but have not evaluated CS. A mean endocardial area voltage ratio (BV <1.5 mV/UV <5.5 mV) of 0.29 has been reported, similar to the 0.33 in our study (13). Another study including ARVC patients (also fulfilling the 2010 TFC) applied an arbitrarily defined cutoff of 0.58 (BV <1.5 mV/UV <5.3 mV), based on the mean value within their cohort. In their study, patients with a ratio ≥0.58 had significantly more VT recurrences after ablation (26). As CS patients may present with the same phenotype as ARVC patients, including RV dysfunction and VTs, it is interesting to speculate that these patients with a ratio ≥0.58 may have had CS instead of ARVC, and hence a poorer prognosis (1).

DIAGNOSTIC VALUE OF EAVM IN ISOLATED CS WITH RV INVOLVEMENT. The role of EAVM as a diagnostic modality is evolving. In ARVC, EAVM has been shown to be more sensitive to delineate scar, compared with LGE-CMR (11), and EAVM has been used to guide EMB. Accordingly, we have developed an algorithm,

CENTRAL ILLUSTRATION Algorithm to Diagnose (Isolated) Cardiac Sarcoidosis in Patients Presenting With Monomorphic Ventricular Tachycardia From the Right Ventricle



Hoogendoorn, J.C. et al. J Am Coll Cardiol EP. 2020;6(6):696–707.

*Basal septal wall motion abnormalities or basal septal wall thinning on echocardiography or basal septal late gadolinium enhancement on cardiac magnetic resonance. ARVC = arrhythmogenic right ventricular cardiomyopathy; AV = atrioventricular; BV = bipolar voltage; CS = cardiac sarcoidosis; EAVM = electroanatomical voltage mapping; LVEF = left ventricular ejection fraction; RV = right ventricle; UV = unipolar voltage; VT = ventricular tachycardia.

including easily available non-EAVM characteristics and EAVM characteristics, to distinguish CS from ARVC, excluding extracardiac manifestation, as we also aimed to improve the diagnosis of isolated CS with RV involvement.

Among non-EAVM criteria, only AV conduction abnormalities, an impaired LVEF, and basal septal involvement on imaging were different between groups, in previous studies and in our population (2,9,19). The sensitivity of these non-EAVM

characteristics was 43%, with a specificity of 100%. Adding EAVM characteristics, the sensitivity increased to 93%, with a specificity of 85%, to accurately diagnose CS. The same sensitivity and specificity would have been achieved based on EAVM only, showing the diagnostic value of routinely obtained EAVM data even without additional image modalities. The diagnostic performance of the algorithm was validated in a second population with excellent sensitivity and specificity.

TABLE 4 Algorithm Characteristics in a Separate Validation Population

	CS (n = 6)	ARVC (n = 10)
Non-EAVM characteristics		
PR interval ≥ 220 ms	0 (0)	1 (10)
Second- or third-degree AV block	4 (67)	0 (0)
LVEF $< 50\%$	3 (50)	2 (20)
Basal septal involvement on imaging	4 (67)	1 (10)
EAVM characteristics		
Area BV < 1.5 mV, cm ²	73 \pm 63	34 \pm 43
Area UV < 5.5 mV, cm ²	132 \pm 88	137 \pm 89
Ratio _{5,5}	0.57 \pm 0.18	0.18 \pm 0.14
Basal septal involvement (BV < 1.5 mV)	5 (83)	0 (0)

Values are n (%) or mean \pm SD.
Abbreviations as in [Tables 1 to 3](#).

FUTURE PERSPECTIVES. EAVM is a promising tool in diagnosing (isolated) right-sided CS as the underlying etiology in patients presenting with scar-related RV VT, providing information about both scar characteristics and scar distribution. Future studies are needed to evaluate if EAVM can be of diagnostic value in patients with early RV cardiomyopathies *without* VTs for the diagnosis of CS, which may be combined with EAVM-guided biopsy allowing for early diagnosis and treatment.

STUDY LIMITATIONS. First, this is a retrospective study, in patients undergoing ablation for VT in tertiary centers. These are rare diseases, and the study population is small. LGE-CMR and ¹⁸F-FDG-PET imaging were not available in the majority of patients. However, if all of our CS patients had had positive ¹⁸F-FDG-PET or LGE-CMR, still only 9 (64%) CS patients would have fulfilled the Japanese criteria for isolated CS. Furthermore, owing to the retrospective design, the use of contact force catheters was limited. Second, cutoff values derived from this study are based on a small reference population, evaluated with LGE-CMR and only recently T1 mapping; therefore, microfibrosis cannot be fully excluded. The regional differences in BV and UV likely reflect regional differences in wall thickness and the proximity of fibrous valve annuli. Whether region-specific endocardial cutoff values improve accurate subepicardial scar detection requires further studies. Moreover, as shown, binary cutoffs might be an oversimplified concept considering the linear relationship between amount of viable myocardium and voltage and the large range of “normal” voltages (14).

Third, this study includes patients referred to tertiary centers. This might reflect a more advanced stage of disease. Fourth, endocardial BV/UV ratio was used as a surrogate for transmural scar, as epicardial mapping was not performed solely for diagnostic purposes. Moreover, a drawback of epicardial mapping is the presence of subepicardial fat, leading to overestimation of epicardial low voltage. For this analysis, region-specific cutoffs could not be used, as the accurate measurement of low voltage surface per region would have required a higher mapping density to subdivide surfaces into regions.

CONCLUSIONS

Unipolar and bipolar voltages differ significantly according to region in the normal RV. Therefore, one cutoff is likely to have limited accuracy. EAVM is a promising method to distinguish CS with RV involvement from ARVC, which can have substantial implications for patient management.

ADDRESS FOR CORRESPONDENCE: Dr. Katja Zeppenfeld, Department of Cardiology (B4-P), Leiden University Medical Center, P.O. Box 9600, 2300 RC Leiden, the Netherlands. E-mail: k.zeppenfeld@lumc.nl.

PERSPECTIVES

COMPETENCY IN MEDICAL KNOWLEDGE 1:

Both BV and UV differ per RV region in healthy control subjects. Therefore, one cutoff value cannot be valid. Cutoffs for pathological involvement need to be adjusted per RV region.

COMPETENCY IN MEDICAL KNOWLEDGE 2:

EAVM is of diagnostic value in patients presenting with monomorphic sustained VT from the RV. An algorithm including the endocardial voltage Ratio_{5,5} ([area BV < 1.5 mV]/[area UV < 5.5 mV]) and bipolar basal septal involvement can distinguish cardiac sarcoidosis with RV involvement from ARVC with high sensitivity and specificity.

TRANSLATIONAL OUTLOOK: Further prospective studies are needed to determine if EAVM can be used as additional diagnostic modality in patients with early RV cardiomyopathies without VTs.

REFERENCES

1. Kumar S, Baldinger SH, Kapur S, et al. Right ventricular scar-related ventricular tachycardia in nonischemic cardiomyopathy: electrophysiological characteristics, mapping, and ablation of underlying heart disease. *J Cardiovasc Electrophysiol* 2018;29:79–89.
2. Vasaivala SC, Finn C, Delpriore J, et al. Prospective study of cardiac sarcoid mimicking arrhythmogenic right ventricular dysplasia. *J Cardiovasc Electrophysiol* 2009;20:473–6.
3. Tavora F, Cresswell N, Li L, Ripple M, Solomon C, Burke A. Comparison of necropsy findings in patients with sarcoidosis dying suddenly from cardiac sarcoidosis versus dying suddenly from other causes. *Am J Cardiol* 2009;104:571–7.
4. Birnie DH, Sauer WH, Bogun F, et al. HRS expert consensus statement on the diagnosis and management of arrhythmias associated with cardiac sarcoidosis. *Heart Rhythm* 2014;11:1305–23.
5. Terasaki F, Yoshinaga K. New guidelines for diagnosis of cardiac sarcoidosis in Japan. *Ann Nucl Cardiol* 2017;3:42–5.
6. Vita T, Okada DR, Veillet-Chowdhury M, et al. Complementary value of cardiac magnetic resonance imaging and positron emission tomography/computed tomography in the assessment of cardiac sarcoidosis. *Circ Cardiovasc Imaging* 2018;11:e007030.
7. Muser D, Santangeli P, Liang JJ, et al. Characterization of the electroanatomic substrate in cardiac sarcoidosis: correlation with imaging findings of scar and inflammation. *J Am Coll Cardiol EP* 2018;4:291–303.
8. Marcus FI, McKenna WJ, Sherrill D, et al. Diagnosis of arrhythmogenic right ventricular cardiomyopathy/dysplasia: proposed modification of the Task Force Criteria. *Circulation* 2010;121:1533–41.
9. Philips B, Madhavan S, James CA, et al. Arrhythmogenic right ventricular dysplasia/cardiomyopathy and cardiac sarcoidosis: distinguishing features when the diagnosis is unclear. *Circ Arrhythm Electrophysiol* 2014;7:230–6.
10. te Riele AS, James CA, Groeneweg JA, et al. Approach to family screening in arrhythmogenic right ventricular dysplasia/cardiomyopathy. *Eur Heart J* 2016;37:755–63.
11. Marra MP, Leoni L, Bauce B, et al. Imaging study of ventricular scar in arrhythmogenic right ventricular cardiomyopathy: comparison of 3D standard electroanatomical voltage mapping and contrast-enhanced cardiac magnetic resonance. *Circ Arrhythm Electrophysiol* 2012;5:91–100.
12. Kumar S, Barbhaiya C, Nagashima K, et al. Ventricular tachycardia in cardiac sarcoidosis: characterization of ventricular substrate and outcomes of catheter ablation. *Circ Arrhythm Electrophysiol* 2015;8:87–93.
13. Kubala M, Pathak RK, Xie S, et al. Electrocardiographic repolarization abnormalities and electroanatomic substrate in arrhythmogenic right ventricular cardiomyopathy. *Circ Arrhythm Electrophysiol* 2018;11:e005553.
14. Gashan CA, Androulakis AFA, Tao Q, et al. Whole human heart histology to validate electroanatomical voltage mapping in patients with non-ischaemic cardiomyopathy and ventricular tachycardia. *Eur Heart J* 2018;39:2867–75.
15. Venlet J, Piers SRD, Kapel GFL, et al. Unipolar endocardial voltage mapping in the right ventricle: optimal cutoff values correcting for computed tomography-derived epicardial fat thickness and their clinical value for substrate delineation. *Circ Arrhythm Electrophysiol* 2017;10:e005175.
16. Tokuda M, Tedrow UB, Inada K, et al. Direct comparison of adjacent endocardial and epicardial electrograms: implications for substrate mapping. *J Am Heart Assoc* 2013;2:e000215.
17. Polin GM, Haqqani H, Tzou W, et al. Endocardial unipolar voltage mapping to identify epicardial substrate in arrhythmogenic right ventricular cardiomyopathy/dysplasia. *Heart Rhythm* 2011;8:76–83.
18. Marchlinski FE, Callans DJ, Gottlieb CD, Zado E. Linear ablation lesions for control of unmappable ventricular tachycardia in patients with ischemic and nonischemic cardiomyopathy. *Circulation* 2000;101:1288–96.
19. Decherer DG, Kochhauser S, Wasmer K, et al. Electrophysiological characteristics of ventricular tachyarrhythmias in cardiac sarcoidosis versus arrhythmogenic right ventricular cardiomyopathy. *Heart Rhythm* 2013;10:158–64.
20. Kelesidis I, Desjardins B, Muser D, Santangeli P, Zado ES, Marchlinski FE. Unipolar voltage mapping criteria for right ventricular septum: influence of the aortic root. *J Cardiovasc Electrophysiol* 2018;29:1113–8.
21. Kandolin R, Lehtonen J, Airaksinen J, et al. Cardiac sarcoidosis: epidemiology, characteristics, and outcome over 25 years in a nationwide study. *Circulation* 2015;131:624–32.
22. Bravo PE, Singh A, Di Carli MF, Blankstein R. Advanced cardiovascular imaging for the evaluation of cardiac sarcoidosis. *J Nucl Cardiol* 2019;26:188–99.
23. Muser D, Santangeli P, Pathak RK, et al. Long-term outcomes of catheter ablation of ventricular tachycardia in patients with cardiac sarcoidosis. *Circ Arrhythm Electrophysiol* 2016;9:e004333.
24. Steckman DA, Schneider PM, Schuller JL, et al. Utility of cardiac magnetic resonance imaging to differentiate cardiac sarcoidosis from arrhythmogenic right ventricular cardiomyopathy. *Am J Cardiol* 2012;110:575–9.
25. Marchlinski FE, Zado E, Dixit S, et al. Electroanatomic substrate and outcome of catheter ablation therapy for ventricular tachycardia in setting of right ventricular cardiomyopathy. *Circulation* 2004;110:2293–8.
26. Mussigbrodt A, Bertagnolli L, Efimova E, et al. Myocardial voltage ratio in arrhythmogenic right ventricular dysplasia/cardiomyopathy. *Herzschrittmacherther Elektrophysiol* 2017;28:219–24.

KEY WORDS arrhythmogenic right ventricular cardiomyopathy, cardiac sarcoidosis, electroanatomical voltage mapping, right ventricle, ventricular tachycardia

APPENDIX For expanded Methods and References sections as well as supplemental tables and figures, please see the online version of this paper.