



Universiteit
Leiden
The Netherlands

Immune cells in mesothelioma microenvironment simplistic marker of response to nivolumab plus ipilimumab?

Disselhorst, M.J.; Lubeck, Y.; Noort, V. van der; Quispel-Janssen, J.; Seignette, I.M.; Sanders, J.; ... ; Baas, P.

Citation


Disselhorst, M. J., Lubeck, Y., Noort, V. van der, Quispel-Janssen, J., Seignette, I. M., Sanders, J., ... Baas, P. (2022). Immune cells in mesothelioma microenvironment simplistic marker of response to nivolumab plus ipilimumab? *Lung Cancer*, 173, 49-52.
doi:10.1016/j.lungcan.2022.08.019

Version: Publisher's Version

License: [Licensed under Article 25fa Copyright Act/Law \(Amendment Taverne\)](#)

Downloaded from: <https://hdl.handle.net/1887/3565038>

Note: To cite this publication please use the final published version (if applicable).



Immune cells in mesothelioma microenvironment simplistic marker of response to nivolumab plus ipilimumab?

Maria J. Disselhorst^{a,*}, Yoni Lubeck^b, Vincent van der Noort^c, Josine Quispel-Janssen^a, Iris M. Seignette^b, Joyce Sanders^b, Dennis Peters^d, Erik Hooijberg^b, Paul Baas^a

^a Department of Thoracic Oncology, Netherlands Cancer Institute – Antoni van Leeuwenhoek (NKI-AvL), Amsterdam, the Netherlands

^b Department of Pathology, Netherlands Cancer Institute – Antoni van Leeuwenhoek (NKI-AvL), Amsterdam, the Netherlands

^c Biometrics Department, Netherlands Cancer Institute – Antoni van Leeuwenhoek (NKI-AvL), Amsterdam, the Netherlands

^d Core Facility Molecular Pathology Netherlands Cancer Institute – Antoni van Leeuwenhoek (NKI-AvL), Amsterdam, the Netherlands

ARTICLE INFO

Keywords:

Malignant pleural mesothelioma
Immune checkpoint inhibitor
Tumor microenvironment

ABSTRACT

Introduction: Malignant pleural mesothelioma (MPM) is a malignant disease of the pleura which recently can be treated with immune checkpoint inhibitors (ICI). To optimize this treatment, a better understanding of the tumor micro environment is needed. We investigated subgroups of immune cells in subsequent tumor biopsies of patients treated with ICI.

Methods: Biopsies from MPM patients included in two clinical ICI trials (nivolumab alone and an ipilimumab/nivolumab combination) were examined. At baseline and after 6 weeks of treatment, pleural biopsies were taken to examine the tumor microenvironment (CD20+, CD4+, CD8+, FoxP3+ and PD-1+). Cell density was defined as the number of marker positive cells per mm². Radiological responses were evaluated as partial response, stable disease or progressive disease according to modified RECIST criteria.

Results: Thirty-four and 36 patients were included in the nivolumab and ipilimumab/nivolumab trial respectively. In the nivolumab trial, no significant differences in cell densities were seen in baseline biopsies of patients with partial response versus progressive disease. In contrast, in the ipilimumab/nivolumab trial, a higher cell density of CD4+, CD8+, FoxP3+ and PD-1+ cells at baseline was significantly correlated with partial responses. On-treatment biopsies of both trials did not show significant changes when compared to baseline biopsies.

Conclusion: Biopsies from patients responding to nivolumab plus ipilimumab treatment show a significant higher cell density of CD4+, CD8+, FoxP3+ and PD-1+ cells, without a change after 6 weeks of treatment. This observation is a first step in exploring the tumor microenvironment as predictor of response in ICI treatment in MPM.

1. Introduction

Malignant pleural mesothelioma (MPM) is a rare malignant tumor arising from the mesothelial cells of the pleura. It is mainly caused by exposure to asbestos, with a latency time between exposure and diagnosis of 30 to 50 years [1].

For decades, standard systemic treatment for MPM was combination chemotherapy consisting of platinum plus pemetrexed. But recently immune checkpoint inhibitor (ICI) treatment with nivolumab (anti-PD-1 antibody) and ipilimumab (anti-CTLA-4-antibody) was approved as first line therapy, following the results of the phase III Checkmate 743 trial. This study showed a survival benefit of combination ICI treatment over

standard chemotherapy (18.1 versus 14.1 months, HR 0.74 (96.6 % CI 0.60–0.91, $p = 0.002$)) [2].

Unfortunately, ICI treatment is not effective in all patients and may lead to side effects. A better understanding of MPM and its microenvironment is needed to select the proper patients for ICI treatment. The tumor micro-environment (TME) plays an important role in the response to ICI therapy. The TME in MPM is composed of stromal, endothelial and immune cells and has a heterogenous distribution in the pleural cavity.

We investigated the possible impact of subgroups of immune cells in subsequent tumor biopsies of patients treated with ICI.

* Corresponding author.

E-mail address: m.disselhorst@nki.nl (M.J. Disselhorst).

<https://doi.org/10.1016/j.lungcan.2022.08.019>

Received 28 February 2022; Received in revised form 24 August 2022; Accepted 26 August 2022

Available online 5 September 2022

0169-5002/© 2022 Elsevier B.V. All rights reserved.

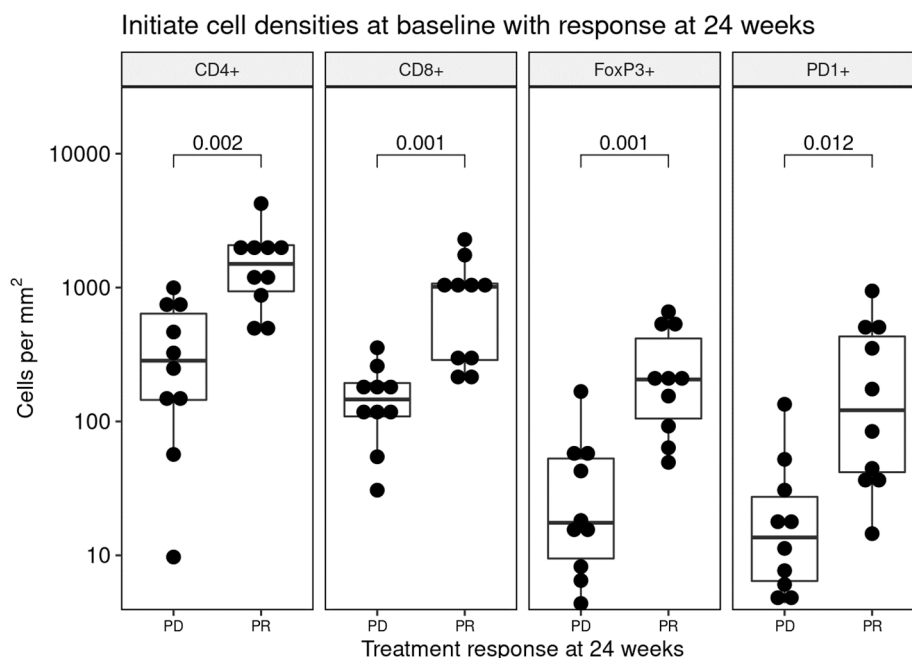


Fig. 1. number of CD4+, CD8+, FoxP3+ and PD-1+ cells per mm² at baseline in the nivolumab plus ipilimumab trial, comparing patients with progressive disease (PD) with partial response (PR) at 24 weeks.

2. Materials and methods

Patients from the Nivomes (NCT02497508) [3] and Initiate (NCT03048474) [4] clinical trials were included in this analysis. In these two single center phase II trials, patients with recurrent MPM were treated with nivolumab monotherapy (Nivomes) or nivolumab plus ipilimumab (Initiate). In both trials pleural biopsies were taken at baseline and after 6 weeks of treatment and stored formalin-fixed paraffin-embedded (FFPE).

For nivolumab treated patients, two multiplex immunofluorescence panels were used. Panel 1 included antibodies against CD4, FOXP3, CD68, CD163, pancytokeratin (panCK) and DAPI to identify all nucleated cells. Panel 2 included antibodies against CD8, PD-1, CD20, panCK and DAPI. Macrophage markers (CD68 and CD163) of panel 1 could not be validated and evaluated. For the nivolumab plus ipilimumab trial, immunohistochemistry staining was performed for CD4, CD8, FoxP3 and PD-1.

The stained slides were annotated and analyzed using HALO software for counting and calculating the percentage of all nucleated cells. Cell density was defined as the number of marker positive cells per mm². Details about stainings and HALO software are provided in the [supplementary methods](#).

In both trials, PD-L1 staining was performed. In the nivolumab trial, the PD-L1 expression on tumor cells (TCs) and tumor infiltrating immune cells (ICs) was assessed using the 28–8 antibody (EnVisio, Agilent Dako, Santa Clara, Ca). In the nivolumab plus ipilimumab trial, PD-L1 expression was assessed using the 22C3 antibody (pharmDx Agilent Technologies, Santa Clara, CA). In both trials, expression on TCs and ICs was scored as negative (<1% PD-L1 positive cells) or positive (≥1% PD-L1 positive cells) and as a percentage. Readers were blinded to patient outcomes.

Responses were monitored via computed tomography (CT) scans and evaluated according to modified Response Evaluation Criteria in Solid Tumors (mRECIST) for mesothelioma [5] and reported as partial response (PR), stable disease (SD) and progressive disease (PD). Responses were evaluated at 24 weeks. Patients were monitored every-six weeks thereafter (every-eight weeks after 24 weeks of treatment) to calculate the median progression free survival (mPFS) and median

overall survival (mOS).

A Wilcoxon rank-sum test was used to test for response group similarity based on cell densities, where a rejection region of $p < 0.05$ was regarded significant. Multiple testing correction was performed on all P -values where applicable, using the Bonferroni correction.

3. Results

Thirty-four patients treated with nivolumab and thirty-six treated with nivolumab plus ipilimumab, were included. At the time of analysis, median follow-up time for the Nivomes trial was 58.6 months. The updated results show a mPFS of 2.6 months (95 % CI: 2.2 – 5.5) and a mOS of 11.8 months (95 % CI: 9.7 – 15.7). Median follow-up time for the Initiate patients was 46 months (95 % CI 44.2 – 46.4 months). The updated results show a mPFS of 6.2 months (95 % CI 4.2 – 11.0) and a median OS of 22.9 months (95 % CI 12.6 – 32.6).

At baseline, pleural biopsies were obtained from all patients. After 6 weeks of treatment, 31 and 32 on-treatment biopsies were taken from respectively nivolumab and nivolumab plus ipilimumab treated patients. Not all on-treatment biopsies were evaluable: some only contained muscle tissue, others only fibrotic connective tissue or necrosis.

4. Baseline biopsies

At baseline, in the nivolumab alone group, no significant differences in cell densities of CD20+, CD4+, CD8+ and FoxP3+ were seen in biopsies of patients with partial response versus progressive disease. ([suppl Fig. 1](#)).

In contrast, in the nivolumab plus ipilimumab trial, a significant higher cell density of CD4+ ($p = 0.002$), CD8+ ($p = 0.001$), FoxP3+ ($p = 0.001$) and PD-1+ ($p = 0.012$) cells was observed in patients achieving a partial response compared to those with progressive disease. ([Fig. 1](#)).

5. On-treatment biopsies

Cell densities of CD20+, CD4+, CD8+ and FoxP3+ in the nivolumab trial showed no significant change nor difference after six weeks of treatment, not for all responses taken together, nor for partial response

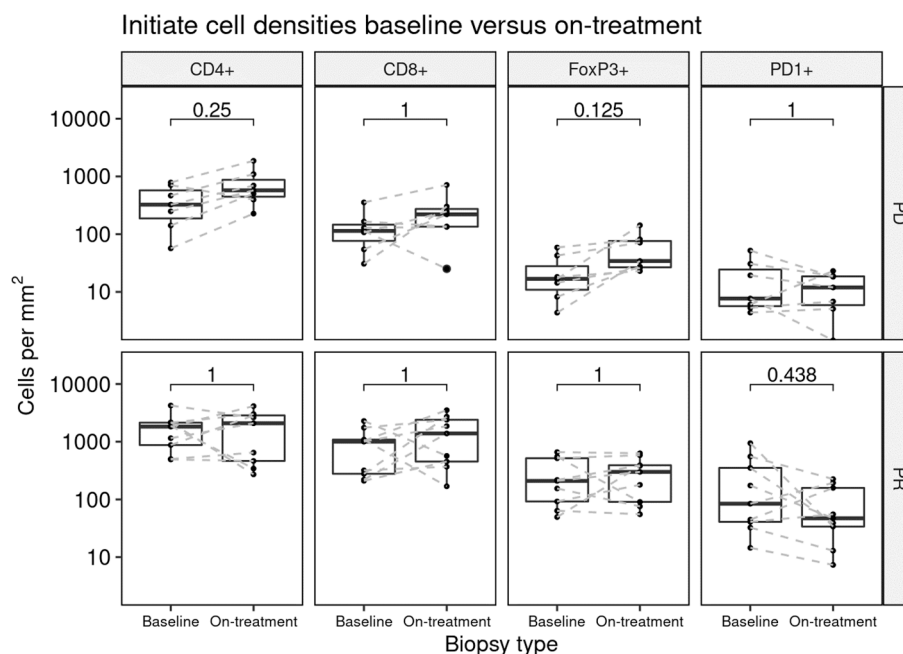


Fig. 2. The number of CD4+, CD8+, FoxP3+ and PD-1+ positive cells per mm² in the nivolumab plus ipilimumab trial, comparing baseline with 6 weeks on-treatment biopsies in patients with progressive disease (PD)(upper plots) and partial response (PR) (lower plots) at 24 weeks.

and progressive disease separately. On-treatment biopsies in nivolumab trial showed no difference between patients having PR or PD (data not shown).

In the nivolumab plus ipilimumab trial no significant change was seen in cell density of CD4+, CD8+, FoxP3+ and PD-1+ cells in patients having progressive disease or partial response (Fig. 2).

6. PD-L1 expression

PD-L1 expression on tumor cells or immune cells was not significantly correlated with PFS or OS (data not shown). Positive PD-L1 expression ($\geq 1\%$) on immune cells was correlated with a higher cell density of CD4+, CD8+ and FoxP3+ positive cells in both nivolumab as nivolumab plus ipilimumab group. (suppl Fig. 2) This correlation was not observed when looking at PD-L1 expression on tumor cells.

7. Discussion

In the nivolumab plus ipilimumab study, biopsies of patients with a partial response have a higher cell density of CD4+, CD8+, FoxP3+ and PD-1+ cells, as compared to biopsies from patients having progressive disease. This is not seen in patients treated with nivolumab alone.

Immune cells in the TME can influence tumor growth and mediate response to therapy. In different tumor types it is shown that the density of tumor-infiltrating lymphocytes (TILs) is associated with response to anti-PD-1 treatment [6] Not only cell density itself, but also the type of immune cells is important; for example, infiltration of CD8+ cytotoxic T cells is associated with higher ORR, longer disease free and overall survival in NSCLC [7].

The TME in MPM is known to be highly immune suppressive, with the presence of a large amount of tumor associated macrophages, myeloid derived suppressor cells and regulatory T cells. Conflicting data on T cell subsets exists. Some studies in MPM suggest that higher levels of CD8+ T cells have a favourable prognostic impact while others found that higher levels are associated with a lower survival [8,9] Higher levels of CD4+ and CD20+ cells and lower levels of FoxP3+ cells are linked to a better outcome, irrespective of therapy [8,10]. Until now, no prospective study has been performed with analysis of biopsies in MPM patients treated with ICI.

In our trial we hoped to identify changes in the TME but no significant change in immune cell subsets was observed after 6 weeks of treatment with nivolumab (plus or minus ipilimumab). Therefore, on-treatment biopsies of mesothelioma do not seem to add information on prediction of effect of ICI treatment, in contrast to melanoma, where adaptive immune signatures in early treatment biopsies are predictive of response to ICIs [11].

In this study we focused on the extreme responses, progressive disease and partial response, to find a signal in studies with a relatively low number of patients. We deliberately excluded patients with stable disease since response analysis in patients with MPM is notoriously difficult. Mesothelioma spreads around the pleura in a circular way making treatment response difficult to determine with unidimensional measurements via modified RECIST criteria.

In our Initiate trial, PD-L1 expression on tumor cells and immune cells was predictive of response to nivolumab plus ipilimumab [4], but did not correlate with PFS or OS. In larger phase III trials, PD-L1 expression on tumor cells was not predictive of response to ICI treatment in MPM [2,12]. Expression on immune cells was, however, not reported. We demonstrated that positive PD-L1 expression ($\geq 1\%$) on immune cells but not on tumor cells is correlated with a higher cell density of CD4+, CD8+ and FoxP3+ positive cells in both the nivolumab and in the nivolumab plus ipilimumab group, pointing to a more inflamed environment. Which of the immune-cells co-expressed PD-L1 is not known from our studies.

The prognostic or predictive value of TIL infiltration or specific T cell subsets alone may be a too simple reflection of reality; integrating expression of proliferation markers, inhibitory receptors, cytokines, sequencing or gene expression data is needed to provide more detailed information on the TME and effect of ICI treatment.

Limitations of this study may be the sample size and limited number of representative on-treatment biopsies. In some patients having a partial response, it was not possible to take a biopsy anymore, or only necrosis was found. Also the timing of the biopsy after 6 weeks of treatment could have influenced the effect. In peripheral blood of lung cancer patients, changes in CD8 subsets are already seen within 4 weeks of PD-1 treatment [13].

Although comparable patient groups were included in both ICI trials, they were not designed to be compared with each other. Besides that,

different staining techniques were used for the biopsies. The immunofluorescence technique in the nivolumab trial was performed many years ago and was hard to validate, and not all markers (that is CD68 and CD163) could be used. Therefore, for the successive nivolumab plus ipilimumab trial, immunohistochemistry was used. This makes it difficult to compare both trials.

Based on recent publications, it would be interesting to focus on the non-epithelioid subgroup, since that has a different micro-environment [9] and a larger benefit of ICI treatment compared to the epithelioid subgroup [2]. Brockwell found high proportions of T lymphocytes and CD45RO+ cells in sarcomatoid MPM having prolonged progression free and overall survival to ICI treatment [14]. In our study there were not enough biopsies available to draw any conclusions on the subgroup of non-epithelioid MPM.

In conclusion, biopsies from patients responding to nivolumab plus ipilimumab treatment show a significant higher cell density of CD4+, CD8+, FoxP3+ and PD-1+ cells at baseline, but no specific changes after 6 weeks of treatment. This observation is a first step in exploring the TME as a predictor of response to guide ICI treatment in MPM. Larger studies are needed, with more detailed analyses of the TME.

Declaration of Competing Interest

The authors declare that they have no known competing financial interests or personal relationships that could have appeared to influence the work reported in this paper.

References

- [1] A. Scherpereel, I. Opitz, T. Berghmans, I. Psallidas, M. Glatzer, D. Rigau, P. Astoul, S. Bötükbaz, J. Boyd, J. Coolen, C. De Bondt, D. De Ruysscher, V. Durieux, C. Faivre-Finn, D. Fennell, F. Galateau-Salle, L. Greillier, M.A. Hoda, W. Klepetko, A. Lacourt, P. McElnay, N.A. Maskell, L. Mutti, J.-C. Pairon, P. Van Schil, J.P. van Meerbeeck, D. Waller, W. Weder, G. Cardillo, P.M. Putora, ERS/ESTS/EACTS/ESTRO guidelines for the management of malignant pleural mesothelioma, *The European respiratory journal*. 55 (6) (2020) 1900953.
- [2] P. Baas, A. Scherpereel, A.K. Nowak, N. Fujimoto, S. Peters, A.S. Tsao, A. S. Mansfield, S. Popat, T. Jahan, S. Antonia, Y. Oulkhovir, Y. Bautista, R. Cornelissen, L. Greillier, F. Grossi, D. Kowalski, J. Rodríguez-Cid, P. Aanur, A. Oukessou, C. Baudalet, G. Zalzman, First-line nivolumab plus ipilimumab in unresectable malignant pleural mesothelioma (CheckMate 743): a multicentre, randomised, open-label, phase 3 trial, *Lancet*. 397 (10272) (2021) 375–386.
- [3] J. Quispel-Janssen, V. van der Noort, J.F. de Vries, M. Zimmerman, F. Lalezari, E. Thunnissen, K. Monkhorst, R. Schouten, L. Schunselaar, M. Disselhorst, H. Klomp, K. Hartemink, S. Burgers, W. Buikhuisen, P. Baas, Programmed Death 1 Blockade With Nivolumab in Patients With Recurrent Malignant Pleural Mesothelioma, *Journal of thoracic oncology : official publication of the International Association for the Study of Lung Cancer*. 13 (10) (2018) 1569–1576.
- [4] M.J. Disselhorst, J. Quispel-Janssen, F. Lalezari, K. Monkhorst, J.F. de Vries, V. van der Noort, E. Harms, S. Burgers, P. Baas, Ipilimumab and nivolumab in the treatment of recurrent malignant pleural mesothelioma (INITIATE): results of a prospective, single-arm, phase 2 trial, *The Lancet Respiratory medicine*. 7 (3) (2019) 260–270.
- [5] S.G. Armato, A.K. Nowak, Revised Modified Response Evaluation Criteria in Solid Tumors for Assessment of Response in Malignant Pleural Mesothelioma (Version 1.1), *Journal of Thoracic Oncology* 13 (7) (2018) 1012–1021.
- [6] P.C. Tumeq, C.L. Harview, J.H. Yearley, I.P. Shintaku, E.J.M. Taylor, L. Robert, B. Chmielowski, M. Spasic, G. Henry, V. Ciobanu, A.N. West, M. Carmona, C. Kivork, E. Seja, G. Cherry, A.J. Gutierrez, T.R. Grogan, C. Mateus, G. Tomasic, J. A. Glaspy, R.O. Emerson, H. Robins, R.H. Pierce, D.A. Elashoff, C. Robert, A. Ribas, PD-1 blockade induces responses by inhibiting adaptive immune resistance, *Nature*. 515 (7528) (2014) 568–571.
- [7] Hu-Lieskovan S, Lisberg A, Zaretsky JM, Grogan TR, Rizvi H, Wells DK, et al. Tumor Characteristics Associated with Benefit from Pembrolizumab in Advanced Non-Small Cell Lung Cancer. *Clinical cancer research : an official journal of the American Association for Cancer Research*. 2019;25(16):5061-8.
- [8] N. Yamada, S. Oizumi, E. Kikuchi, N. Shinagawa, J. Konishi-Sakakibara, A. Shimine, K. Aoe, K. Gemba, T. Kishimoto, T. Torigoe, M. Nishimura, CD8+ tumor-infiltrating lymphocytes predict favorable prognosis in malignant pleural mesothelioma after resection, *Cancer immunology, immunotherapy : CII*. 59 (10) (2010) 1543–1549.
- [9] G. Pasello, G. Zago, F. Lunardi, L. Urso, I. Kern, G. Vlacic, F. Grosso, M. Mencoboni, G.L. Ceresoli, M. Schiavon, F. Pezzuto, A. Pavan, S.E. Vuljan, P. Del Bianco, P. Conte, F. Rea, F. Calabrese, Malignant pleural mesothelioma immune microenvironment and checkpoint expression: correlation with clinical-pathological features and intratumor heterogeneity over time, *Annals of oncology : official journal of the European Society for Medical Oncology*. 29 (5) (2018) 1258–1265.
- [10] H. Ujjie, K. Kadota, J.-I. Nitadori, J.G. Aerts, K.M. Woo, C.S. Sima, W.D. Travis, D. R. Jones, L.M. Krug, P.S. Adusumilli, The tumoral and stromal immune microenvironment in malignant pleural mesothelioma: A comprehensive analysis reveals prognostic immune markers, *Oncoimmunology*. 4 (6) (2015) e1009285.
- [11] Chen PL, Roh W, Reuben A, Cooper ZA, Spencer CN, Prieto PA, et al. Analysis of Immune Signatures in Longitudinal Tumor Samples Yields Insight into Biomarkers of Response and Mechanisms of Resistance to Immune Checkpoint Blockade. *Cancer discovery*. 2016;6(8):827-37.
- [12] D.A. Fennell, S. Ewings, C. Ottensmeier, R. Califano, G.G. Hanna, K. Hill, S. Danson, N. Steele, M. Nye, L. Johnson, J. Lord, C. Middleton, P. Szlosarek, S. Chan, A. Gaba, L. Darlison, P. Wells-Jordan, C. Richards, C. Poile, J.F. Lester, G. Griffiths, G. Price, P. Shaw, J. Cave, J. Naik, A. Ford, T. Geldhart, G. Dancey, D. Papadatos, A. Polychronis, P. Jankowska, A. Scott, J. Gardiner, M. Cominos, L. Campbell, C. MacGregor, L. Mullholand, M. Chitnis, G. Dougherty, Nivolumab versus placebo in patients with relapsed malignant mesothelioma (CONFIRM): a multicentre, double-blind, randomised, phase 3 trial, *The Lancet Oncology*. 22 (11) (2021) 1530–1540.
- [13] A.O. Kamphorst, R.N. Pillai, S. Yang, T.H. Nasti, R.S. Akondy, A. Wieland, G. L. Sica, K.e. Yu, L. Koenig, N.T. Patel, M. Behera, H. Wu, M. McCausland, Z. Chen, C. Zhang, F.R. Khuri, T.K. Owonikoko, R. Ahmed, S.S. Ramalingam, Proliferation of PD-1+ CD8 T cells in peripheral blood after PD-1-targeted therapy in lung cancer patients, *Proc Natl Acad Sci U S A*. 114 (19) (2017) 4993–4998.
- [14] N.K. Brockwell, M. Alamgeer, B. Kumar, G. Rivalland, T. John, B.S. Parker, Preliminary study highlights the potential of immune checkpoint inhibitors in sarcomatoid mesothelioma, *Translational lung cancer research*. 9 (3) (2020) 639–645.